


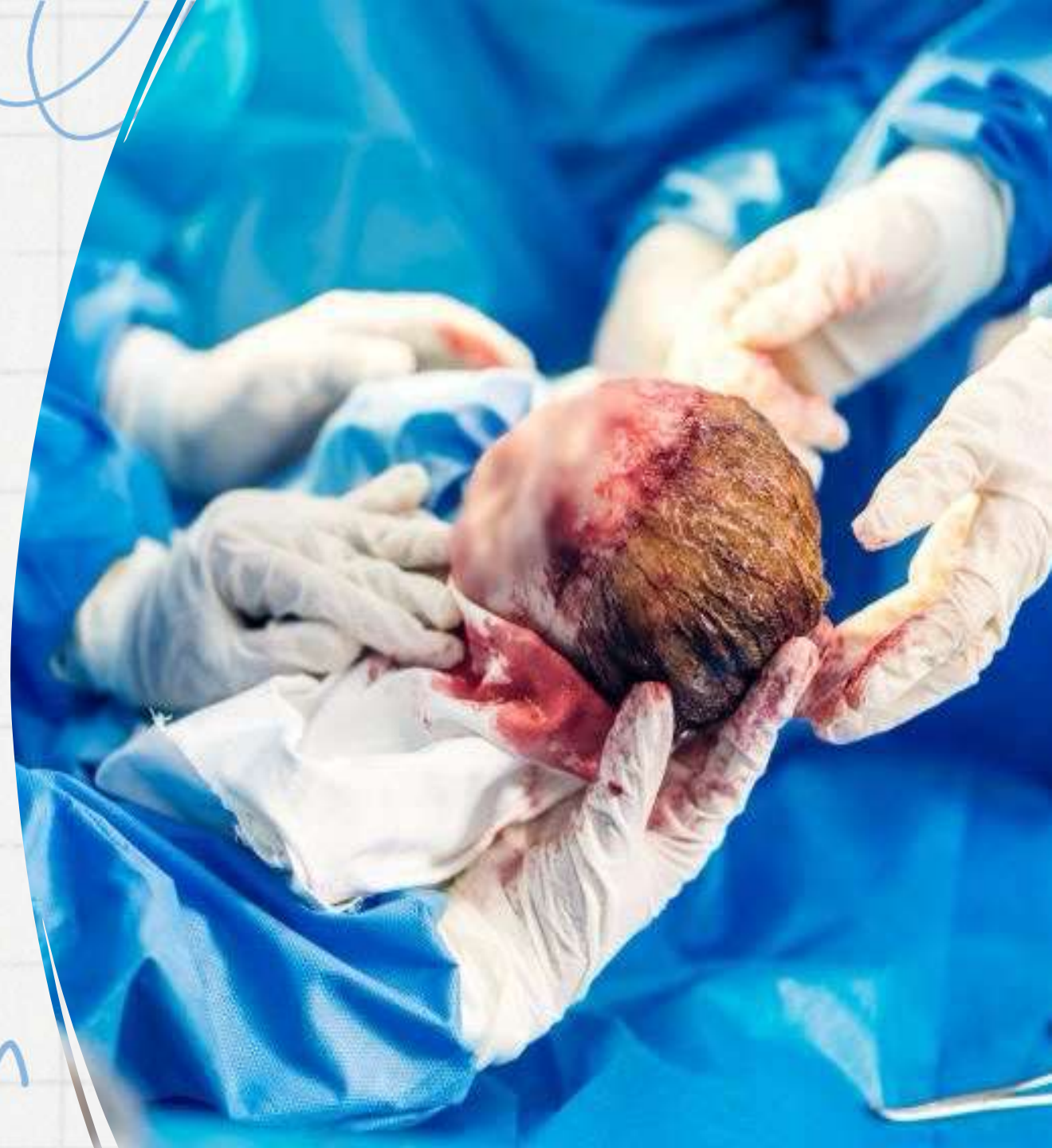
Maternal and neonatal
Birth injuries
Neonatal resuscitation

Dr. Ala'a Awees
Presey by :
Shams Arman

Birth injuries

- **Definition:**
- Are any physical or emotional distress that occurs to the fetus or the mother during labor (specially the 2nd stage). They may be avoidable, or they may be unavoidable and occur despite skilled and competent obstetric care, as in an especially hard or prolonged labor or with an abnormal presentation.



Risk factors for birth injury:

Fetal

Macrosomia

Abnormal presentation

cephalopelvic disproportion

Maternal

Obesity

Pelvic abnormalities

Short stature

Uterine inertia

Delivery

Instrumental delivery:
Vacuum & Forceps

Prolonged labour

Skills of the obstetrician

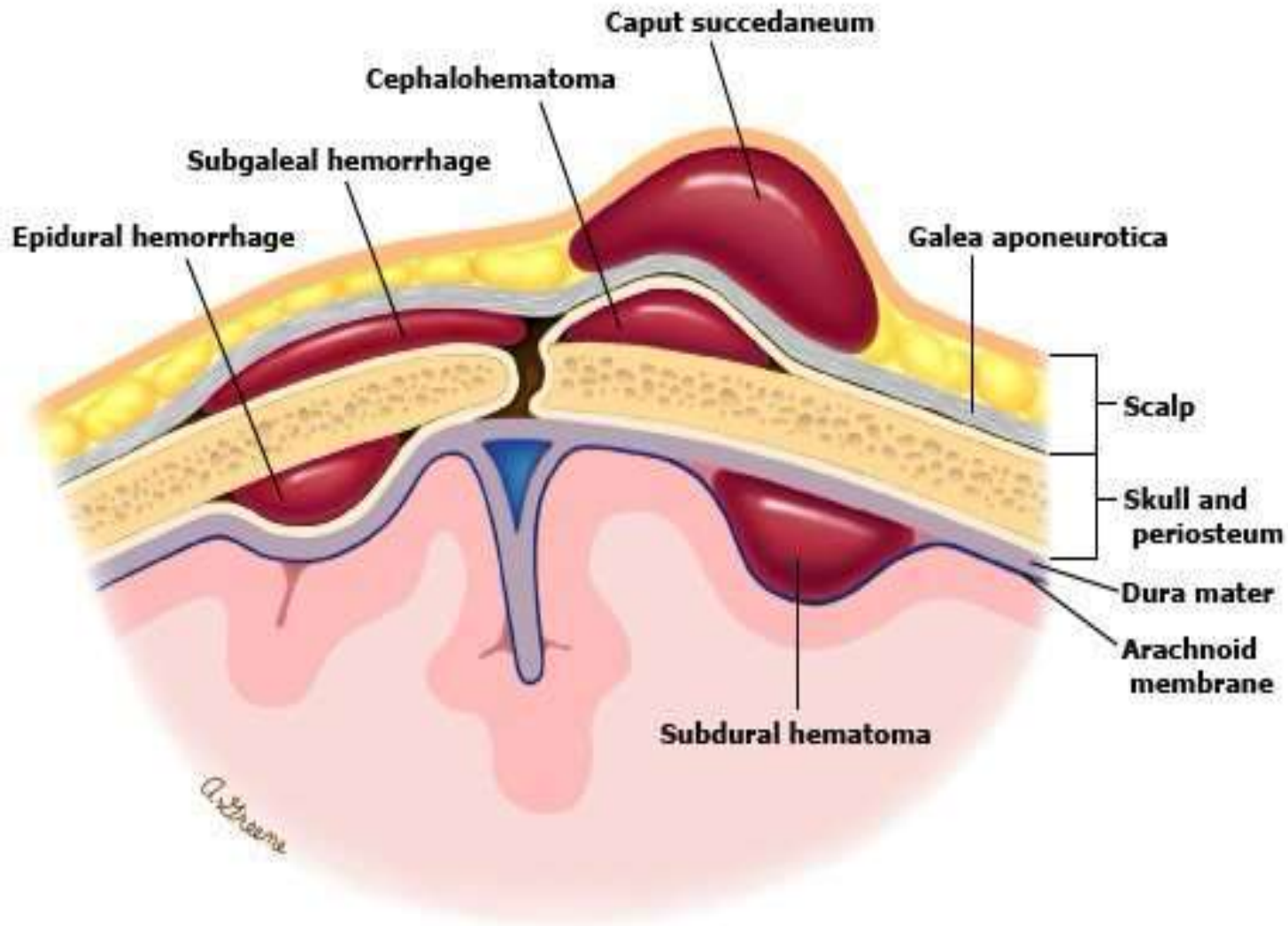
TYPES OF BIRTH INJURIES:

Newborn injuries:

- **Extracranial injuries:** Caput succedaneum, Subgaleal hematoma & Subperiosteal hematoma.
- **Intracranial injuries:** Epidural, Subdural, Subarachnoid, Intracerebral & Intraventricular
- **Facial injuries:** Nasal septal dislocation & Ocular injuries.
- **Neurological injuries:** Bell's palsy, Erb's palsy & Klumpke's paralysis.
- **Soft tissue injuries:** Bruising, Abrasions , Lacerations, Fat necrosis & Torticollis.
- **Fractures:** Clavicle , Skull , Humerus & Femur.
- **Abdominal injuries.**

Maternal injuries:

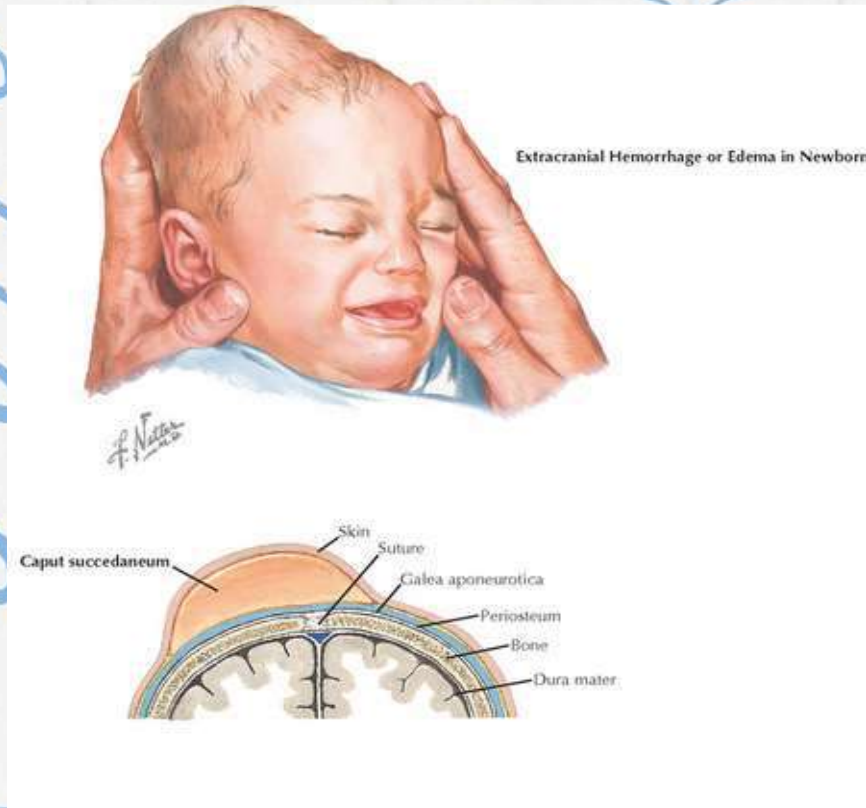
- Perineal tears.
- Vulvar hematoma.
- Uterine rupture.



Extracranial injuries :

- Caput succedaneum
- Subgaleal hematoma .
- Subperiosteal hematoma.

-Caput Succedaneum:



- a frequently observed lesion, is characterized by a Serum, blood, or both accumulate above the periosteum (subcutaneous, above aponeurosis) in the presenting part during labor.
- This extravasation results from the higher pressure of the uterus or vaginal wall on those areas of the fetal head that border the caput.
- Causes:
 1. normal delivery
 2. Vacuum application
 3. Prolonged or obstructed labor

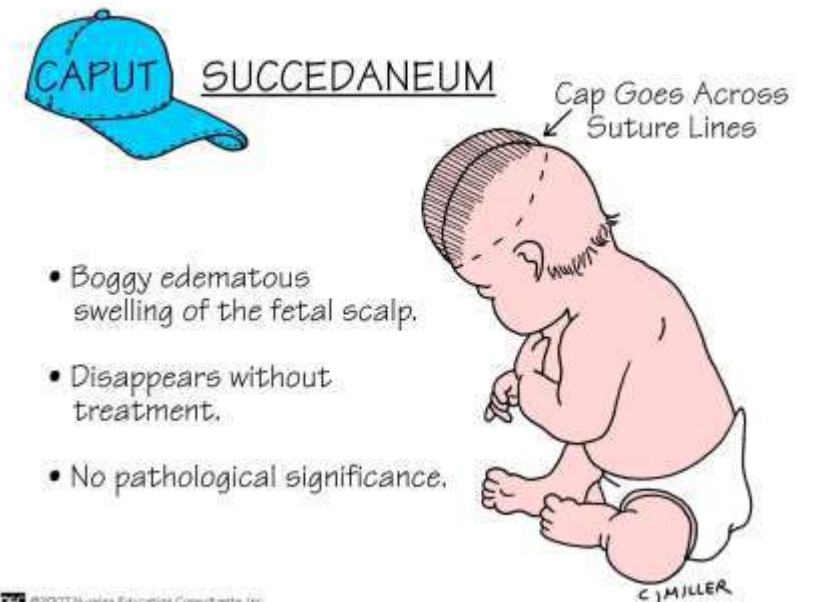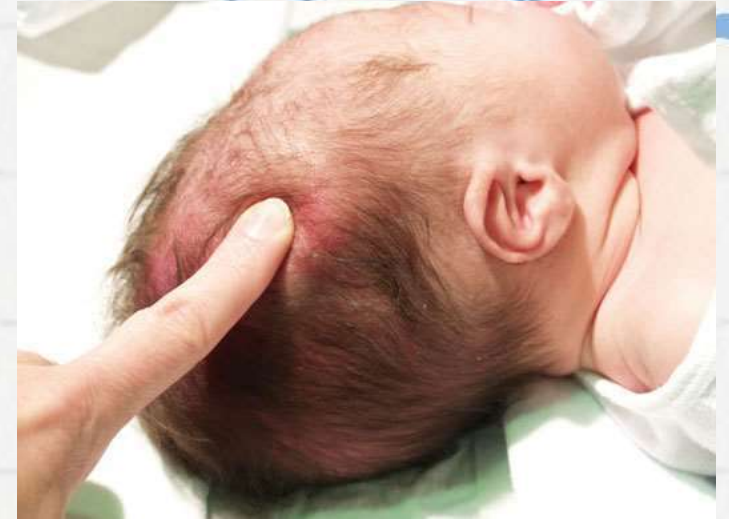Caput Succedaneum

Clinical Manifestations

- soft swelling is usually a few millimeters thick (pits on pressure) .
- with overlying petechiae, purpura, or ecchymoses.
- across the midline of the skull and across suture lines.
- caput may obscure various sutures and fontanelles.

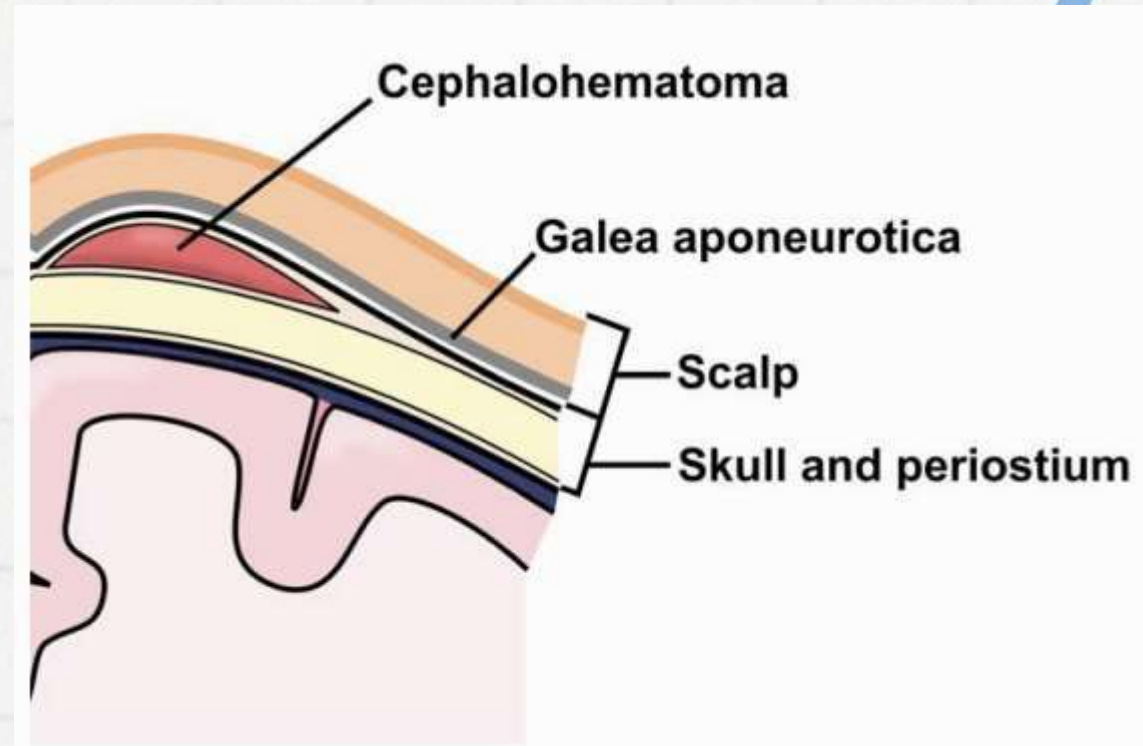
Treatment

A caput succedaneum usually resolves within several days. Usually , no specific treatment is indicated. Rarely, a hemorrhagic caput may result in shock and require blood transfusions .



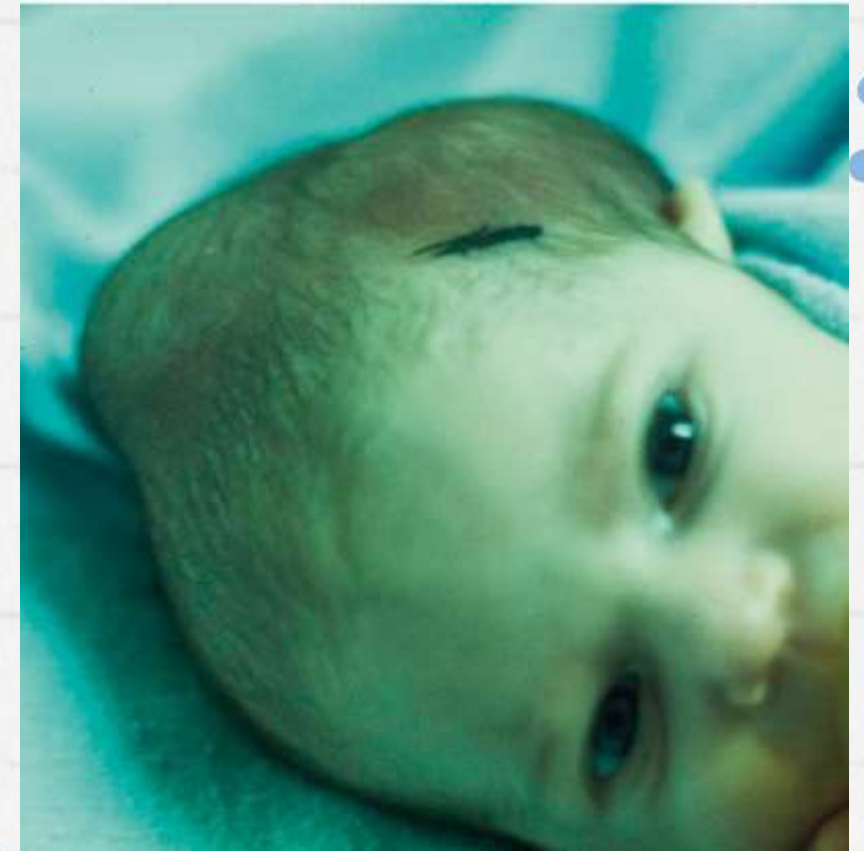Cephalhematoma :

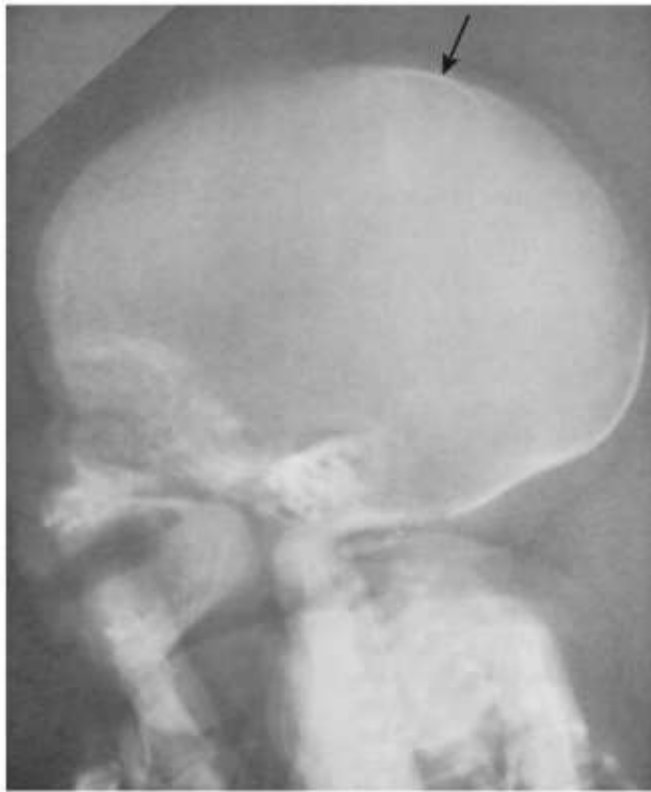- Cephalhematoma is an infrequently seen subperiosteal collection of blood overlying a cranial bone.
- A cephalhematoma is caused during labor or delivery by a rupture of diploic blood vessels that traverse from skull to periosteum. Repeated buffeting of the fetal skull against the maternal pelvis during a prolonged or difficult labor and mechanical trauma caused by use of forceps and vacuum suction devices in delivery have been implicated.



• Clinical Manifestations :

- The bleeding is sharply limited by periosteal attachments to the surface of one cranial bone; there is no extension across suture lines.
- The overlying scalp is not discolored.
- Because subperiosteal bleeding is slow, the swelling may not be apparent for several hours or days after birth. The swelling is often larger on the second or third day , when sharply demarcated boundaries are palpable.
- The cephalhematoma may feel fluctuant and often is bordered by a slightly elevated ridge of organizing tissue that gives the false sensation of a central bony depression.
- It may be associated with an underlying linear, non depressed skull fracture in a small percentage of infants.
- may be infected, calcified ,lead to hyperbilirubinemia (blood break down)





- **Radiographic manifestations :**

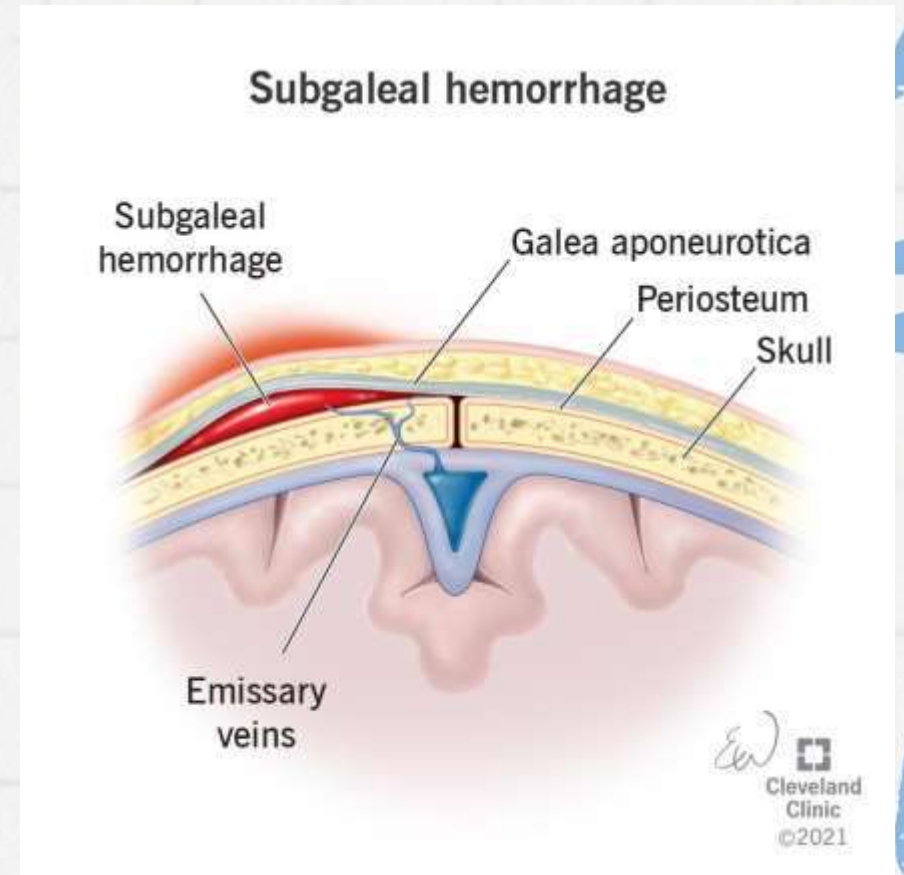
- vary with the age of the cephalhematoma. During the first 2 weeks, bloody fluid results in a shadow of water density. At the end of the second week, bone begins to form under the elevated pericranium at the margins of the hematoma; the entire lesion is progressively overlaid with a complete shell of bone.

Treatment :

No therapy is indicated for the uncomplicated cephalhematoma because more than 80% resolve by gradual hemolysis and resorption in 3 to 4 weeks. When the hematoma does not resolve spontaneously, it may get organized, and calcification may be seen. It may still get absorbed slowly and often disappears over 3 to 6 months. Persistent calcification that is not resolved by time may be an indication for surgical excision.

Subgaleal Hemorrhage :

- Subgaleal Hemorrhage Subgaleal hemorrhage is a collection of blood in the soft tissue space between the galea aponeurotica and the periosteum of the skull .
- The most common predisposing factor is difficult operative vaginal delivery, particularly mid forceps delivery and vacuum extraction.¹³ The risk for subgaleal hemorrhage may be reduced by the use of softer silicone vacuum cups instead of the original rigid metallic ones.
- **The major risk factors:**
- include coagulopathies , prematurity, macrosomia, fetal dystocia, precipitous labor, intrapartum hypoxia, male sex, cephalopelvic disproportion, prolonged labor, and nulliparity.



vacuum traction pulling the scalp away from stationary bony calvarium

open the subgaleal space and causing the bridging vessels to tear and bleed into the subgaleal space.

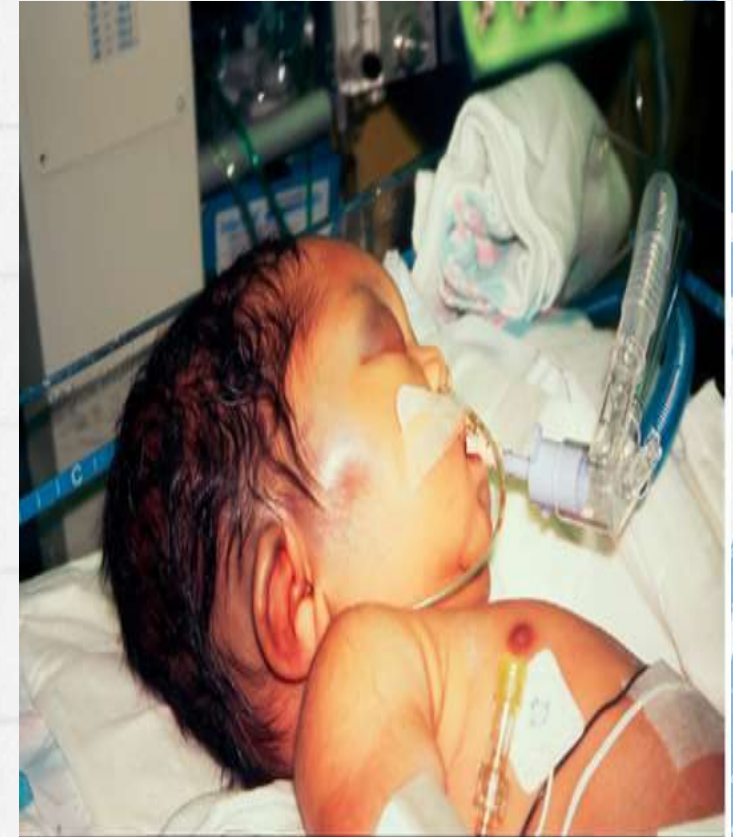
The loose connective tissue of the subgaleal space is extremely expansive and extends over the entire area of the scalp.

The space can accommodate the entire neonatal blood volume (250 mL or more in a term baby)

leading to hypovolemic shock, disseminated intravascular coagulation, and multiorgan failure, resulting in death in up to 14% of the cases

Clinical Manifestations

- Early manifestations may be limited to pallor, hypotonia, and diffuse swelling of the scalp. The development of a fluctuating mass straddling cranial sutures, fontanelles, or both is highly suggestive of the diagnosis
- Blood accumulates beneath the aponeurotic layer, ecchymotic discoloration of the scalp is a later finding. This is often associated with pitting edema and progressive posterior spread toward the neck and lateral spread around the ears, frequently displacing the ears anteriorly . Periorbital swelling and ecchymosis also are commonly observed.
- Eventually, hypovolemic shock, multiorgan failure, and signs of cerebral irritation develop. Massive lesions can cause extracranial cerebral compression, which may lead to rapid neurologic decompensation

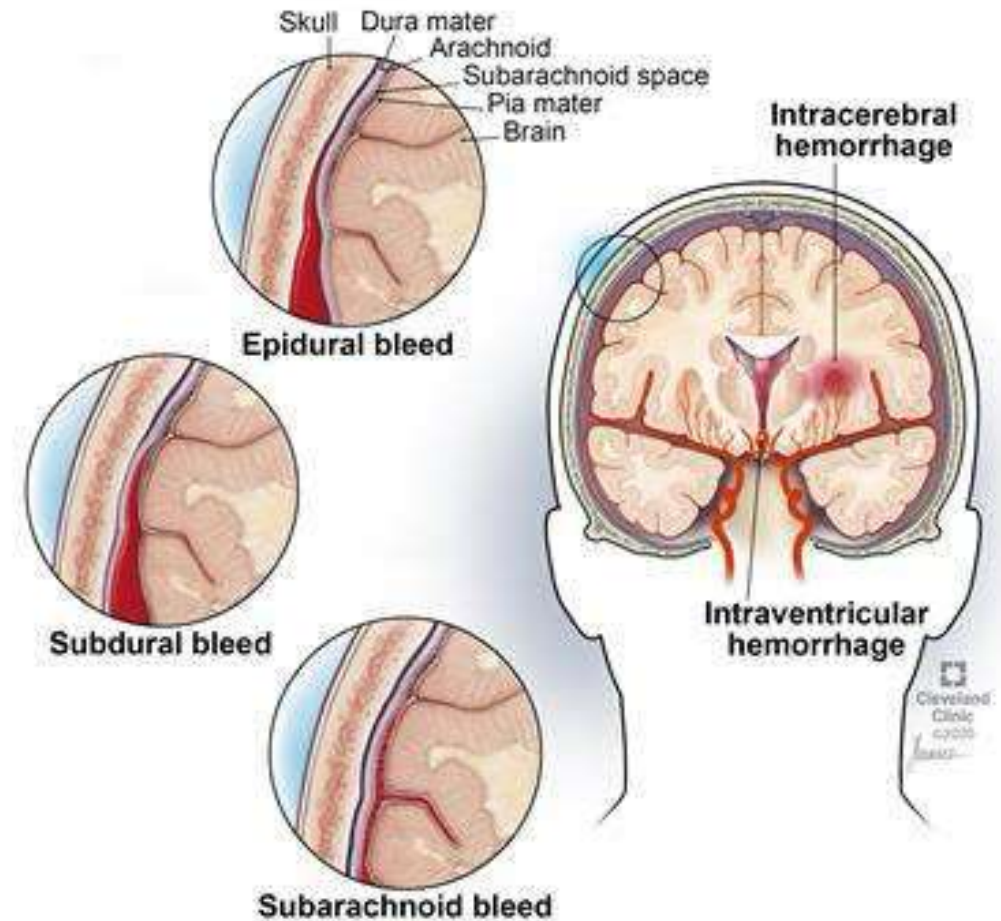



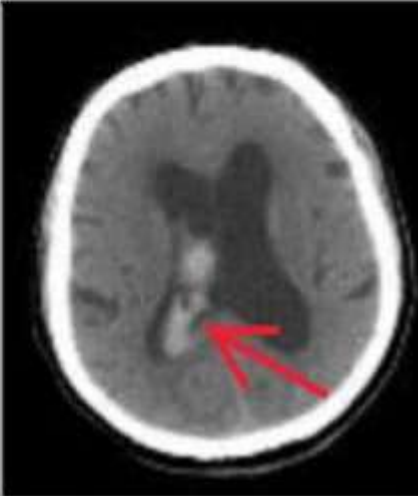

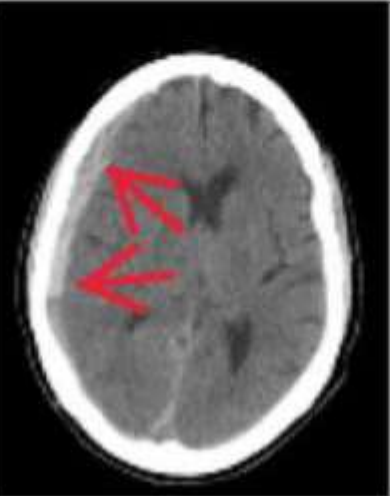
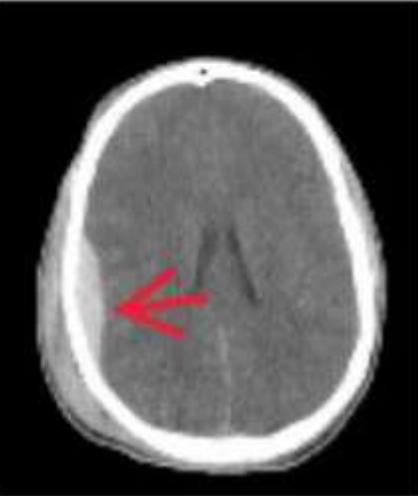
Treatment :

- Prompt restoration of blood volume with fresh frozen plasma or blood is essential. In the presence of continued deterioration, neurosurgery may be considered as a last resort . A bicoronal incision allows for exposure of the subgaleal space. Bipolar cauterization of any bleeding points can then be accomplished, and a drain can be left in the subgaleal space.
- 14% of infants with subgaleal hemorrhage —> die .
- long-term prognosis for survivors is generally good.

Infants intracranial hemorrhage (Brain bleeds)

- Infant intracranial hemorrhages (otherwise known as brain bleeds) are birth injuries that range from minor to extremely severe.
- They can be caused by birth asphyxia (oxygen deprivation during or around the time of birth) or birth trauma (injuries caused by excessive mechanical force to the baby's head)
- In many cases, may these complications stem from medical negligence
- **Intracranial injuries:** Epidural, Subdural, Subarachnoid, Intracerebral & Intraventricular

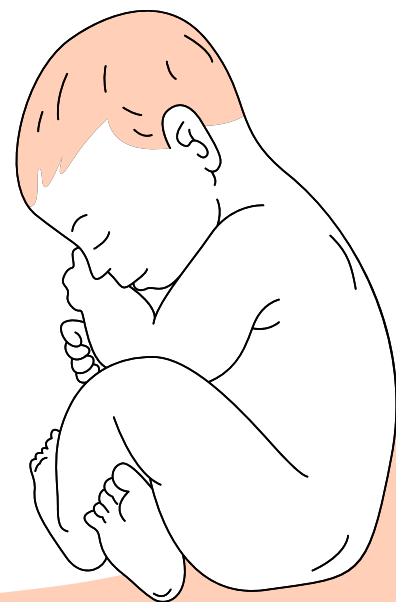
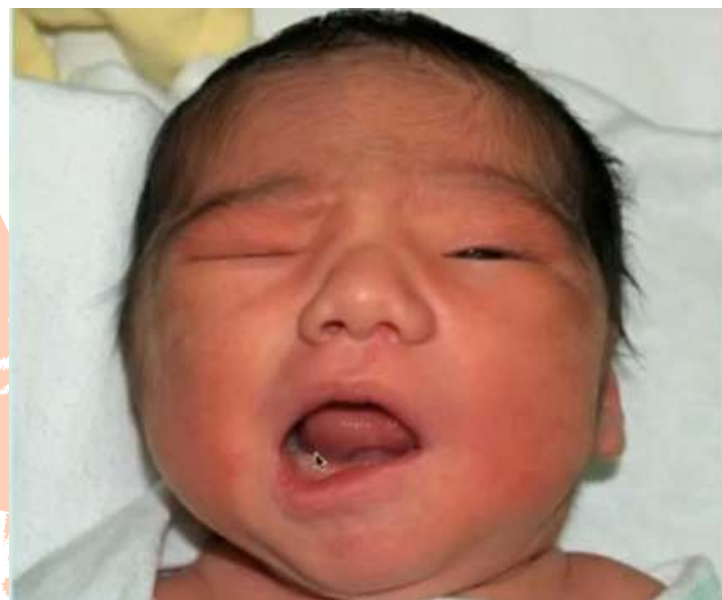

	Intraparenchymal	Intraventricular	Subarachnoid	Subdural	Epidural
Location	Inside of the brain	Inside of the ventricle	Between the arachnoid and the pia mater	Between the Dura and the arachnoid	Between the dura and the skull
Imaging					
Mechanism	High blood pressure, trauma, arteriovenous malformation, tumor, etc	Can be associated with both intraparenchymal and subarachnoid hemorrhages	Rupture of aneurysms or arteriovenous malformations or trauma	Trauma	Trauma or after surgery
Source	Arterial or venous	Arterial or venous	Predominantly arterial	Venous (bridging veins)	Arterial
Shape	Typically rounded	Conforms to ventricular shape	Tracks along the sulci and fissures	Crescent	Lentiform
Presentation	Acute (sudden onset of headache, nausea, vomiting)	Acute (sudden onset of headache, nausea, vomiting)	Acute (worst headache of life)	May be insidious (worsening headache)	Acute (skull fracture and altered mental status)

Facial Nerve Palsy

Etiology

- Compression of the peripheral portion of the nerve either near the stylomastoid for men through which the nerve emerge or where the nerve travels the Ramus of the mandible
- The nerve may be compressed by **forceps**
- Or after spontaneous delivery in which prolonged depression was apply by the maternal sacral promontort



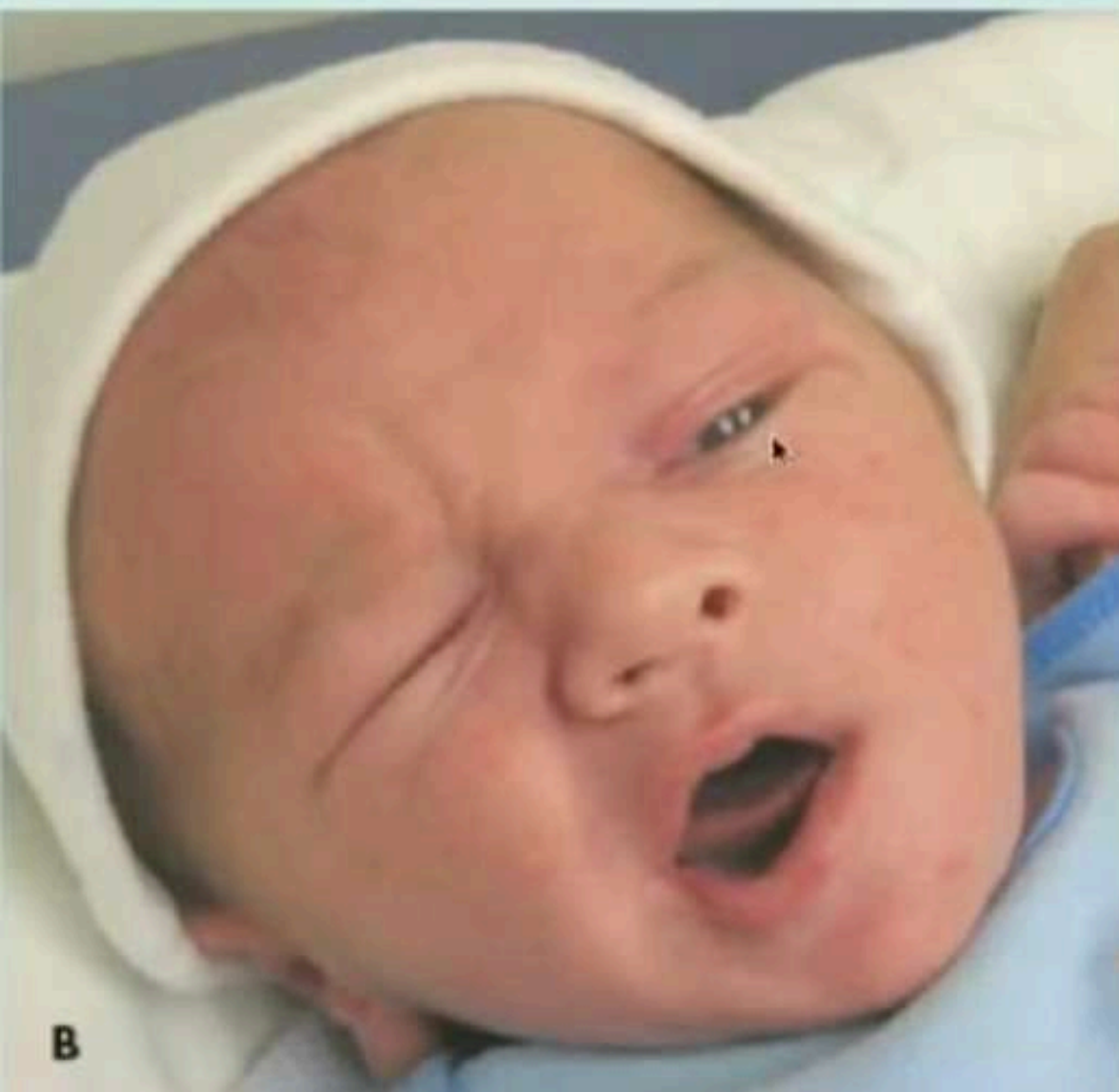Clinical picture

1. Absence of nasolabial fold
2. Loss of wrinkling of the forehead
3. Impaired closure of the eye
4. Mouth does not move down the same way on both sides while crying

Treatment

Tx: Observation. In the meantime, provide the infant w/ lubricating eye drops. Typically this will resolve within a week. If it doesn't, consult peds neuro; sx that persist may be due to an absence of the facial n. or a congenital syndrome.

Facial nerve injury



B

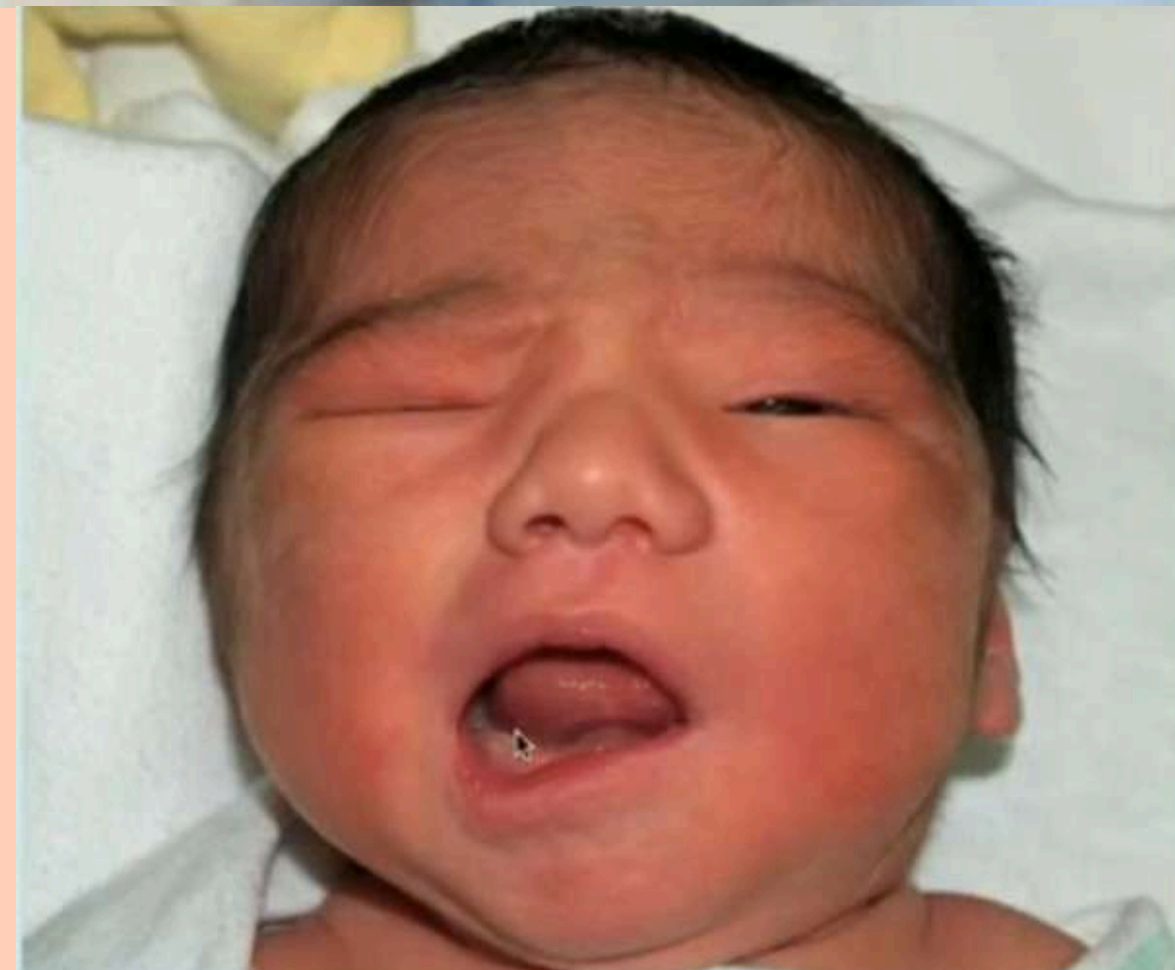no wrinkles on
right sided forehead

Left Side (Normal)

Right eye remains
open during crying

Drooping of right
corner of mouth

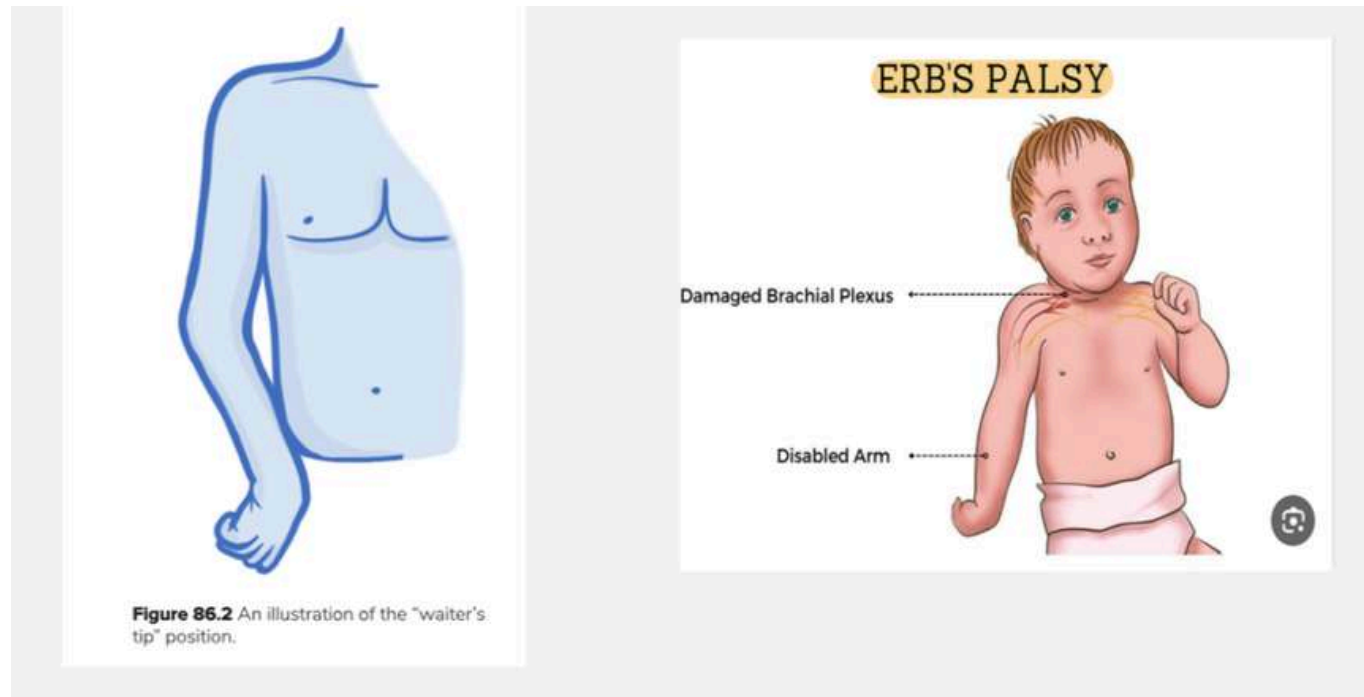
Symptoms



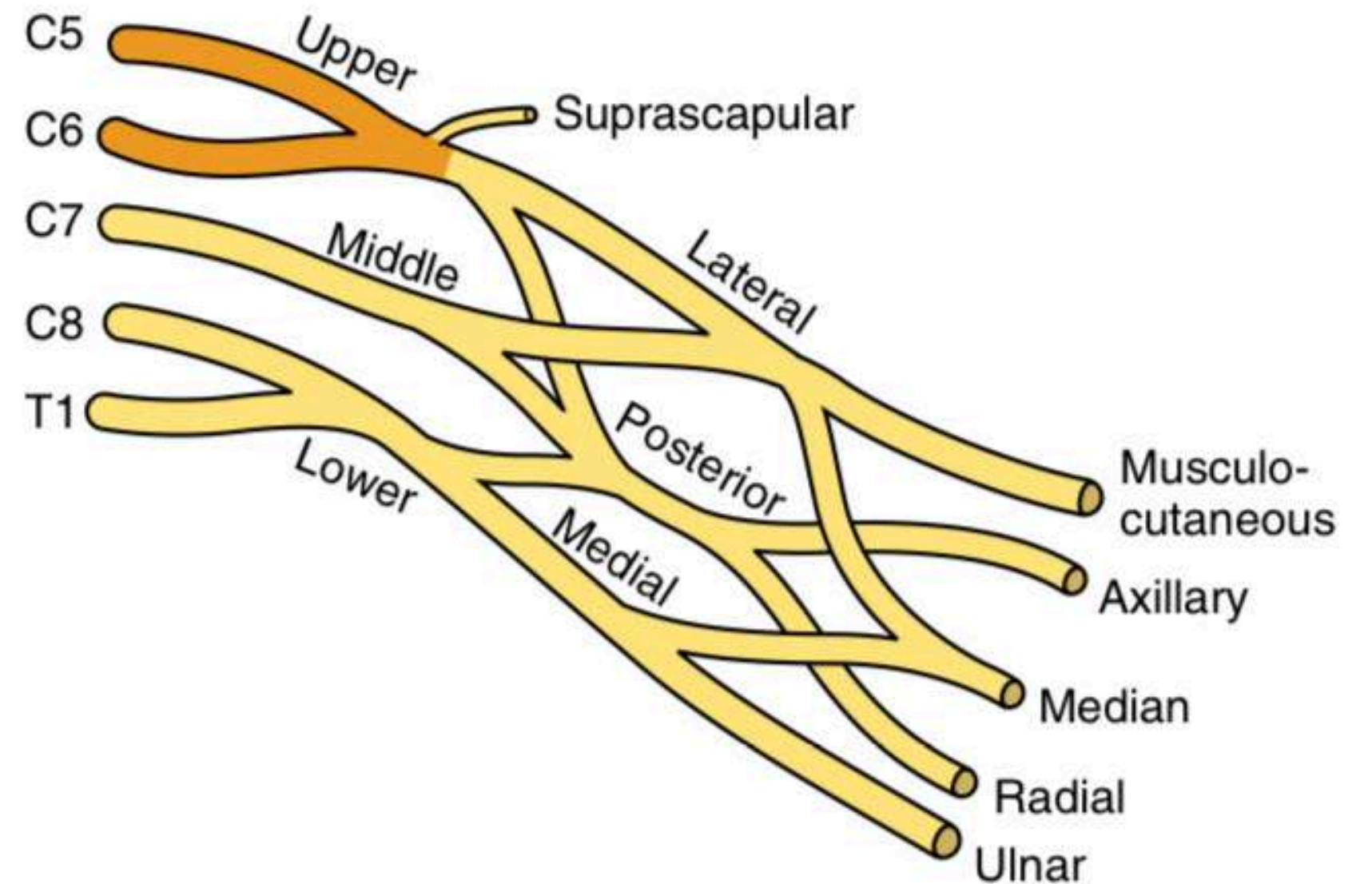
Neonatal brachial plexus palsy:

1. **Erb paralysis** result from injury of the fifth and sixth cervical roots of the brachial plexus

2. **Klumpke** or lower arm paralysis results from injury of the eighth cervical and first thoracic roots



3. **Paralysis of the entire arm**



Erb's palsy (C5 -C6)

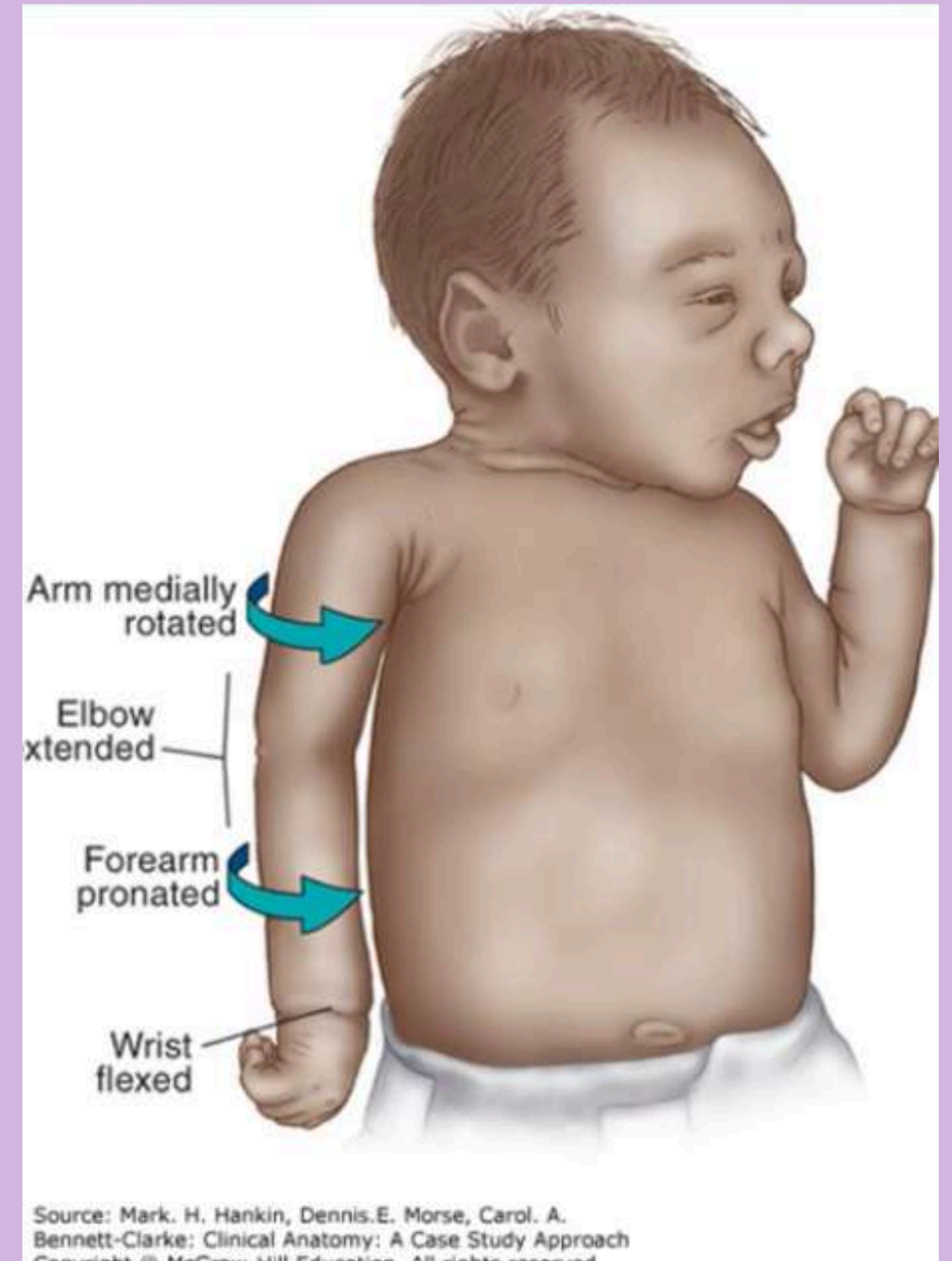
* Excessive lateral traction on the neck during delivery. →

Injury to the upper trunk of the brachiales.
→ erb's palsy

● The arm is adducted and internally rotated, with extension at the elbow, pronation of the forearm, and flexion of the wrist.

● Moro, biceps, and radial reflexes are absent on the affected side.

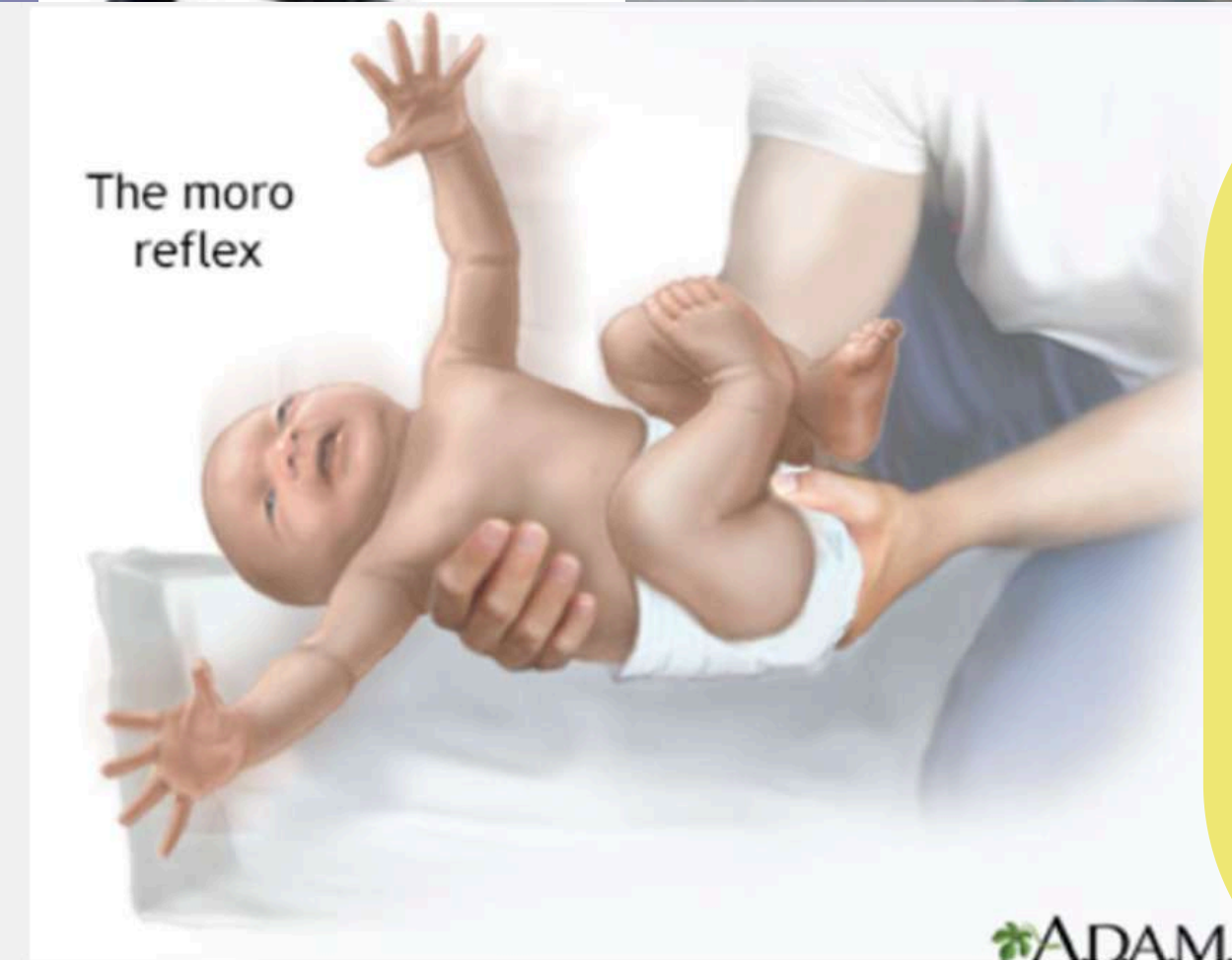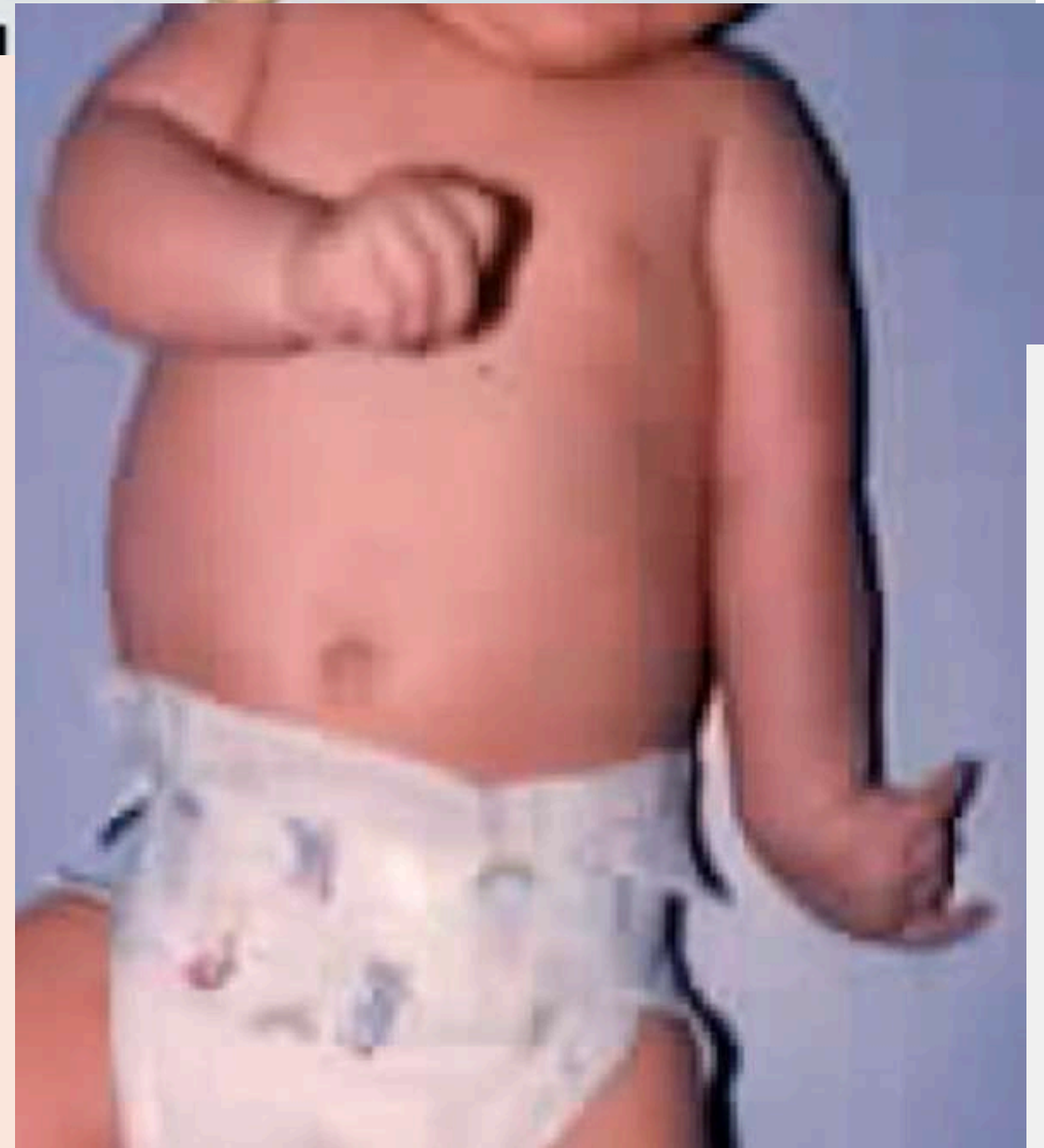
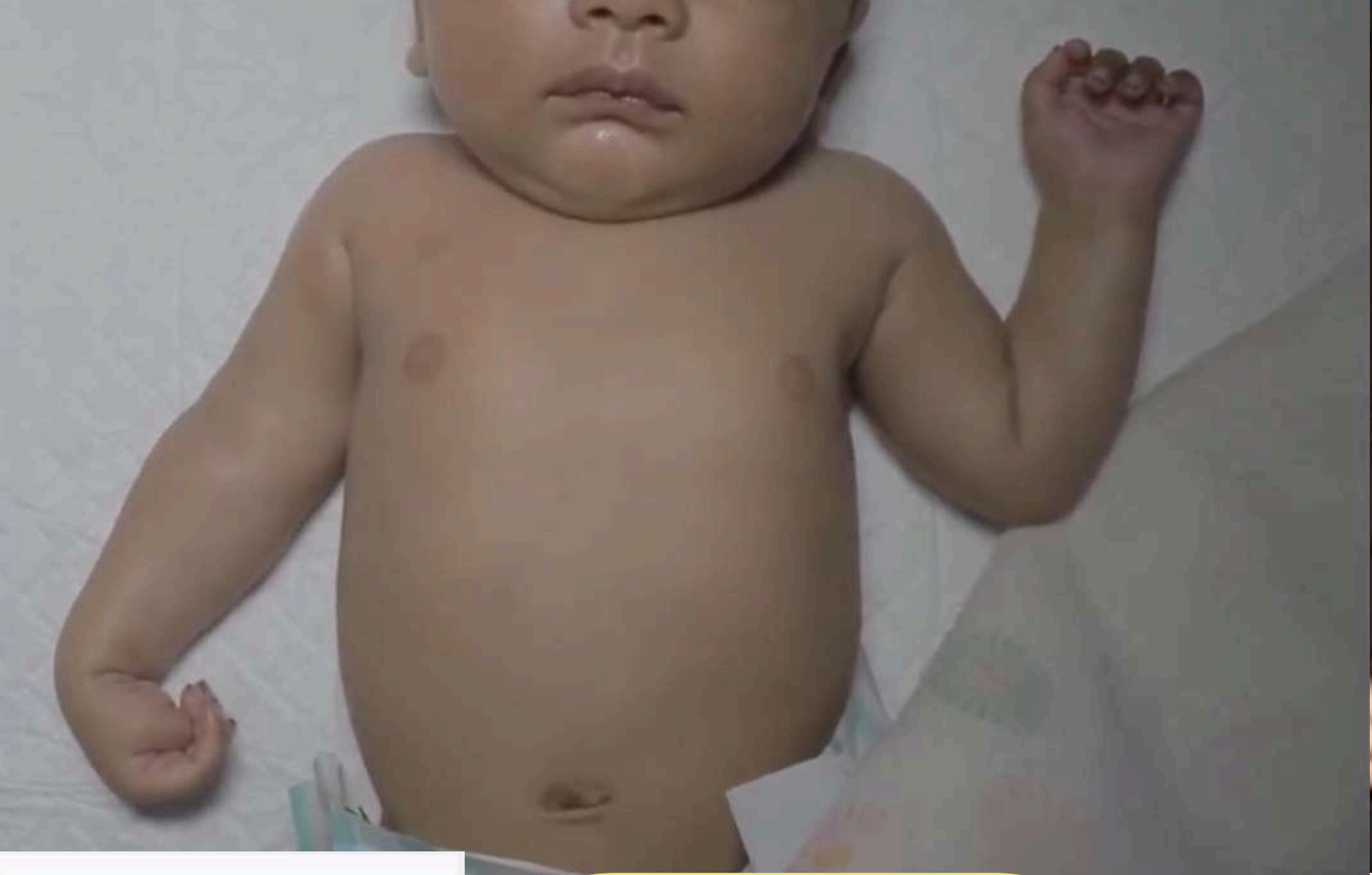
● The grasp reflex is usually present.



Source: Mark. H. Hankin, Dennis.E. Morse, Carol. A. Bennett-Clarke: Clinical Anatomy: A Case Study Approach Copyright © McGraw-Hill Education. All rights reserved.



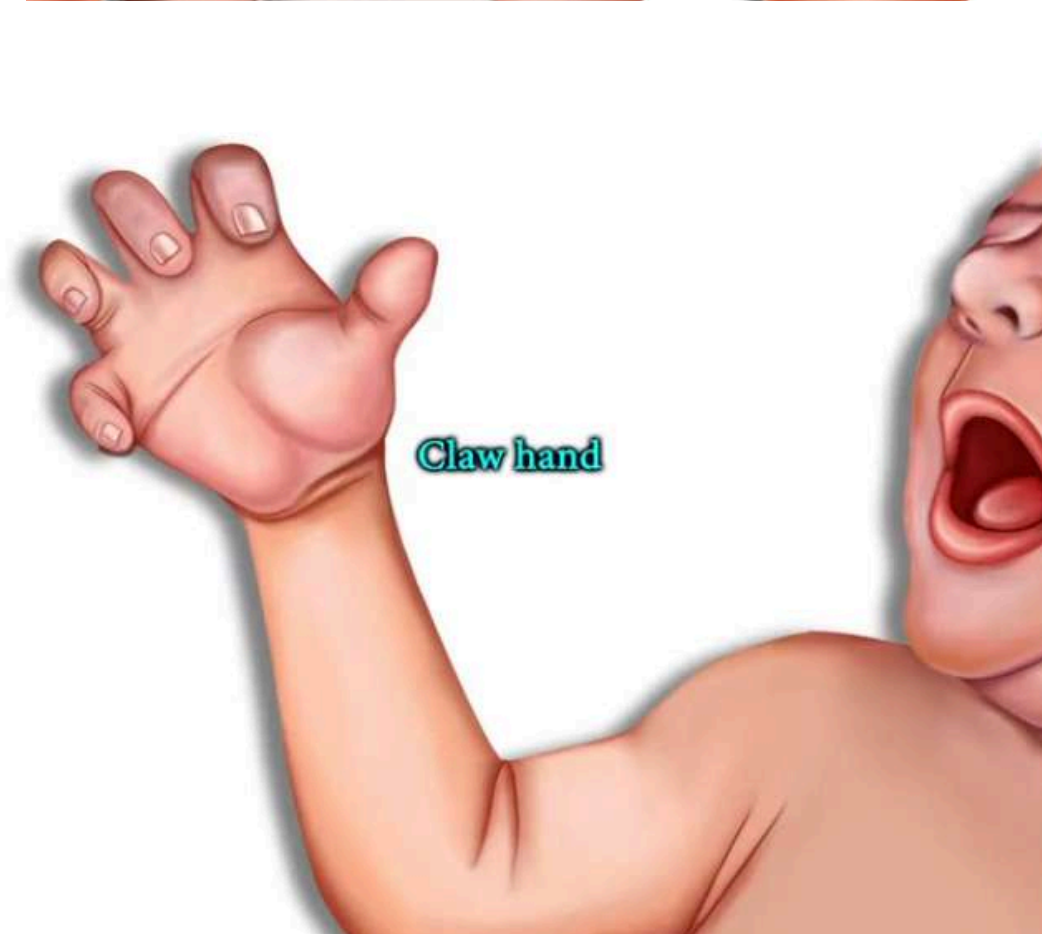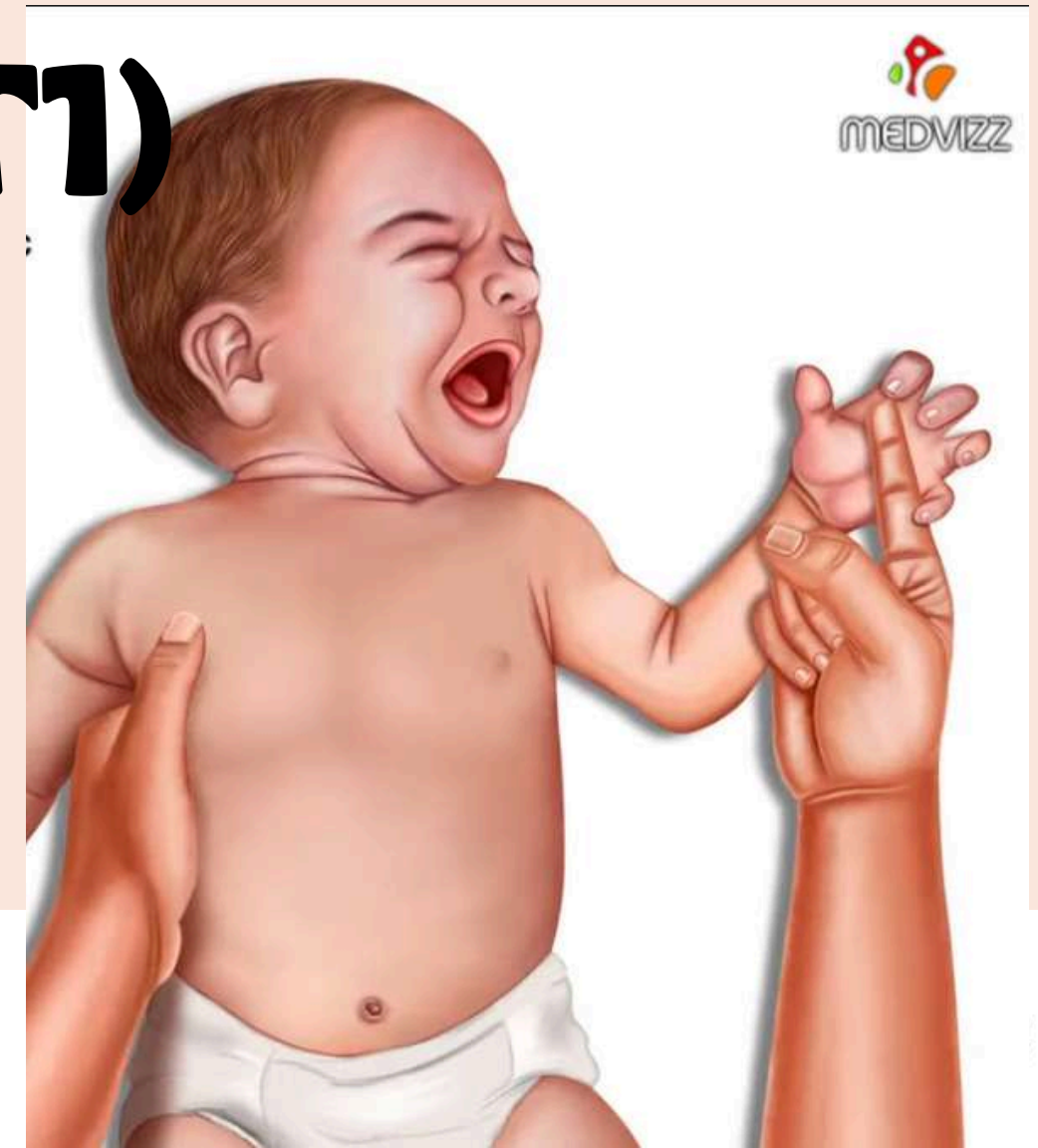
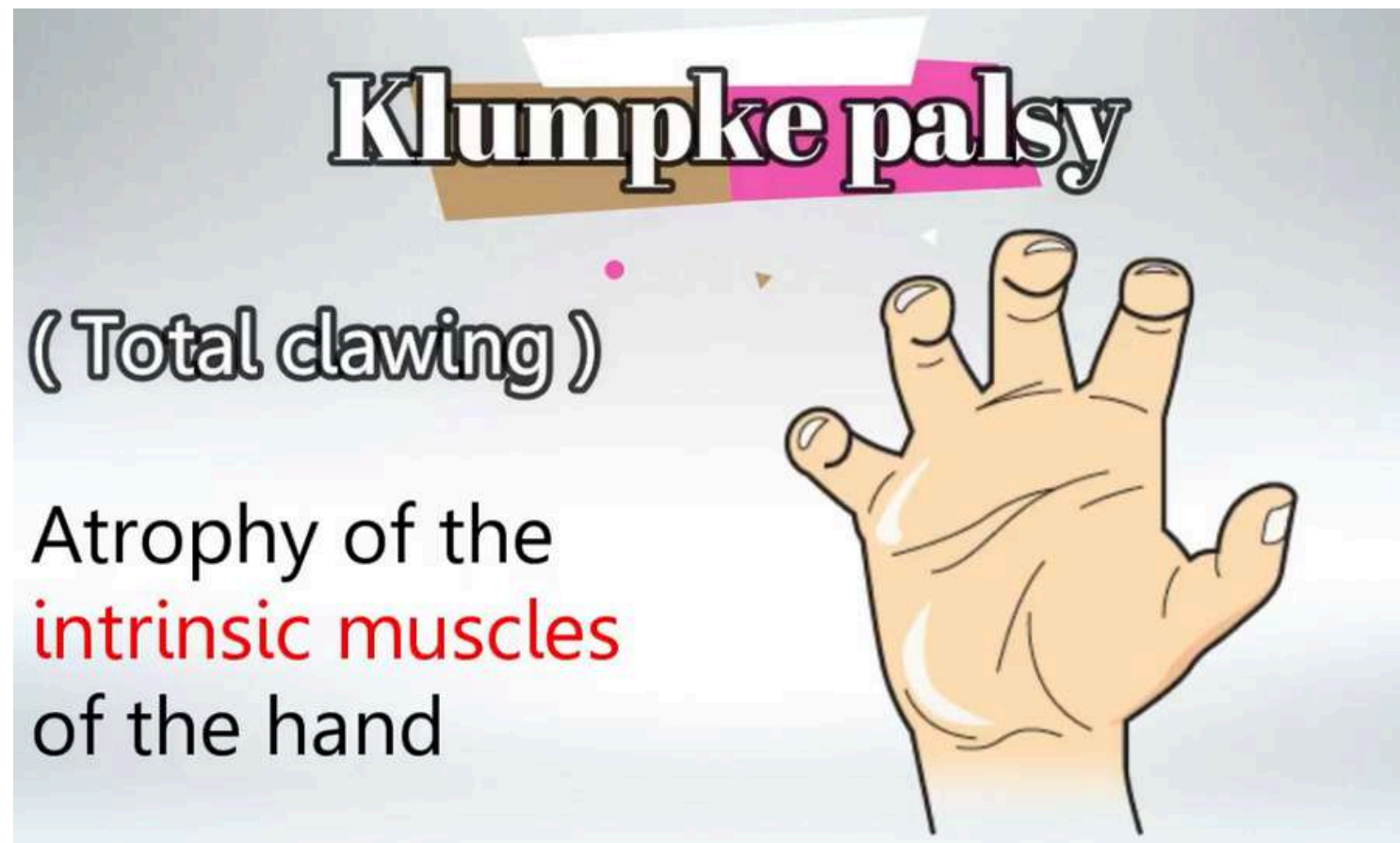ERB PALSY



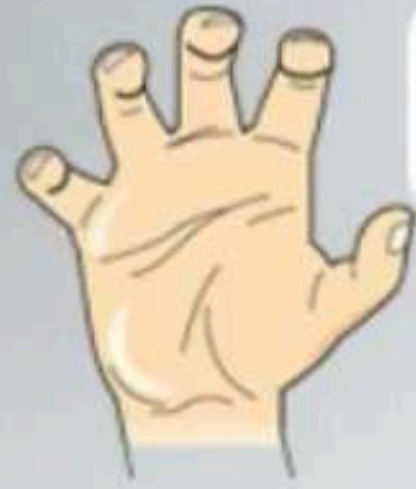The Moro reflex is a normal reflex for an infant when he or she feels like they are falling

Klumpke's paralysis (C8, T1)

- Excessive traction of the arm during delivery i
→ injury to the lower trunk of the brachial plexus
→ klumpke's palsy
- Lower arm paralysis involves the intrinsic muscles of the hand and the long flexors of the wrist and fingers.
- The grasp reflex is absent;



- Brachial plexus injury is associated with shoulder dystocia, which more commonly leads to Erb palsy than Klumpke palsy.



KLUMPKE PALSYP

-upward force on arm
or grabbing a tree branch

-Tear of **Lower** Trunk

-Total **clawing** of hand



ERB PALSYP

-lateral traction of neck

-Tear of **Upper** Trunk

-**waiter's tip** arm

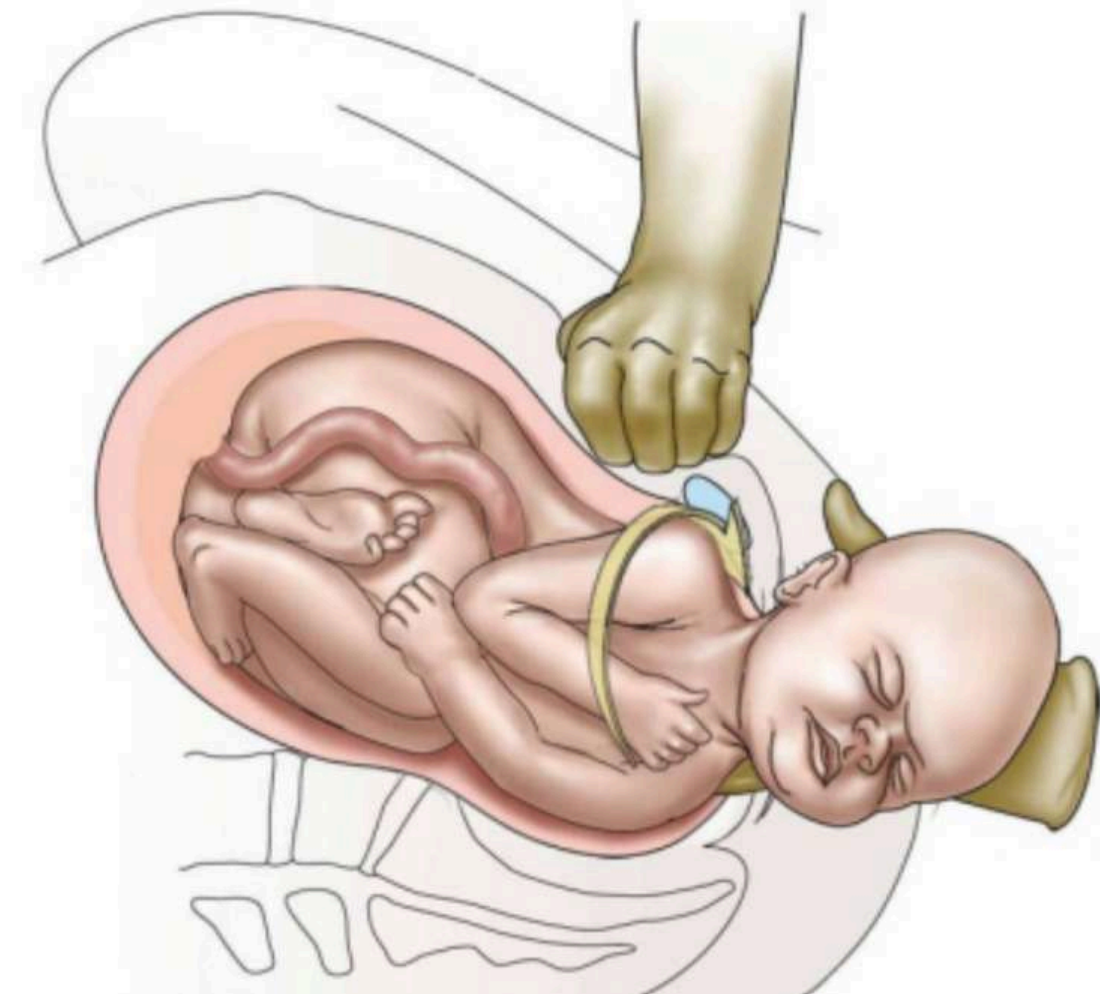Shoulder dystocia

Definition:

.Difficulty with delivery of the fetal shoulders, after delivery of fetal head

Risk factors:

1. Large baby
2. Small mother
3. Maternal obesity
4. Diabetes mellitus
5. Postmaturity
6. Previous shoulder dystocia
7. Prolonged first and second stage of labour
8. Assisted vaginal delivery.



Complication

A –Fetal:

- 1.Hypoxia and cerebral damage: due to occlusion of the vessels in the fetal neck after 5 minutes, if the baby is already compromised, this may occur earlier.
- 2.Nerve and brachial plexus damage (Erb's palsy): due to inappropriate traction on the head causing lateral flexion of the head on the neck.
- 3.Fetal death
- 4.Bone fractures: like humerus and clavicular fracture.

B –Maternal:

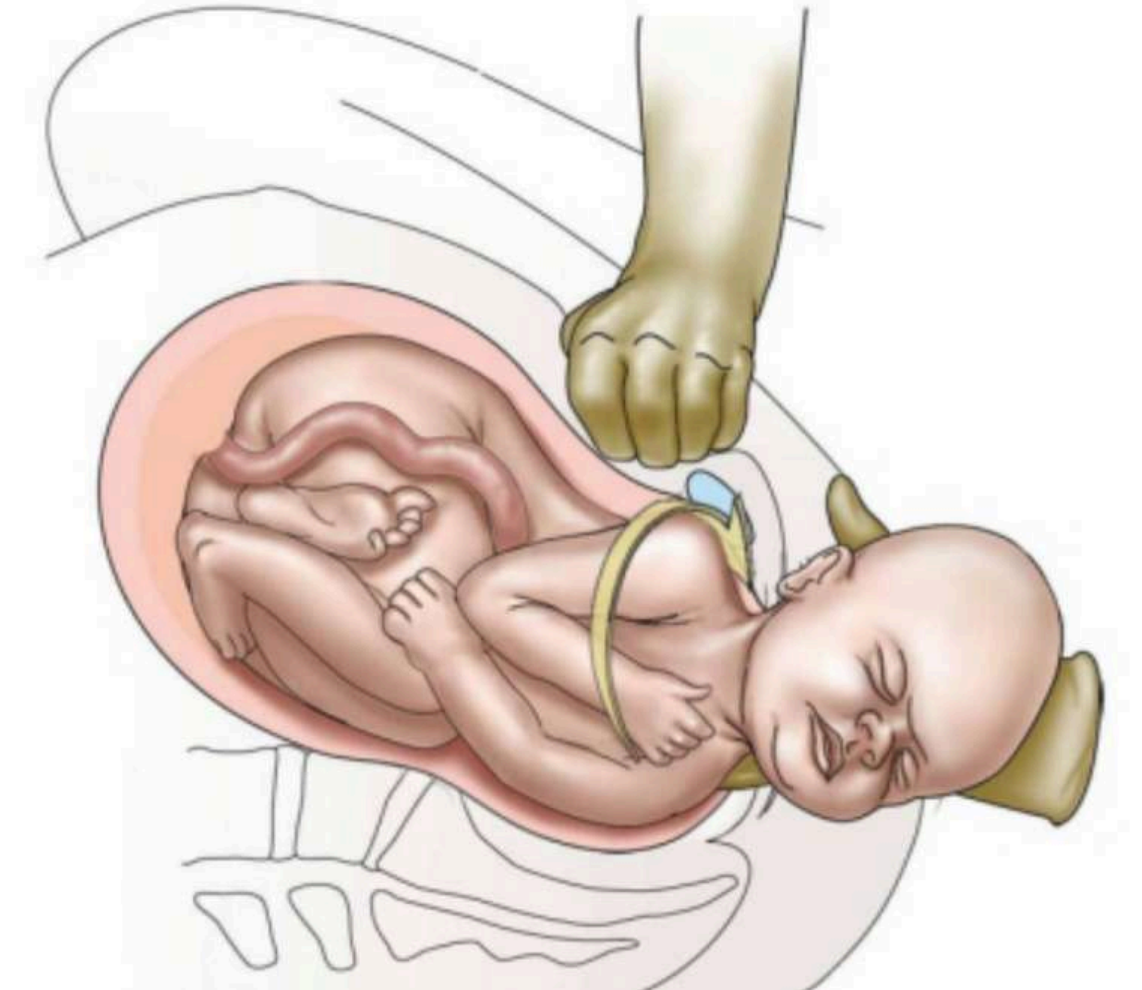
Postpartum hemorrhage is the major maternal risk from shoulder dystocia, usually from uterine atony, but also from vaginal and cervical lacerations, trauma to the genital tract, uterine rupture and puerperal sepsis.

Diagnosis: the head recoils against the perineum after delivery (turtle's sign) with failure of restitution

Management:

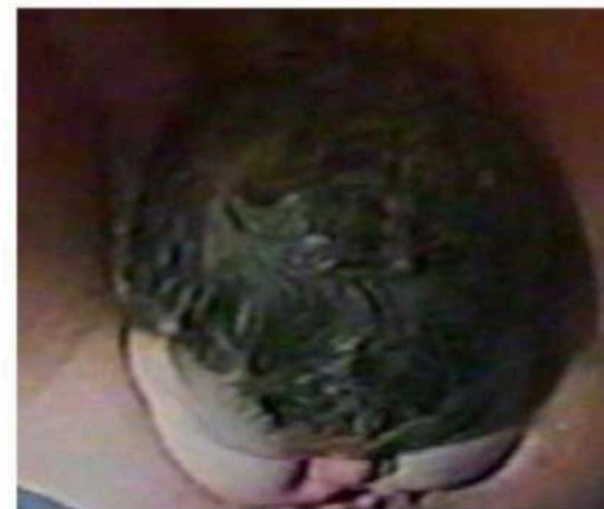Avoid it

Prophylactic caesarean section is indicated when:
Estimated fetal weight > 5 kg in women without DM.
Estimated fetal weight > 4.5 kg in women with DM



Mini OSCE – 1

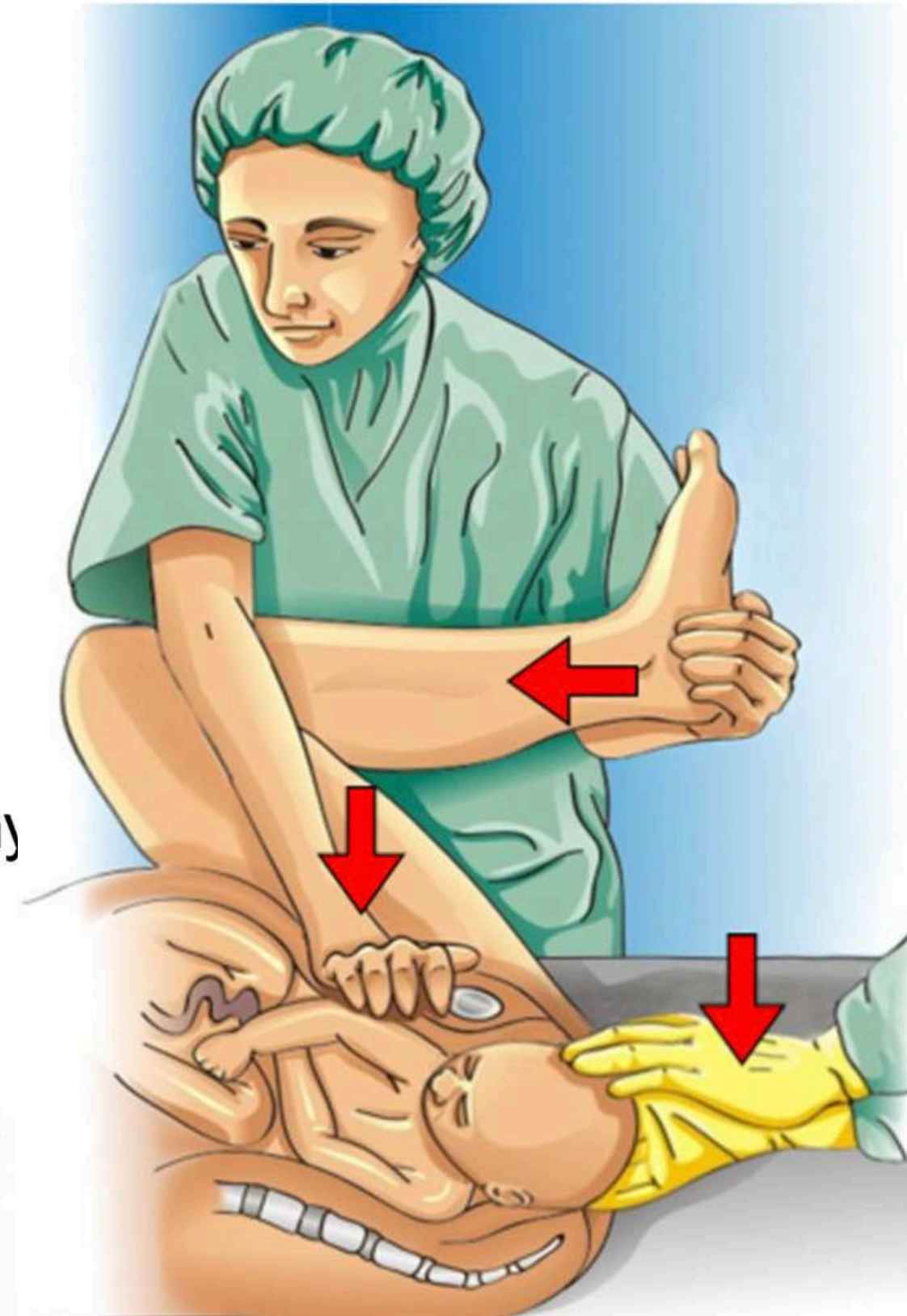
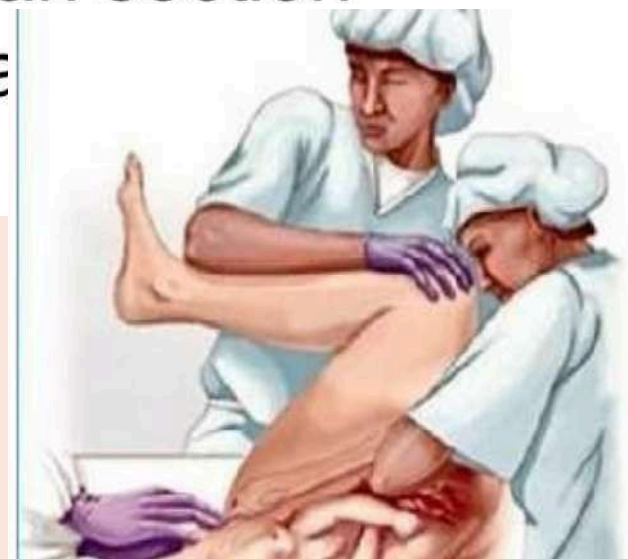- ❖ Dx:
 - shoulder dystocia
- ❖ 3 risk factors:
 - Macrosomia, gestational DM, previous dystocia, mass
- ❖ 2 initial manoeuvres:
 - McRoberts and suprapubic pressure
- ❖ 2 complications;
 - Perineal and vaginal laceration, PPH
 - brachial plexus injury

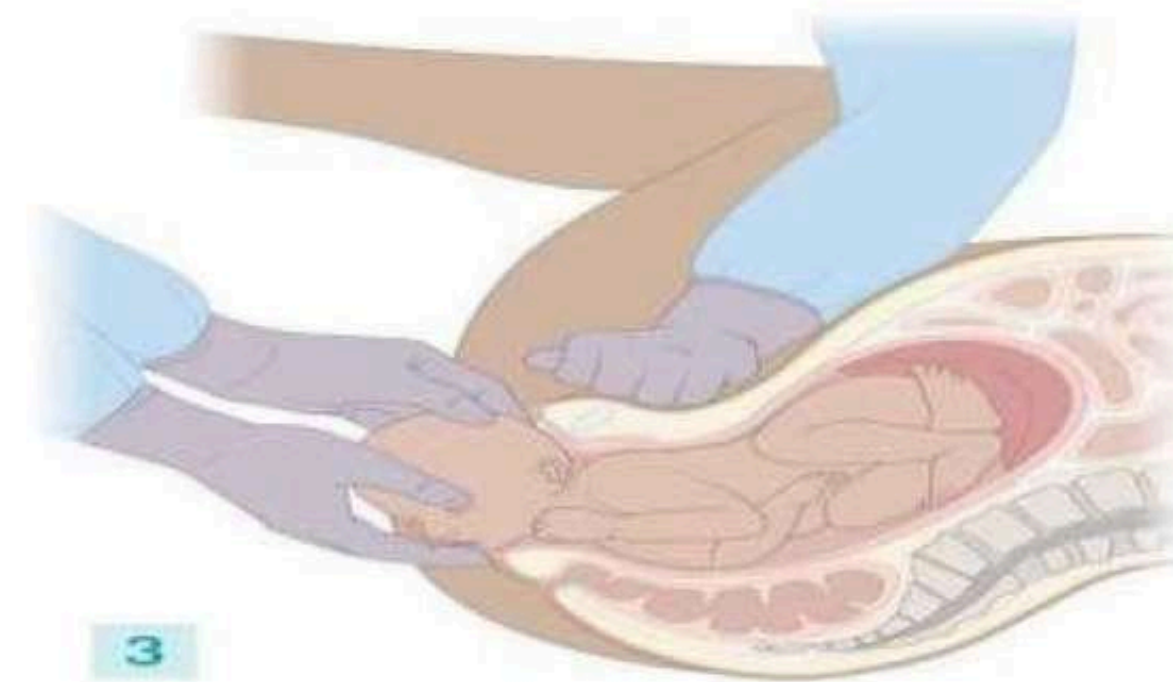
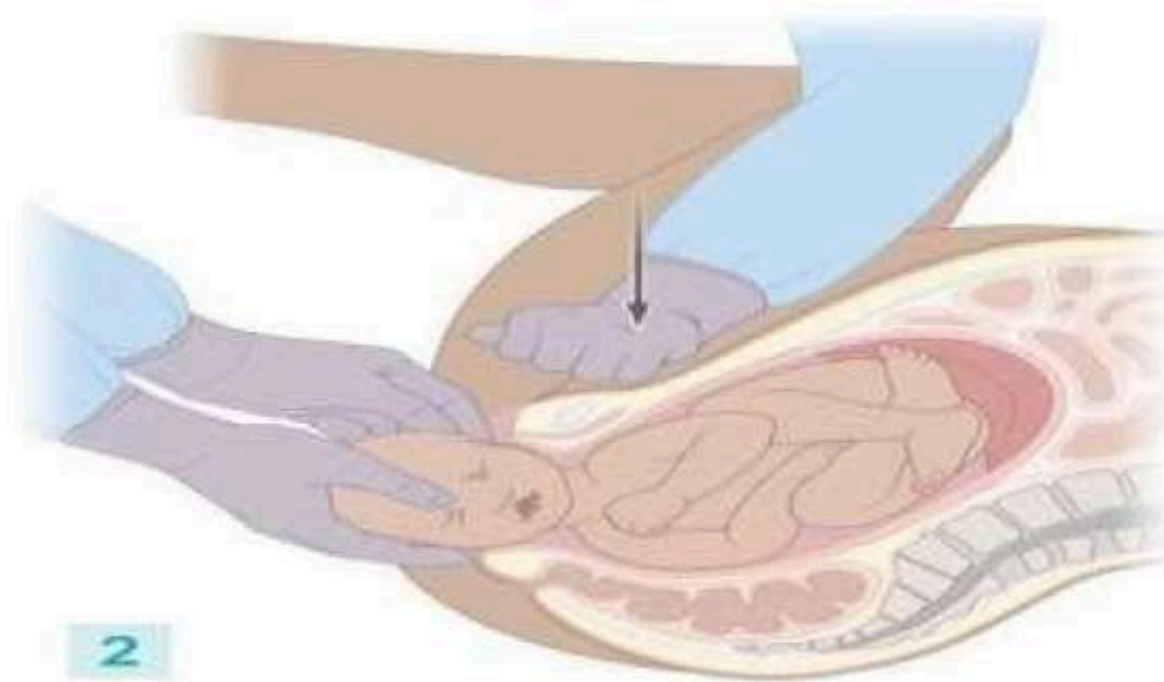
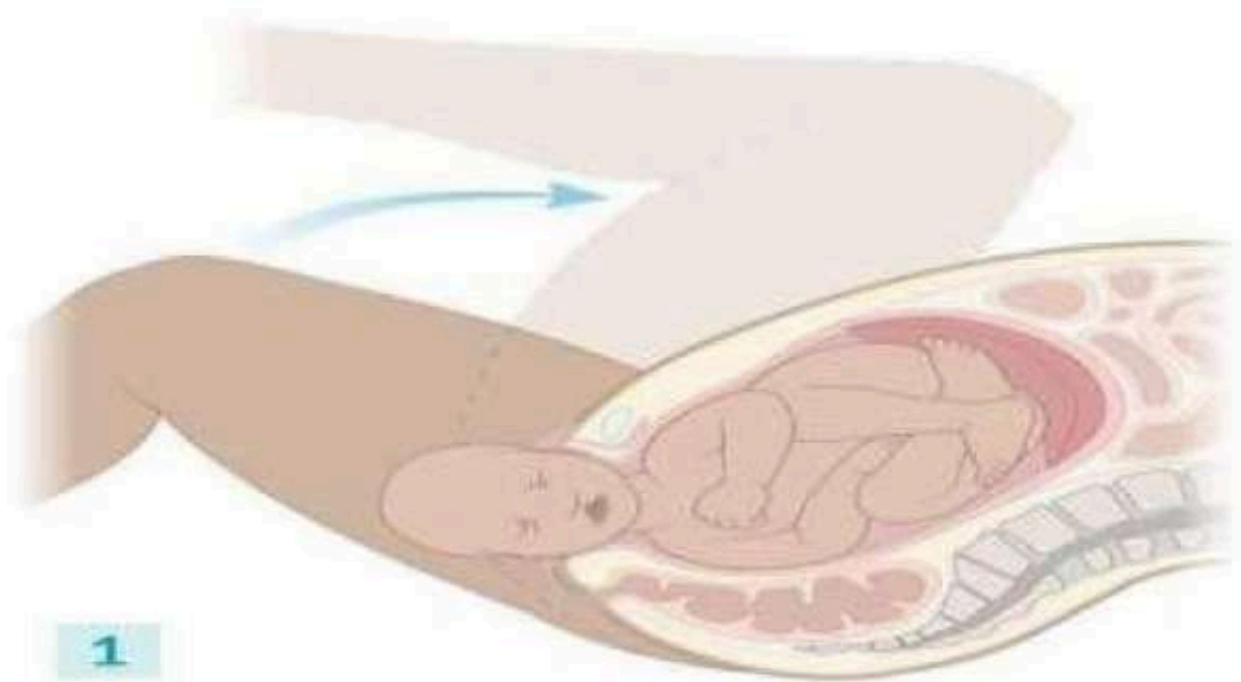


HLPEER

1. **H**elp: senior Obstetrician, anesthesiologist and pediatrician
 2. **L**egs: Hyperflex and abduct the hips (Mc Robert's position)
 3. **P**ressure: Apply suprapubic pressure
- These will be successful in most of the cases, if failed then:
4. **E**pisiotomy
 5. **E**nter: Rotate the shoulders by internal manipulation (Wood's screw)
- Deliver the posterior arm, posterior arm sling can be done by NG tube
5. **R**oll: Turn the patient into (all four) position

More dramatic techniques as fracture of the fetal clavicle, symphysiotomy replacement of the fetal head and delivery by caesarean section (Zavanelli maneuver) are traumatic and rarely necessary





McRoberts maneuver and suprapubic pressure (Rubin I maneuver) in shoulder dystocia

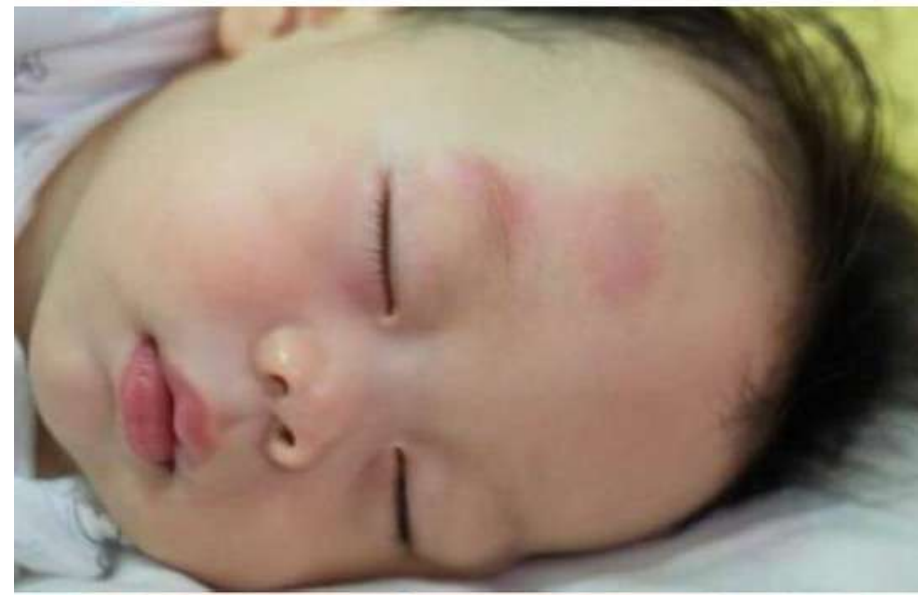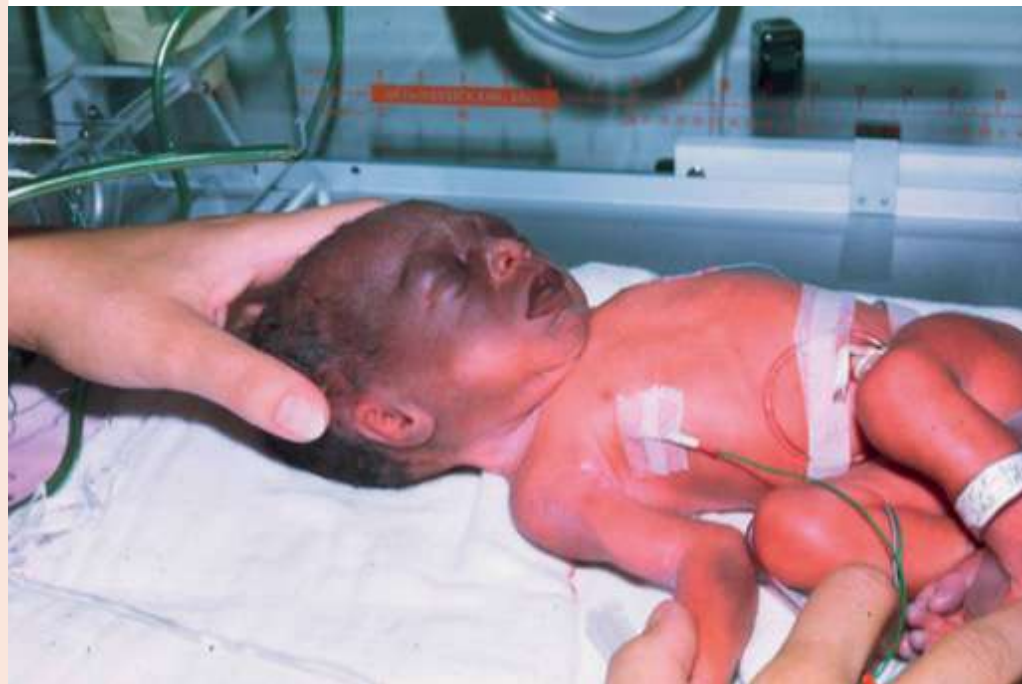1. The fetal head is partially delivered but has retracted against the perineum (Turtle sign). Both maternal hips are abducted, externally rotated, and maximally flexed (McRoberts maneuver).
2. Suprapubic pressure is applied to the impacted anterior shoulder (Rubin I maneuver).
3. The anterior shoulder passes under the pubic symphysis, and delivery can be completed.

Soft tissue injuries

1. Bruising and ecchymosis :

-**Causes** : difficult delivery may lead to bruising especially on the head and face , from pressure against the mother's pelvis or pressure-caused by forceps

-**no need for treatment, spontaneous resolution in 1 week**



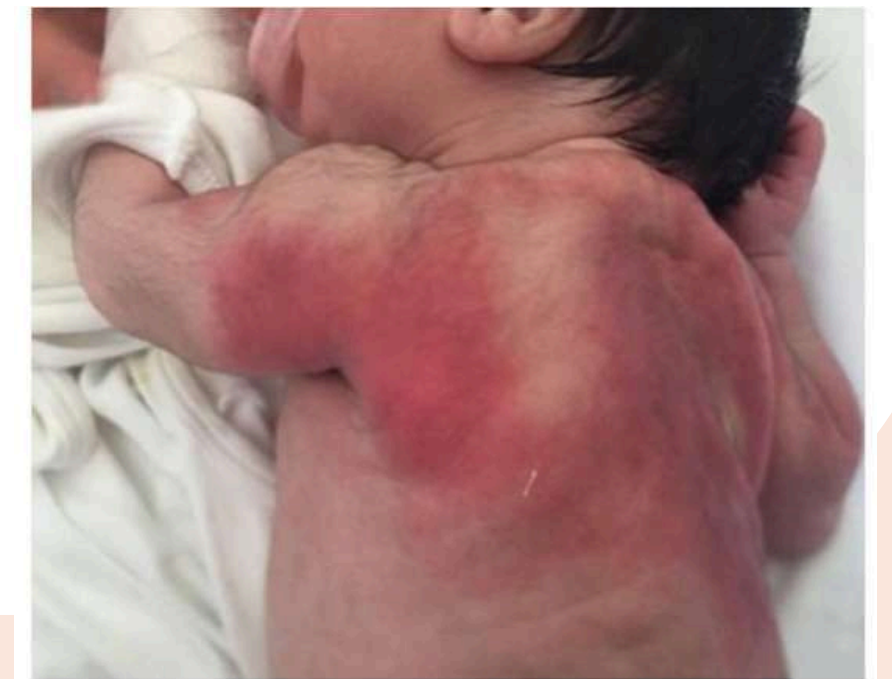2) Subcutaneous fat necrosis

-**causes**: use of instruments during delivery and stress on newborn can injure the fat under the skin

□ **Clinical picture**:
appear in 1st 2 weeks of life
irregular, hard, non-pitting, subcutaneous plaque with overlying dusky, red purple discoloration

sites: cheeks, arms, back, buttocks, thigh

No treatment is necessary



Nasal septal dislocation in neonates :

Definition

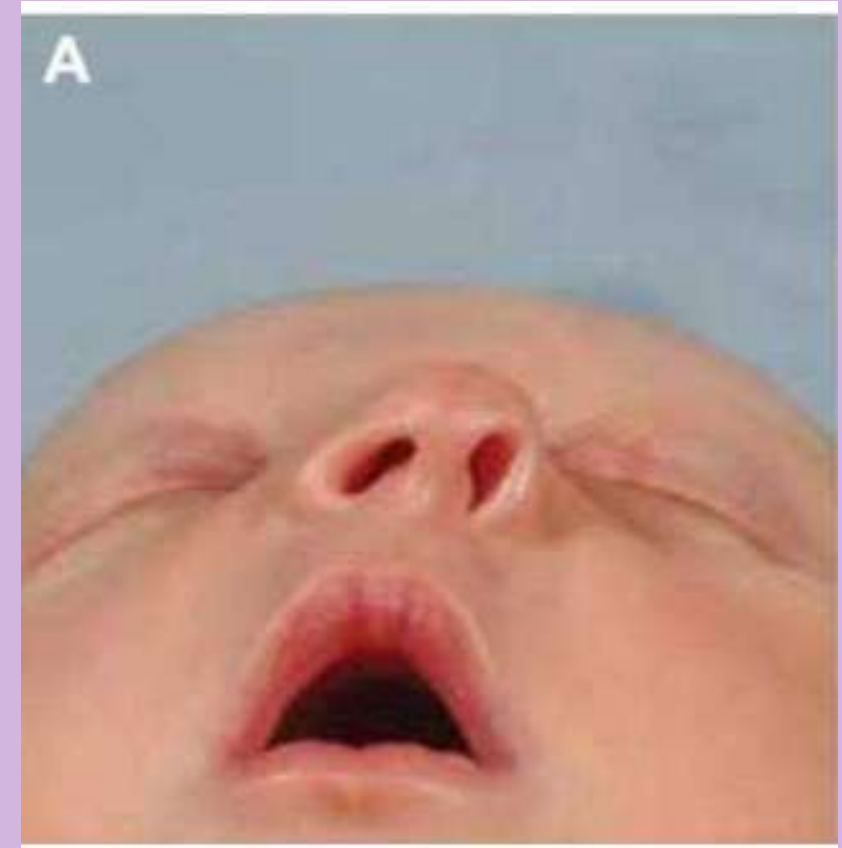- The most frequent nasal injury is dislocation of the cartilaginous part of the septum from the vomerine groove and columella.

Causes

- persistent pressure on the nose by fetal small parts or during delivery from pressure on the nose by the symphysis pubis,
- during forceps application and delivery

Presentation

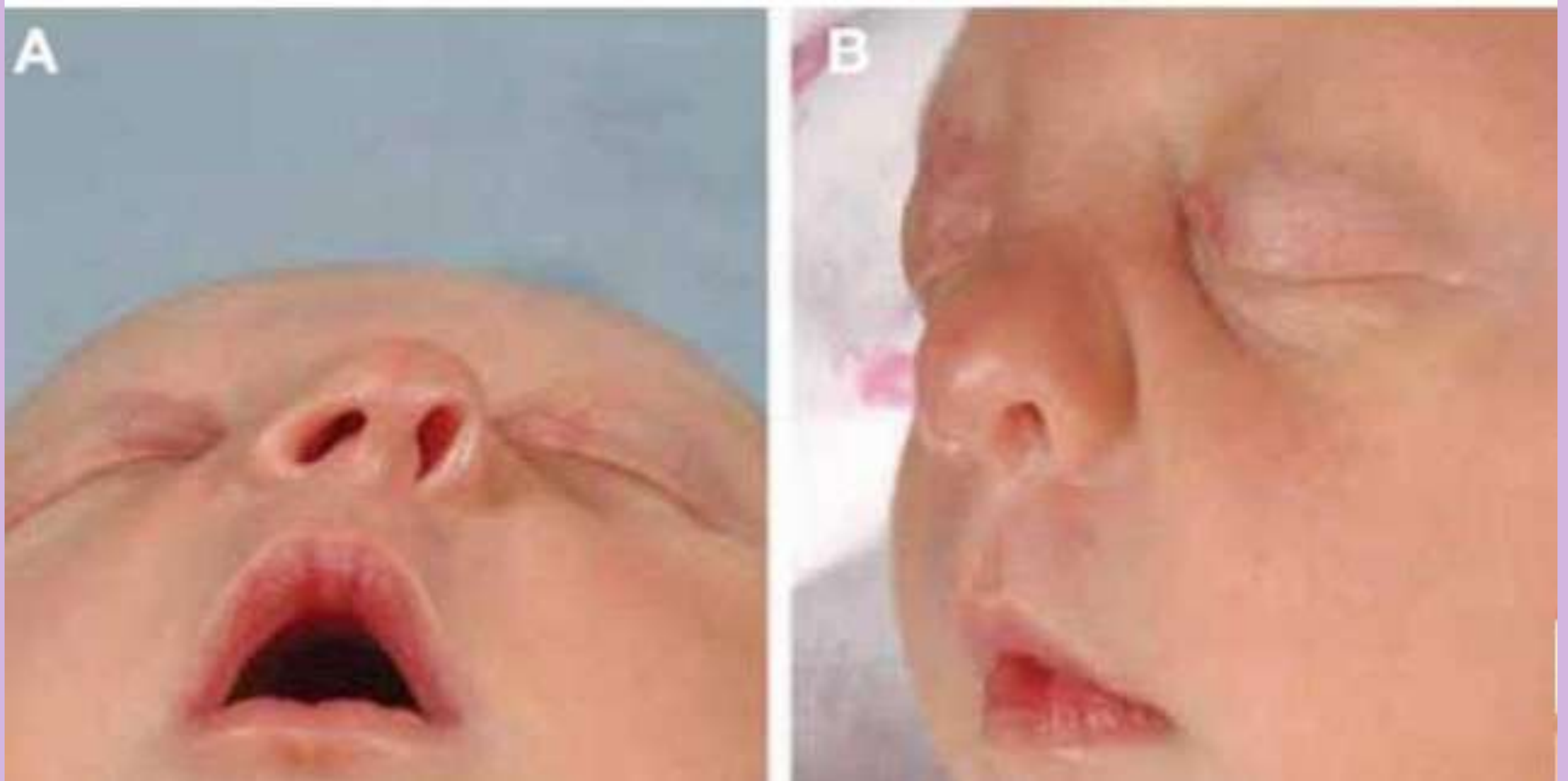- Presentation :
- 1. deviation of the nose to one side
 - 2. airway obstruction
 - 3. an asymmetrical appearance of the nose.
 - 4. noisy breathing (stridor)



Definitive diagnosis by Rhinoscopy

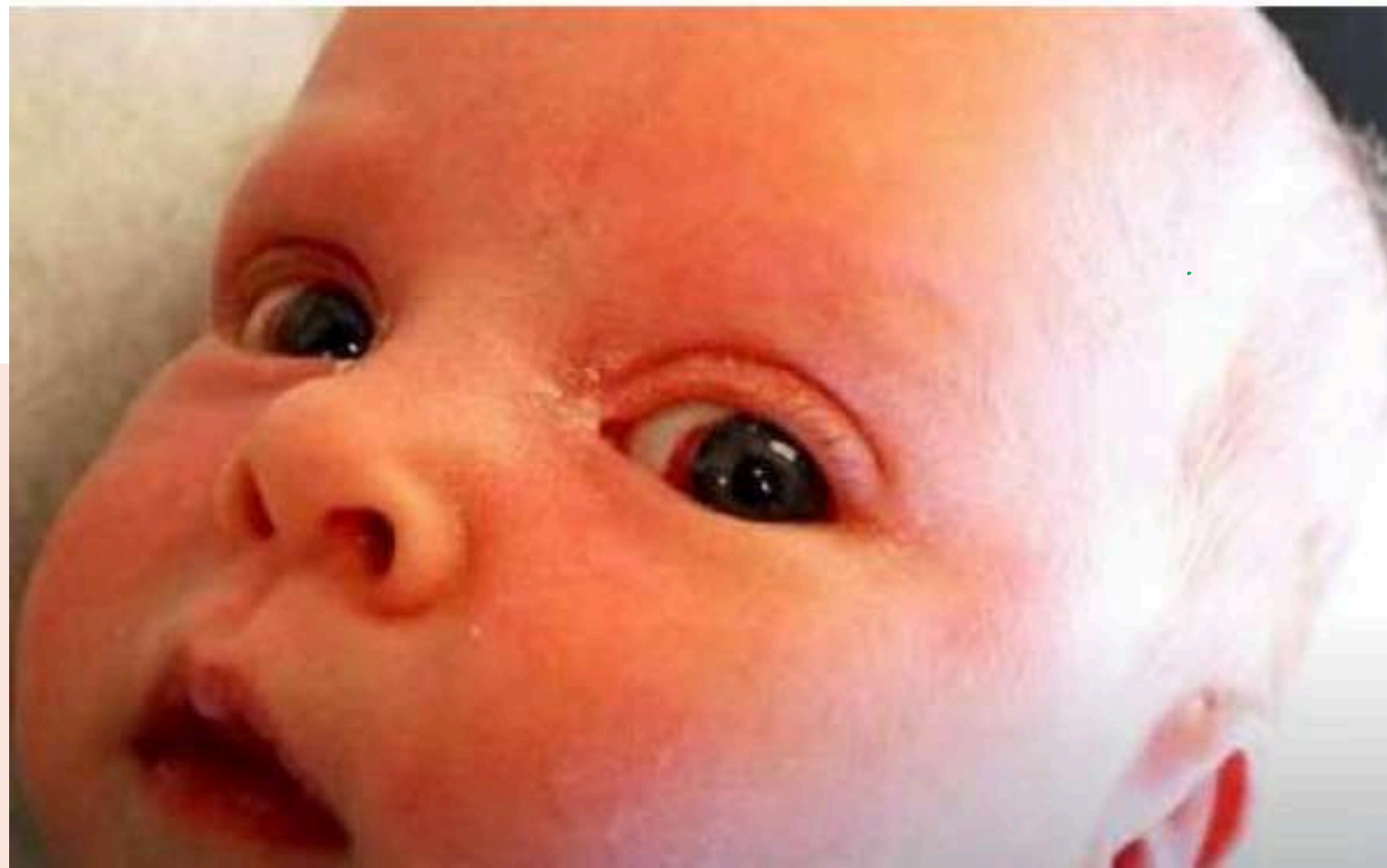Treatment: manual reduction within 3 days of age

.: Nasal septal dislocation in neonates



Ocular Injuries:

- * **retinal, subconjunctival hemorrhage** <vaginal delivery>
- * **ocular, periorbital injury** <forceps delivery>
 - * **local laceration**
 - * **palpebral edema**



FRACTURES

Clavicle

- most common (occurring in 2% of normal births)

Causes

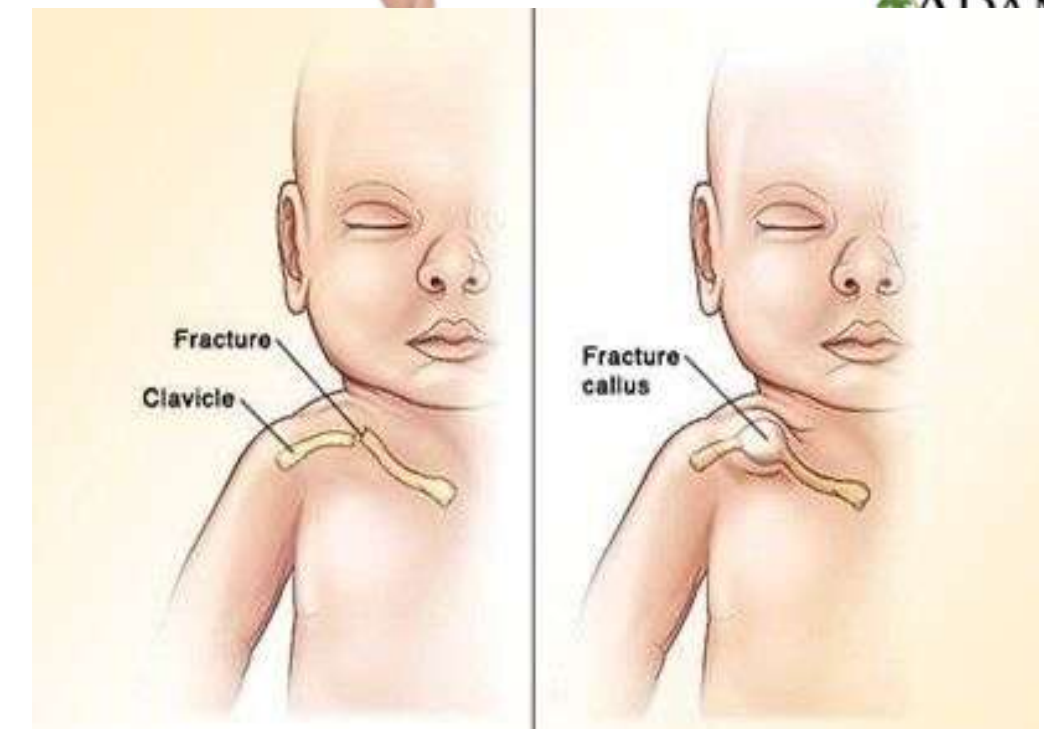
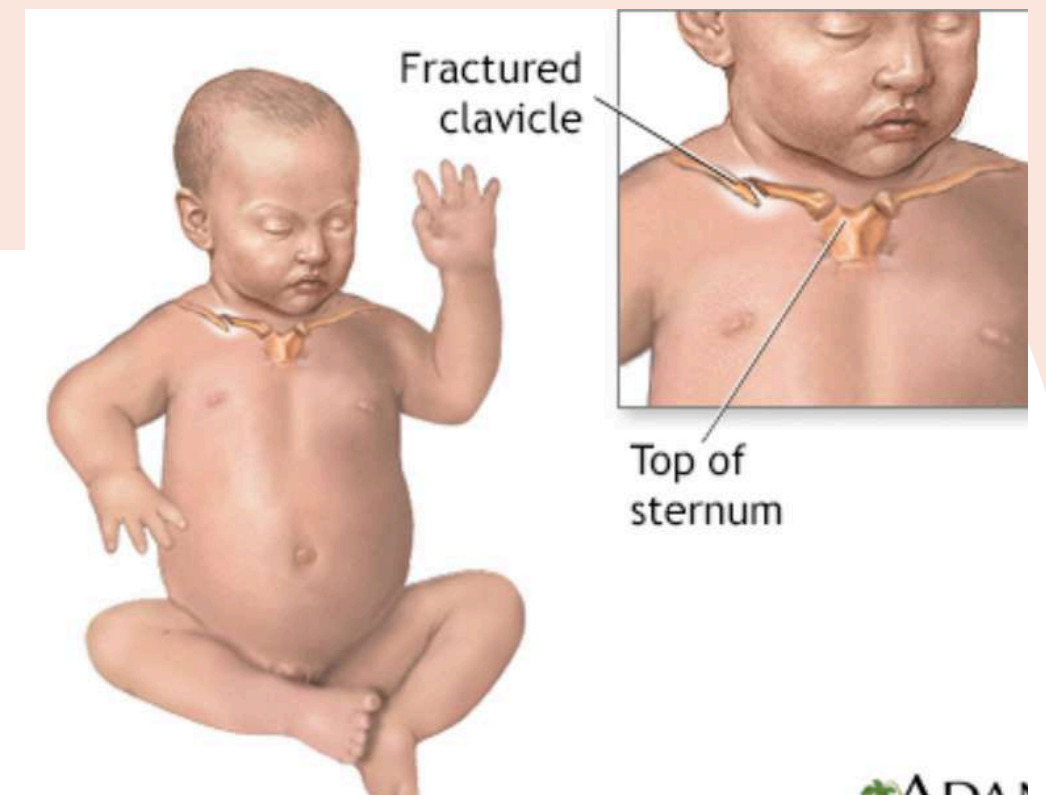
- difficult delivery

of the shoulders in vertex presentations and extended arms in breech deliveries. Vigorous, forceful manipulation

Clinical Manifestations

movement of

- ① the arm on the affected side is decreased or absent
- ② discoloration may be visible over the fracture site
- ③ Passive movement of the arm elicits cries of pain
- ④ Palpation reveals tenderness, crepitus,
- ⑤ Moro reflex absent



management

x-ray studies for chest, shoulders and cervical spines

Skull Fractures

Etiology

Come on in breech position and shoulder dystocia in macrosomic infant
forceps delivery

types of fracture and management

Linear fracture

soft tissue changes and the infant's behavior is normal unless there is an associated neurological symptoms

if linear fracture without CNS manifestation observation

Depressed fractures

visible, palpable indentations The infant may be entirely free of symptoms unless there is an associated intracranial injury.

surgical elevation of the indented segment

Basal fractures carry a poor prognosis

x-ray and CT scan for diagnosis

complications:

seizure, disruptions of blood vessels, brain contusions, death

Humerus, Femur:

etiology

Fracture of the Humerus

Fracture of the Femur

difficult

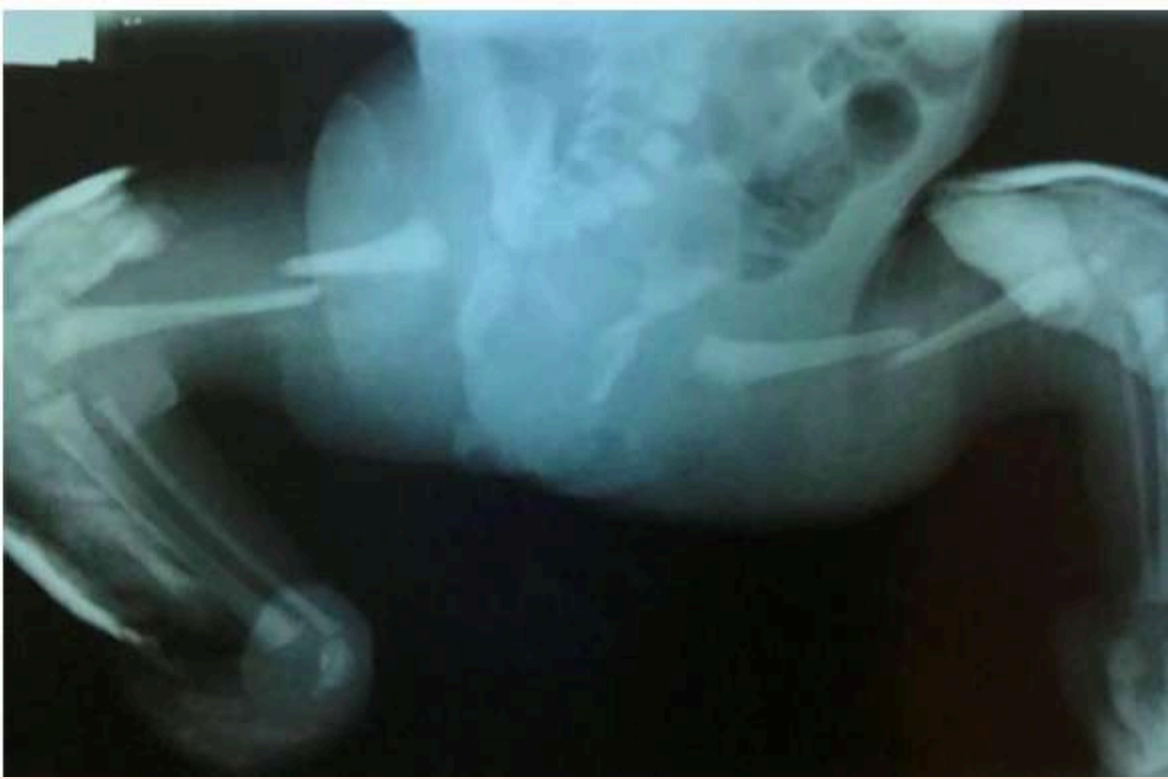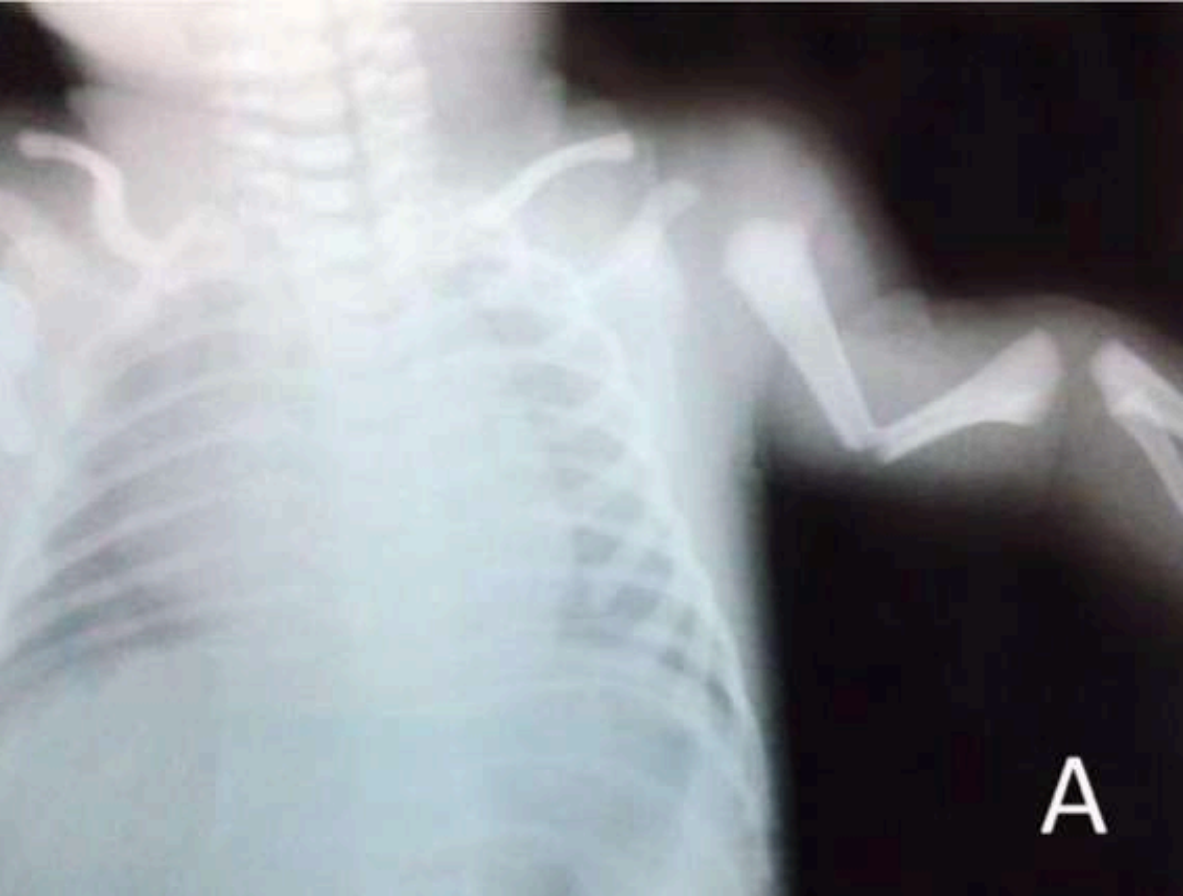delivery of extended arms in breech presentations

femur usually follows a breech delivery when the leg is pulled down improperly held by one thigh during delivery

presentation

immobility/. tenderness / crepitation/ swelling/pain

management: splinting



Injuries to Intra-Abdominal Organs

The condition usually occurs in large infants, infants with hepatomegaly (infants with erythroblastosis fetalis and infants of diabetic mothers), and infants who underwent breech delivery.

Types:

Rupture or subcapsular hemorrhage into liver, spleen or adrenal glands.

***clinical presentation**

Abdominal distention

poor feeding

pallor & shock.

jaundice, tachypnea

***management**

1. clinical examination and serial hematocrit levels.

2. abdominal ultrasound.

3. paracentesis in case of intraperitoneal bleeding.

Immediate management consists of transfusion with packed red blood cells, as well as recognition and correction of any coagulation disorder.

NEONATAL RESUSCITATION

safa'a olimat

DEFINITION

is the series of actions used to assist new born babies who have difficulty with making the physiological transition from the intrauterine to extra uterine life

FACTORS ASSOCIATED WITH AN INCREASED RISK OF A NEED FOR STABILIZATION / RESUSCITATION AT BIRTH

Category	Ante-partum Factors	Intrapartum Factors
Fetal Factors	- Intrauterine growth restriction	- Evidence of fetal compromise (non-reassuring fetal status)
	- Gestation < 37 weeks	- Meconium-stained amniotic fluid
	- Multiple pregnancy	- Vaginal breech delivery
	- Serious congenital abnormality	- Forceps or vacuum delivery
	- Oligo- or polyhydramnios	- Significant bleeding
Maternal Factors	- Infection	- Cesarean section before 39 weeks
	- Gestational diabetes	- Emergency cesarean section
	- Pregnancy-induced hypertension	- General anesthesia
	- Pre-eclampsia	
	- High BMI	
	- Short stature	

THE BASIC NEEDS OF A BABY AT BIRTH

The four basic needs of ALL babies at the time of birth (and for the first few weeks of life) are:

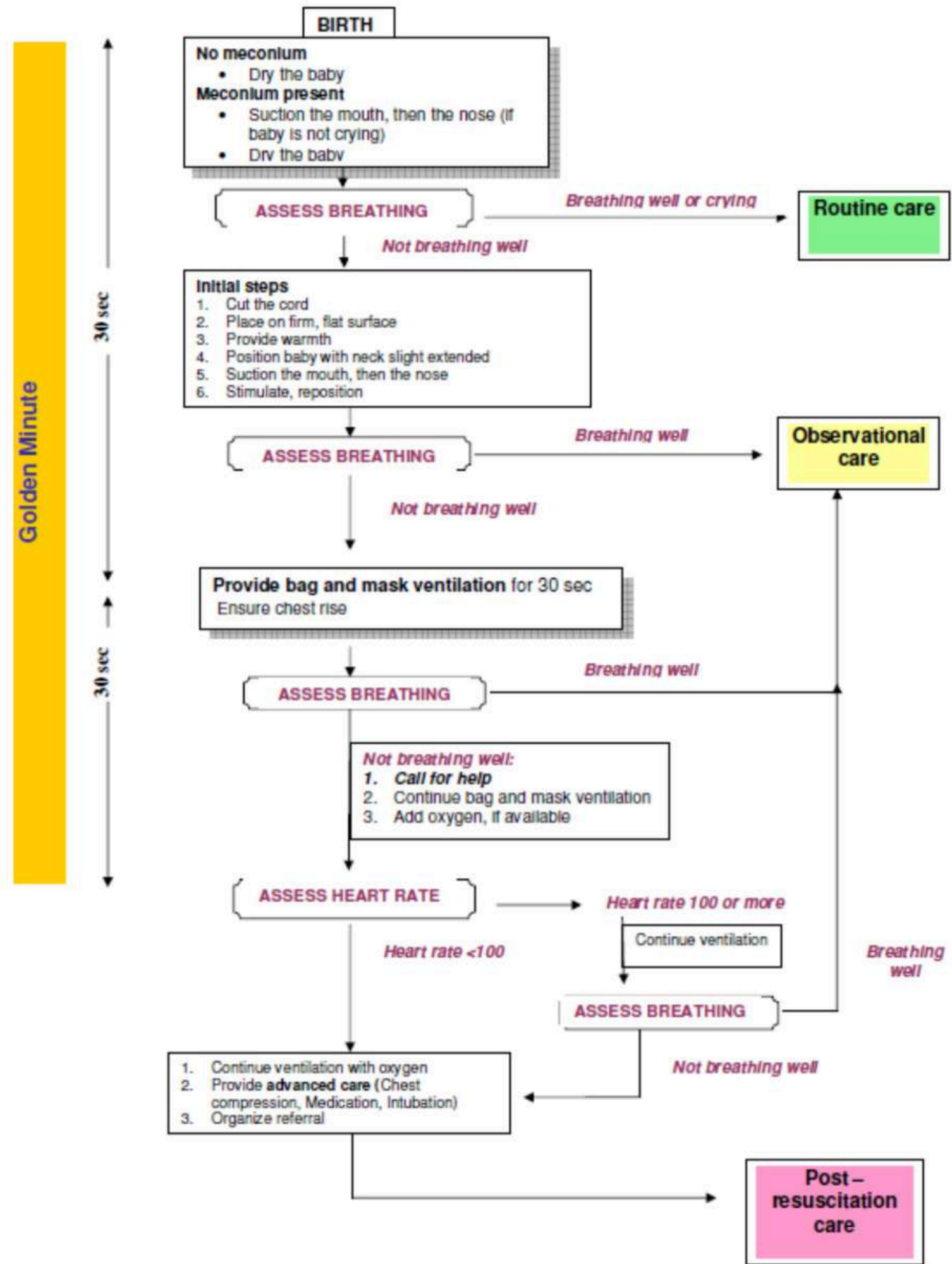
- i. Warmth
- ii. Normal breathing
- iii. Mother's milk
- iv. Protection from infection

STEPS OF RESUSCITATION

If the baby need resuscitation

- cut the cord.
- Tell the mother that her baby is having difficulty beginning to breathe and that you are going to help him. Tell her quickly but calmly.
- Transfer the baby to a warm clean, flat and dry surface.
- Provide warmth
- Position the baby
- Clear the airway
- Stimulate and reposition

Flow Diagram for Basic Neonatal Resuscitation



1. Provide warm environment :

A baby's skin temperature falls within seconds of being born. If the temperature continues to fall, the baby will become ill and may even die.

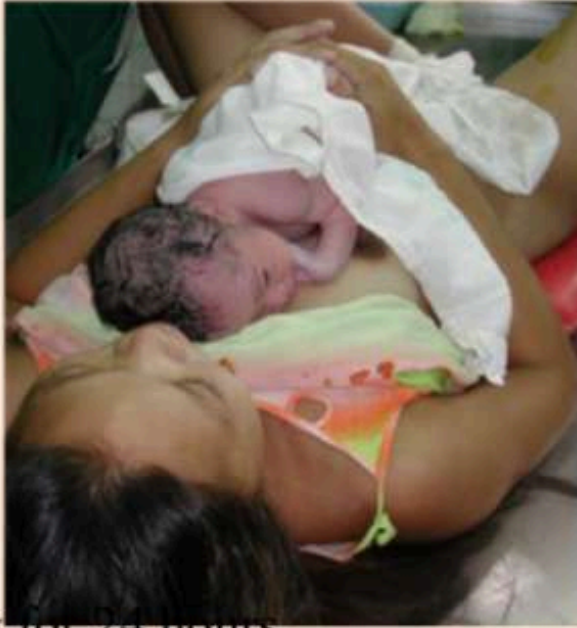This is why a baby **MUST** be dried immediately after birth and delivered onto a warm towel or piece of cloth, and loosely wrapped before being placed (naked) between the mother's breasts.

This first skin-to-skin contact should last uninterrupted for at least one hour after birth or until after the first breastfeed. The mother and baby should be covered with a warm and dry cover, especially if the room temperature is lower than 25°C. The steps of prevention of heat loss are explained in the lesson on 'Thermal protection'.

'Warm chain'

1. At delivery:

- Ensure the delivery room is warm (25° C), with no draughts.
- Dry the baby immediately; remove the wet cloth.
- Wrap the baby with clean dry cloth.
- Keep the baby close to the mother (ideally skin-to-skin) to stimulate early breastfeeding.



- Postpone bathing/sponging for 24 hours.

2. After delivery:

- Keep the baby clothed and wrapped with the head covered.
- Minimize bathing especially in cool weather or for small babies.
- Keep the baby close to the mother.
- Use kangaroo care for stable LBW babies and for re-warming stable bigger babies

How to keep baby warm :

Use dry, warm towel to hold the baby at birth. Remove wet towel after cleaning

ii. Adequate and appropriate clothing

iii. Skin-to-skin contact or next to mother (Rooming in)

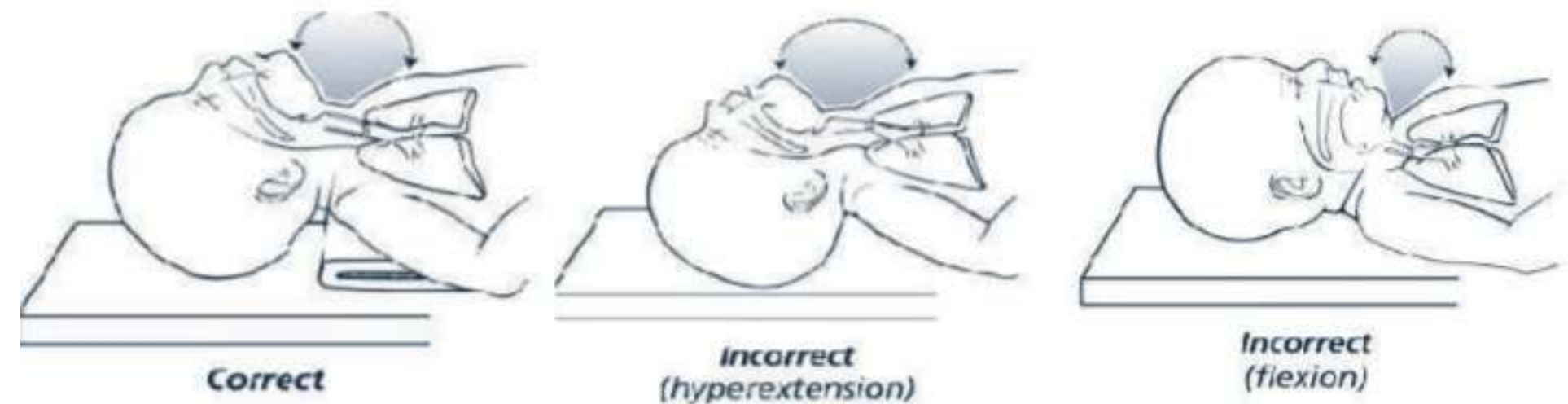
iv .Radiant warmer in nursery

v. Keep the room temperature of baby care area 25°C

* Using a 200 watt bulb may not be sufficient to keep the baby warm. There is also a risk of breakage of bulb.

2. Open the baby's airway : place baby on his back , head is slightly extend , place folded of cloth under the baby shoulder (help to maintain position) the folded cloth **should not** too thick this may cause overextension or flexion which close the airway then suction the mouth then nose

open the airway : suction the mouth then nose



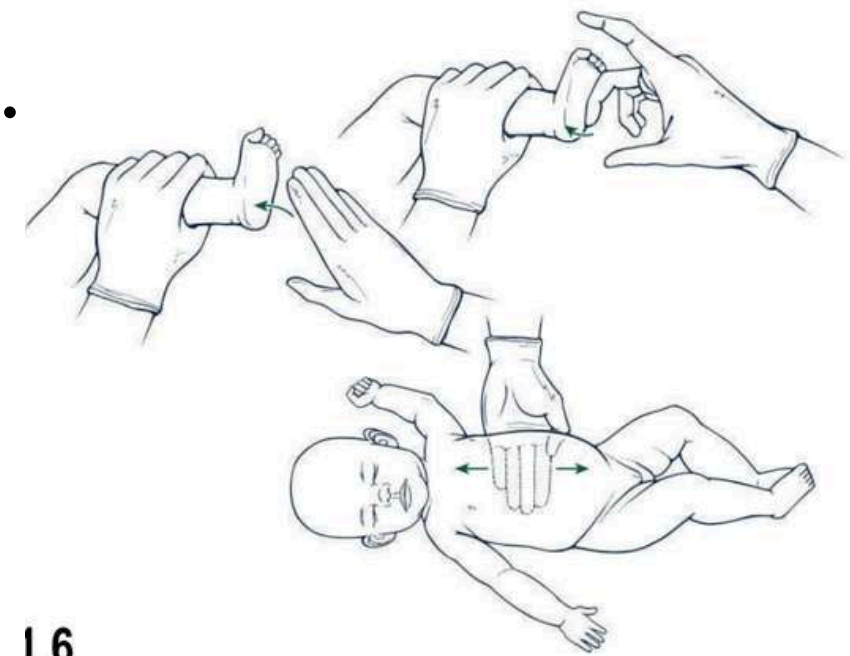
Suctioning some time stimulate breathing , if this happend place the baby with mother and provide **observational care** :

Keep baby with mother: Do not separate the mother and the newborn. Allow the newborn skin-to-skin contact with the mother.

- Observe breathing and temperature.
- Watch for complications (convulsions, coma, etc);
- Initiate breastfeeding, if well

2. Stimulate to breath : if baby doesn't cry after birth position the baby and stimulate for breathing also remove wet clothes , safe methods used to provide tactile stimulation:

- 1) slapping or flicking the soles of the feet
- 2) gently rubbing the newborn back or extremity.
- - some harmful action like slapping the back , squeezing the rib cage ,Forcing thighs into abdomen Dilating anal sphincter , shaken should be avoided .
- if baby is still not breathing or breath abnormally at the end of 30 seconds after providing initial steps after resuscitation >> immediately ventilation with bag & mask .



PREPERATION FOR VEN WITH BAG & MASK

1. selection of mask : it depend on how the mask fit the newborn face , the rim should cover the tip of the chin , mouth & nose but not the eye (may cause eye damage) .
2. Position the baby head : should be placed in sniffing positions to maintain open airway .
3. Position your self at the bed side or head of the baby : if you're right handed you probably will feel most comfortable controlling the bag with your right hand and mask with your left hand.

Start ventilation by squeezing the bag to deliver breath

- remember the fetal lung is filled with fluid so the first breath requires high pressure and longer inflation times than will subsequent breaths.
- Adequate pressure required to squeeze the bag should be enough to produce gentle chest rise as it happens in normal breathing
- breath should be delivered at rate 40 to 60 breaths/ min and help to maintain it.
- try saying to yourself as you ventilate the newborn: “Breathe – Two – Three, Breathe – Two – Three”.
- If you squeeze the bag on “Breathe” and release while you say “Two, Three”, you will probably find you are ventilating at a proper rate and insure chest rise

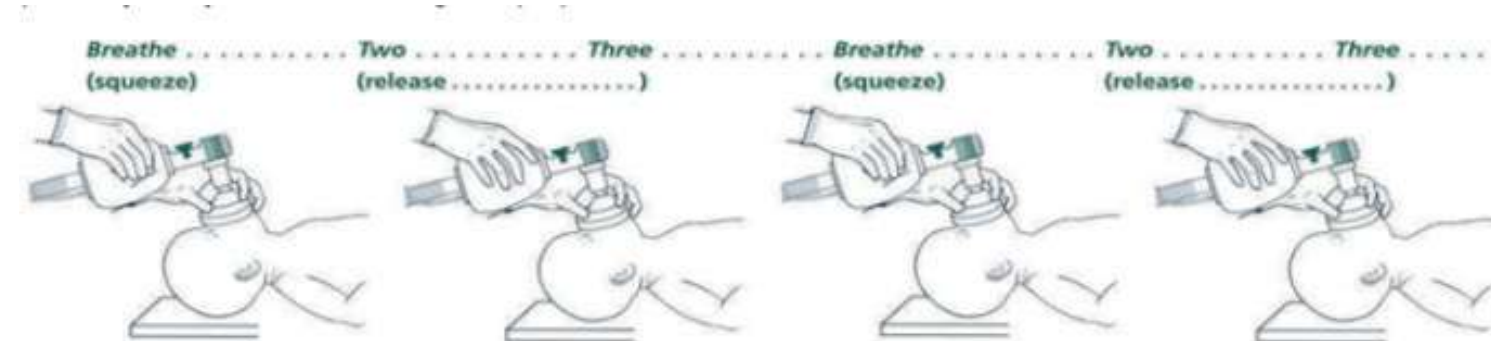


Fig. 1.11 Counting out loud to maintain a rate of 40 to 60 breaths per minute

Reasons for inadequate or absent chest movements are

- The seal is inadequate
- The airway is blocked
- Not enough pressure is being given.

You should immediately take following “Steps to improve the ventilation”

Reapply the mask to the face and try to form a better seal

Check the baby’s position and extend the neck a bit farther.

Check the mouth, oropharynx, and nose for secretions c l e a r

Try ventilating with the baby’s mouth slightly open.

Increase the pressure to squeeze the bag until there is perceptible movement of chest

Evaluate success of ventilation :

By **spontaneous breathing** if the baby improves gradually reduced rate and volume of breath and watch for baby breath .

baby who is breathing well will be crying or breathing quietly and regularly (chest is rising symmetrically with frequency 30-60 /minute, and there is no chest in drawing and no grunting for one minute).

A baby who is not breathing well (gasping or not breathing at all) after 30 seconds of adequate ventilation needs continued ventilation and further evaluation.



If there's no chest rise or adequate ventilation :

Call for help. A more skilled worker will be required to evaluate and assist in resuscitation.

Ø Continue bag and mask ventilation.

Ø Provide oxygen through bag and mask if available.

Ø Assess the heart rate.



Evaluate heart rate :

By feeling the umbilical cord pulse (while you attach to baby abdomen) or listening to the heart beat with stethoscope while you stop ventilation for 6 sec.

If no pulse can be felt in the cord, you or your helper must listen over the left side of chest with the stethoscope and count the heart beat. It may be necessary to stop ventilation for few seconds to listen with stethoscope.

- heart rate above 100 beats per minute is normal.
- A heart rate less than 100 beats per minute is slow.

If you are unable to count the heart rate then minimize the time without ventilation by listening to the heart rate :

If the heart rate sounds faster than your own pulse – probably the heart rate is normal .

If the heart rate sounds slower than your own pulse - probably the heart rate is slow.

If the heart rate is normal (above 100 bpm) but the baby is still not breathing well continue to provide bag and mask ventilation and reassess after every 30 seconds until the baby is breathing well .

If the heart rate is slow make sure that you have taken all the steps to improve the ventilation.

The chest should move gently with each breath. Continue to do bag and mask ventilation and reassess heart rate approximately after every 30 seconds.

The baby may need more advanced support such as endotracheal intubation, chest compressions and medications

The procedure of bag and mask ventilation should be continued until the baby establishes spontaneous breathing; however, if there are no signs of life (breathing / heart rate) even after 20 minutes of birth, ventilation may be stopped.

POST RESUSCITATION CARE

Keep the baby warm

- Check breathing, temperature, colour and CFT
- Monitor blood sugar
- Watch for complications
- Initiate breastfeeding if well

FOLLOW UP CARE AFTER SUCCESSFUL RESUSCITATION :

For the baby

- The mother and baby should be kept together with the baby in skin-to-skin contact.
- Encourage the mother to breastfeed her baby as soon as it is ready. This will help to prevent hypoglycemia (a low blood sugar).
- Assess the baby's attachment at the breast, can you hear him swallow? Help the mother breastfeed if needed.
- Good suckling is a sign of recovery. If the baby is unable to suck effectively help the mother to express colostrum.

For the mother and family

- After resuscitation, explain to the mother and family what has happened and how the baby is now.
- Keep the mother and baby in the delivery room and DO NOT separate them.
- NEVER leave the woman and newborn alone. Monitor them every 15 minutes during the first hour.

RECORD THE EVENTS



EXAMINE THE BABY BEFORE DISCHARGE

S. No	Steps
1.	Deliver the baby on to mother's abdomen
2.	Note the time of birth and dry the baby- If no meconium-
3.	Assess the baby's breathing: <ul style="list-style-type: none"> ○ Baby breathing or crying – no further action ○ Baby gasping or not breathing – start initial steps
4.	Cut cord quickly; transfer baby to a firm warm surface and START resuscitation. Provide warmth Position the baby Suction first mouth and then the nose Stimulate, reposition
5.	If still not breathing, VENTILATE <ul style="list-style-type: none"> ○ Use correct sized mask ○ Ensure proper seal ○ Squeeze 2-3 times and observe the chest rise ○ If chest rise is adequate, ventilate for 30 seconds and reassess ○ If chest rise is NOT adequate, take steps to improve ventilation
6.	Assess heart rate after 30 seconds of ventilation, if not breathing well: If > 100/min: assess breathing; if breathing well, STOP VENTILATION If <100/min or not breathing well: continue ventilation with oxygen, provide advanced care if available or organize referral.



Maternal Birth Injuries

Omar Abdallah



Perineal Tears

tear of the perineal area due to significant or rapid stretching forces during labor and delivery.



All women undergoing vaginal delivery are at risk of experiencing **obstetric anal sphincter injuries (OASIS)**.

Consequently, a systematic examination, including a digital rectal examination, is essential to evaluate the extent of any damage, particularly before suturing.

Classifications

Obstetric anal sphincter injuries (OASIS) include both third- and fourth-degree perineal lacerations.

First-Degree

- Injury to perineal skin and/or vaginal mucosa.
- Cutaneous to subcutaneous tissue tear with no involvement of the perineal muscles.

Second-Degree

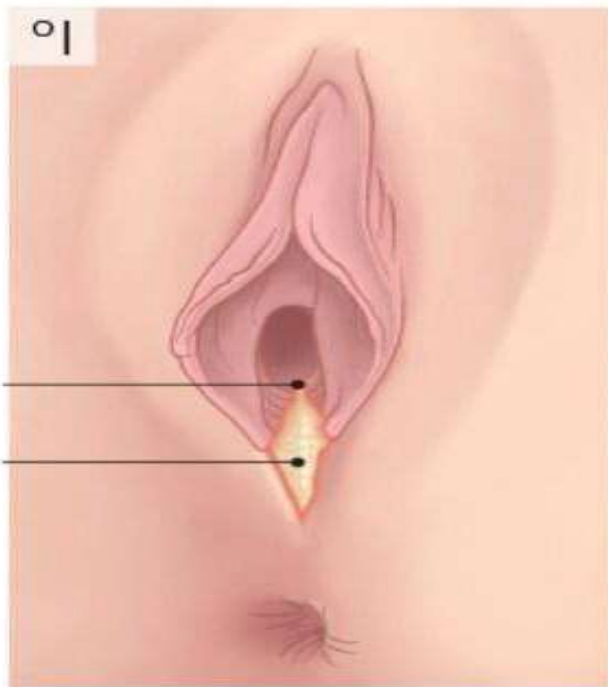
- Injury to perineum involving perineal muscles but not involving the anal sphincter.

Third-Degree

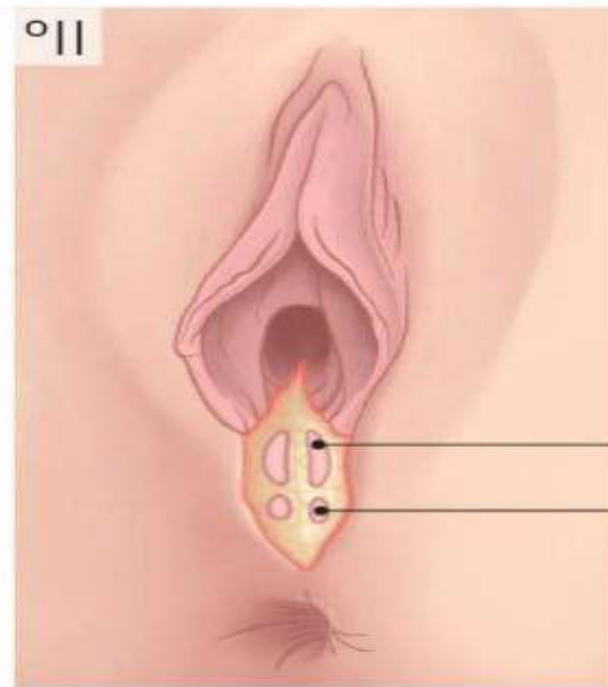
- Injury to perineum involving the anal sphincter complex:
 - > **Grade 3a tear:** <50% of external anal sphincter (EAS) thickness torn.
 - > **Grade 3b tear:** >50% of EAS thickness torn.
 - > **Grade 3c tear:** Both EAS and internal anal sphincter (IAS) torn

Fourth-Degree

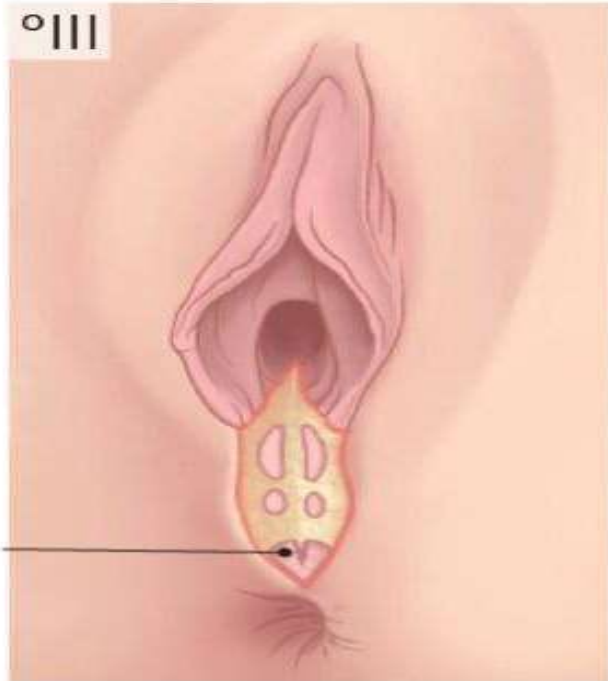
- Injury to perineum involving the anal sphincter complex (EAS and IAS) and anorectal mucosa.



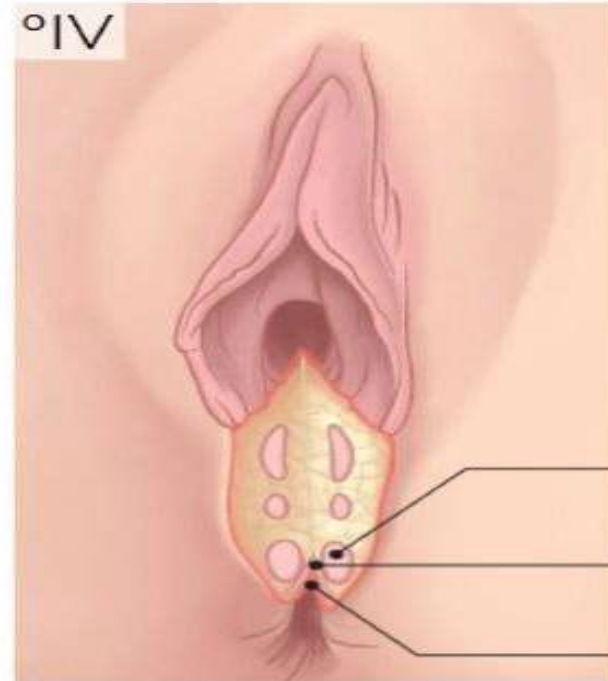
Vaginal tear
Perineal skin tear



Bulbospongiosus muscle
Superficial transverse perineal muscle

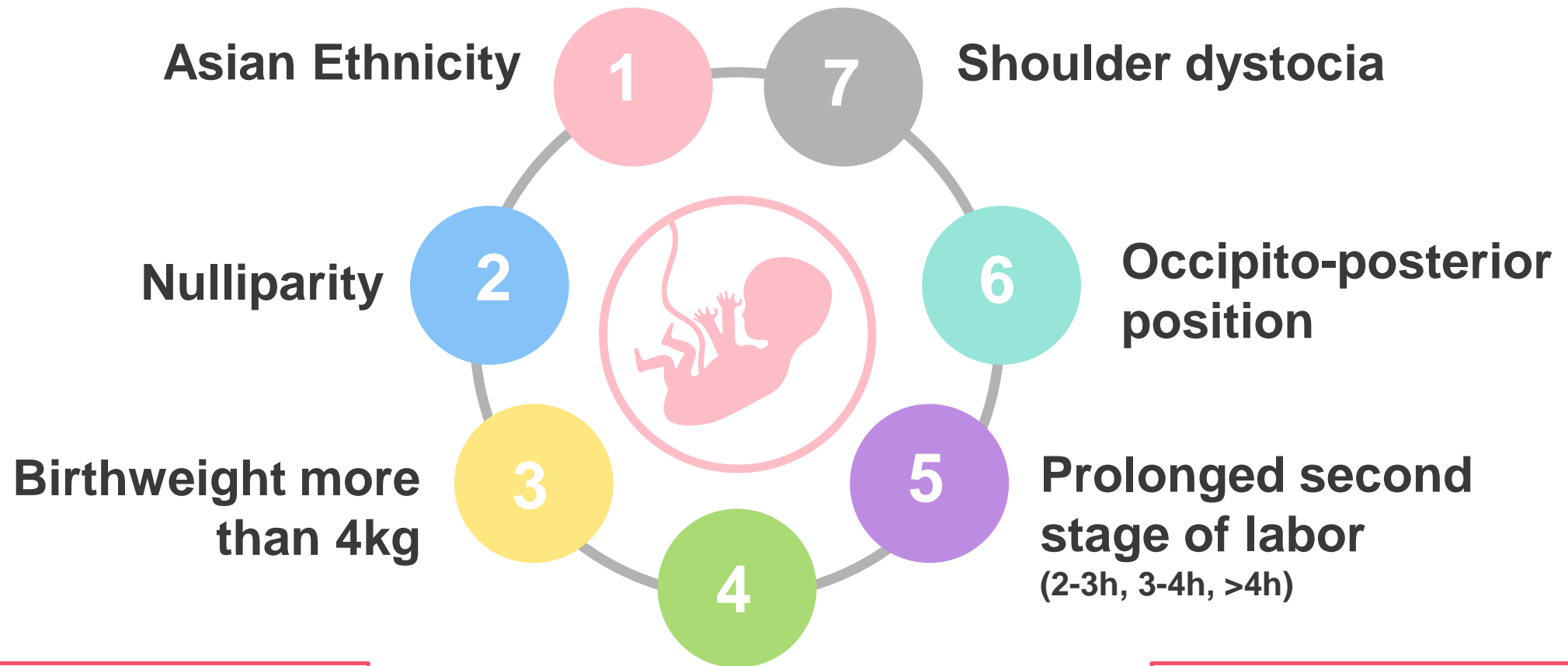


External anal sphincter



External anal sphincter
Internal anal sphincter
Anal mucosa

Risk Factors of OASIS



Forceps delivery with or without episiotomy

Instrumental delivery

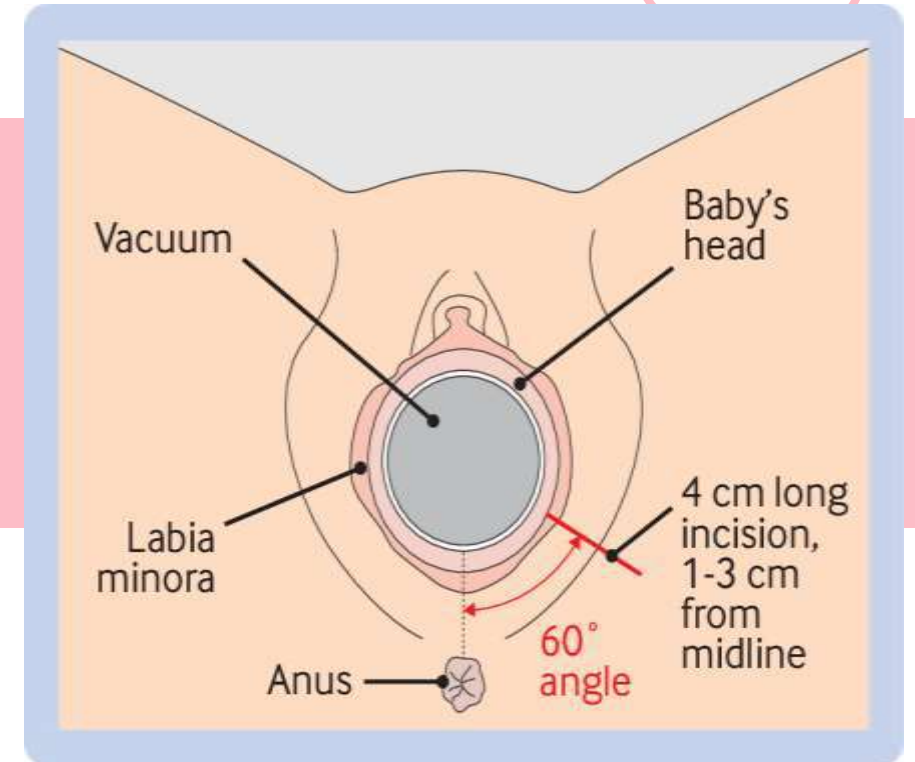
Ventouse delivery with or without episiotomy

OASIS Prevention

1. Episiotomy

Evidence suggests that a mediolateral episiotomy should be performed during instrumental deliveries, as it appears to offer a protective effect against obstetric anal sphincter injuries (OASIS).

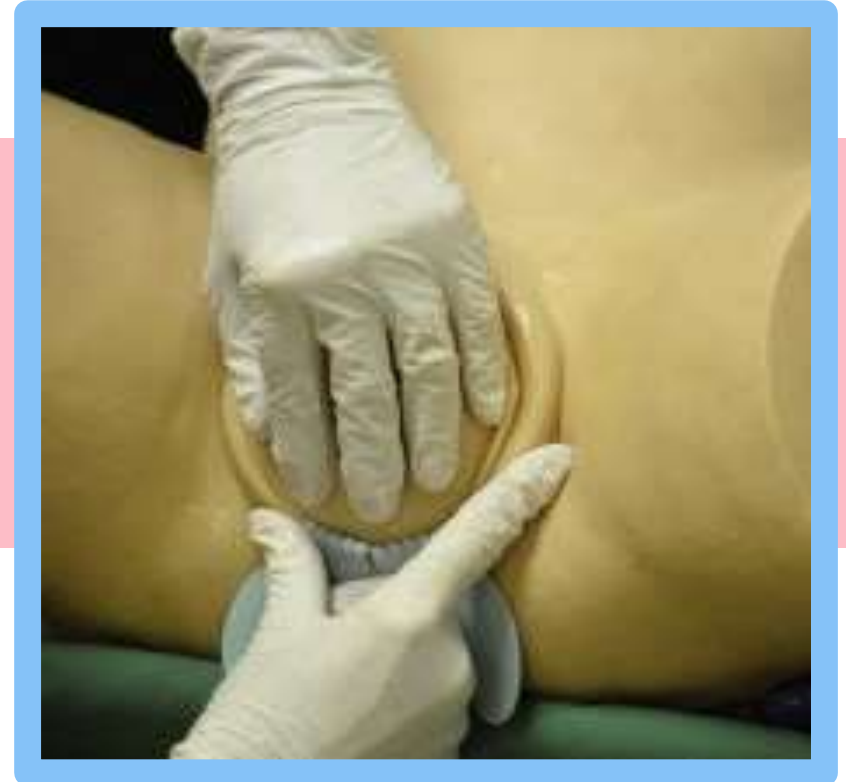The angle of the episiotomy relative to the midline is crucial in reducing the risk of OASIS, recommending an angle of **45 to 60 degrees** from the midline.



2. Perineal Protection

Manual perineal protection techniques, often referred to as "**hands-on birth**", encompass the following practices:

1. The left hand is used to slow the delivery of the fetal head.
2. The right hand is employed to protect the perineum.
3. The mother is advised not to push during crowning, emphasizing clear communication.
4. Consideration of episiotomy should be given.



A decorative header section with a solid pink background. At the top, there are two dashed pink circles. The left one is partially cut off by the top edge, while the right one is fully visible. Below this background, the title '3. Warm Compress' is written in a large, bold, dark grey font.

3. Warm Compress

Using warm compresses during the second stage of labor has been shown to significantly lower the risk of OASIS, including **third- and fourth-degree tears**.

This technique involves keeping a warm compress, such as a pad, swab, or gauze, on the perineum continuously throughout and between contractions. Your healthcare professional will gently apply the warm compress as the baby's head stretches the surrounding tissues

A decorative header featuring a solid pink horizontal band. Above this band, there are two dashed red circles. The circle on the left is partially cut off by the top edge of the pink band, while the circle on the right is fully visible above it.

4. Perineal massage

Perineal massage, both during the antenatal period and the second stage of labor, has been proposed as an effective method to facilitate the easier expansion of perineal tissue during birth.

Repair of OASIS

When consulting the patient, it is essential to clearly explain to the woman what they plan to do and why.

Offer inhalational analgesia & ensure good lighting.

The woman should usually be in the **lithotomy position** to allow adequate visual assessment of the degree of the trauma and for the repair itself

a rectal examination to assess whether there has been any damage to the external or internal anal sphincter, if there is any suspicion that the perineal muscles are damaged.

Repair of OASIS

The repair of 3rd & 4th degree tears should be performed by a trained clinician in an operating theatre under regional or general anesthesia, with appropriate lighting and instruments.

- **Anorectal Mucosa:** should be repaired using either the continuous or interrupted suture technique.
- **Internal Anal Sphincter (IAS):** it is advisable to repair it separately with interrupted or mattress sutures, ensuring not to overlap the IAS.
- **External Anal Sphincter (EAS):** For full-thickness EAS tears, either an **overlapping or end-to-end** (approximation) technique may be employed. For partial-thickness tears (types 3a and some 3b), an **end-to-end technique** should be utilized.

In cases of excessive bleeding, a vaginal pack should be inserted.

Figure-of-eight sutures should be avoided during the repair of OASIS to prevent tissue ischemia.

After the repair, a rectal examination should confirm that no sutures have been inadvertently placed through the anorectal mucosa; if any are found, they should be removed.

Postoperative management

How should women with obstetric anal sphincter injury be managed postoperatively?

1. Broad-spectrum antibiotics.
2. Laxatives
3. Bulking agents

Usually, they should be reviewed at **6 –12 weeks** postpartum.

Following surgical repair, it is important to convey to women that there is a favorable prognosis, with 60–80% reporting **asymptomatic outcomes 12 months** after delivery and EAS repair.

Complications

1. Rectovaginal Fistula
2. Infection
3. Wound dehiscence
4. Hemorrhage

Usually, they should be reviewed at **6 –12 weeks** postpartum.

Following surgical repair, it is important to convey to women that there is a favorable prognosis, with 60–80% reporting **asymptomatic outcomes 12 months** after delivery and EAS repair.

THANK YOU