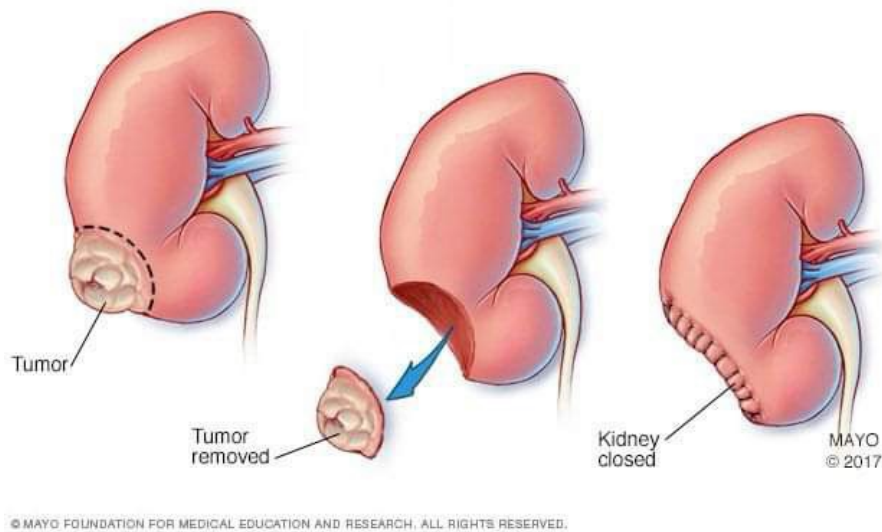


Q1

## Archive urology



patient with hematuria and flank pain ,dignosis as RCC

- ① name the procedure  
**partial nephrectomy**
- ② Mention 3 syndrome may associate with this mass  
**Von Hippel lindau syndrome**  
**Tuberous sclerosis**  
**Birt-Hogg-Dube syndrome**  
**Hereditary leiomyomatosis and renal cancer syndrome (HLRCC)**  
**Hereditary papillary renal cell carcinoma (HPRCC)**

## Q2

1) what's that ??

(JJ)stent

2) 3 indications of it related to urolithiasis

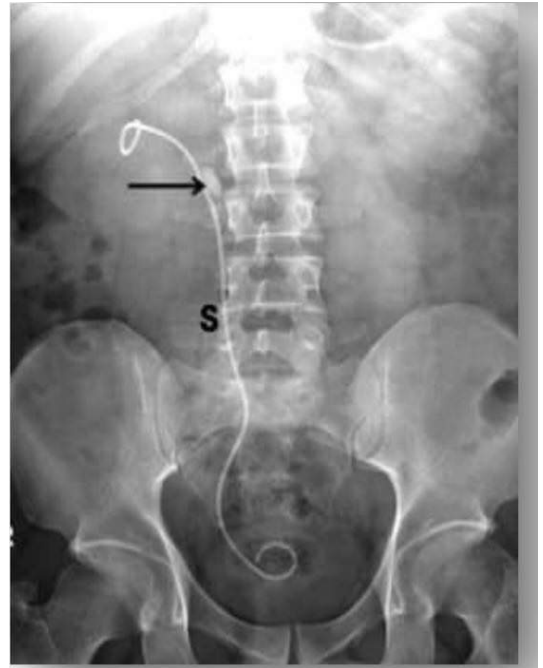
Single kidney .1

Bilateral obstruction .2

Obstructive nephropathy .3

Obstructive pyelonephritis .4

Intractable pain .5



## Q3

1) ? what is your diagnosis pic(A)

Hydrocele

2) ? what is your diagnosis pic(B)

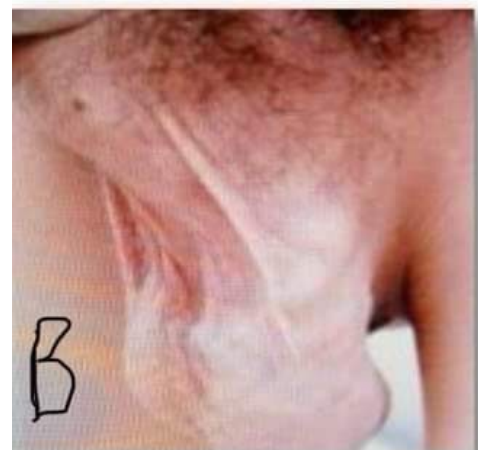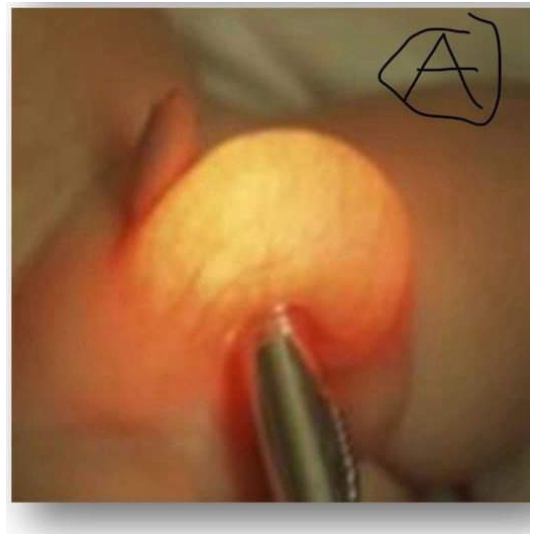
Varicocele

3) What is the name of the test in pic  
?(A)

Transillumination test

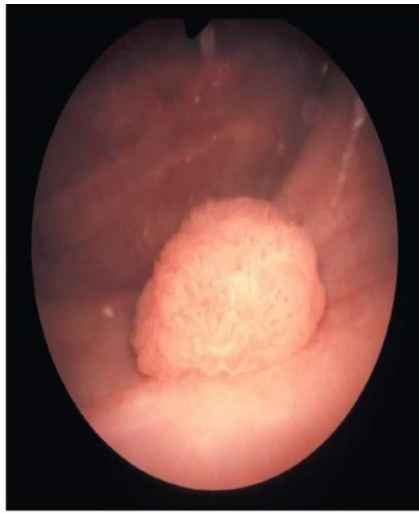
4) Two associated pathologies of -  
?Hypospadias

hooded foreskin and chordee and  
deviation of raphe



أكثر صورة تكررت (5 مرات)

Q4



Source: John L. Probert:  
Urology: An Atlas of Investigation and Diagnosis  
Copyright © Evidence Based Networks Ltd.

history of Bladder ca

70y old male patient , smoker , presented to urology clinic complaining of painless intermittent gross hematuria and urinary retention on U / S : 33 cm urinary mass was found , if the mass was shown to malignant

①

Most common type ?

Transitional cell carcinoma

② gold stander diagnosis-

Cystoscopy

③ ?mangment

According to the stage

T1, T2: TURBT, transurethral •  
cystodiathermy, or laser

T3: cystectomy •

T4: chemoradiotherapy •

Q5

Fever 38.5, tachycardia, loin pain and Costovertebral angle tenderness There are RBCs & 18000 WBC in

Urine analysis

① Diagnosis?

Pyelonephritis

② Management ?

1st Gluroquinolone

2nd second generation cephalosporin

3rd Aminopenicillin

For 7 to - 10 days

Q6

سؤال أكمل الفراغ

① sperm count.....39 million

② morphology.....4%

③ best modality of tertment of Erectile dysfunction in fail of medical treatment?

Penile prosthesis

④ ??treatment of psycho-social Erectile dysfunction(2)

⑤ ?most important physical sign in male infertility(2)

Q7

① treatment of epididymitits??

1st doxycycline

2nd Macrolide

For 14 days

② best imaging in prostat urethral trauma??

Urethrography

\* سوالات مشهوره وعلیها اجزاء  
 آناتومی

Q 8

1) most of semen fluid produced in??

**Seminal vesicle**

2) most common part associated with urethral-injury in pelvic fracture??

**Membranous urethra**

3) ??site of action of a-blocker in BBH-

**Bladder neck**

4) ??site of production PSA-

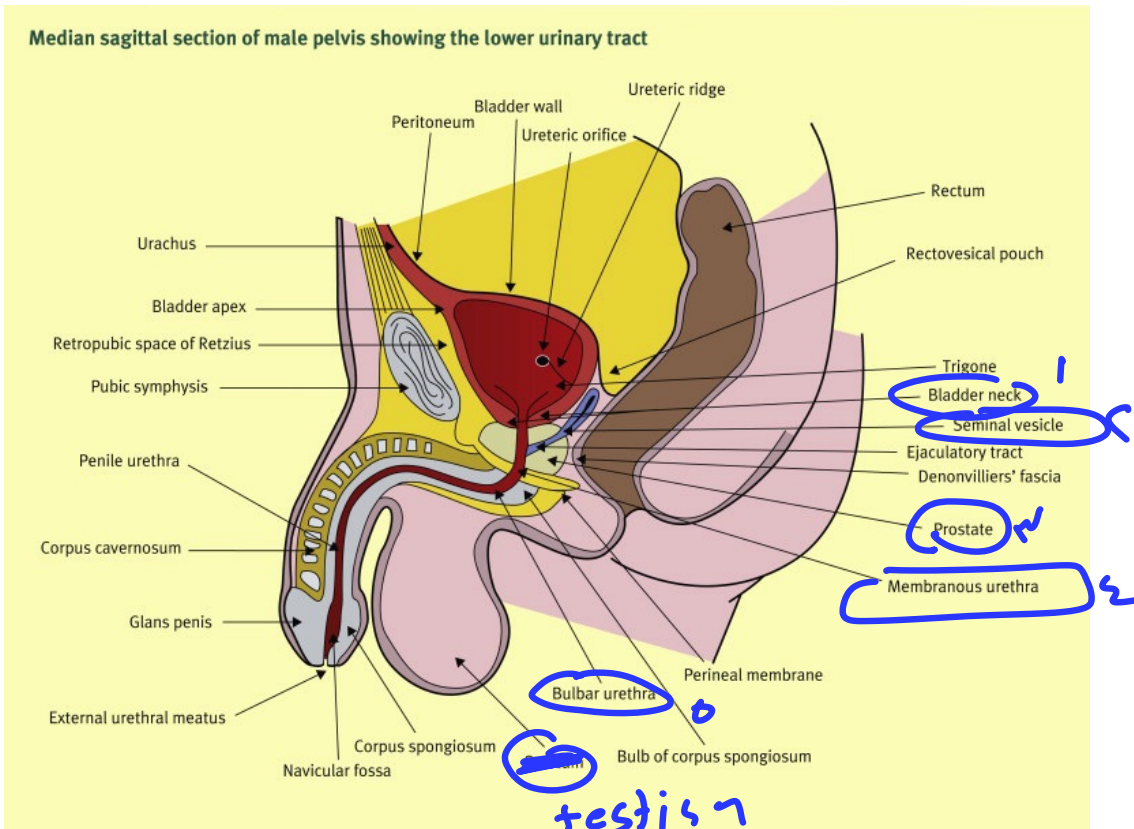
**Epithelial cells of prostate**

ونکیبی

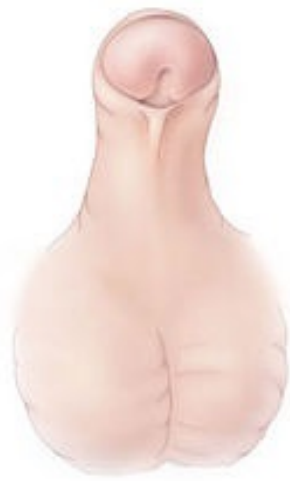کلی

جزء

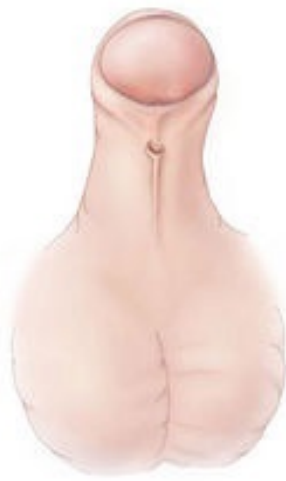(رهن + اسم)



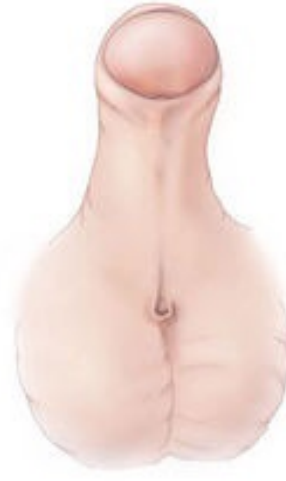Q9



Subcoronal



Midshaft



Penoscrotal

① What is this ?  
**Hypospadias**

② How to determine severity ?