

# Family medicine

1. 45 male Patient has discomfort and epigastric pain after 3 to 4 hours of meals

A) what's your diagnosis ? Duodenal ulcer

B) what's the first investigation for this patient? H. Pylori test

2. Female patient has abdominal pain radiate to the back, emesis and discomfort

A) three differential diagnosis ? Any two possible diagnosis

3. Male patient complains of fatigue from 7 months, with irritability he has sleep disturbances, impairment in concentration and exhaustion

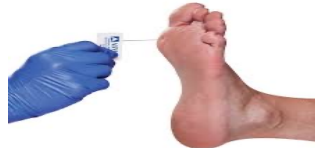1)dx : idiopathic fatigue syndrome

2)four investigations : CBC, CK, TSH , Chemistries

4. Dm type 2 patient with numbness and burning sensation, the level of B12 was normal and he is non alcoholic

A) what is this test ? Monofilament

B) Dx ? Peripheral neuropathy



5. Patient with migraine.....

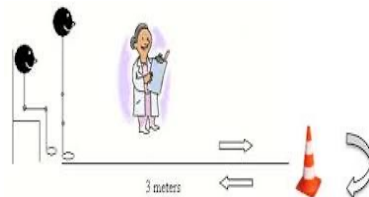
A) do you use prophylactic treatment ? Yes

B) two drug? Anticonvulsants, BB

6. according to this test

A) what is interpretation for this patient? High Dependence

B) two interventions ? Walking aid  
remove hazard in the home



30 seconds

7) Why family medicine ?

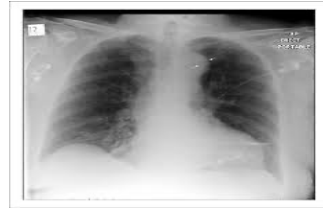- A) recent changes in medicine
- B) social changes
- C) limitations of resources
- D) better doctor patient relationship

8) HTN patient his medications ( thiazide + ACEi ) he has BPH

- A) what is the drug I can give to this patient? Alpha blocker
- B) give me one side effect of this drug ? Postural hypotension

9) I miss the scenario but patient with tearing pain ...

- A) dx : aortic dissection
- B) give me two findings

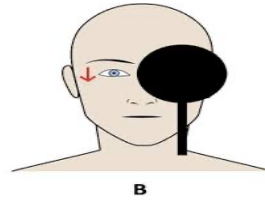


10) 45 male with DM ASCVD = 15%

- A) tx : moderate statin + life style modification
- B) one side effect : nausea

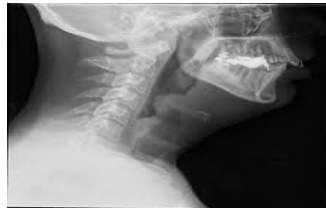11) according to the picture

- A) what is this test? Test of skew
- B) vertical gaze means? CNS problem ( stroke)



12) according to the picture

- A) sign? Thumbprint sign
- B) Dx ? Epiglottitis



13) male 52 years old , smoker pack year 20

- A) interval screening for lung cancer ? Every year
- B) two screening? Colon + depression

14)

- A) dx: osteoporosis
- B) first line treatment? Bisphosphonate

