

Tracheostomy and Chest tube

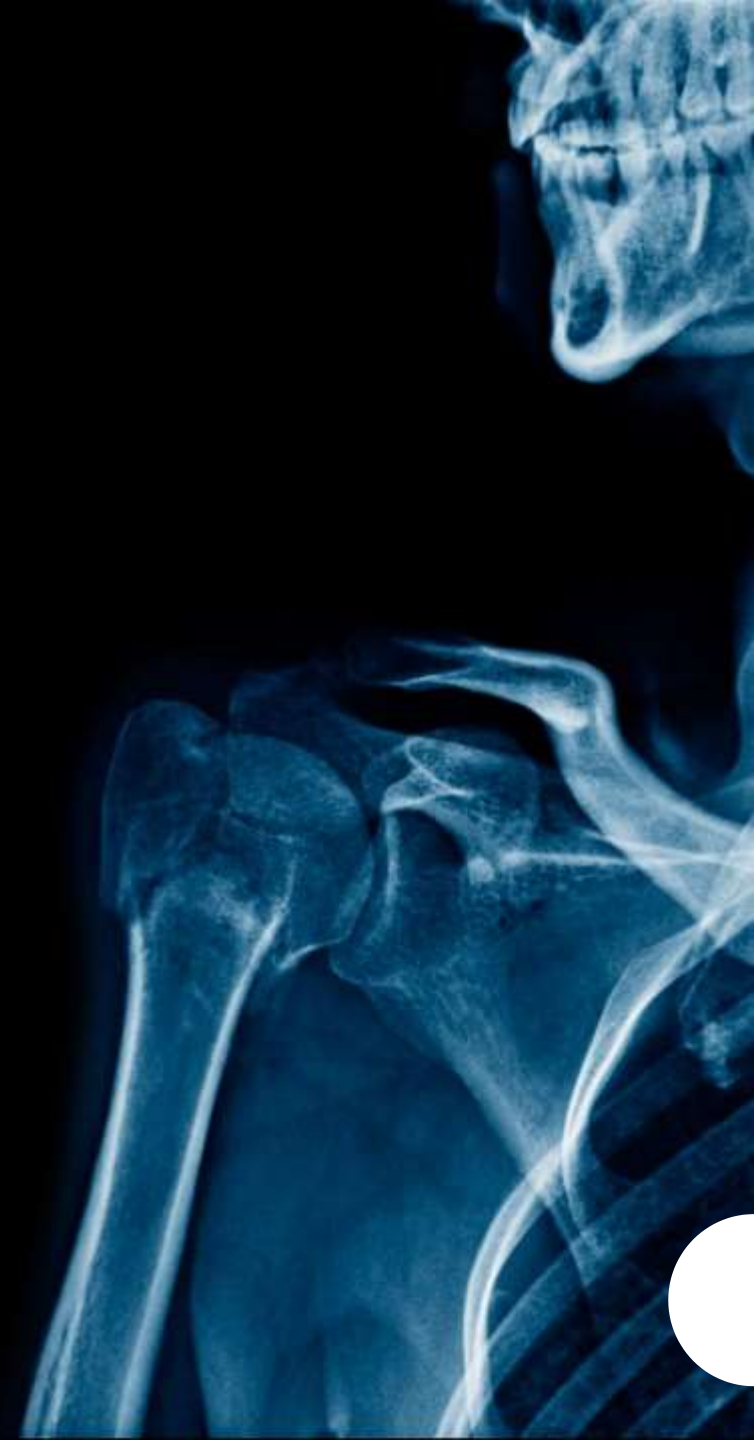Dr Mohd Asim Aideh

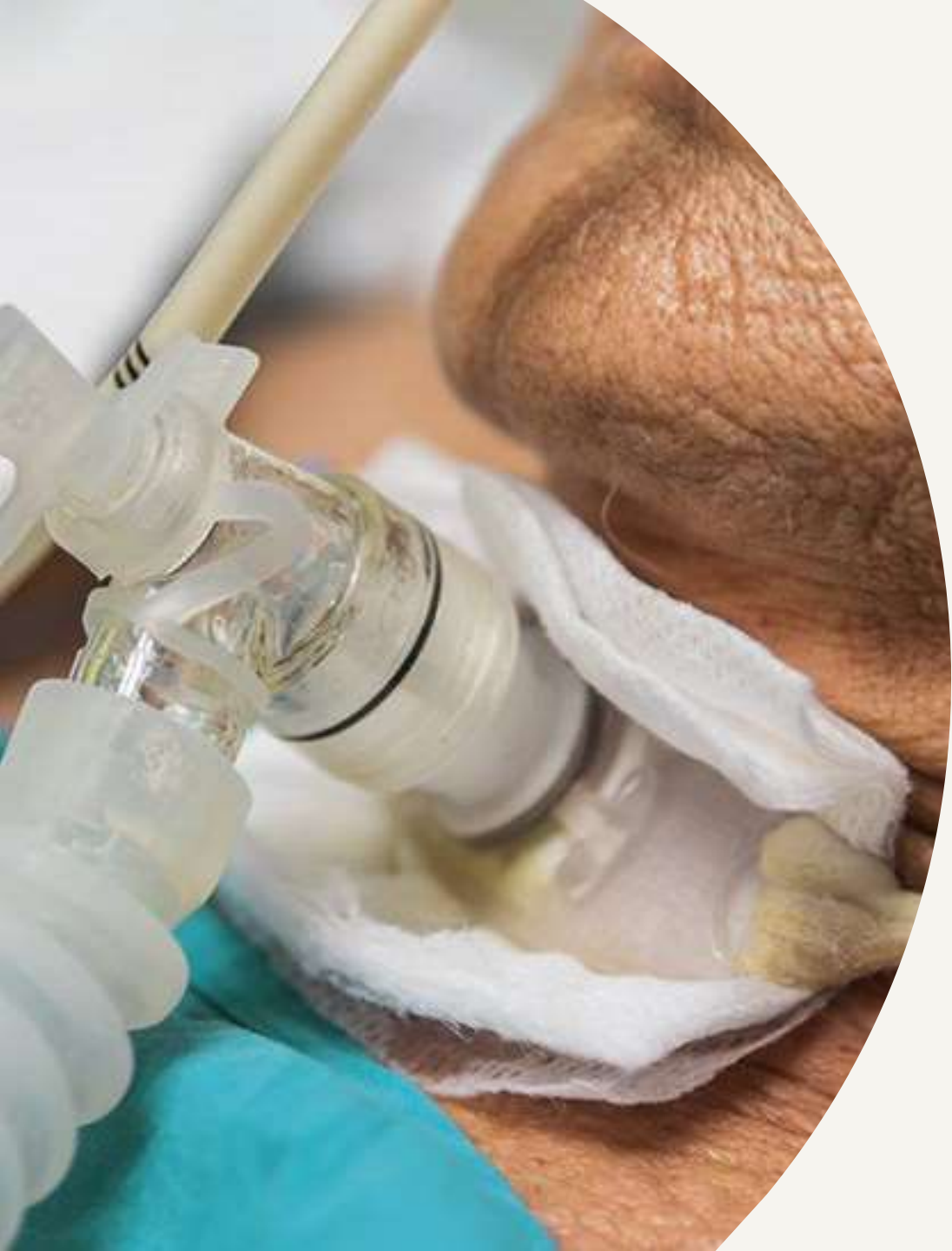MD, MRCS

Mu'tah University

Faculty of Medicine

Department of General surgery





Definition

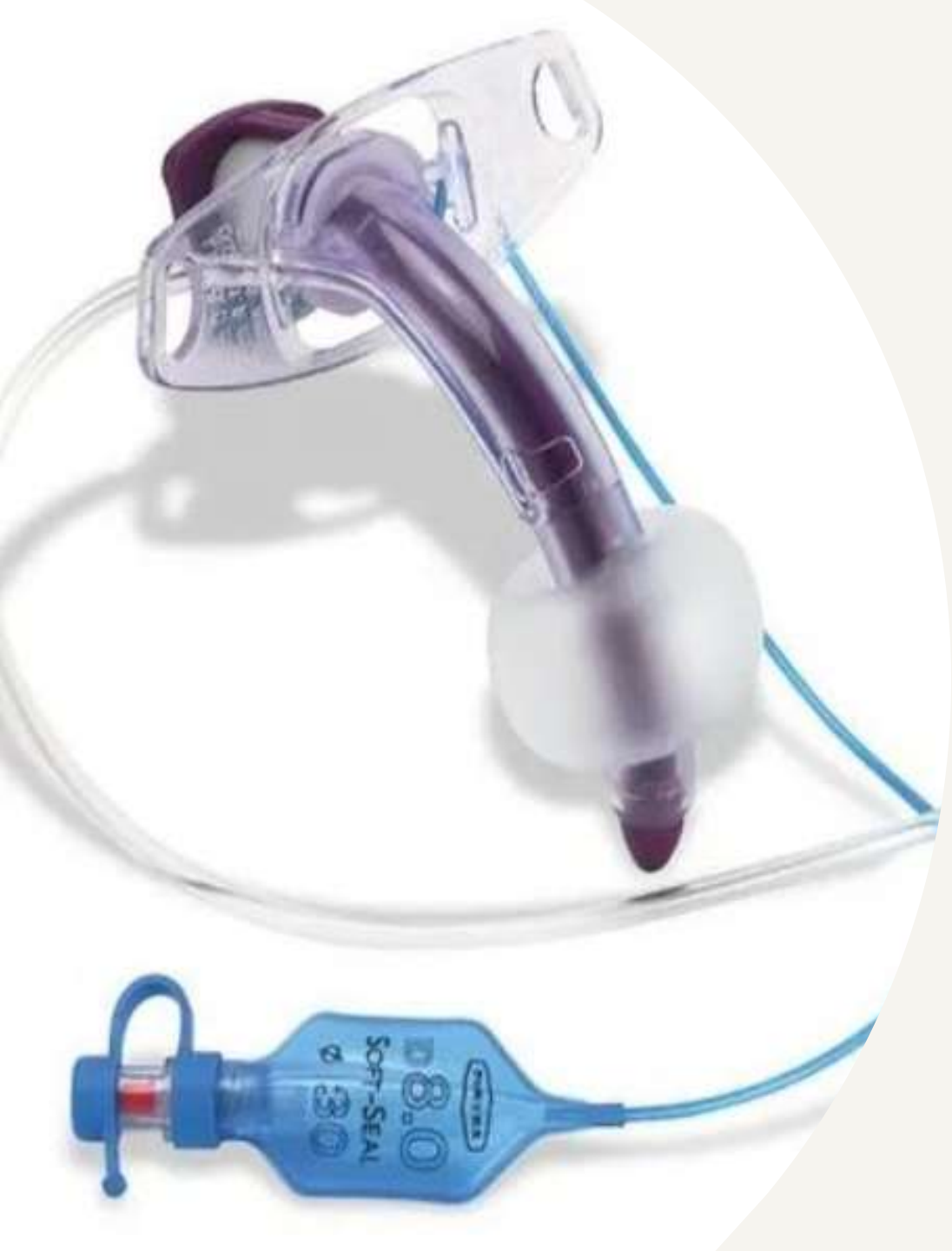- An artificial (usually) surgically created airway fashioned by making a hole in the anterior wall of the trachea and the insertion of a tracheostomy tube, which may or may not be permanent.

Types of surgical airway

1- Elective Tracheostomy

2- Cricothyroidotomy (Mini Tracheostomy)

3- percutaneous Dilatational Tracheostomy

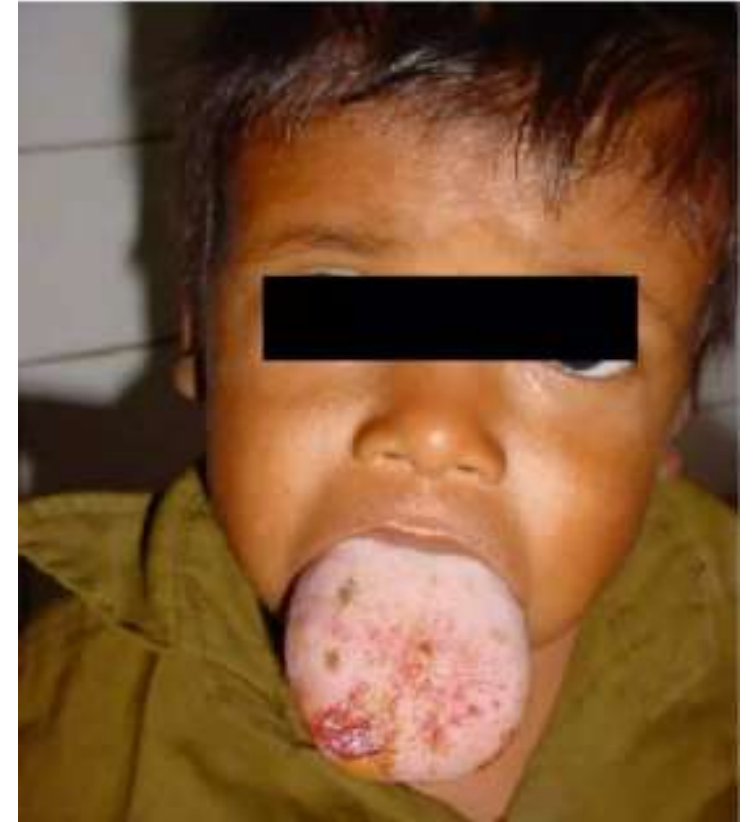

Indications

- . Upper Airway Obstruction.
- . Pulmonary Ventilation.
- . Pulmonary Toilet.
- . Elective Procedure.

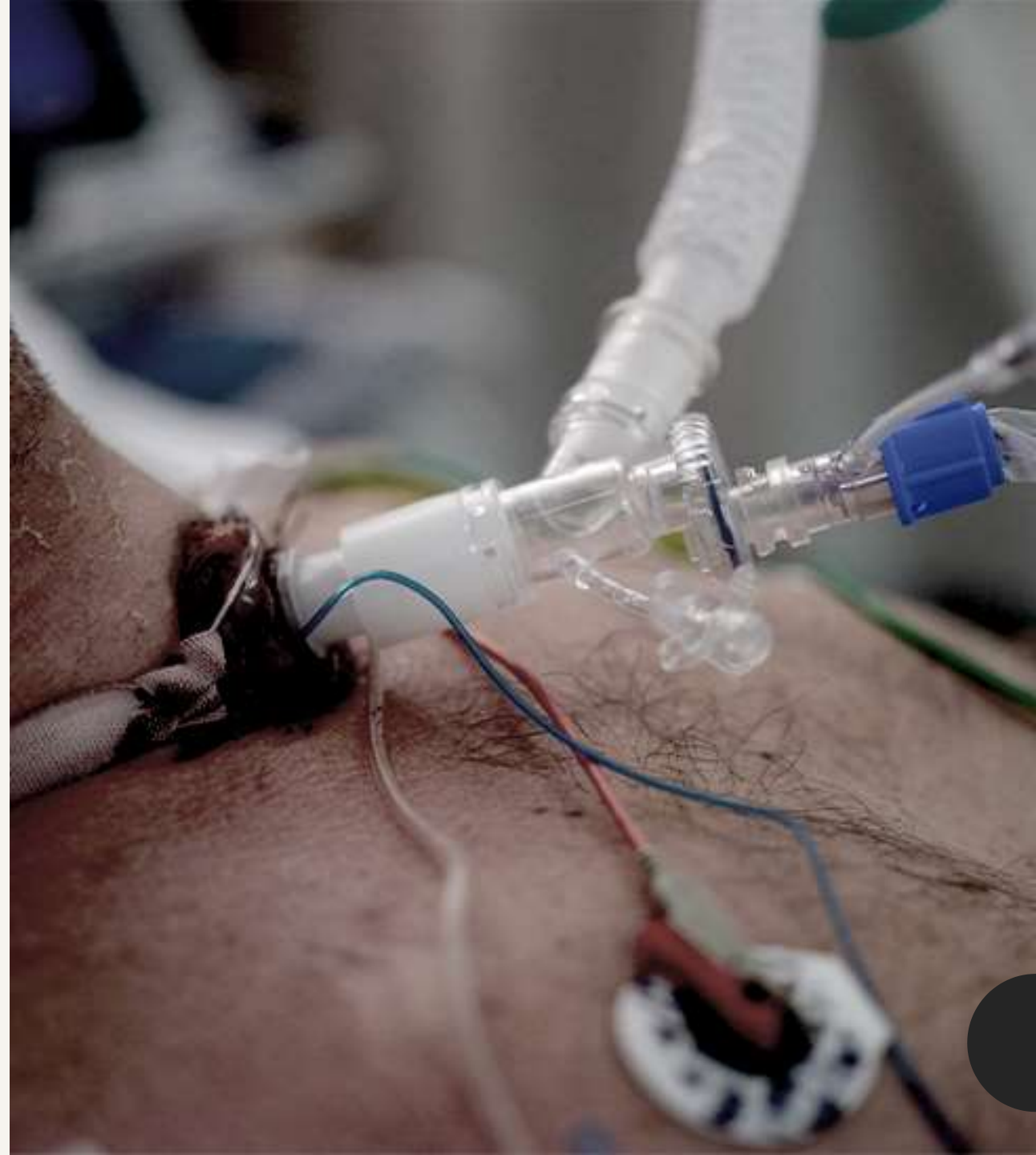
Upper Airway Obstruction

- Trauma
- Foreign body
- Infections
- Malignant lesions
- Vocal cord palsy



Pulmonary Ventilation

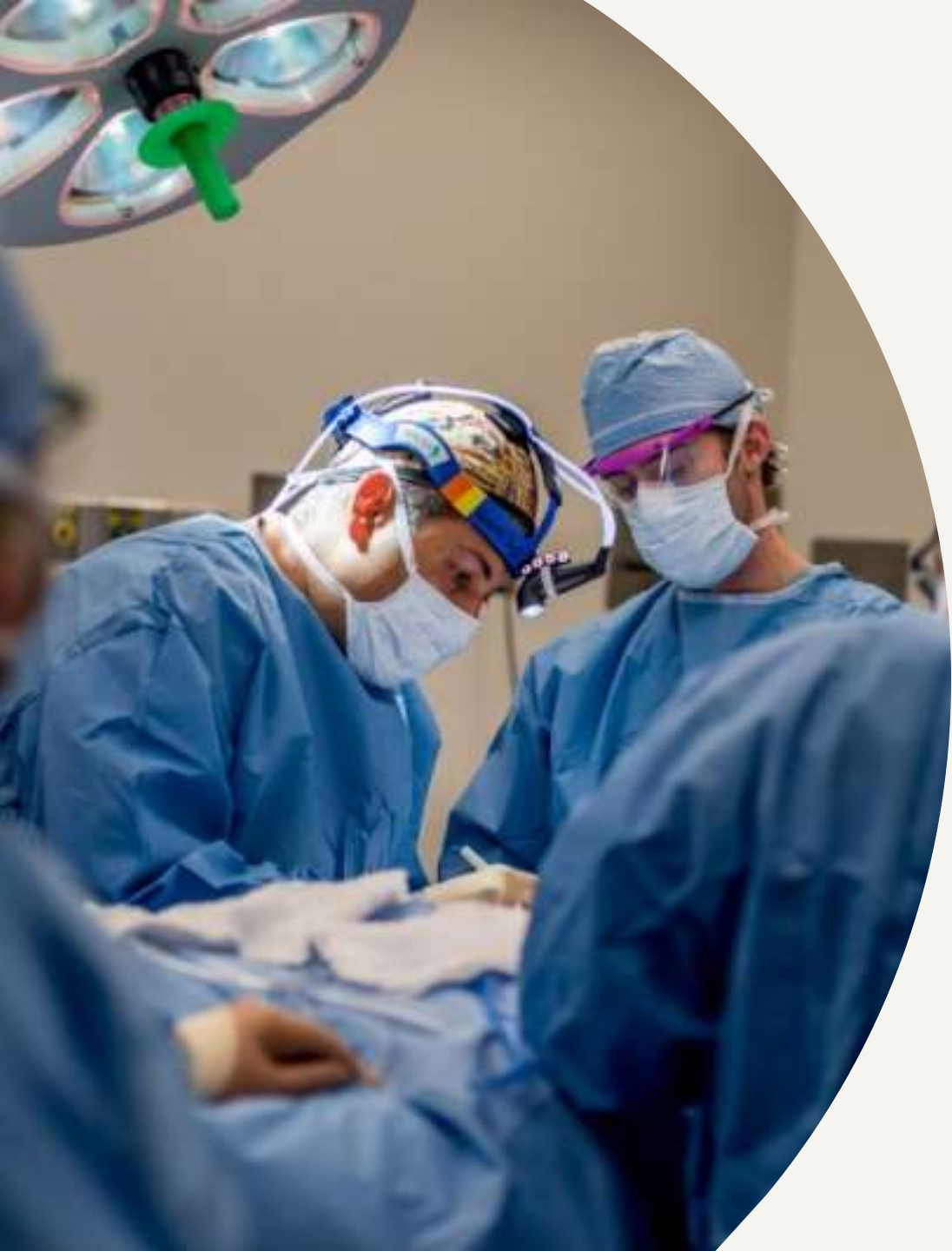- Tracheostomy should be performed in a patient still requiring ventilation through an endotracheal tube for more a one week



Pulmonary toilet

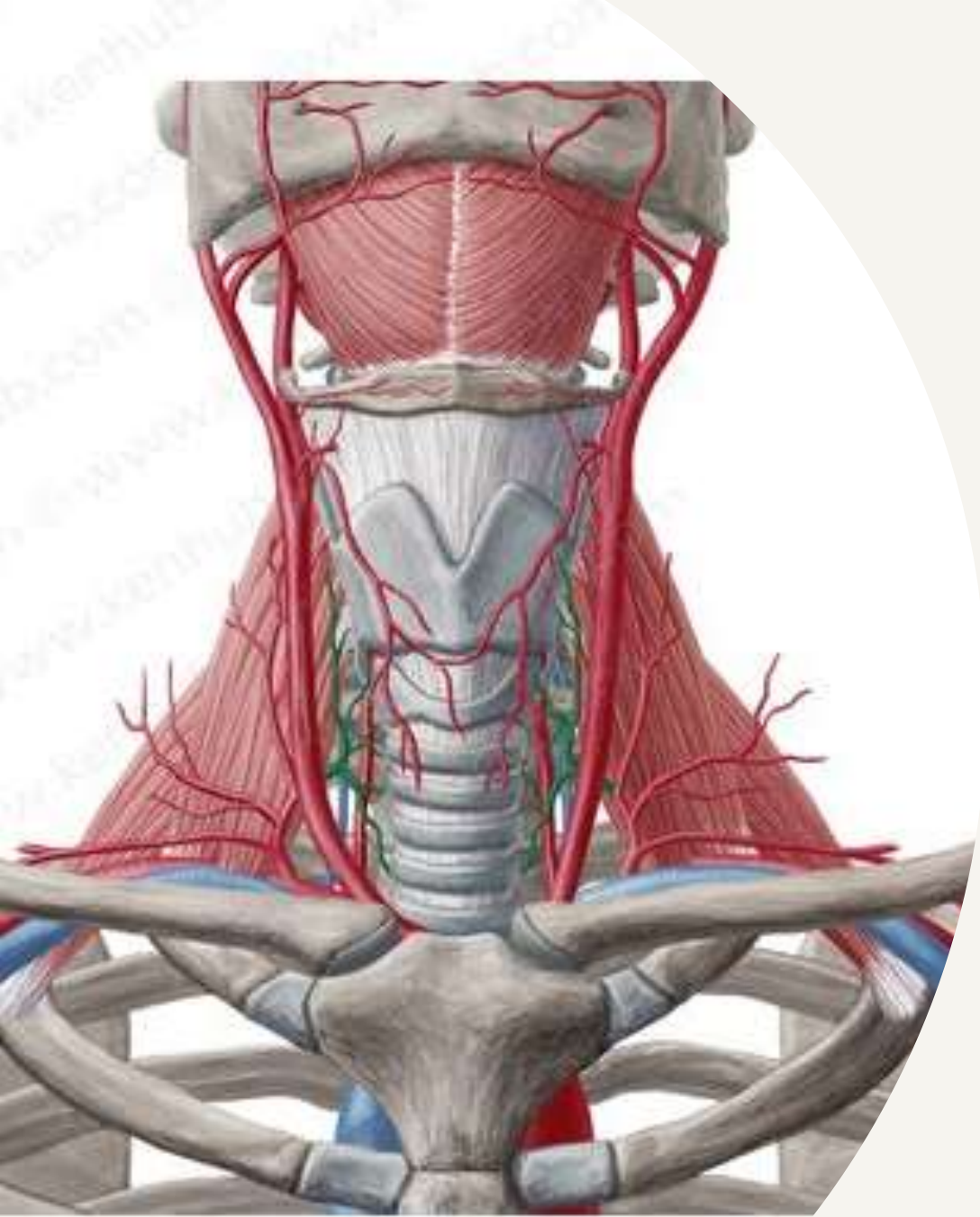
Those who cannot cough and clear their chest.

Prevent aspiration by low-pressure high-volume cuff tracheostomy tube.



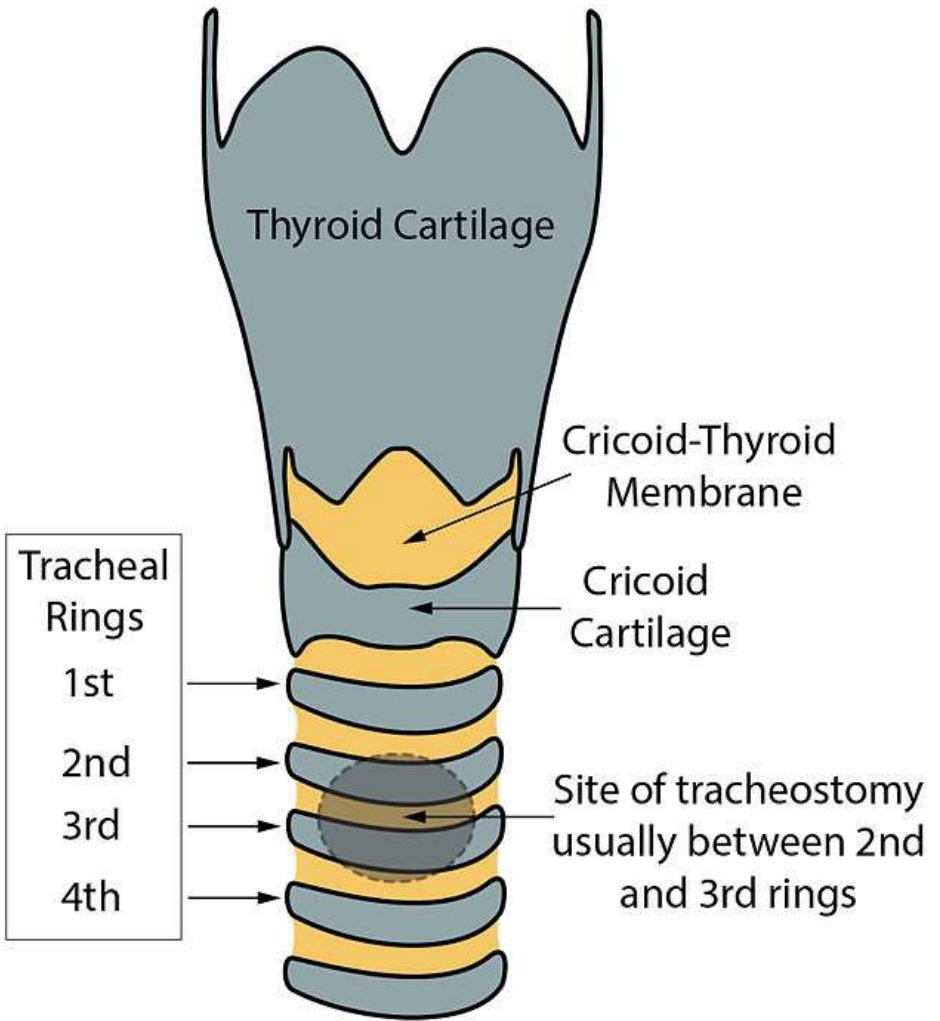
Elective procedures

- For major head and neck operations.

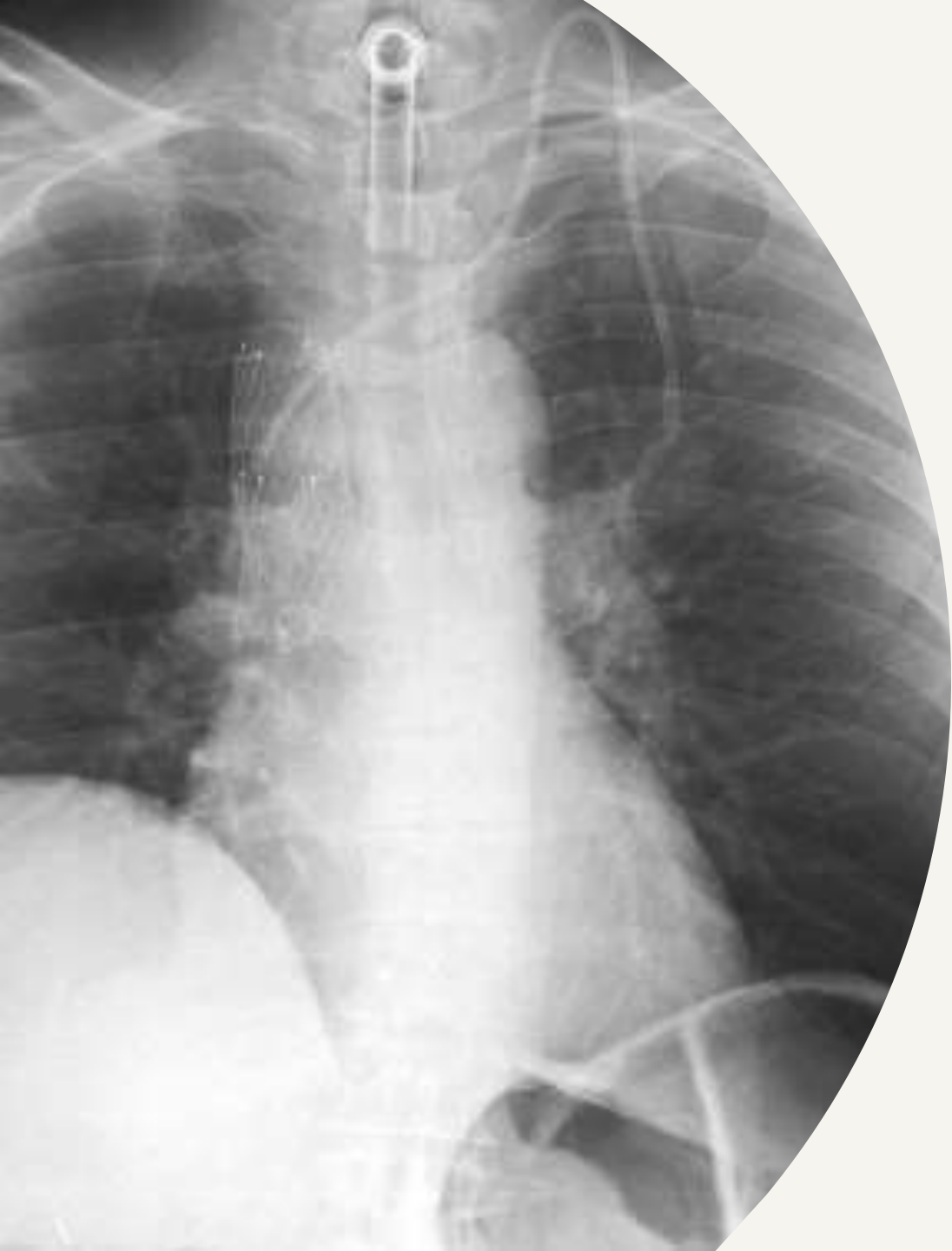

anatomy

- Trachea lies in midline of the neck extending from cricoid cartilage C6 superiorly to the tracheal bifurcation at the level of sternal angle of Luis T4.
- Comprises of 16-20 C shaped cartilage rings.
- Length 10-12 cm.
- Diameter 15-20 mm.

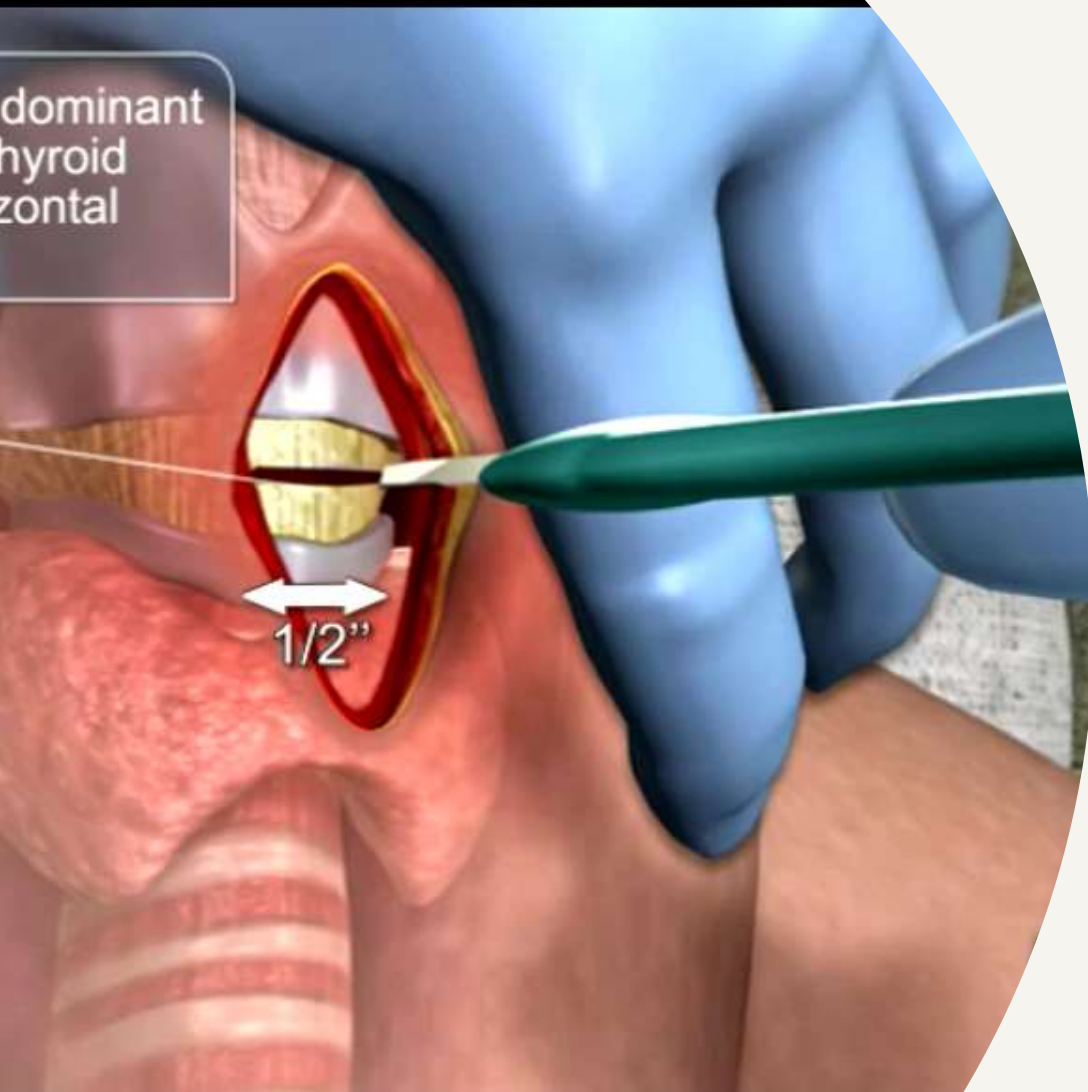


-
- Where do cricothyroidotomy insert?
 - Where do tracheostomy insert?
 - What are the layers anterior the trachea?



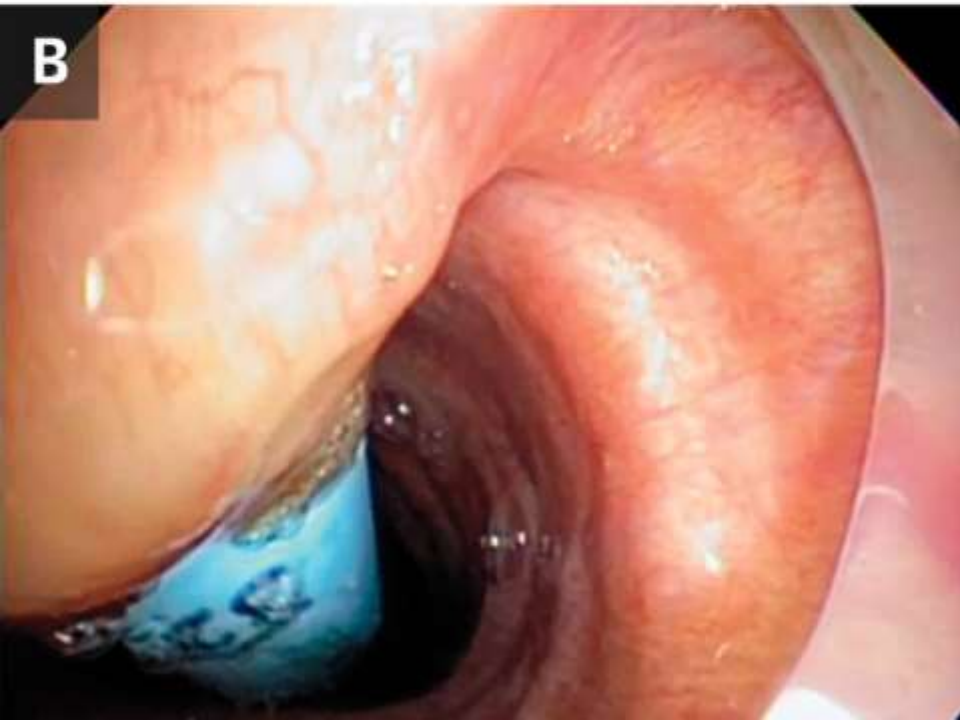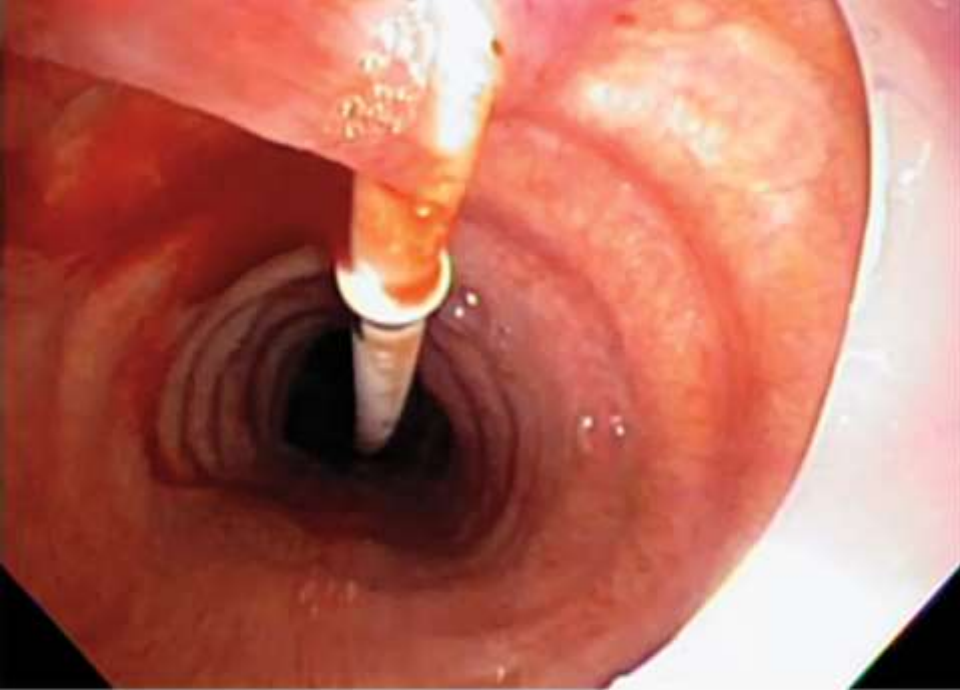- 1- skin
 - 2- subcutaneous tissue and fascia
 - 3- anterior jugular vein
 - 4- pretacheal muscle
 - 5- thyroid isthmus
 - 6- pretracheal fascia
 - 7- trachea
-

dominant
thyroid
horizontal



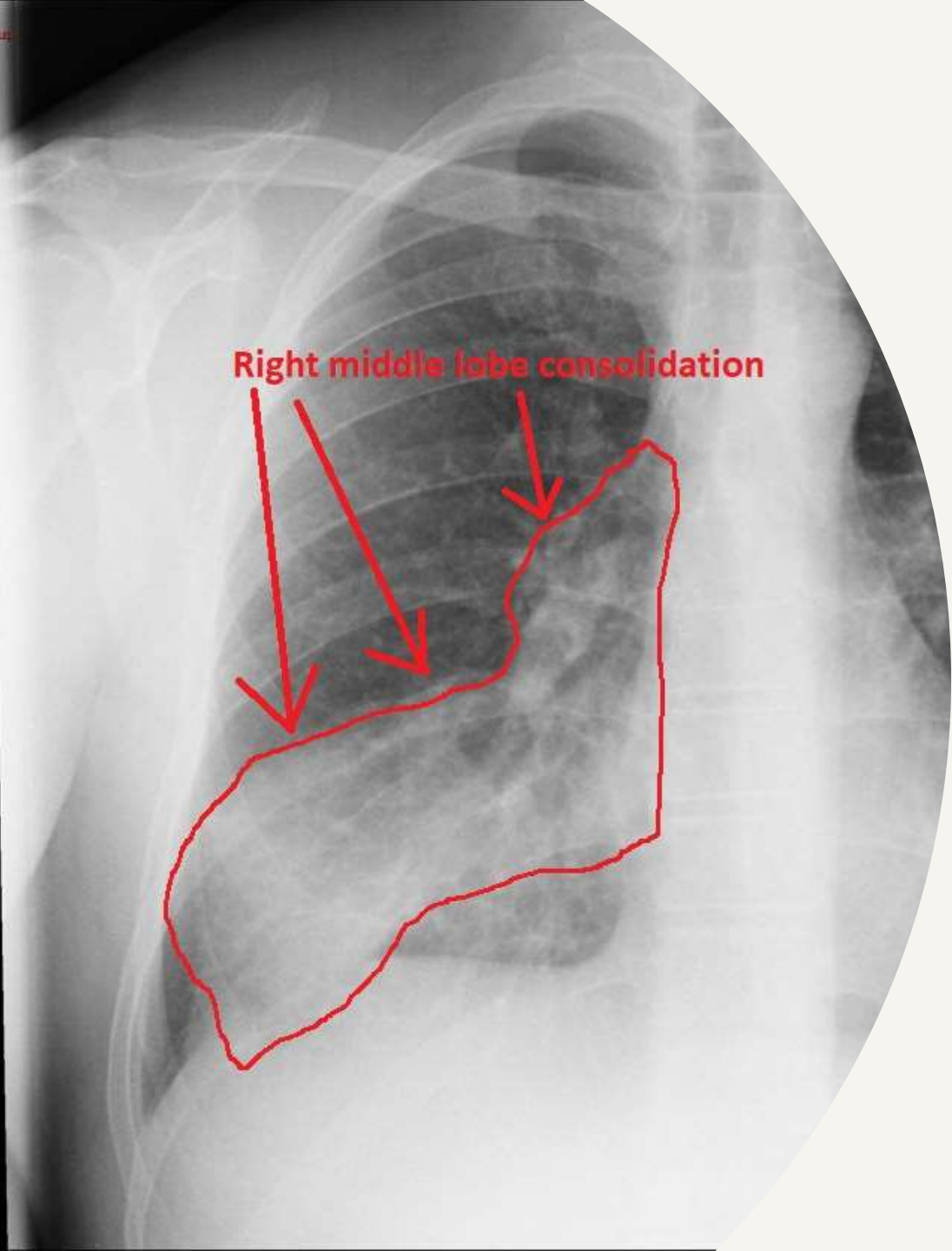
Cricothyroidotomy (*mini tracheostomy*)

- Transverse incision over the cricothyroid membrane.



Percutaneous dilatational tracheostomy

- ICU bed side tracheostomy.
- Use of guide wire and dilators.
- May be under the vision of bronchoscope through endotracheal tube.
- Less time, less expensive.
- Not suitable for thick neck and in emergency.



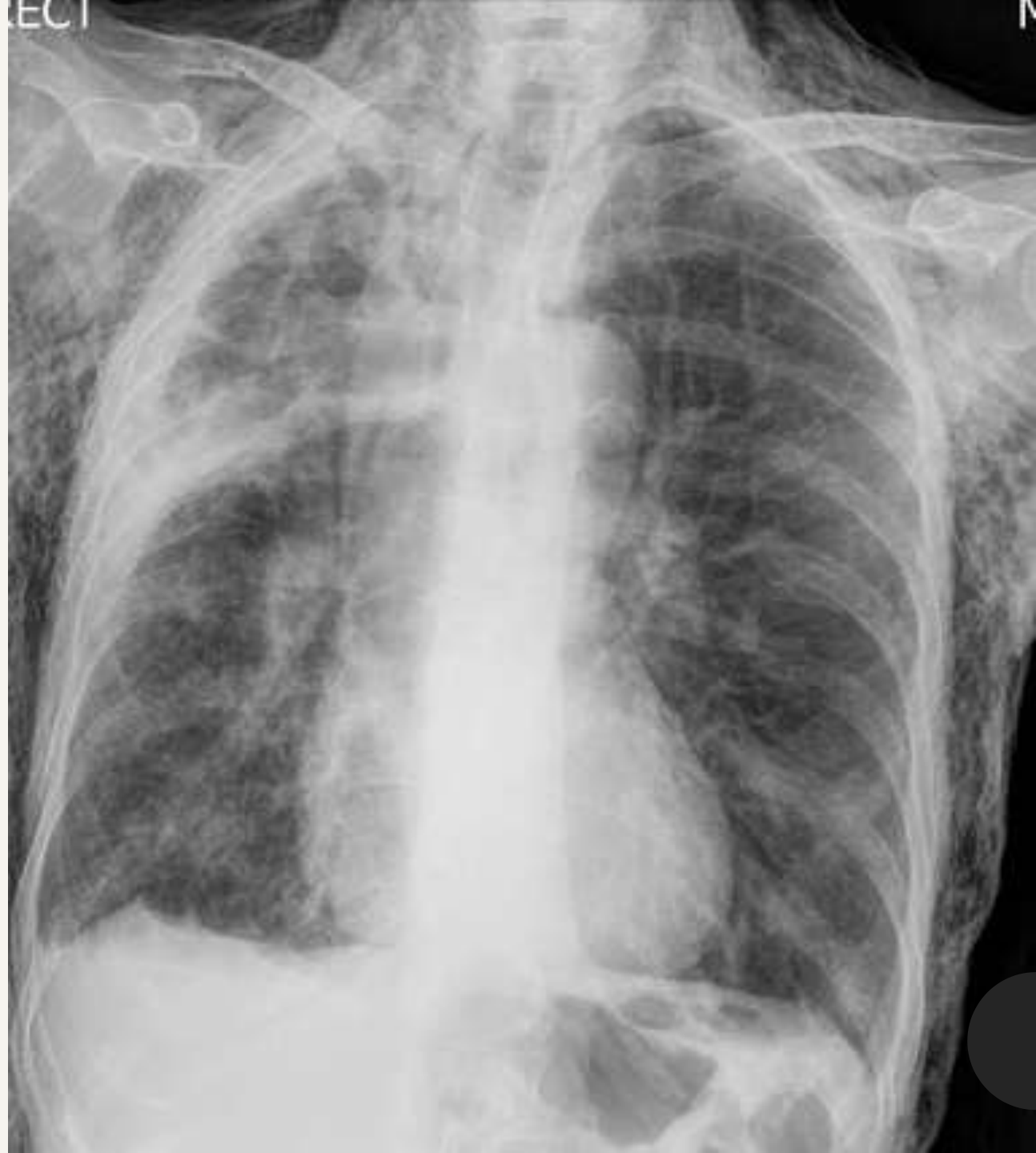Complications of tracheostomy

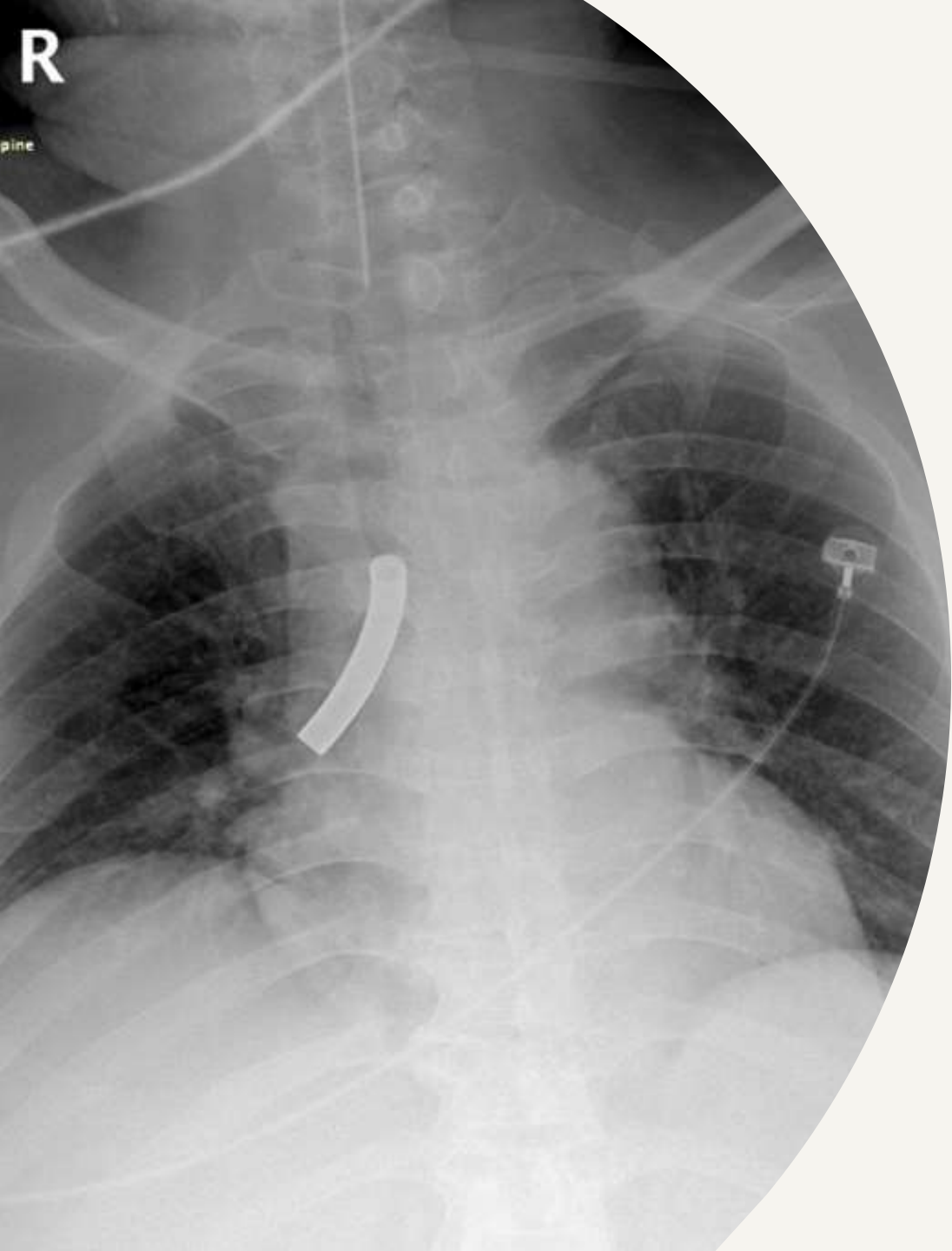
Intraoperative complications:

- Loss of airway
- Bleeding and injury to big (major) vessels
- Injury to tracheoesophageal wall
- Pneumothorax
- Aspiration

Early complications

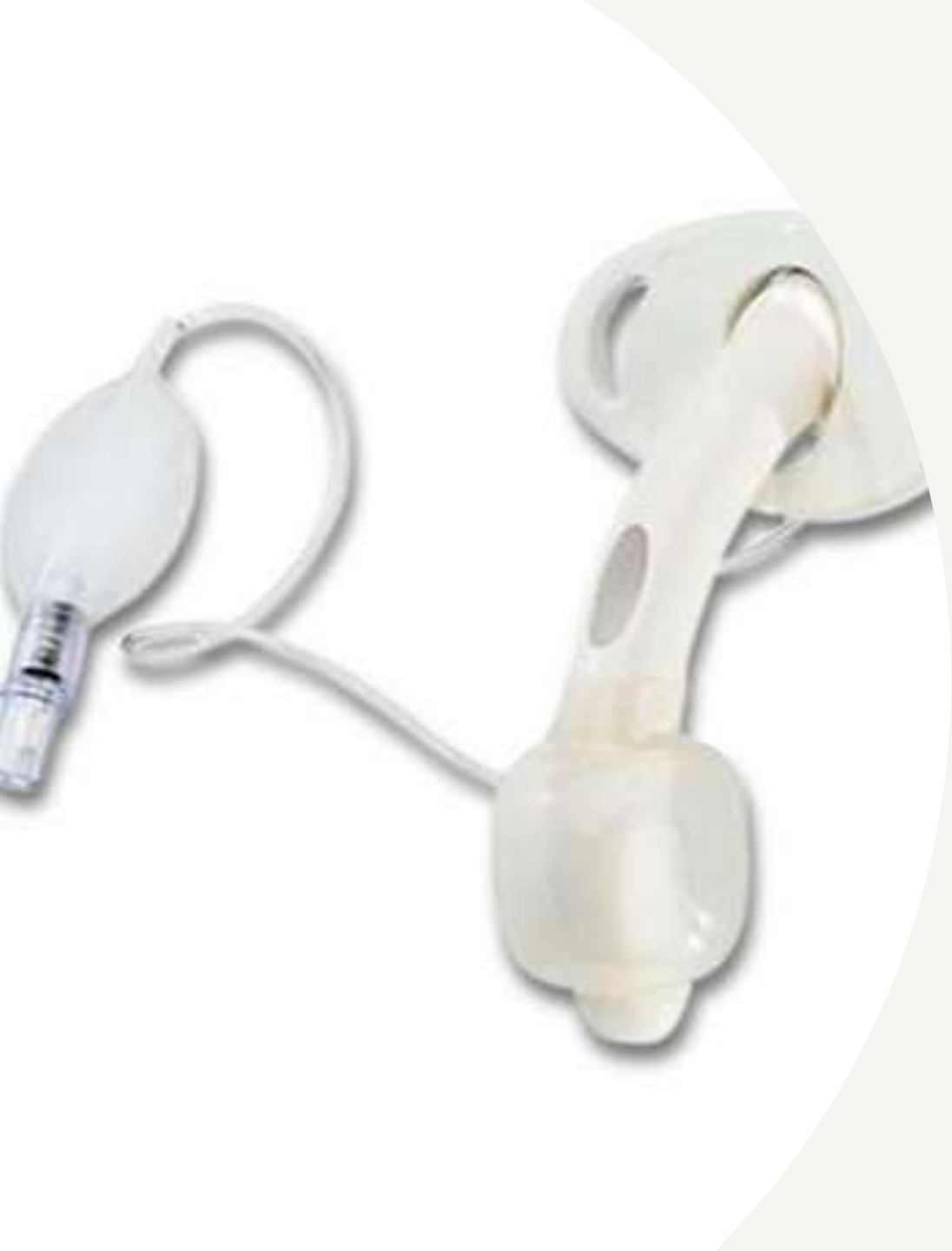- Bleeding and local hematoma
- Tracheostomy tube obstruction and desaturation
- Tracheostomy tube displacement
- Infection
- Surgical emphysema





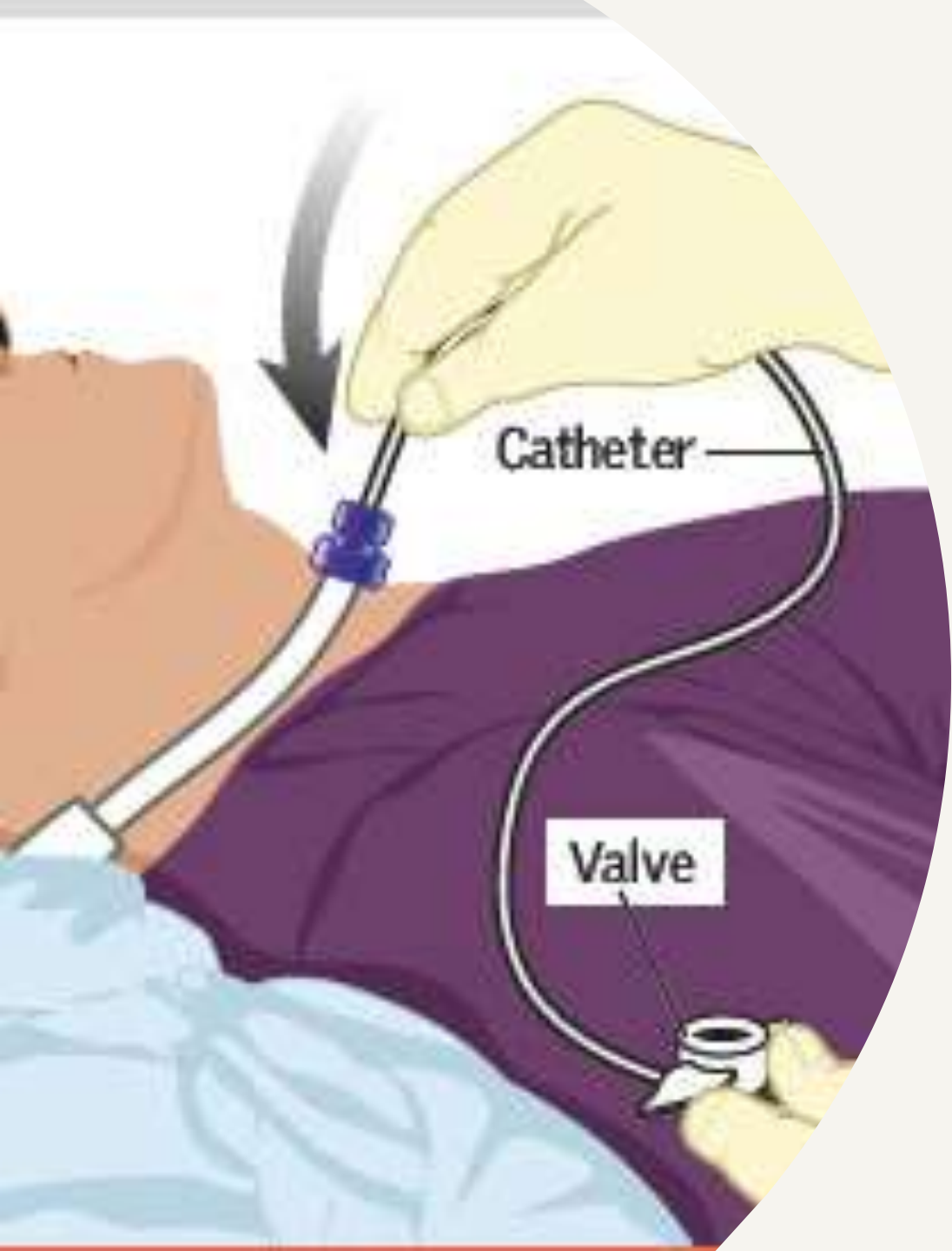
Late complications:

- Tracheal or subglottic stenosis
 - Granulation tissue
 - Tracheocutaneous fistula
 - Tracheo-esophageal fistula
 - Dislocation of tracheostomy tube
 - Bleeding from stoma or during suction
 - Blockage of tracheostomy tube
 - Laryngeal injury or alteration of phonation
-



Tracheostomy tubes

- Plastic / metal
- Fenestrated / Non fenestrated
- Cuffed / uncuffed

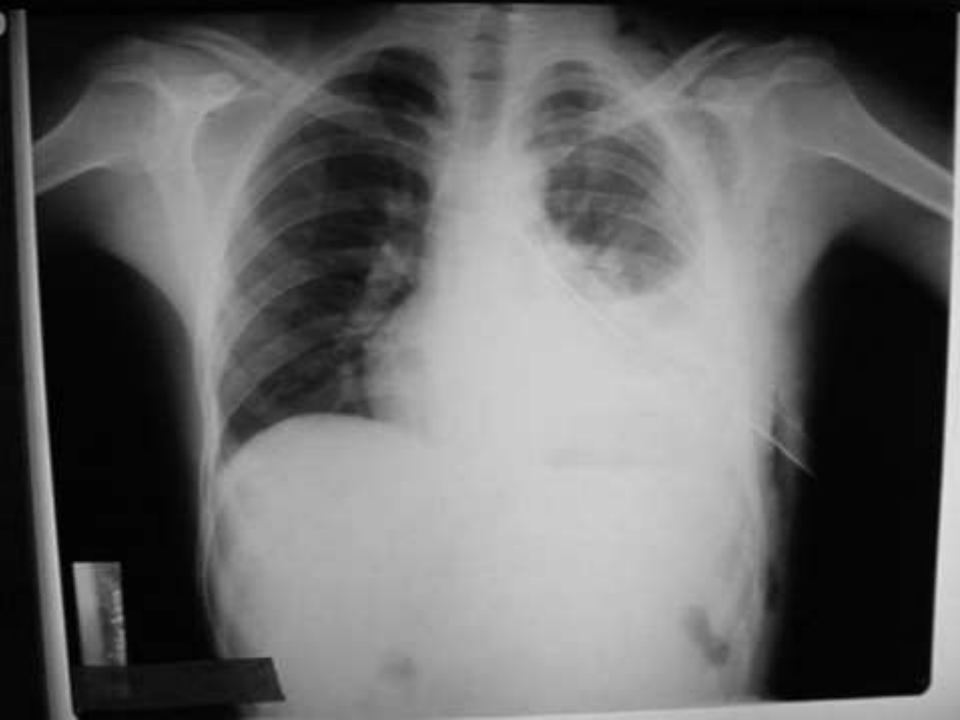
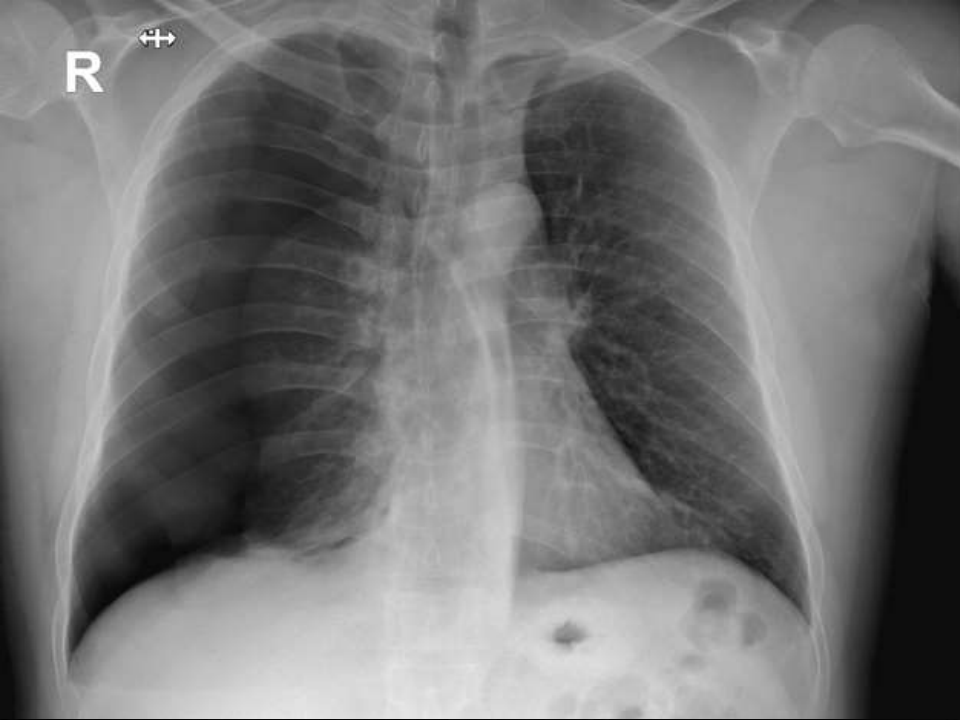
Tracheostomy patient care

- Safety first
- Care of the stoma (suction) - using aseptic technique and dressing – 2 to 3 times per day – once removed the stoma will close over few days.
- Nutrition - can the patient eat?
- Infection control

Chest tube


Intercostal drainage is the insertion of a tube into the pleural space to evacuate air/fluid, to help regain negative pressure and thus promote lung expansion.



Indications

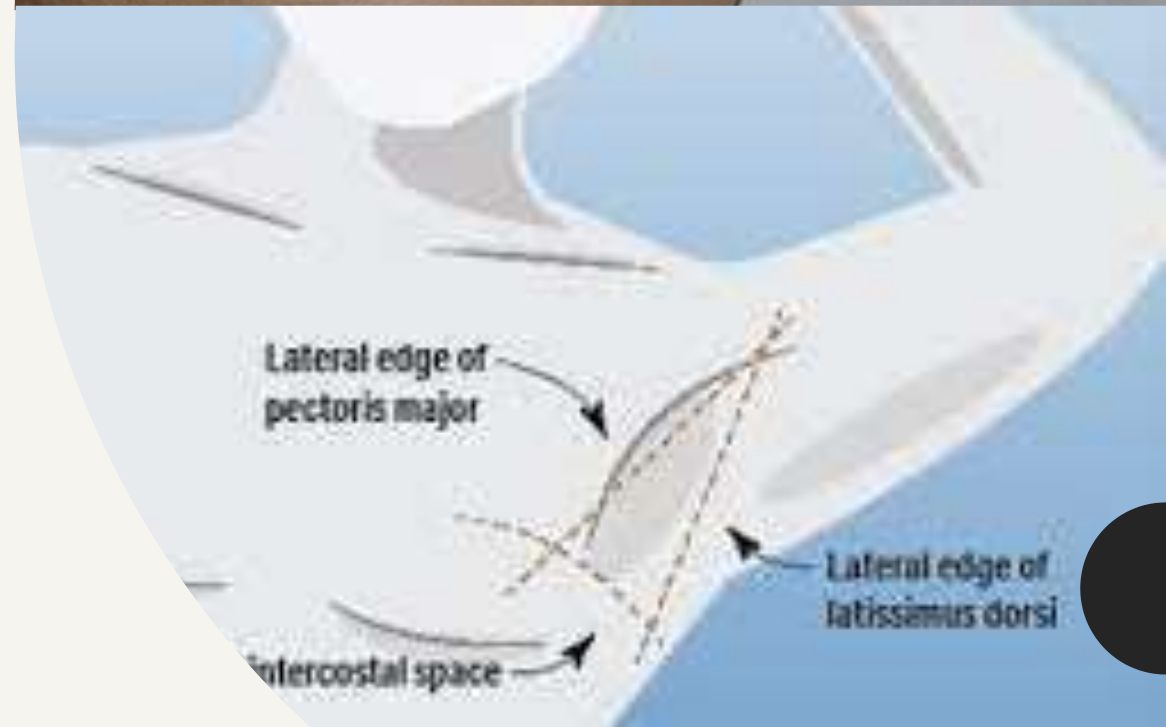
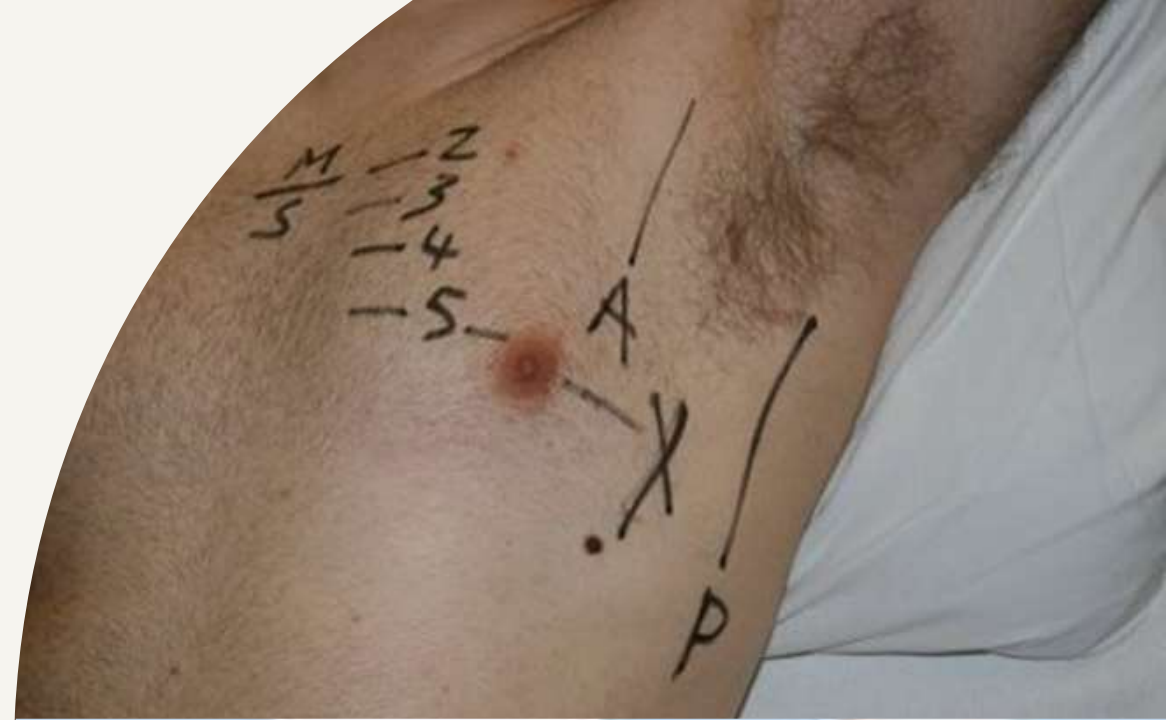
- Pneumothorax (primary – secondary – tension)
- Hemothorax
- Pleural effusion (malignant – empyema)
- Chylothorax
- Post operative cardiothoracic surgery
- Mechanically ventilated patients with any size pneumothorax / hemothorax

Contraindications

- *Lung adherent to the chest wall*
 - *Uncorrected coagulopathy*
 - *Skin infection*
 - *Loculated pleural effusion*
- 

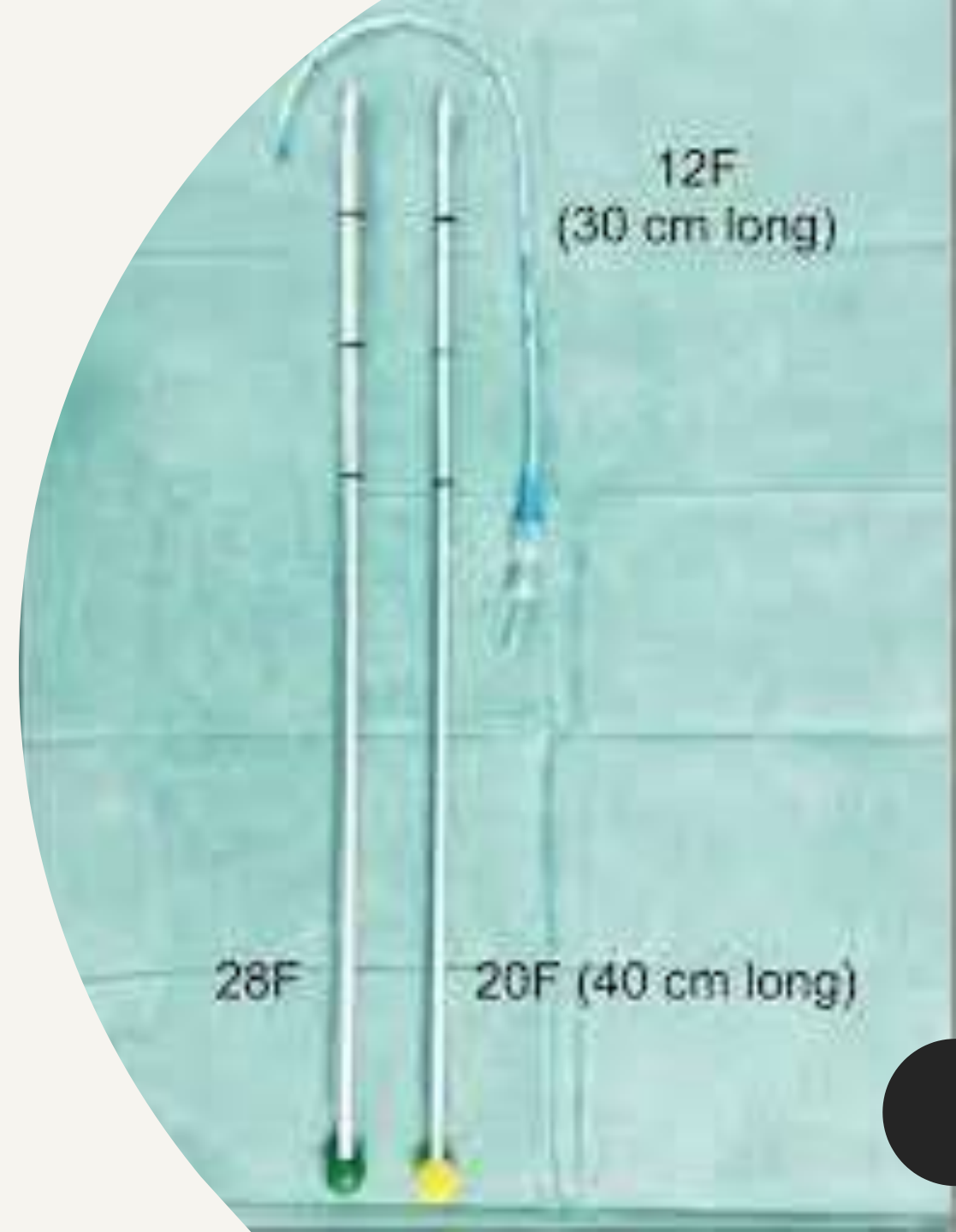
Site of insertion

- Triangle of safety – boundaries ?
- 4th to 5th intercostal space, anterior to the mid axillary line
- Patient position ? (supine – sitting/semi - lateral position, with ipsilateral arm behind her/his head)

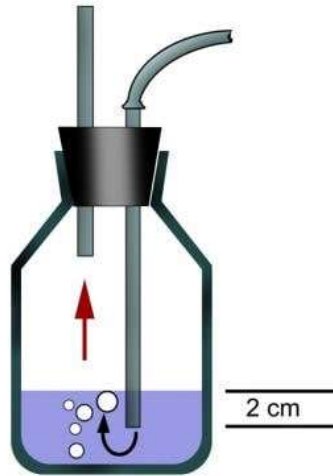


Size of tube

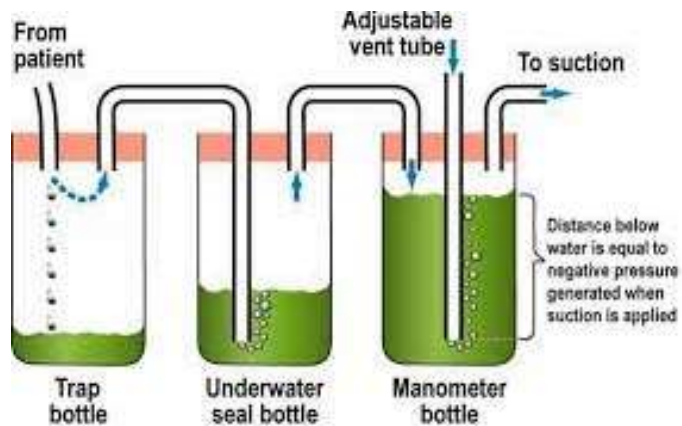
- The unit of chest tube size is French sizing, which refers to circumference in millimeters
- Adult : 28-32 Fr
- Child : 18 Fr
- Newborn : 12-14 Fr

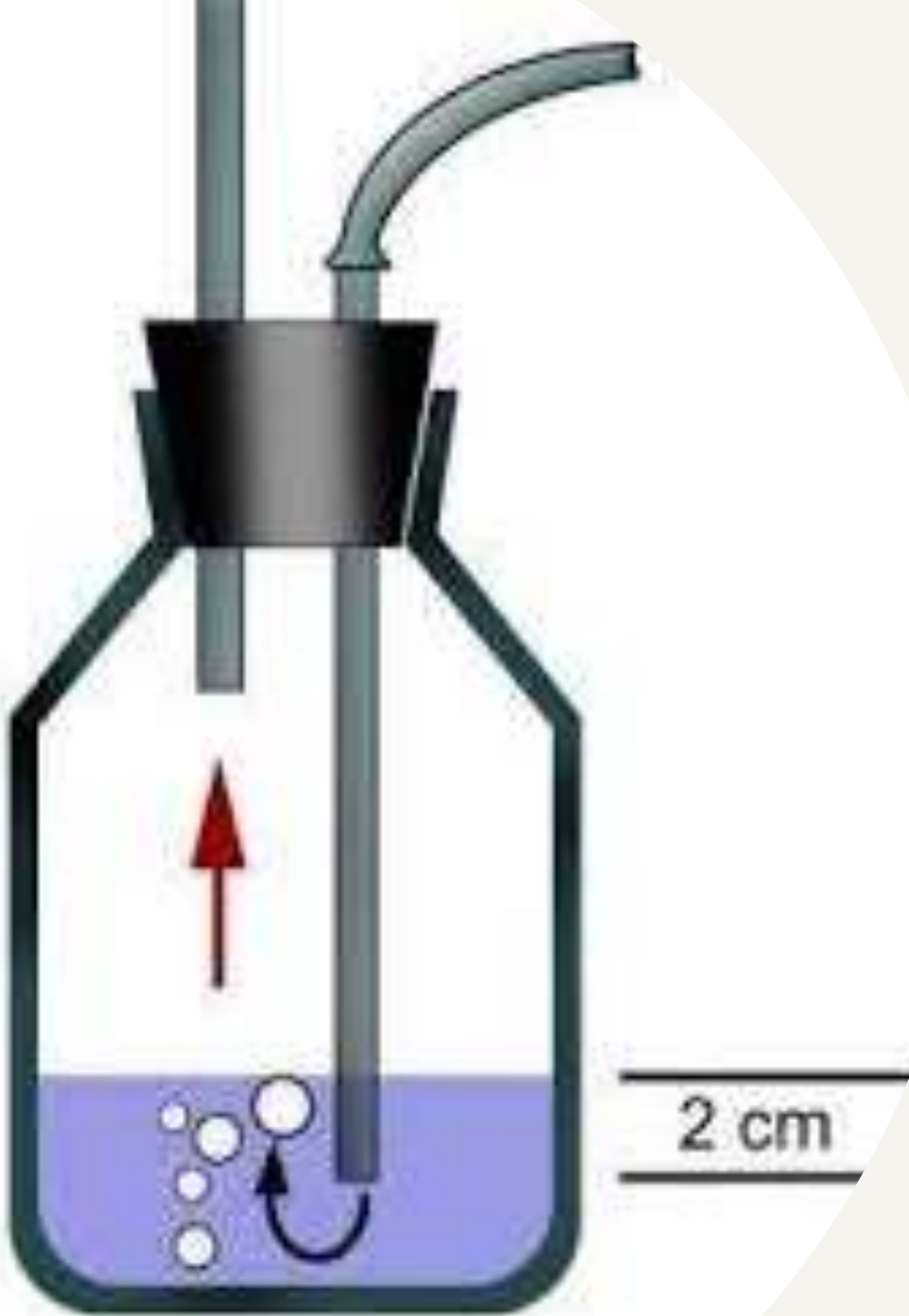


Chest tube bottle



- Underwater seal
- 3 chamber bottle (collection chamber – water seal chamber – suction control chamber)

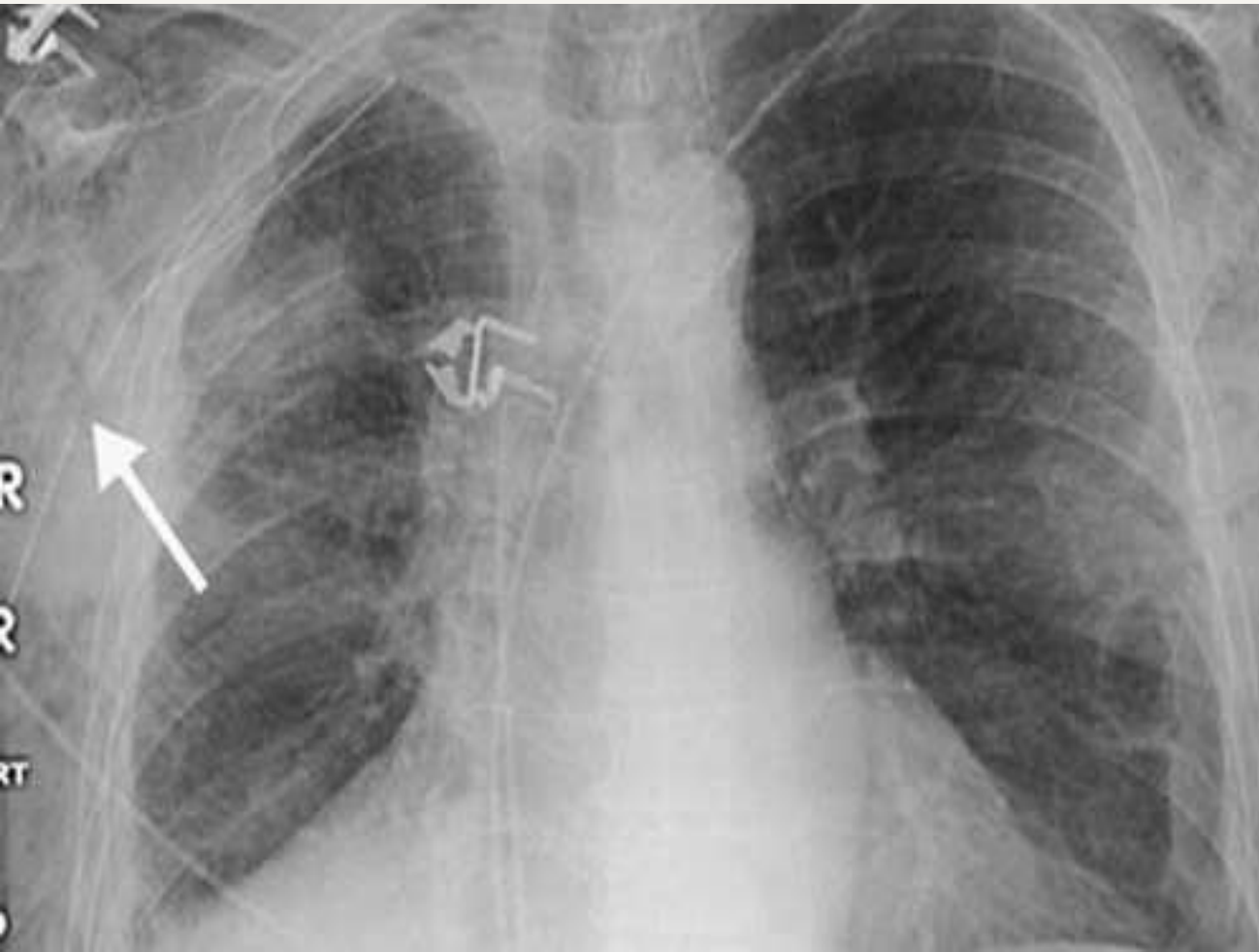




How to confirm that the chest tube is functioning?

-
- 1- physical examination : bilateral chest wall movement – air entry – improve saturation .
 - 2 – fogging of the tube
 - 3- bubbling
 - 4 – chest Xray

Complications



- Injury to the neurovascular bundle in the ICS
- Injury to lung parenchyma
- Injury to the diaphragm and consequent injury to intraperitoneal structures
- Injury to the heart and other great vessel
- Massive bleeding
- Empyema
- Skin excoriation and inflammation
- Subcutaneous emphysema and hematoma
- Obstruction
- Malposition
- Re-expansion pulmonary edema