

NEOPLASIA 1

Neoplasia means “new growth,” and a new growth is called a neoplasm.

Tumor originally applied to the swelling caused by inflammation

Oncology: (Greek oncos = tumor) is the study of tumors or neoplasms.

Although all physicians know what they mean when they use the term neoplasm.

British oncologist Willis came closest: “A neoplasm is an abnormal mass of tissue, the growth of which exceeds and is uncoordinated with that of the normal tissues and persists in the same excessive manner after cessation of the stimuli which evoked the change.

COMPONENTS OF THE TUMOR

Neoplastic cells: that constitute the tumor parenchyma

Reactive stroma: made up of connective tissue, blood vessels, and variable numbers of cells of the adaptive and innate immune system.

CLASSIFICATION OF TUMORS

The classification of tumors and their **biologic behavior** are based **primarily on the parenchymal component**, but their **growth** and spread are critically **dependent on their stroma**.

In some tumors, connective tissue is scant ([refers to the tumor having a limited or insufficient amount of supportive connective tissue, also known as the stroma.](#)) and so the neoplasm is soft and fleshy ([easily broken or crumbled](#)) e.g. Lymphoma.

In other cases, the parenchymal cells stimulate the formation of an **abundant collagenous stroma**, referred to as **desmoplasia**.

Some desmoplastic tumors—for example, some cancers of **the female breast**—are stony hard or scirrhous ([very hard and firm](#)).

BENIGN TUMORS

A tumor is said to be benign, when its gross and microscopic appearances are considered relatively innocent, implying that it will **remain localized, will not spread to other sites**, and is [amenable \(willing to\)](#) to local **surgical removal**; understandably, the **patient generally survives**.

However, may cause significant morbidity and are sometimes even fatal.

BENIGN TUMORS (NOMENCLATURE)

Benign tumors are designated by attaching the suffix **-oma** to the name of the cell type from which the tumor originates.

Tumors of **mesenchymal cells generally follow this rule**. For example, a benign tumor arising in fibrous tissue is called a **fibroma**, whereas a benign cartilaginous tumor is a **chondroma**.

In contrast, the nomenclature of benign epithelial tumors is more complex; some are classified based on their **cells of origin**, others on **microscopic pattern**, and others on their **macroscopic architecture**.

BENIGN TUMORS

Adenoma is applied to **benign epithelial neoplasms derived from glands**, although they **may or may not form glandular structures**.

On this basis, a benign epithelial neoplasm that arises from renal tubular cells growing in the form of numerous tightly clustered small glands is termed an adenoma, as is a heterogeneous mass of adrenal cortical cells growing as a solid sheet.

If renal tubular cells (from the kidney) grow into many small, tightly packed glands, it's still called an **adenoma** because it's gland-derived. If adrenal cortical cells grow into a solid sheet without forming glands, it's also an **adenoma**, simply because the tumor arises from glandular epithelial cells. The key is the origin of the tumor (glandular epithelial cells), not necessarily the tumor's appearance.

Benign epithelial neoplasms producing **microscopically or macroscopically visible** fingerlike or warty projections from epithelial surfaces are referred to as **papilloma**.

Those that form large cystic masses, such as in the ovary, are referred to as **cystadenomas**.

Some tumors produce papillary patterns that protrude into cystic spaces and are called **papillary cystadenomas**.

benign epithelial tumors characterized by the formation of **cystic spaces** (fluid-filled cavities) lined by epithelial cells that grow in a **papillary pattern** (finger-like projections). These projections extend into the cystic spaces, giving the tumor its name.

papillary cystadenomas, the **papillary patterns** and the **cystic spaces** often develop together as part of the tumor's growth. However, the sequence can vary depending on how the tumor forms:

1. Cyst First:

- In some cases, a **cyst** (fluid-filled cavity) forms first, and then the **papillary growths** (finger-like projections) develop on the lining of the cyst.
- Example: In ovarian cystadenomas, the epithelial lining of the cyst starts proliferating to form papillary projections.

2. Papilla First:

- In other cases, a **papillary structure** may form as part of the tumor's early growth, and cystic spaces develop later as the tumor tissue degenerates, becomes necrotic, or accumulates fluid.

POLYPS

When a neoplasm—benign or malignant— produces a **macroscopically visible** projection above a mucosal surface and projects, for example, into the gastric or colonic lumen, it is termed a **polyp**. If the polyp has glandular tissue, it is called an adenomatous polyp. **Adeno-**: Refers to **gland** (from Greek "aden," meaning gland). **-matous**: A suffix meaning **pertaining to, or characterized by the presence of**. It implies that the tissue or growth is of a particular type, or has a structure resembling the tissue it's named after.

MALIGNANT TUMORS

Malignant tumors are collectively referred to as **cancers**.

Malignant tumors can invade and destroy adjacent structures and spread to distant sites (metastasize) to cause death.

Not all cancers pursue so deadly a course. Some are discovered early enough to be excised surgically or are treated successfully with chemotherapy or radiation

Malignant always raises a red flag.

MALIGNANT TUMORS (NOMENCLATURE)

Malignant tumors arising in **solid mesenchymal tissues** are usually called **sarcomas** (Greek sar = fleshy; e.g., **fibrosarcoma**, **chondrosarcoma**, **leiomyosarcoma** (**smooth muscle cells**), and **rhabdomyosarcoma** (**skeletal muscle cells**)).

whereas those arising from blood-forming cells are designated **leukemias** (**literally, white blood**) Leukemia primarily affect the **bone marrow** and **blood cells**, causes the body to produce an excessive number of abnormal white blood cells, which can crowd out healthy cells and disrupt normal blood function. **or lymphomas** (**tumors of lymphocytes or their precursors**). lymphocyte white blood cell and can also involve the **precursors** of lymphocytes (immature cells). These tumors often develop in the **lymph nodes**, but they can also affect other parts of the lymphatic system, such as the **spleen, bone marrow, thymus**, and other tissues.

Malignant neoplasms of epithelial cell origin, derived from any of the three germ layers, are called carcinomas. Thus, cancers arising in the ectodermally derived epidermis, the mesodermally derived renal tubules, and the endodermally derived lining of the gastrointestinal tract are all termed carcinomas.

Carcinomas are **malignant neoplasms (cancers)** that originate from **epithelial cells**—cells that line the surfaces of organs and structures in the body. Epithelial cells can arise from any of the three **germ layers** in the embryo:

1. **Ectoderm**: Forms the outer layer, including the **epidermis (skin)**. Cancers arising from these cells are **squamous cell carcinoma** or **basal cell carcinoma**.
2. **Mesoderm**: Forms structures like the **renal tubules** in the kidneys. A cancer from these cells is called **renal cell carcinoma**.
3. **Endoderm**: Forms the lining of internal organs like the **gastrointestinal (GI) tract**, lungs, and other organs. Cancers from these cells are typically **adenocarcinomas**.

Carcinomas may be further qualified. **Squamous cell carcinoma** denotes a cancer in which the tumor cells resemble **stratified squamous epithelium**, and **adenocarcinoma** denotes a lesion in which the neoplastic epithelial cells grow in a **glandular pattern**.

Sometimes the tissue or organ of origin can be identified and is added as a descriptor, as in **renal cell adenocarcinoma** or **bronchogenic squamous cell carcinoma**.

Not infrequently (often) a cancer is composed of cells of **unknown tissue origin** (undifferentiated malignant tumor).

MIXED TUMORS

In most benign and malignant neoplasms, all of the parenchymal cells closely resemble one another. Infrequently, however, divergent differentiation of a single neoplastic clone creates a mixed tumor, such as the mixed tumor of salivary gland **epithelial** and **mesenchymal** cells are present.

In most benign and malignant tumors, the cells of the **parenchyma** (the functional part of the tumor) **look similar** to each other. However, in some cases, a **single neoplastic cell** (tumor cell) can undergo **divergent differentiation**, meaning it develops into **different cell types**. This creates a **mixed tumor** that contains various types of cells.

These tumors contain epithelial components scattered within a myxoid stroma that may contain islands of cartilage or bone. All of these elements arise from a single clone capable of producing both epithelial and myoepithelial cells; thus, the preferred designation of this neoplasm is **pleomorphic adenoma**: (a tumor with both **epithelial** and **myoepithelial** components, and the ability to produce different tissue types like **cartilage** or **bone**).

Myxoid stroma refers to a type of **extracellular matrix** (ECM) found in some tumors, characterized by a **gelatinous, mucoïd consistency**. It is rich in **mucopolysaccharides** (such as hyaluronic acid and chondroitin sulfate) that give it a slimy or mucous-like texture.

The great majority of neoplasms, even mixed tumors, are composed of cells from a single germ layer. An exception is a tumor called a **teratoma**, which contains recognizable mature or immature cells or tissues belonging to more than one germ cell layer (and sometimes all three).

Teratoma originates from germ cells that are **normally present in the ovary and testis** and sometimes also found in **abnormal midline embryonic rests**. Such cells can differentiate into any of the cell types found in the adult body and so, may give rise to neoplasms that contain, in a helter-skelter fashion (**disorganized or chaotic manner**), bone, epithelium, muscle, fat, nerve, and other tissues.

Common pattern is seen in the **ovarian cystic teratoma (dermoid cyst)** **its benign**, which create a cystic tumor lined by skin replete with hair, sebaceous glands, and tooth structures.

MISNOMERS (important)

There are some inappropriate usages. For instance, benign-sounding designations such as **lymphoma**, **melanoma** (**melanocytes**), **mesothelioma** (**mesothelium**), and **seminoma** (**testicular cancer**) are used for certain malignant neoplasms.

Hamartomas (benign): are disorganized but benign masses composed of cells indigenous to the involved site. Once thought to be a developmental malformation unworthy of the -oma designation, many in fact have clonal chromosomal aberrations that are acquired through somatic mutations and on this basis are now considered neoplasm.

hamartomas are now recognized as **neoplasms** because they often have **clonal chromosomal changes** caused by **somatic mutations**, which means they arise from mutations in the cells of the tissue itself.

Choristoma (benign): is a heterotopic rest of cells. For example, a small nodule of well-developed and normally organized pancreatic tissue may be found in the submucosa of the stomach, duodenum, or small intestine.

Tissue of Origin	Benign	Malignant
Connective Tissue and Derivatives	Fibroma, Lipoma, Chondroma, Osteoma	Fibrosarcoma, Liposarcoma, Chondrosarcoma, Osteogenic sarcoma
Endothelium and Related Cell Types	Hemangioma, Lymphangioma, Meningioma	Angiosarcoma, Lymphangiosarcoma, Mesothelioma, Invasive meningioma
Blood Cells and Related Cell Types	-	Leukemias, Lymphomas
Muscle	Leiomyoma, Rhabdomyoma	Leiomyosarcoma, Rhabdomyosarcoma
Skin	Squamous cell papilloma, Nevus	Squamous cell carcinoma, Basal cell carcinoma, Malignant melanoma
Epithelial Lining of Glands or Ducts	Adenoma, Papilloma, Cystadenoma	Adenocarcinoma, Papillary carcinoma, Cystadenocarcinoma
Lung	Bronchial adenoma	Bronchogenic carcinoma
Kidney	Renal tubular adenoma	Renal cell carcinoma
Liver	Liver cell adenoma	Hepatocellular carcinoma
Bladder	Urothelial papilloma	Urothelial carcinoma
Placenta	Hydatidiform mole	Choriocarcinoma
Testicle	-	Seminoma, Embryonal carcinoma
More Than One Neoplastic Cell Type (More Than One Germ Layer)		
Salivary Glands	Pleomorphic adenoma (mixed tumor)	Malignant mixed tumor of salivary gland
Renal Anlage	-	Wilms tumor
More Than One Neoplastic Cell Type (More Than One Germ Layer)		
Totipotential cells in gonads or in embryonic rests	Mature teratoma, dermoid cyst	Immature teratoma, teratocarcinoma

Malignant tumors also tend to grow more rapidly than benign tumors, but there are so many exceptions that growth rate is not a very useful discriminator between benignity and malignancy.

In fact, **even cancers exhibit remarkably varied growth rates**, from slow-growing tumors associated with survival for years, often without treatment, to rapidly growing tumors that may be lethal within months or weeks.

Differentiation refers to the extent to which neoplastic parenchymal cells resemble the corresponding normal parenchymal cells, both morphologically and functionally; **lack of differentiation is called anaplasia.**

In general, benign tumors are well differentiated

DIFFERENTIATION AND ANAPLASIA

The neoplastic cell in a tumor of **benign adipocytes—a lipoma—so closely resembles normal adipocytes that it may be impossible to recognize the tumor by microscopic examination of individual cells.** Only the growth of these cells into a discrete mass discloses the neoplastic nature of the lesion.

In well-differentiated benign tumors, **mitoses are usually rare and are of normal configuration.**

Characteristic	Benign	Malignant
Differentiation/Anaplasia	Well-differentiated; structure sometimes typical of tissue of origin	Some lack of differentiation (anaplasia); structure often atypical
Rate of Growth	Usually progressive and slow; may come to a standstill or regress; mitotic figures rare and normal	Erratic, may be slow to rapid; mitotic figures may be numerous and abnormal
Local Invasion	Usually cohesive, expansile, well-demarcated masses that do not invade or infiltrate surrounding normal tissues	Locally invasive, infiltrating surrounding tissue; sometimes misleadingly cohesive and expansile
Metastasis	Absent	Frequent; more likely with large undifferentiated primary tumors

malignant neoplasms exhibit **a wide range of parenchymal cell differentiation, most exhibit morphologic alterations that betray their malignant nature.** (will be discussed)

There are exceptions, certain well-differentiated **adenocarcinomas of the thyroid**, for example, **form normal-appearing follicles**, and **some squamous cell carcinomas** contain cells that appear **identical to normal squamous epithelial cells.** Thus, the morphologic distinction between well differentiated malignant tumors and benign tumors may be difficult.

At the other end of the spectrum lie tumors exhibiting little or no evidence of differentiation. (anaplastic)

In between the two extremes lie tumors that are loosely referred to as moderately well differentiated.

Malignant neoplasms that are composed of poorly differentiated cells are said to be anaplastic.

Lack of differentiation, or anaplasia, is considered a hallmark of malignancy. The term anaplasia means “to form backward,” implying a **reversal of differentiation to a more primitive level.**

ANAPLASIA

Anaplasia, is often associated with many other morphologic changes:

1 Pleomorphism:

variation in size and shape. Thus, cells within the same tumor are not uniform, but range from small cells with an undifferentiated appearance, to tumor giant cells many times larger than their neighbors.

Some tumor giant cells possess only a single huge polymorphic nucleus, while others may have two or more large hyperchromatic nuclei.

These giant cells are not to be confused with inflammatory Langhans or foreign body giant cells, which are derived from macrophages contain many small, normal-appearing nuclei.

2 Abnormal nuclear morphology:

The nuclei are disproportionately large for the cell, with a nuclear-to cytoplasm ratio that may approach 1 : 1 instead of the normal

1 : 4 or 1 : 6.

The nuclear shape is variable and often irregular, and the chromatin is **often coarsely clumped (irregular, rough appearance) and distributed along the nuclear membrane, or more darkly stained than normal (hyperchromatic).**

Abnormally large nucleoli are also commonly seen.

3 Mitoses:

The presence of mitoses, however, does not necessarily indicate that a tumor is malignant.

Mitoses are indicative of rapid cell growth. Hence, cells in mitosis are often seen in normal tissues exhibiting rapid turnover (*rate at which cells are produced and replaced*), such as the epithelial lining of the gut and nonneoplastic proliferations such as hyperplasia.

More important morphologic feature of malignancy are **atypical, bizarre mitotic figures, sometimes with tripolar, quadripolar, or multipolar spindle**

4 Loss of polarity:

In addition to the cytologic abnormalities, the orientation of anaplastic cells is markedly disturbed(*easily recognized irregular distribution*). Sheets or large masses of tumor cells grow in a disorganized fashion.

Anaplasia, is often associated with many other morphologic changes:

Other changes. Growing tumor cells obviously **require a blood supply**, but often the **vascular stroma is insufficient**, and as a **result in many rapidly growing malignant tumors develop large central areas of ischemic necrosis.**

DIFFERENTIATION AND ANAPLASIA

As one might surmise, the better the differentiation of the transformed cell, the more completely it retains the functional capabilities of its normal counterpart.

Thus, benign neoplasms and well-differentiated carcinomas of endocrine glands frequently secrete hormones characteristic of their origin. Increased levels of these hormones in the blood are used clinically to detect and follow such tumors.

Well-differentiated squamous cell carcinomas of the epidermis synthesize keratin, and well-differentiated hepatocellular carcinomas elaborate bile. (helps in diagnosis)

In some instances, new and unanticipated functions emerge. Thus, some tumors express fetal proteins that are not produced by comparable cells in the adult, while others express proteins that are normally only found in other types of adult cells. For example, bronchogenic carcinomas may produce corticotropin, parathyroid-like hormone, insulin, glucagon, and other hormones, giving rise to paraneoplastic syndromes.

Some tumors can develop **new or abnormal functions**, producing substances not typically made by their original cell type. For example:

1. **Fetal proteins:** Tumors may produce proteins normally made during fetal development but absent in adult tissues.
2. **Ectopic proteins:** Tumors can make proteins or hormones usually found in other types of cells, leading to abnormal effects.

For instance, **bronchogenic carcinomas** (lung cancers) can produce hormones like:

- **Corticotropin:** Mimicking stress hormone regulation.
- **Parathyroid-like hormone:** Causing calcium imbalances.
- **Insulin or glucagon:** Leading to abnormal blood sugar levels.

These abnormal productions can result in **paraneoplastic syndromes**, which are medical conditions caused by substances secreted by the tumor, not the tumor's growth itself.

Despite such exceptions, **rapidly growing anaplastic tumors are less likely to have specialized functional activity.**

METAPLASIA AND DYSPLASIA (important)

Metaplasia is defined as the replacement of one type of cell with another type.

Metaplasia is nearly always found in association with tissue damage, repair, and regeneration.

Often the replacing cell type is better suited to some alteration in the local environment. For example, **gastroesophageal reflux damages the squamous epithelium of the esophagus**, leading to its **replacement by glandular (gastric or intestinal) epithelium** more suited to an acidic environment.

Dysplasia means “disordered growth.” It is characterized by a constellation of changes that include **a loss in the uniformity of the individual cells as well as a loss in their architectural orientation.**

For example, in dysplastic squamous epithelium the normal progressive maturation of tall cells in the basal layer to flattened squames on the surface may fail in part or entirely, leading to replacement of the epithelium by basal-appearing cells with hyperchromatic nuclei.

In **dysplastic squamous epithelium**, the normal process where **tall basal cells** (the immature cells) mature into **flat squamous cells** on the surface is **disrupted** (something went wrong) or **does not occur properly**. Instead:

- The epithelium becomes replaced by **immature basal-like cells** throughout its layers. (immature cells on the surface)
- These immature cells have **hyperchromatic nuclei** (darker-staining, indicating increased DNA content) and appear abnormal.

This change signifies **disordered growth** and maturation, which may potentially progress to **cancer** if left unchecked.

In addition, **mitotic figures are more abundant than in the normal tissue and rather than being confined to the basal layer may instead be seen at all levels, including surface cells.**

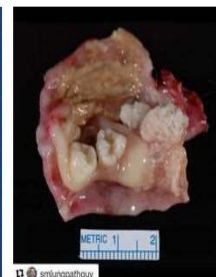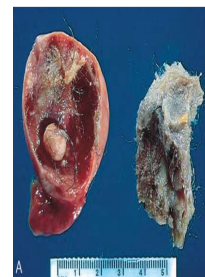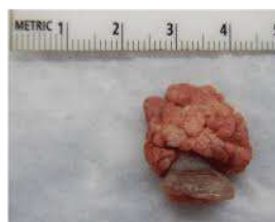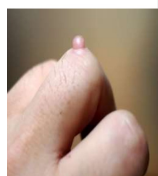
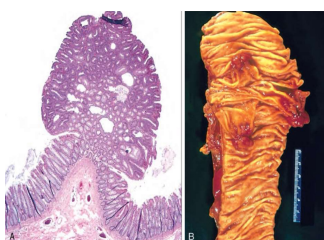
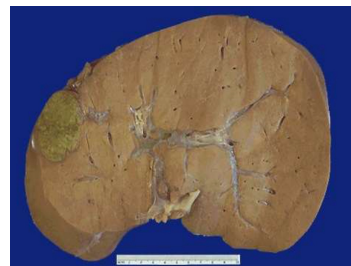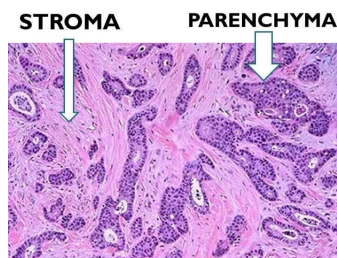
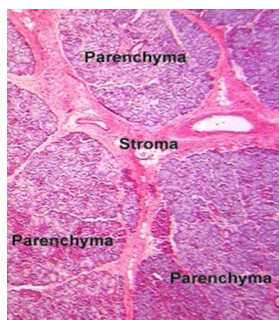
When dysplastic changes are marked and involve the full thickness of the epithelium, but the lesion does not penetrate the basement membrane, it is considered a preinvasive neoplasm and is referred to as carcinoma in situ. (so important)

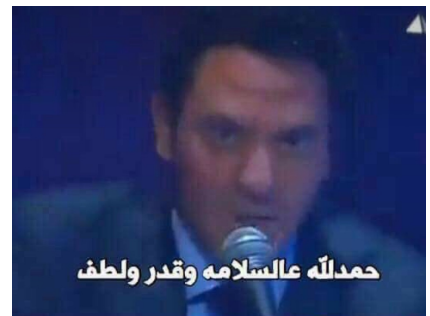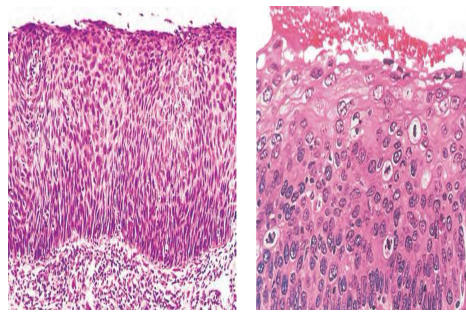
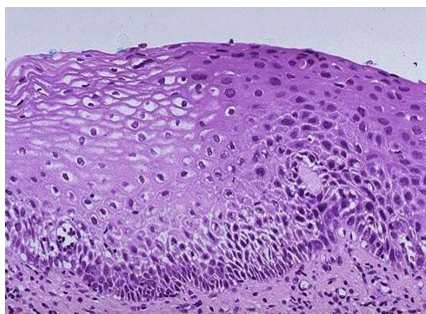
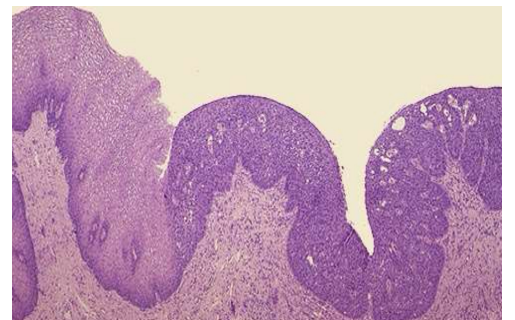
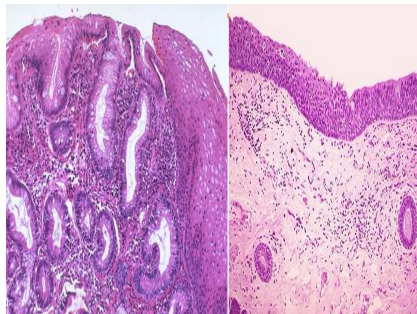
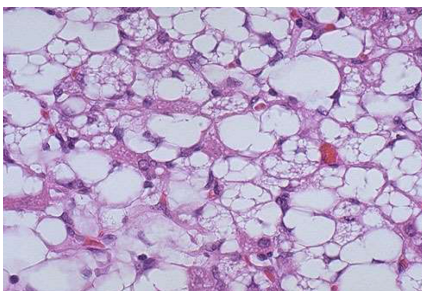
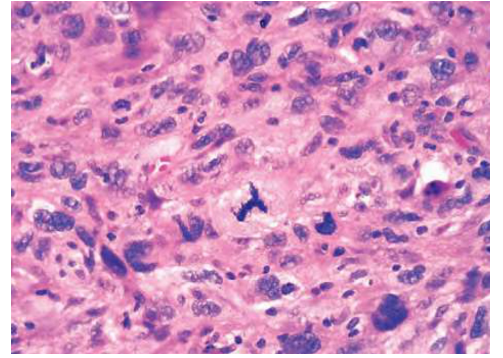
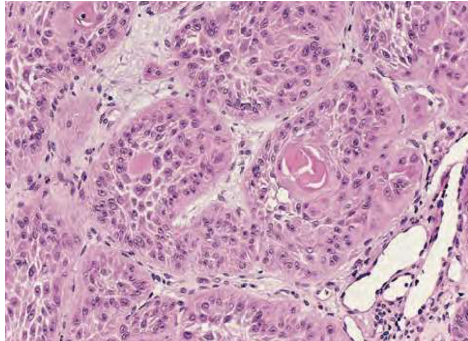
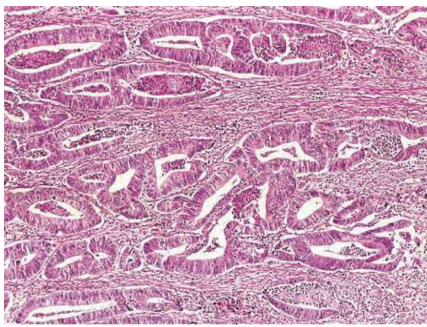
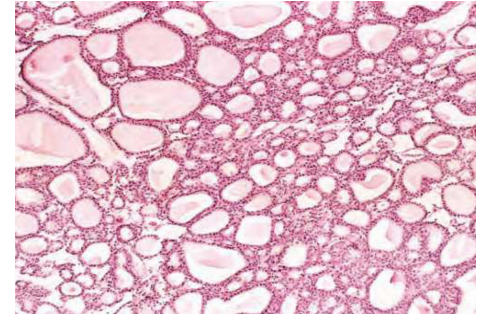
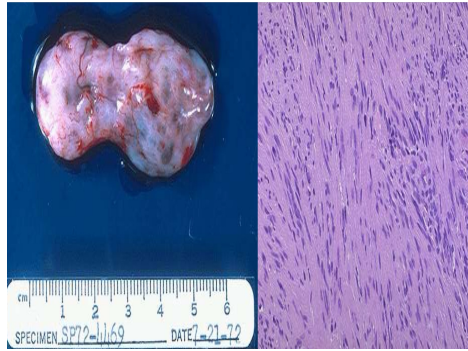
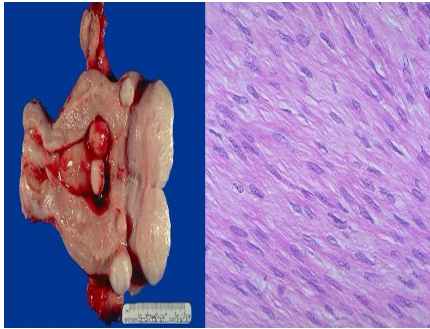
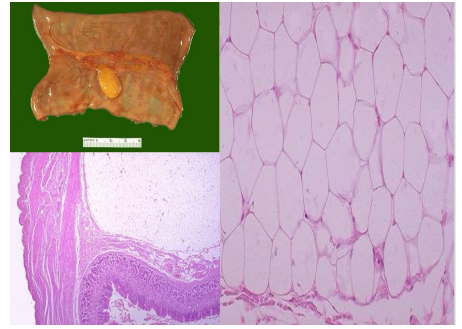
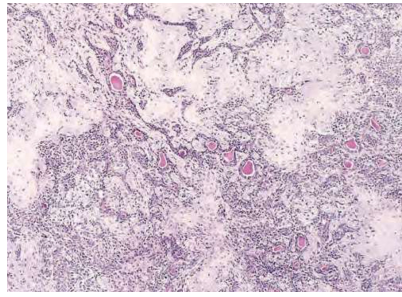
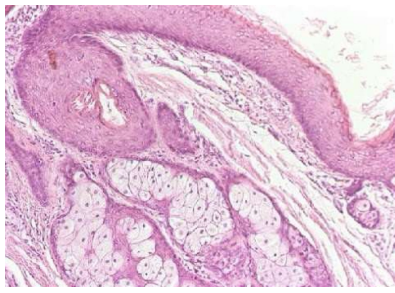
Once the tumor cells **breach the basement membrane**, the tumor is said to be **invasive**.

Dysplasia may be a **precursor to malignant transformation**, it does not always progress to cancer.

Carcinoma in situ may persist for years before it becomes invasive.

Dysplasia **often occurs in metaplastic epithelium**, but not all metaplastic epithelium is dysplastic.





Done by we'am abdullah