



1) Some one has loss of consciousness we found obstruction of water heat vent pipe the cause of except?

- A) cerebrovascular stroke
- B) respiratory failure
- C) Dysarrhythmia
- D) Curve shift to left
- E) Anemic anoxia

2) - when there is methyl poisoning with no ethanol antidote available :

- A) Emesis
- B) Gastric lavage
- C) Hemodialysis
- D) Fomepiazole
- E) sodium bicarb

3) Activated charcoal

- A -enhance elimination of toxic only
- B -enhance absorption of toxic only
- C -decrease absorption of toxic only
- D-enhance elimination of toxic and decrease absorption

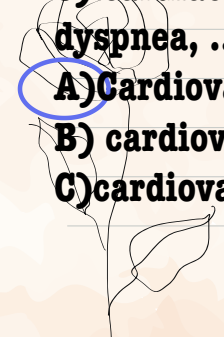

4) best hospital management for corrosive :

- A) Emesis
- B) Ac
- C) Secure the patient's air and endoscopy
- D) Milke and water

5- dry bite of this snake :

- A) Venomous
- B) Nonvenomous
- C) No poisoning or small

6) cardiac patient that comes with ischemic heart disease come with dyspnea, ..., but he died (death certificate)

- A) Cardiovascular failure due to MI due to IHD
  - B) cardiovascular failure due to IHD
  - C) cardiovascular failure due to IHD due to hypertension
- 
- 

7) what the most indication to make sure that child abuse burn (Pic)

- A) Pattern specific object**
- B) Burn in forearm**
- C) Small burn in the head**

8- contusion that indicate child abuse (pic)

- A) Multiple at knee**
- B) Small Contusion at head**
- C) Multiple contusions with different healing stages**

9)-head injury indicate child abuse (pic)

- A) Scalp hematoma with no other injuries**
- B) Subdural and retinal hemorrhage**
- C) skull fracture**

10 - House in fire (pic) what poisoning:

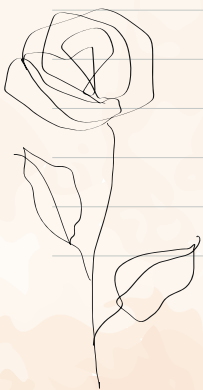
- A) Co, cyanide**
- B) Co only**
- C) Cyanide only**
- D) H<sub>2</sub>s, co**
- E) H<sub>2</sub>s, co, cyanide**

11) Primary side effect of acute ethanole toxicity C(11

- A) hypoglycemia**
- B) respiratory failure**
- C) Metabolic alkalosis**
- D) hypercalcemia**

12) )Wrong about pic?

- A) Very severe toxicity**
- B) continue atropin unless pneumonia developed should be stoped**
- C) SLUDGE muscarinic actions of drug**



13) we found someone have metabolic acidosis with unknown causes?

A )no toxic causes

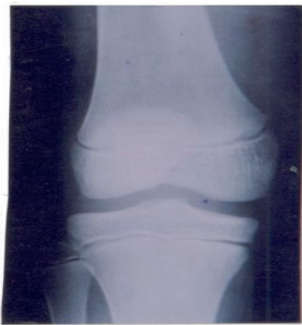**B )obtain blood sample for toxic analysis**

C)blood test if have history of addiction

14) Open disaster : 2

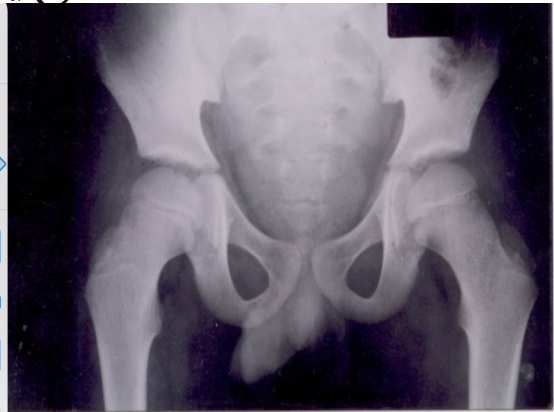

14) ③



X-ray of knee showing that the age is below 21 years due to nonunion of the distal end of femur and nonunion of proximal ends of tibia and fibula

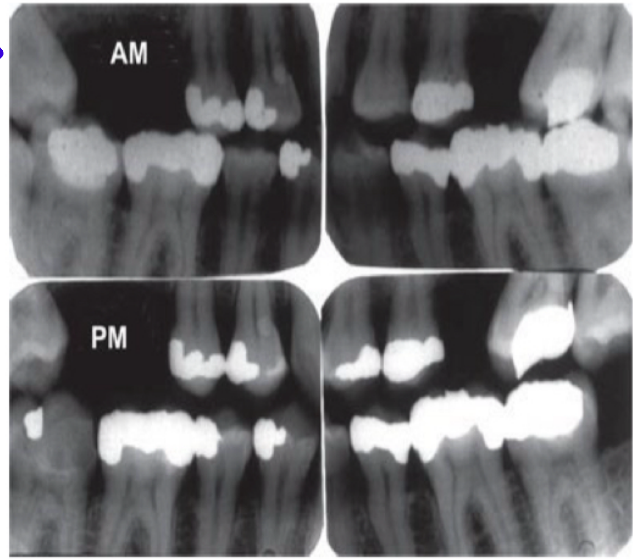
14) ④



X-ray of pelvis showing that the age is above 6 years due to union of the inferior ramus of pubis with the superior ramus of ischium , and below puberty due to nonunion of the 3 bones (pubis , ischium and iliac bones ) together at the acetabulum

15) Choses corect ID type of this pic

- A) Dental pulp dna
- B) Dental pattern**



16) What is the legal definition of abortion:

- A) expulsion of an embryo, viable, of 28 weeks of pregnancy
- B) expulsion of an embryo, before 24 weeks of pregnancy
- C) expulsion of an embryo, dead, of 28 weeks of pregnancy**
- D) expulsion of an embryo, viable or dead, of 28 weeks of pregnancy

17) Main mechanism of kerosine in rs

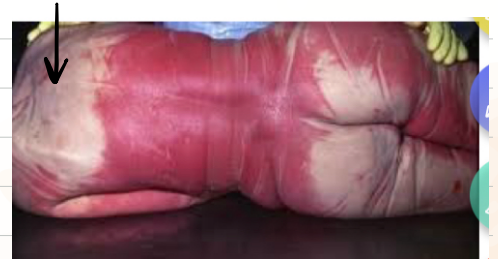- A) disrupt surfactant**
- B) chemical irritant
- C) polmonary edema

18) priapism mean

Continous errection in male child cause by scorpion sting

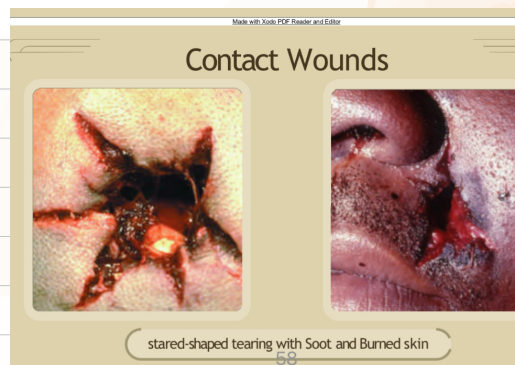
-19) hypostosis picture) what is causing the arrow (on the A) white area )

- B) Algor mortis
- C) Flaccidity
- D) Cadveric
- E) Contact flattening**



21) firearm pic\* what is false:

- A) Intermediate distance**
- B) Stalliate shape
- D) Clothes internally
- (E) Breveled of bone** اتوقع كانت موجودة



stared-shaped tearing with Soot and Burned skin

20- fire arm pic

A) Multiple exit wound

**B) Multiple inlet wound**

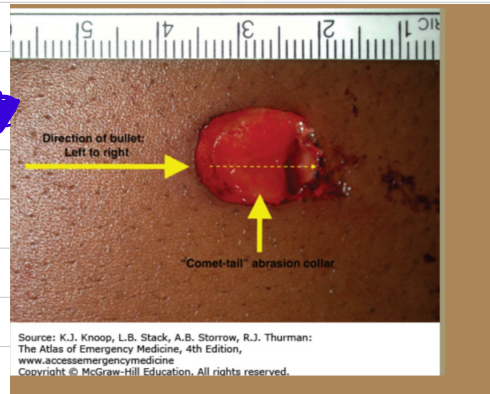
22) pic of a firearm what the arrow presented

A) Abrasion chori

B) Muzzle imprint

C) Blackening

D) Tattooing



23- صورة asphyxia chose wrong statement

A) Hypostosis in lower limb

**B) Most common continuous around the neck**

C) Unlikely to cause hyoid bone fracture

D) Commonly suicidal

24) Rumak mathew namogram :

A) Prediction of acetaminophen toxicity

25) peeling of skin

**A) Immersion sign**

B) Drowning sign

يوجد تكمة للضيار



26- complication of acute ethanol poisoning that cause death commonly :

A) Metabolic alkalosis

B) Renal failure

**C) Respiratory depression**

27) pic of a wound

A) Am wound

B) Pm wound

C) Healed wound

28)- asphyxia chose wrong statement (hanging pic)

A) Hypostosis in lower limb

B) Most common continuous around the neck

C) Unlikely to cause hyoid bone fracture

D) Commonly suicidal

29) indicate to ?

A) basal skull fracture

raccoon eyes كانت واضحة اكثر

