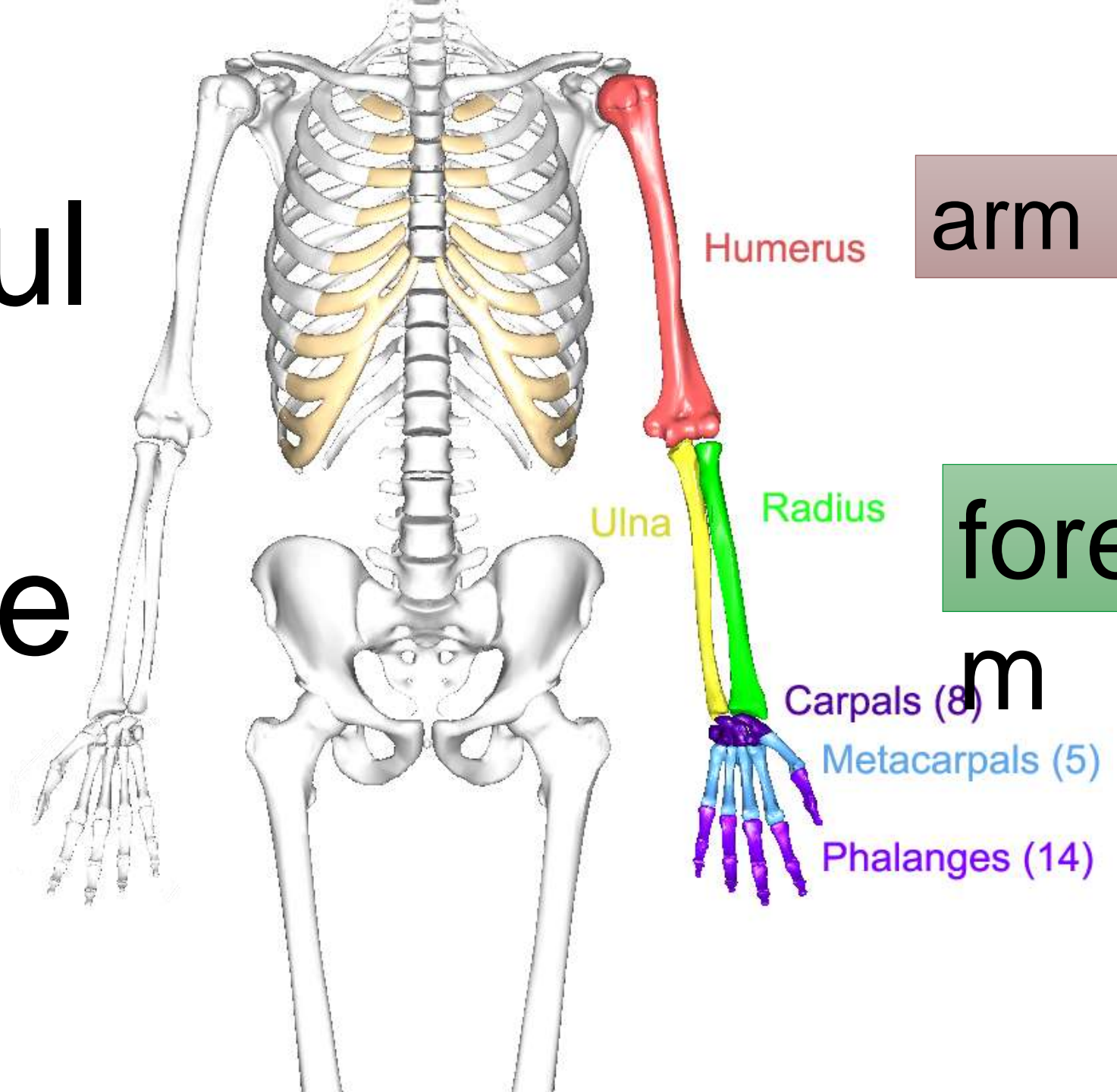


terms

**Dr Amal
Albtoosh**



Shoulder girdle



Humerus

arm

Ulna

Radius

forearm

Carpals (8)

Metacarpals (5)

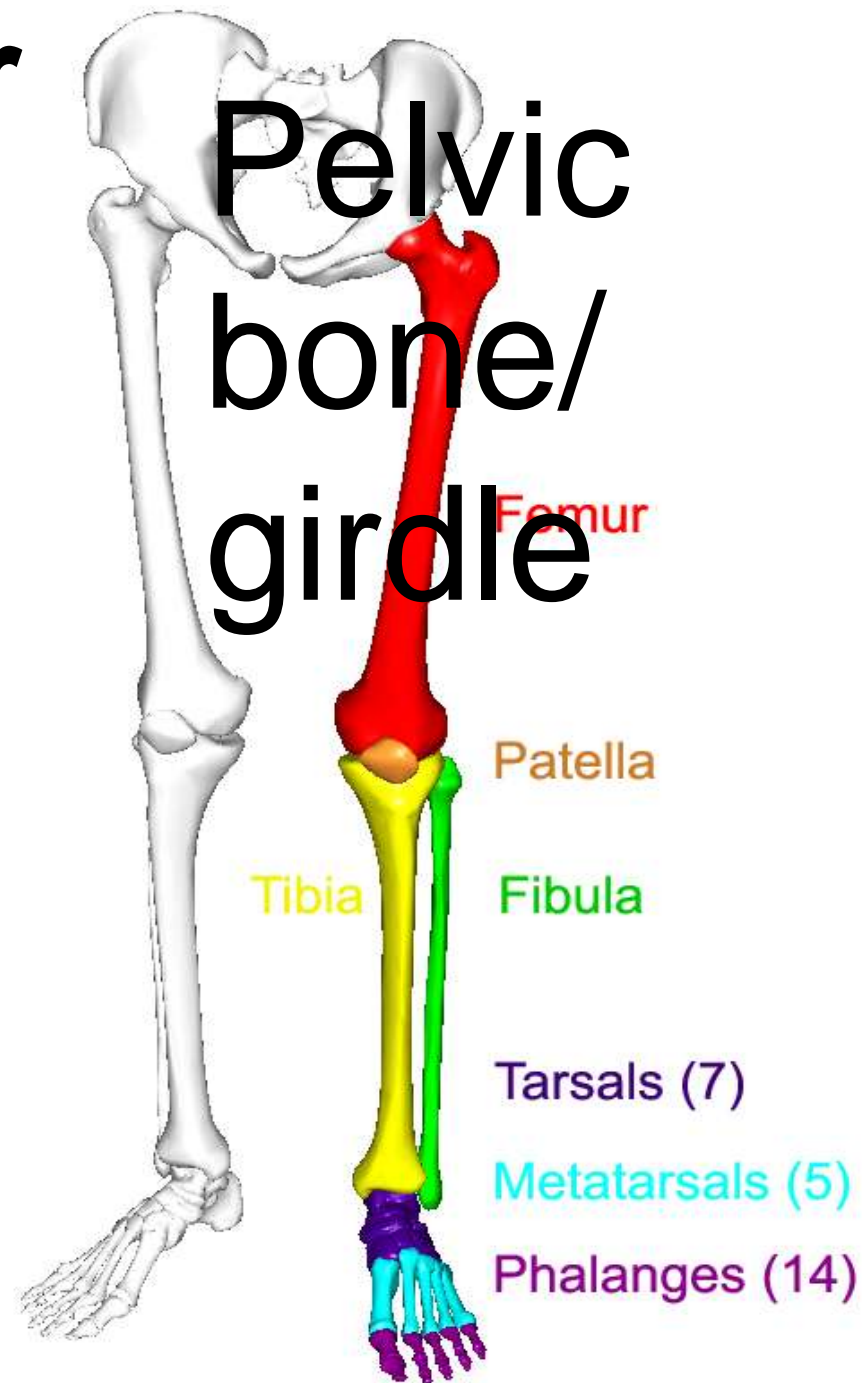
Phalanges (14)

hand

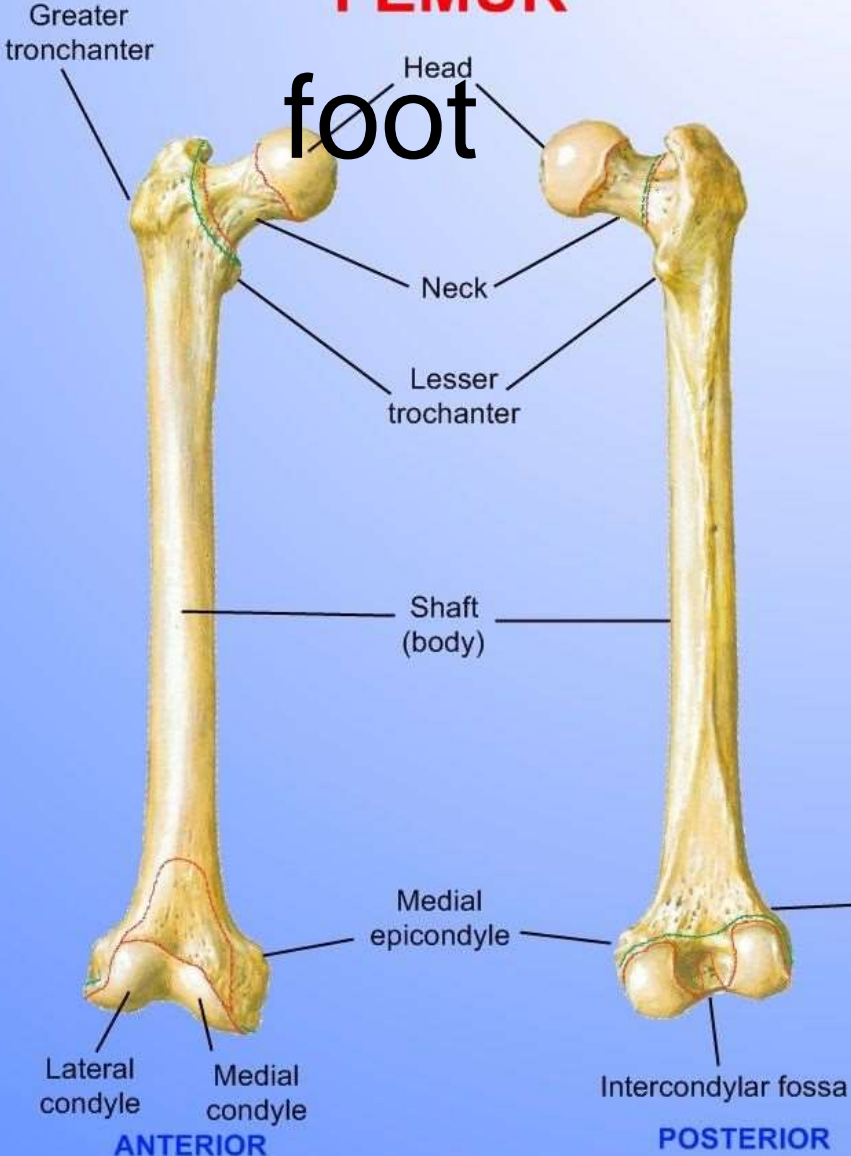
d

Bones of the Lower Limb

- Components:
 - Thigh
 - Femur
 - Patella
 - Leg
 - Tibia (medial)
 - Fibula (lateral)
 - Foot
 - Tarsals (7)
 - Metatarsals (5)
 - Phalanges (14)

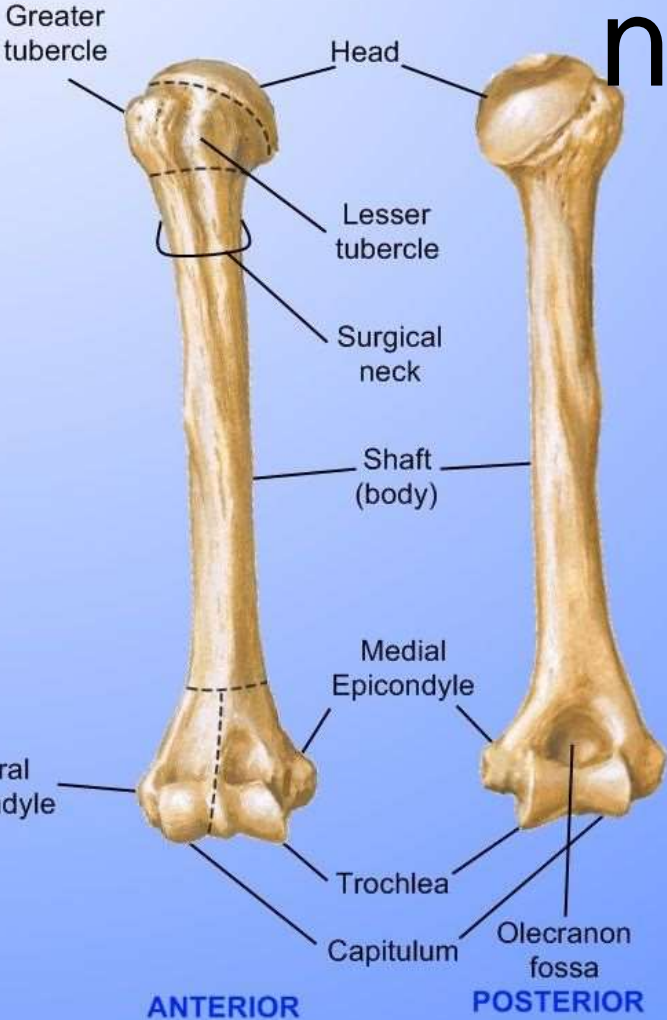


FEMUR



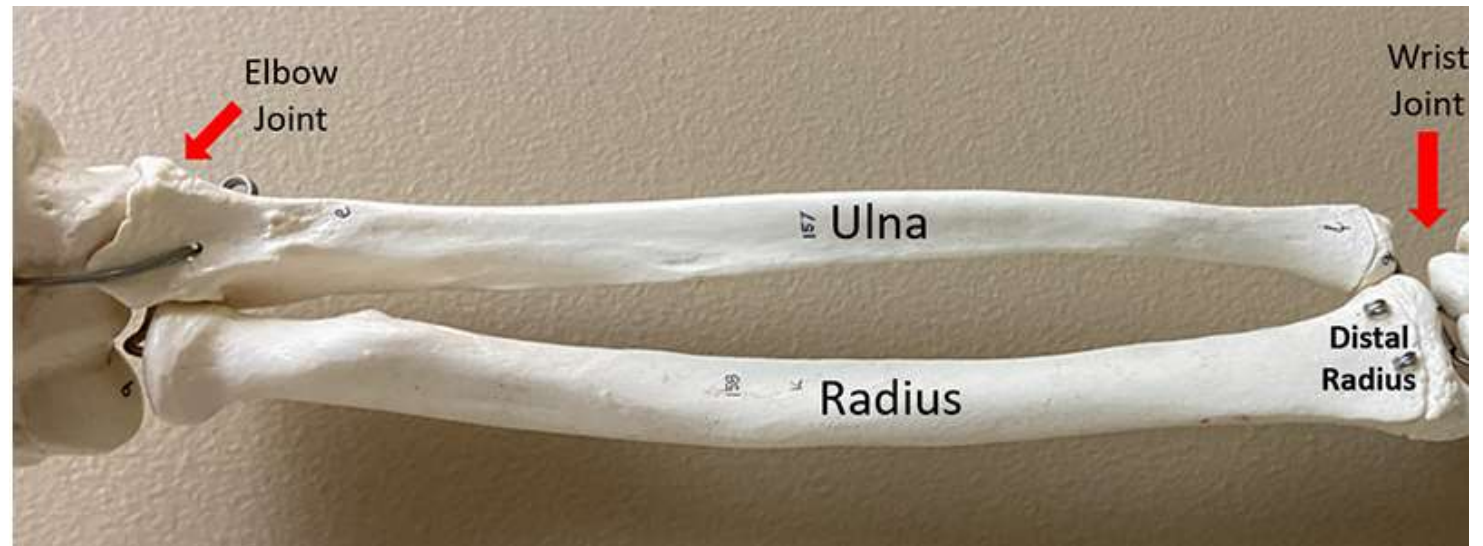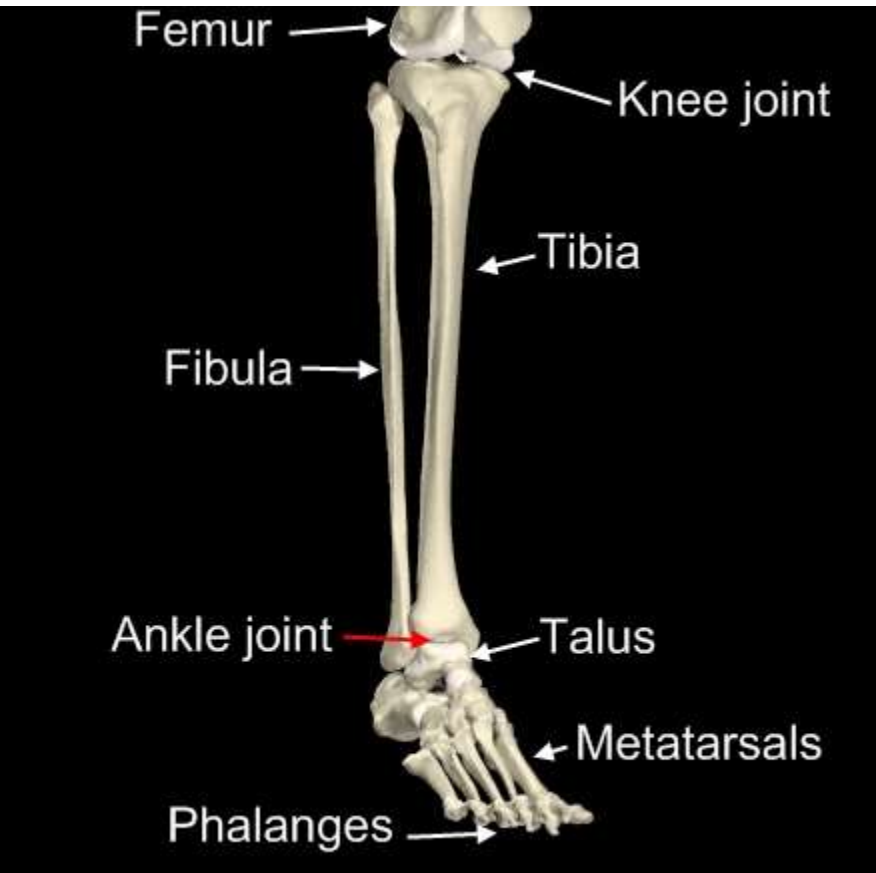
foot

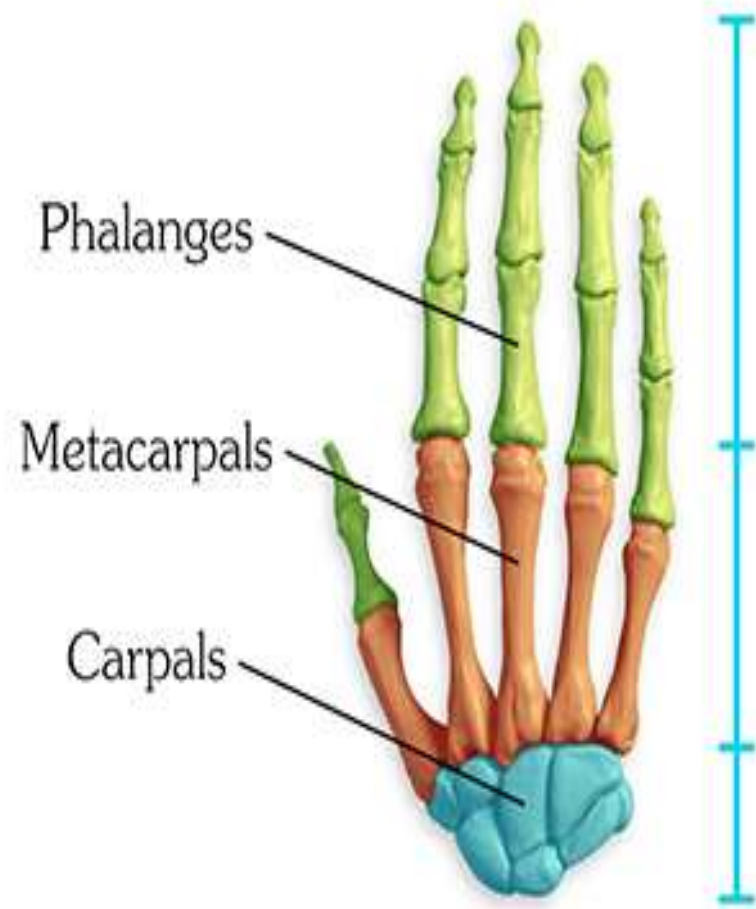
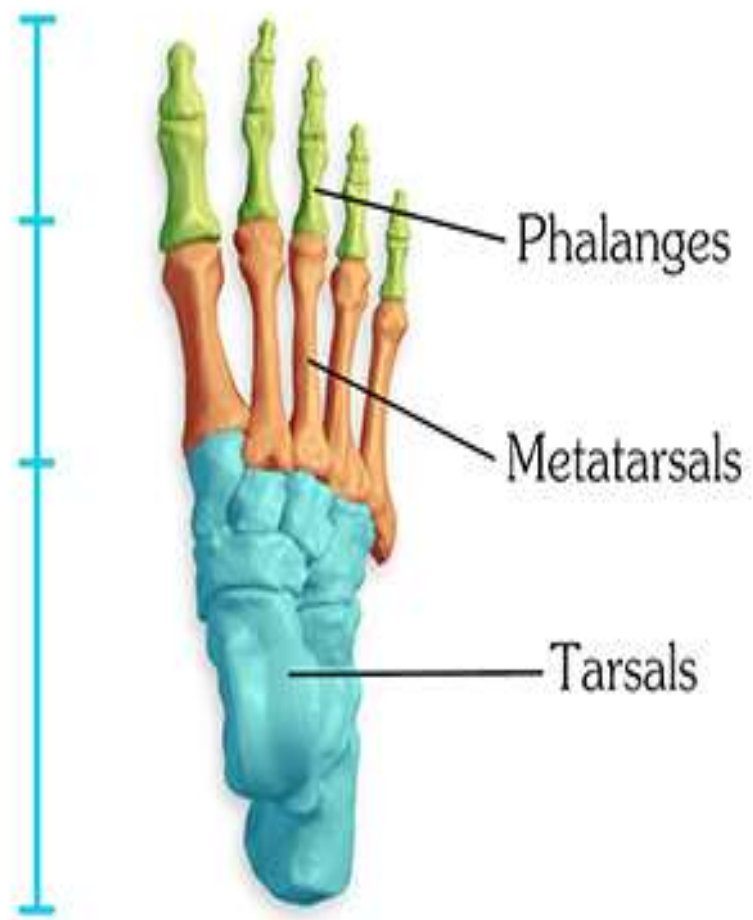HUMERUS



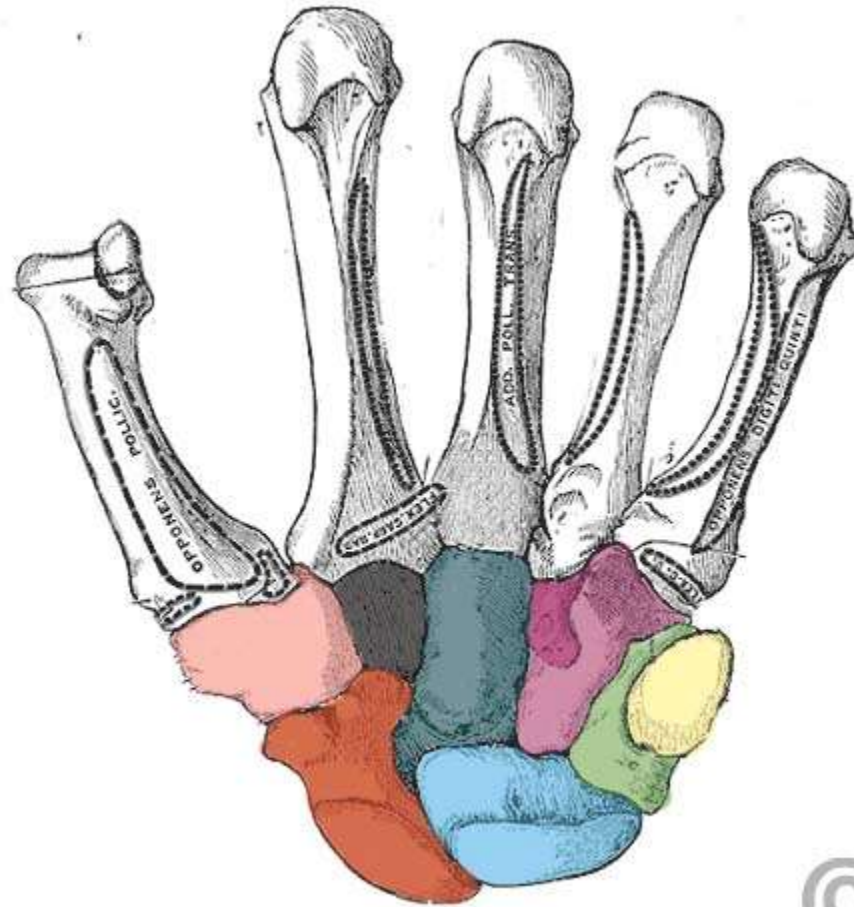
hand
nd

Leg's and Forearm's Bone





Carpal bone [for comparison]



- Scaphoid
- Lunate
- Triquetrum
- Pisiform
- Trapezium
- Trapezoid
- Capitate
- Hamate

Bones of the Foot

- The bones of the foot are the tarsal bones, the metatarsal bones, and the phalanges

- **TARSAL BONES**

- The tarsal bones are the calcaneum, the talus, the navicular, the cuboid, and the three cuneiform bones

