

# Radiology Mini Osce archive

## Rouh Group D

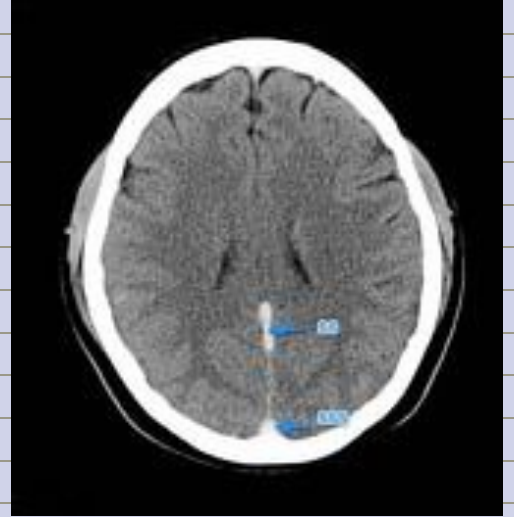
**Q1:**

**1. SSS THROMBOSIS \*\***

**2. Epidural hematoma**

**3. Normal CT**

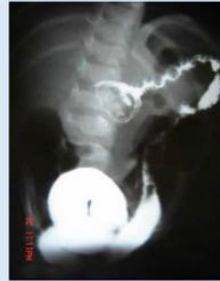مش هاي الصورة بالضبط بس اشفي قريب كان



**Q2:**

كانت جايبة صورتين والجواب كان انه

**Reduction with out recurrence  
doesn't need surgical resection**



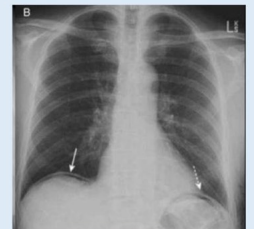
- Claw sign
- barium enema
- intussusception

**Q3:**

وزي هاي انه **air under daiphragm**

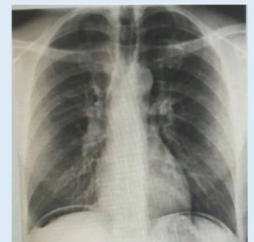6.

Bowel perforation



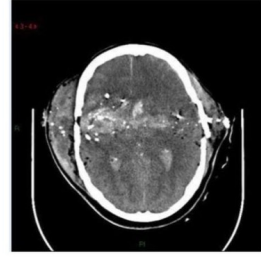
Q1:

**BOWEL PERFORATION**

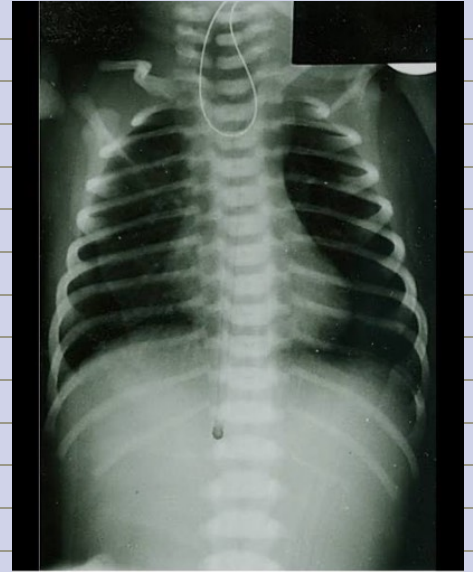


**Q4:**  
*What is the true regarding this picture?*

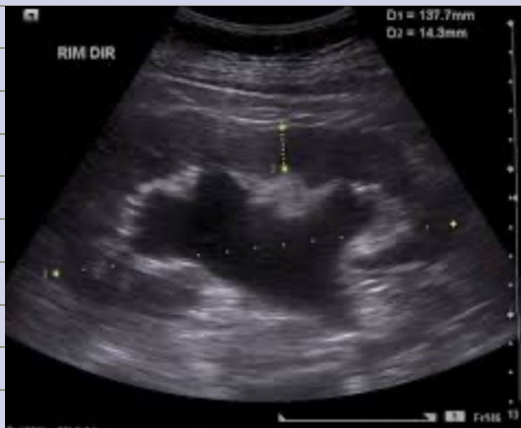No epidural hemorrhage



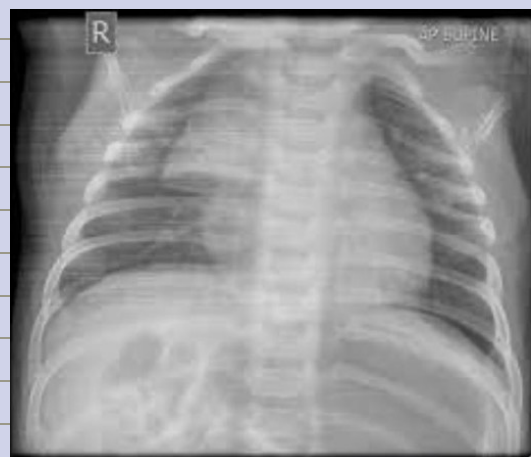**Q5:**  
*Esophageal atresia w/o fistula*



**Q6:**  
*Hydronephrosis*



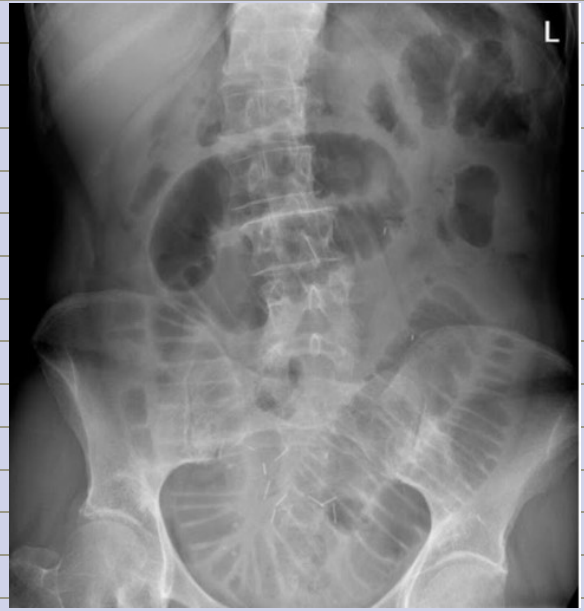**Q7:**  
*Normal x ray*



**Q8:**

**What is the true regarding this picture?**

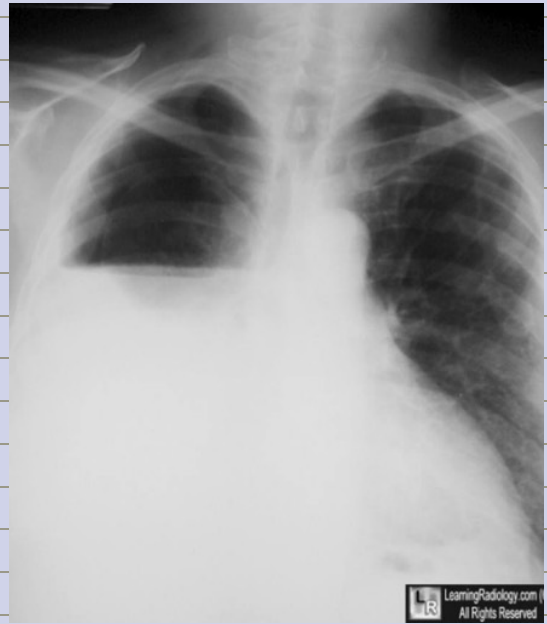- 1) large bowel obstruction**
- 2) The most common cause of it is adhesions. \*\*\*\***



**Q9:**

**Diagnosis?**

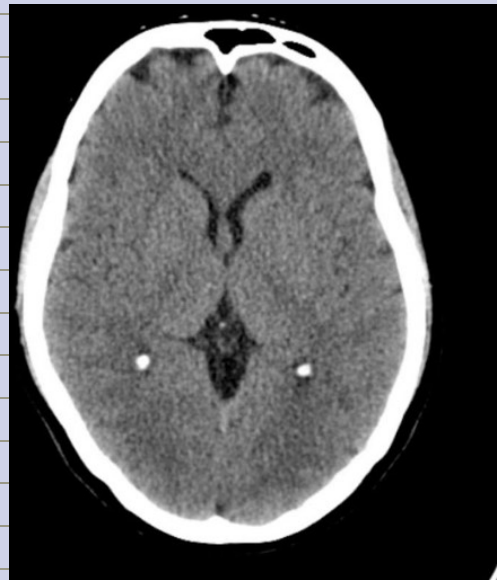
**Hydropneumothorax**



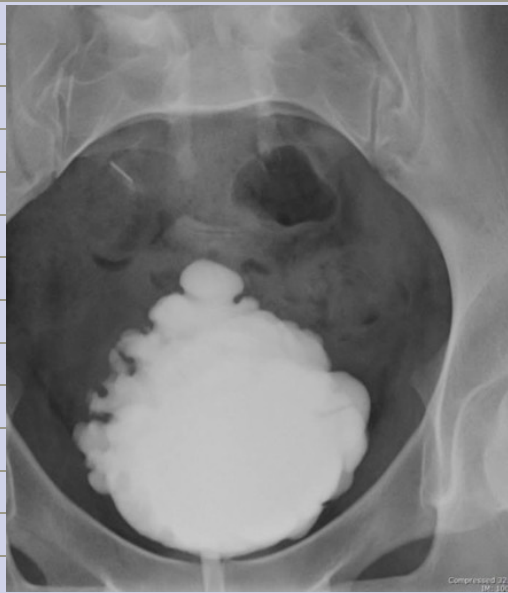
**Q10:**

**الف سهم ونجمة وكان بدھا**

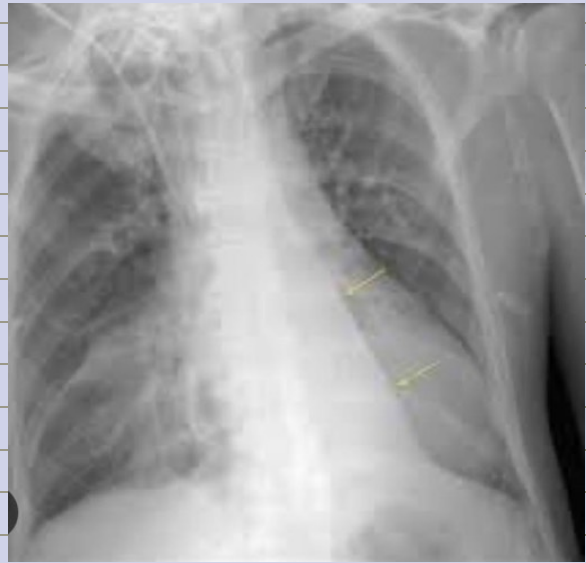**Anatomy og frontal horn of left ventricle + frontal lobe**



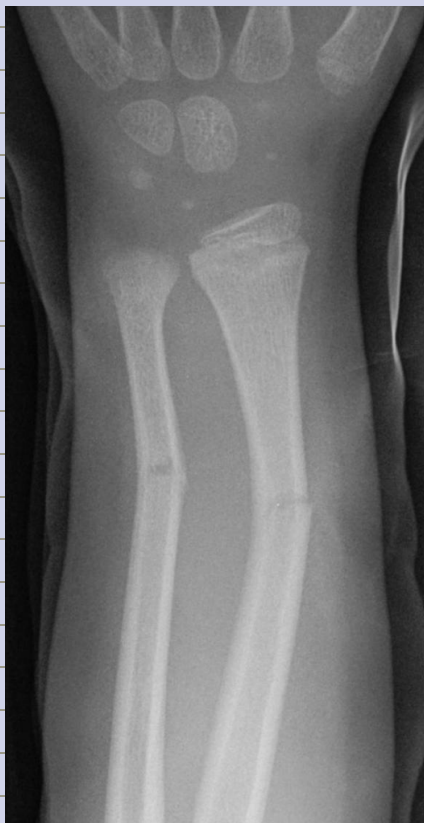**Q11:**  
**Diagnosis?**  
**Neurogenic bladder**



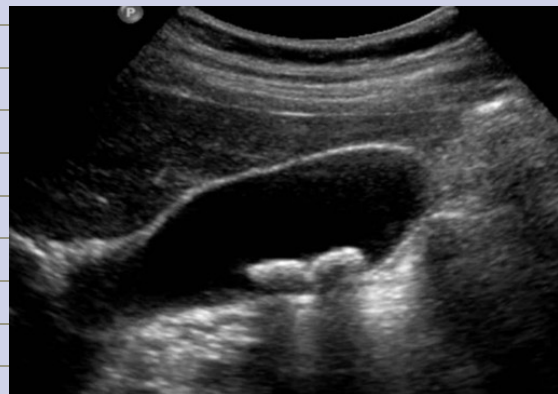**Q12:**  
**Diagnosis?**  
**Lt lower lobe collapse**



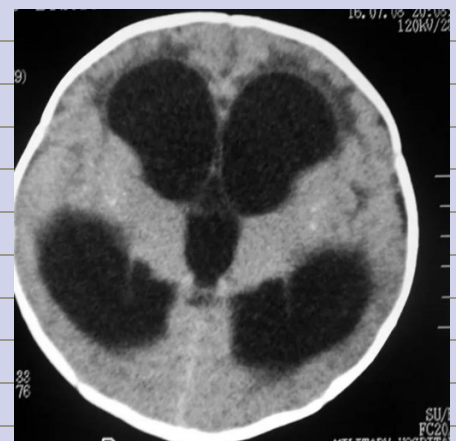**Q13:**  
**Diagnosis?**  
**Greenstick**



**Q14:**  
**Diagnosis?**  
**Gall bladder stone**



**Q15:**  
**Diagnosis?**  
**Hydrocephelus**



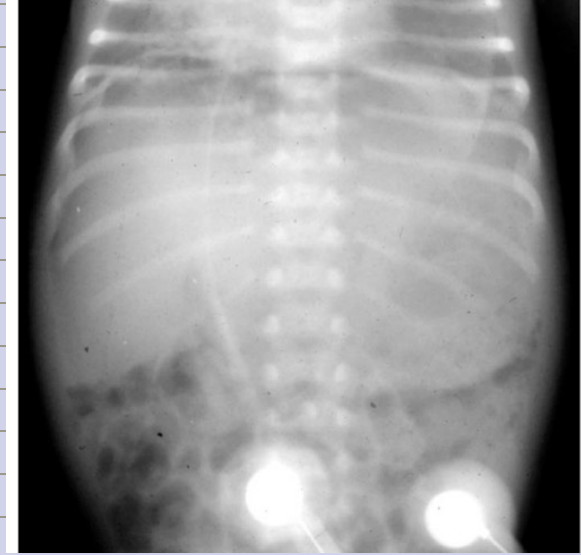**Q16:**

*All of these signs are present except?*

*1)football sign*

*2)falciform ligament sign*

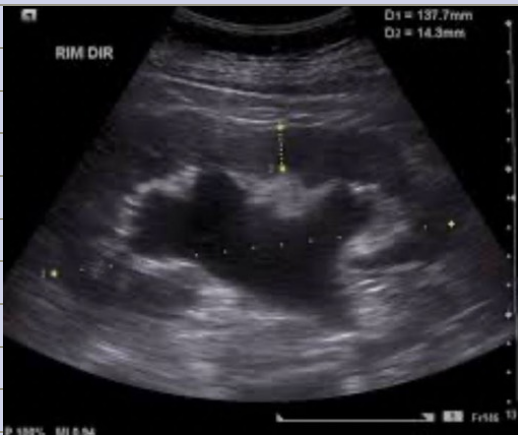*3)crescent sign\*\*\**



**Q17:**

*Diagnosis?*

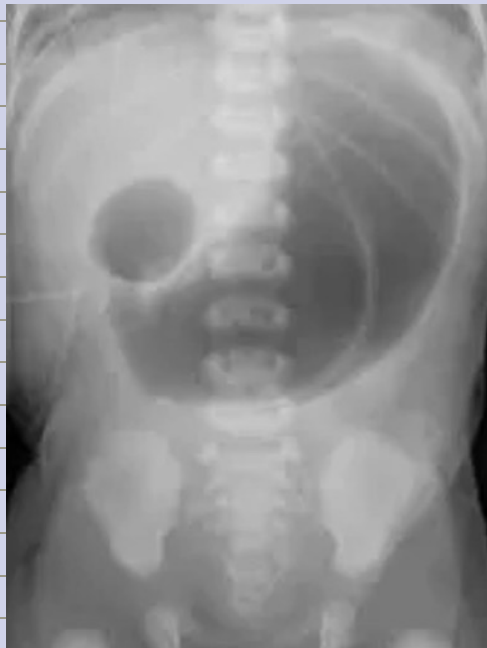*Hydronephrosis*



**Q18:**

*Diagnosis?*

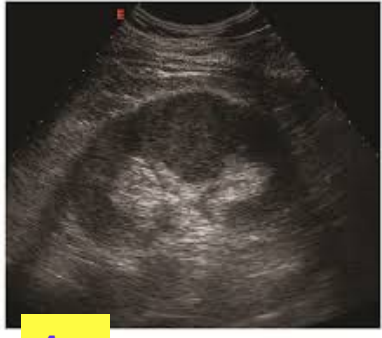*Gastric obstruction in duodenal portion*



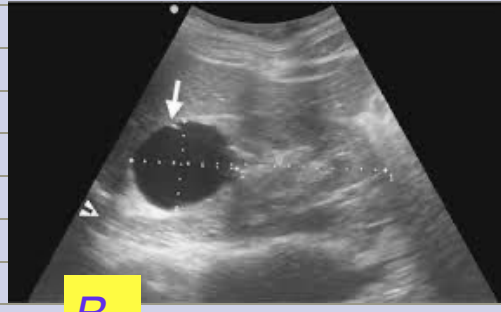

**Q19:**

ناسيه كيف كانت صيغة السؤال بس كانت  
جاييه هدول الصورتين وبدها الصح



**A**



**B**

**A: renal cell carcinoma**

**B: simple cyst**

**Q20:**

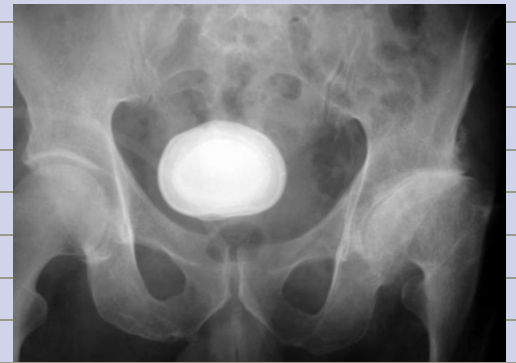**Diagnosis?**

**Urinary bladder stone**

وكان معها صورة تانية ل

**stone**

كان بدها الصح

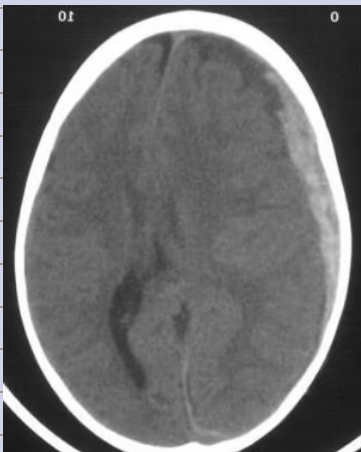


**Reporting:**

**1) Write a report about this picture :**

ما كانت بالضبط هاي الصورة بس انه كانت

**subdural hematoma**



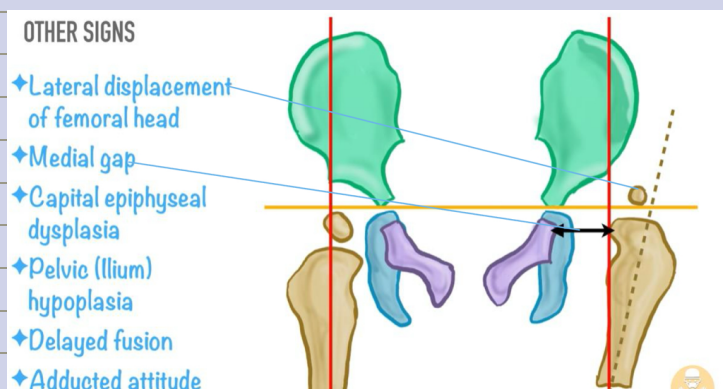
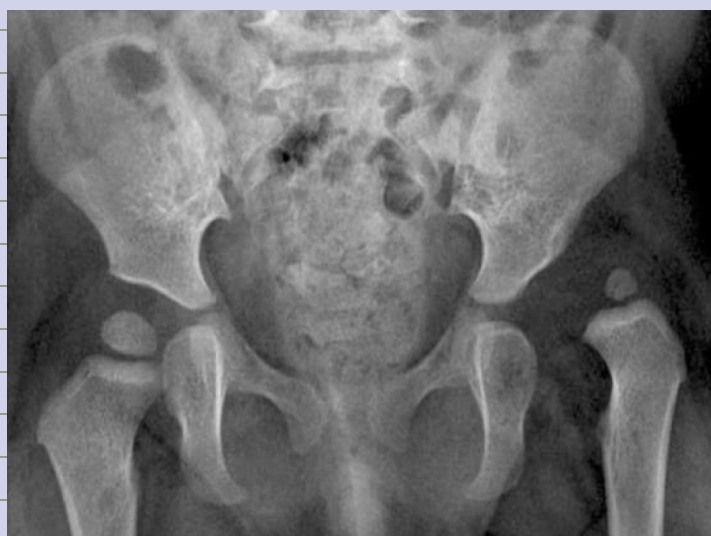***This is a non-enhanced soft tissue***

***CT scan of the brain Window:***

***There is a crescent-shaped  
hyperdense lesion in the left  
frontoparietal region***

***It crossed suture line represents an  
acute subdural hematoma. There is  
effacement of sulci but no shift of  
the midline structures***

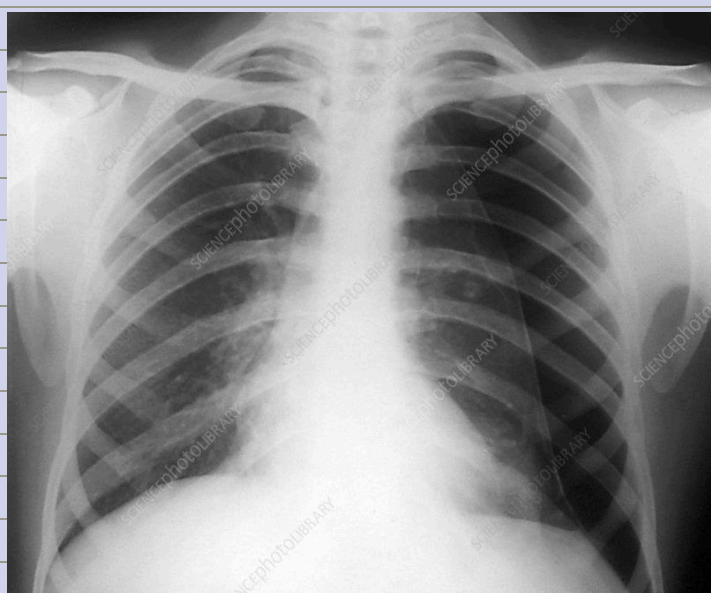
2) 5 year old boy with DDH write a report about the picture



3) Write a report about this picture :

ما كانت بالضبط هاي الصورة بس انه كانت

**Lt sided simple pneumothorax**



**PA cxr male erect good exposure , visible pleural edges of lt lung and increased ipsilateral ICS w no mediastinal shift no tracheal deviation normal both costophrenic angles normal cardiothoracic ratio, non remarkable bony thoracic cage and no hilar lymphadenopathy No deviation of trachea or mediastinal structures**

الصورة كان مبين فيها بس ال **pleural edges** باقي ال **signs** لا