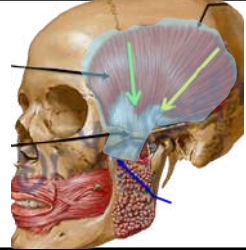
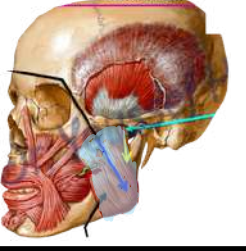
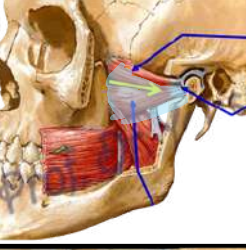


MUSCLES OF THE MASTICATION

muscles	Origin	Insertion	actions	Nerve supply	photo
Temporalis	1- From inferior temporal line 2- From Temporal fossa and temporal fascia	Into the tip, anterior border and posterior border and inner surface of the coronoid process.	1-elevation(closing) Chewing 2-Protrusion 3-Retraction (posterior fibres)	anterior division of mandible nerve	
Masseter	Superficial fibers from lower border zygomatic arch Deep fibers from deep surface of zygomatic arch Deep fibers from deep surface of zygomatic arch	Into the outer surface of the ramus of the mandibl	1-elevation(closing) Chewing 2-Protrusion	anterior division of mandible nerve	
lateral pterygoid	Upper head from infratemporal surface of greater wing of sphenoid Lower head lateral surface of the lateral pterygoid plat	Pterygoid fovea on anterior aspect of neck of mandible. • Capsule and articular disc of temporomandibular joint.	1-depression (opening) 2-Protrusion 3-Side to side movement	anterior division of mandible nerve	
Medial pterygoid	Deep head from medial surface of lateral pterygoid plate Superficial head from maxillary tuberosity	Into the inner surface of the ramus and angle of the mandible	1-elevation(closing) Chewing 2-Protrusion 3-Side to side movement	mandible nerve	