

UPPER LIMB LECTURE FOUR

Dr AMAL ALBTOOSH

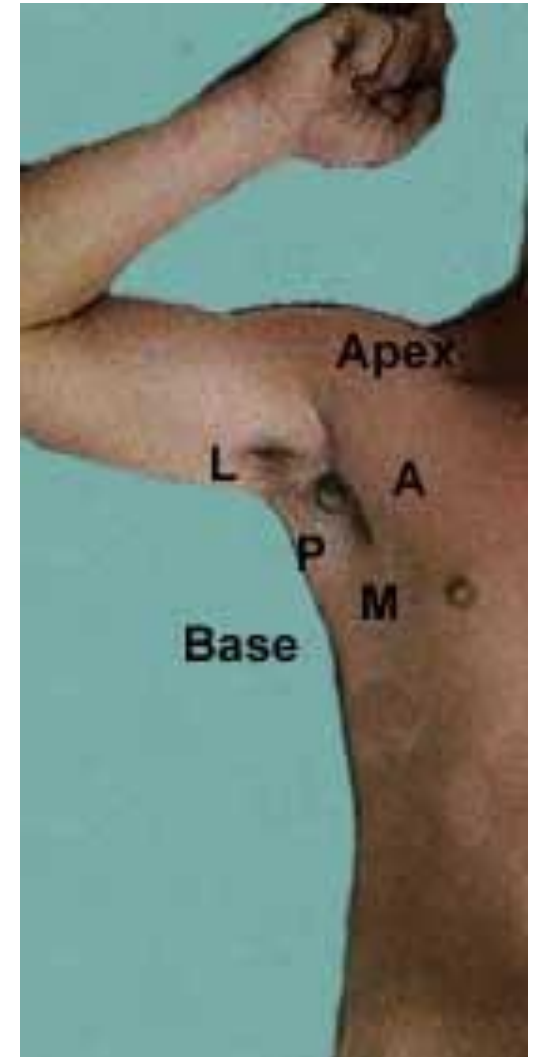
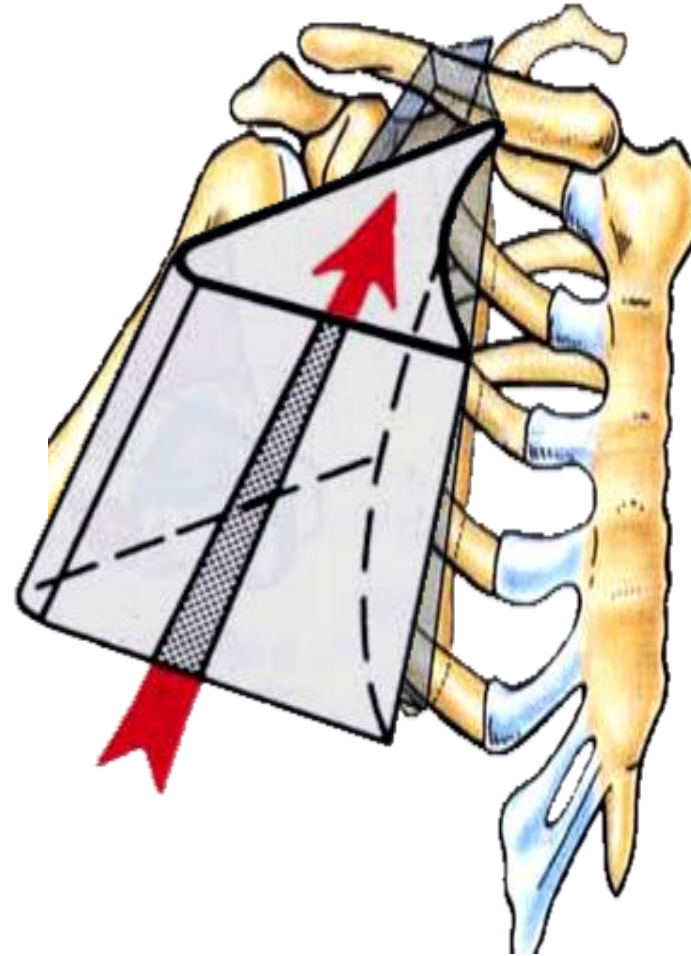


AXILLA



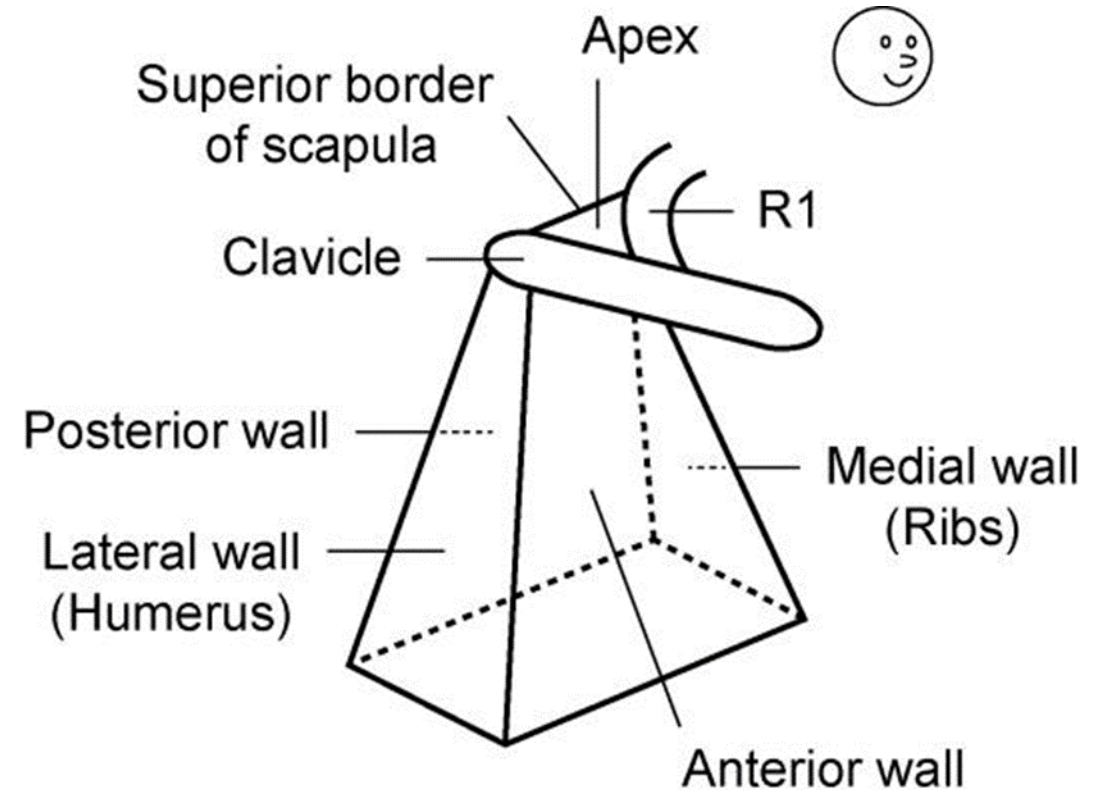
AXILLA

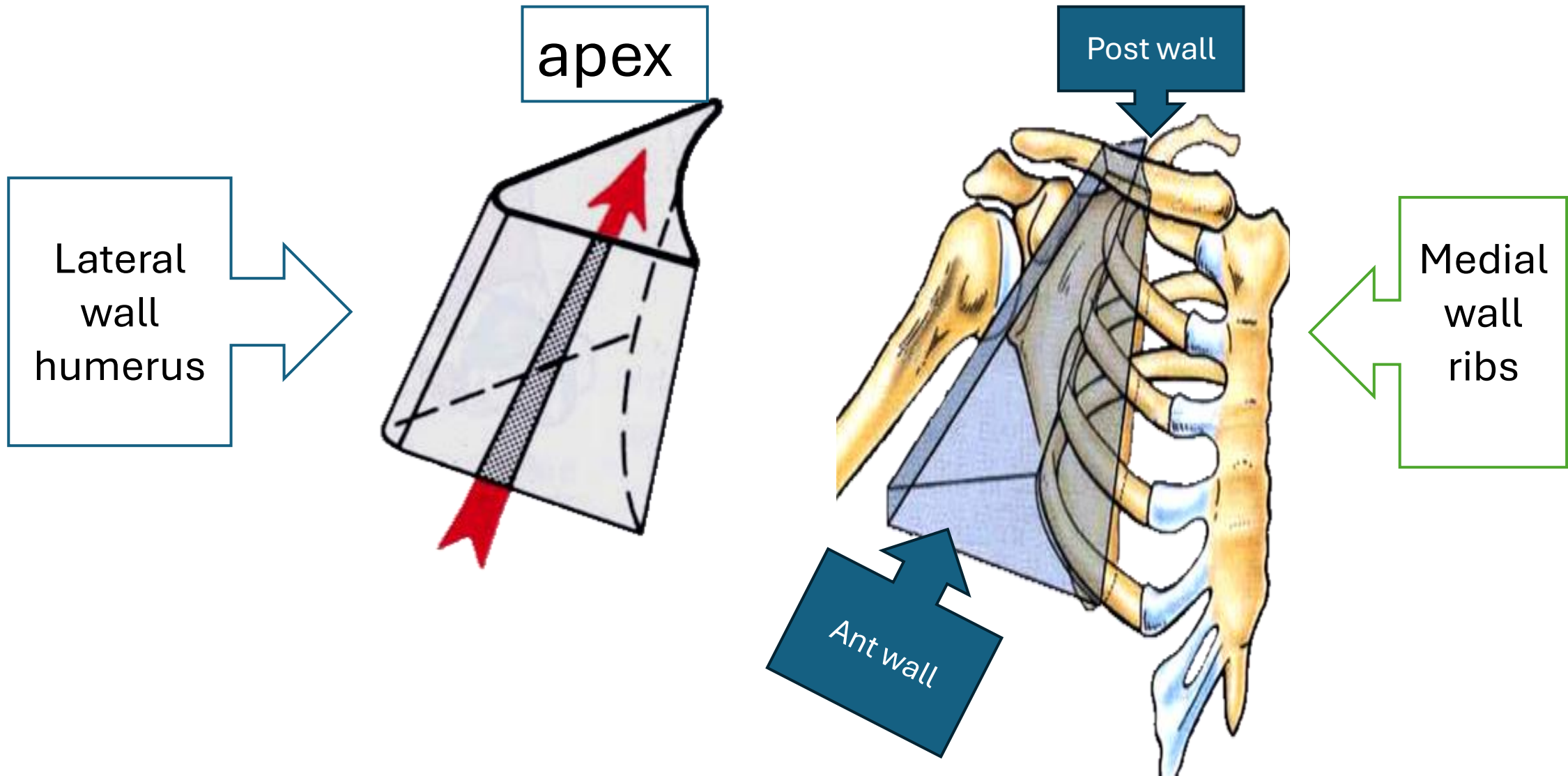
- A pyramid-shaped space between the upper part of the arm and the side of the chest through which major **neurovascular** structures pass between neck & thorax and upper limbs.
- Axilla has an **apex**, a **base** and **four walls**.



The axilla is a pyramid with:

- A. an apex
- B. four walls: Ant, post, med, lat
- C. a quadrangular base. The triangular apex is formed by the clavicle, R1, and superior border of scapula. Through the apex, the brachial plexus, axillary artery, and axillary vein enter the axilla from the neck





apex

Lateral wall humerus

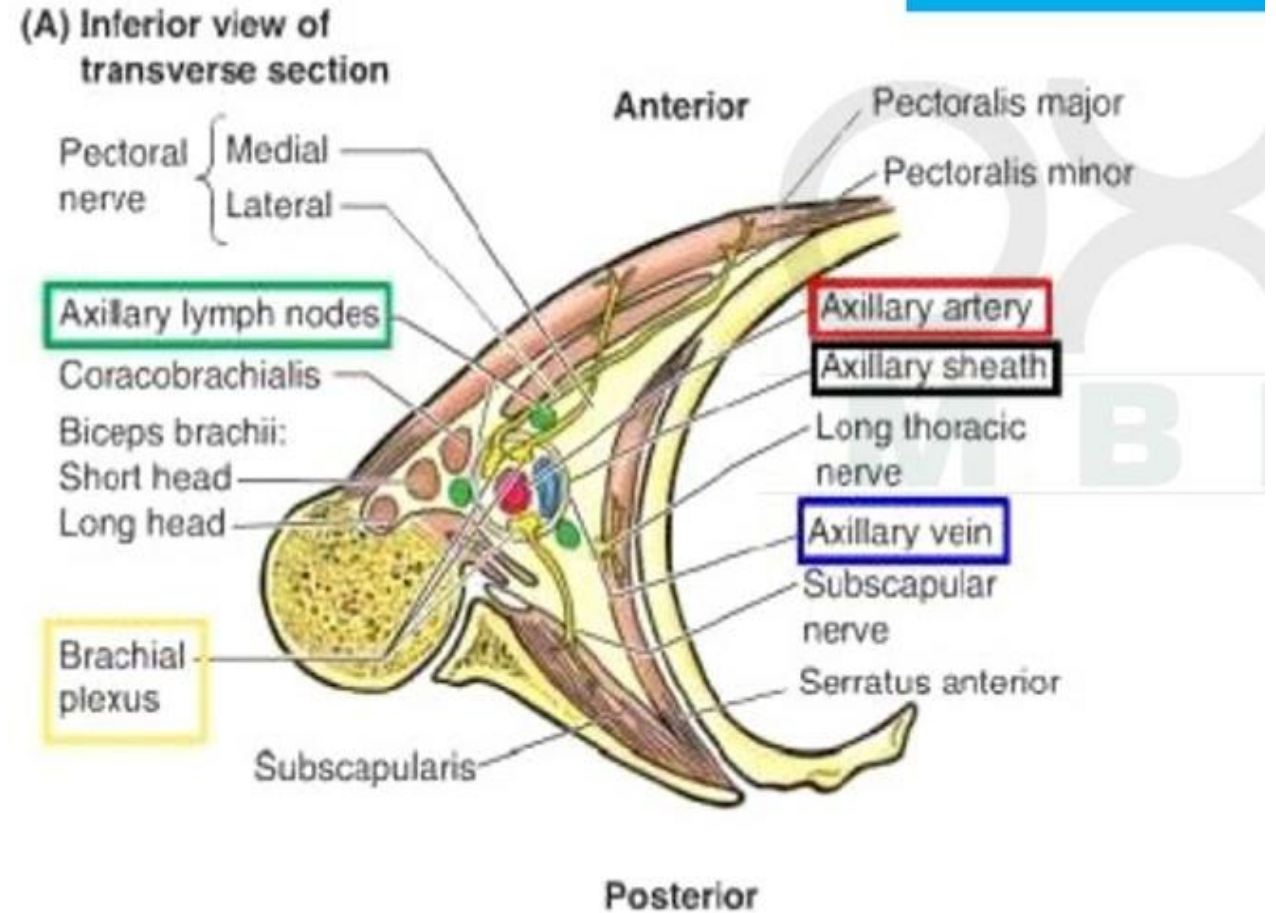
Post wall

Medial wall ribs

Ant wall

Contents of The Axilla

- The most distinguished component of the axilla is the brachial plexus
→ **Cords** and **braches** of the **brachial plexus**
- **Axillary artery and its branches.**
- **Axillary vein and its tributaries.**
- **Axillary lymph nodes.**
- **Axillary fat.**
- **Loose connective tissue.**



The neurovascular bundle is enclosed in connective tissue sheath, called '**axillary sheath**'

Pectoral muscles

The Pectoral Region

❖ The **pectoral region** is located on the anterior chest wall.

❖ It contains

I. **Four muscles** that exert a force on the upper limb:

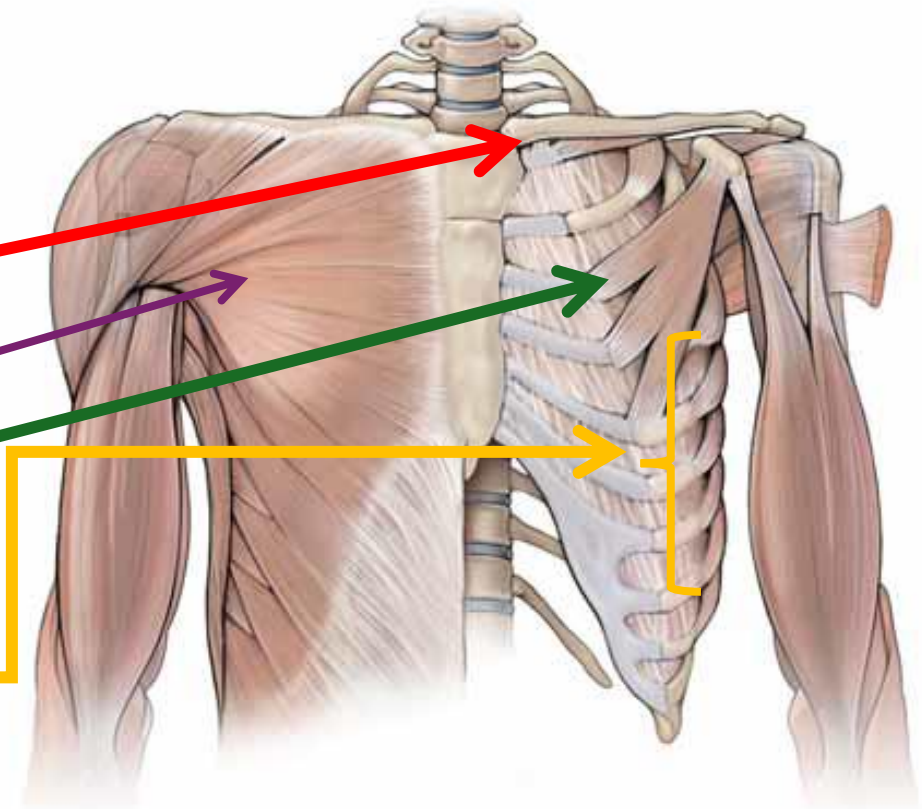
1. **Subclavian**

2. **The Pectoralis major**

3. **Pectoralis minor**

4. **Serratus anterior**

II. **Breast**



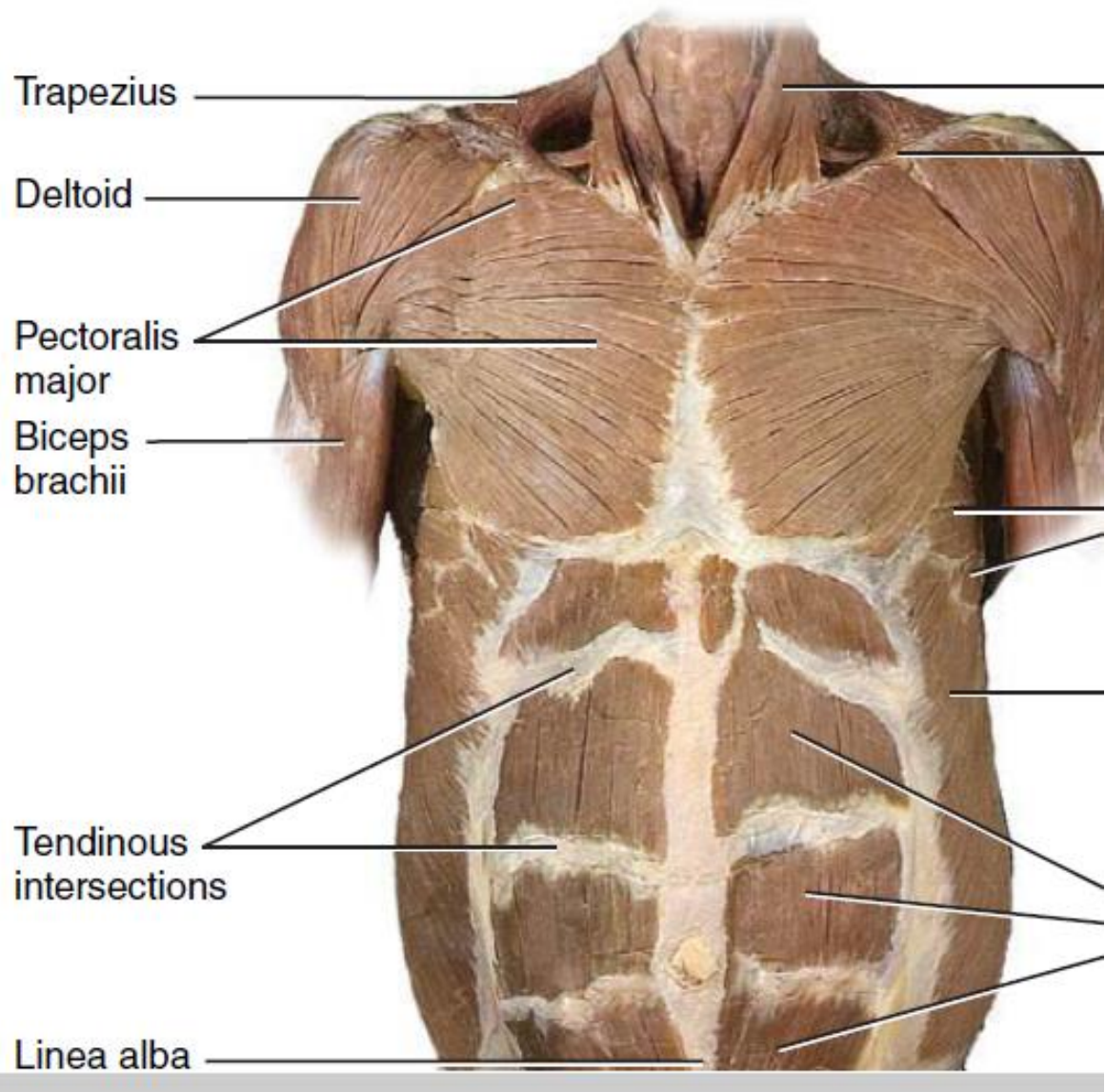
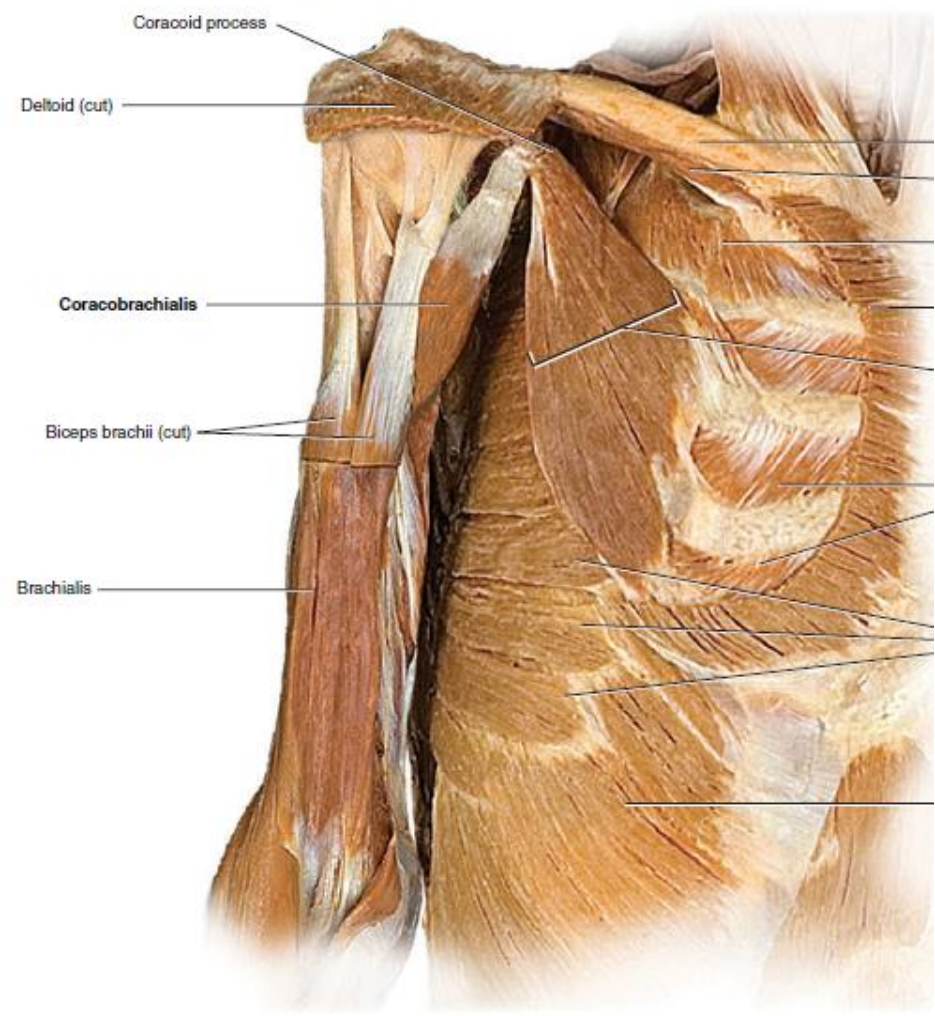


FIGURE 11.18 CONTINUED

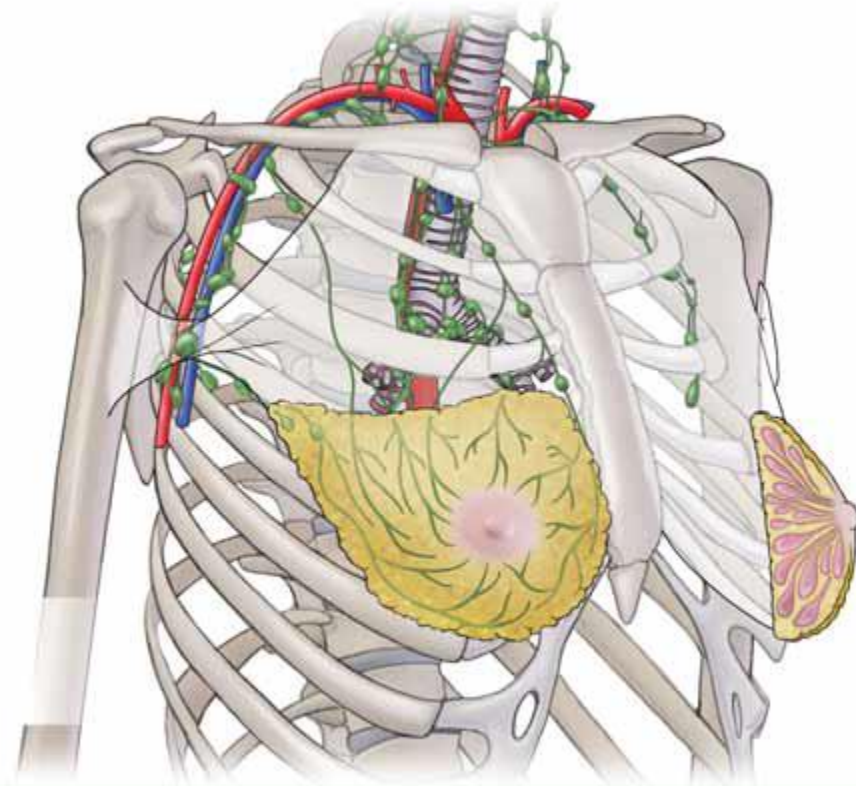


Mark Nielsen

The Pectoral Region

The Breasts

- The breasts, although strictly speaking, are not anatomically part of the upper limb; they are situated in the pectoral region (anterior chest wall).
- They are present in both sexes.
- they are similar in structure in males and immature females,
- An adult female the breast has the mammary glands and the subcutaneous tissue .

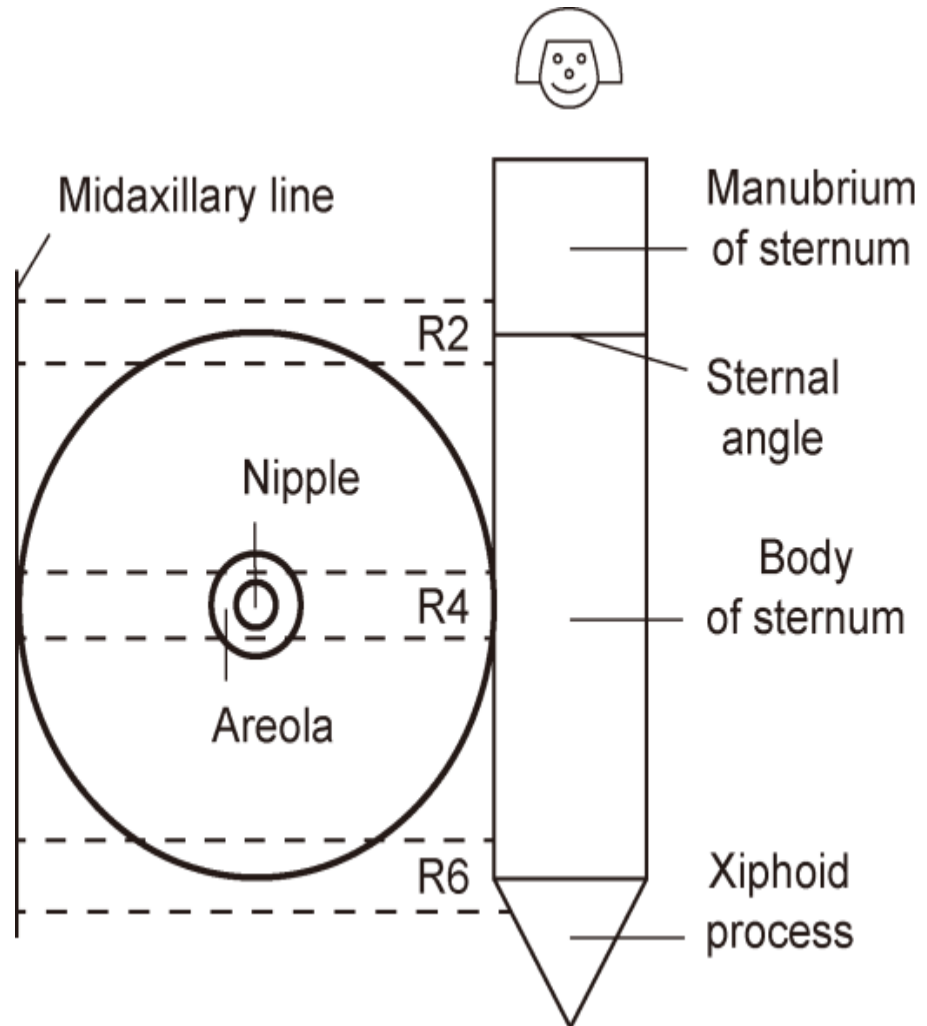


The subcutaneous tissue that supports the mammary glands determines the size of a breast.

The Pectoral Region

Location and Description

- The breasts are specialized accessory glands of the skin that secrete milk.
- The level of the breast is Rib 2–Rib 6 , and the level of the nipple, located at the centre of the breast, is Rib 4.





Try to be relaxed