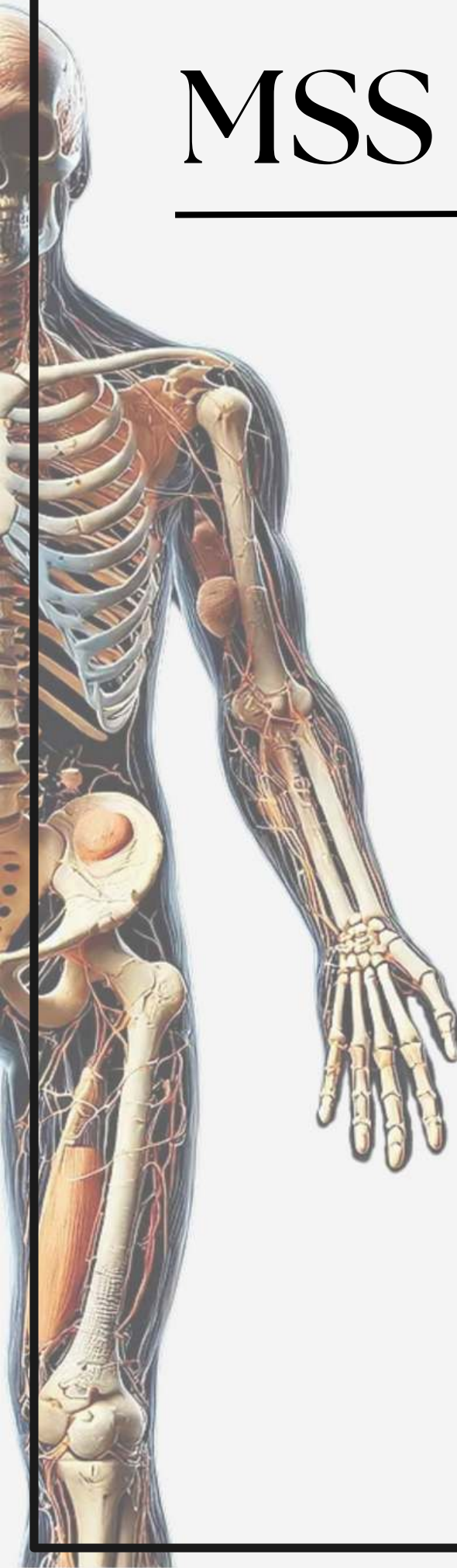


MSS - Anatomy

Archive

Lecture 2

Lecture's name
The Skull II



Anatomy - lecture (2)

questions

1) Middle meningeal artery pass through :

- A. Foramen spinosum.
- B. Foramen lacerum.
- C. Foramen ovale.
- D. Carotid canal.
- E. Hypoglossal canal

Answer: A

2) Which nerve cross over sternomastiod:

- A. Great auricular nerve.
- B. Lesser occipital nerve.
- C. Transverse cervical nerve.
- D. Accessory nerve.
- E. Phrenic nerve.

Answer: C

3) The mandibular nerve pass through which foramen of the skull :

- A- Foramen spinosum.
- B- Foramen ovale.
- C- Stylomastoid foramen.
- D- Foramen lacerum.
- E- Jugular foramen.

Answer: B