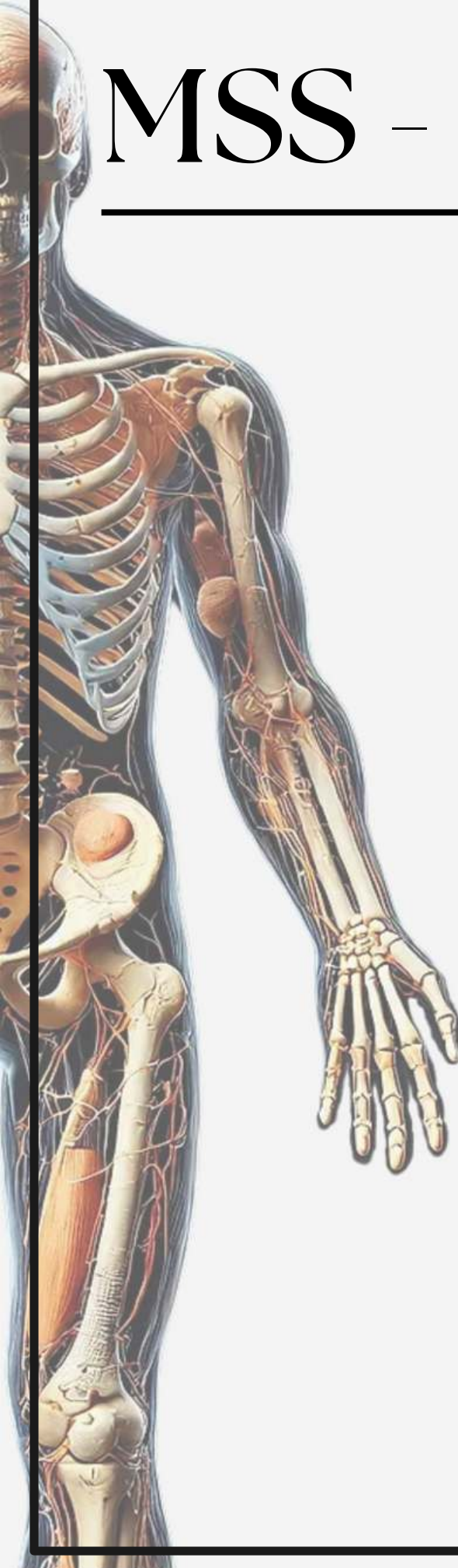


MSS - Histology

Archive

Lecture 2

Cartilage



Histology - lecture (2)

1) Type of cartilage in epiglottis :

- A. Elastic cartilage
- B. Fibro cartilage
- C. Hyaline cartilage

Answer: A

2) Cartilage is:

- a. has typical vascularity
- b. avascular
- c. has low vascularity
- D. with excessive vascularity

Answer: B