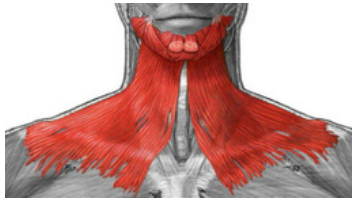
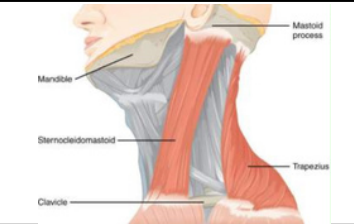


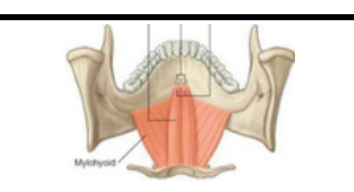
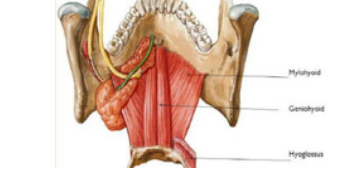


ANTERIOR TRIANGLE

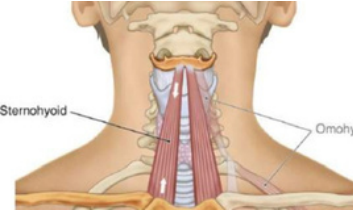
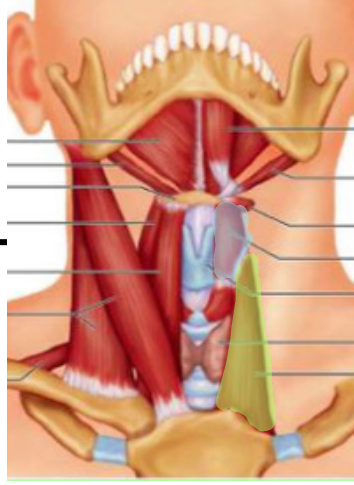
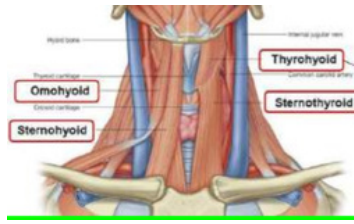
Muscles of the Neck & Suprahyoid



muscles	Origin	Insertion	actions	Nerve supply	photo
Platysma <i>Muscles of the Neck</i>	Deep fascia over pectoralis major and deltoid	Body of mandible and angle of mouth	Depresses mandible and angle of mouth	Facial nerve; cervical branch	
Sternocleidomastoid <i>Muscles of the Neck</i>	Manubrium sterni and medial third of clavicle	Mastoid process of temporal bone and occipital bone	Two muscles acting together extend head and flex neck; one muscle rotates head to opposite side.	Spinal part of accessory nerve and C2 and 3	
Digastric <i>Suprahyoid Muscles</i>	Posterior belly: Mastoid process of temporal bone Anterior belly: Body of mandible	Intermediate tendon is held to hyoid by fascial sling	Depresses mandible or elevates hyoid bone	Posterior belly: Facial nerve Anterior belly: Nerve to mylohyoid	
Stylohyoid <i>Suprahyoid Muscles</i>	Styloid process	Body of hyoid bone	Elevates hyoid bone Dr. Aiman	Facial nerve	
Mylohyoid <i>Suprahyoid Muscles</i>	Mylohyoid line of body of mandible	Body of hyoid bone and fibrous raphe	Elevates floor of mouth and hyoid bone or depresses mandible	Inferior alveolar nerve (Nerve to mylohyoid)	
Geniohyoid <i>Suprahyoid Muscles</i>	Inferior mental spine of mandible	Body of hyoid bone	Elevates hyoid bone or depresses mandible	1st cervical nerve	

ANTERIOR TRIANGLE

Infrahyoid Muscles

muscles	Origin	Insertion	actions	Nerve supply	photo
Sternohyoid	Manubrium sterni and clavicle	Body of hyoid bone	Depresses hyoid bone	Ansa cervicalis; C1, 2, and 3	
Sternothyroid	Manubrium sterni	Oblique line on lamina of thyroid cartilage	Depresses larynx	Ansa cervicalis; C1, 2, and 3	
Thyrohyoid	Oblique line on lamina of thyroid cartilage	Lower border of body of hyoid bone	Depresses hyoid bone or elevates larynx	1st cervical nerve	
Omohyoid	Inferior belly: Upper margin of scapula and suprascapular ligament Superior belly: Lower border of body of hyoid bone	Intermediate tendon is held to clavicle and first rib by fascial sling	Depresses hyoid bone	Ansa cervicalis; C1, 2, and 3	