

# MSS-pathology

---

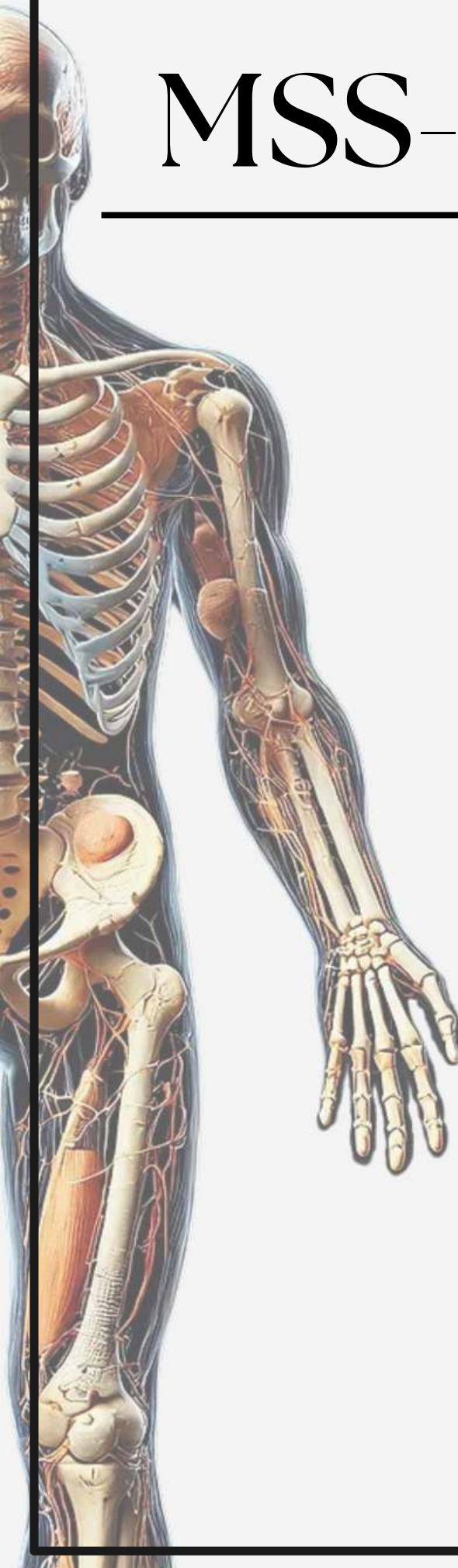
## Archive

### Lecture 3

Chronic inflammatory  
dermatoses and blistering  
disease.

Done by :

Layan Riyadh



# pathology - lecture (3)

Nail changes due to :

- A) psoriasis
- B) rheumatoid arthritis

Answer:A

Civate body:

- A- necrotic basel cell
- B-necrotic detach of stratum corneum
- C-epidermal acantholysis

Answer:A

Lichen planus:

- A- CD8
- B- CD4
- C- both
- D- non of the following

Answer :A