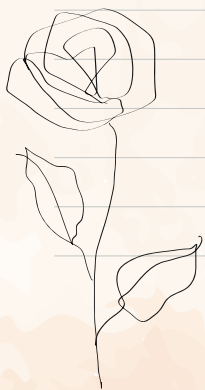



INTERNAL MEDICINE ARCHIVE
MINI-OSCE.
FIRST SEMSTER-ROUH.
2024/2025.

DONE BY BOSHRA AL-OMOUSH



Hematology;

1) write 2 about cbc results?

-low platelet

-anemia

-leukocytosis

2) what's your diagnosis ?

-AML

3) write 2 investigations?

-bone marrow biopsy

-peripheral blood smear

GIT :

29 years old women came with bleeding ulcer in antrum of stomach

1) most common cause ?

H.pylori

2) 3 line of urgent management?

-endoscopic hemostasis

-IV PPI

-H.pylori eradication therapy

3) write 3 complications?

-gastric outlet obstruction

-perforation


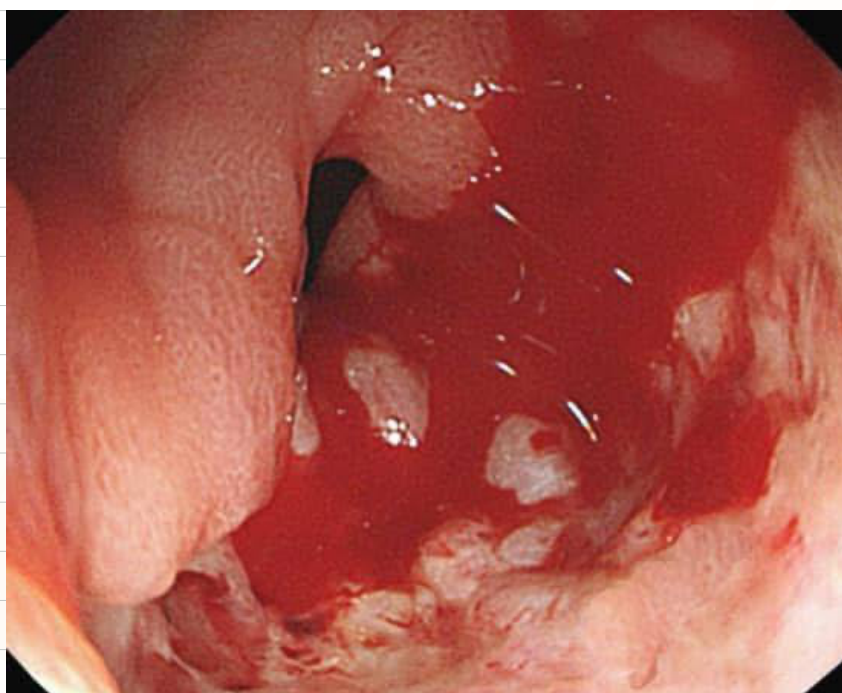
-haemorrhage

Clinical History

- A 29 year-old pregnant female (G3P1A1) presented at ~6 weeks gestation with night sweats and nausea for one week.
- She had also experienced an episode of gum bleeding while brushing her teeth approximately one week prior.
- She was found to have leukocytosis, anemia and thrombocytopenia on routine CBC:

CBC Results

CBC Result	Normal Range
WBC: 55 K/mm ³	4.0-11.0 K/mm ³
RBC: 3.29 M/mm ³	3.70 – 5.10 M/mm ³
Hgb: 11 g/dL	12.0 – 15.0 g/dL
HCT: 31.8%	34.0 - 44.0%
MCV: 96.7 fl	80.0 – 98.0 fl
MCH: 33.4 pg	27.0 – 33.0 pg
MCHC: 34.6 g/dL	33.0 – 35.0 g/dL
RDW: 13.7%	11.3 – 15.1 %
Platelets: 33 K/mm ³	150 – 450 K/mm ³



GIT ;

Female patient 6 months of fatigue, SOB , itchy rash , Iron deficiency anemia

1) what's your diagnosis ?

-celiac disease

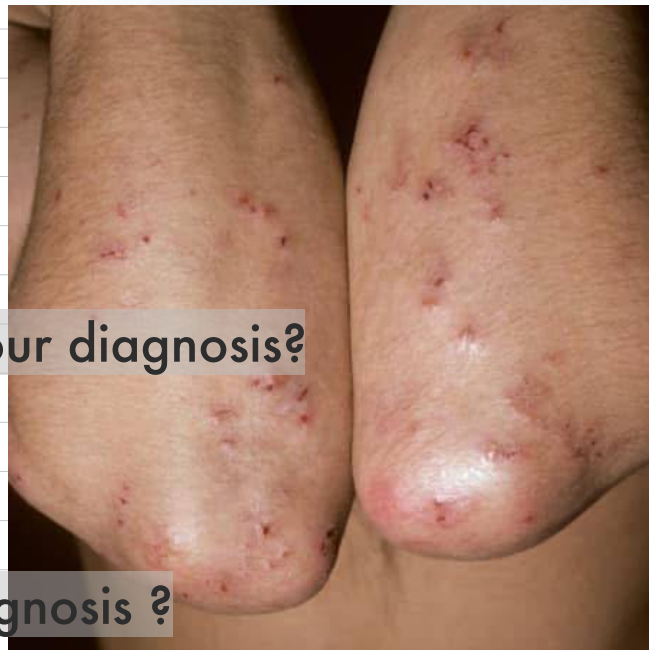2) write 2 investigations that supports your diagnosis?

-tTG IgA , total IgA

-endomysial IgA

3) the best thing for confirming your diagnosis ?

-endoscopy with biopsy ما يعرف اذا هيك صح



4) write 2 complications?

-secondary lactose deficiency

-T cell lymphoma

-refractory celiac disease

Endocrine ;

50 years female patient came to outpatient clinic with period of fatigue, weight gain, constipation and cold intolerance

1) 2 facial abnormalities?

-apathic face , dry skin

-loss of lateral third of eyebrows

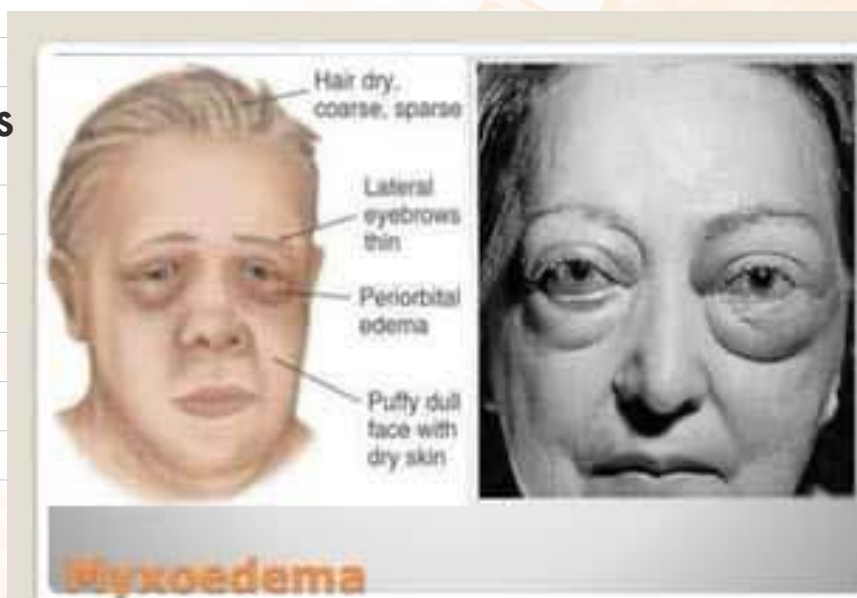
2) your diagnosis ?

-Hypothyroidism

3) 2 diagnostic test?

-TSH

-T4

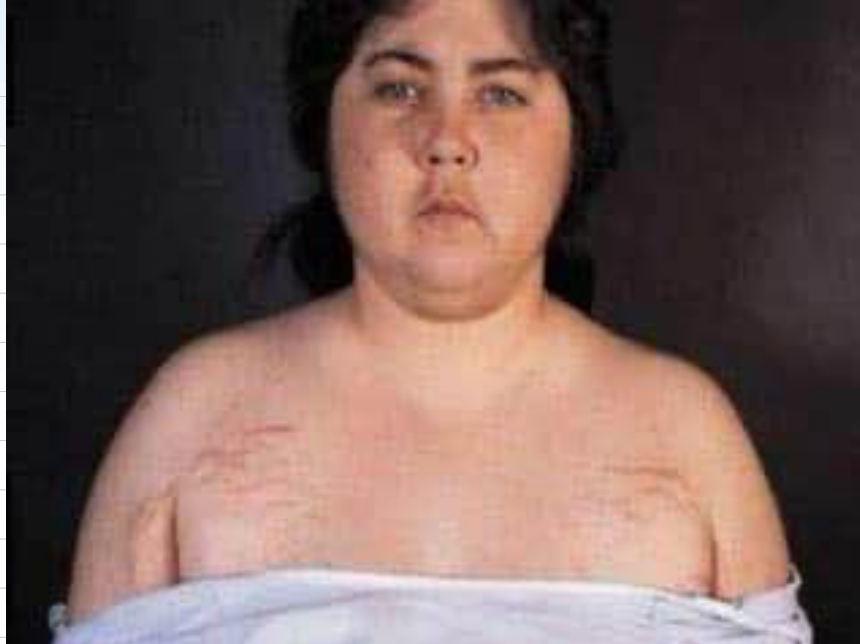

Endocrine

44 female patient with SLE

1) 3 signs you see ?

- moon face
- purple stria
- hirsutism



2) your diagnosis ?

Cushing

3) what the cause for her condition?

Exogenous cortisol

Rheumatology;

34 years old man with fatigue , stiffness back pain that persist for than 1 hour at the morning :

1) what's your diagnosis ?

-Ankylosing Spondylitis

2) Give 2 radiological signs ?

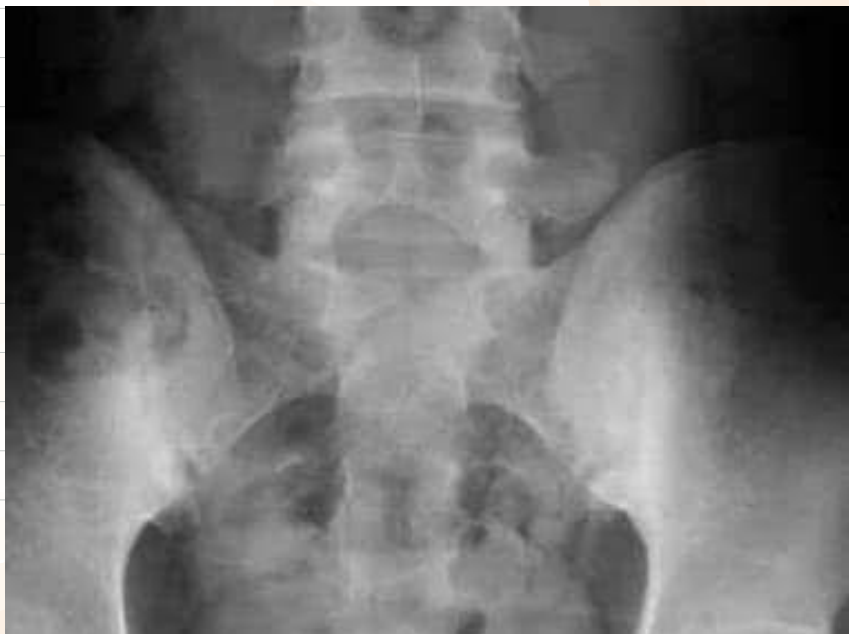- bambo sign
- sacroilitis
- fusion and narrowing of joint space

3) investigations?

- gene study : HLA-B27
- negative rheumatic factor

4) 2 lines of management?

- intra joint glucocorticoid injection
- immunosuppressant agent



Rheumatology;

74 years old male with difference and delay impulses

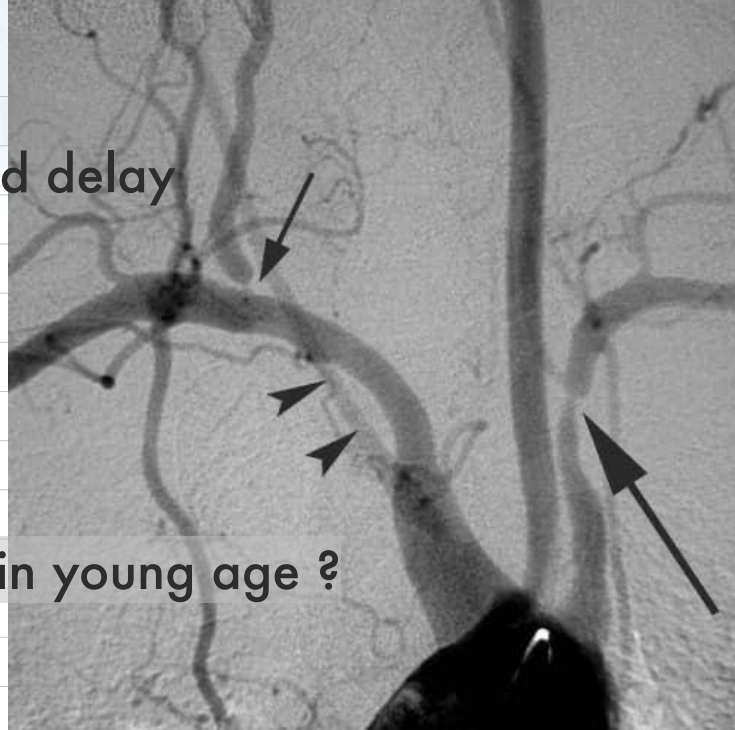1) what the cause of his symptom?

-Atherosclerosis

2) give other 2 differential diagnosis in young age ?

-Takayause

-aortic coartication



3) 2 lines of treatment ?

-treat underlying disease (statin in case of hyperlipidemia)

-life style modification (stop smoking , weight reduction)

Nephro ;

36 years old male , increase in creatine suddenly, apyrexia , then after he dies .. kidney autopsy shows this photo

في تكملة مهمة بس صراحة ما لحقت اقرأ

1) what's the cause for his death?

-PKD

2) the type of inheritance?

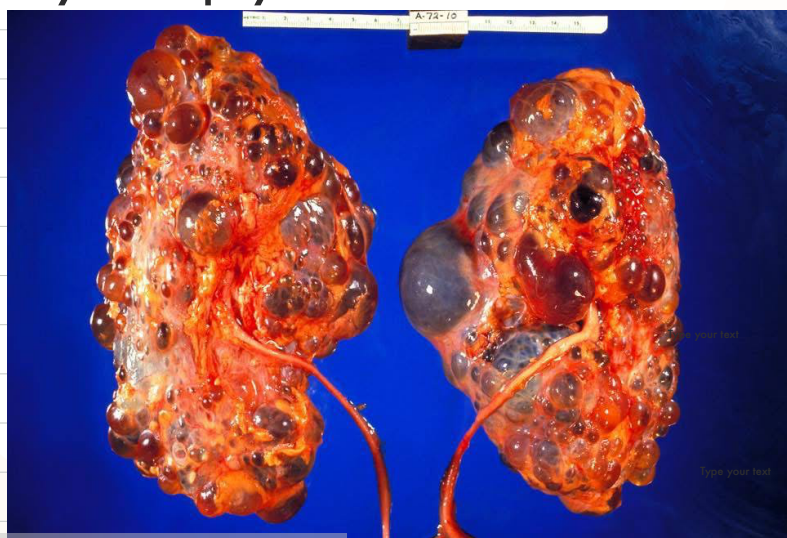
-AD

3) 3 investigations you will need for other than in image ?

-US

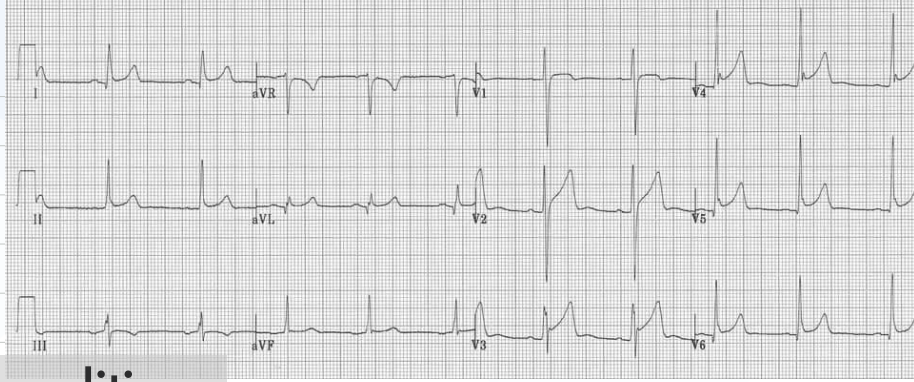
-KFT/urinalysis

-cbc



CVS ;

1) your diagnosis
-pericarditis



2) mention 3 causes for this condition :

- uremia
- post MI
- Radiation
- Idiopathic

3) confirm your diagnosis by?

Echo

4) line of treatment ?

- uremia -> dialysis
- post MI -> colchicine + aspirin
- another causes -> colchicine + high dose of nsaid

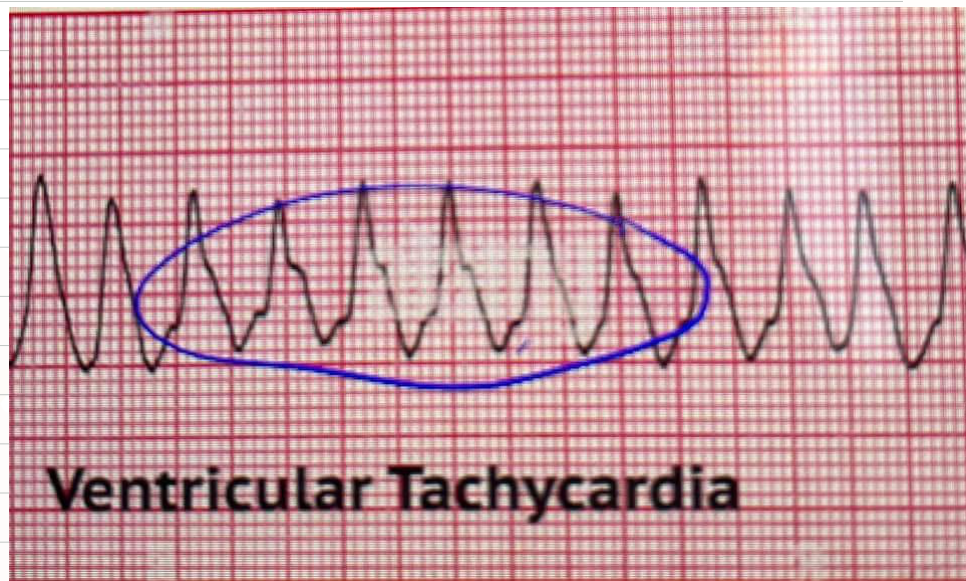
CVS:

1) 2 ecg findings ?


- wide QRS
- No p wave

2) Diagnosis?

-vent tachy



3) 3 lines of treatment?



RS

Diabetic patient with 80/60 BP , HbA1c:8,5 .. في تكملة للهستوري برضه كثير بده
والوقت ما كان بكفي chest X-ray وقت قراءة الكيسات لصون ال

1) your diagnosis?

-left labor Pneumonia

2) 3 physical findings?

-dullnes on percussion

-increase tactile frematus

-bronchial breathing

3) 2 investigations?

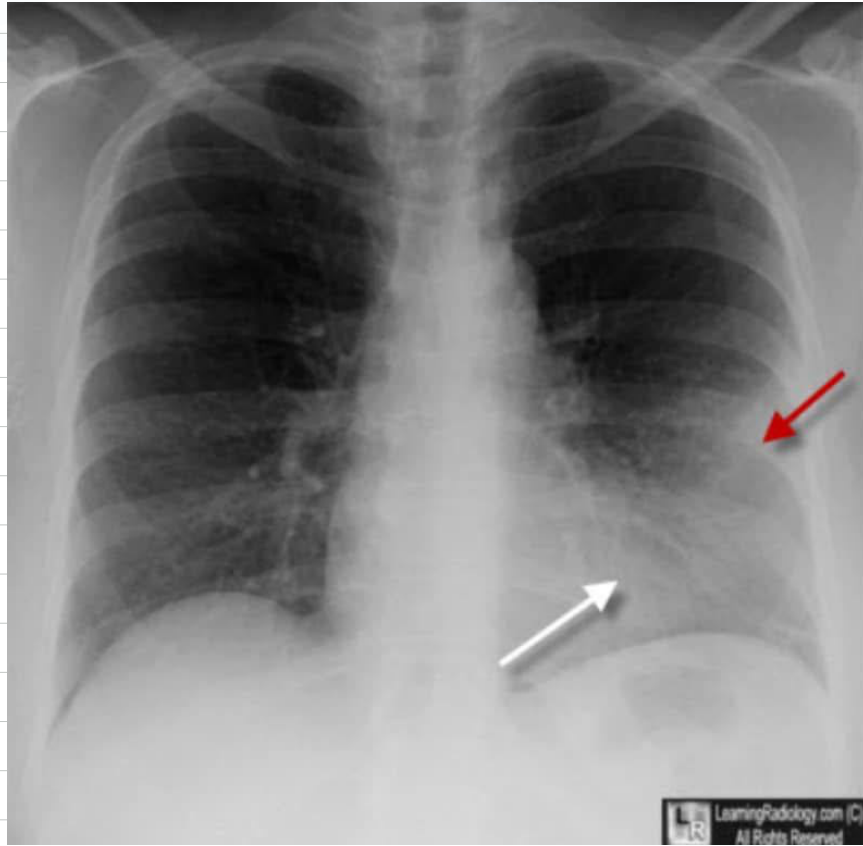
-cbc

-sputum culture

4) give me 3 causes ?

-s.pneumoniae

-klebsilla



RS ;

Female patient with sudden pleuritic chest pain , SOB ..

1) 2 characters of chest X-ray ?

-medistinal shifting

-obliteration of costophrenic angle

2) give 2 differential diagnosis ?

-fibrosis

-atelactasis

3) 2 lines of management?

