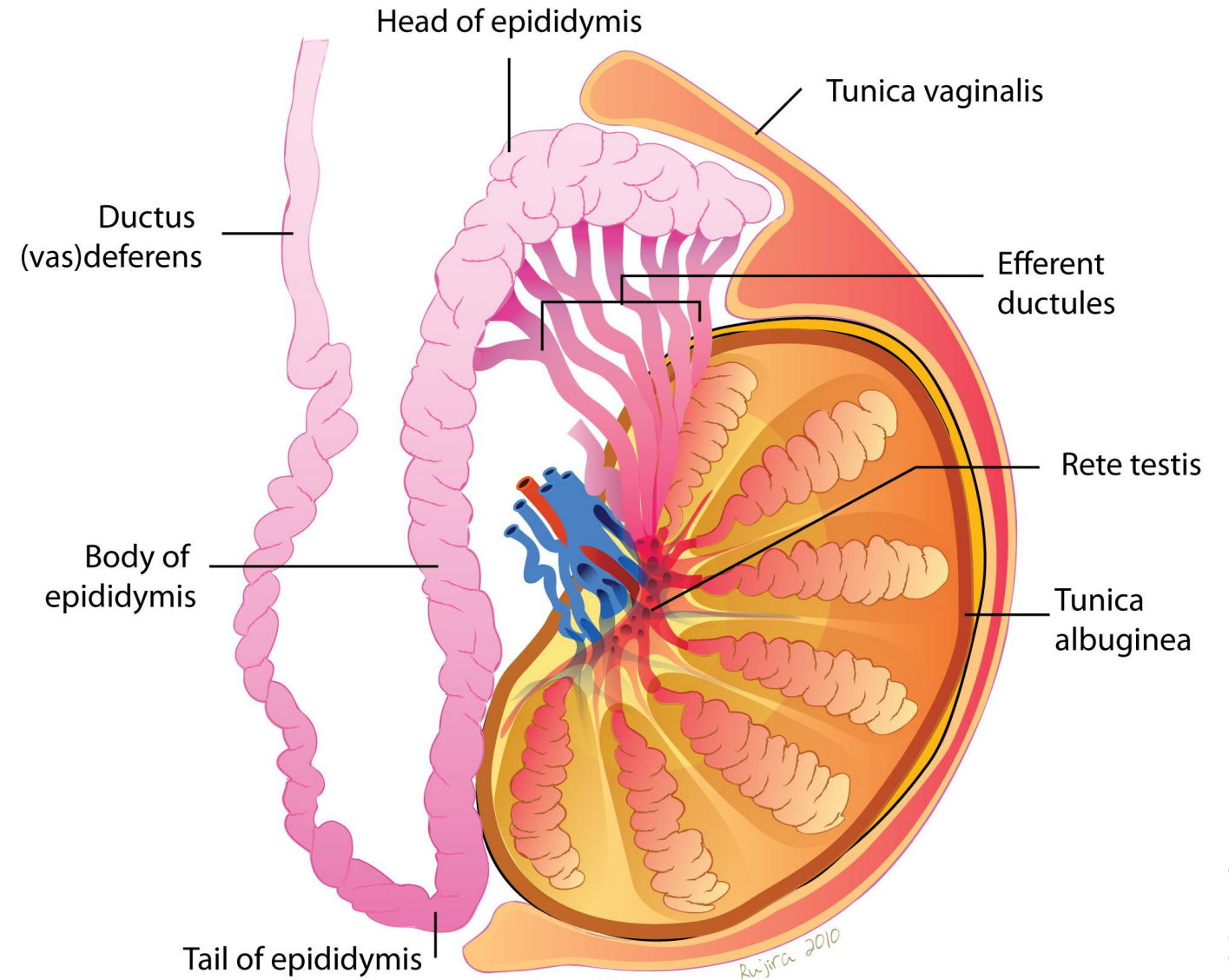
The background features a series of concentric circles in light gray, some solid and some dashed, creating a ripple effect. A large red speech bubble is centered on the page, containing the main text.

urogenital system. Pathology of the Male Genital System- Testis.

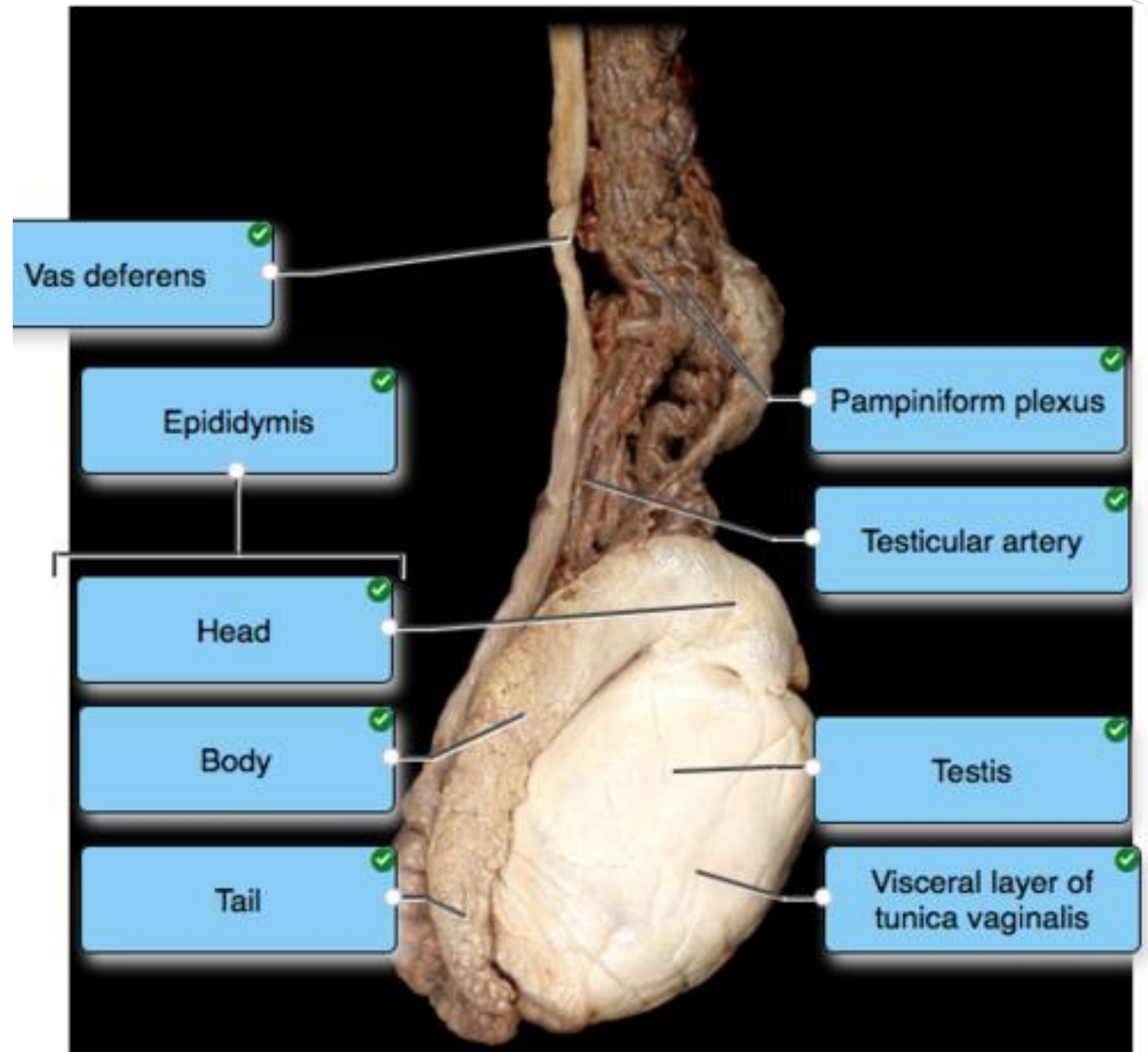
Dr.Eman Kreishan, M.D.

4-5-2025.

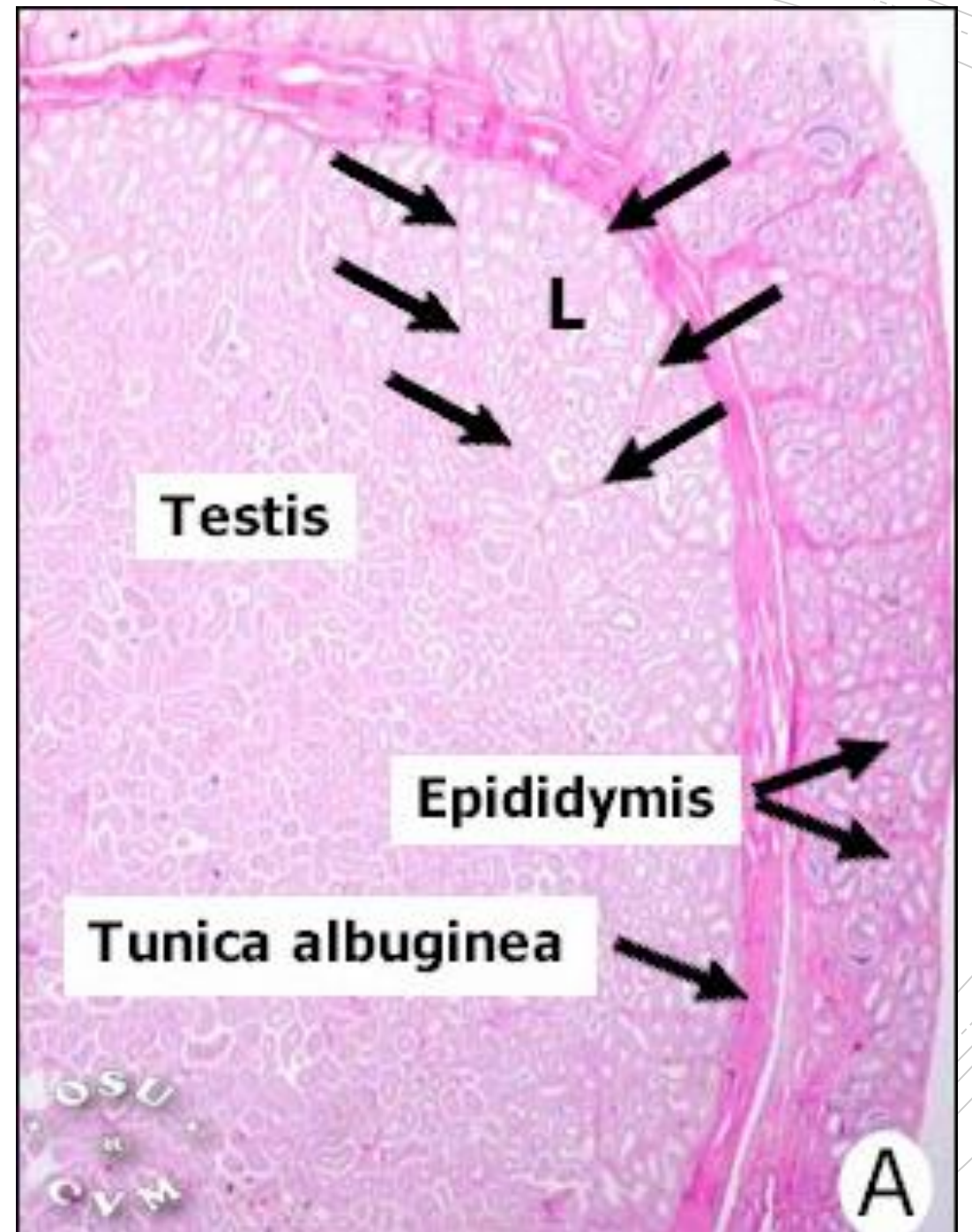
Testis. Anatomy.

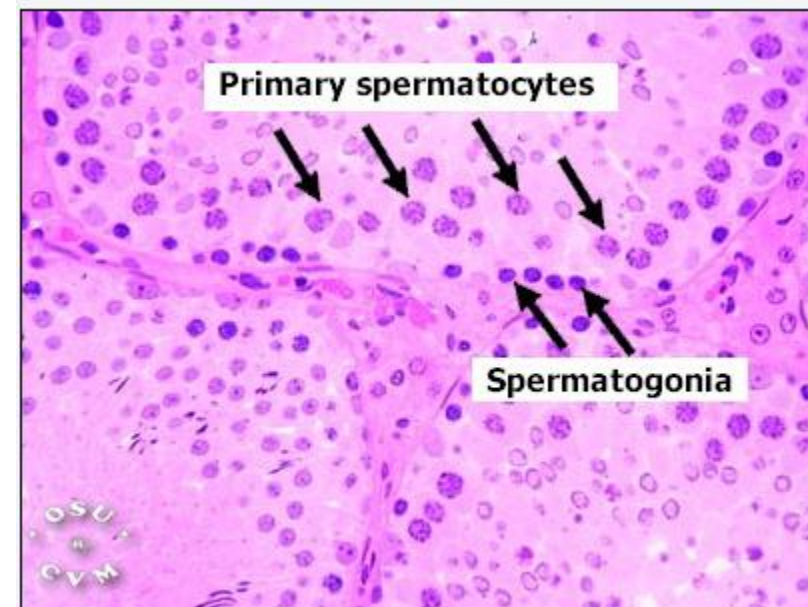
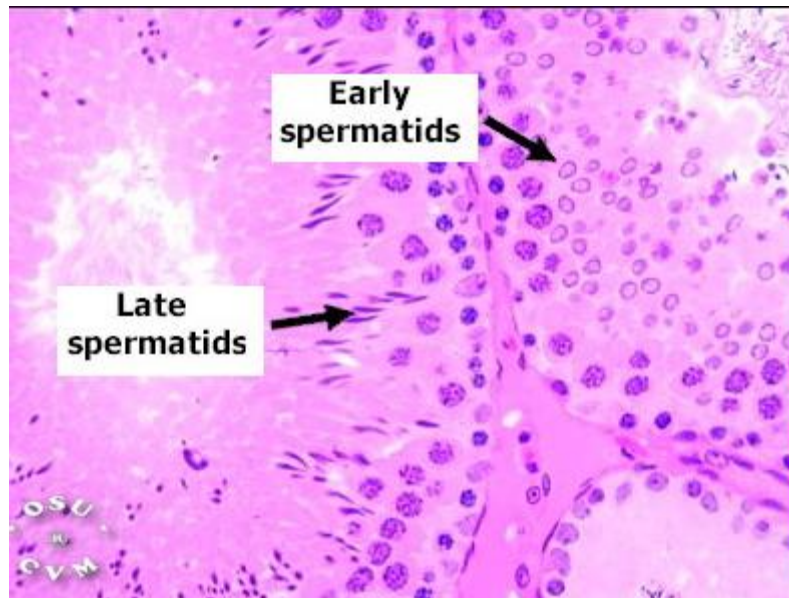
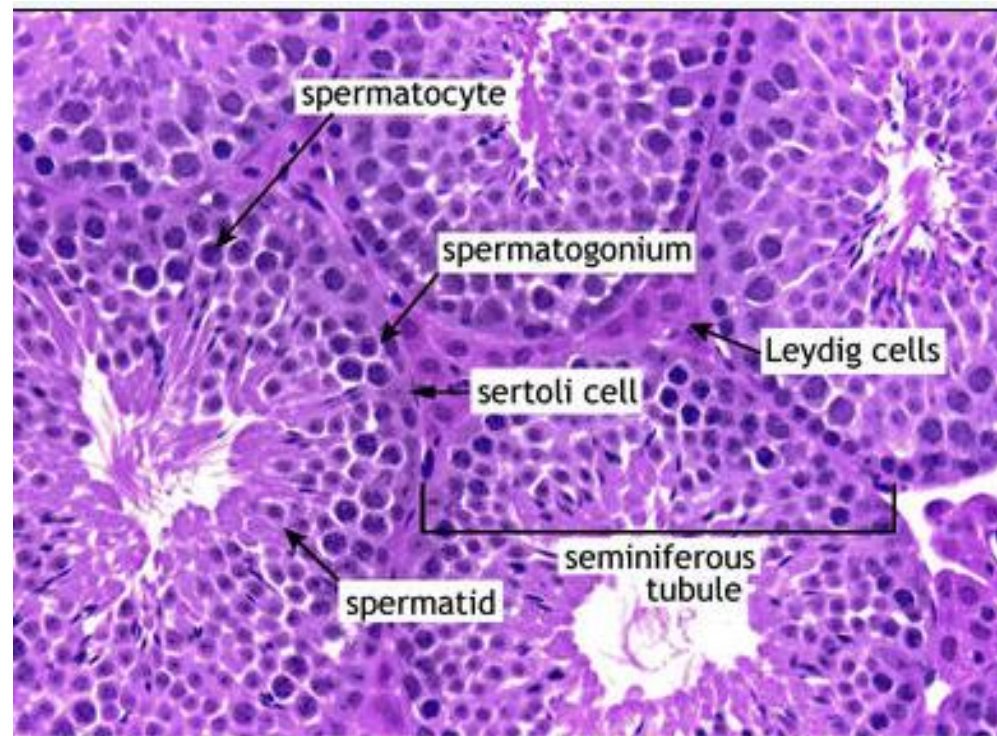


Grossly



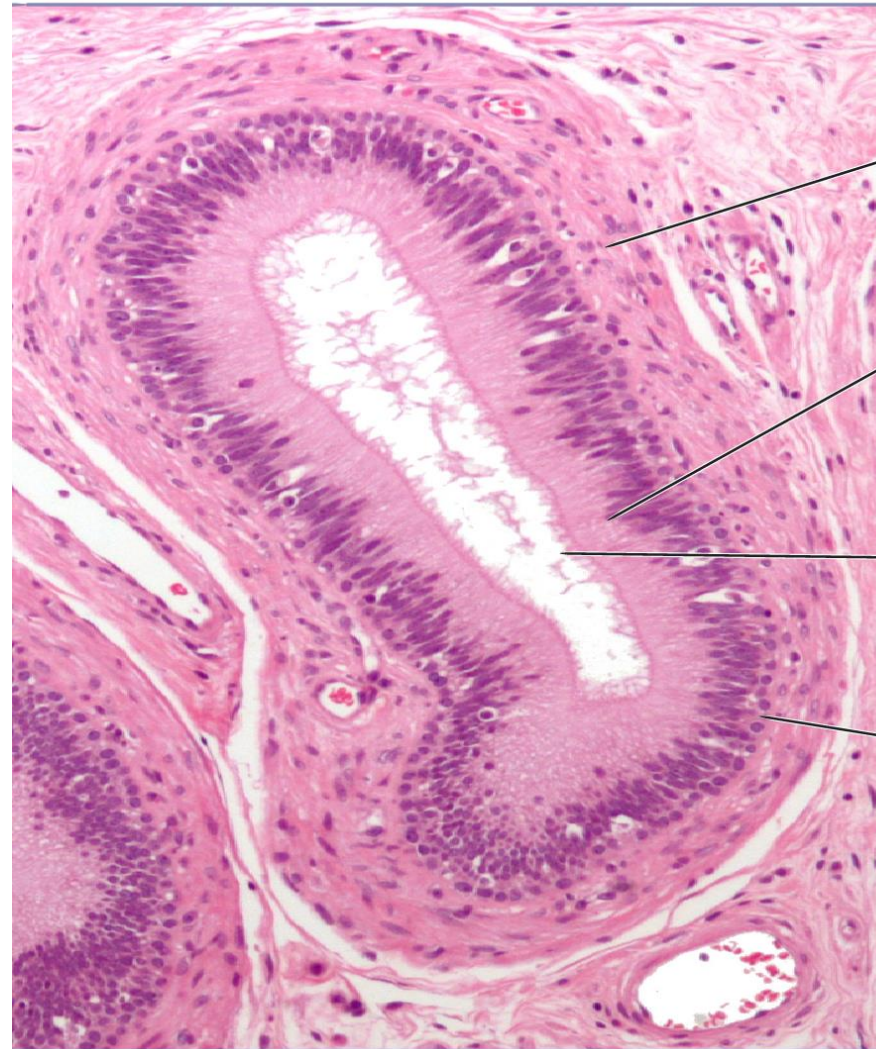Testis..histology





Epididymis ..histology.

Epididymis



Smooth muscle

Columnar cells

Stereocilia

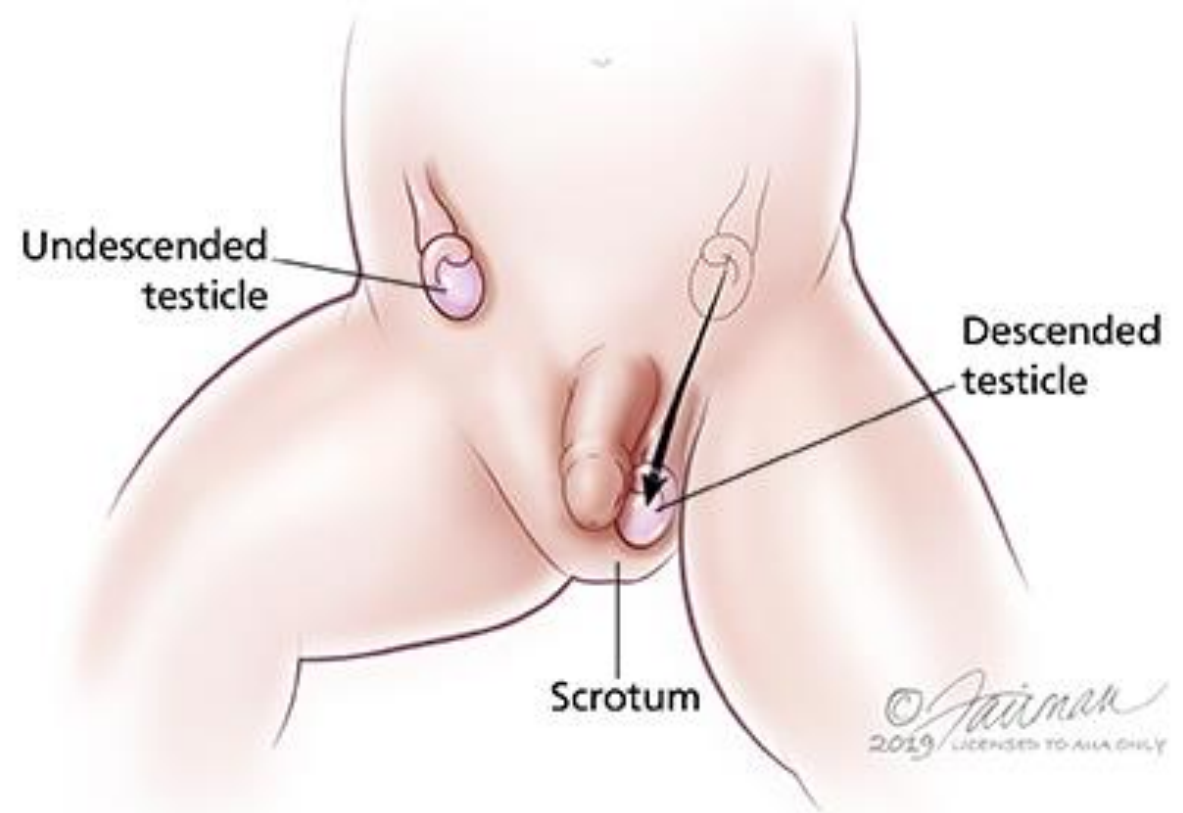
Basal cells

The background of the slide features several thin, curved lines in a light gray color, some solid and some dashed, creating a modern, abstract design.

Testicular disorders

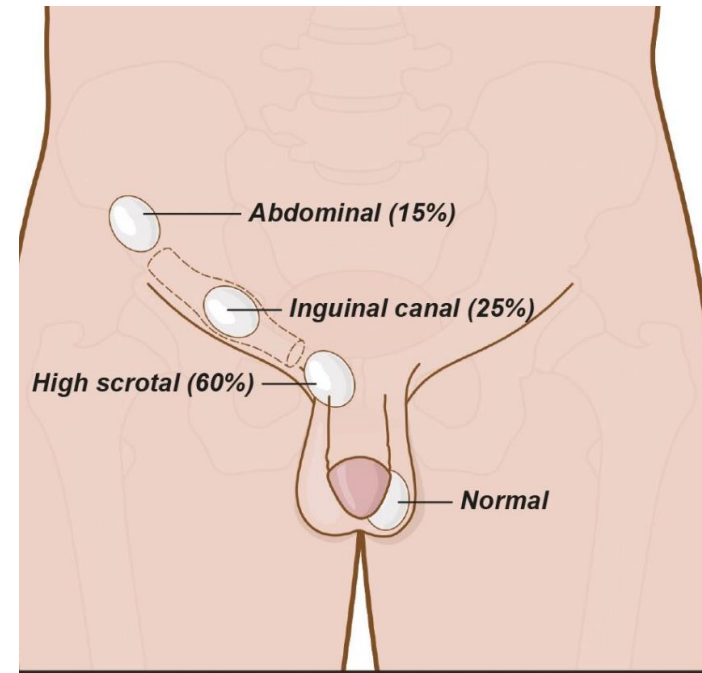
- **Cryptorchidism.**
- **Vascular Disturbances.**
- **Neoplasms.**

1. Cryptorchidism



1. Cryptorchidism

- It is a failure of testicular descent into the scrotum.
- Normally, the testes descend from the abdominal cavity into the pelvis (3rd month of gestation) → then through the inguinal canals into the scrotum (last 2 months of intrauterine life).

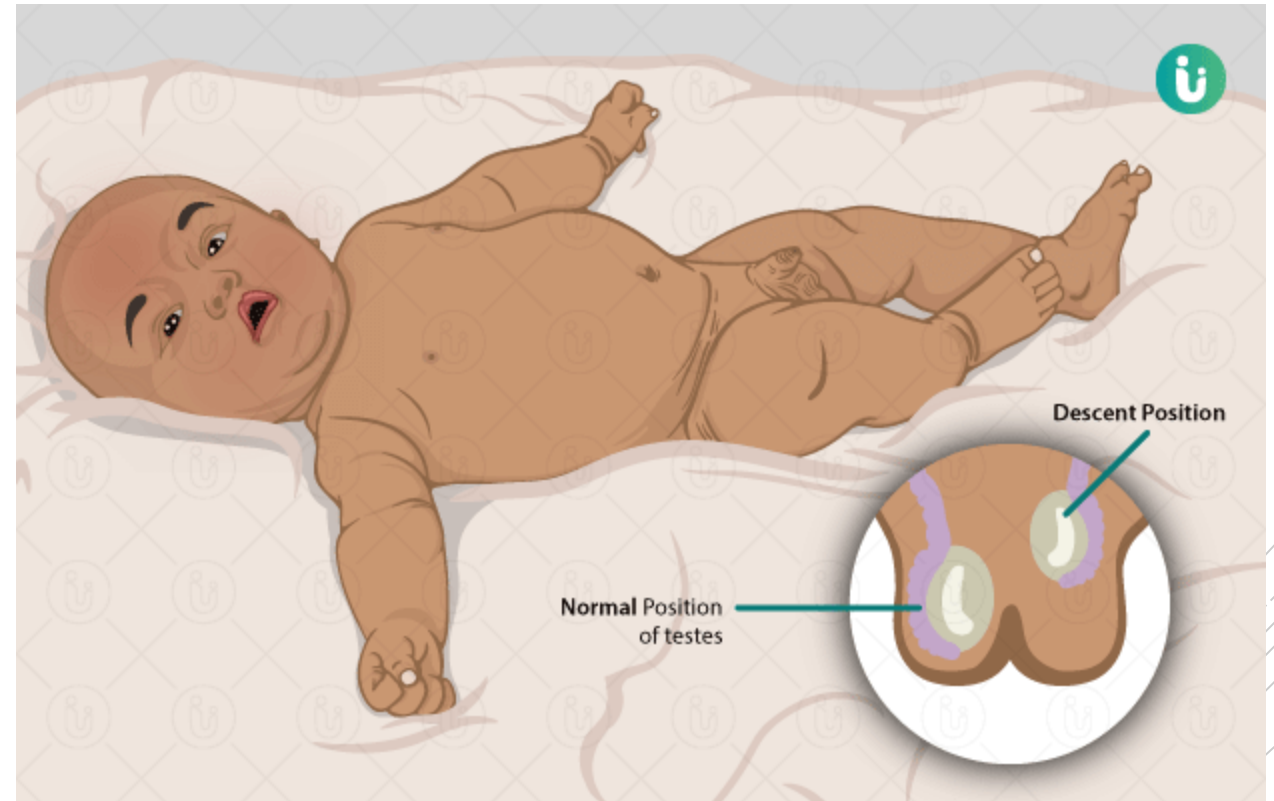


1. Cryptorchidism

- Cryptorchidism affects 1% of the male population.
- Mostly the cause is unknown.
- Bilateral in ~ 10% of affected patients
- Undescended testes may become atrophic → if bilateral → sterility.
- Associated with a 3-5 fold increased risk for testicular cancer → in both testes, (including normally descended testis) suggesting that some intrinsic abnormality)

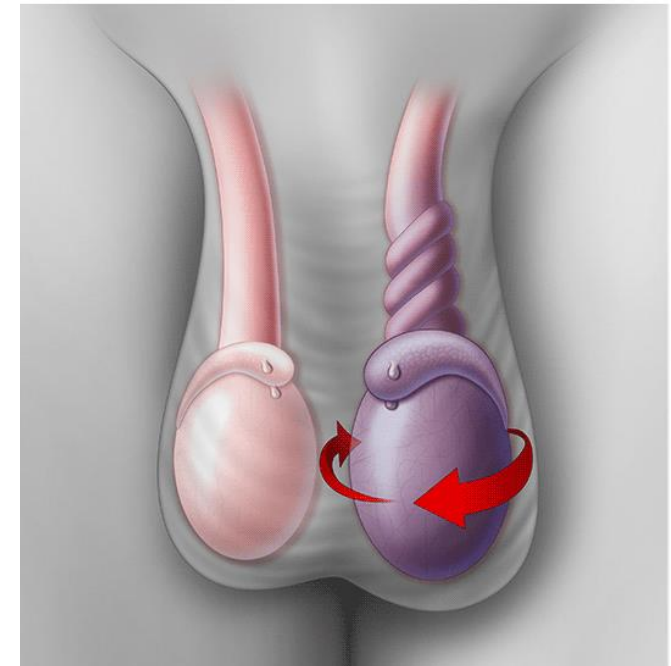
Diagnosis:

- only established with certainty after 1 year of age, particularly in premature infants, because testicular descent into the scrotum is not always complete at birth.



2. Vascular Disturbances. Torsion

- Torsion or twisting of the spermatic cord → results in obstruction of testicular venous drainage (thick-walled & more resilient arteries are left patent)
- Leads to intense vascular engorgement & infarction if not relieved.



The background of the slide features a series of thin, curved, concentric lines in a light gray color, creating a subtle circular pattern. On the left side, there is a large red speech bubble with a white outline. Inside the speech bubble, the word "types" is written in a white, lowercase, sans-serif font. The speech bubble has a small tail pointing towards the bottom right.

types

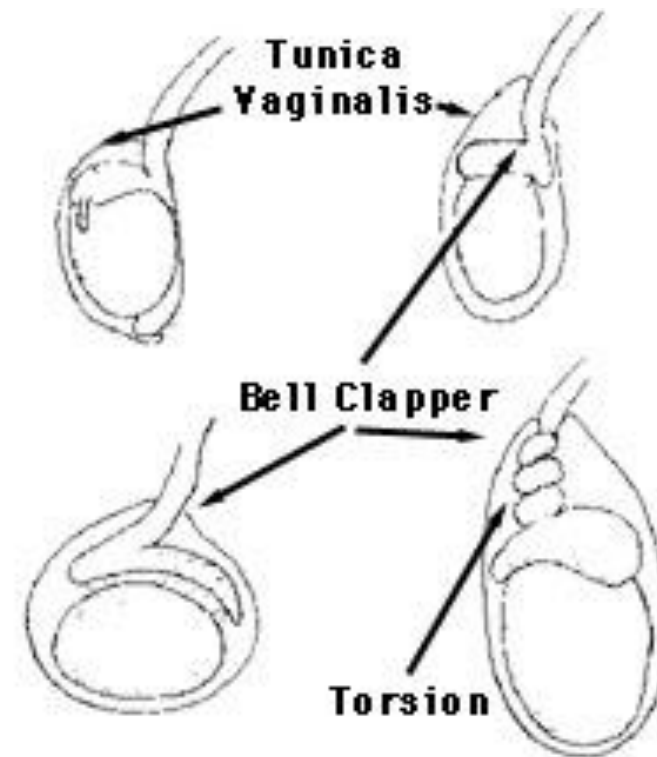
- Two types:
- Neonatal torsion :
 - occurs in utero or shortly after birth. No associated anatomic defect is present.
- Adult torsion.

Adult Torsion

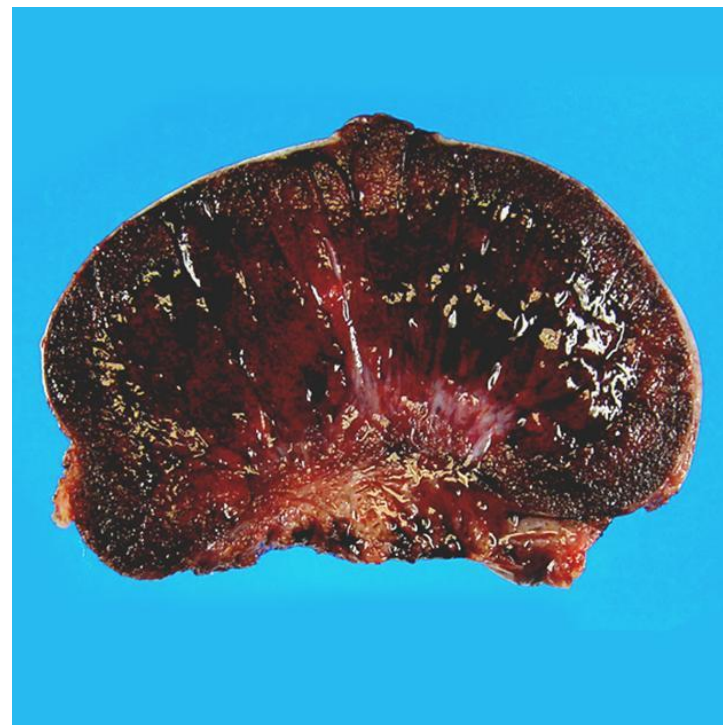
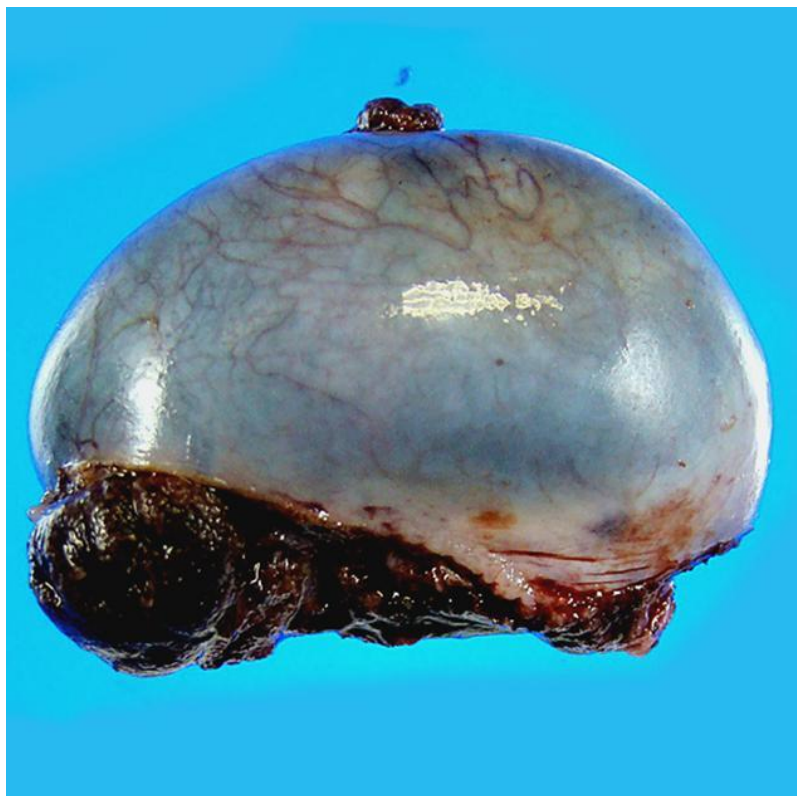
- Surgical emergency due to twisting of the testicle around the spermatic cord or vascular pedicle attachments .
- Mostly under 18 years old.
- Usually patient presented with Unilateral scrotal pain, nausea and vomiting.

pathogenesis

- In contrast with neonatal torsion, it results from a bilateral congenital anomaly; testis is abnormally anchored in the scrotal sac, leading to ↑ mobility (bell clapper abnormality).

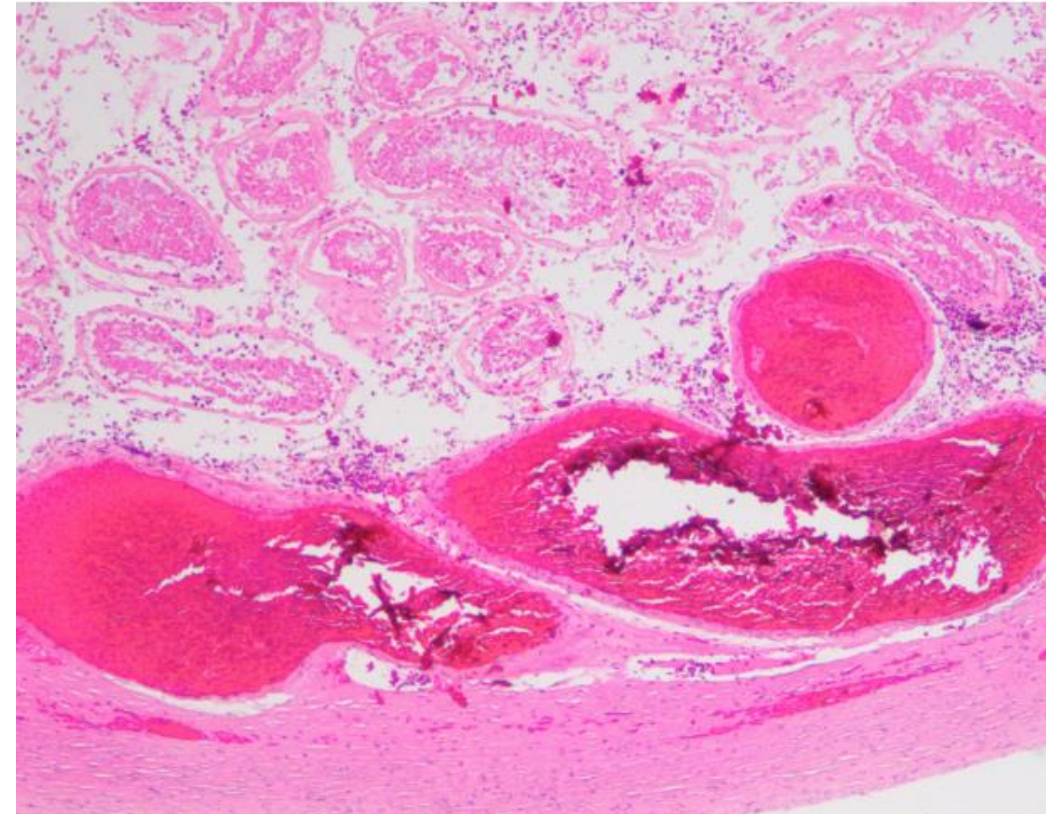


Testicular torsion



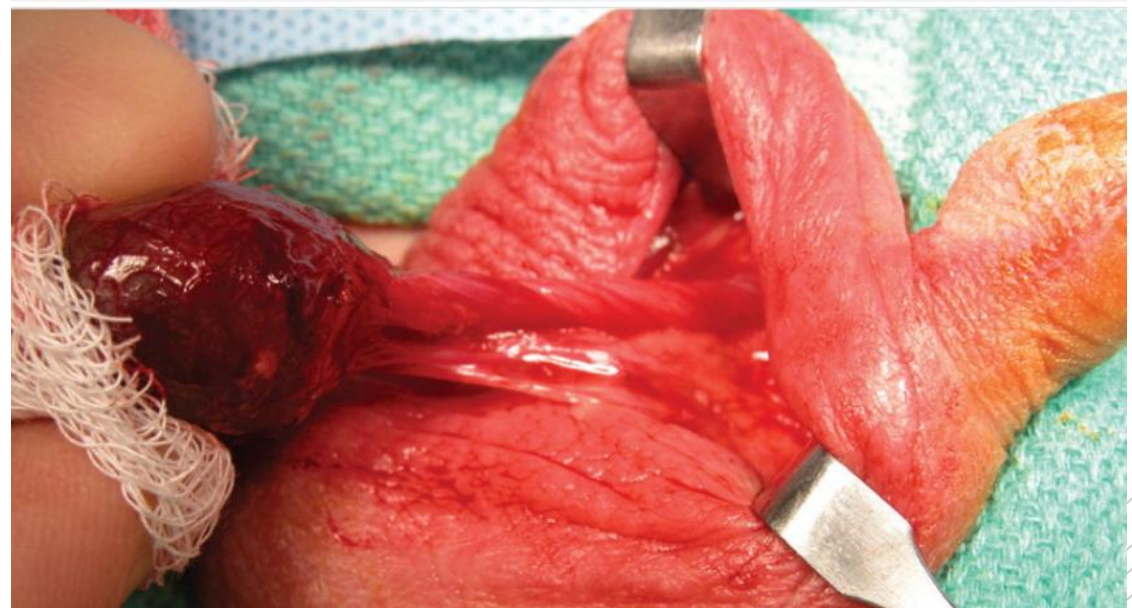
Microscopic

- ❖ Damaged blood vessels with coagulative necrosis



Treatment

- If explored surgically & the cord is manually untwisted within ~ 6 hours, the testis will likely remain viable.
- To prevent the catastrophic occurrence of another torsion in contralateral testis , unaffected testis is surgically fixed within the scrotum (orchiopexy).



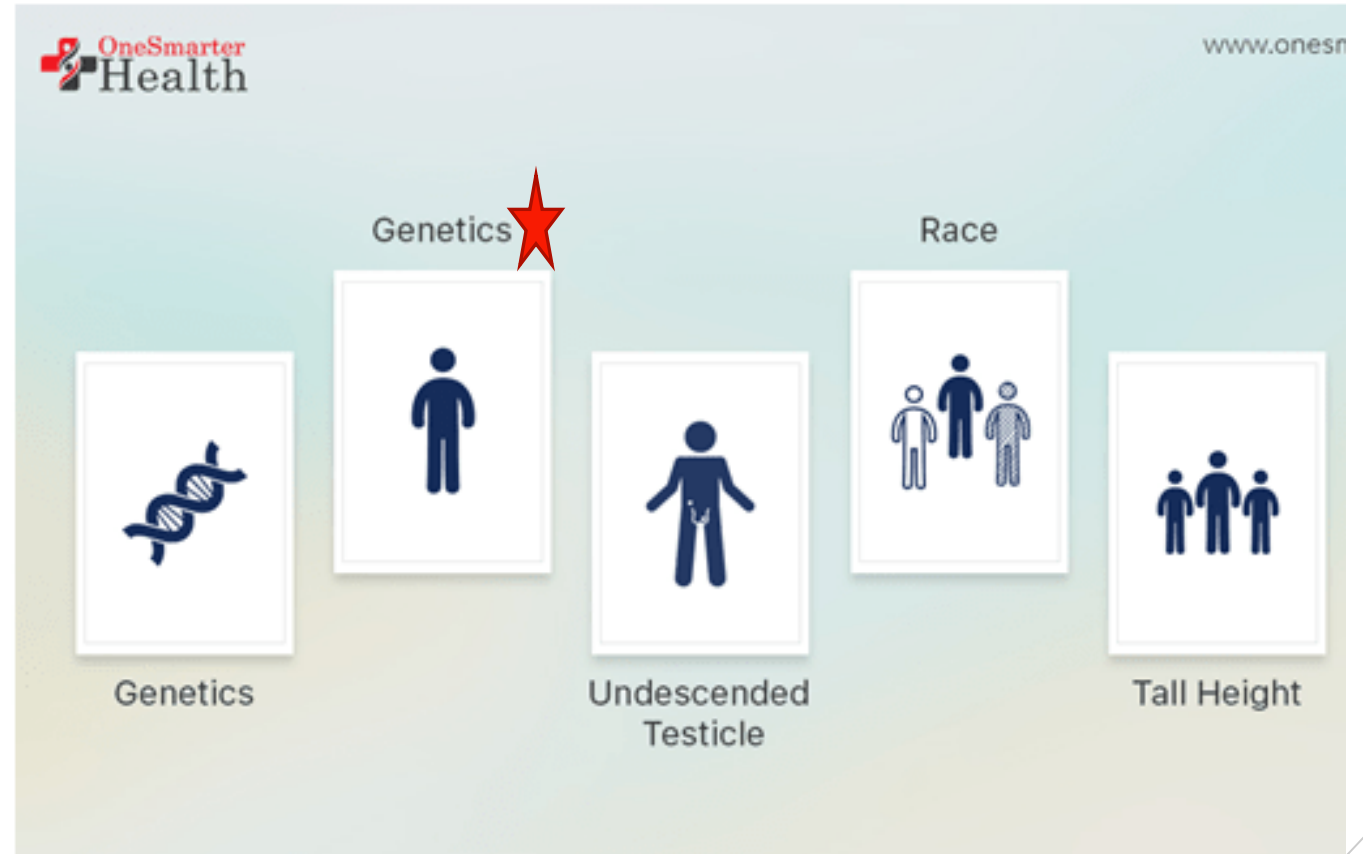
3. Neoplasms

- In the 15-34-year-old age group, they are the most common tumors in men (peak in incidence).
- Heterogeneous groups include:
 - ✓ Germ cell tumors: 95%, all are malignant.
 - ✓ Sex cord–stromal tumors: uncommon, usually benign, & derived from Sertoli or Leydig cells.
- The cause of testicular neoplasms is poorly understood.

Risk factors

isochromosome 12 i(12p)

Intersex syndromes



Testicular tumor

Germ cell tumor (95%)

Non germ cell tumor (5%)

Seminoma

Non Seminomatous

Sex cord- stromal

Others

- Classical (85%)
- Spermatocytic (5%)
- Anaplastic (10%)

- Embryonal carcinoma
- Yolk-sac tumor
(endodermal sinus tumor)
- Teratoma
- Choriocarcinoma

- Sertoli's cell tumor
- Leydig's cell tumor

- Metastases
- Lymphoma

Clinical features

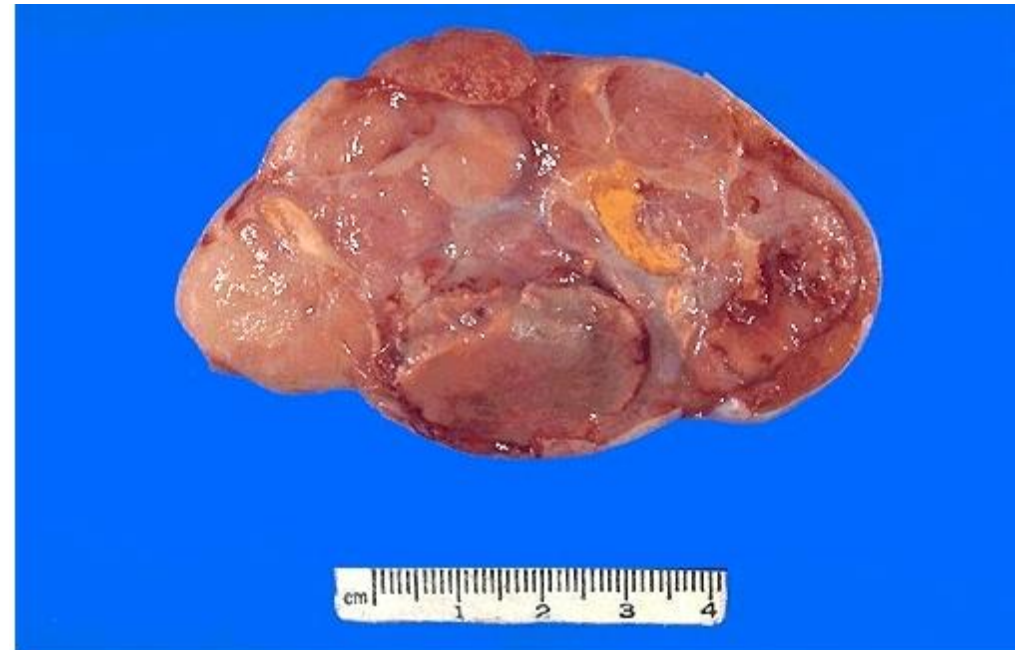- Presentation: mostly as a painless testicular mass.
- Biopsy of a testicular neoplasm is associated with a risk of tumor spillage (contraindicated).
- Standard management of a solid testicular mass is radical orchiectomy, based on the presumption of malignancy.

1. Seminoma

- Third decade of life – never in infants.
- Histologically identical tumors called dysgerminomas , in the ovary, and germinomas of the CNS.
- Presentation: progressive painless enlargement of the testis.

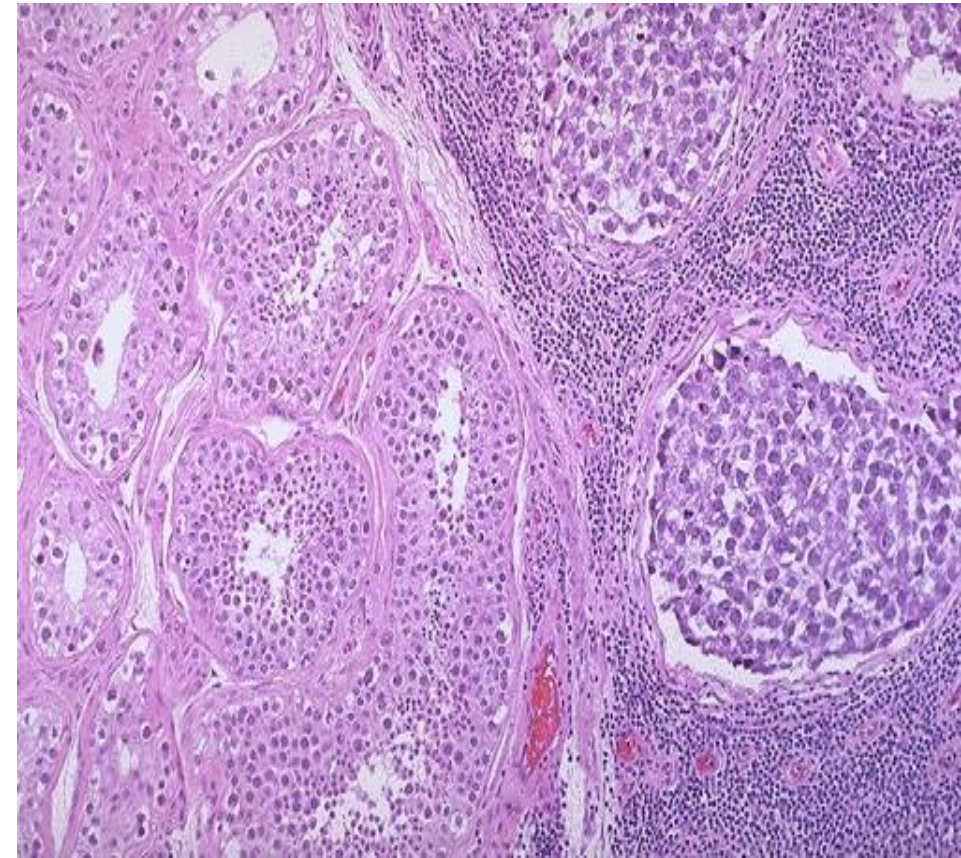
morphology

Gross: soft, well-demarcated gray-white, usually w/o hemorrhage



Microscopic

- Large, uniform cells with clear, glycogen-rich cytoplasm, round nuclei, and conspicuous nucleoli.
- Intervening fibrous septa with dense lymphocytic infiltrate.
- Granulomatous reaction & syncytiotrophoblasts (15%).

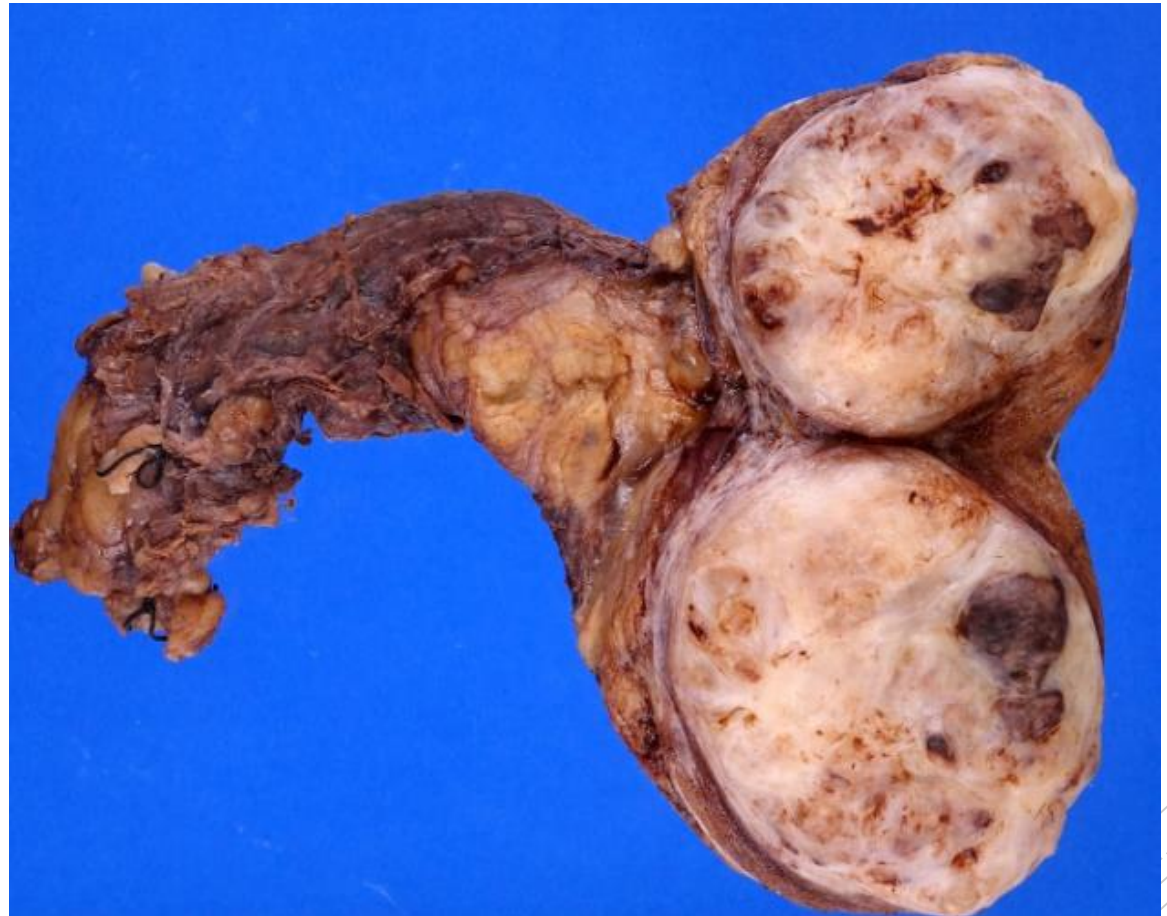

2. Embryonal carcinoma

- malignant germ cell tumor (GCT) resembling undifferentiated stem cells during embryonic development.
- Second most common type of testicular pure GCT
- Average age of presentation 25 - 35 years old, ~10 years younger than seminoma
- Can occur in Anterior mediastinum and retroperitoneum

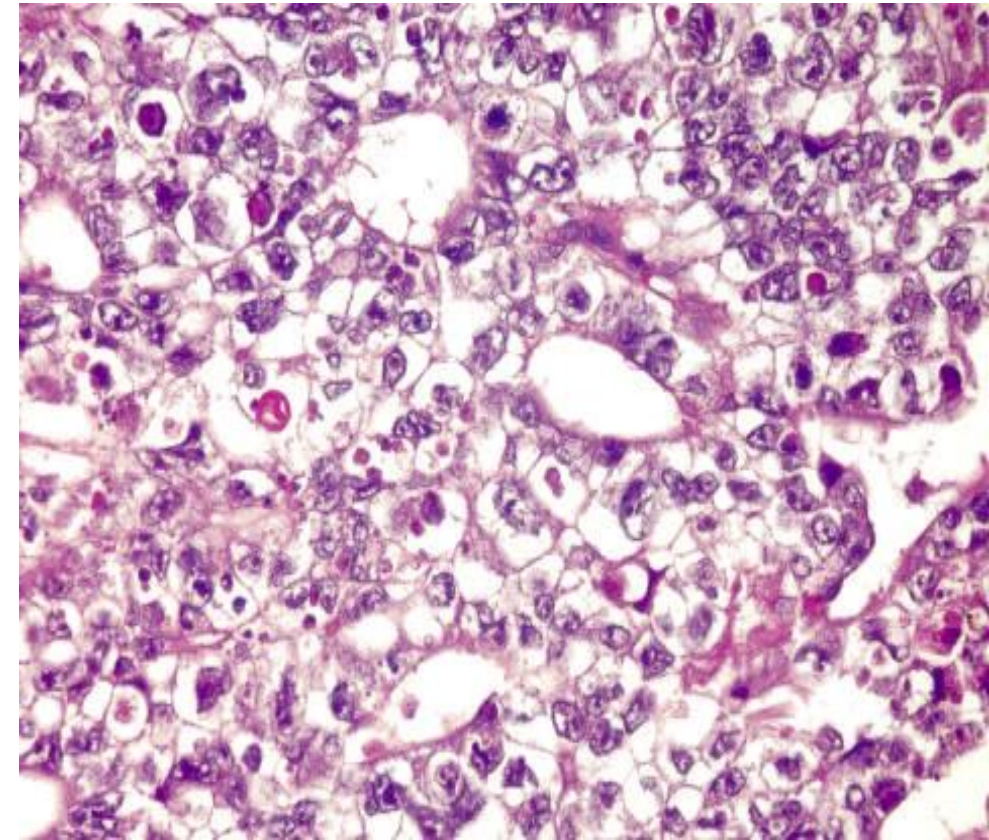
Morphology

- **Gross:** ill-defined, invasive masses containing foci of hemorrhage and necrosis.



Microscopic

- large cells with basophilic cytoplasm, they are undifferentiated & may form primitive glands.

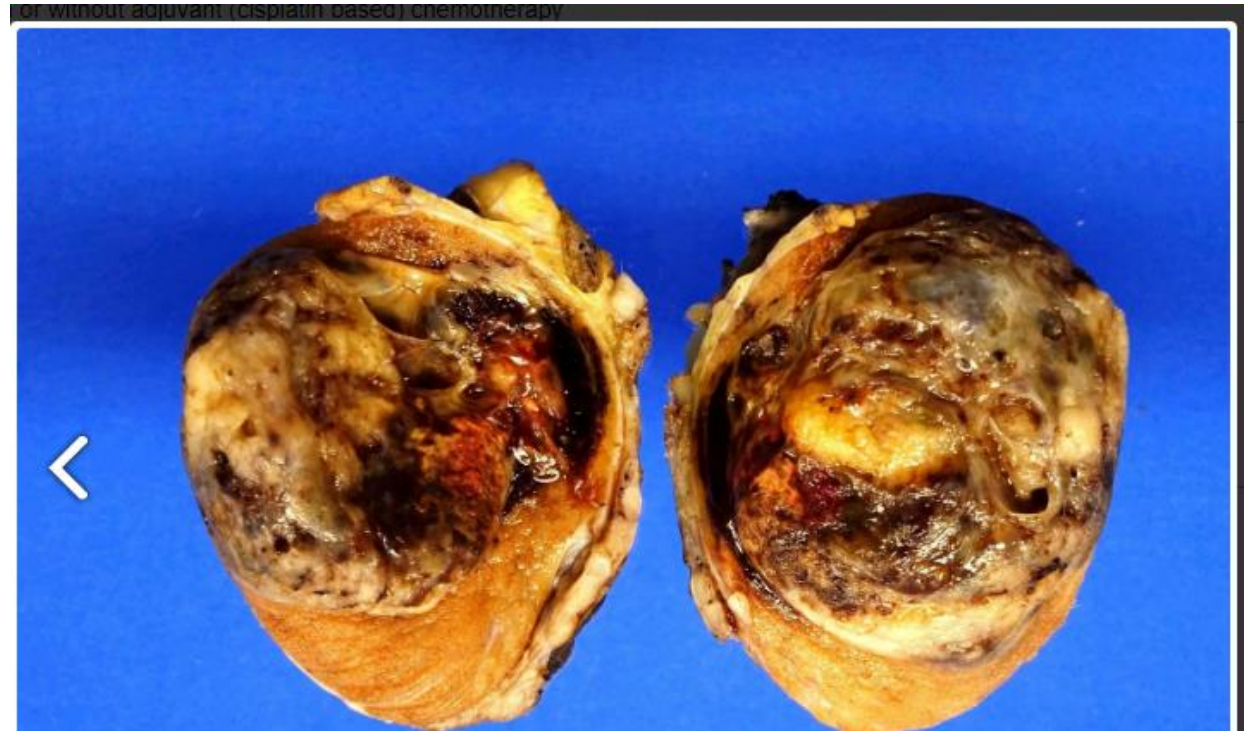

3. Yolk sac tumor

- The most common primary testicular neoplasm in children younger than 3 years old.
- In this age group, it has a very good prognosis.
- In adults, yolk sac tumors most often are seen admixed with embryonal carcinoma (incidence of yolk sac elements is 80% in mixed).

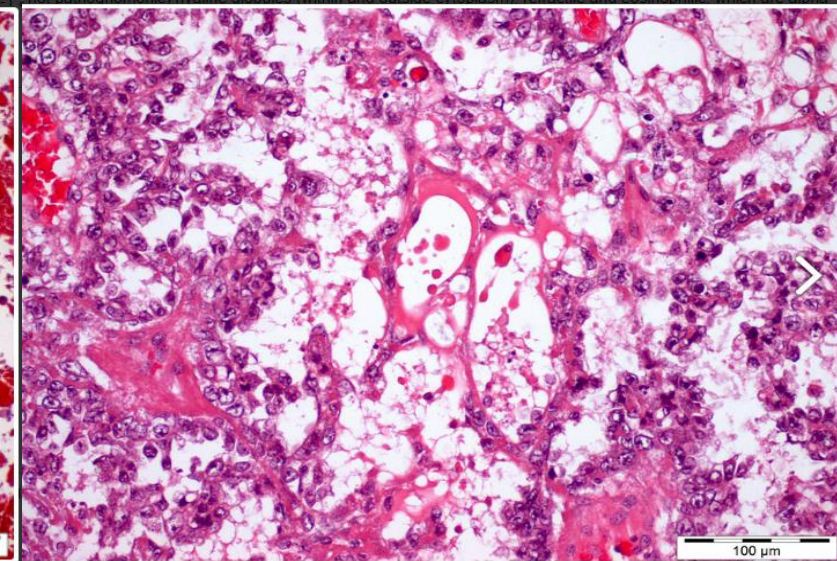
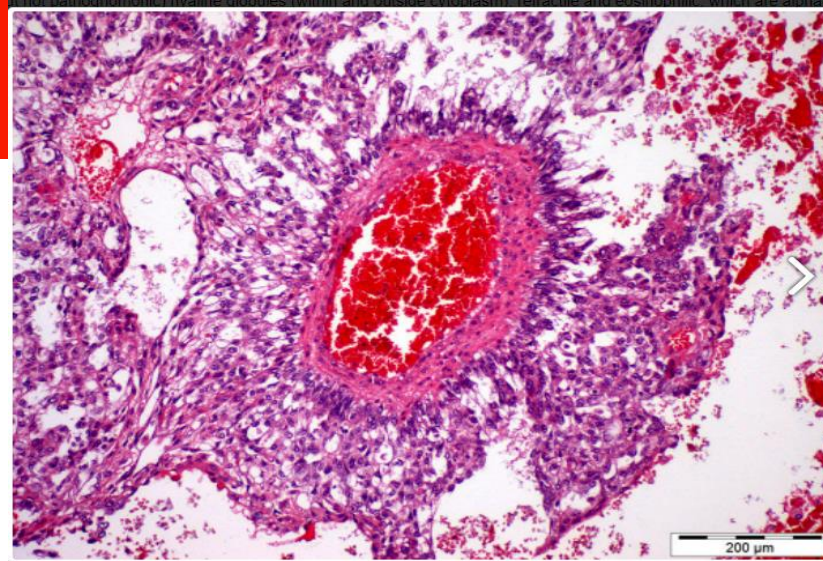
Morphology

- Poorly circumscribed, nonencapsulated, predominantly solid. Gray to white to yellow to tan, gelatinous surface



Microscopic

- ❑ tumor composed of low cuboidal to columnar epithelial cells that form microcysts, lacelike (reticular) patterns.
- ❑ A distinctive feature is the presence of structures resembling primitive glomeruli, the so-called Schiller-Duval bodies.
- ❑ Tumors have eosinophilic globules containing α 1-antitrypsin and alpha fetoprotein (AFP – can be detected in the serum)



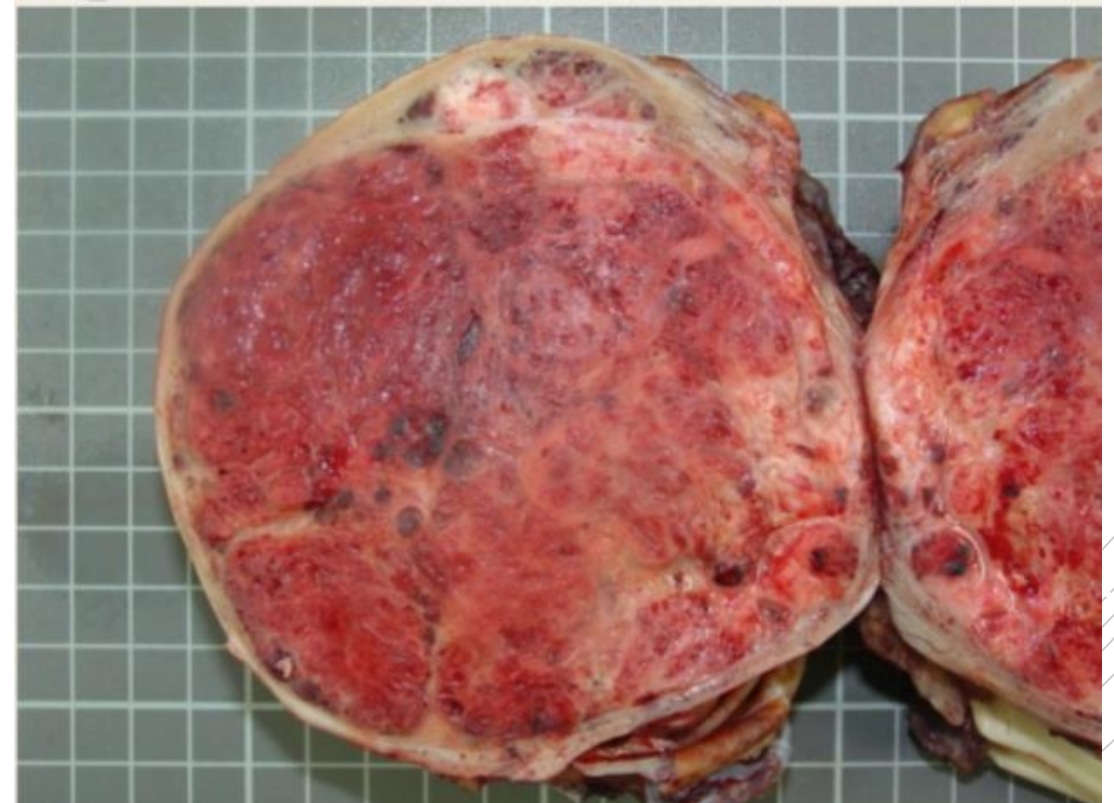4. Choriocarcinoma

- Malignant germ cell tumor composed of syncytiotrophoblast, cytotrophoblast and intermediate trophoblast cells,
- May present initially with metastases (liver, lung, mediastinum, retroperitoneum) with normal testis or small tumor but with increased serum hCG.

Morphology

❖ Gross:

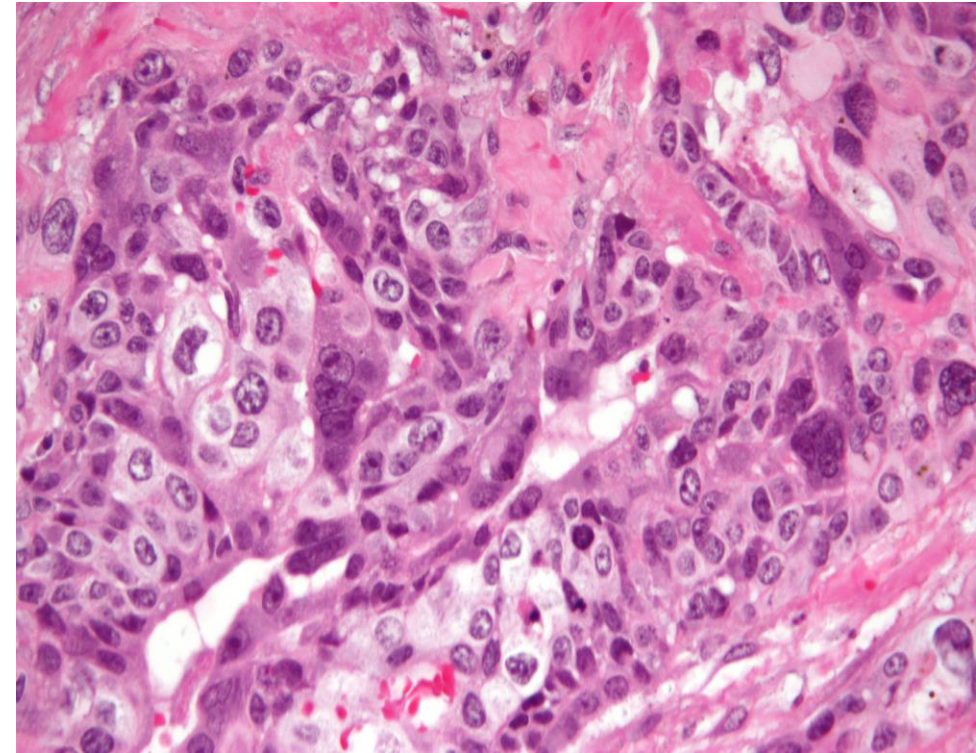
- may be small lesions, even those with extensive systemic metastases
- May show total necrosis & extensive hemorrhage



Microscopic

(1)Cytotrophoblast: Sheets of small cuboidal cells, irregularly intermingled with

- (2)Syncytiotrophoblast: large, eosinophilic cells with multiple dark, pleomorphic nuclei.



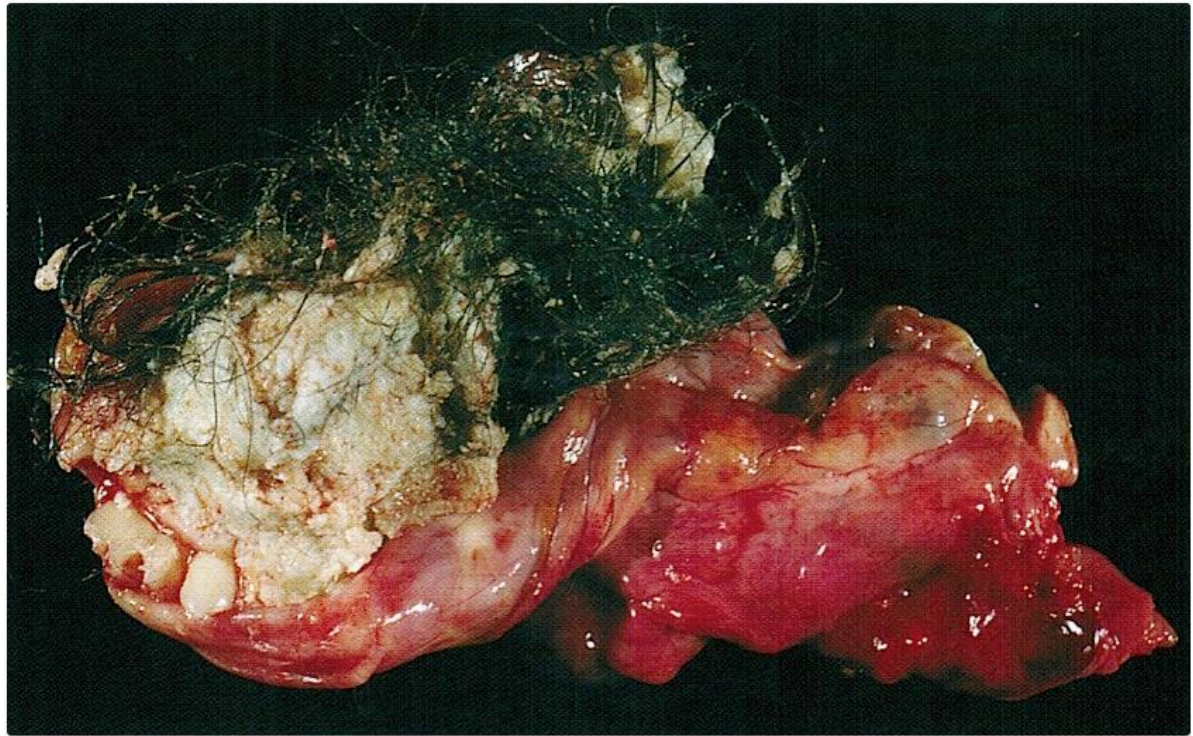
5. Teratoma

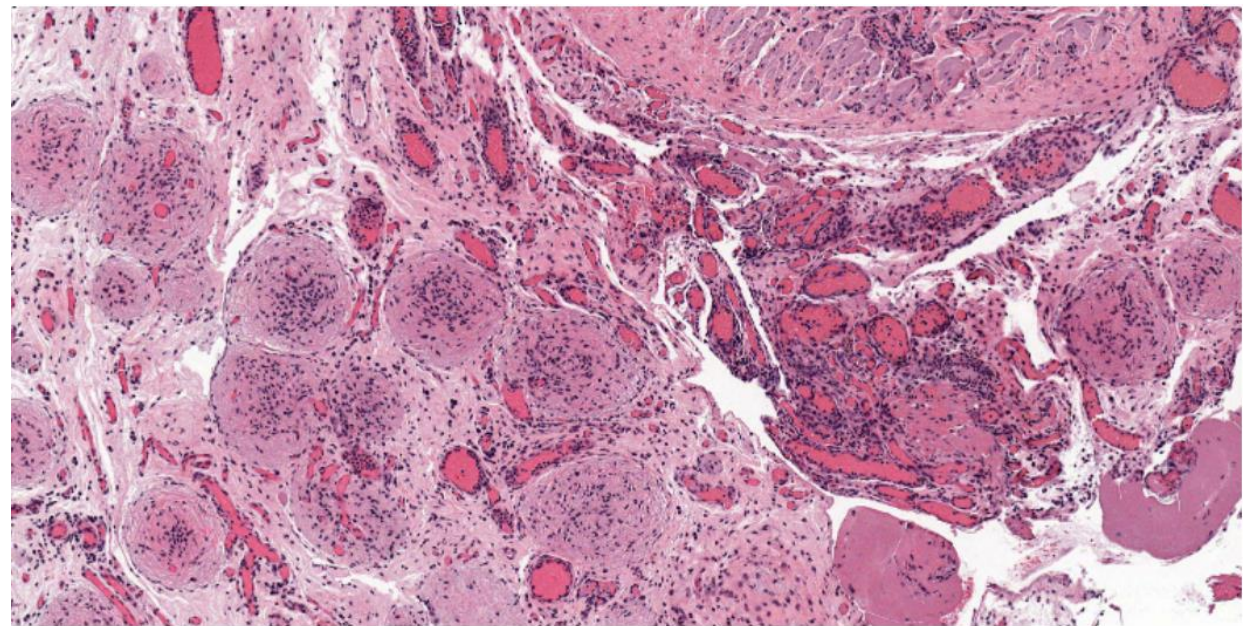
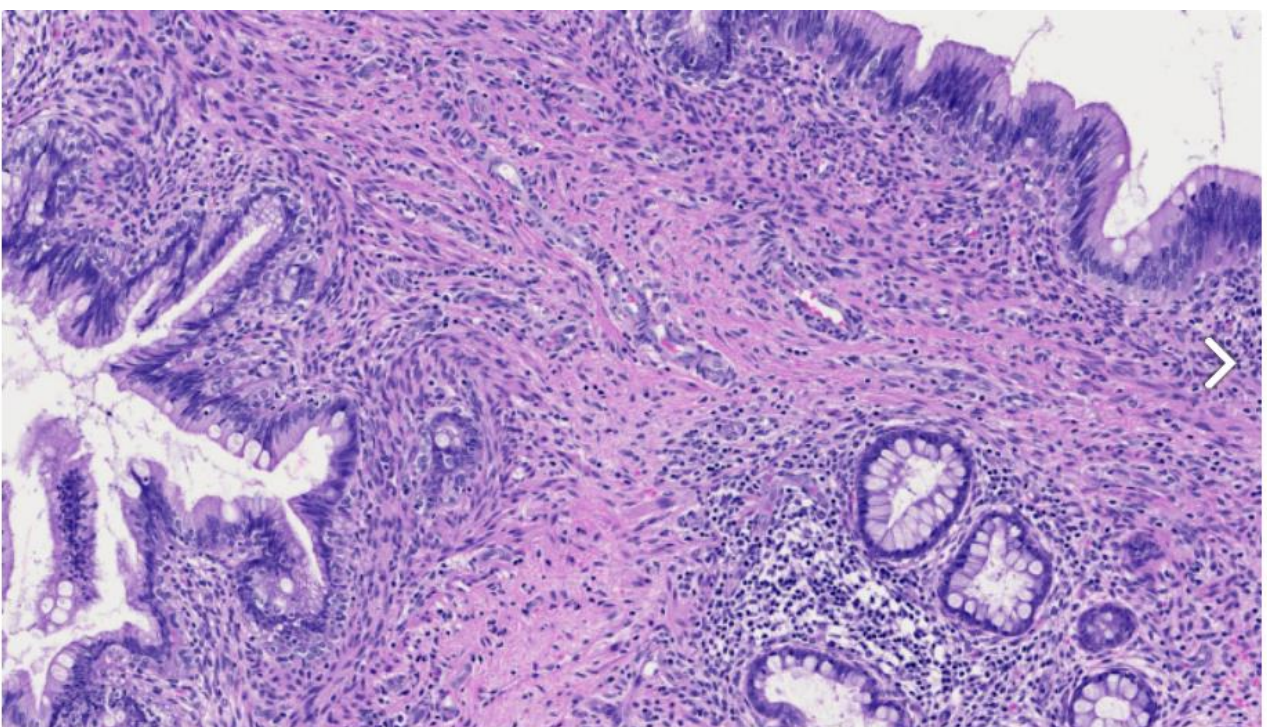
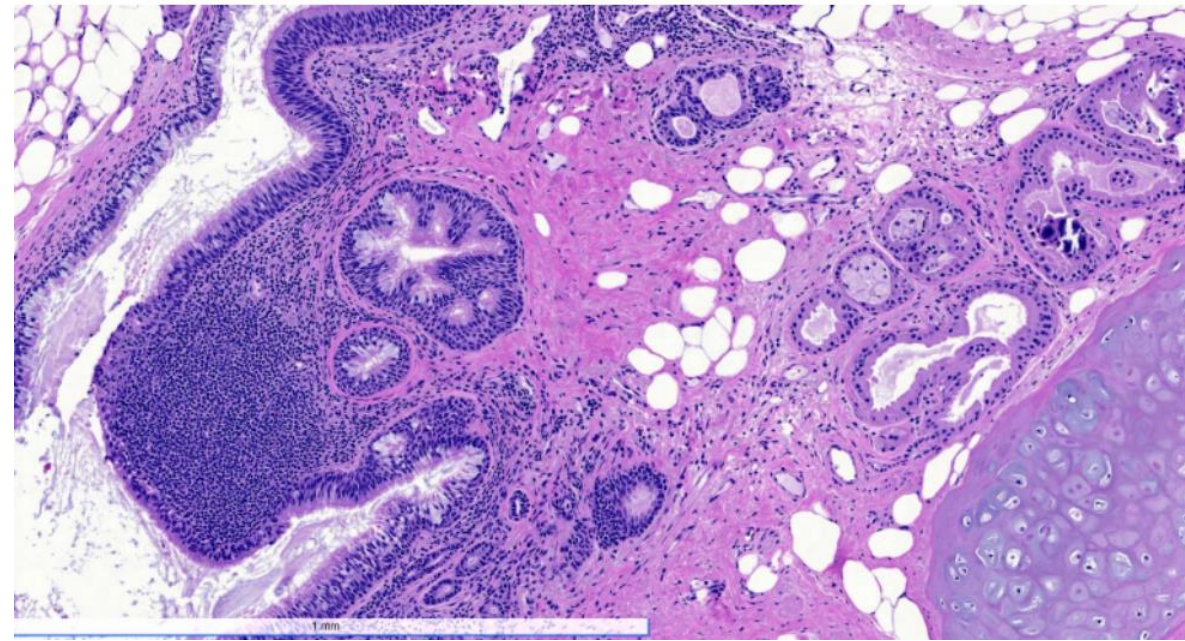
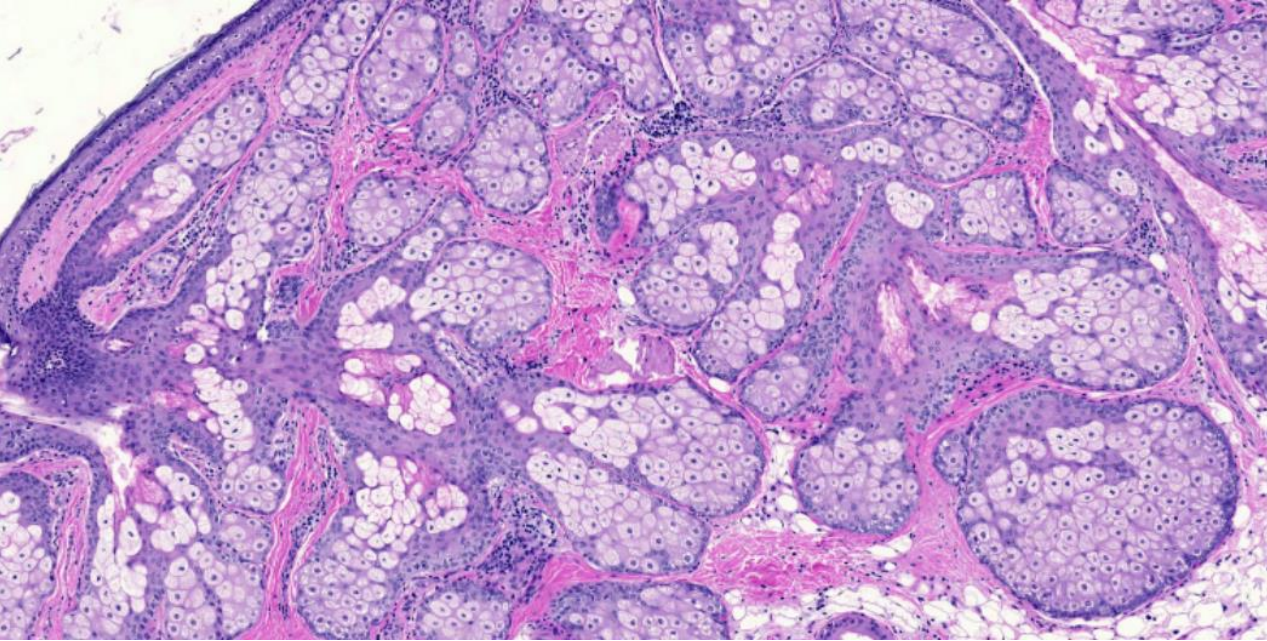
- Neoplastic germ cells differentiate along multiple somatic cell lineages.
- Pure forms of teratoma are common in infants and children , 2nd in frequency only to yolk sac tumors.
- In adults it is seen in combination with other histologic types (mixed), pure forms are rare.

Morphology

- Elements may be:
 - ❖ mature (resembling various tissues within the adult)
 - ❖ immature (sharing features with fetal or embryonal tissues).
- In prepubertal males, teratomas are benign.
- The majority of teratomas in postpubertal males are malignant whether they have mature or immature elements.

Gross





Tumor markers

- Serum tumor markers secreted by germ cell tumors is important in two ways; diagnostically & in following the response to therapy after the diagnosis:
- ✓ Human chorionic gonadotropin (hCG): always elevated in Choriocarcinoma
- ✓ Alpha fetoprotein (AFP): when elevated in testicular neoplasm , indicates a yolk sac tumor component.
- ✓ Lactate dehydrogenase (LDH): correlate with the tumor burden.

GOOD
LUCK!