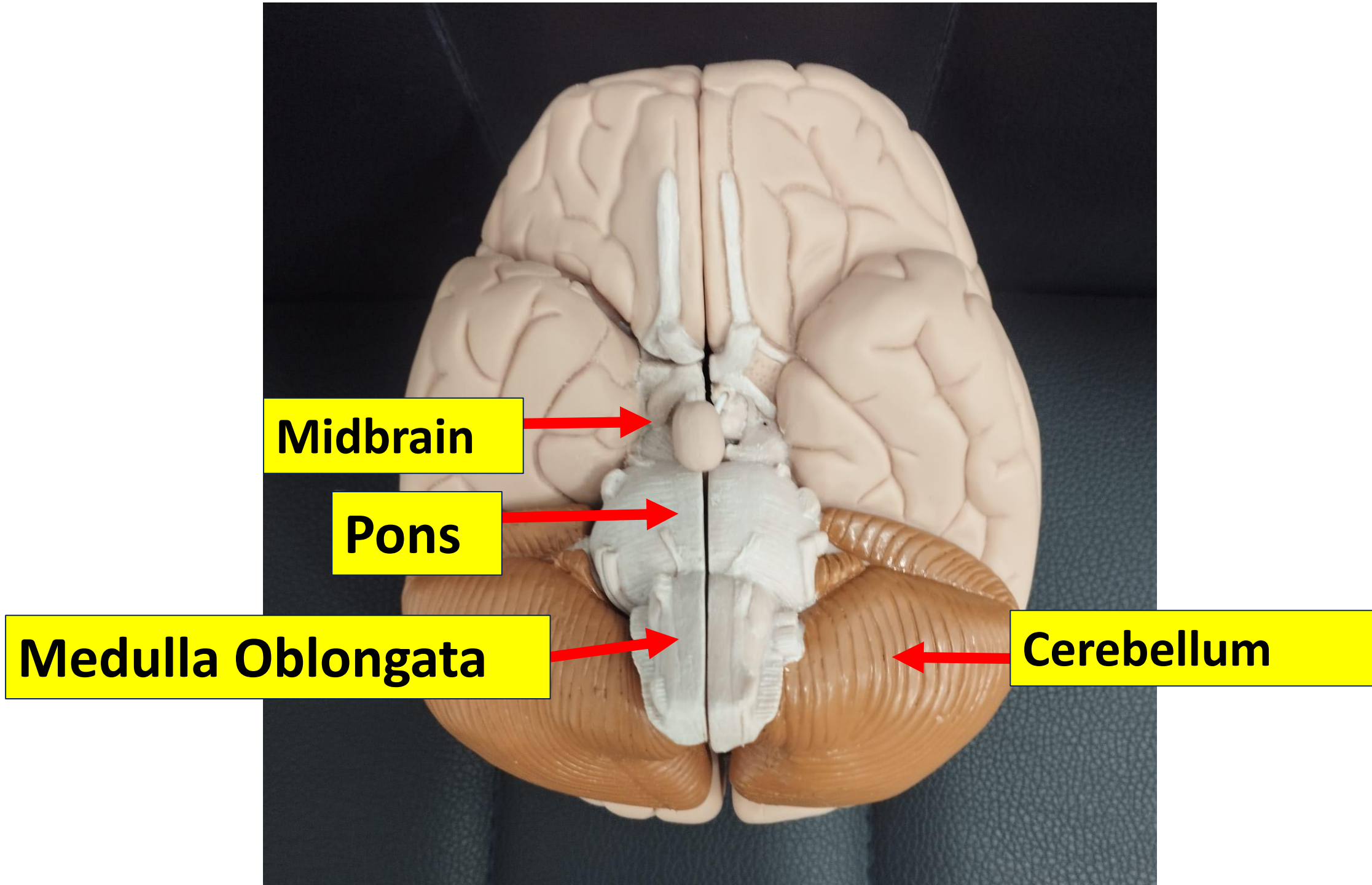


Neuroanatomy practical-2

Brain stem external features

Dr. Rasha Abdelaziz Abdellatif

**Associate professor of human anatomy and
Embryology – Mutah university**

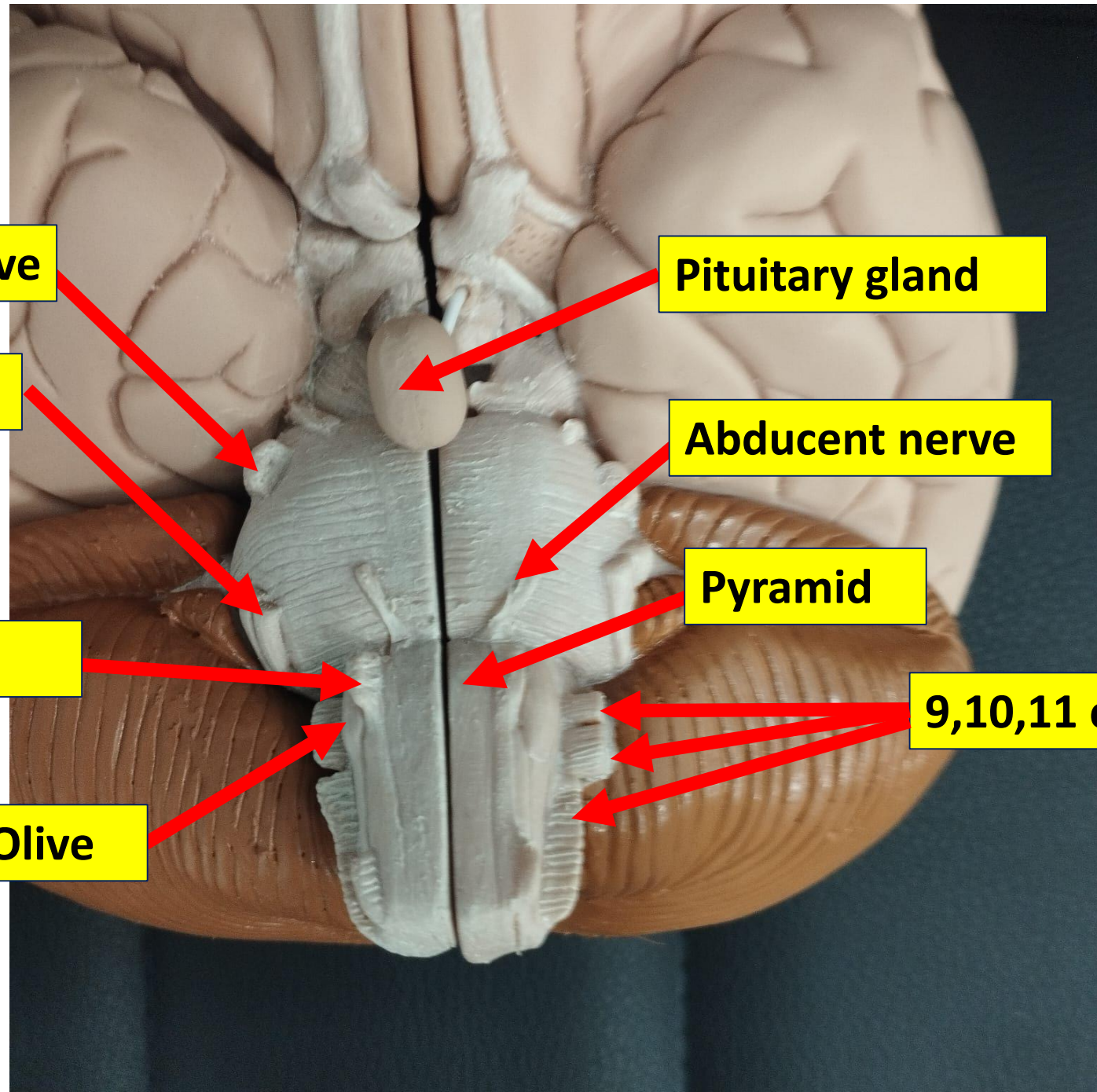


Midbrain

Pons

Medulla Oblongata

Cerebellum



Trigeminal nerve

Pituitary gland

Facial nerve

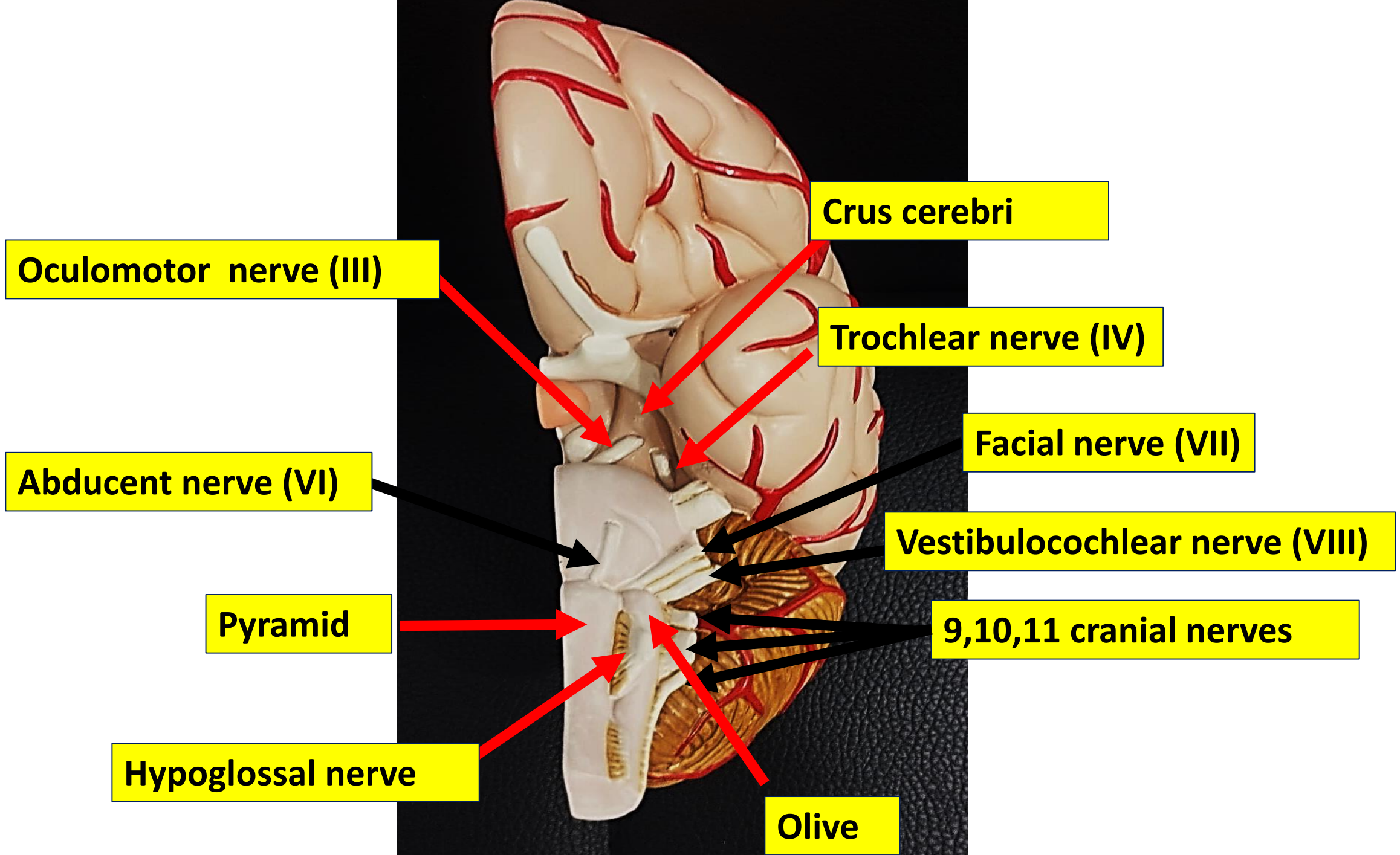
Abducent nerve

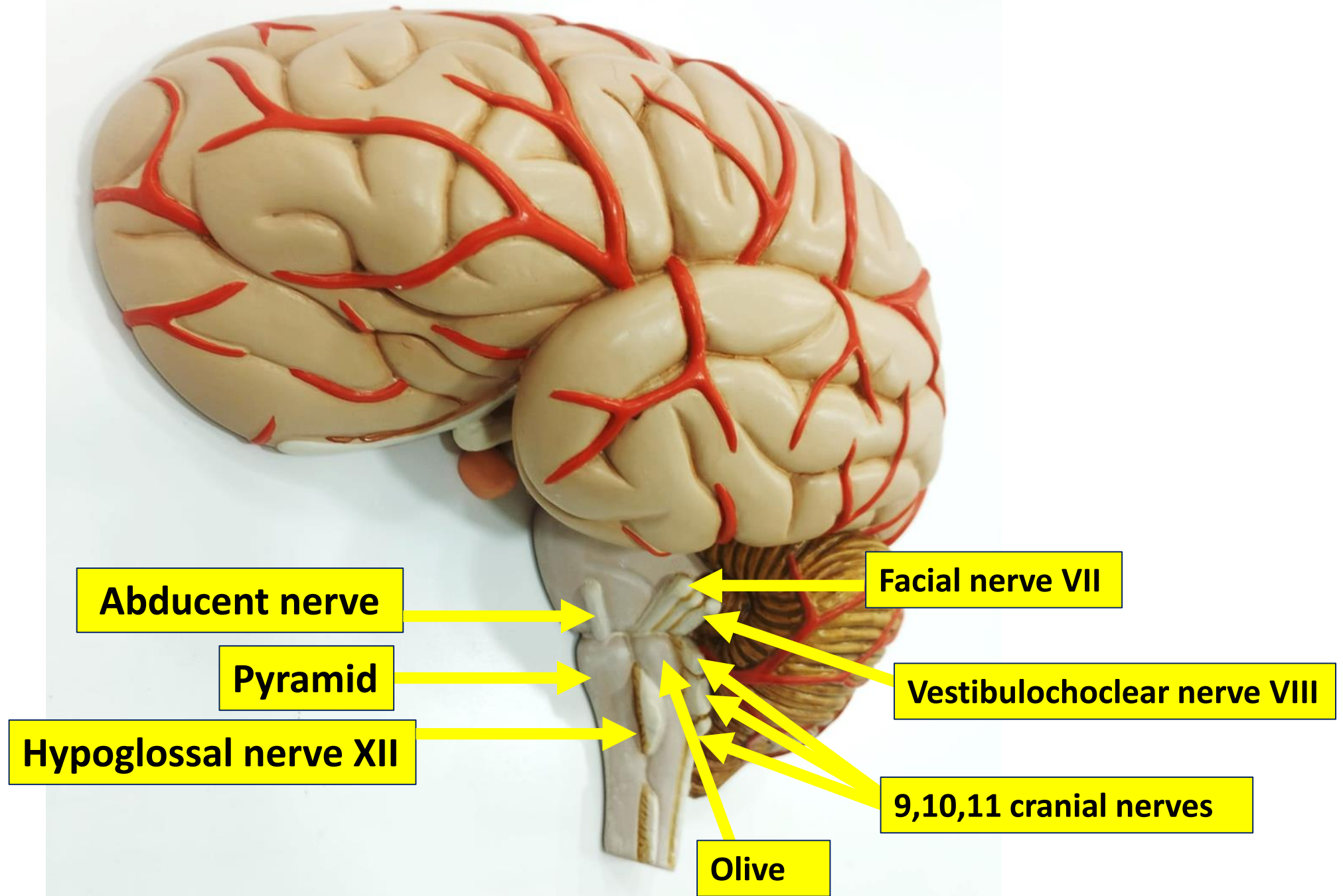
Hypoglossal nerve

Pyramid

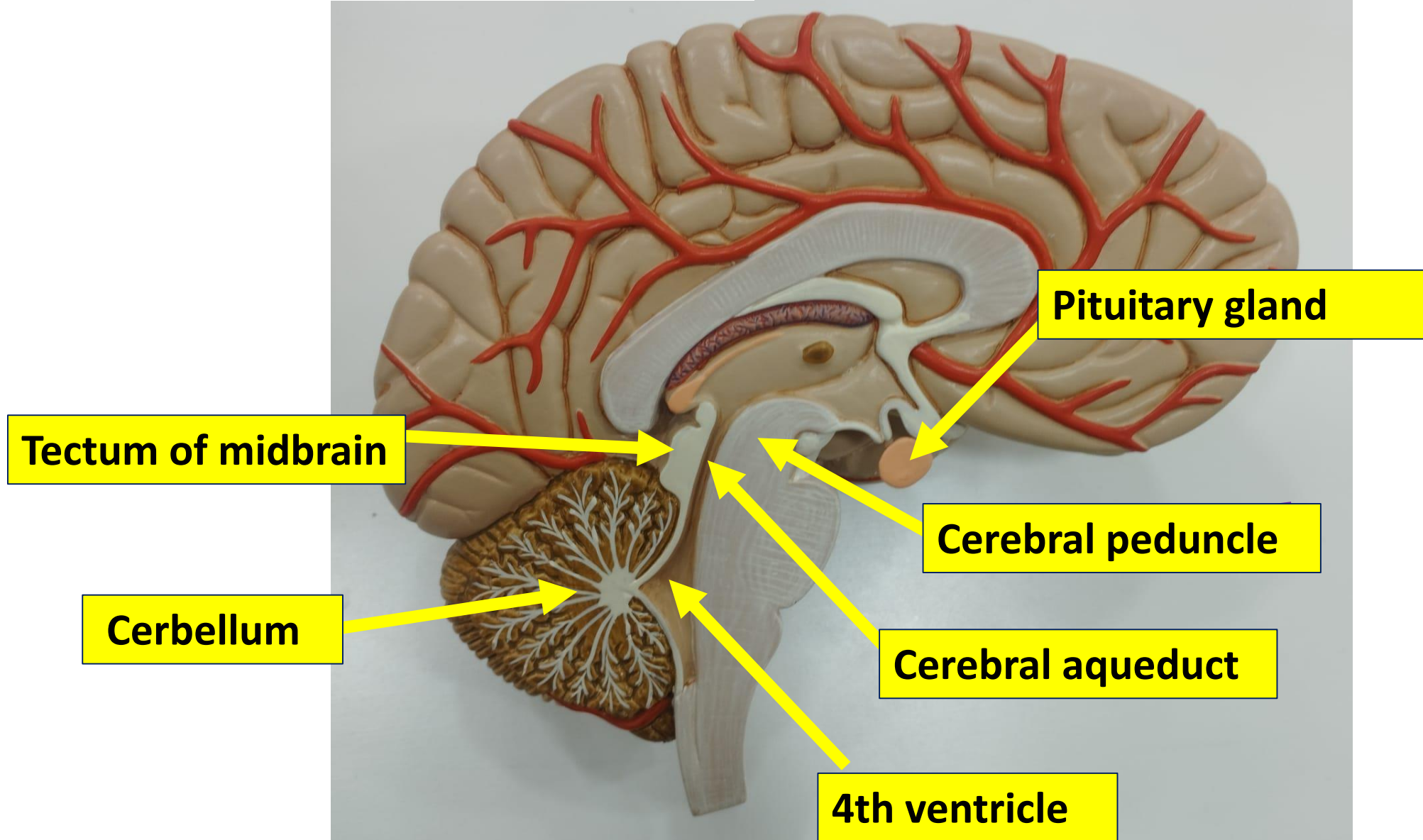
Olive

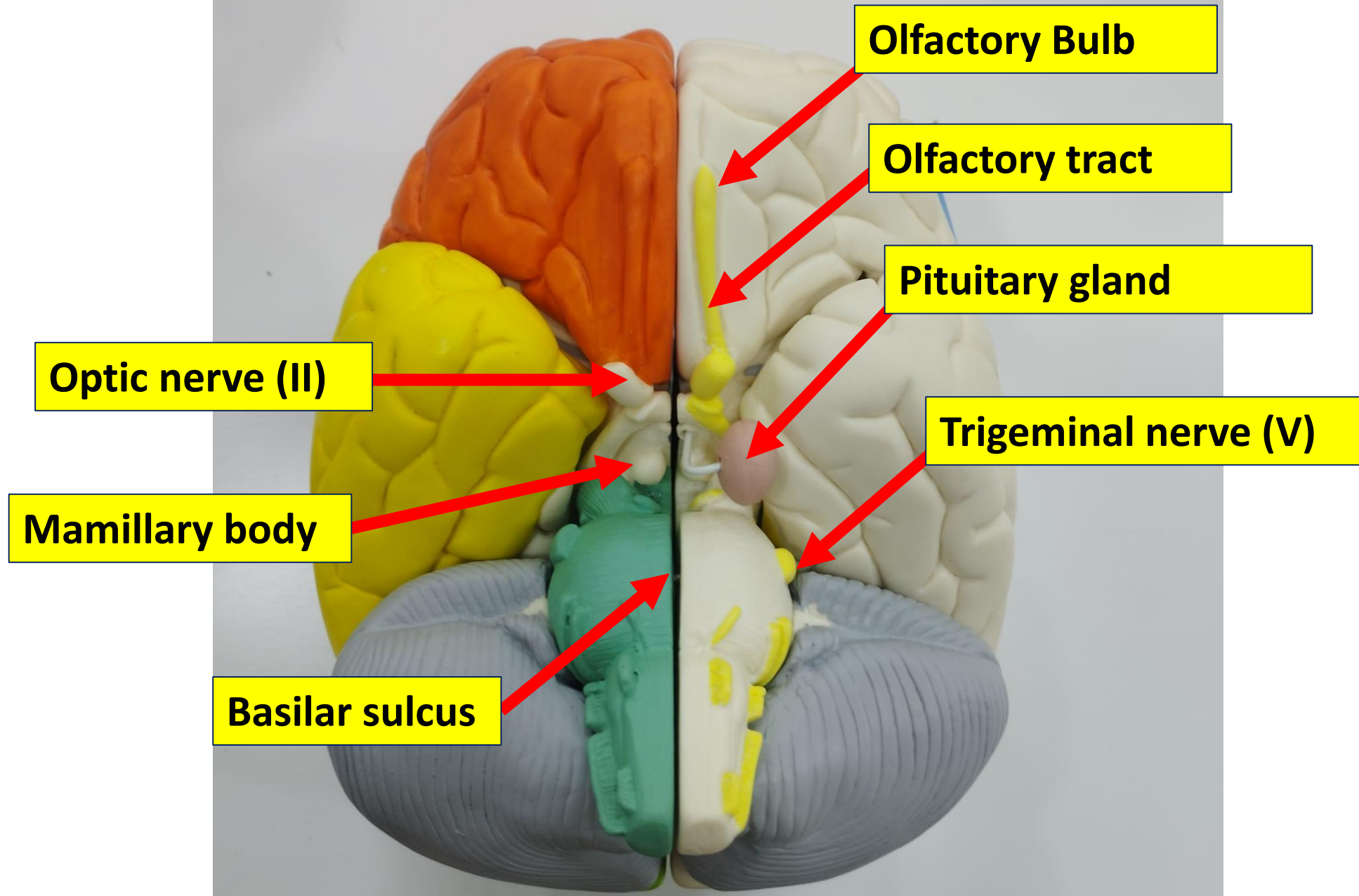
9,10,11 cranial nerves





Midsagittal view





Olfactory Bulb

Olfactory tract

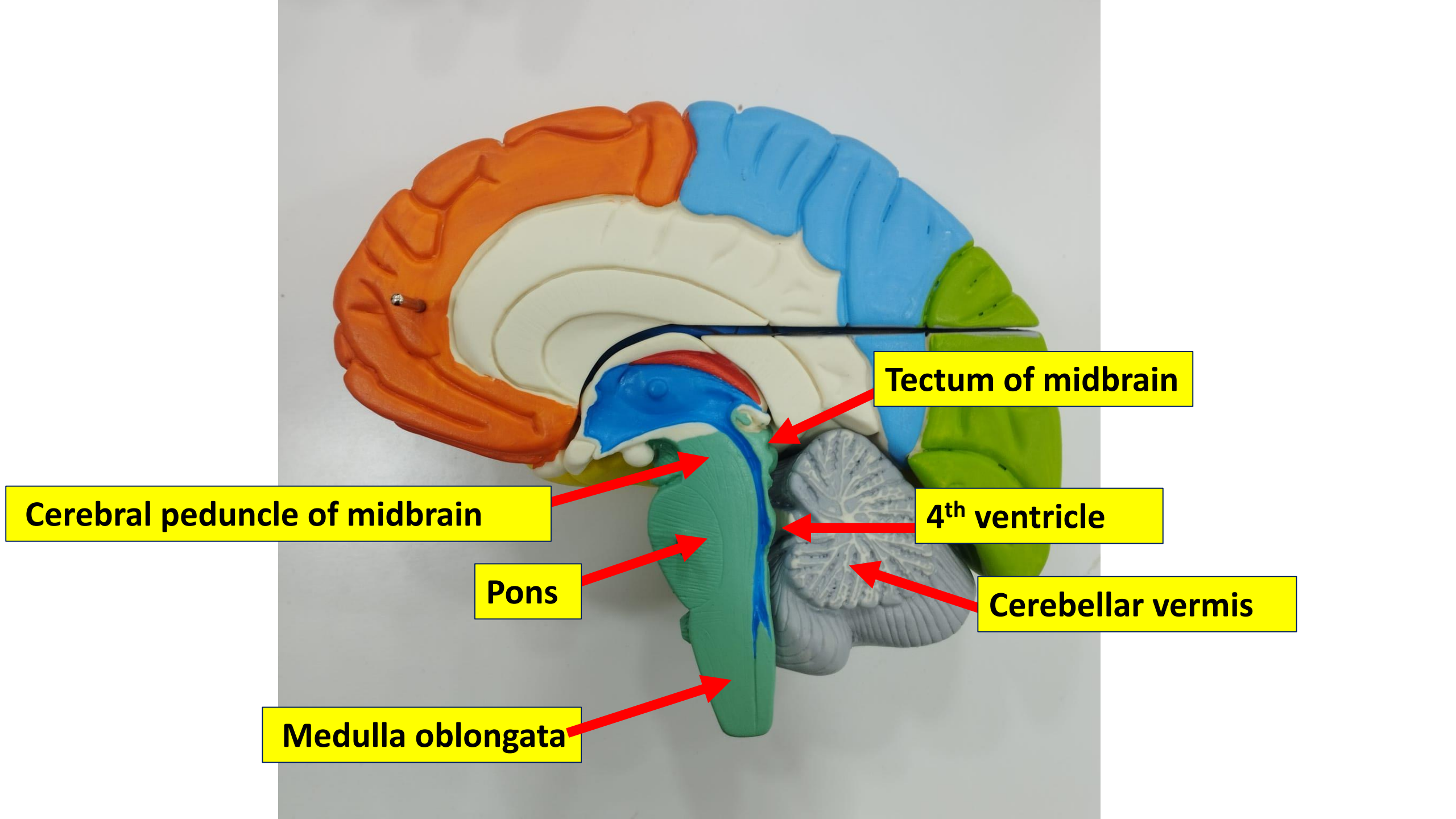
Pituitary gland

Trigeminal nerve (V)

Optic nerve (II)

Mamillary body

Basilar sulcus



Cerebral peduncle of midbrain

Pons

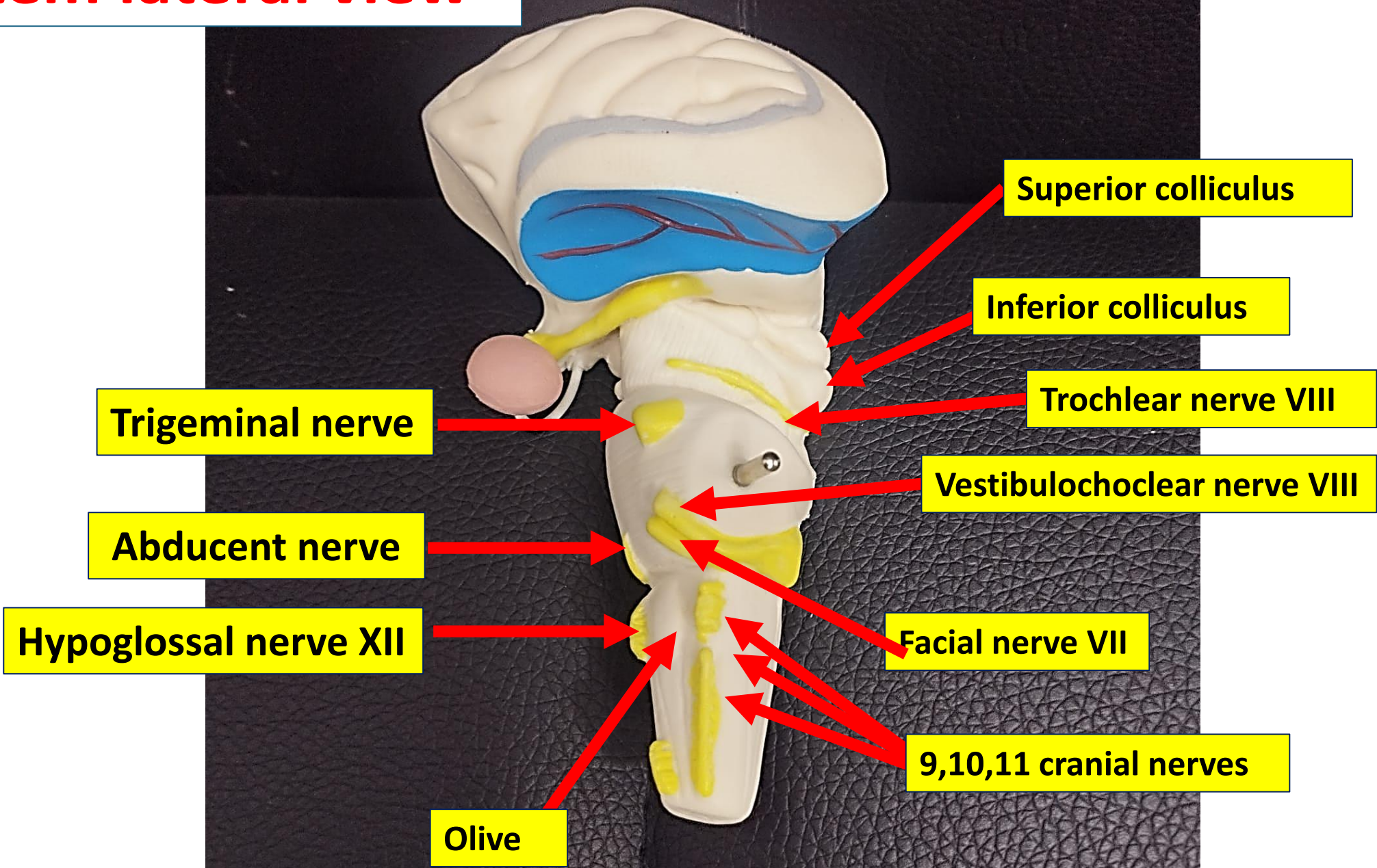
Medulla oblongata

Tectum of midbrain

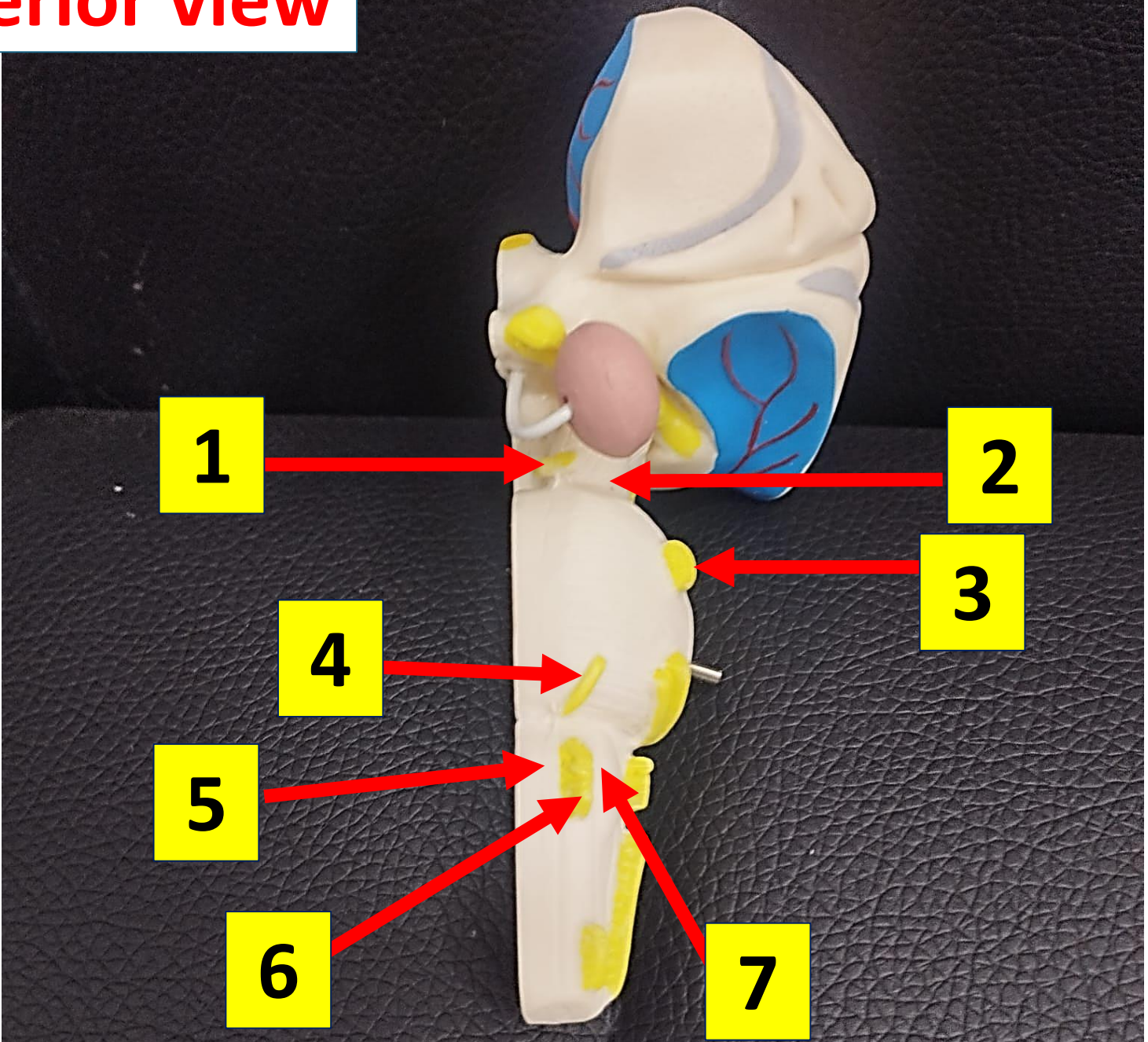
4th ventricle

Cerebellar vermis

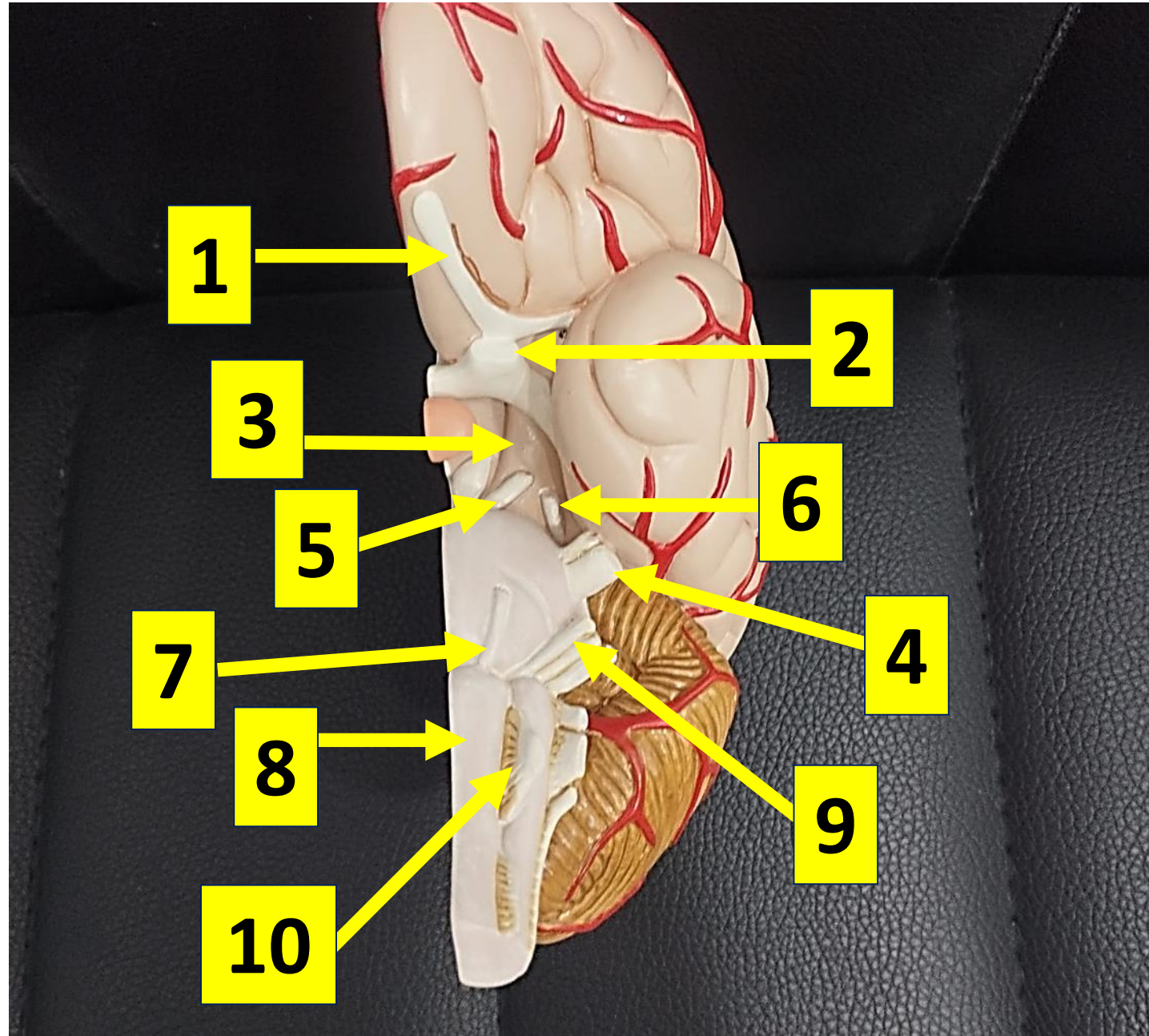
Brain stem lateral view



Brain stem Anterior view



Label the following diagram of spinal cord



THANK

YOU!

