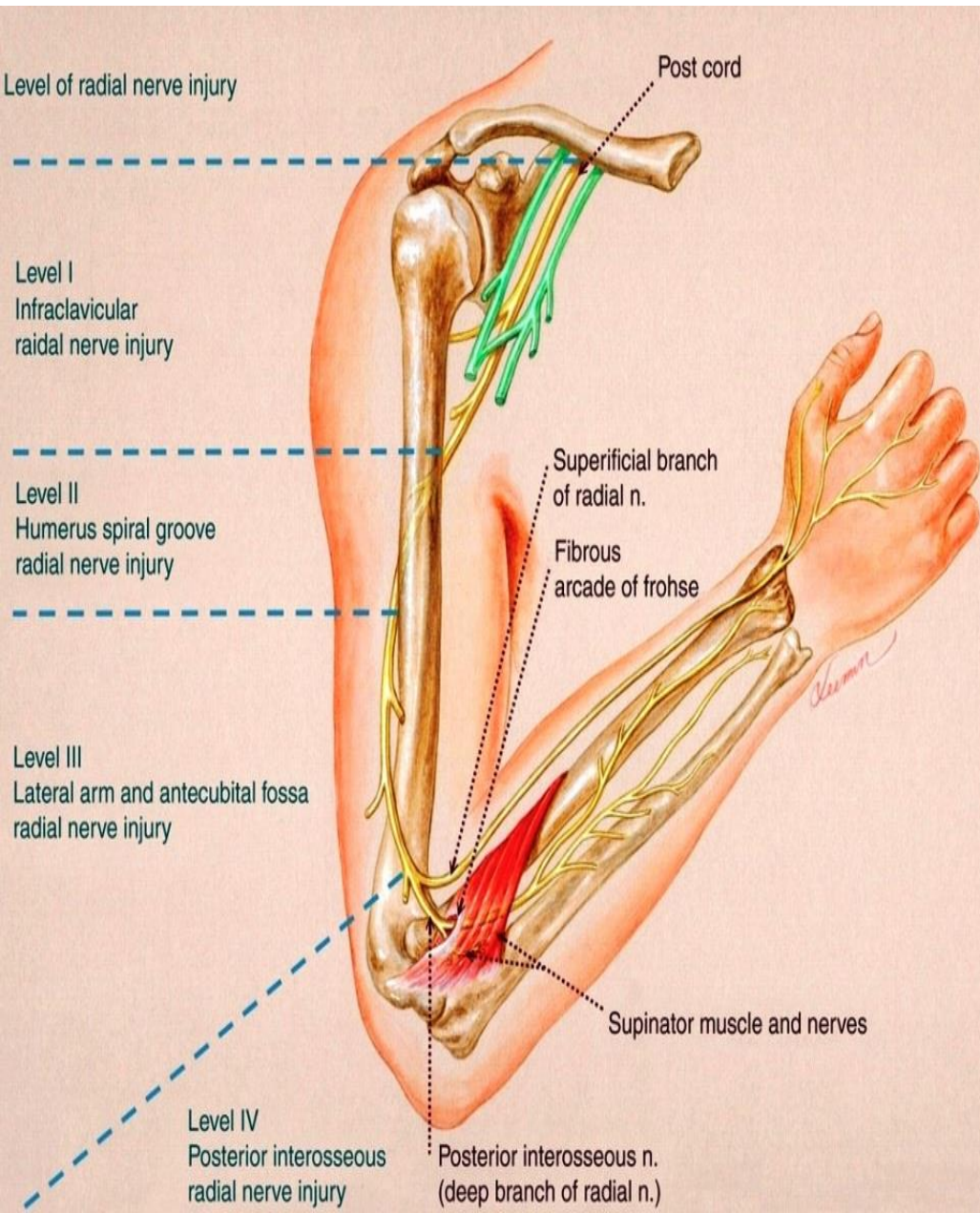


RADIAL NERVE



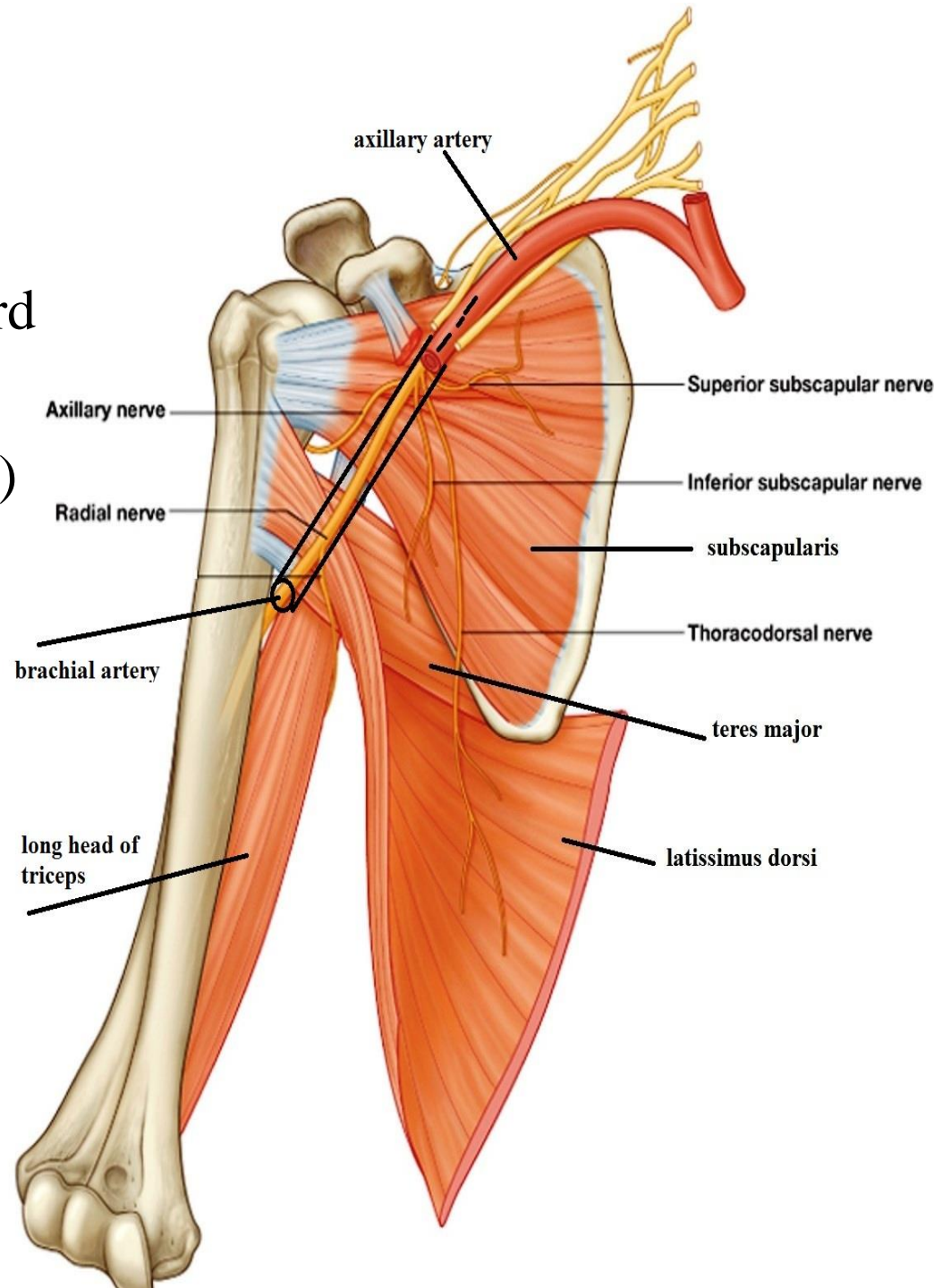
BY
DR ABULMAATY MOHAMED
ASSISTANT PROFESSOR
ANATOMY & EMBRYOLOGY
MUTAH UNIVERSITY

RADIAL NERVE

O.:-

- Behind the axillary artery
 - as a continuation of posterior cord of the brachial plexus
- (largest branch of brachial plexus)

Root value:- C 5 , 6 , 7 , 8, T1



RADIAL NERVE

C. & R.

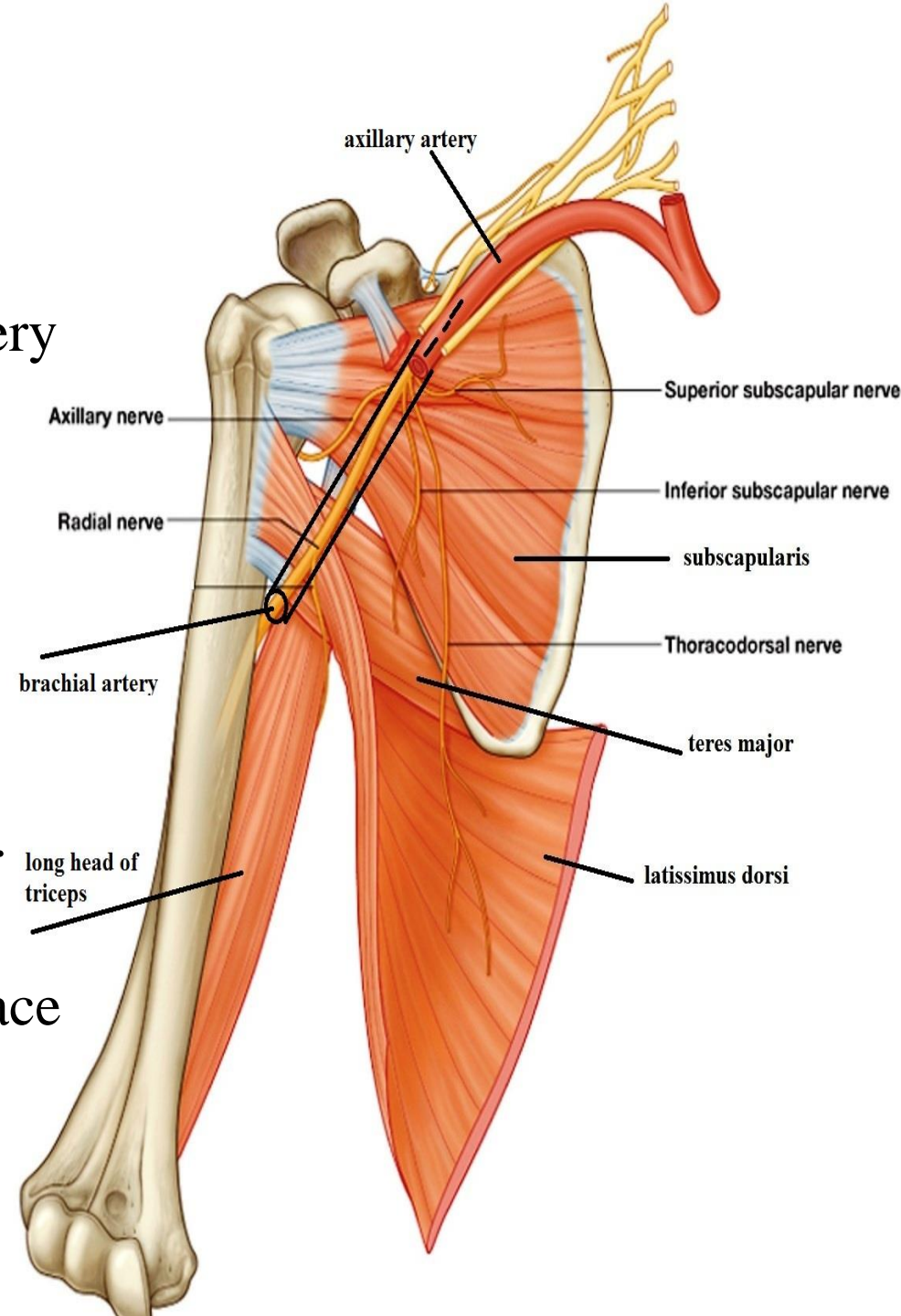
In the axilla

- Descends behind the axillary artery between it & subscapularis, teres major, latissimus dorsi

In the arm

(On medial side of the arm):-

- Descends behind the brachial art. between it & long head of triceps
- pass through lower triangular space with profunda brachii artery to enter the back of arm



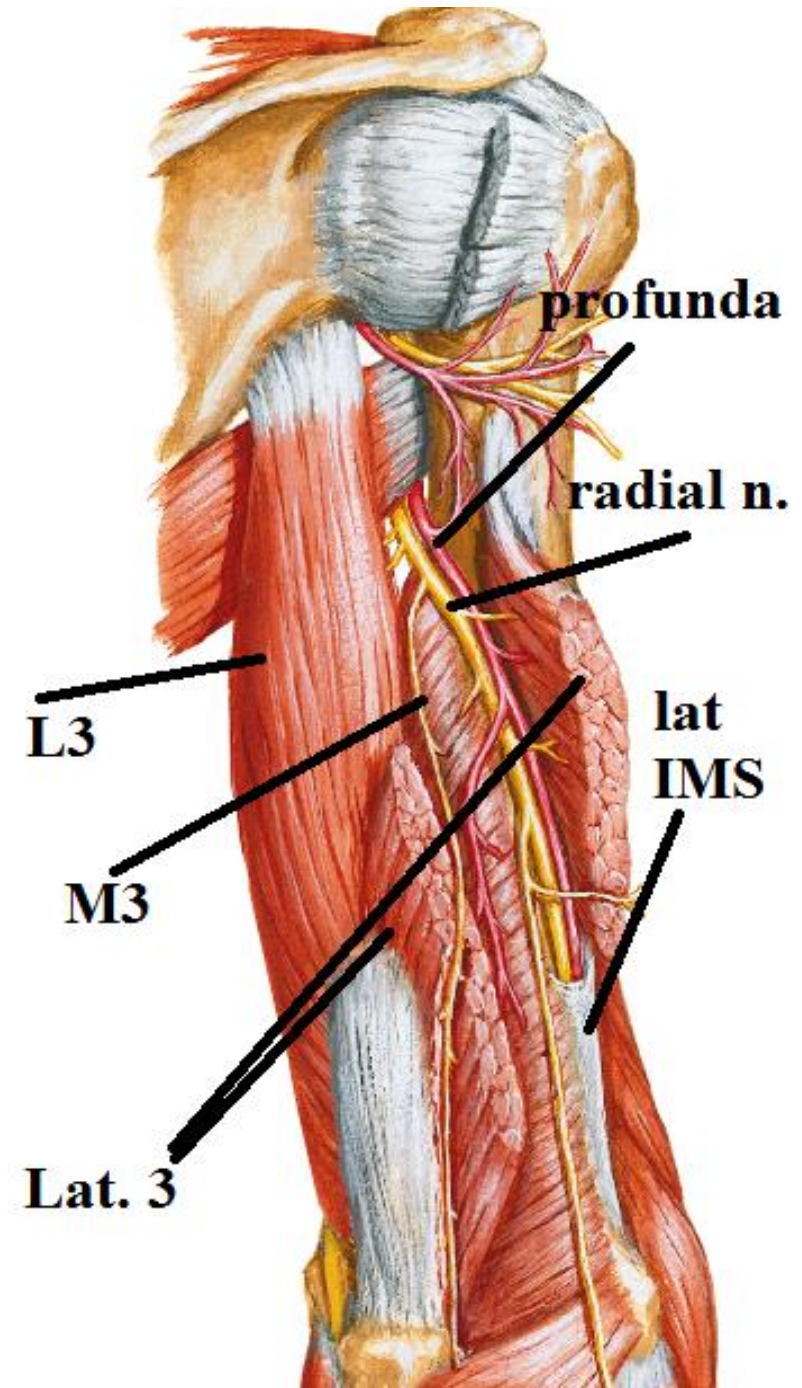
RADIAL NERVE

C. & R.

In the arm

(On back of the arm):-

- Runs in the spiral groove with profunda brachii artery covered by lateral head of triceps to reach the lateral side of arm



RADIAL NERVE

C. & R.

In the arm

(On lateral side of the arm):-

- At middle of the arm it pierces the lateral intermuscular septum to enter the anterior compartment to
- lie () brachialis & brachioradialis,

In the forearm

ends in cubital fossa in front lateral epicondyle

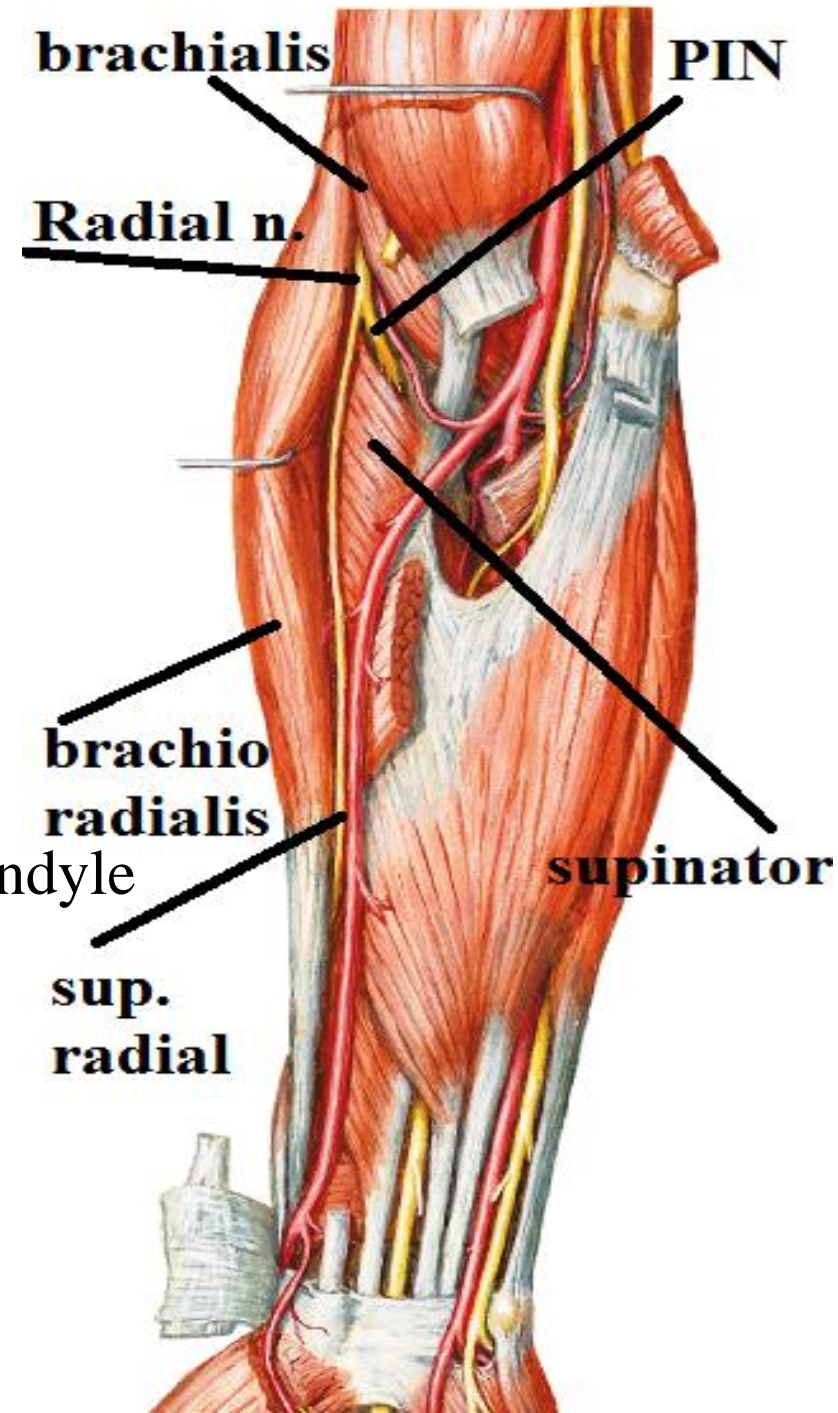
dividing into

1-superficial terminal branch

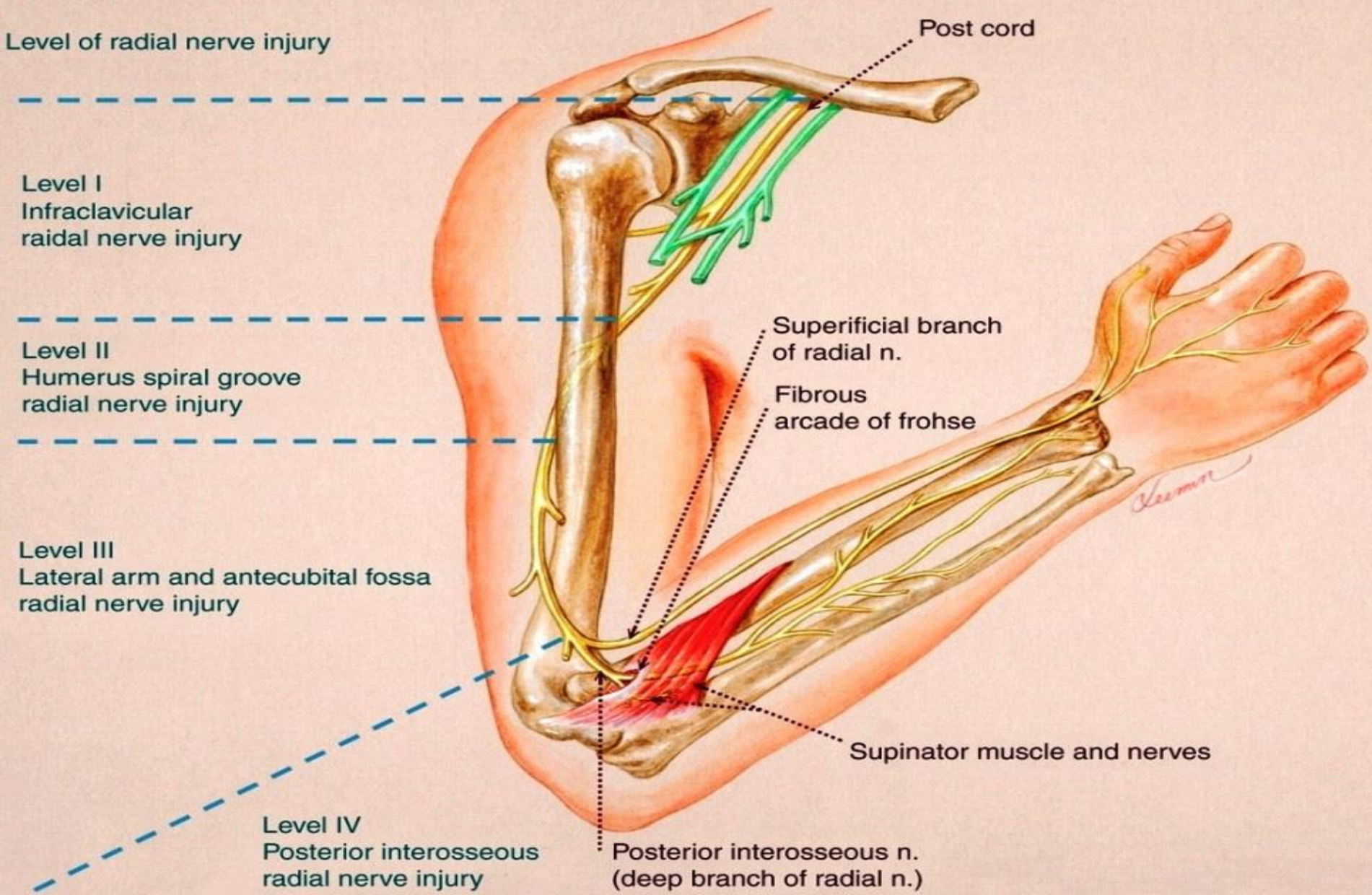
(superficial radial n.)

2- deep terminal branch

(post. interosseous n.)



RADIAL NERVE



RADIAL NERVE

Branches

in the arm

in medial side of arm:

long head of triceps.

medial head of triceps

post. cutaneous n. of arm.

in (back of arm) spiral groove:

medial head of triceps.

lateral head of triceps

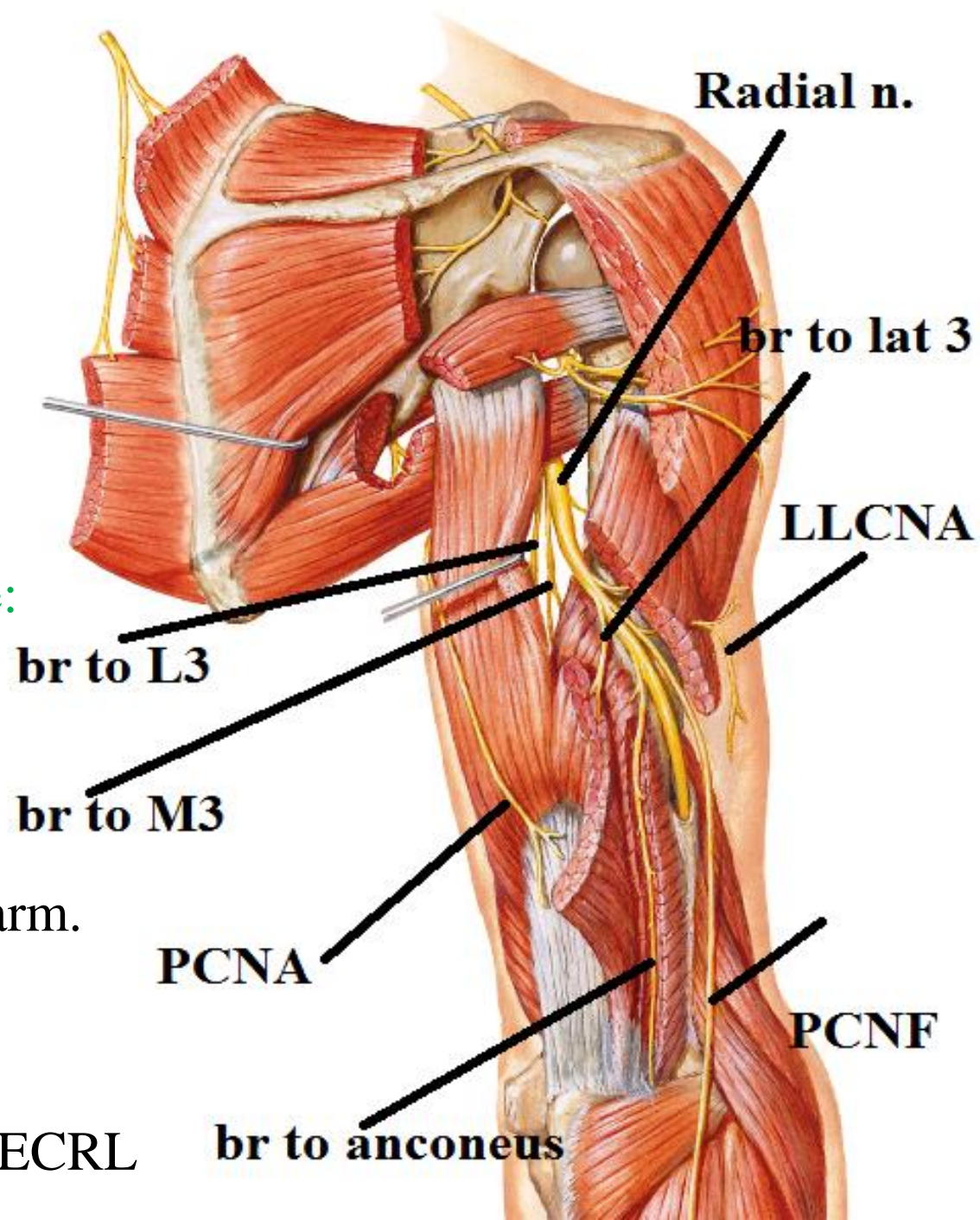
anconeus.

lower lateral cutaneous n. of arm.

post. cutaneous n. of forearm:

in lateral side of arm:

brachialis , brachioradialis & ECRL



RADIAL NERVE

Branches

in the forearm

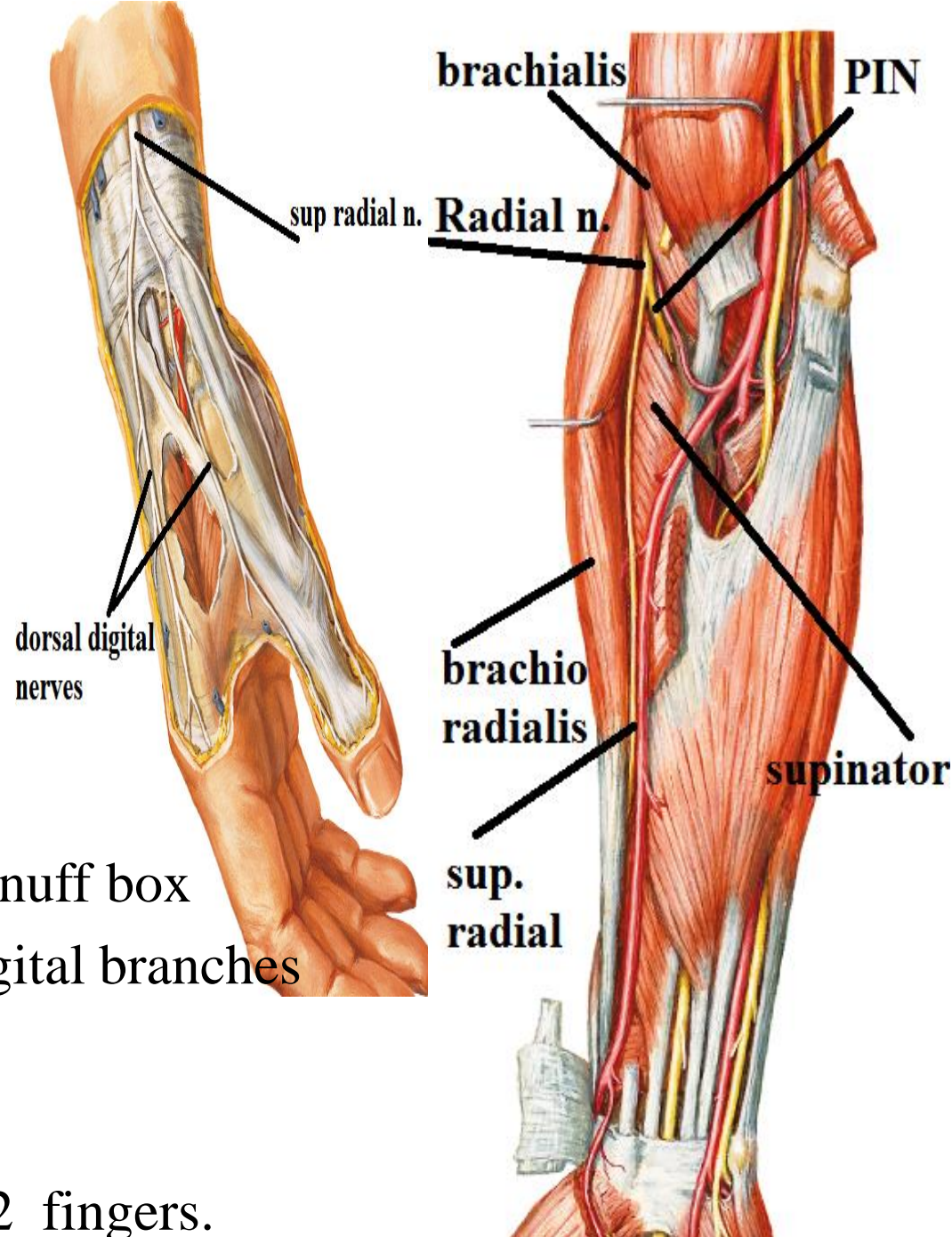
1-superficial radial n. =sensory

Course & relations:-

- Descends vertically in lateral side of forearm deep to brachioradialis
- 5 cm above the wrist it turns backwards to run in roof of anatomical snuff box where it divides into 5 dorsal digital branches

supply:

dorsum of lateral 2/3 of hand &
Proximal phalanx of lateral 3 1/2 fingers.



RADIAL NERVE

Branches

in the forearm

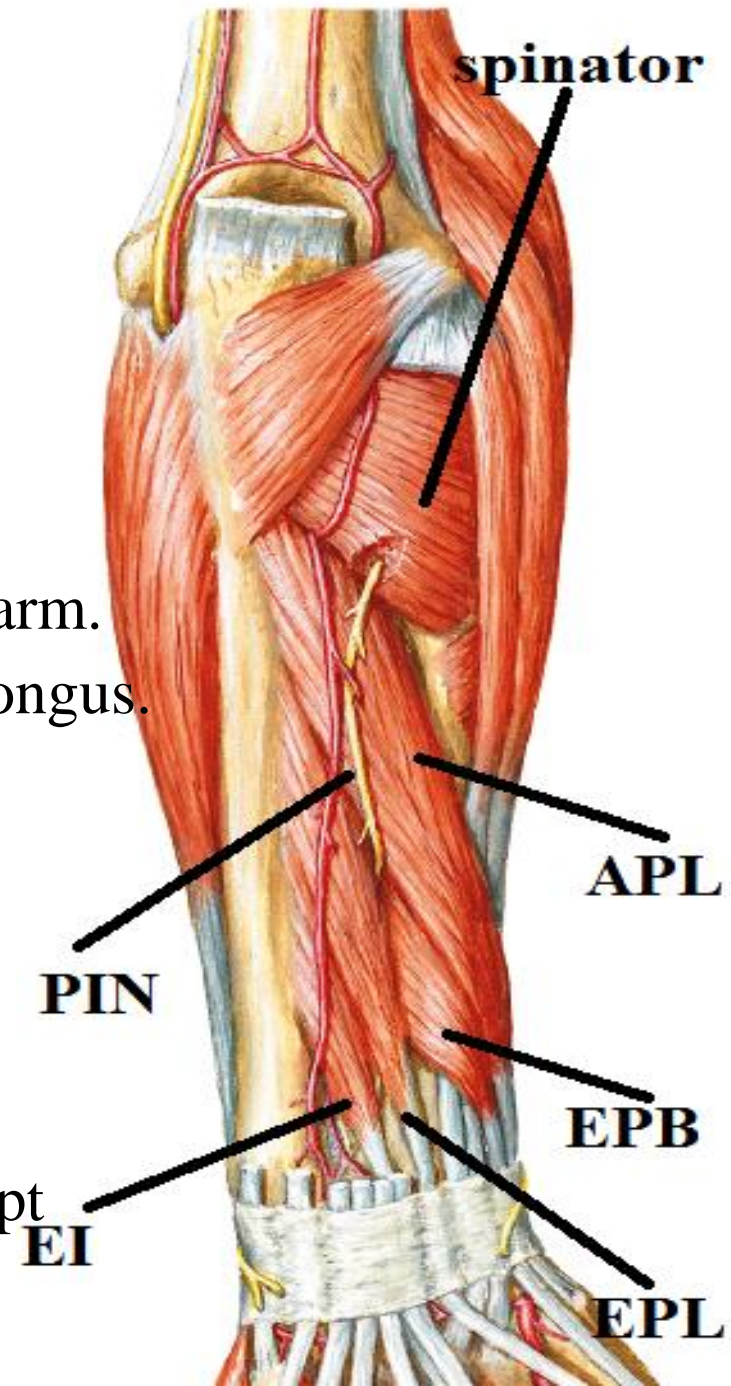
2-post. Interosseous n.=motor

course & relations:

- Pierce supinator
- Turn inside the supinator around lateral side of radius to back of forearm.
- Appear () supinator & abductor pollicis longus.
- Run () superficial & deep extensors
- Then () extensor pollicis longus & inteross. Membrane
- Ends deep to extensor retinaculum

branches:-

--all the muscles of the back of forearm except (brachioradialis – ECRL – anconeus)

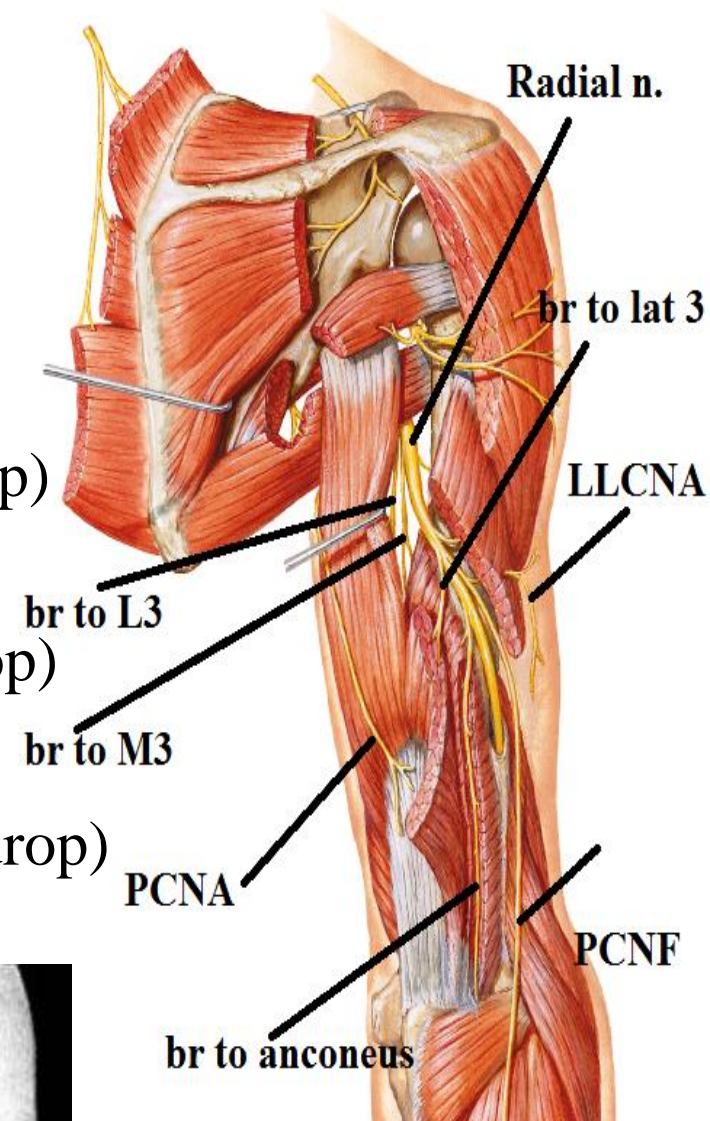
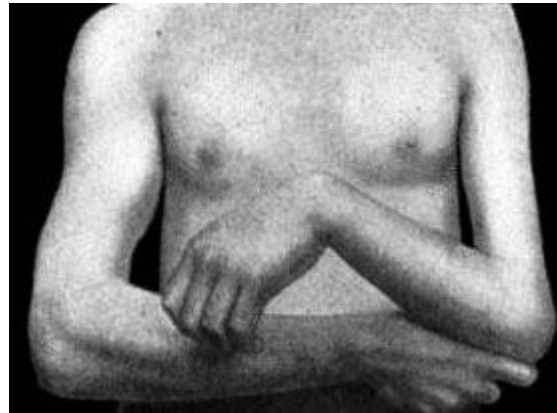


RADIAL NERVE

Effect of injury

In axilla

- paralysis of triceps & anconeus leading to loss of elbow extension (elbow drop)
- Paralysis of wrist extensors leading to loss of wrist extension (wrist drop)
- Paralysis of fingers extensors leading to loss of fingers extension (fingers drop)



RADIAL NERVE

Effect of injury

In spiral groove:-

(fracture shaft of humerus or wrong I.M. injection)

Motor effect: - As above except elbow extension is intact due to long & medial heads of triceps are working

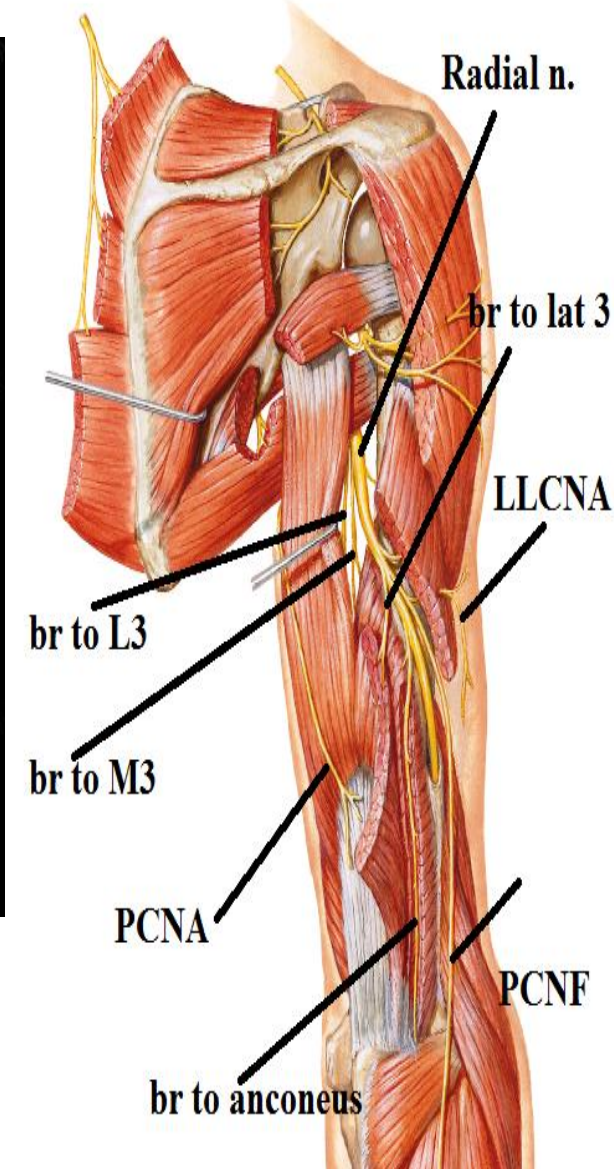
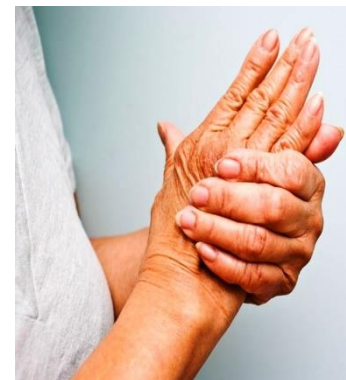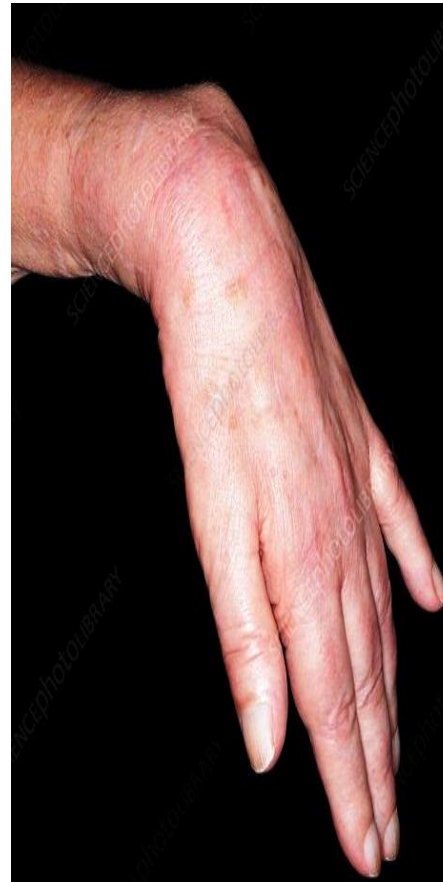as they receive the nerve supply before the spiral groove

Fingers

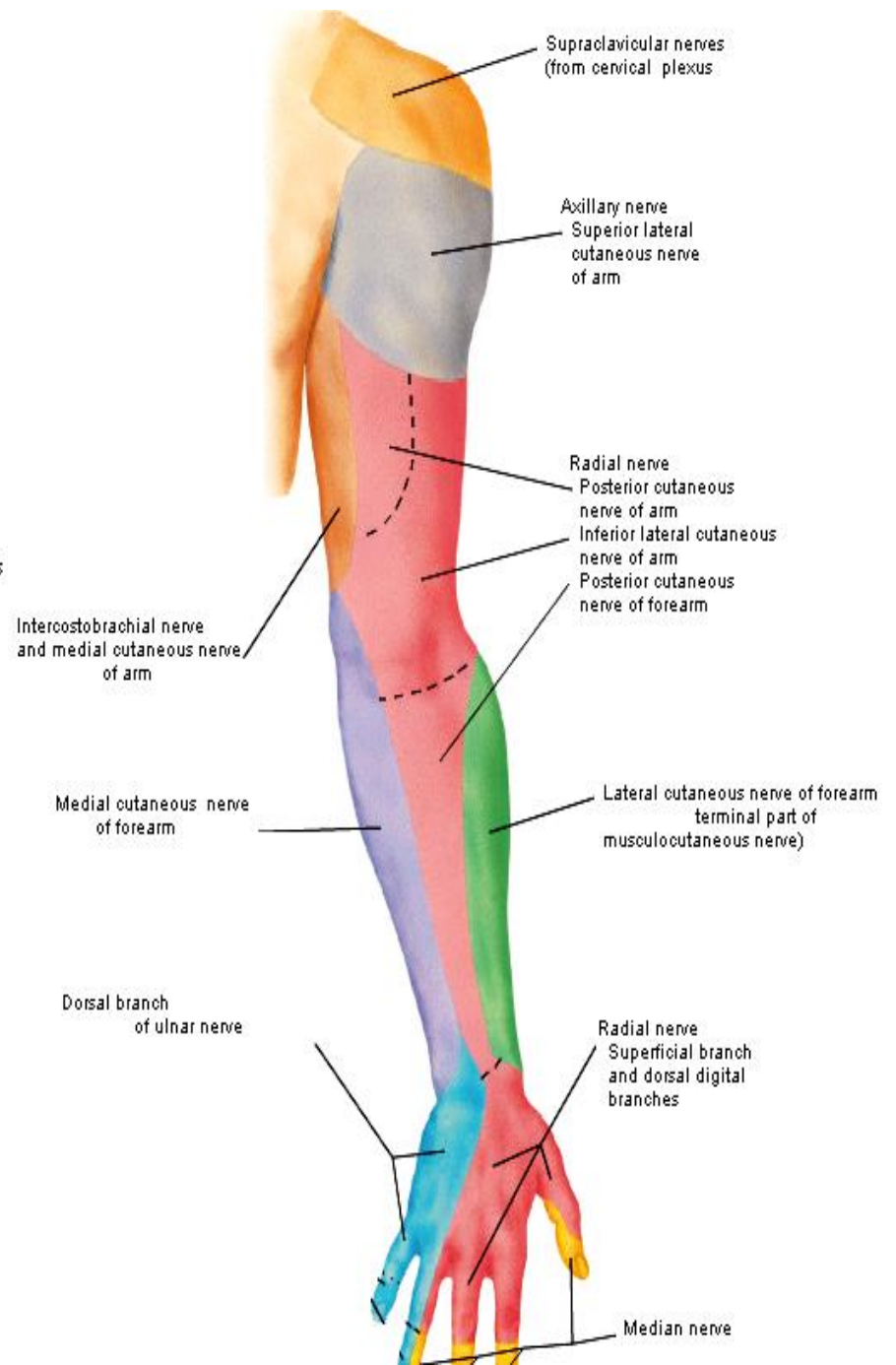
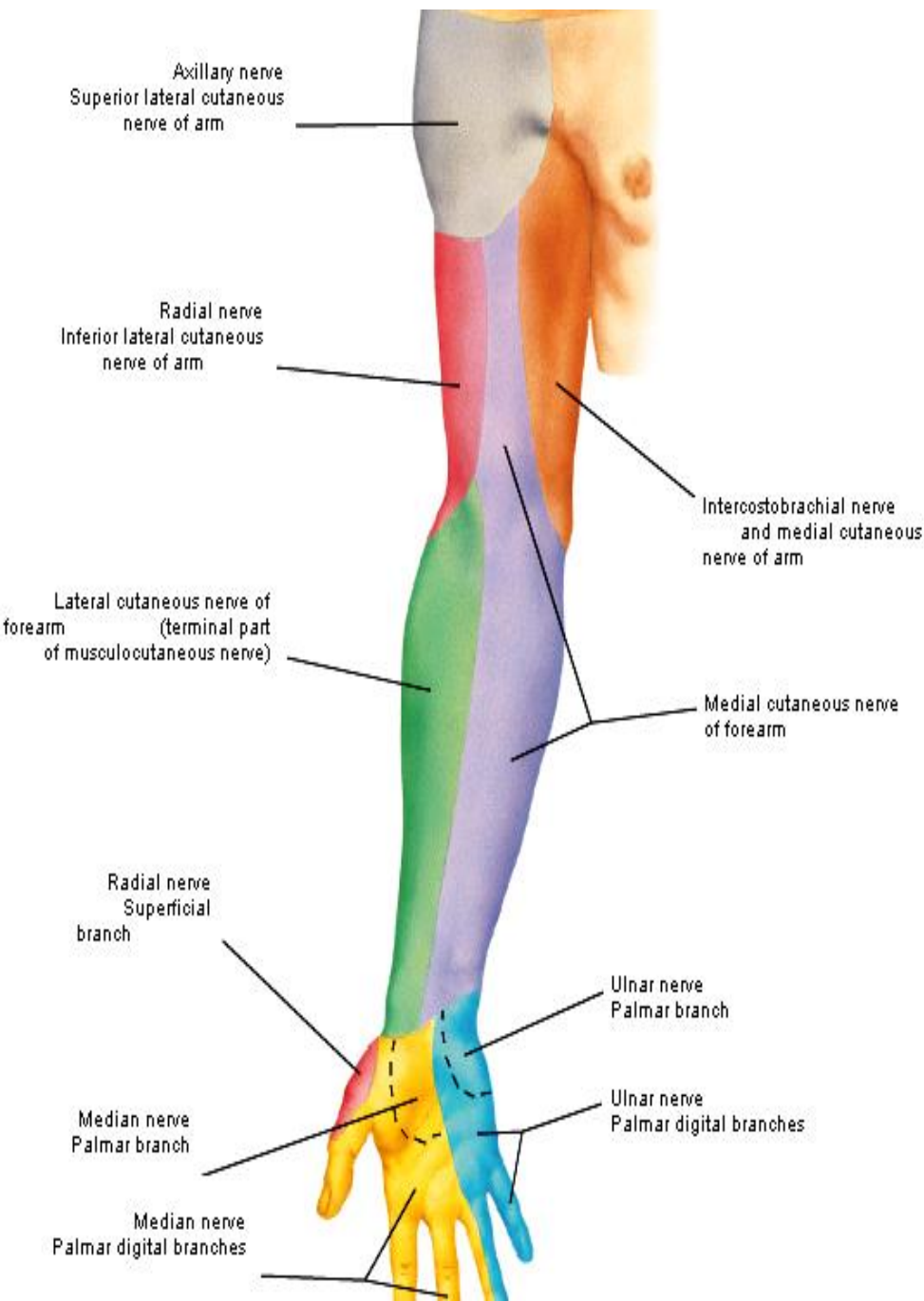
Injury of post. Interosseous nerve:-

(fracture upper part of radius)

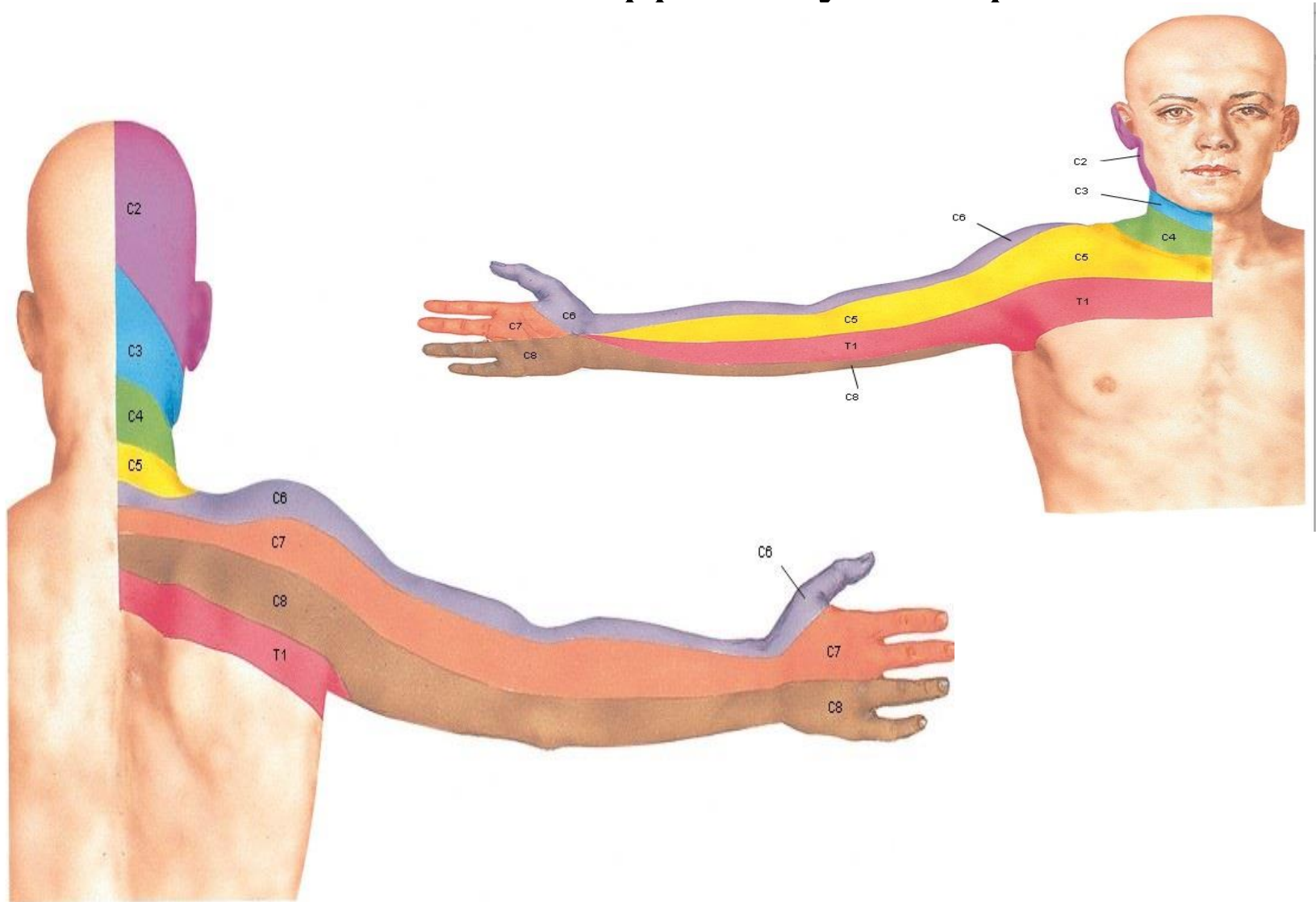
Only finger drop



CUTANEOUS
INNERVATION
OF UPPER LIMB



Dermatome:- area of skin supplied by one spinal nerve



**SUPERFICIAL
VEINS
OF UPPER LIMB**

1-DORSAL VENOUS ARCH

- On back of wrist
- Receive 4 dorsal metacarpal veins which receive dorsal digital veins
- Its medial end gives basilic vein while its lateral end gives cephalic vein

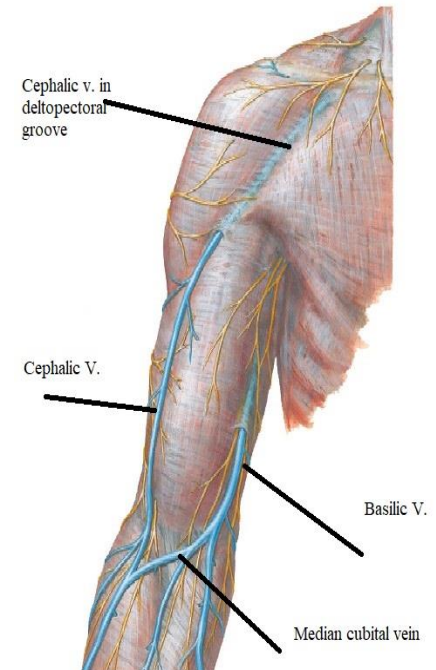
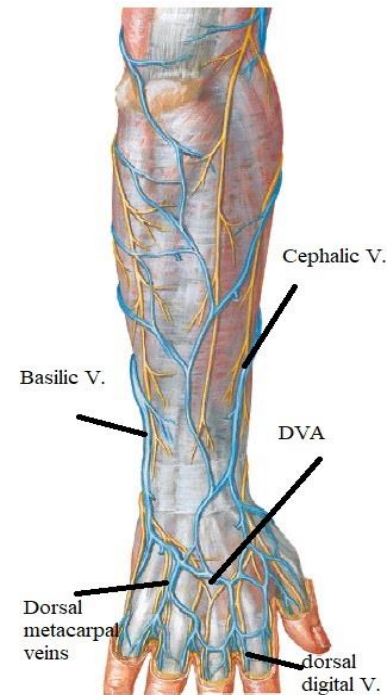
2- CEPHALIC VEIN

O. Lateral end of dorsal venous arch

C.&R.

- Runs in the superficial fascia of upper limb as follows
- Superficial to extensor retinaculum
- Ascends along lateral side of forearm & cubital fossa & biceps
- At the deltopectoral groove it pierces the deep fascia then clavipectoral fascia

END in axillary vein



3- BASILIC VEIN

O. Medial end of dorsal venous arch

C.&R.

--Runs in the superficial fascia of upper limb as follows

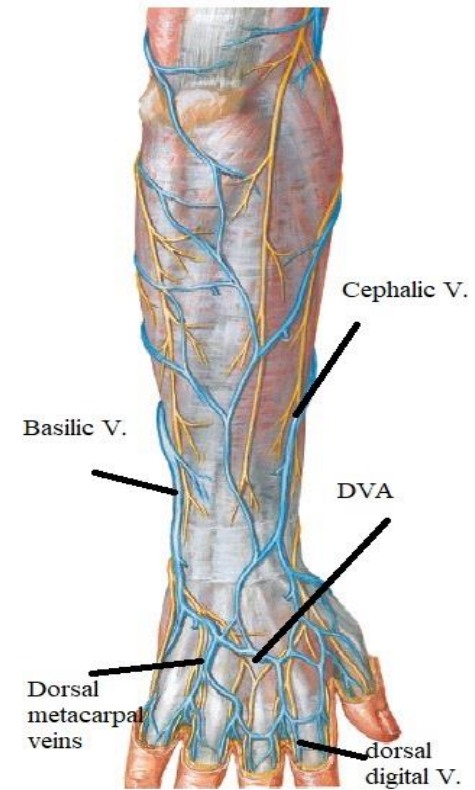
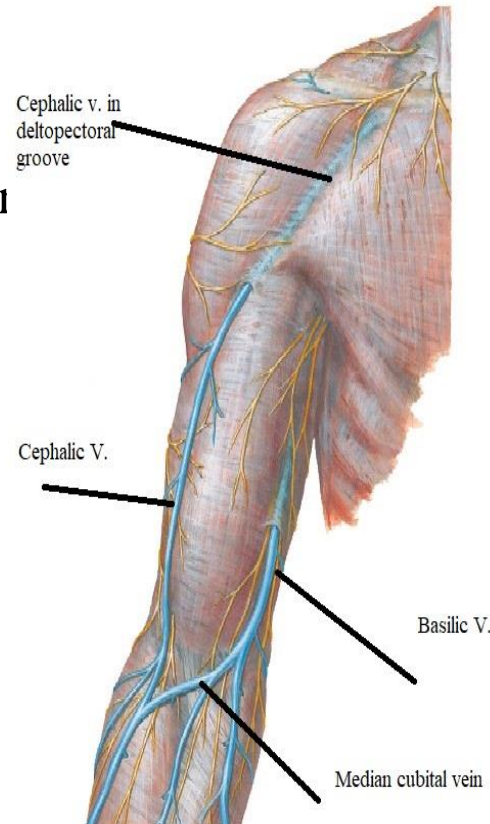
-Superficial to extensor retinaculum

-Ascends along medial side of forearm & cubital fossa & biceps

--At the insertion of coracobrachialis
it Pierces the deep fascia then

ascends medial to the brachial artery

END at the lower border of teres major
it becomes axillary vein



4- MEDIAN CUBITAL VEIN

O.:- from cephalic 1 inch below elbow

C.&R.:- ascends upwards & medially in roof of cubital fossa separated from brachial artery & median nerve by bicipital aponeurosis

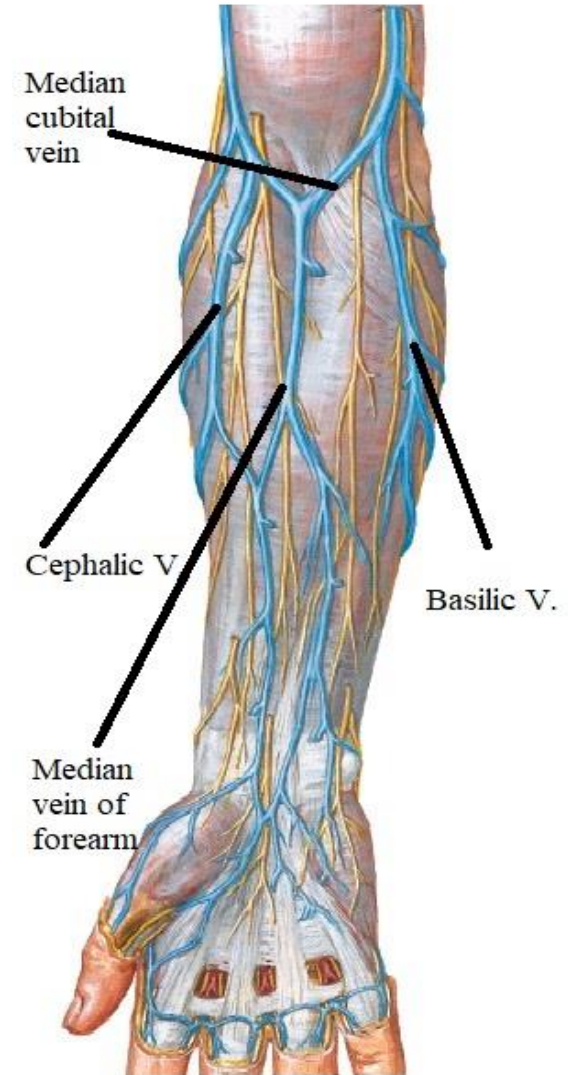
E.:- in basilic 1 inch above elbow

5-MEDIAN VEIN OF FOREARM :-

Formed in front of wrist

Ascend in midline of forearm

End in median cubital vein.



THANQ