

# HLS Red Cell Disorders Anemia-II.

---






DR.EMAN KREISHAN, M.D.

9-4-2026

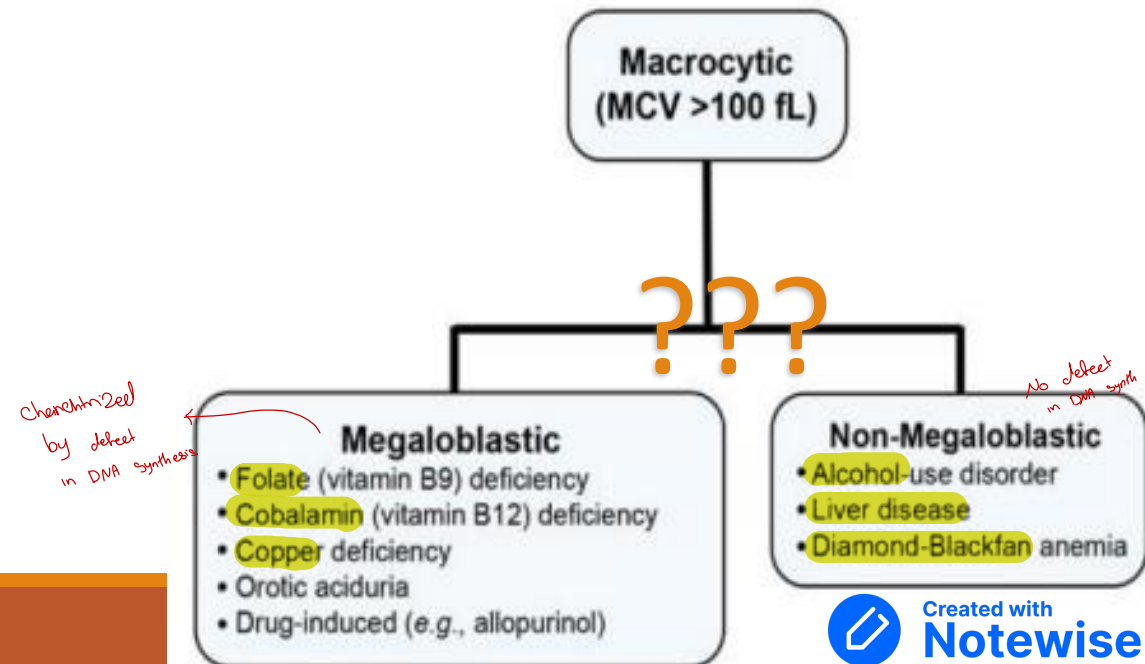
# Morphological Classification of Anemia

Morphological-classification-of-anemia

			
Morphology	Microcytic	Normocytic	Macrocytic
MCV (fL)	<80	80 - 100	>100
Disorders	<ul style="list-style-type: none"><li>Thalassemia</li><li>Anemia of chronic disease</li><li>Iron deficiency anemia</li><li>Lead poisoning</li><li>Sideroblastic anemia</li></ul>	<ul style="list-style-type: none"><li>Hemolytic anemia</li><li>Anemia of chronic disease</li><li>Renal disease</li><li>Acute blood loss</li><li>Bone marrow failure</li><li>Aplastic anemia</li></ul>	<ul style="list-style-type: none"><li>Megaloblastic anemia</li><li>Alcoholism</li><li>Liver disease</li><li>Myelodysplasia</li></ul>

# III. Macrocytic anemia

- Macrocytic anemia is a term used to describe erythrocytes that are larger than normal, typically mean cell volume (MCV) greater than 100 fL.
- The most common cause of macrocytic anemia is megaloblastic anemia.



# Megaloblastic anemia

---

- Megaloblastic anemia describes a heterogeneous group of disorders that share common morphologic characteristics: large cells with an arrest in nuclear maturation.
- These abnormalities are due to impaired DNA synthesis and, to a lesser extent, RNA and protein synthesis.
- Megaloblastic changes are most apparent in rapidly dividing cells such as blood cells and gastrointestinal cells ● Skin cell

- The most common causes of megaloblastosis are:
  - vitamin B12 and folate deficiencies.
  - Medications.
  - Direct interference of DNA synthesis by HIV infections.

# How impaired DNA synthesis leads to megaloblastic anemia

---

As the DNA doesn't synthesize normally, nuclear maturation is delayed, while cytoplasmic maturation continues at normal rate, thus forming a cell with mature cytoplasm with relatively immature, large, open nucleus, known as a megaloblast.

This leads to Unbalanced cell growth and impaired cell division.

Large number of abnormal precursors undergo intramedullary apoptosis leading to anemia

*↳ in bone marrow*

Additionally, impaired DNA synthesis leads to ineffective hematopoiesis in all 3 cell lines → pancytopenia

# Vitamin B12 (Cobalamin) Deficiency Anemia

The primary sources of cobalamin (C1b), a cobalt-containing vitamin, are meat, fish, and dairy products and not vegetables and fruit.

الناس  
الذين يتبعون  
نظام غذائي  
نباتي لا يحصلون  
على فيتامين ب12

It is stored in the liver, which normally contains reserves sufficient for 5-20 years → clinical presentations typically follow years of unrecognized malabsorption.

يتظاهر بعد ما ينفد المخزون

---

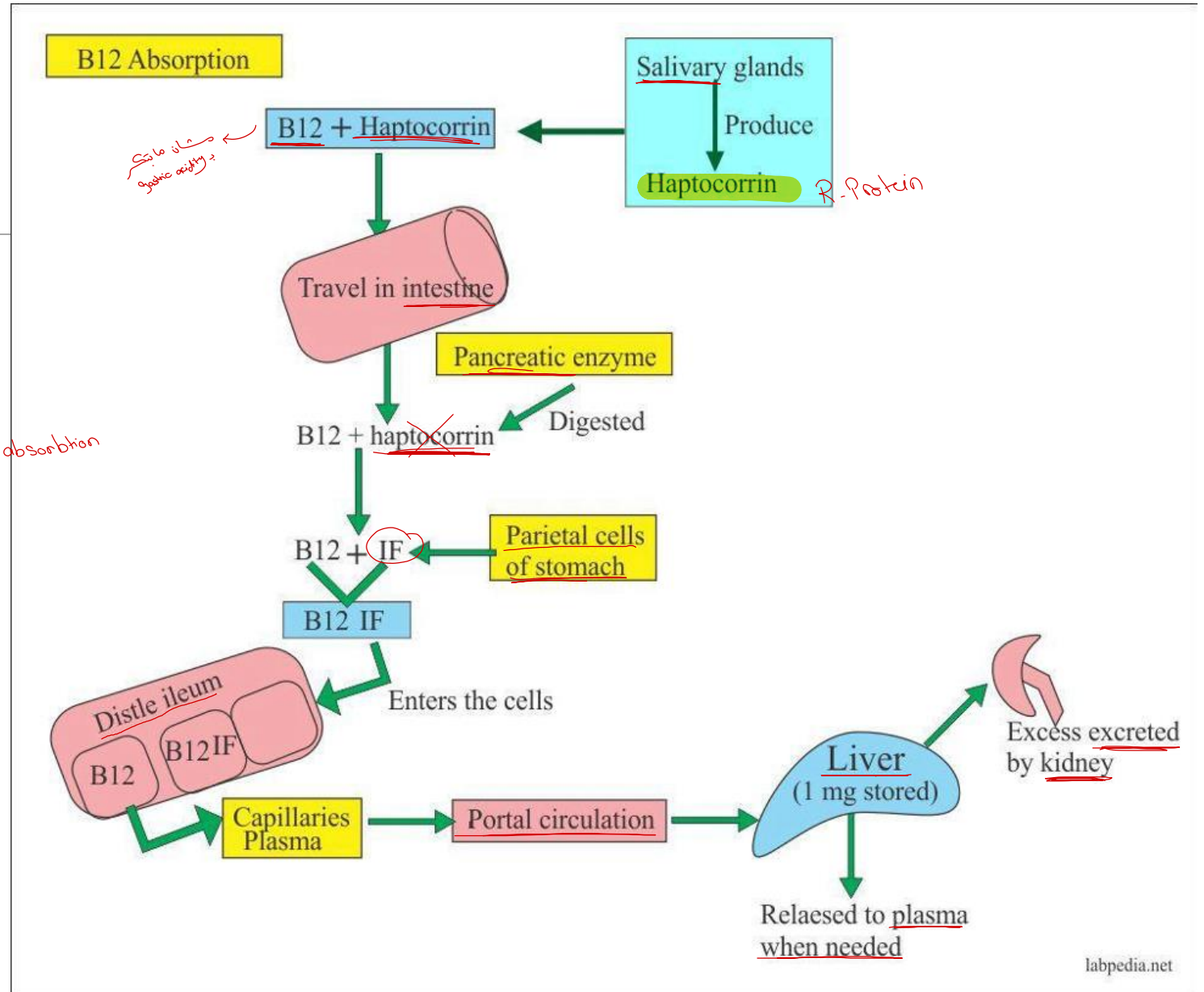
vitamin B12 has to be protected during its passage through the gastrointestinal tract to the distal ileum, the site of B12 absorption, by binding to intrinsic factor (IF)(used to stabilize cobalamin and transport it to the terminal ileum.

- **pernicious anemia\***.
- **Gastrectomy.**
- **ileal resection.**
- **distal ileum disorders ( Crohn disease).**
- **pancreatic insufficiency.**

→ Production of intrinsic factor

absorption

↳ haptocorrin will link with IF and prevent it to bind with intrinsic factor



# Folate (Folic Acid) Deficiency Anemia

---

Result of **inadequate dietary** intake, sometimes complicated by **increased metabolic demands**.

● The risk is increased with:

1. **poor diet** (**poverty** & the **elderly**).

2. increased **metabolic needs** (**pregnant women** and **patients with chronic hemolytic anemias**).

3. Malabsorption or defect in **metabolism**, e.g:

- Absorption is inhibited by **beans & legumes**.

بویا منس ۲ صبحون

- Drugs: **phenytoin** or **methotrexate**.

- **Malabsorptive disorders** .



# Morphology of megaloblastic anemia

---

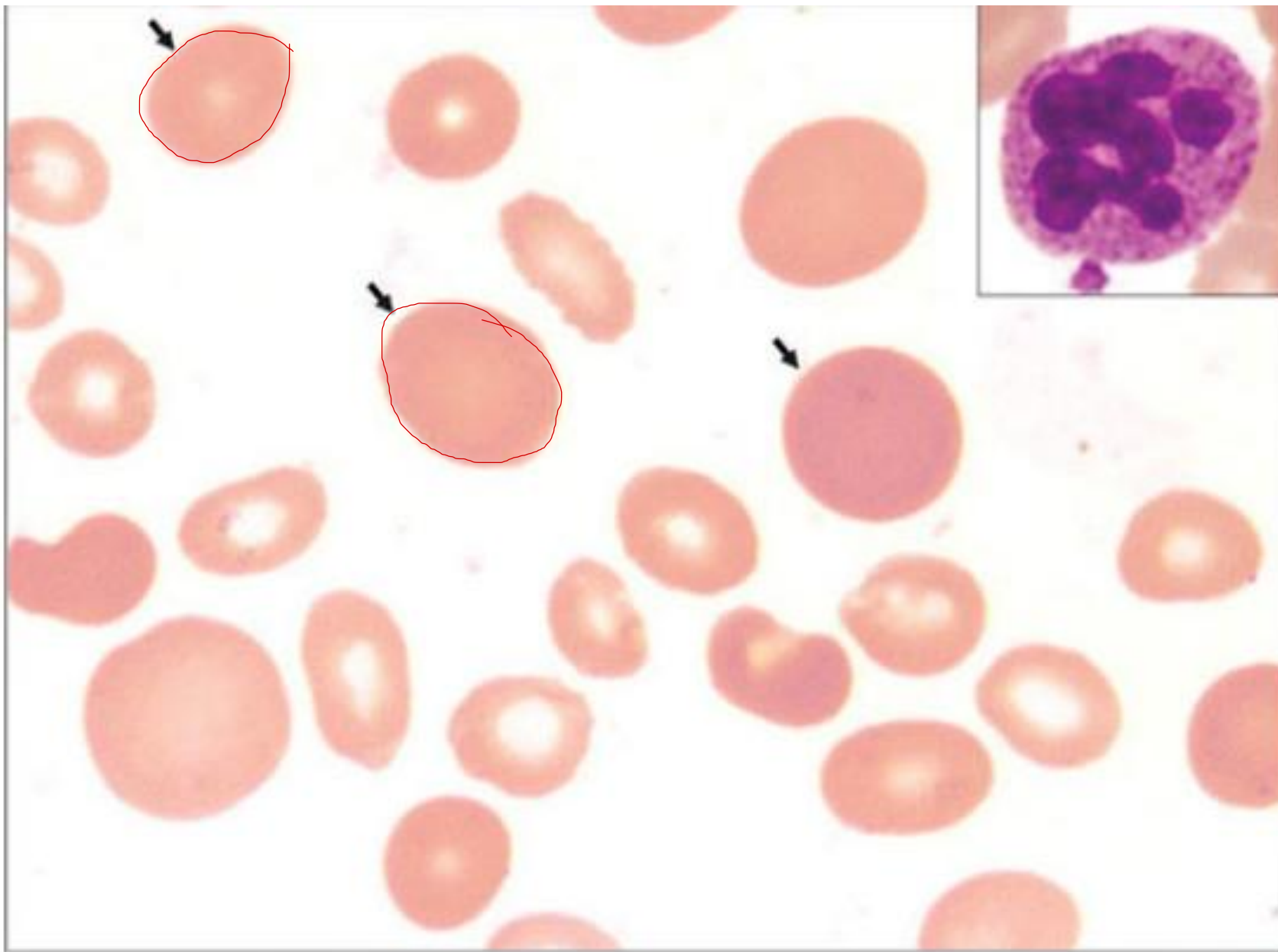
# Bone marrow (BM): hypercellular with numerous megaloblastic erythroid & granulocytic progenitors

- Megaloblasts: larger than normal progenitors with delicate, finely reticulated nuclear chromatin (indicative of nuclear immaturity).

# peripheral blood (PB):

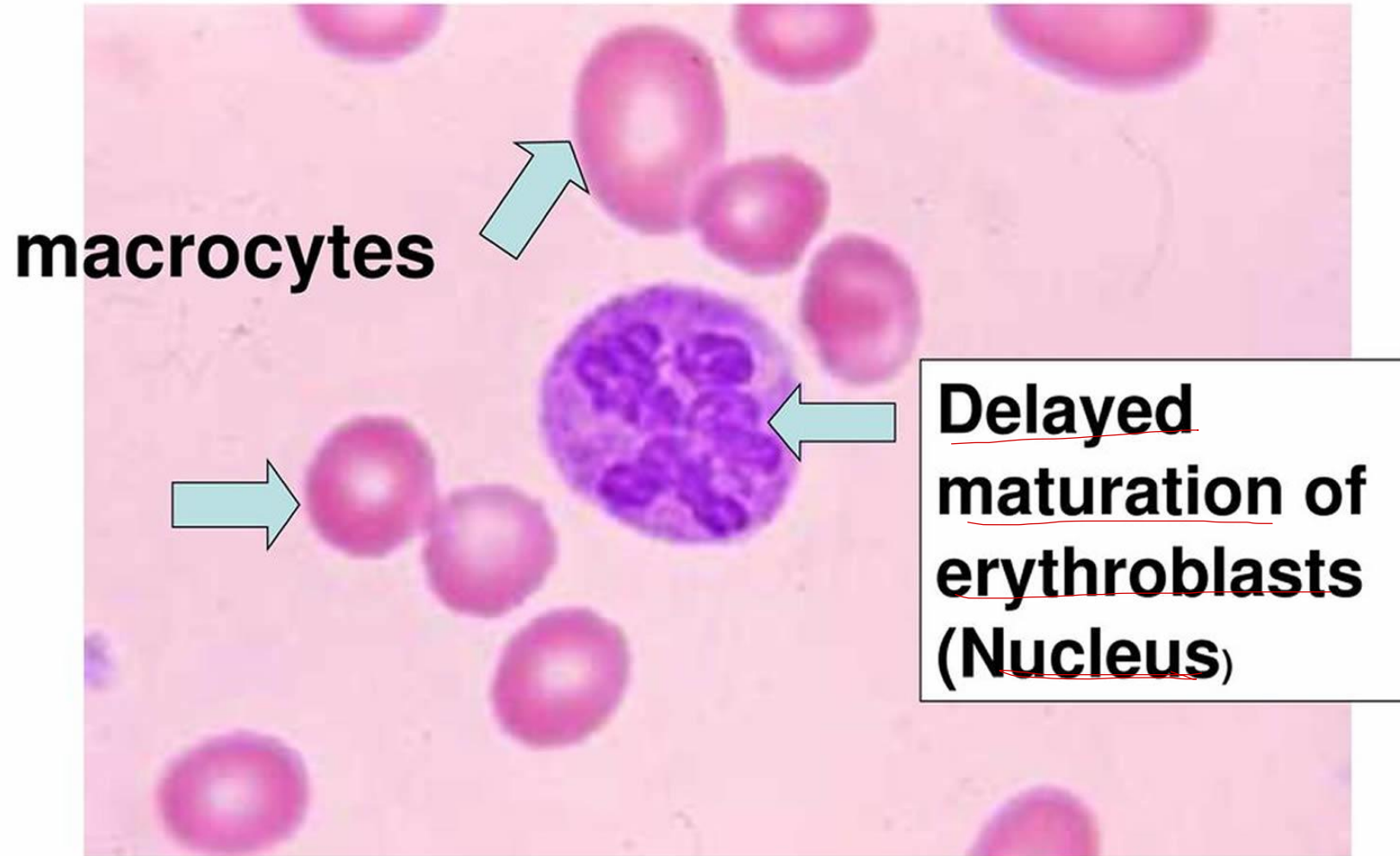
hypersegmented neutrophils ( $\geq 5$ ) → which appear before the onset of anemia.

- The red cells typically include large, egg-shaped macroovalocytes.



1.3: Peripheral blood smear showing macro-ovalocytes (arrows) and hypersegmented neutrophil (ins

# Megaloblastic Anemia



# Clinical manifestation of megaloblastic anemia

---

□ Patient with megaloblastic anemia may exhibit manifestations of:

\*anemia: loss of appetite, weight loss, nausea, and constipation..

\*neurological abnormalities: change in personality, psychosis and peripheral neuropathy.

□ Why???

↻ B12 deficiency lead to demyelination of the posterior & lateral columns of the spinal cord.

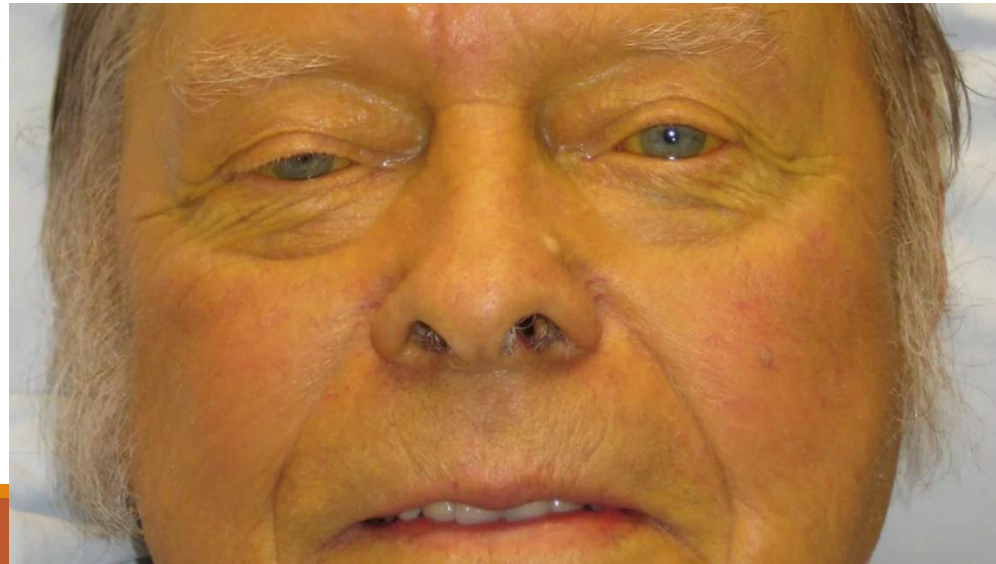
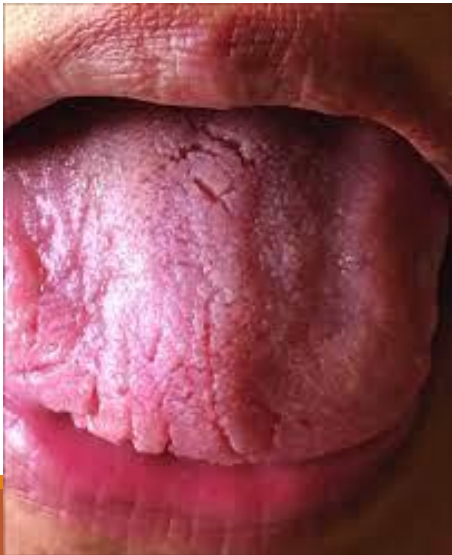□ Clinically:

\*symmetric numbness, tingling, & burning in the feet or hands, followed by unsteadiness of gait and loss of position sense, particularly in the toes.

# Physical findings

---

- \* Glossitis, characterized by a **smooth tongue due to loss of papillae**, occurs in persons with cobalamin deficiency. B<sub>12</sub>
- \* Patients may have a **lemon-yellow hue due increased indirect bilirubin level (intramedullary hemolysis)**.
- \* **hyperpigmentation** of the skin (increased **melanin synthesis**).



# LABORATORY FINDINGS OF MEGALOBLASTIC ANEMIA

---

- Complete blood count (CBC) → Hb ↓ MCV ↑
- Red blood cell (RBC) indices MCV + MCH ↑
- Peripheral blood smear. → + hyper segmented neutrophil  
+ macrocyte RBC
- Serum cobalamin ↓ B<sub>12</sub>
- Serum folate ↓ folic acid

# Treatment

Supplementation of B12 and folate.

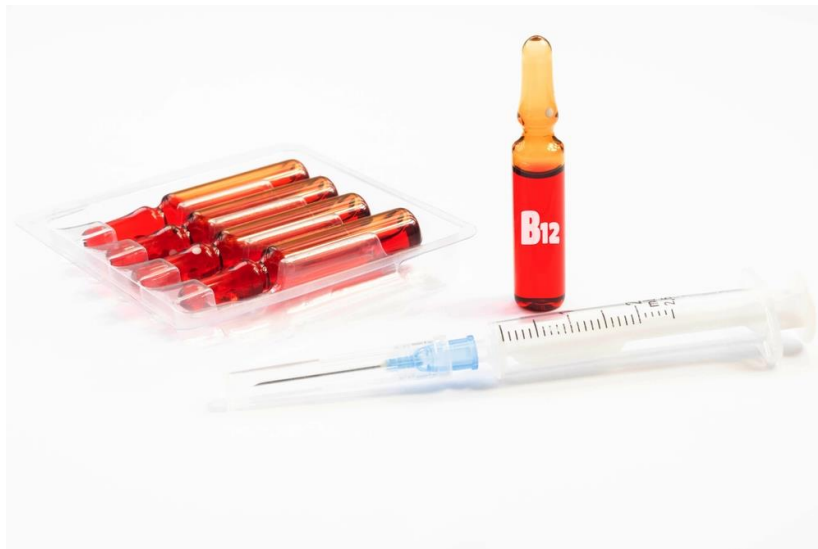
When malabsorption is a cause, parenteral supplementation is needed

Treat the underlying cause

IM

سواء ما كاننا  
نقدر استئصاله  
السبب في الحالة  
GIT

Injection is the  
safest route



# Non-megaloblastic anemia

---

- Non-megaloblastic anemia, in the absence of hypersegmented neutrophils, occurs in a variety of settings like :
- alcohol consumption (RBC toxicity).
- hereditary spherocytosis (impaired volume regulation increases red cell size).
- hypothyroidism and liver disease (due to lipid deposition in the cell membrane).
- marked reticulocytosis from states of excess RBC consumption such as hemolysis or turnover in pregnancy or primary bone marrow disease (reticulocytes are larger than the average RBCs).