

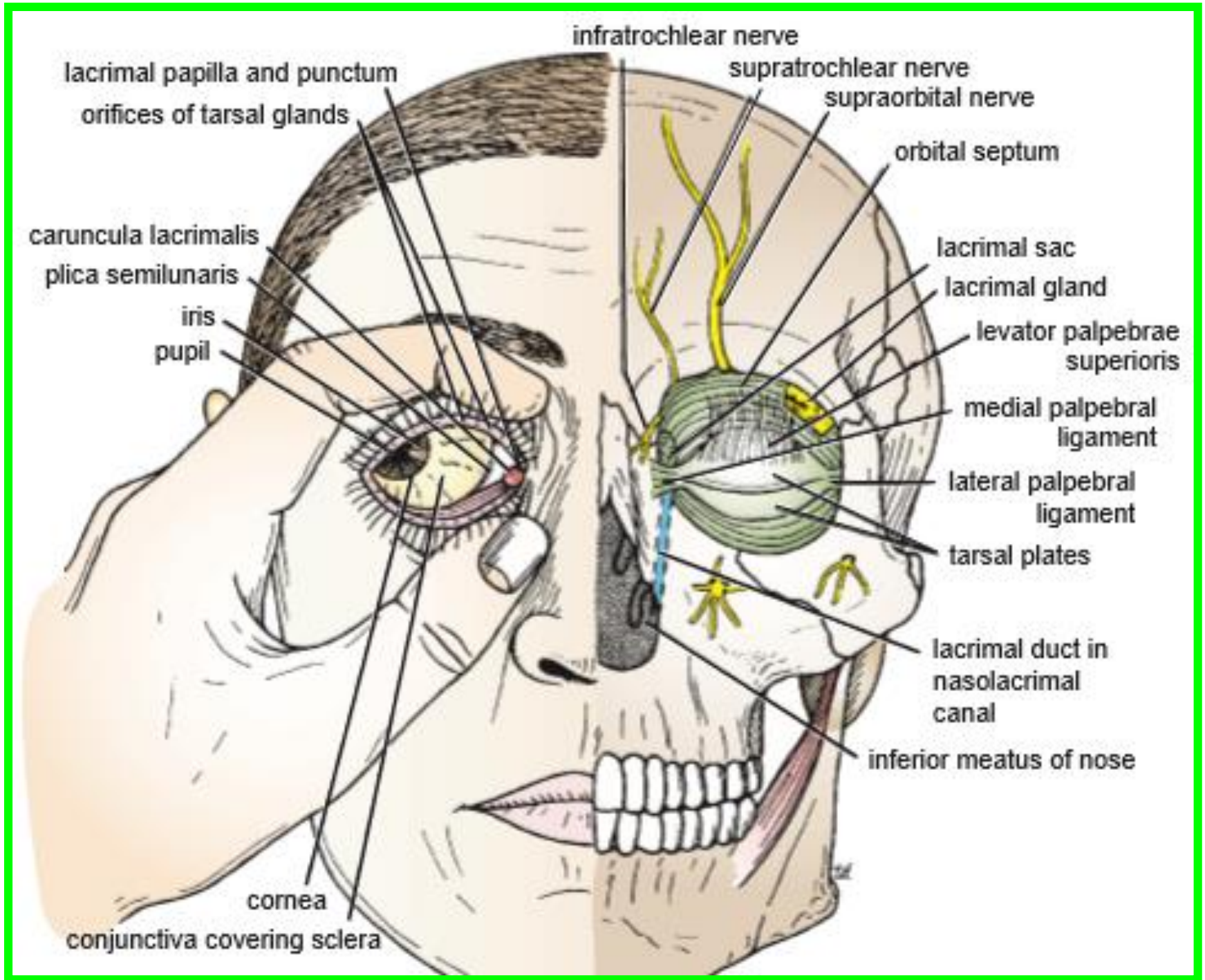
# ***Peripheral Nervous System***

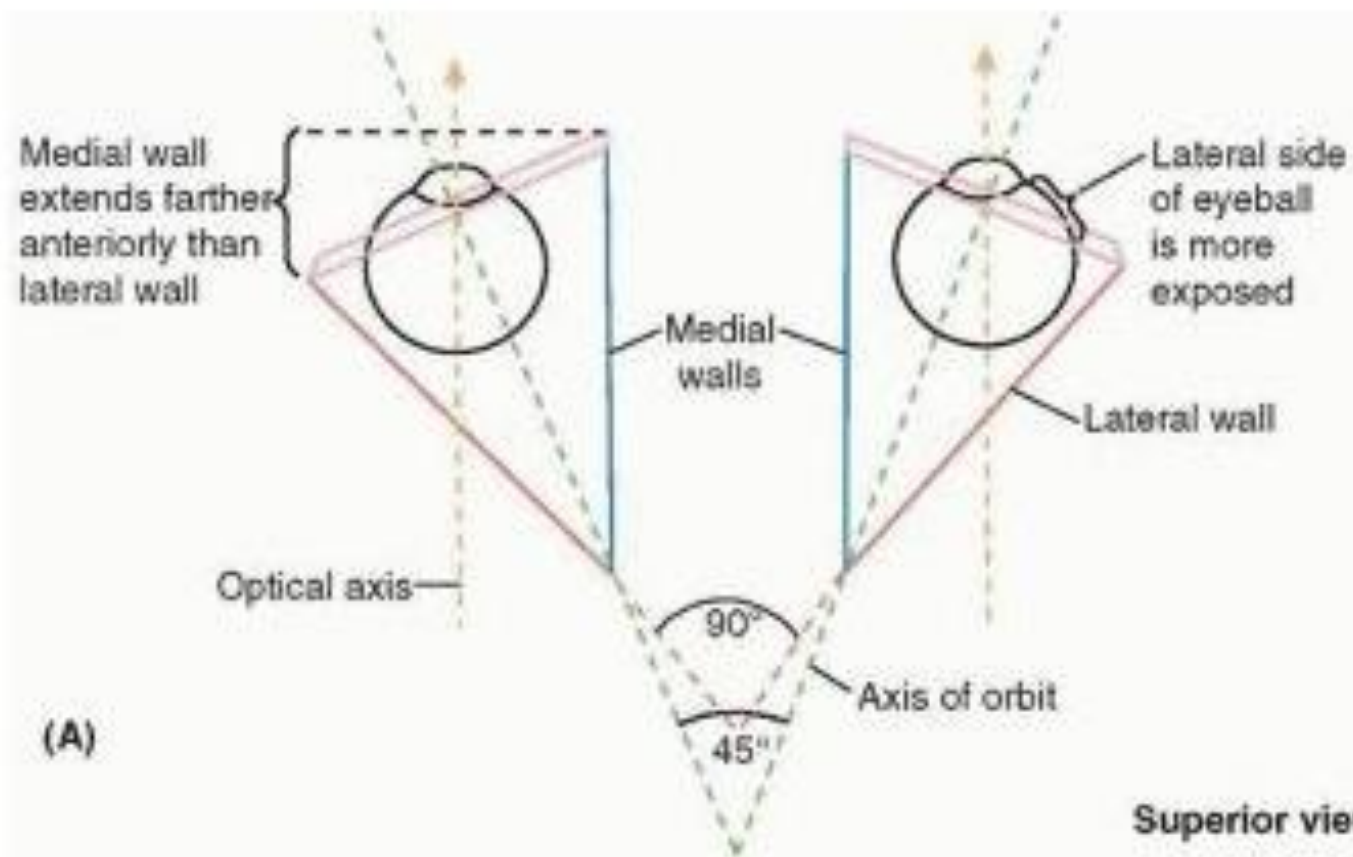
## **LAB 2**

***Dr. Aiman Qais Afar***  
***Surgical Anatomist***

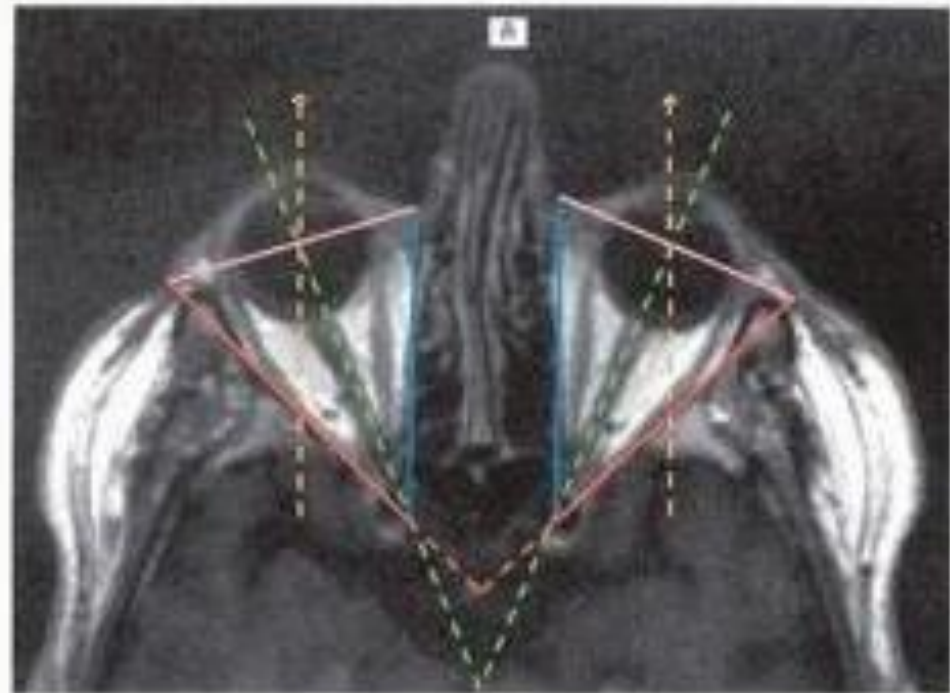
***College of Medicine / University of Mutah***  
***2022-2023***

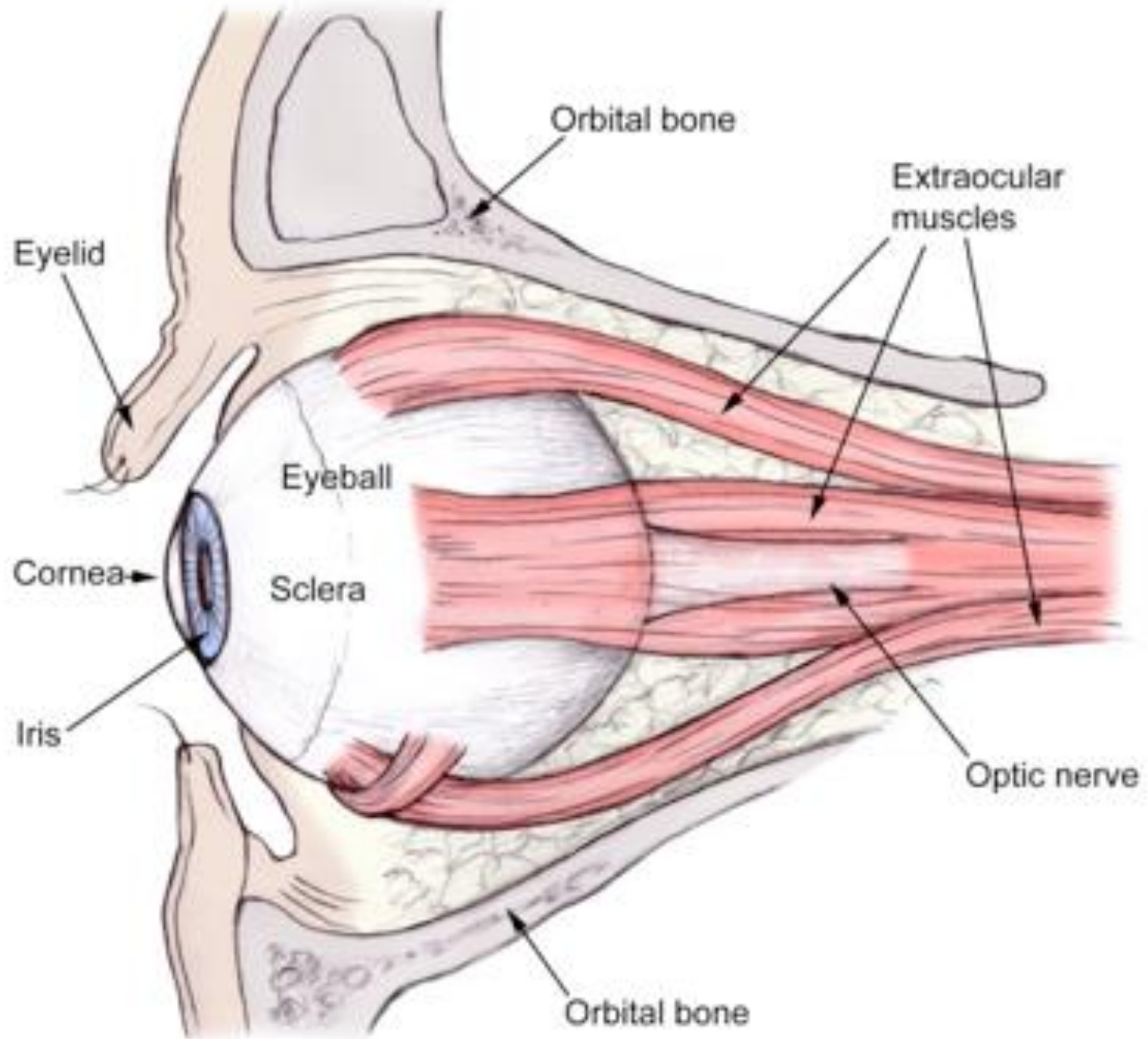
***Thursday 9 March 2023***



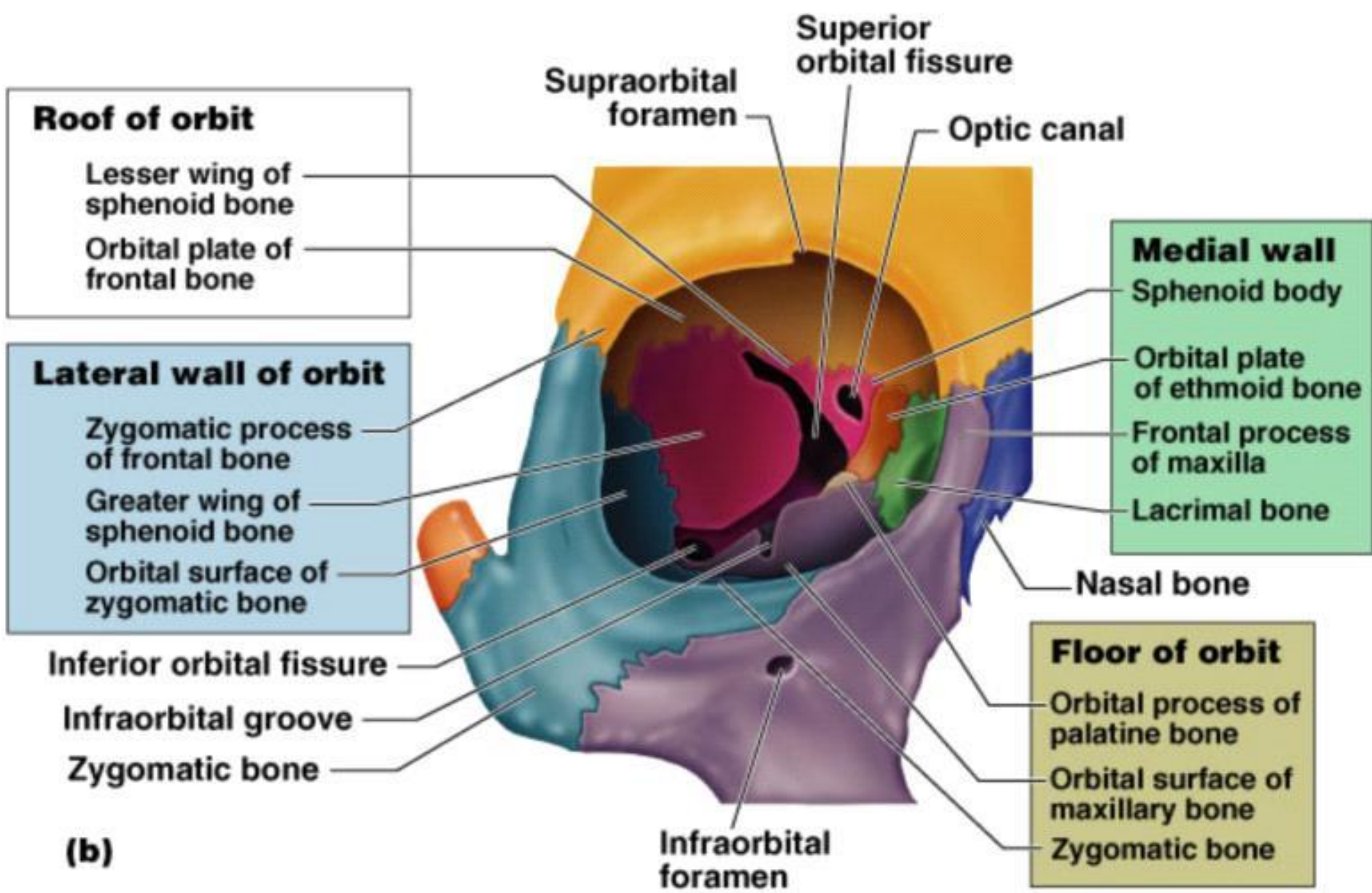
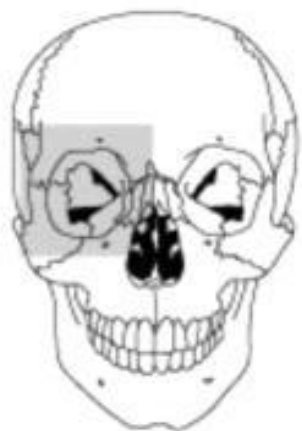


Superior views

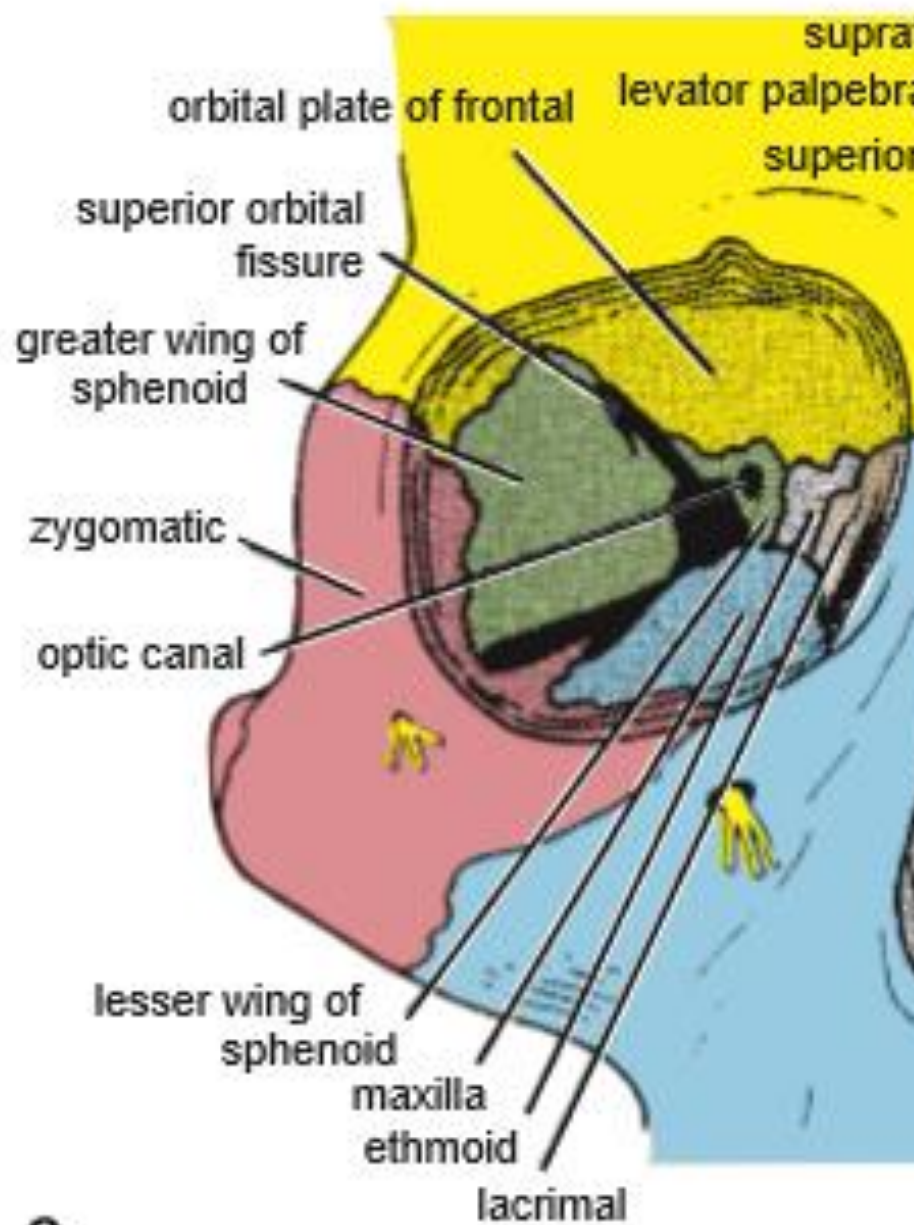
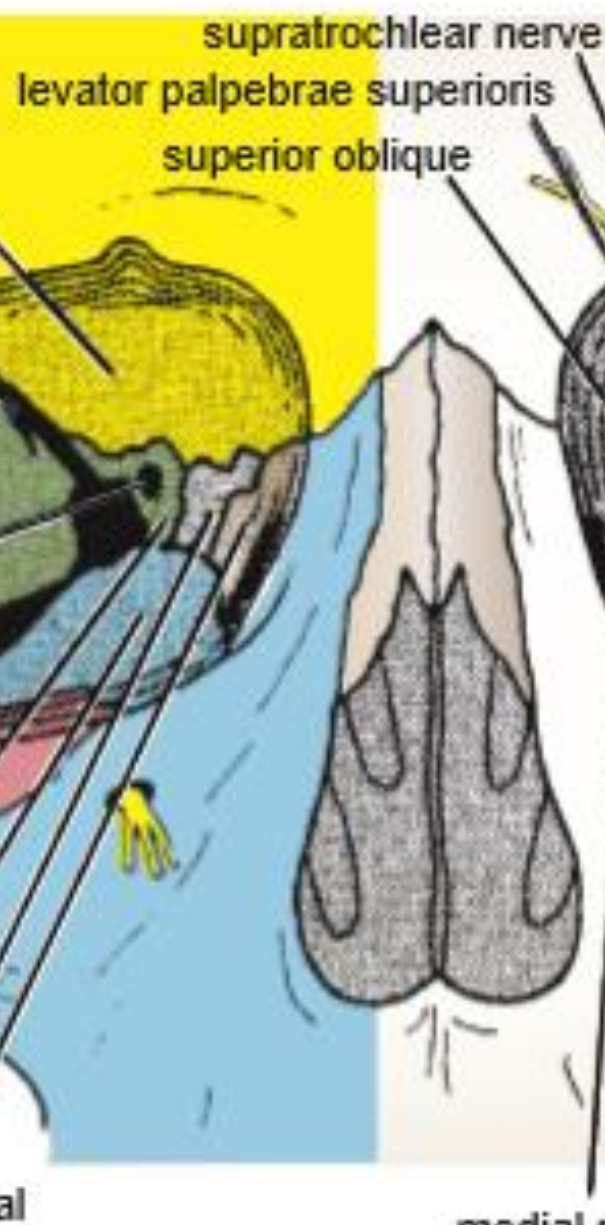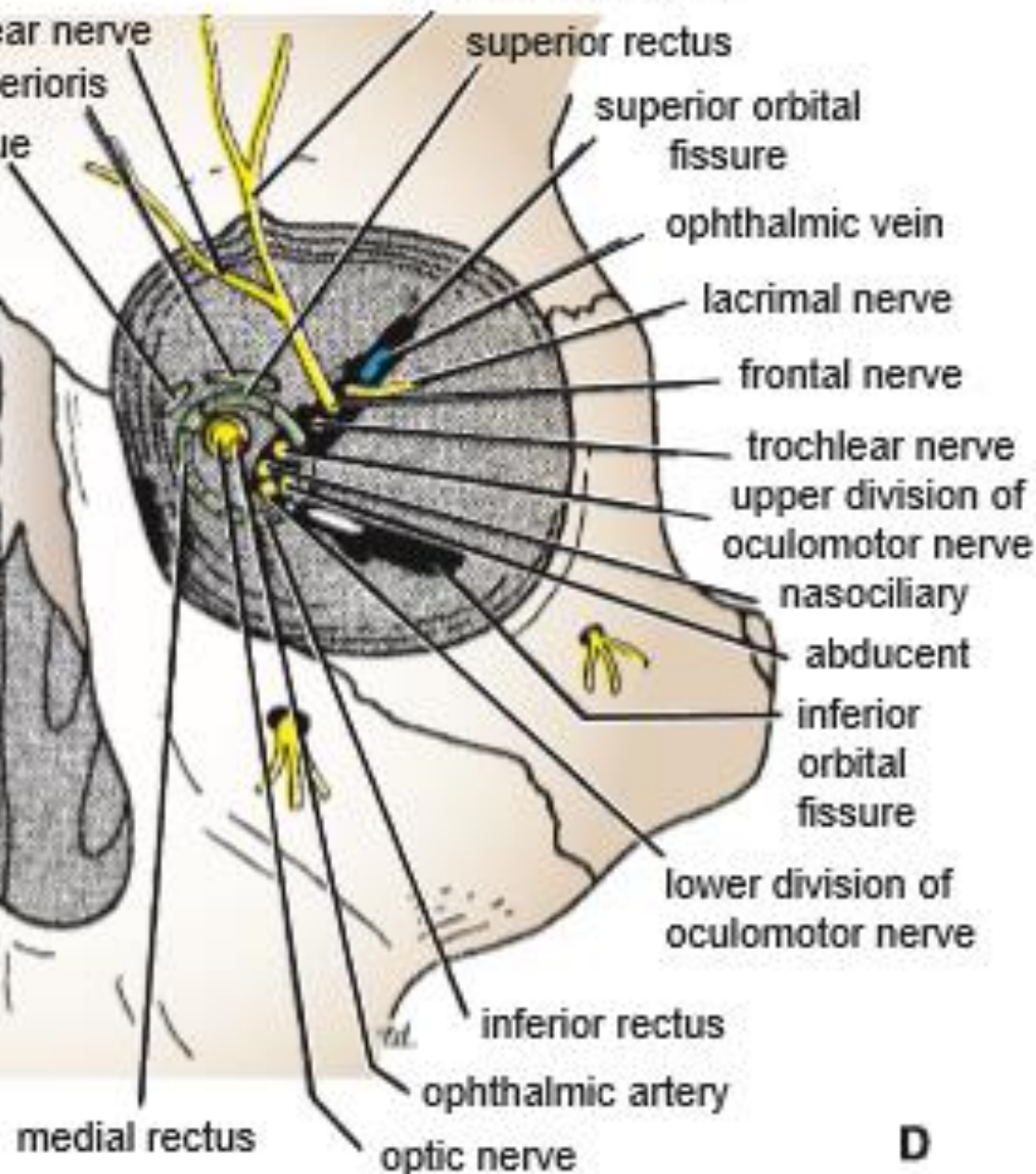




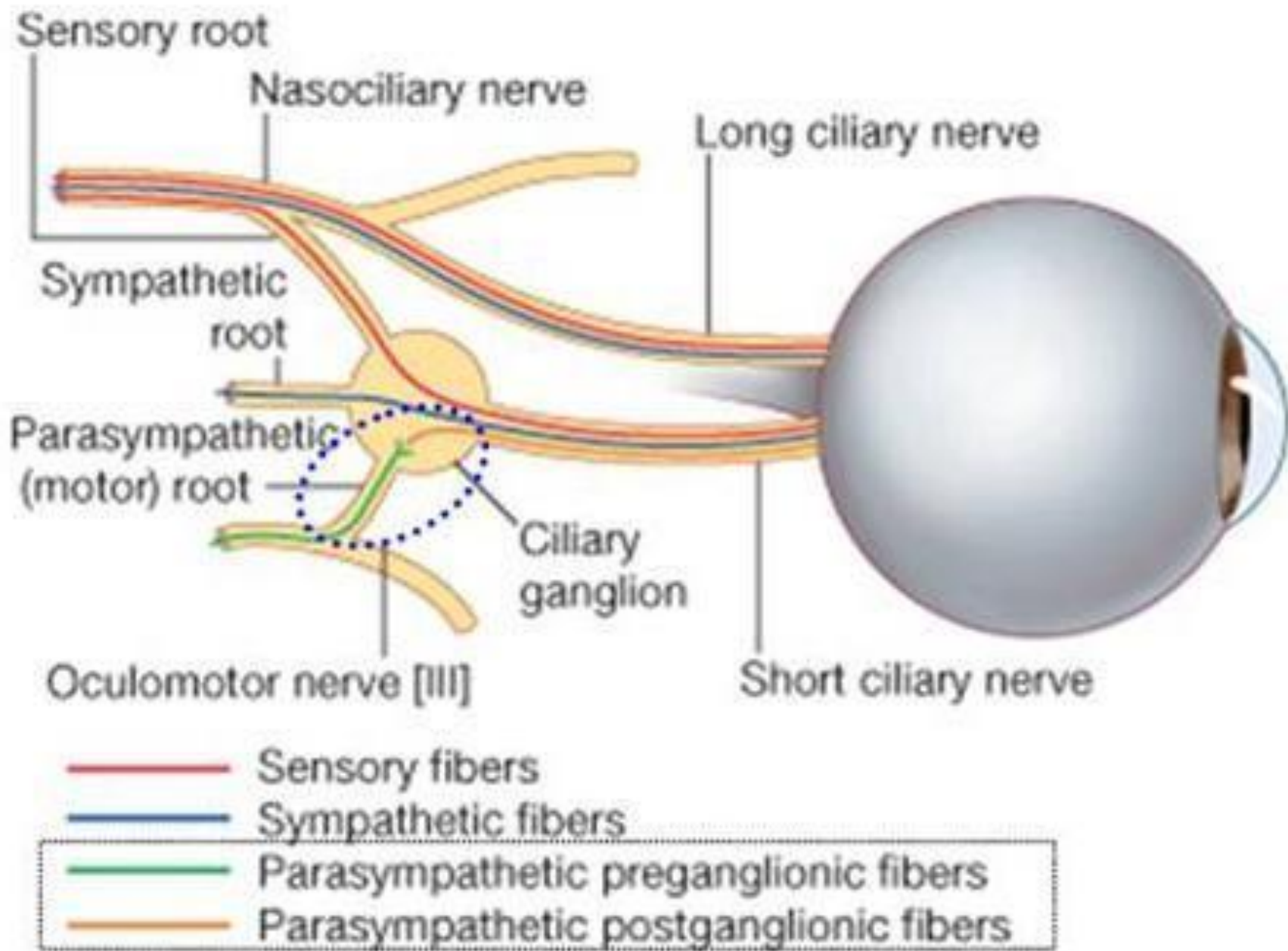


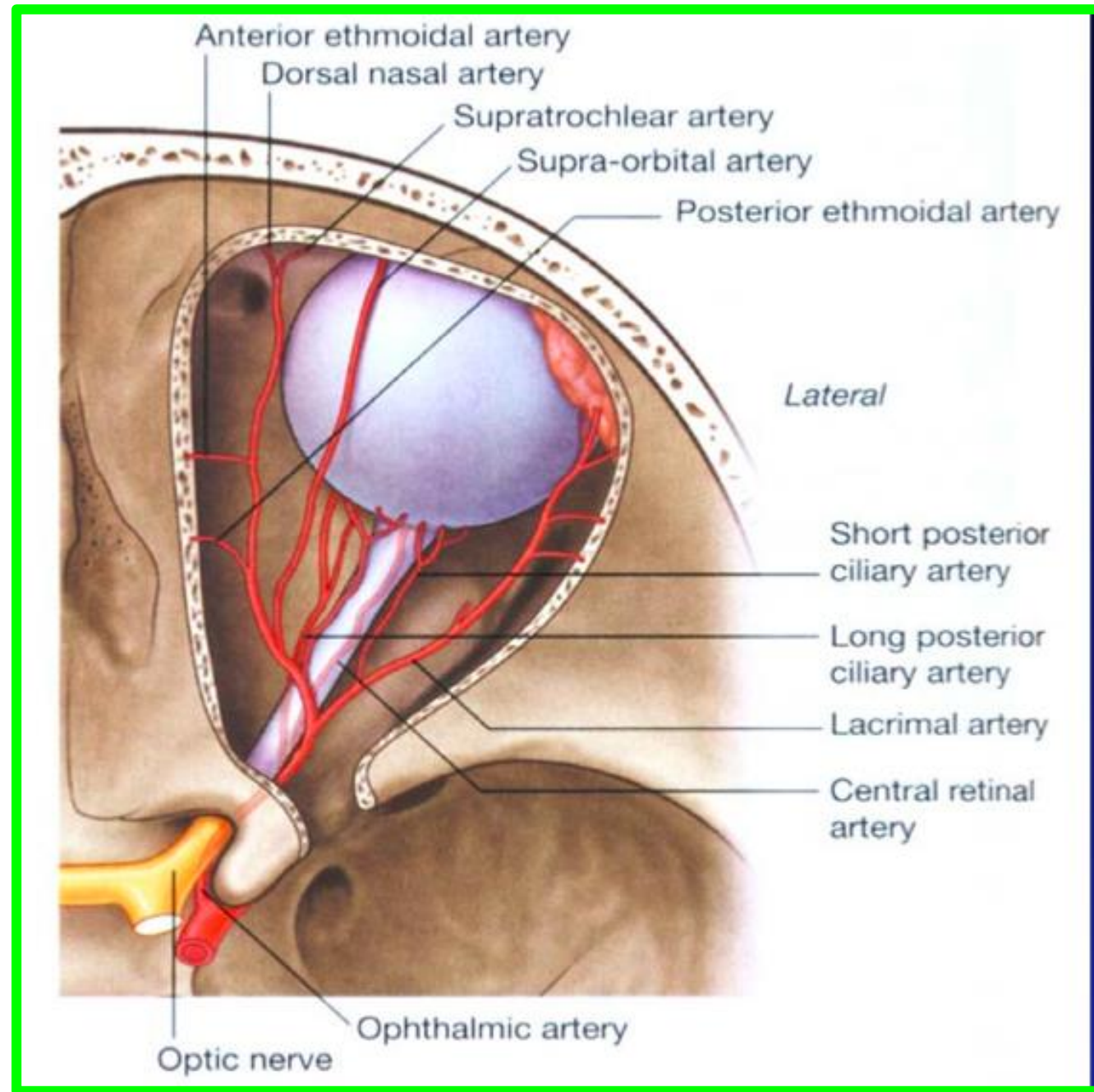
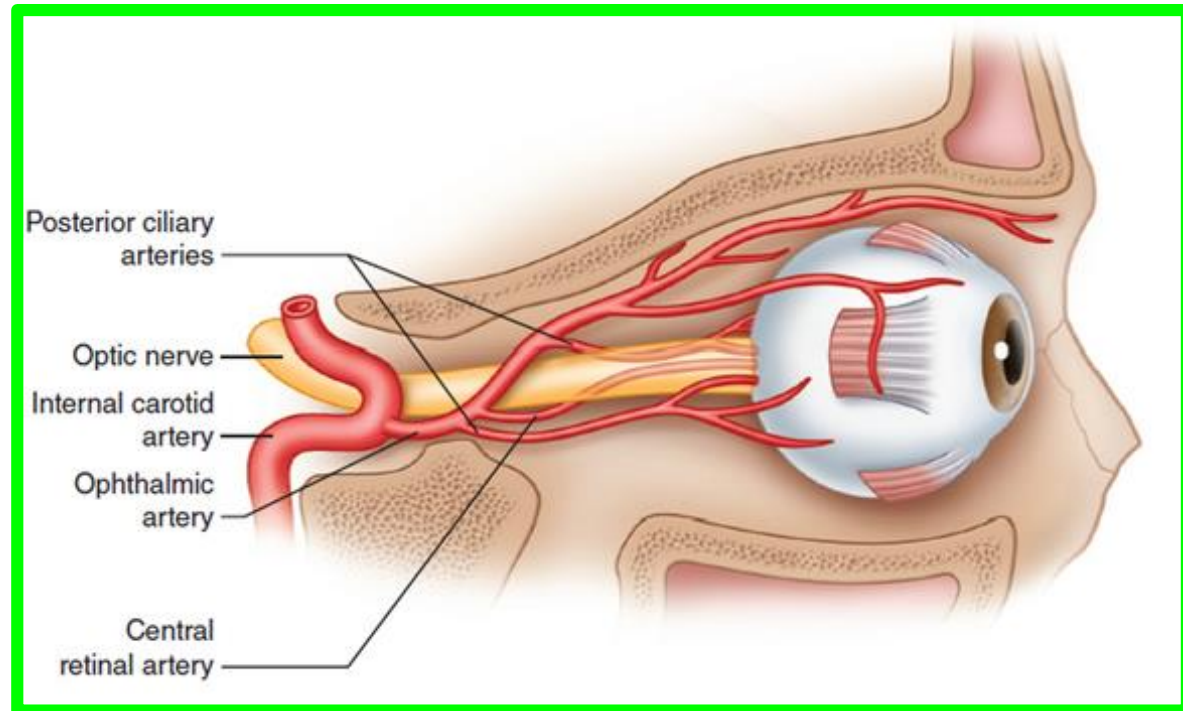


**(b)**

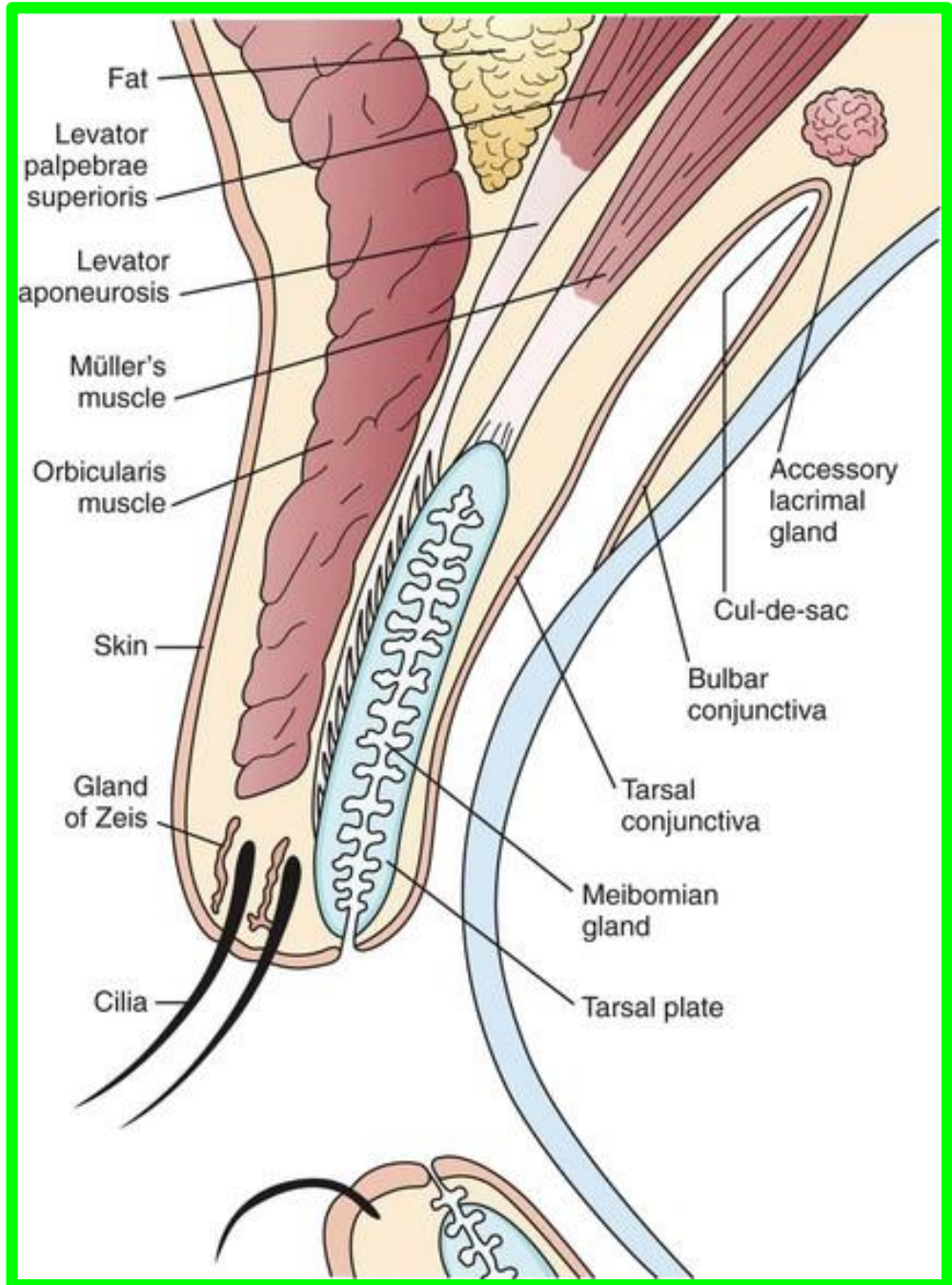
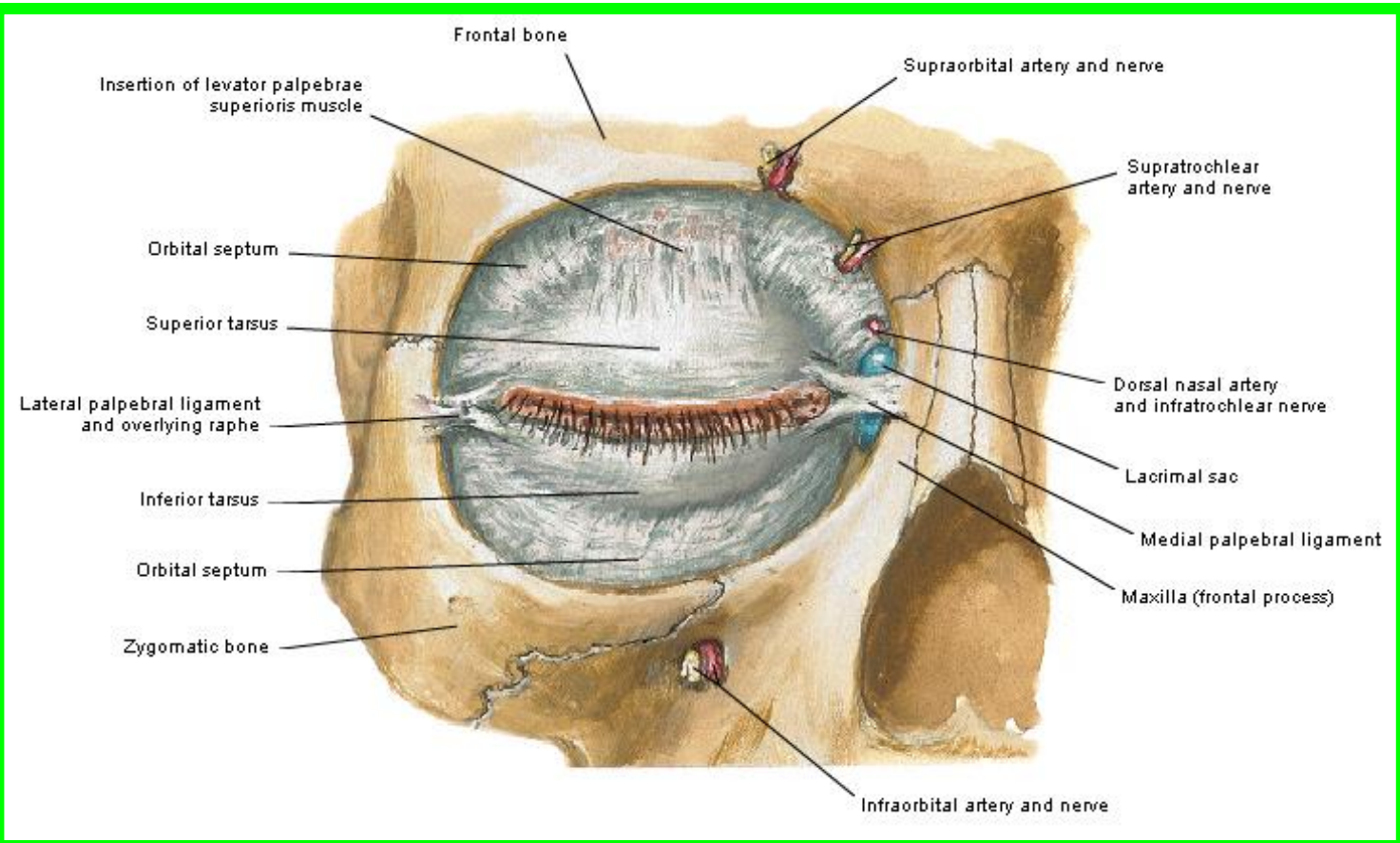
**A****C****B****D**



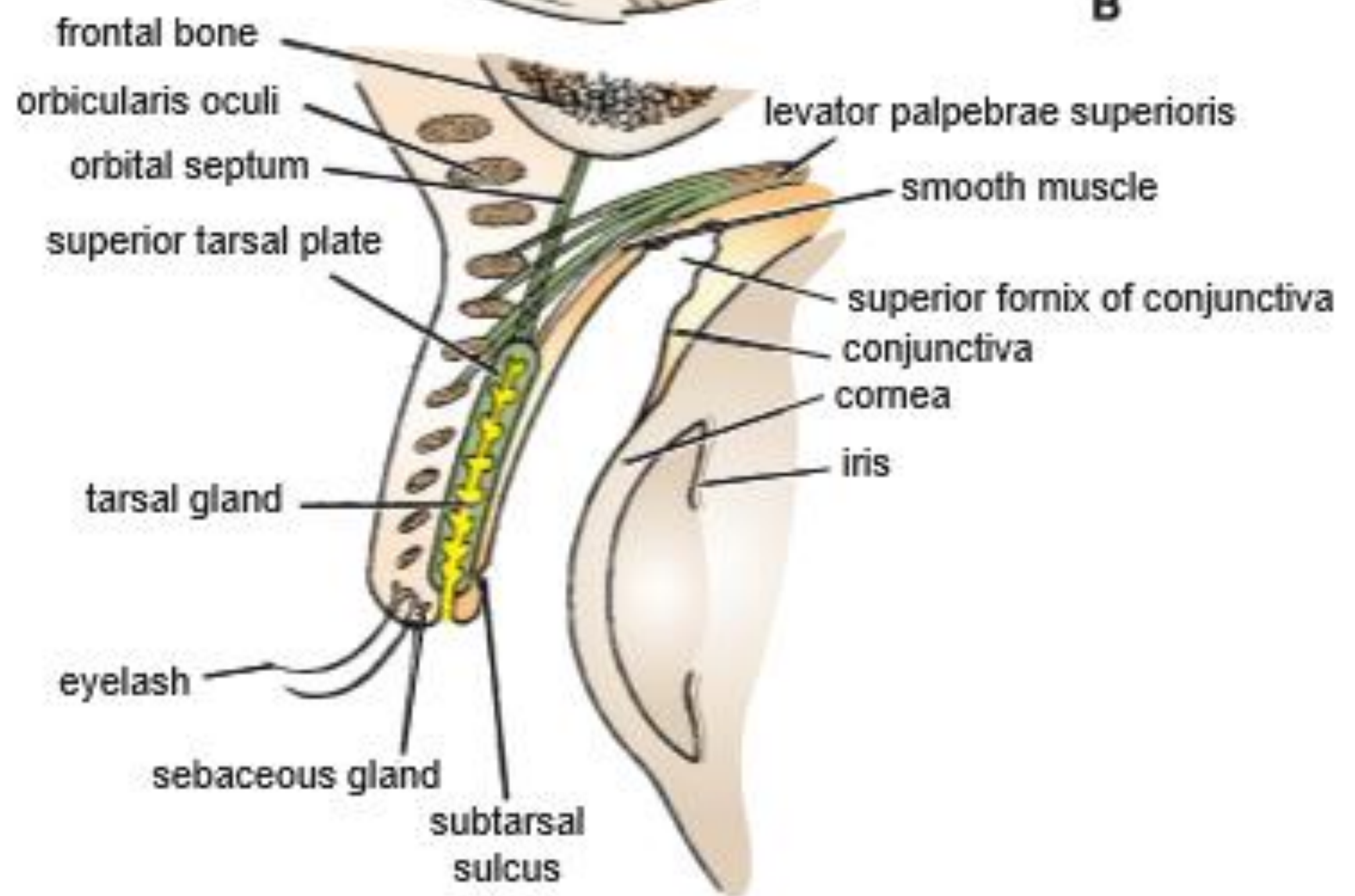




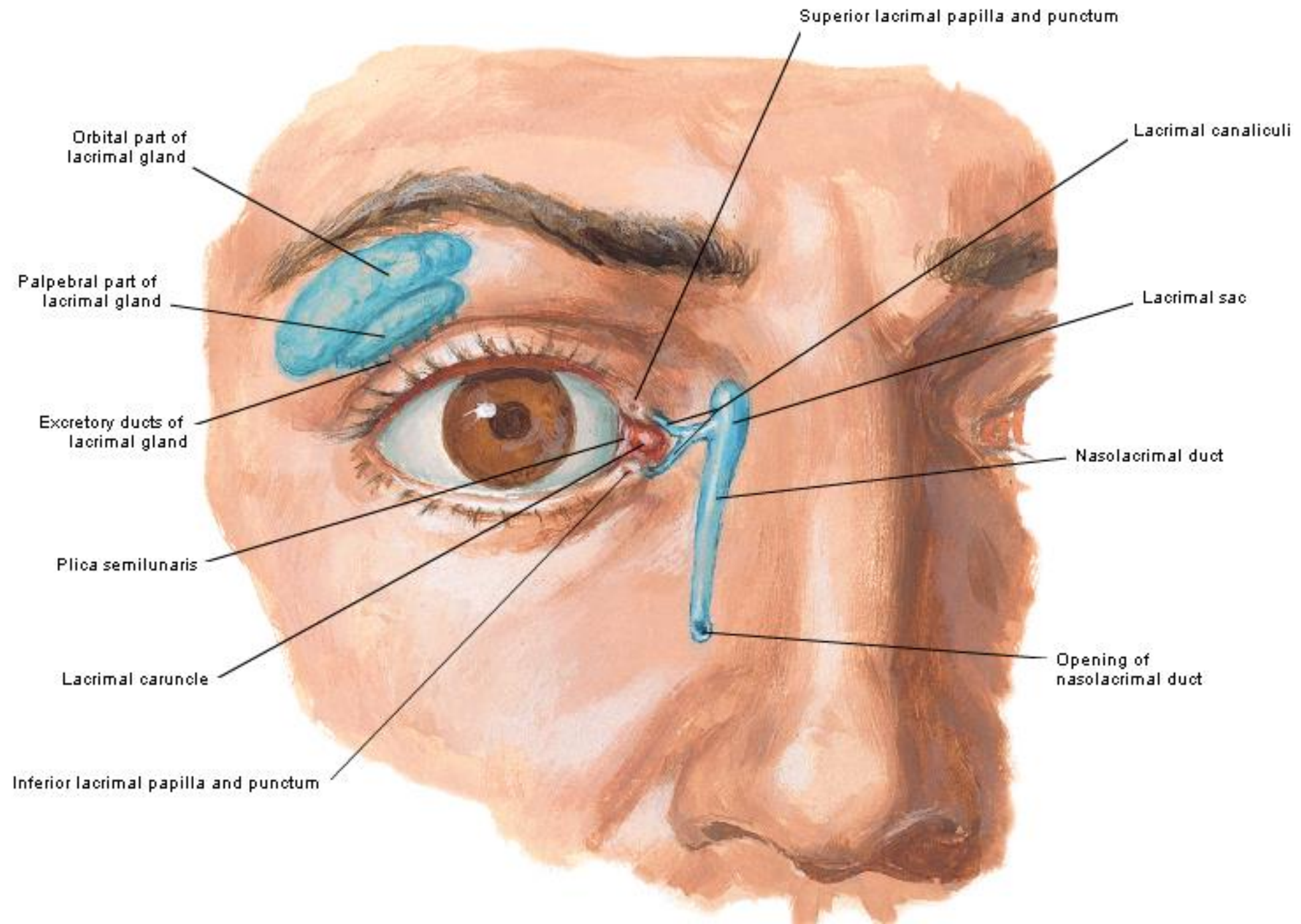




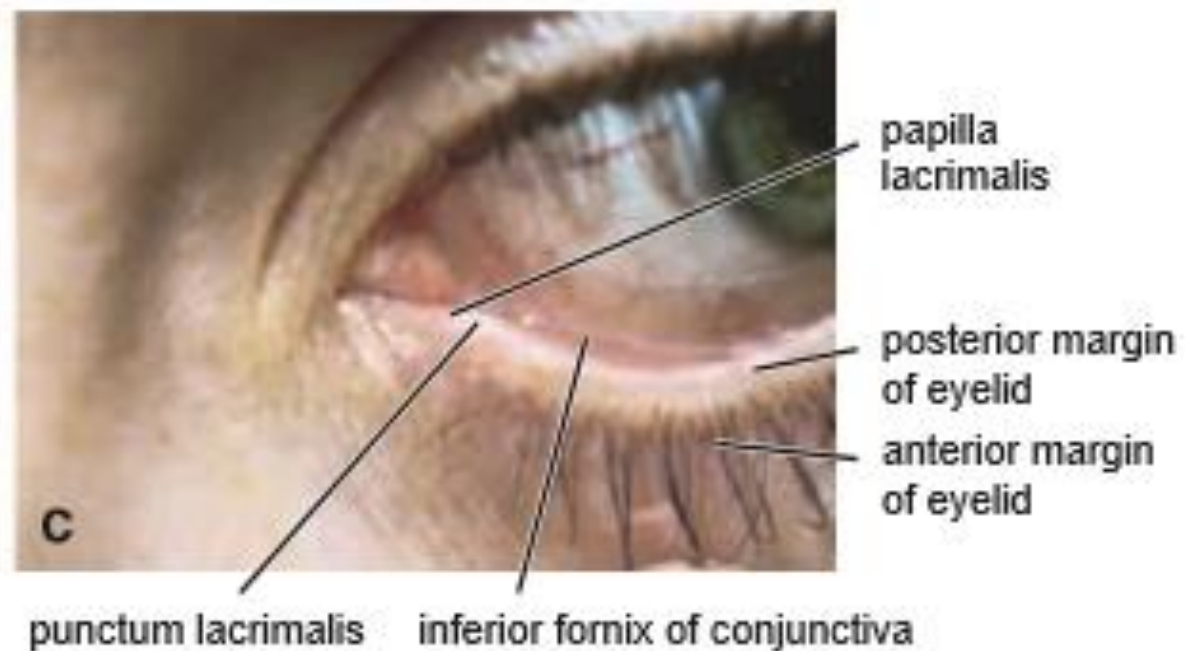
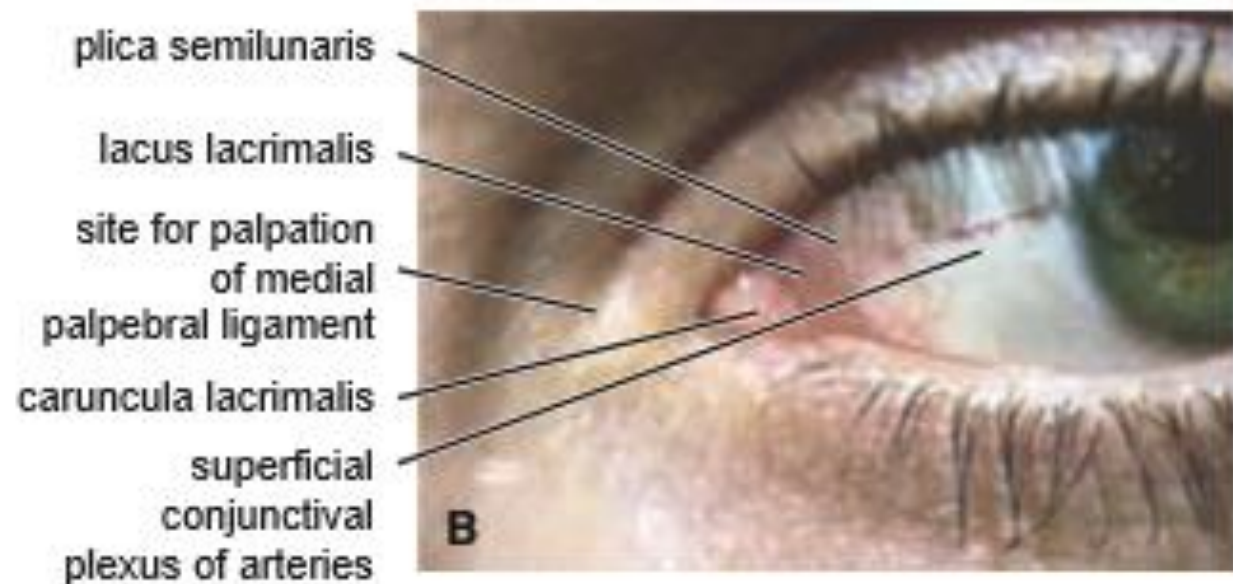
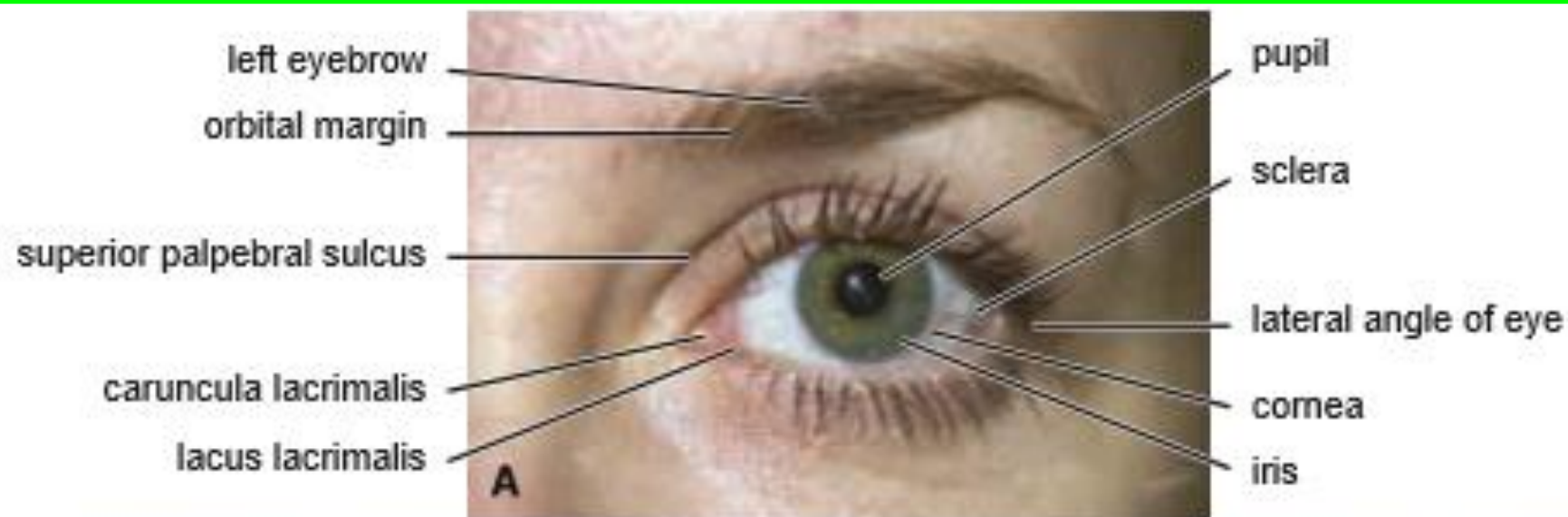
**B**

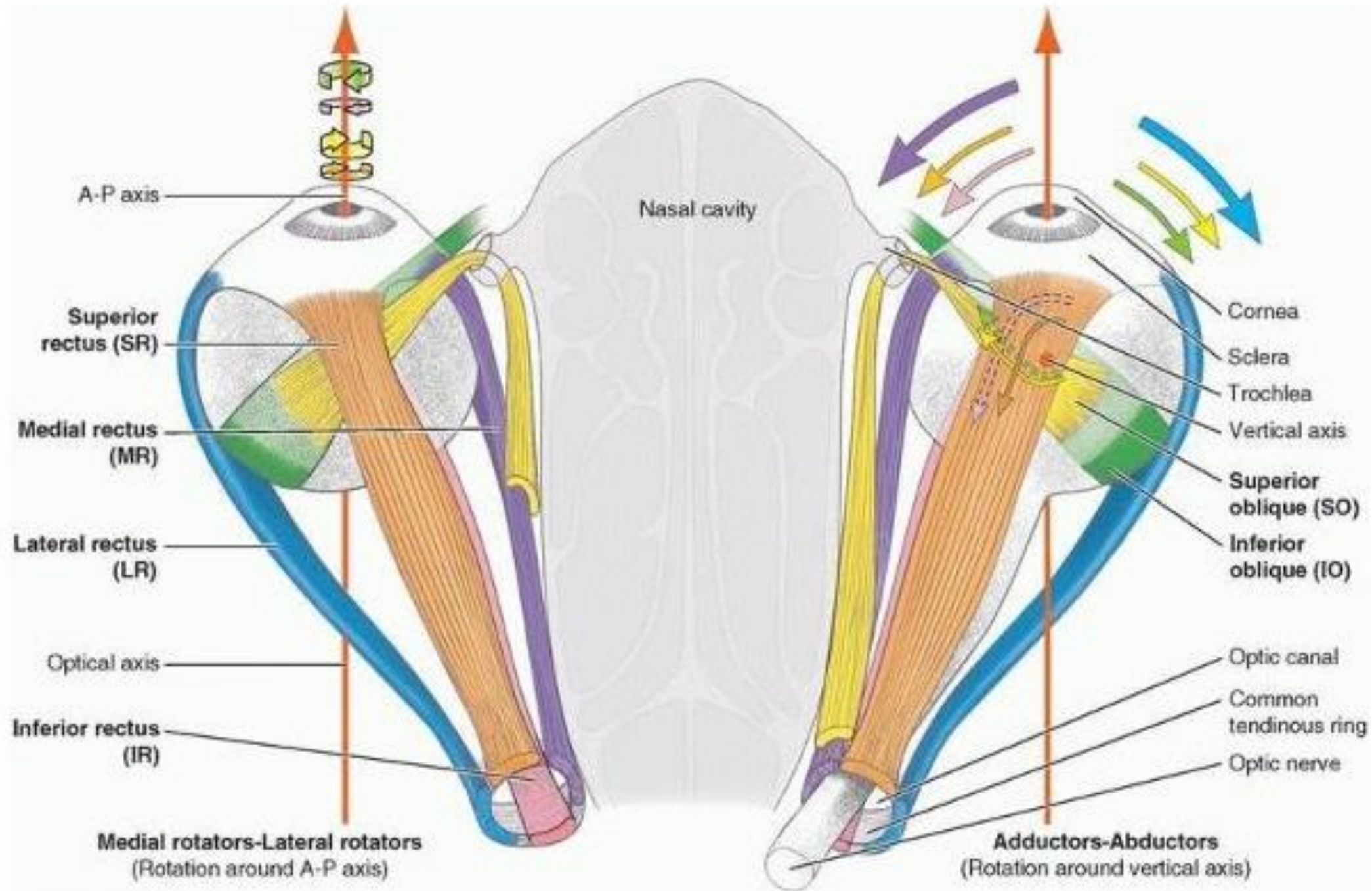






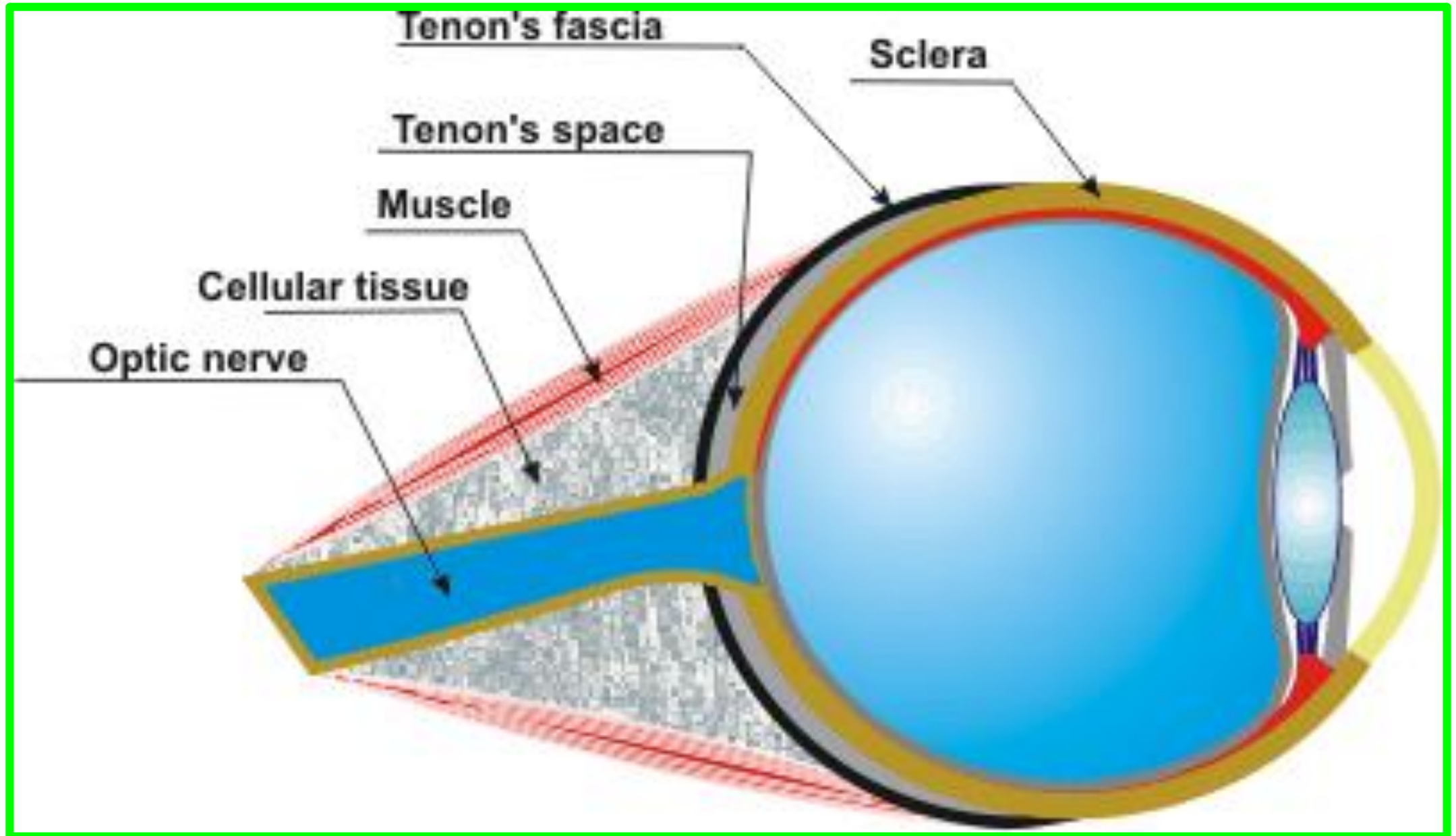






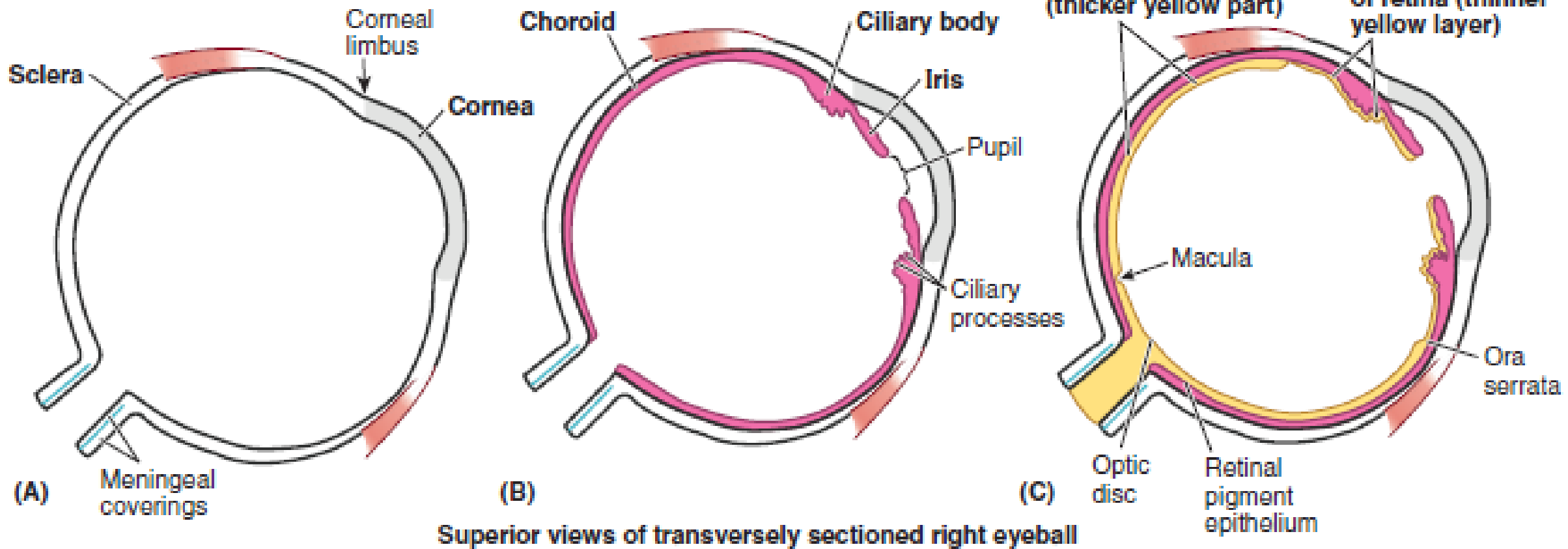


# *fascial suspensory apparatus*





Fibrous layer  
 Vascular layer  
 Inner layer of eyeball



**FIGURE 7.26.** Layers of eyeball. A. Outer fibrous layer. B. Middle vascular layer. C. Inner layer (retina).

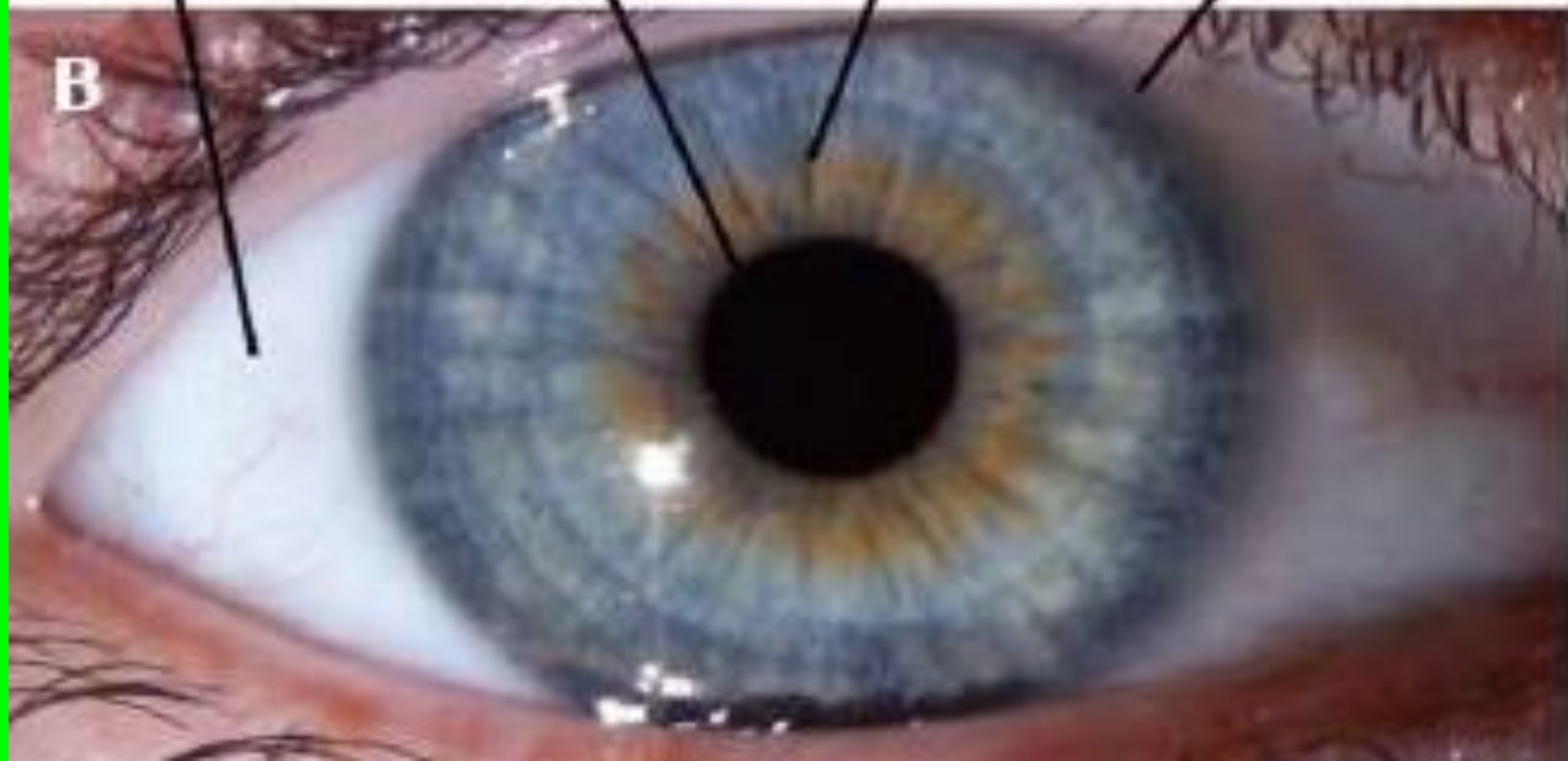
Sclera

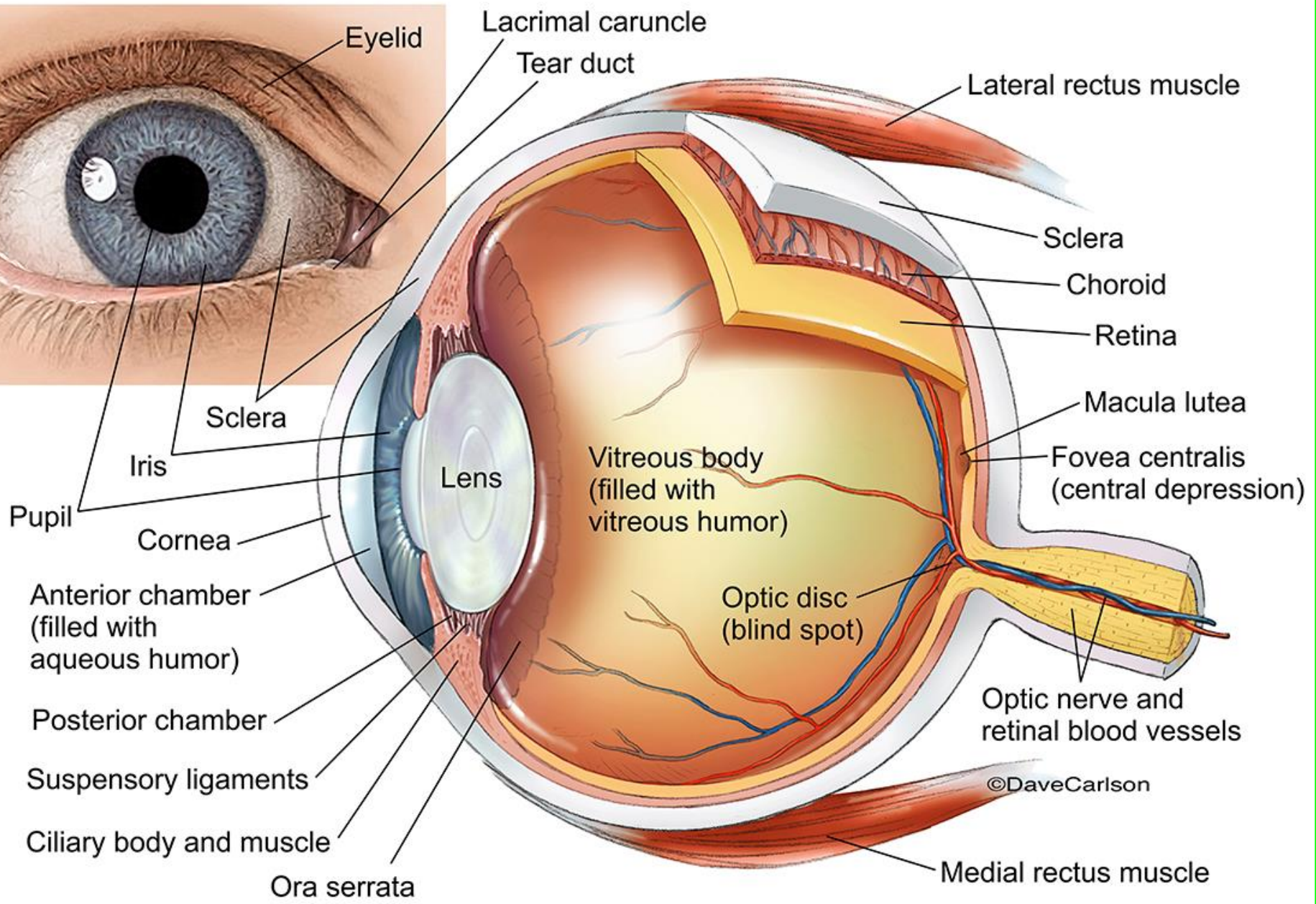
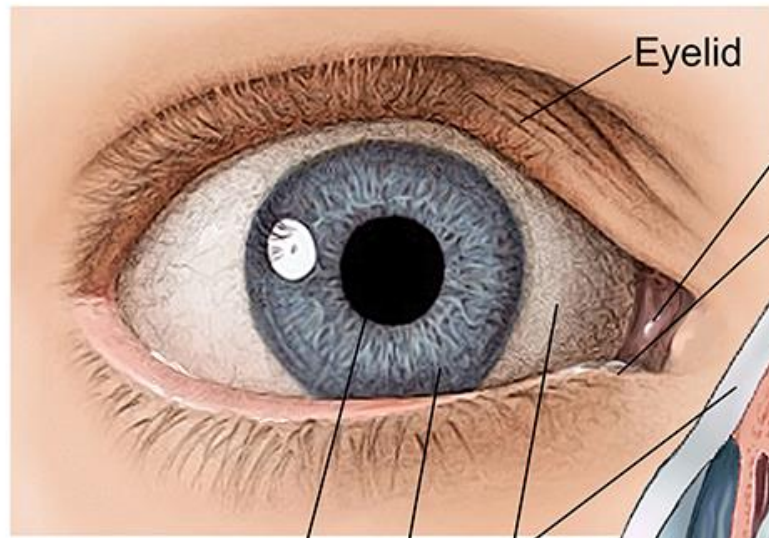
Pupil

Iris

Limbus

B

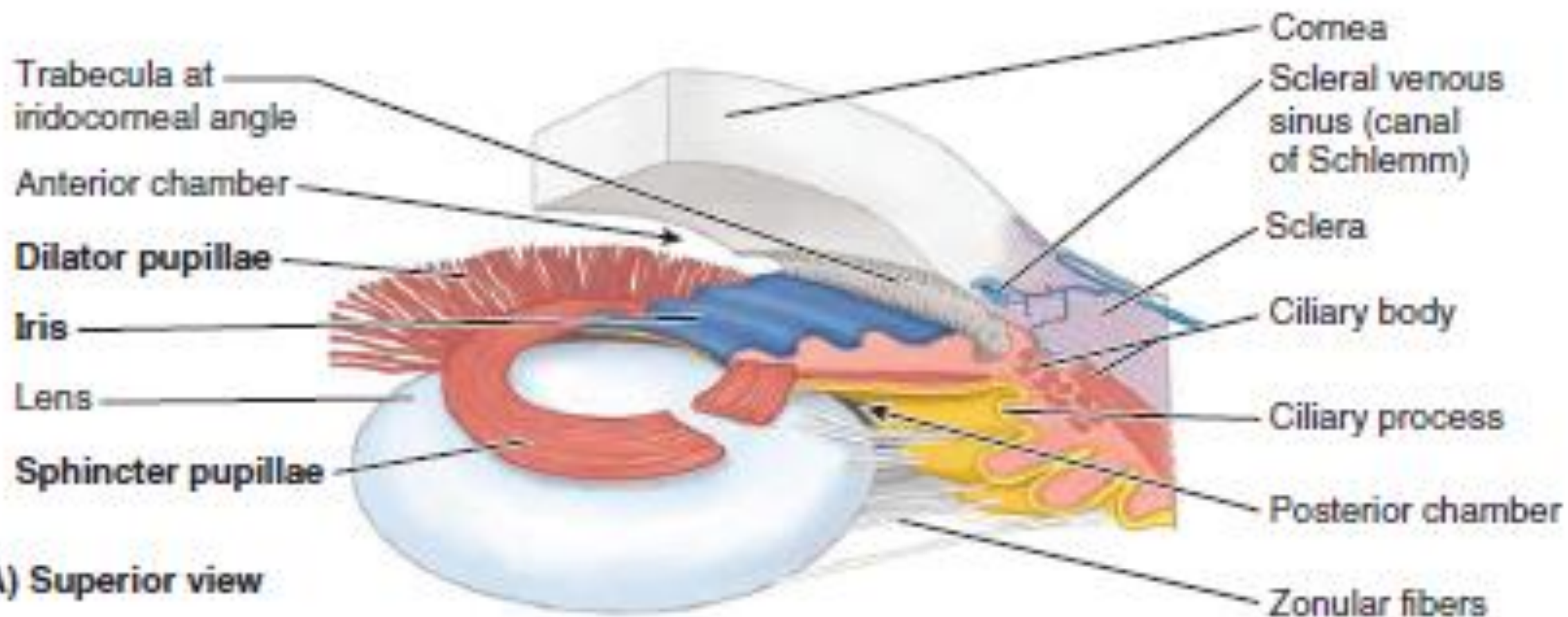


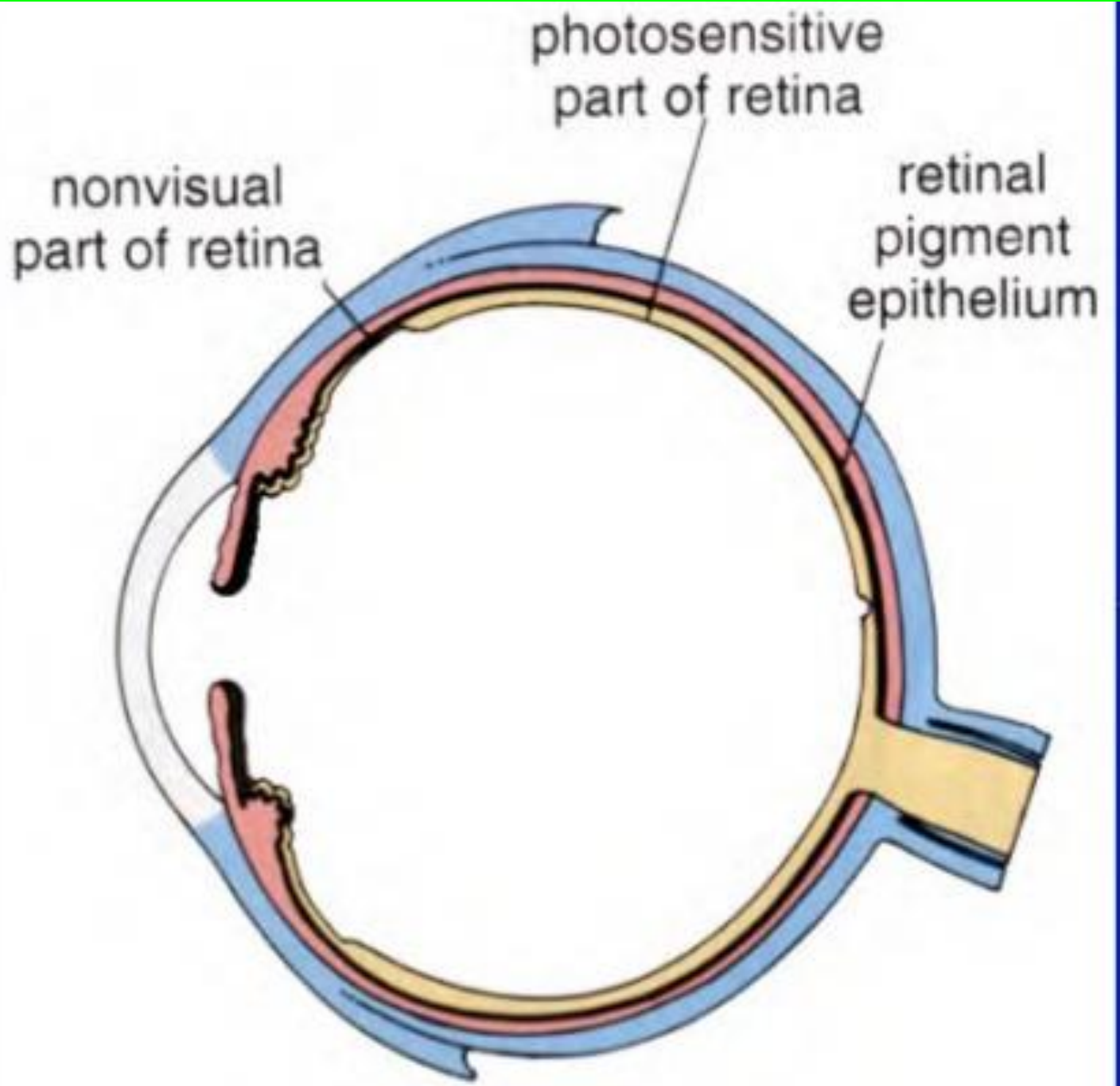


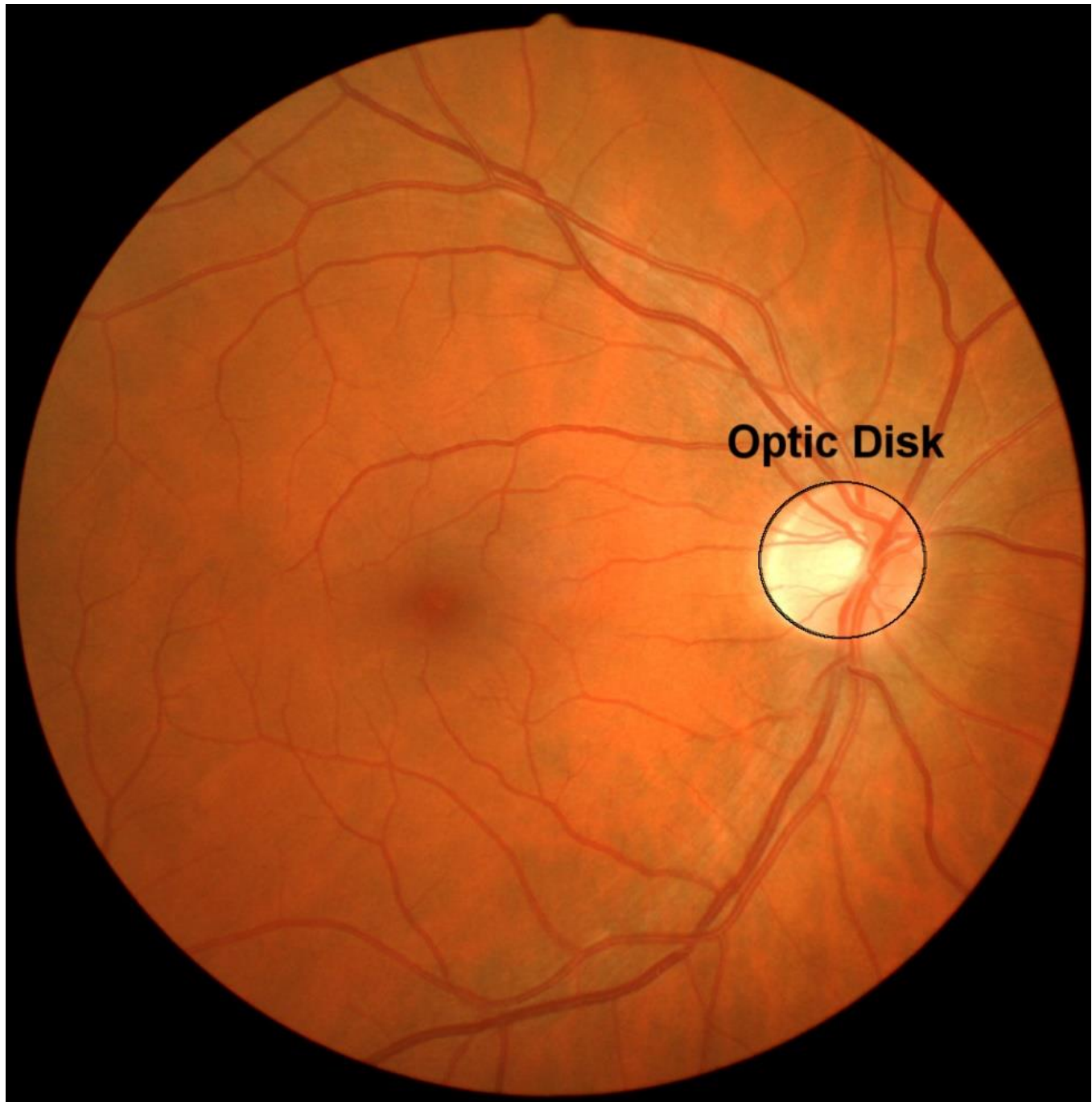
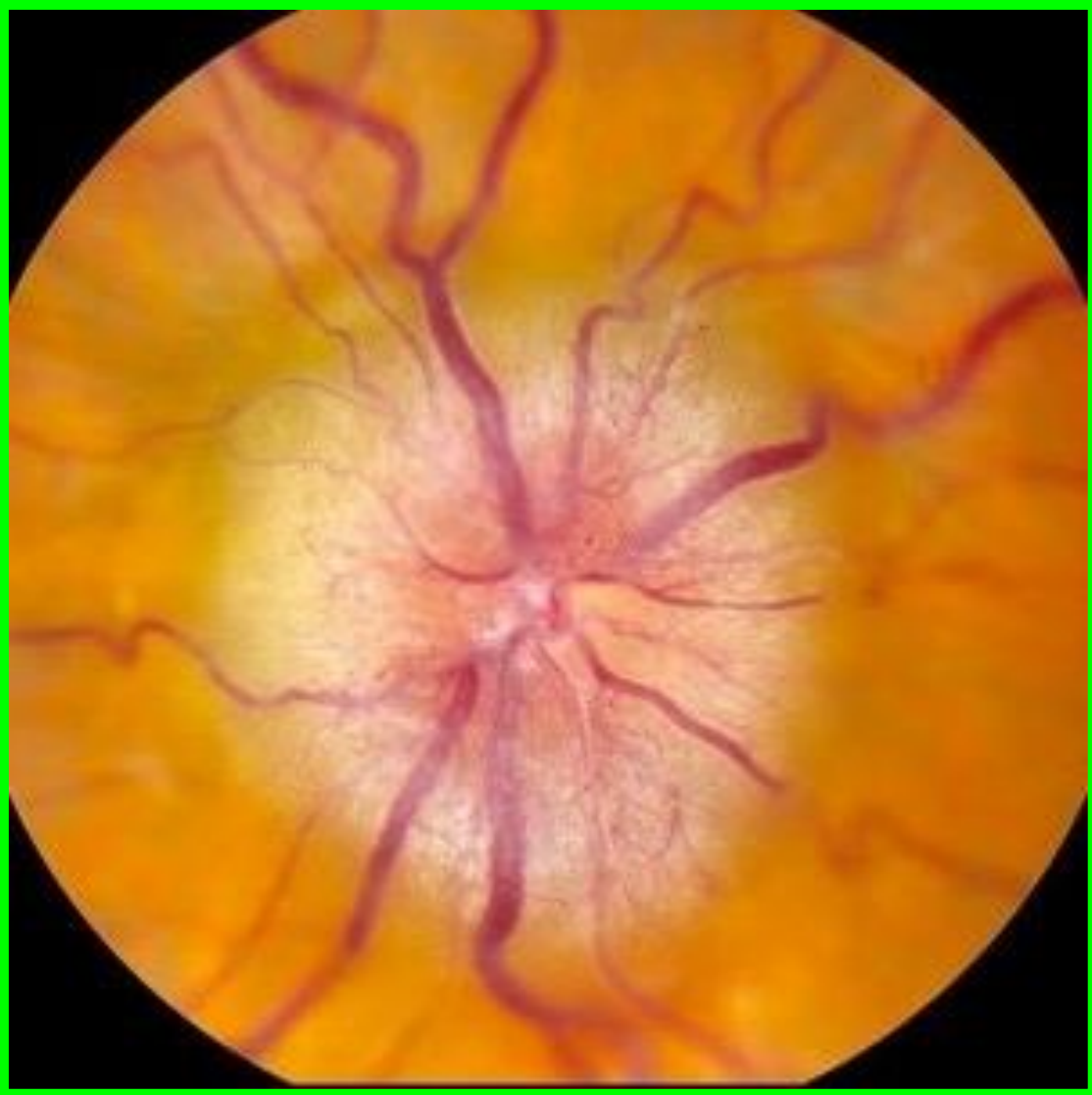**Right Eye (viewed from above)**

©DaveCarlson

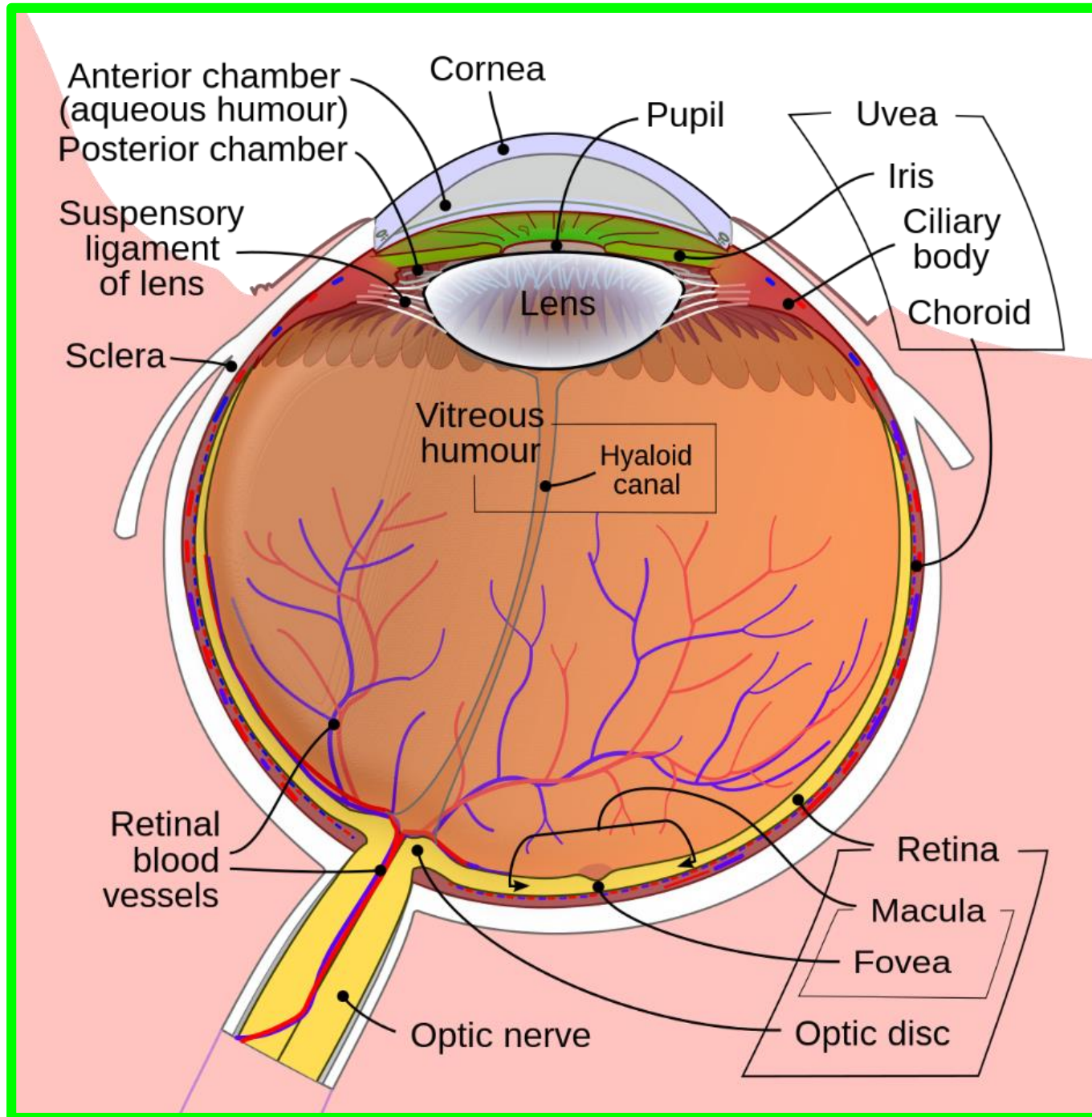














**Dr. Aiman Qais Afar**  
**9 March 2023**

