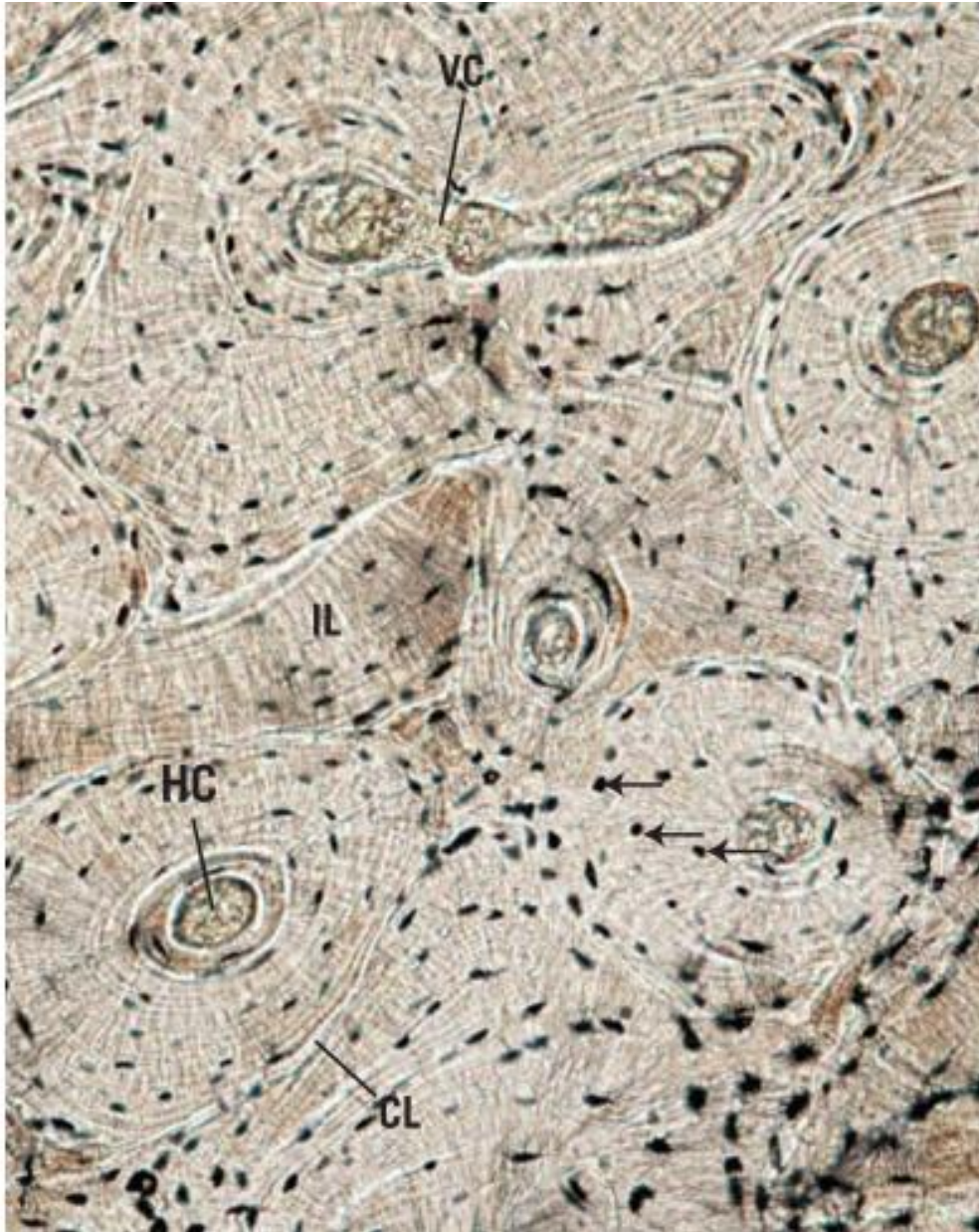

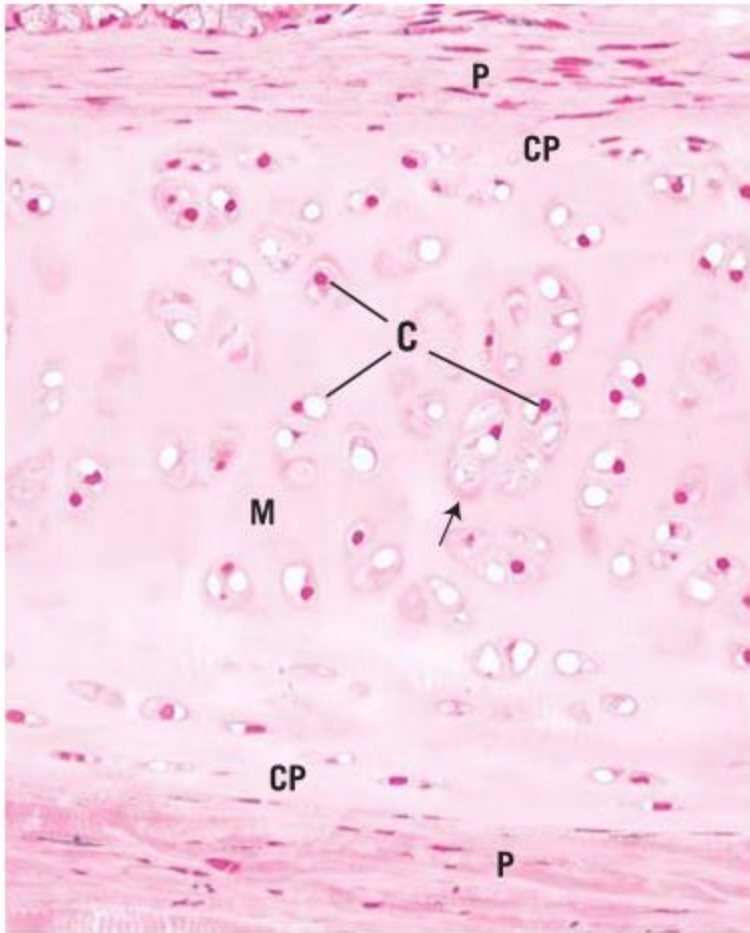
MSS HISTOLOGY 2023

LEC 4/LAB

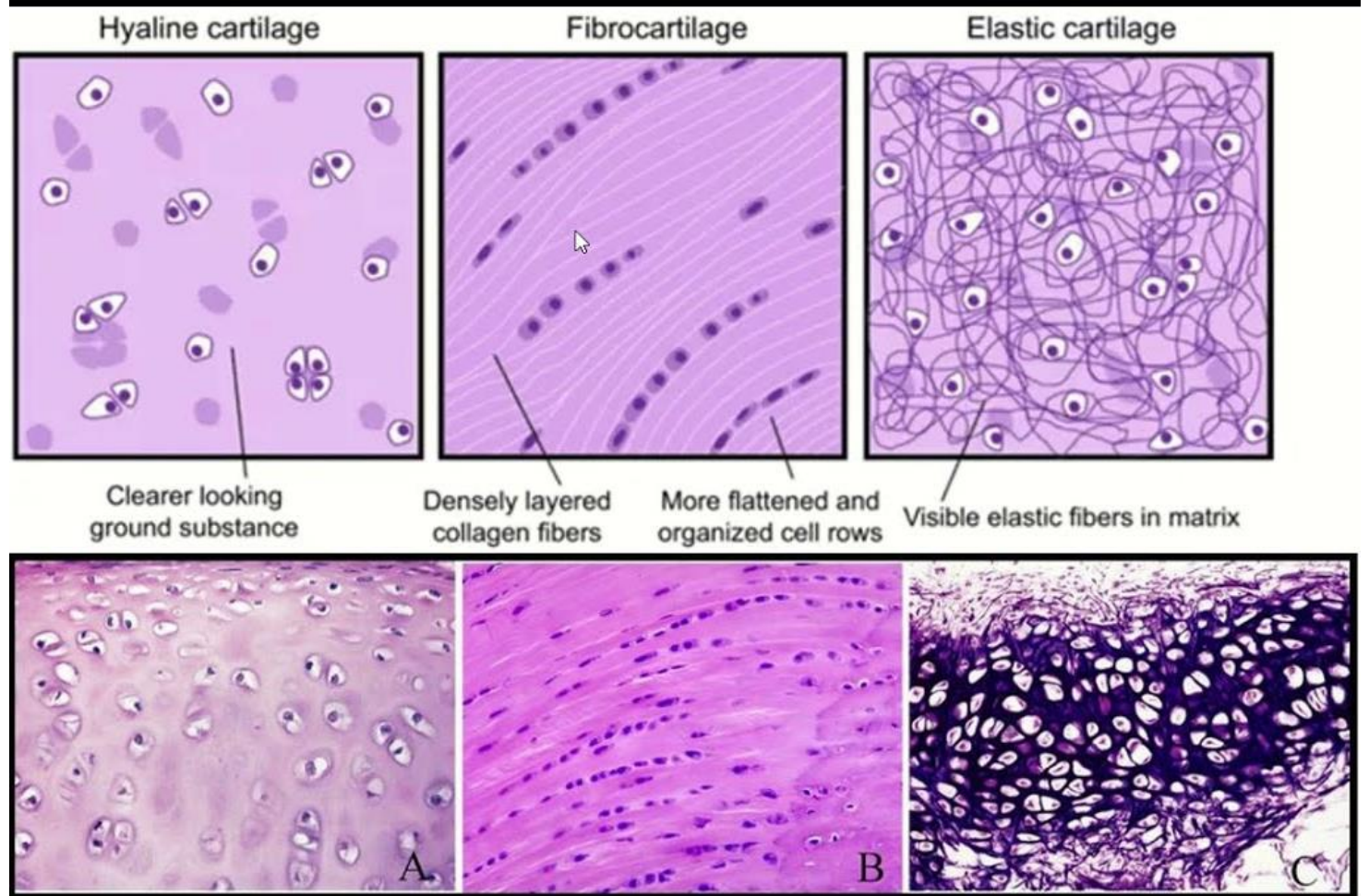
Dr AMAL ALBTOOSH

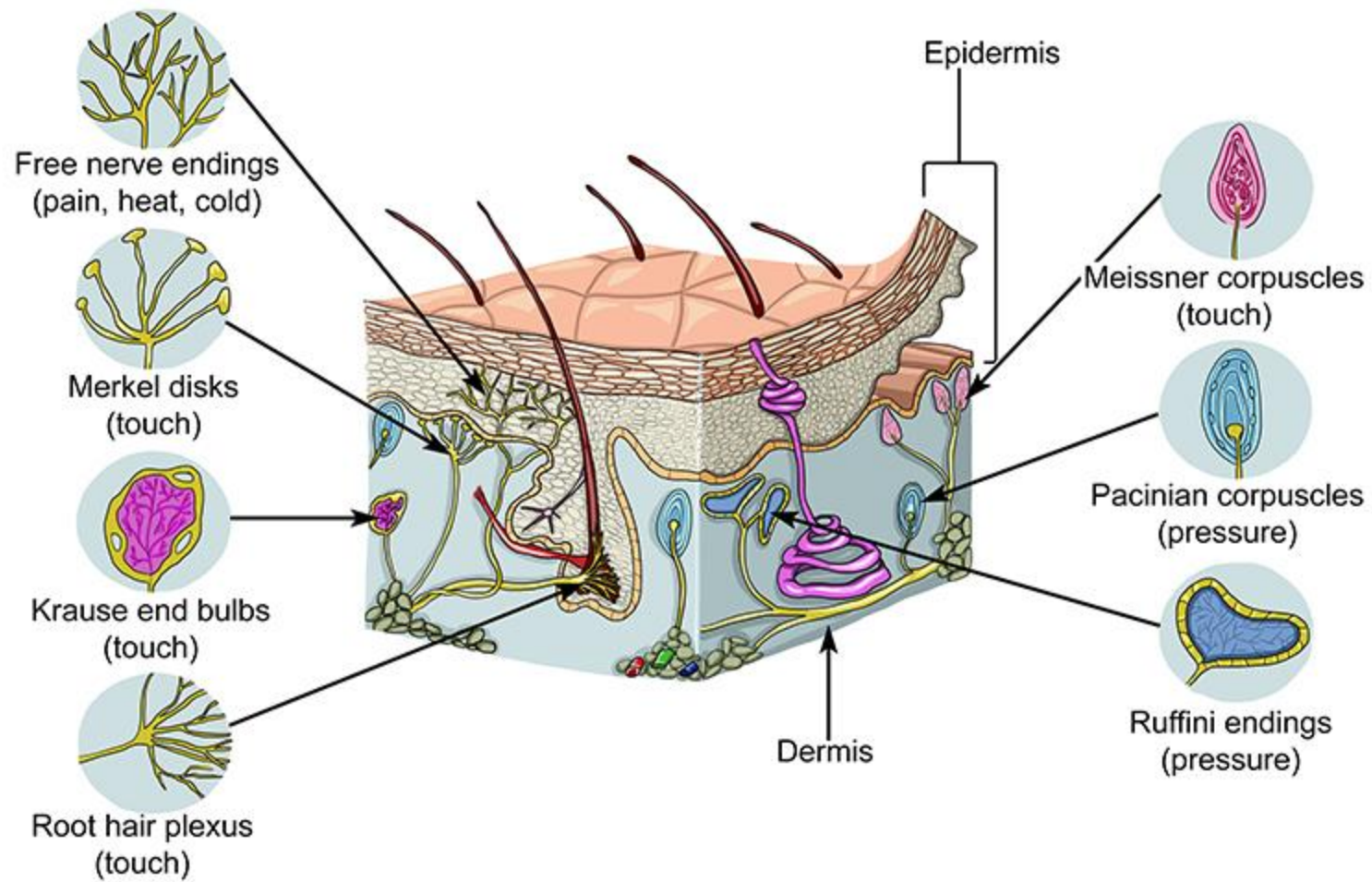


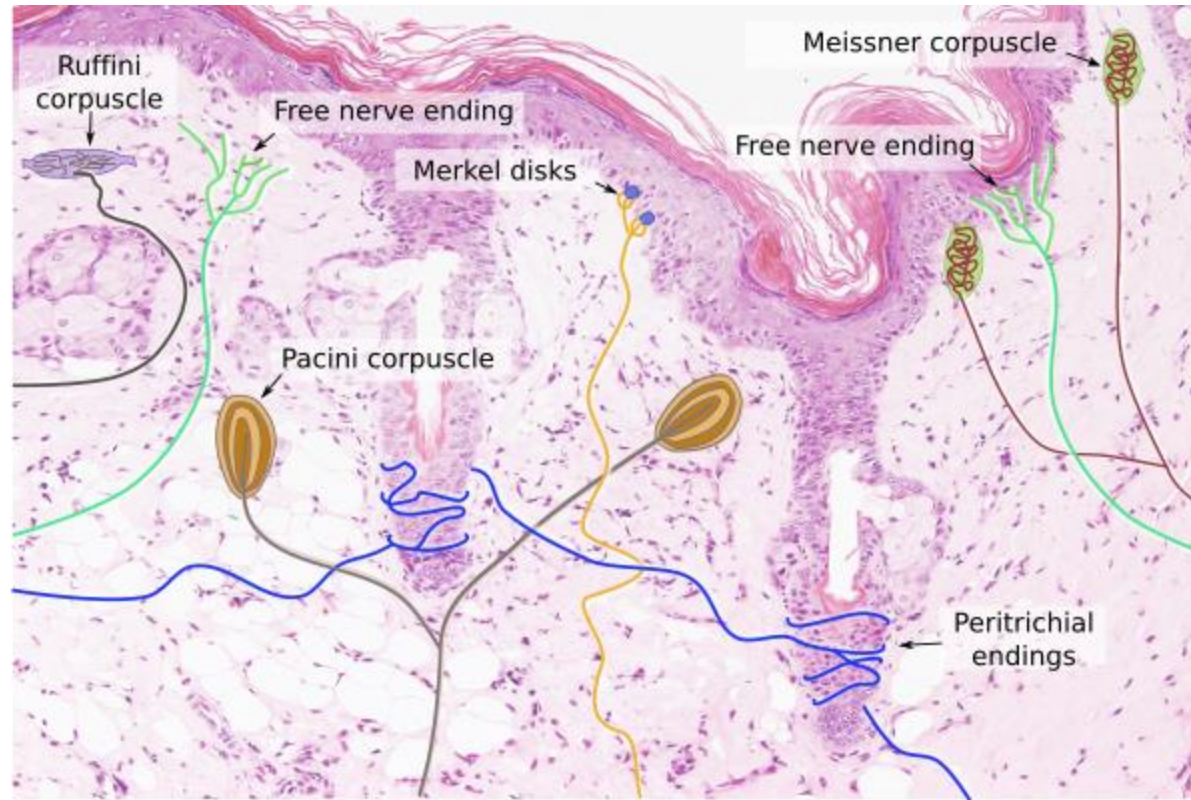
Light micrograph of ground bone. Observe the haversian canal (HC), cementing line (CL), interstitial lamellae (IL), Volkmann canal (VC), and osteocytes within lamellae (arrows).



Light micrograph of hyaline cartilage. Observe the chondrocytes (C), perichondrium (P), chondrogenic perichondrium (CP). matrix (M), and the lacuna (arrow).







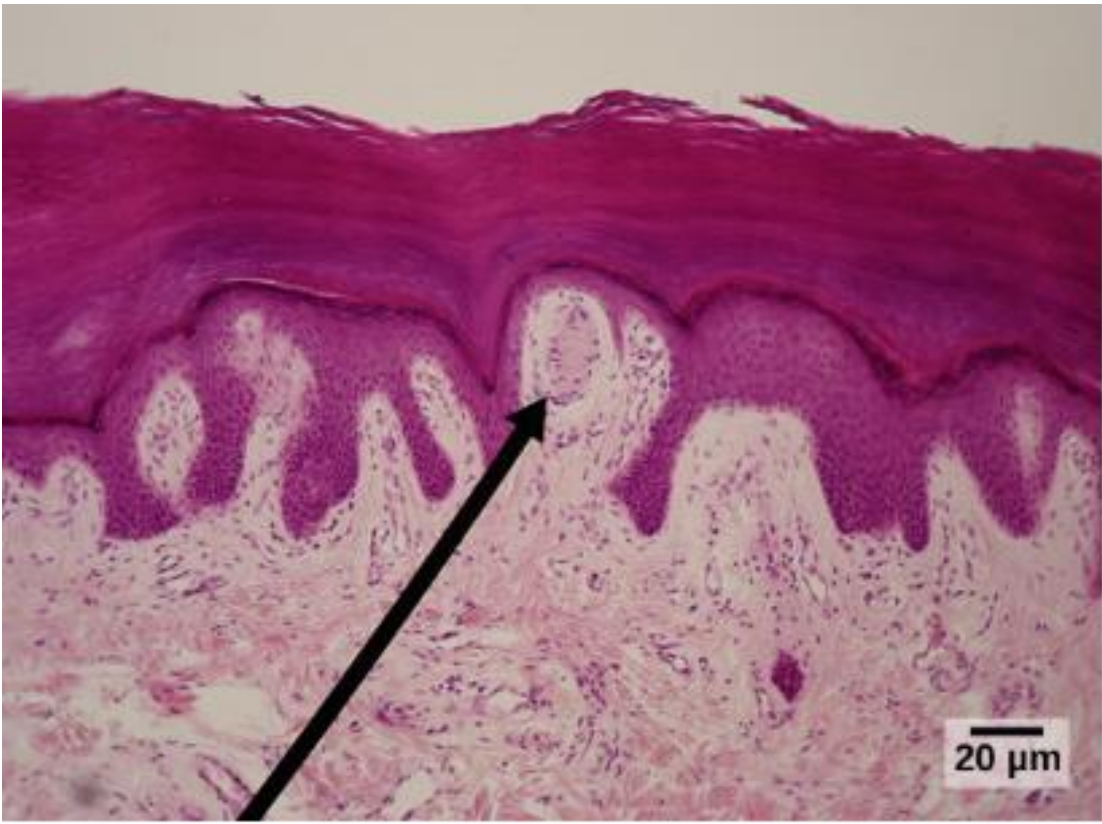


Figure 3. Meissner corpuscles in the fingertips, such as the one viewed here using bright field light microscopy, allow for touch discrimination of fine detail. (credit: modification of work by "Wbensmith"/Wikimedia Commons; scale-bar data from Matt Russell)

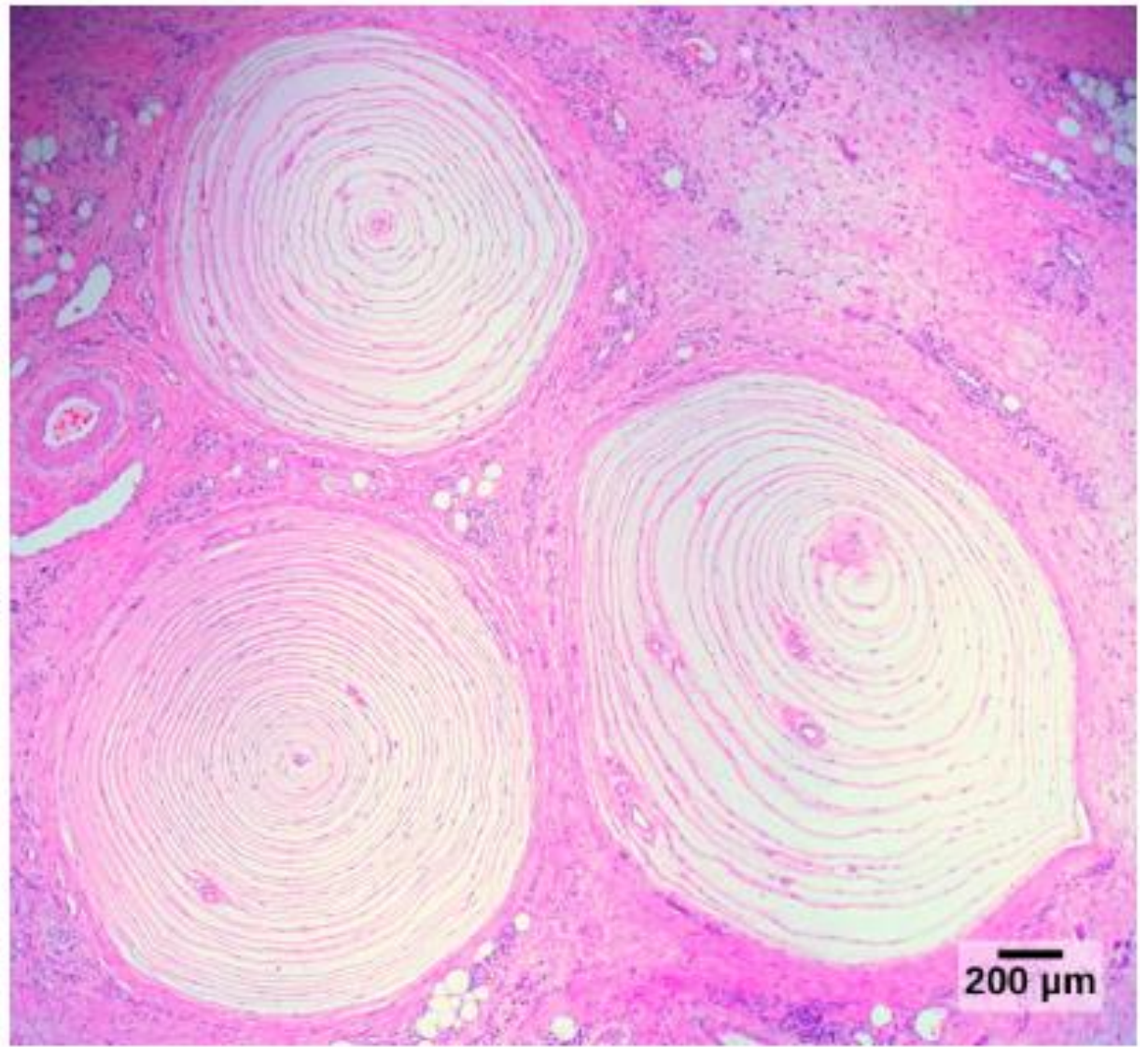


Figure 4. Pacinian corpuscles, such as these visualized using bright field light microscopy, detect pressure (touch) and high-frequency vibration. (credit: modification of work by Ed Uthman; scale-bar data from Matt Russell)

