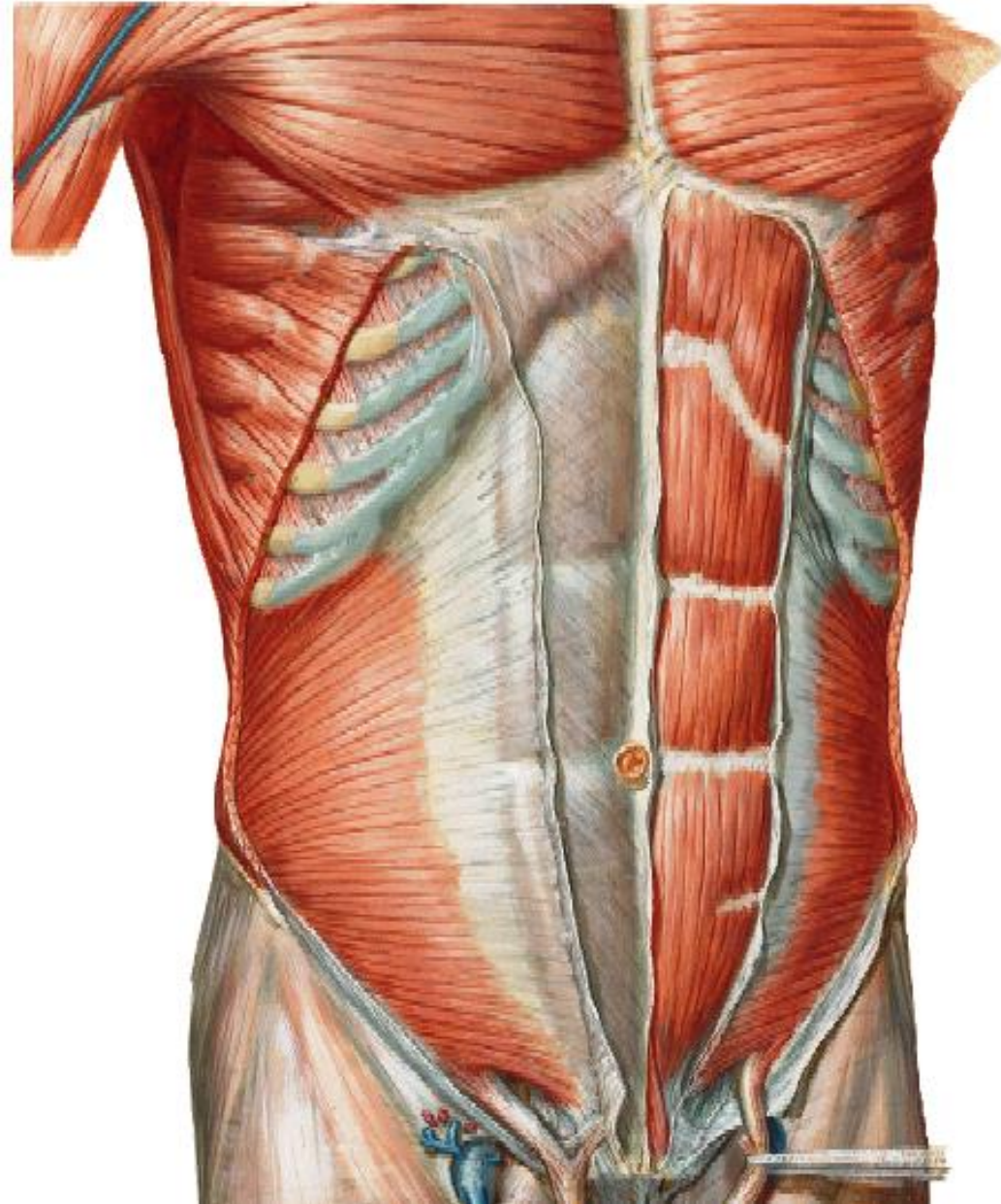


ANT. ABD. WALL & RECTUS SHEATH



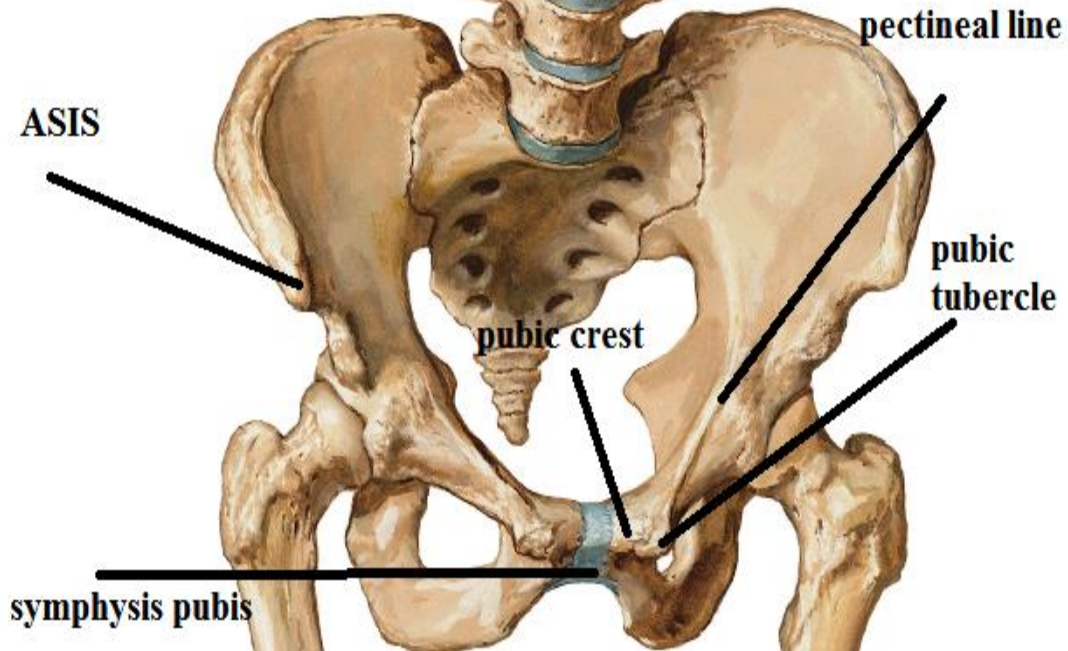
BY

DR ABULMAATY MOHAMED
ASSISTANT PROFESSOR
ANATOMY & EMBRYOLOGY
MUTAH UNIVERSITY

SKELETON

xiphoid
process

costal
margin



ANTERIOR ABDOMINAL WALL

layers:- "from outside inwards"

skin.

superficial fascia: which divides into

Superficial fatty layer

deep membranous layer

N.B.: deep fascia is absent

to allow distension of some organs e.g. uterus.

muscles:

Lateral part:

ext. oblique.

int. oblique

transversus abdominis

Fascia transversalis.

Extra peritoneal fat.

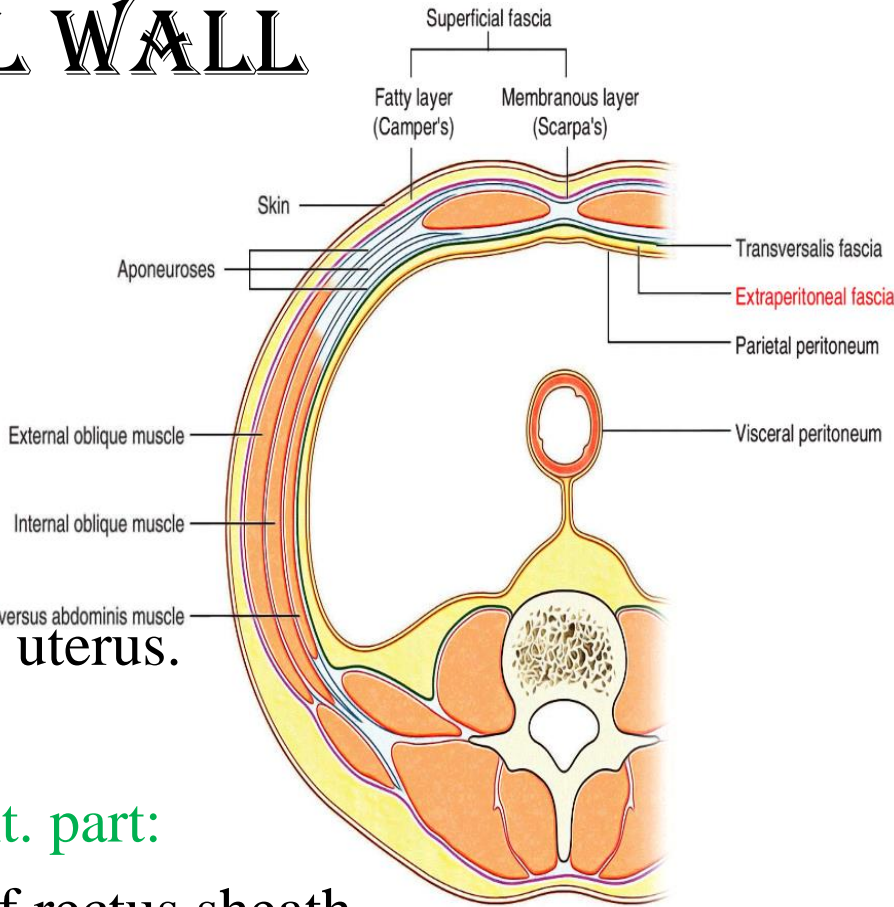
Parietal peritoneum.

ant. part:

ant. Wall of rectus sheath

rectus abdominis & pyramidalis

post. Wall of rectus sheath



ANTERIOR ABDOMINAL WALL

MUSCLES

Vertical muscles

1-Rectus abdominis

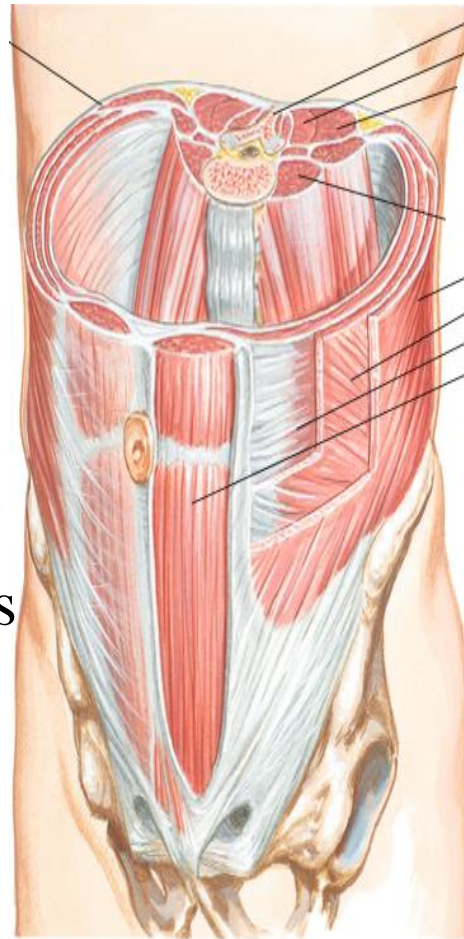
2- Pyramidalis

Flat muscles

External oblique

Internal oblique

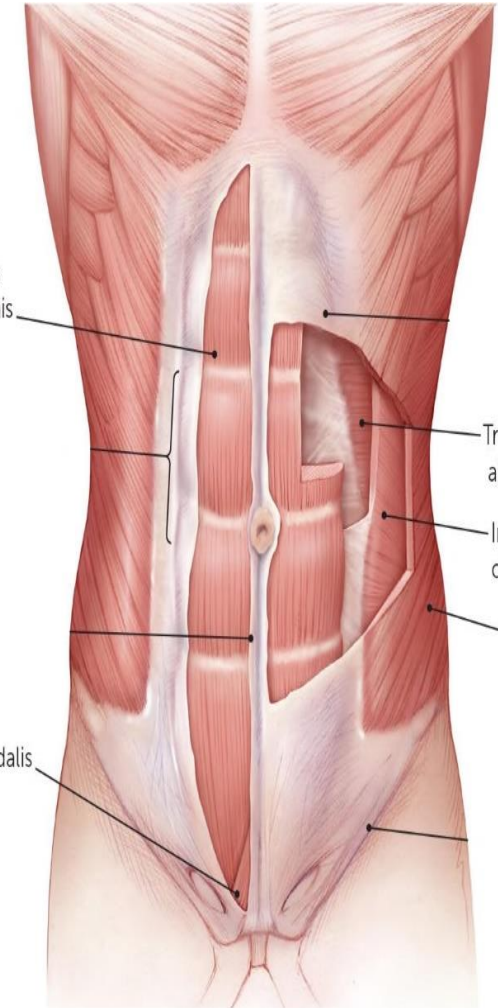
Transversus abdominis



External obliq
Internal obliq
Transversus
Rectus abdom

Rectus
abdominis

Pyramidalis



Transversus
abdominis

Internal
oblique

External
oblique

ANTERIOR ABDOMINAL WALL

RECTUS ABDOMINIS

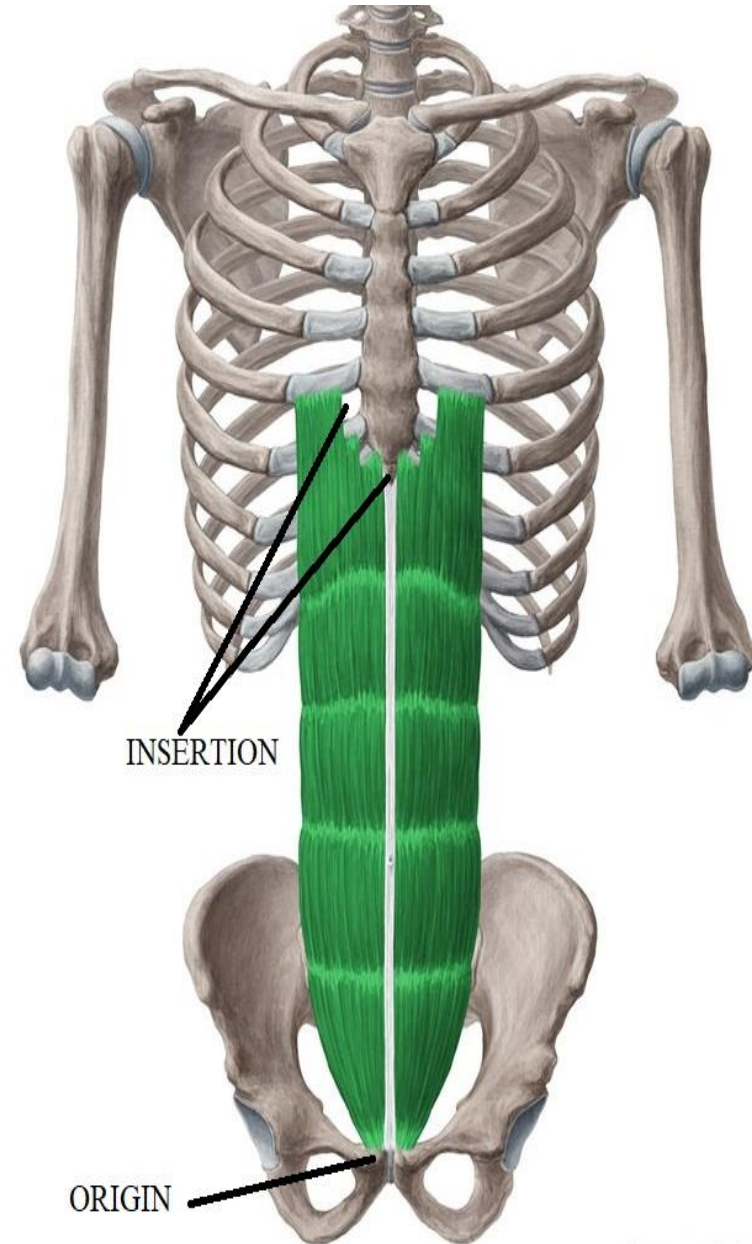
O.:-

1-medial head:- symphysis pubis

2-lateral „ :- pubic crest

I.:-

Front of 5, 6,7 c.c. &
xiphoid process



ANTERIOR ABDOMINAL WALL

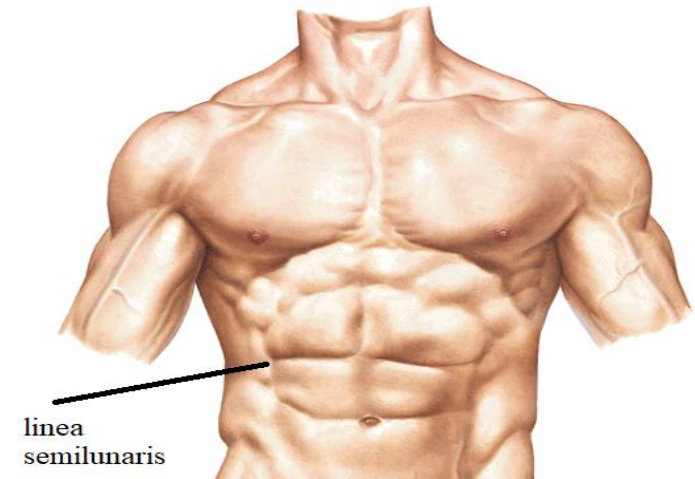
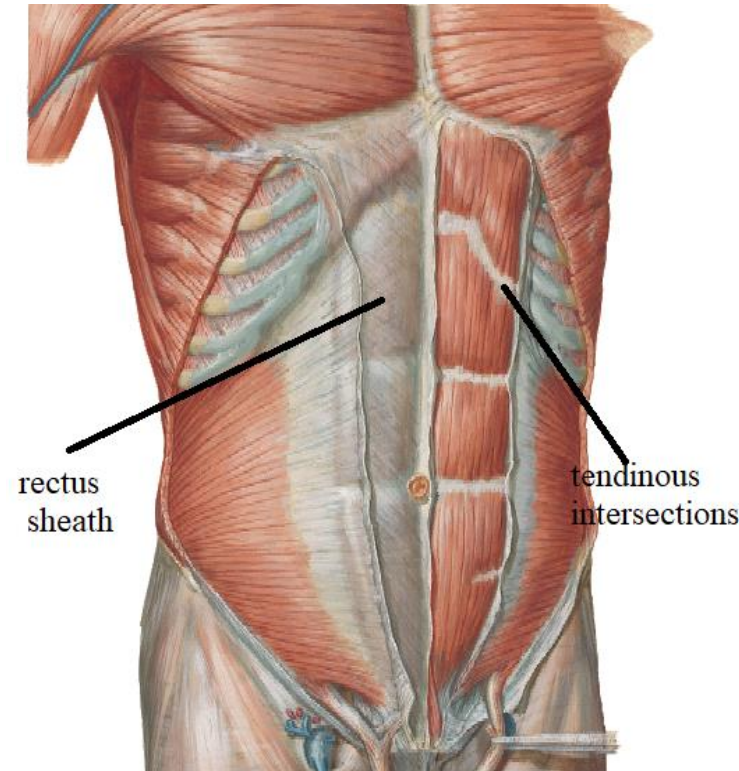
RECTUS ABDOMINIS

PARTICULAR FEATURES

- enclosed by rectus sheath
- divided by tendinous intersections:
- site:-
 - 1-at level of xiphoid process.
 - 2-at level of umbilicus.
 - 3-midway () xiphoid process &umbilicus
 - 4-below umbilicus (may be absent).
- These intersections attach to ant. wall of rectus sheath &seen only anteriorly.

linea semilunaris:

curved groove along lateral border of the muscle



ANTERIOR ABDOMINAL WALL

PYRAMIDALIS

O.:-

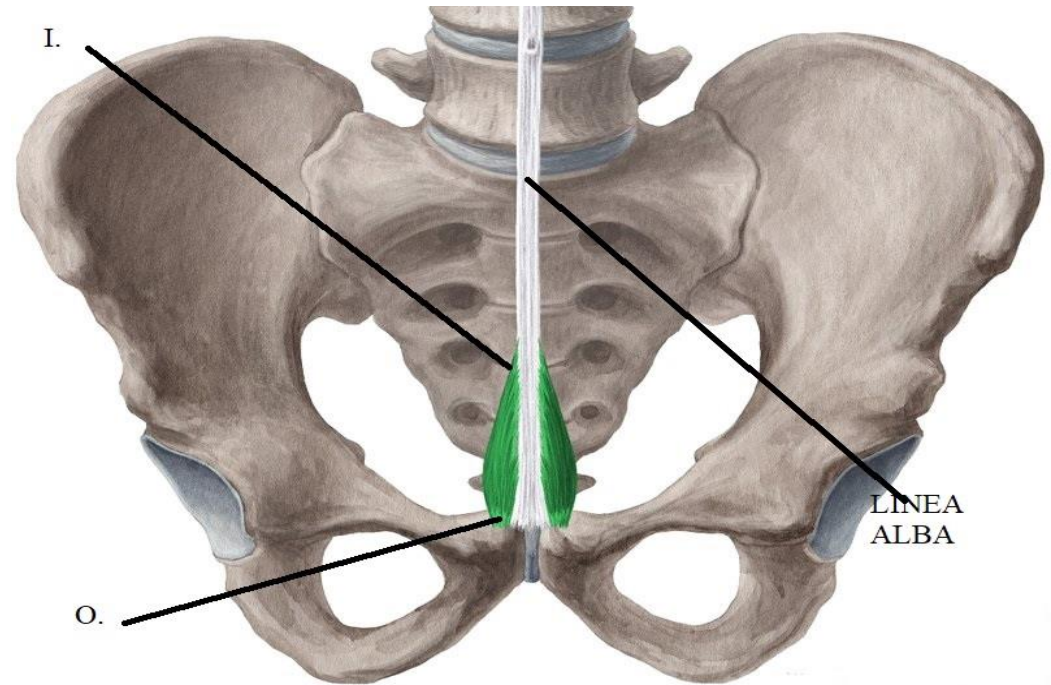
from pubic crest

I.:-

lower part of linea alba
this insertion marks
midline

Particular features

May be absent



ANTERIOR ABDOMINAL WALL

EXTERNAL OBLIQUE

O.:-Outer surface of lower 8 ribs by digitations

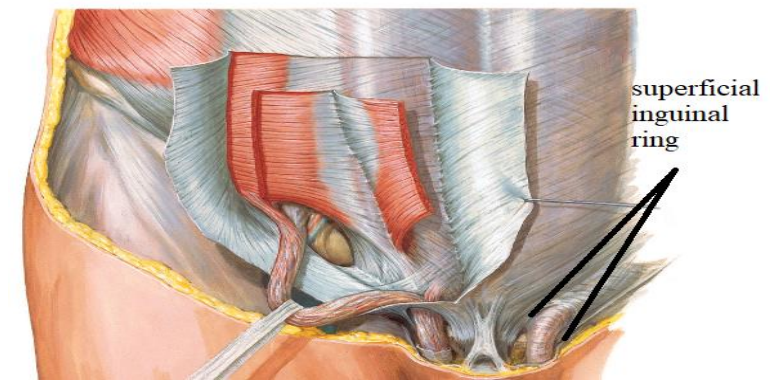
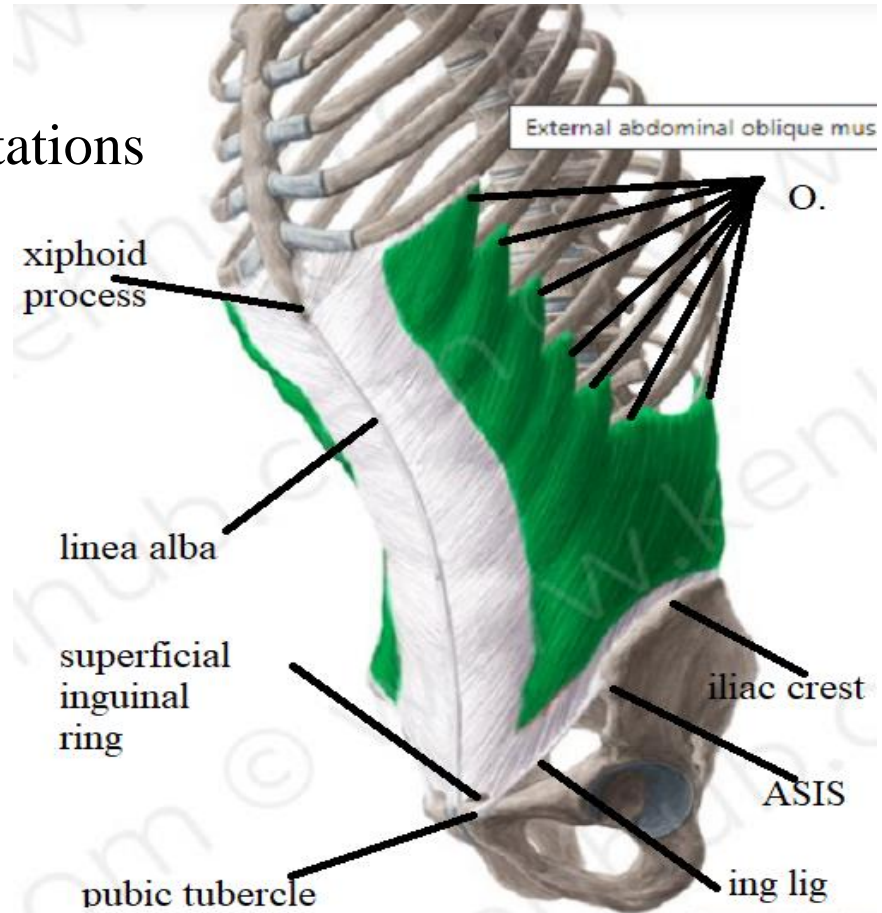
I.:-

Pass downwards, forwards & medially to

- linea alba
- pubic tubercle
- ASIS
- Ant. 1/2 of outer lip of iliac crest

Particular features

- superficial inguinal ring
- "Lower border is folded upwards & backwards forming inguinal Ligament" that extend from pubic tubercle to ASIS



ANTERIOR ABDOMINAL WALL

INTERNAL OBLIQUE

O.:-

- lat. 2/3 of inguinal ligament
- ant. 2/3 intermediate area of iliac crest.
- lumbar fascia.

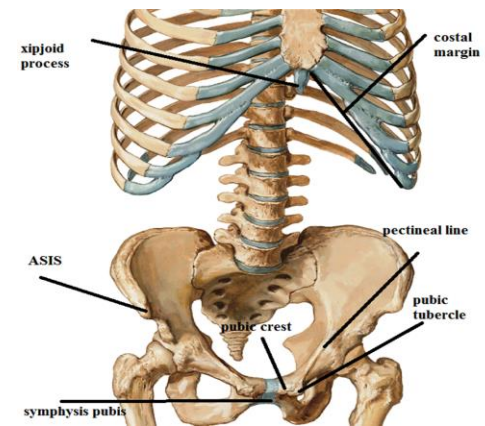
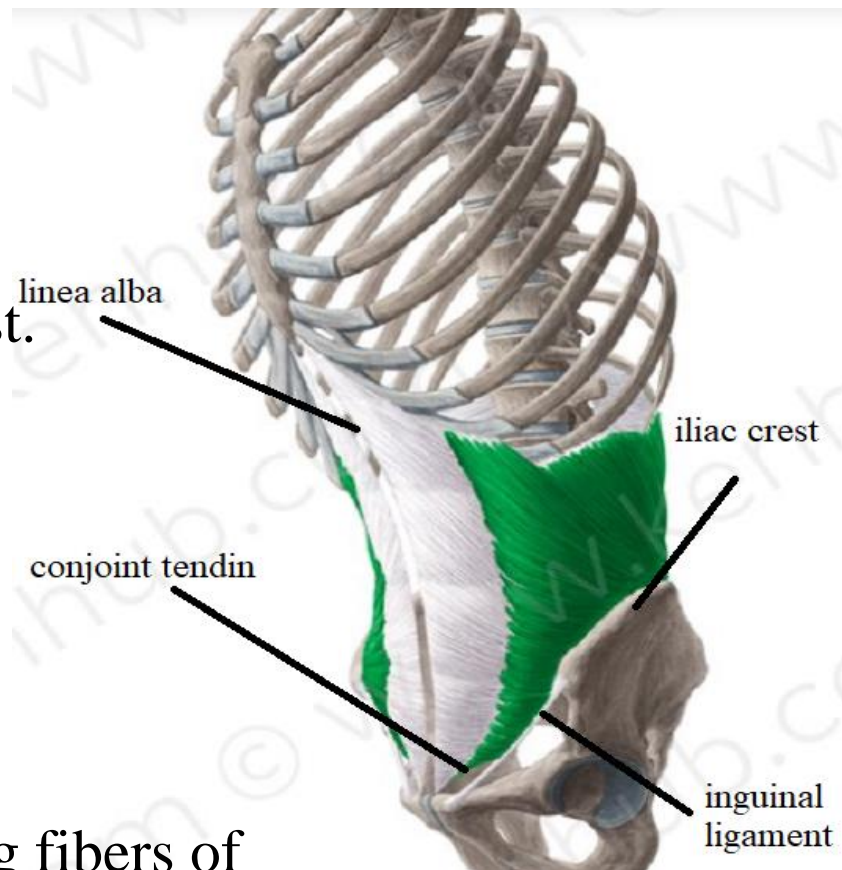
I.:-

pass upwards, forwards & medially to

- Lower 6 ribs.
- Linea alba .
- Lower fibers arch & fuse with arching fibers of transversus abdominis forming conjoint tendon attach to Pubic crest & pectineal line

PARTICULAR FEATURES

Share in conjoint tendon



ANTERIOR ABDOMINAL WALL

Transversus abdominis

O.:-

- Lat. 1/3 of ing. lig.
- ant. 2/3 inner lip of iliac crest.
- lumbar fascia.
- lower 6 ribs & c.c.

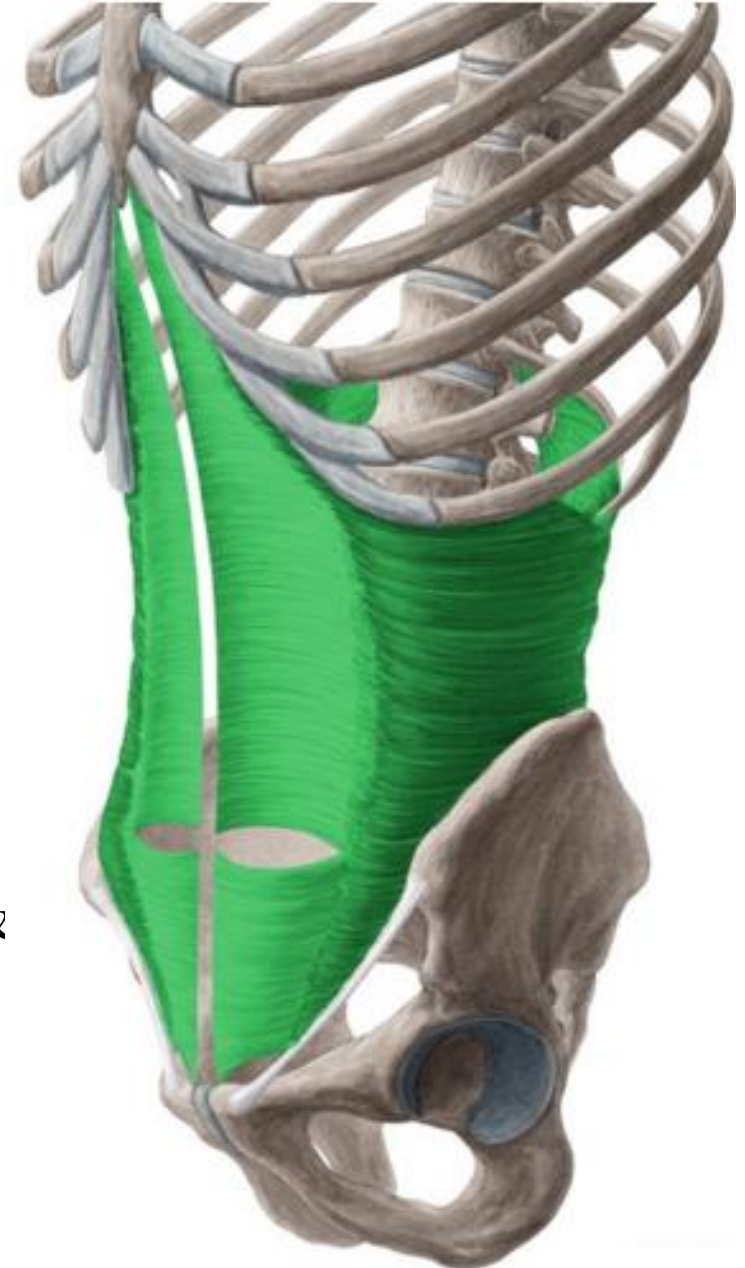
I.:-

Pass horizontally to

- linea alba.
- lower fibers:-arch & fuse with arching fibers of internal oblique forming conjoint tendon attach to pubic crest & pectineal line.

PARTICULAR FEATURES

Share in conjoint tendon



ANTERIOR ABDOMINAL WALL

Nerve Supply :-

The 3 flat muscles

Lower 6 thoracic nerves & L1

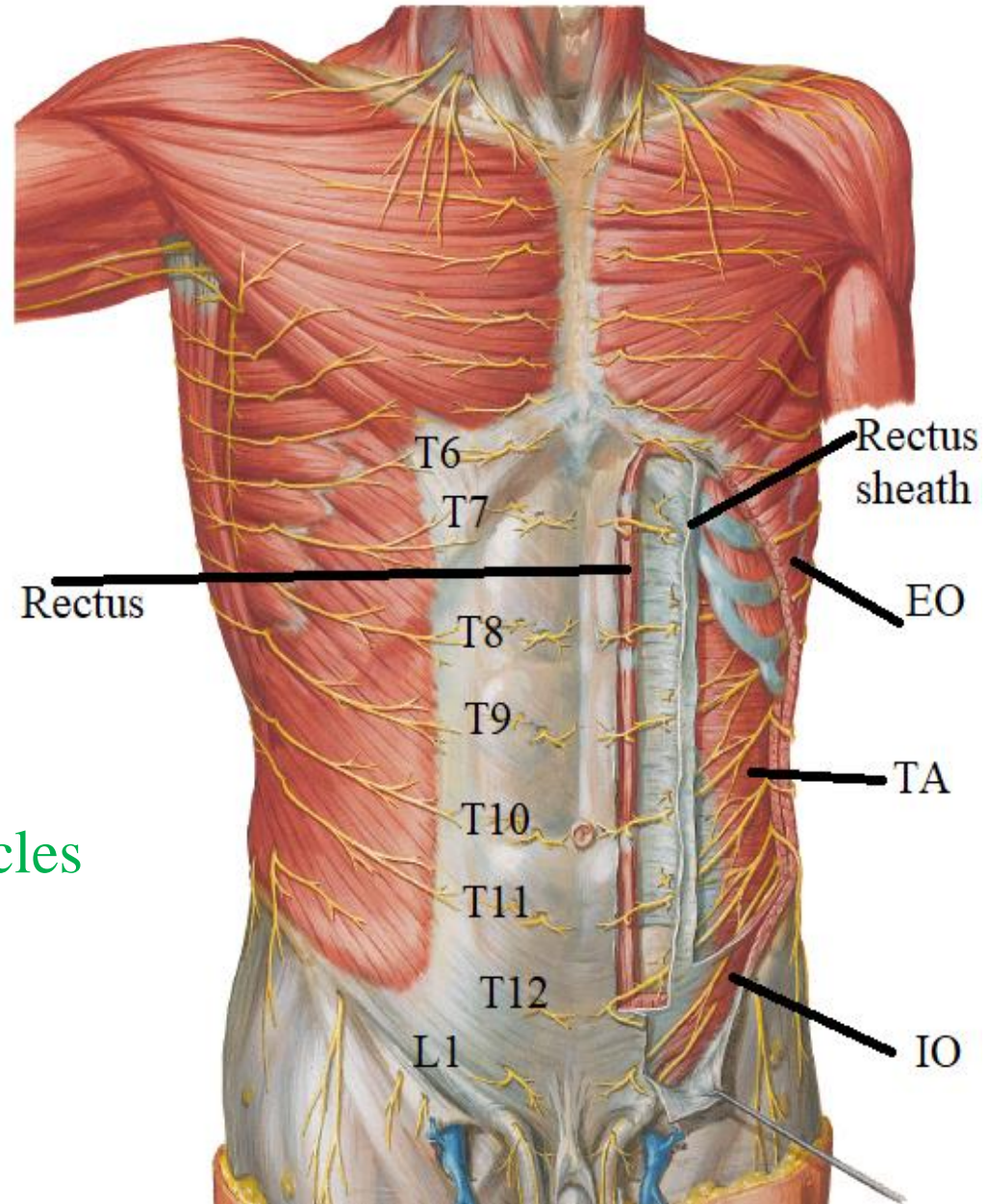
The rectus abdominis

Lower 6 thoracic nerves

The Pyramidalis

T12

N.B.:- The nerves run between the internal oblique and the transversus abdominis muscles (neurovascular plane)



ANTERIOR ABDOMINAL WALL

Action of antero-lateral abd. Wall muscles.

1-movement of the trunk:-

- Pyramidalis ----tense linea alba.
- Recti-----anterior flexion.
- Flat muscles-----lateral flexion & rotation

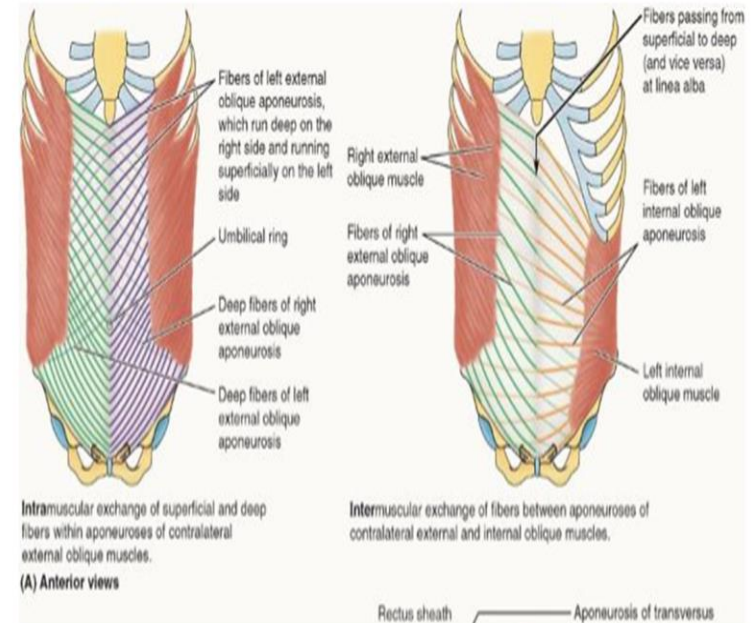
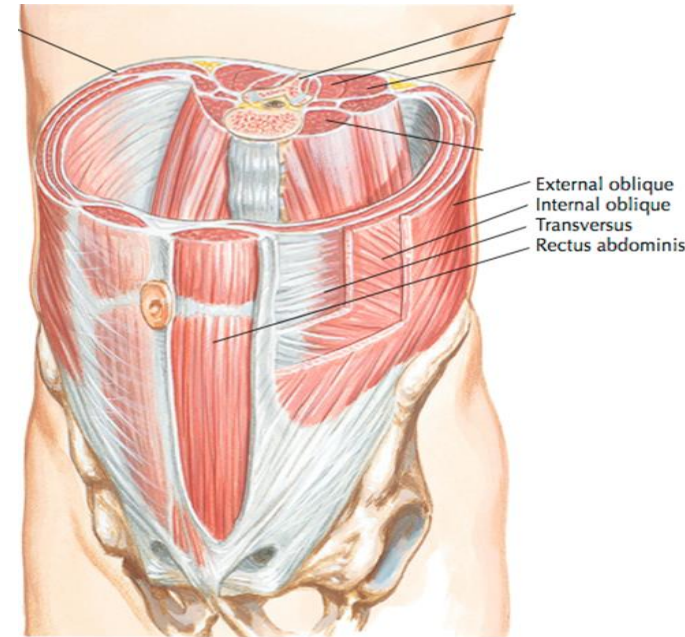
2-Respiration:-

- Inspiratory:- relax to accommodate viscera
- Forced expiratory:- contract to pull thoracic cage downwards in cough& sneezing.

3-Supportive to viscera by their tone

4-Protective to viscera against trauma by reflex contraction

5-Expulsive to viscera as in micturition, defecation, vomiting& delivery

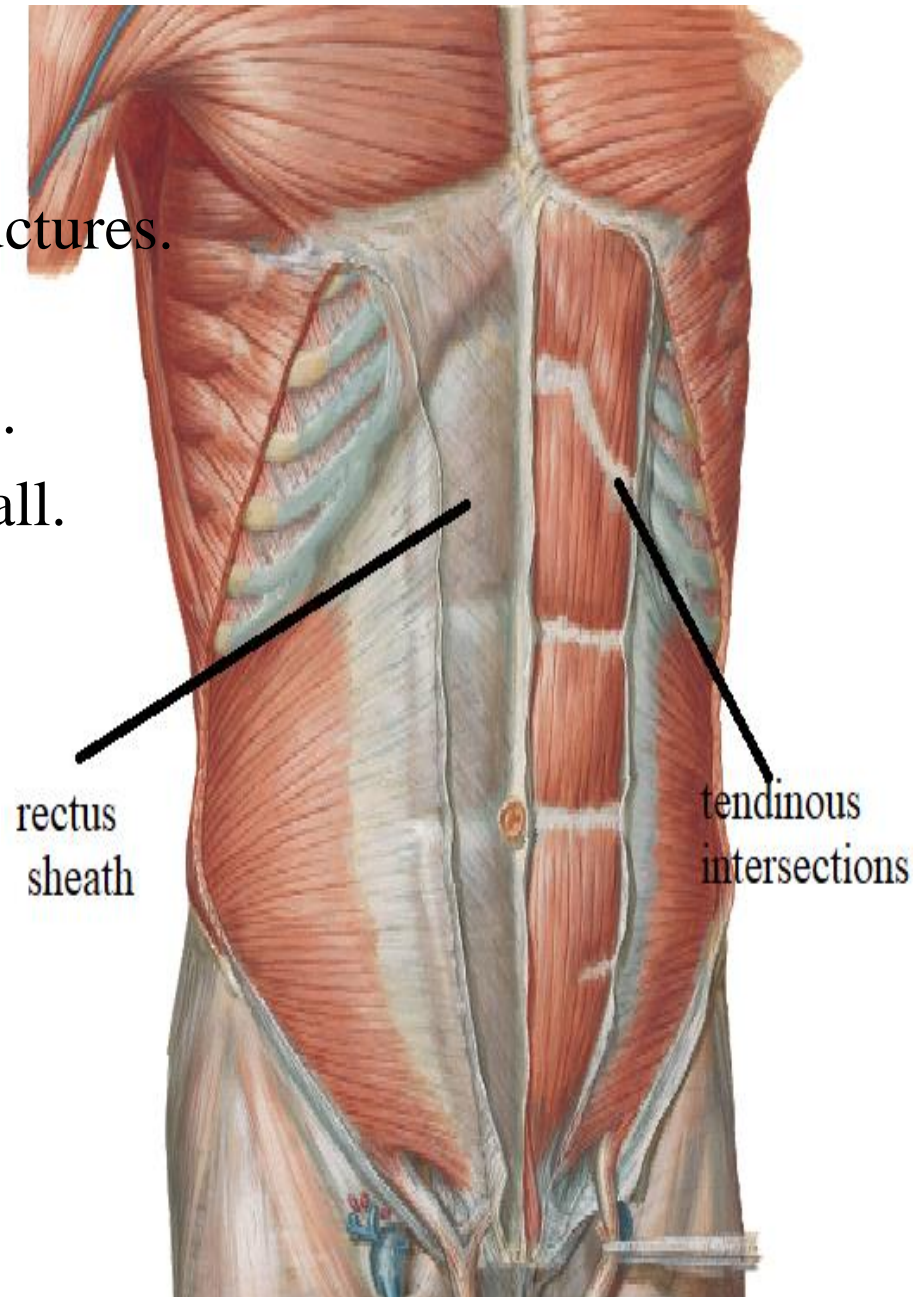


RECTUS SHEATH

Def.:- aponeurotic fibrous sheath
encloses rectus abdominis & other structures.

function

- 1-prevent bowing of rectus abdominis .
- 2-maintain the strength of ant. abd. wall.



RECTUS SHEATH

Formation:

Upper (1st.) part =above costal margin

Ant. Wall:- ext. oblique aponeurosis

Post. Wall:- 5,6 &7 c.c.

middle (2nd.) part

=From costal margin to level of ASIS

Ant. Wall

1.ext. oblique aponeurosis

2.ant. lamina of int. oblique aponeurosis

Post. Wall

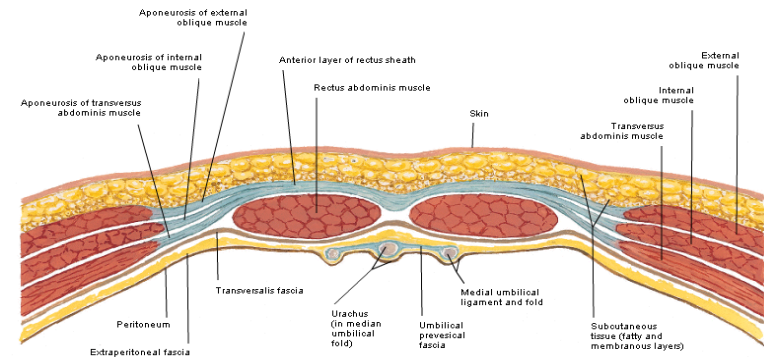
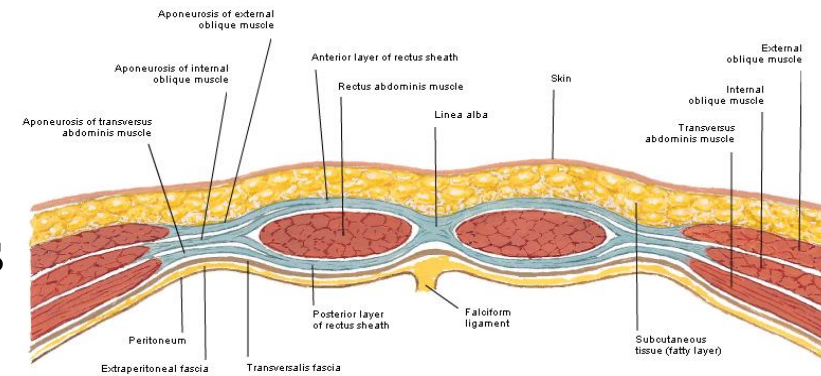
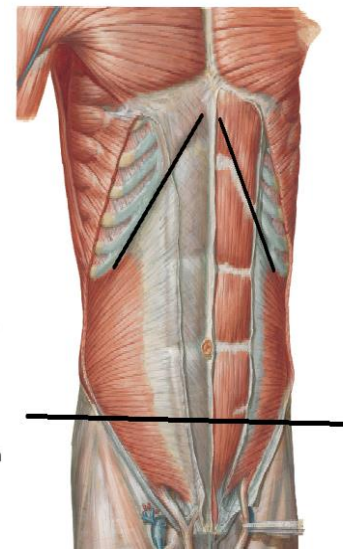
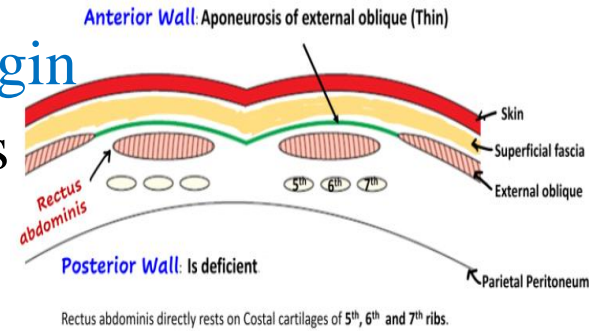
1.Post. lamina of int. oblique aponeurosis

2. Transversus abd. Aponeurosis

lower (3rd.) part =below level of ASIS

Ant. Wall:- The 3 muscles aponeuroses

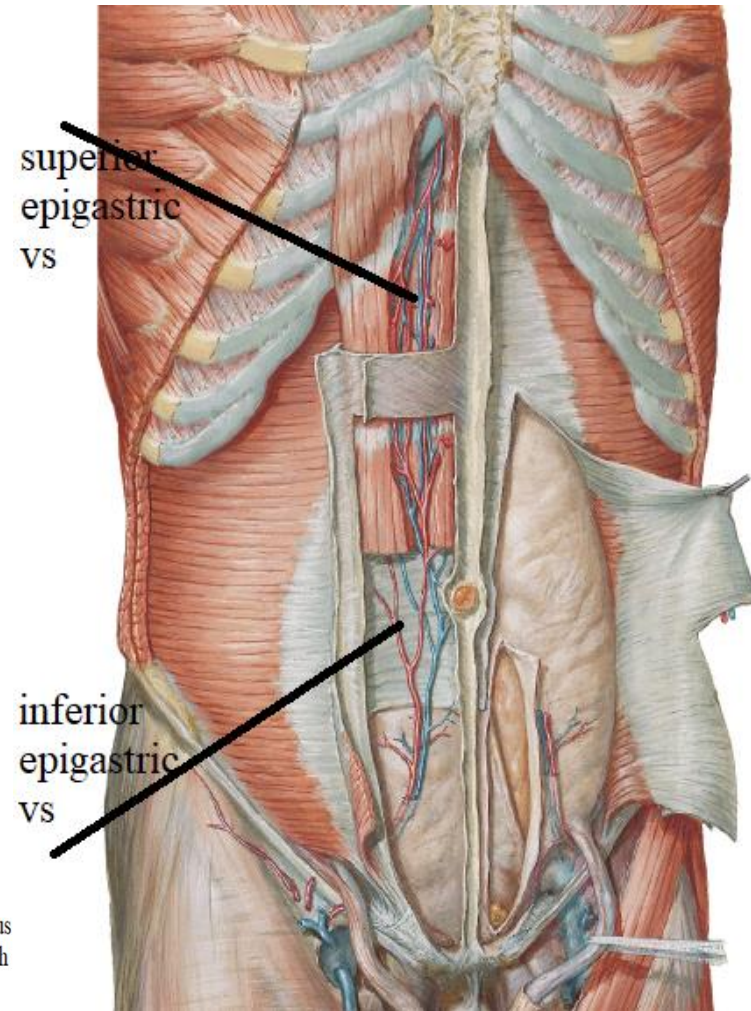
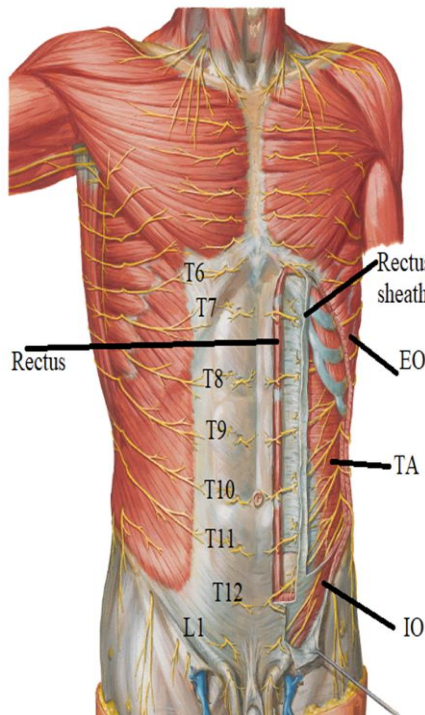
Post. Wall:-fascia transversalis



RECTUS SHEATH

Contents:

- 1-pyramidalis
- 2-rectus abdominis
- 3-superior epigastric vs
- 4-inferior „ „
- 5-lower 6 thoracic nerves
- 6-lymphatics



THANQ