



المطب والجراحة

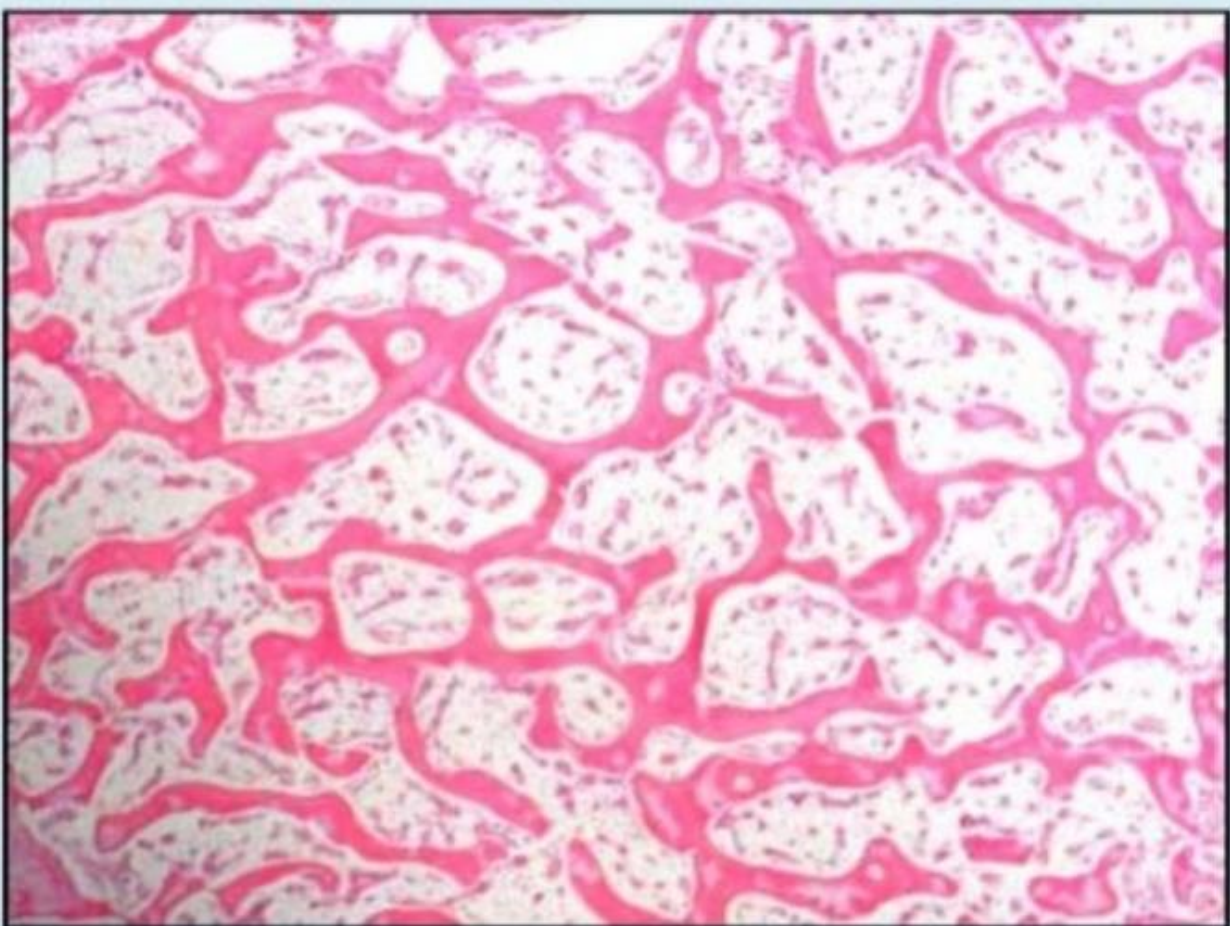
لبننة



MSS LAB 2

دفعه وتين 2020

Q.1 Identify a tissue type?.



Select one :

a. Hyaline cartilage

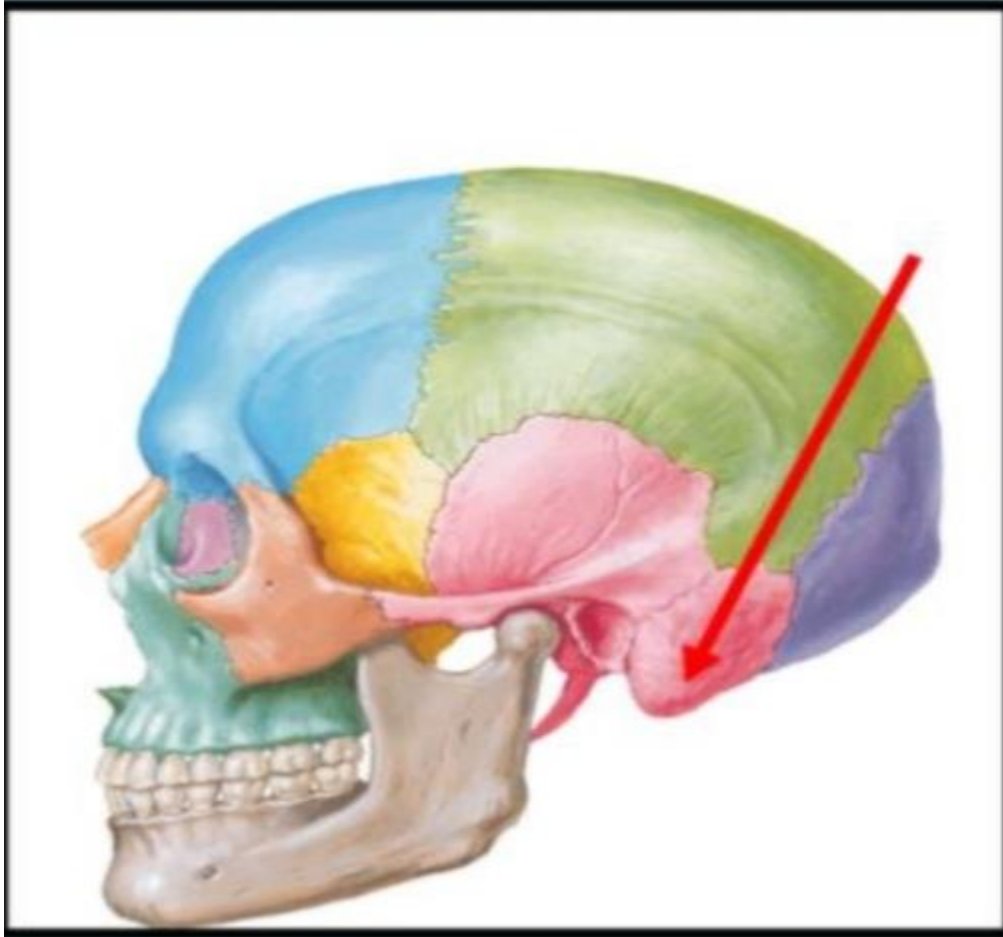b. Trabecular bone

c. cross-section skeletal muscle

d. Articular cartilage

e. Compact bone

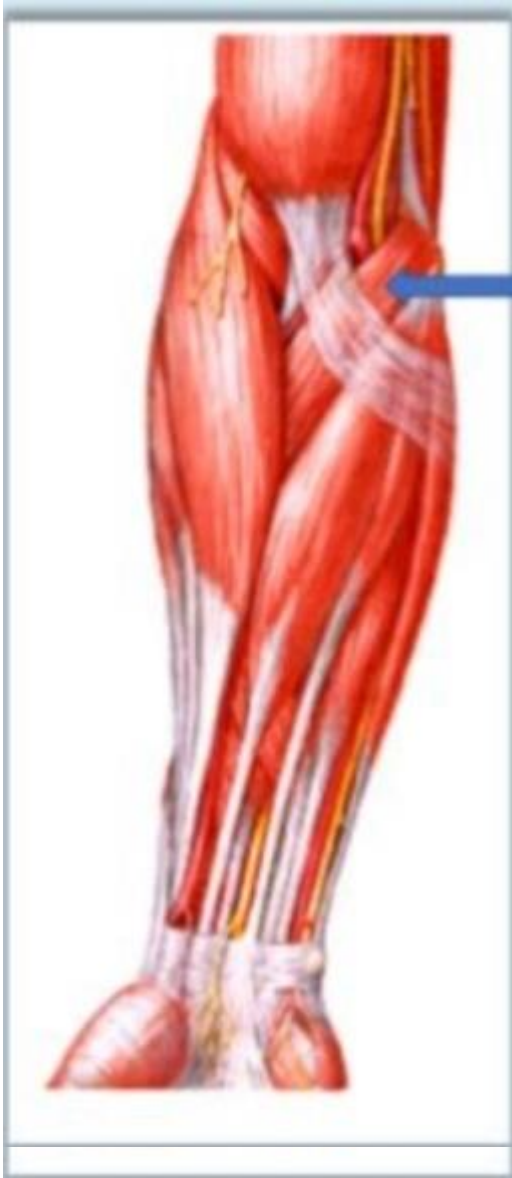Q.2 The mentioned bone is?



Select one:

- a. Mastoid process of the temporal bone
- b. The petrous part of the temporal bone
- c. The squamous part of the temporal bone
- d. Tympanic part of the temporal bone
- e. Styloid process of the temporal bone

Q.3 What is the labelled structure?



Select one :

a. Pronator teres

b. Brachioradialis

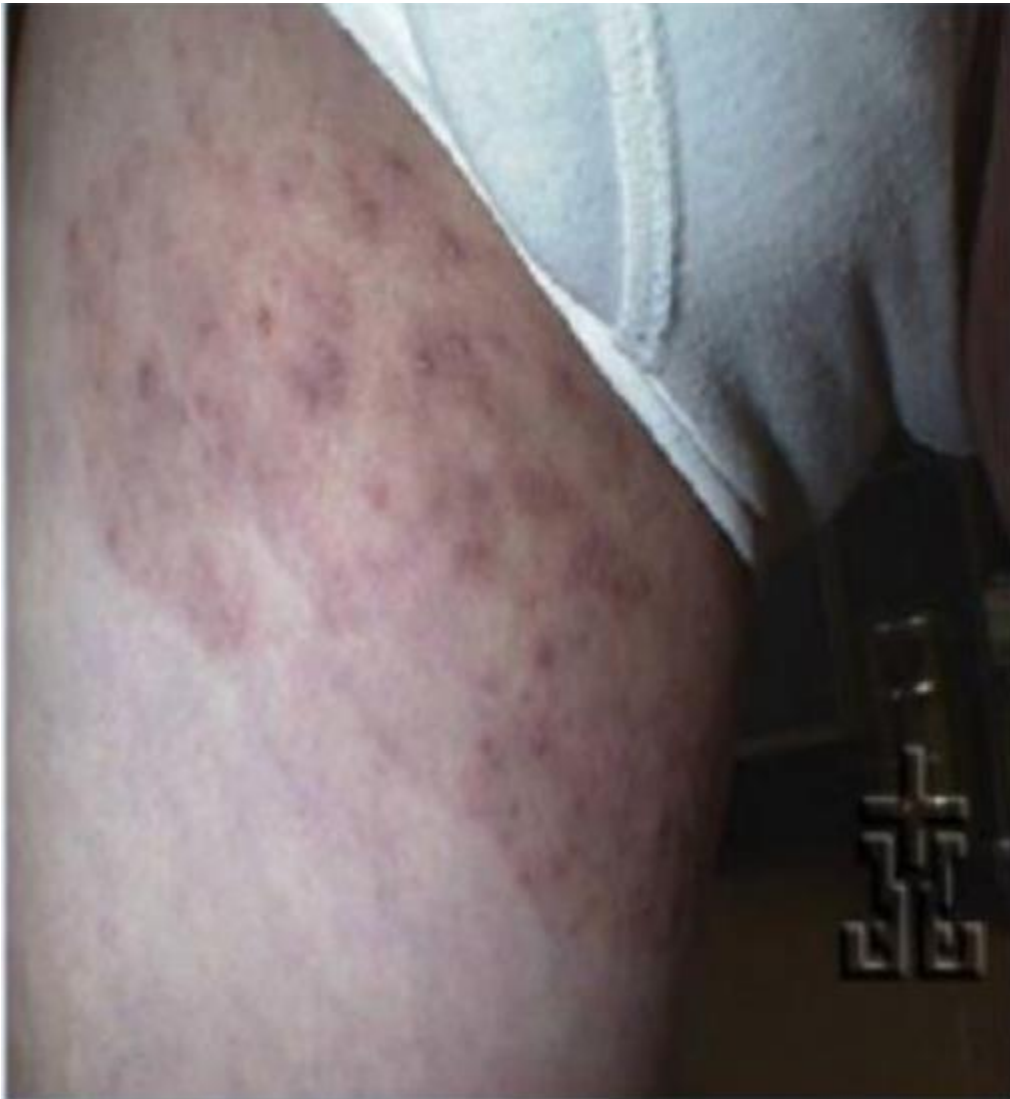c. Flexor carpi radialis

d. Flexor carpi ulnaris

e. Flexor digitorum superficialis

Q. 4 This groin dermatophyte is described as?

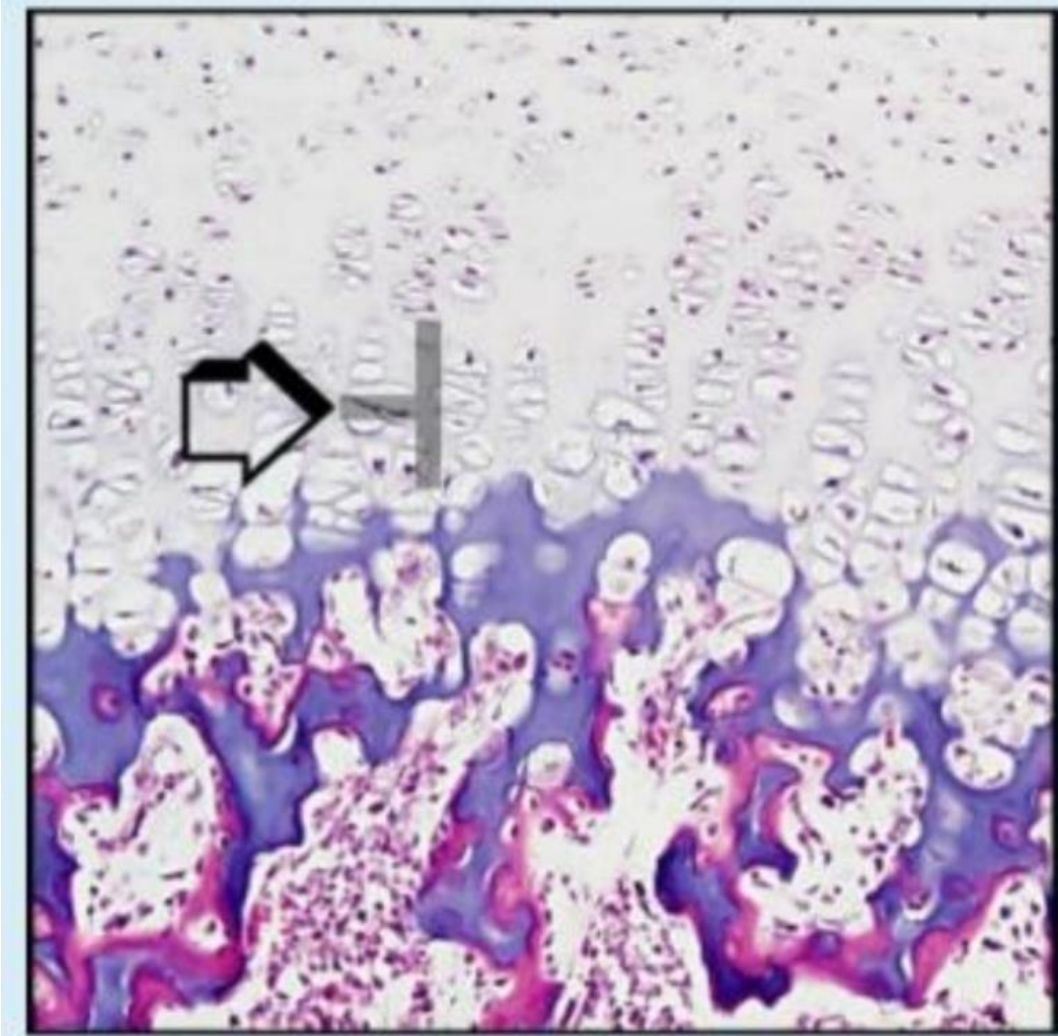
مش ضمن صور اللاب ولا المحاضرة



Select one:

- a. Tinea cruris**
- b. Tinea corporis
- c. Tinea capitis
- e. Tinea unguinum
- e. Tinea pedis

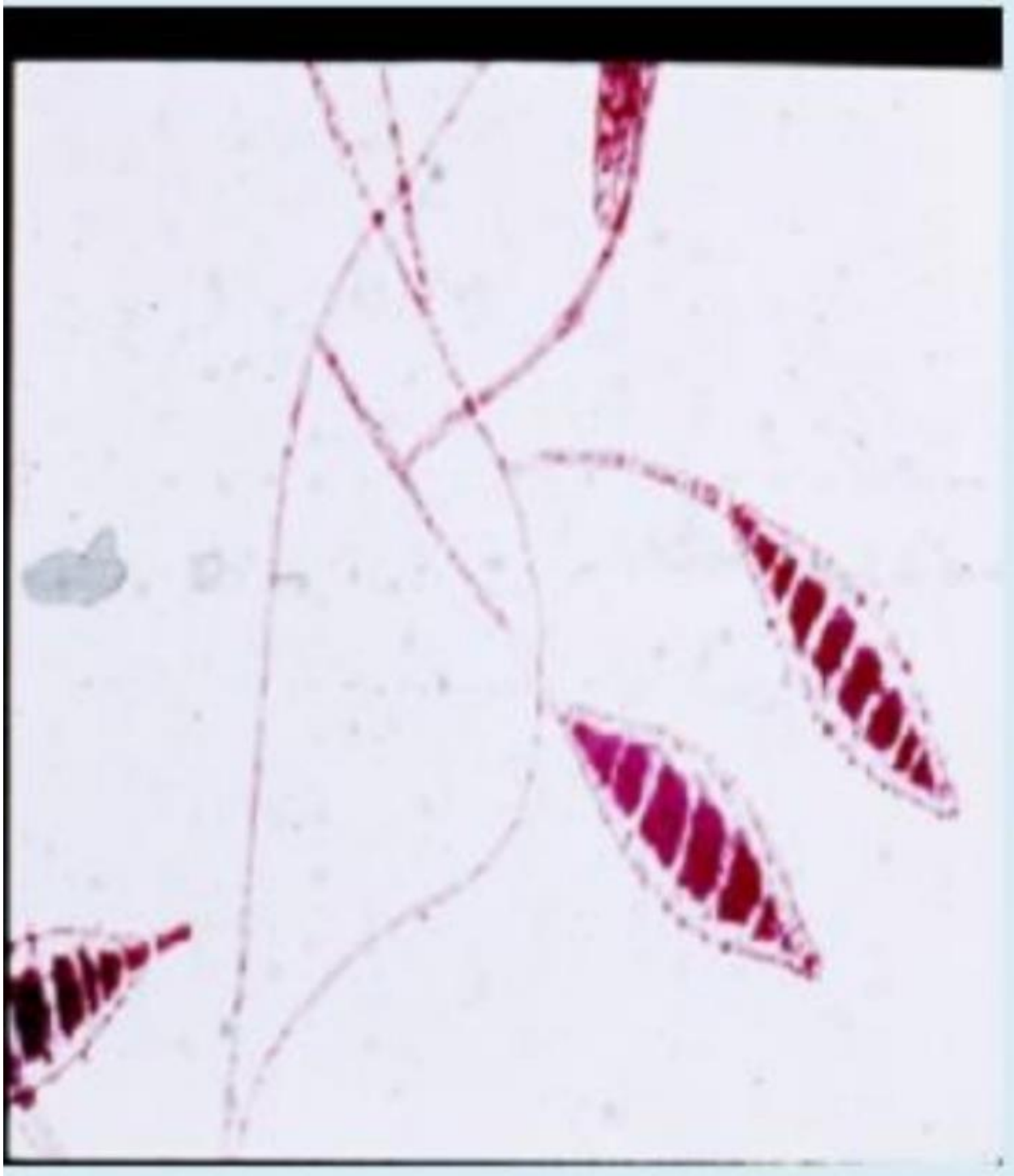Q5. Identify a histological feature?



Select one:

- a. Hypertrophy**
- b. Proliferation
- c. Resting
- d. Calcification
- e. Ossification

Q.6 this is?



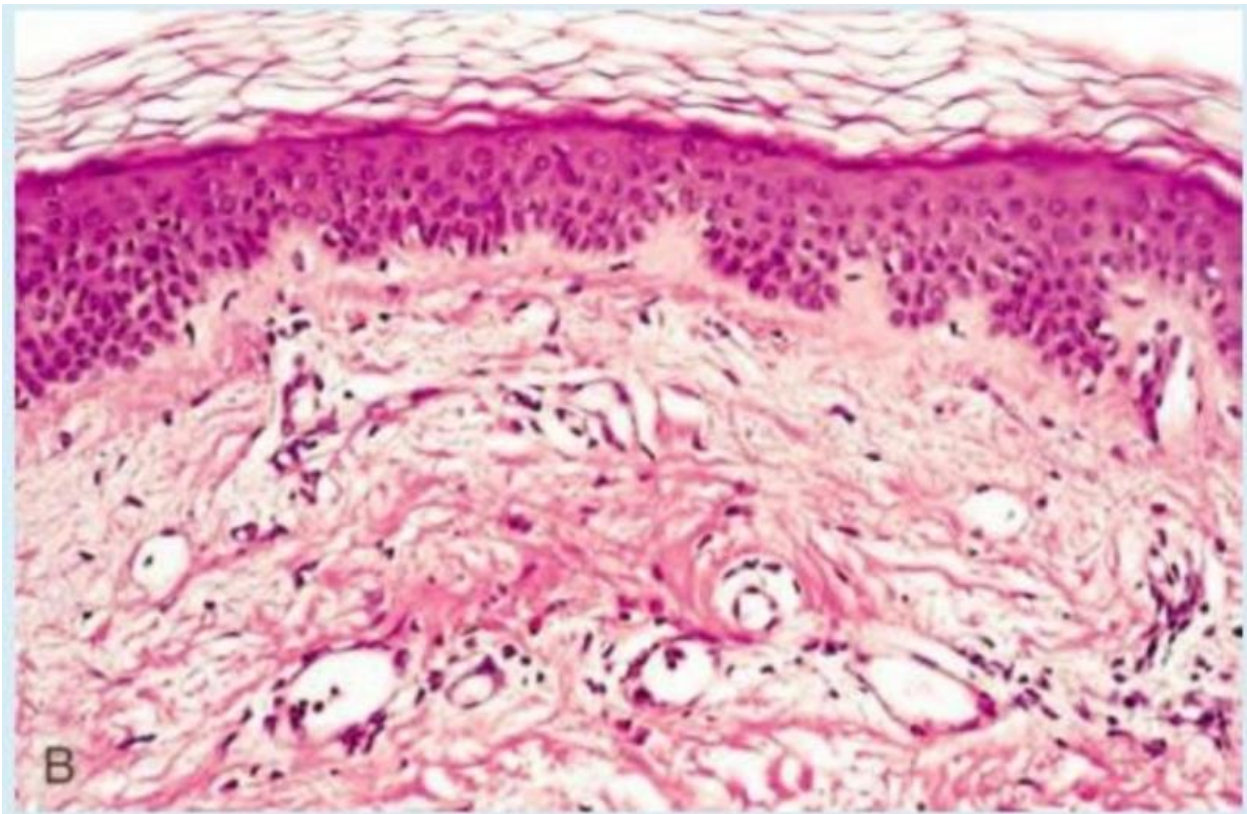
Select one:

a. *Candida albicans*

b. *Microsporium* spp

- c. *M. globosa*
- d. *Trichophyton* spp
- e. *M. Furfur*

Q.7 Which of the following describe the pathogenesis leading to the changes in the photo?

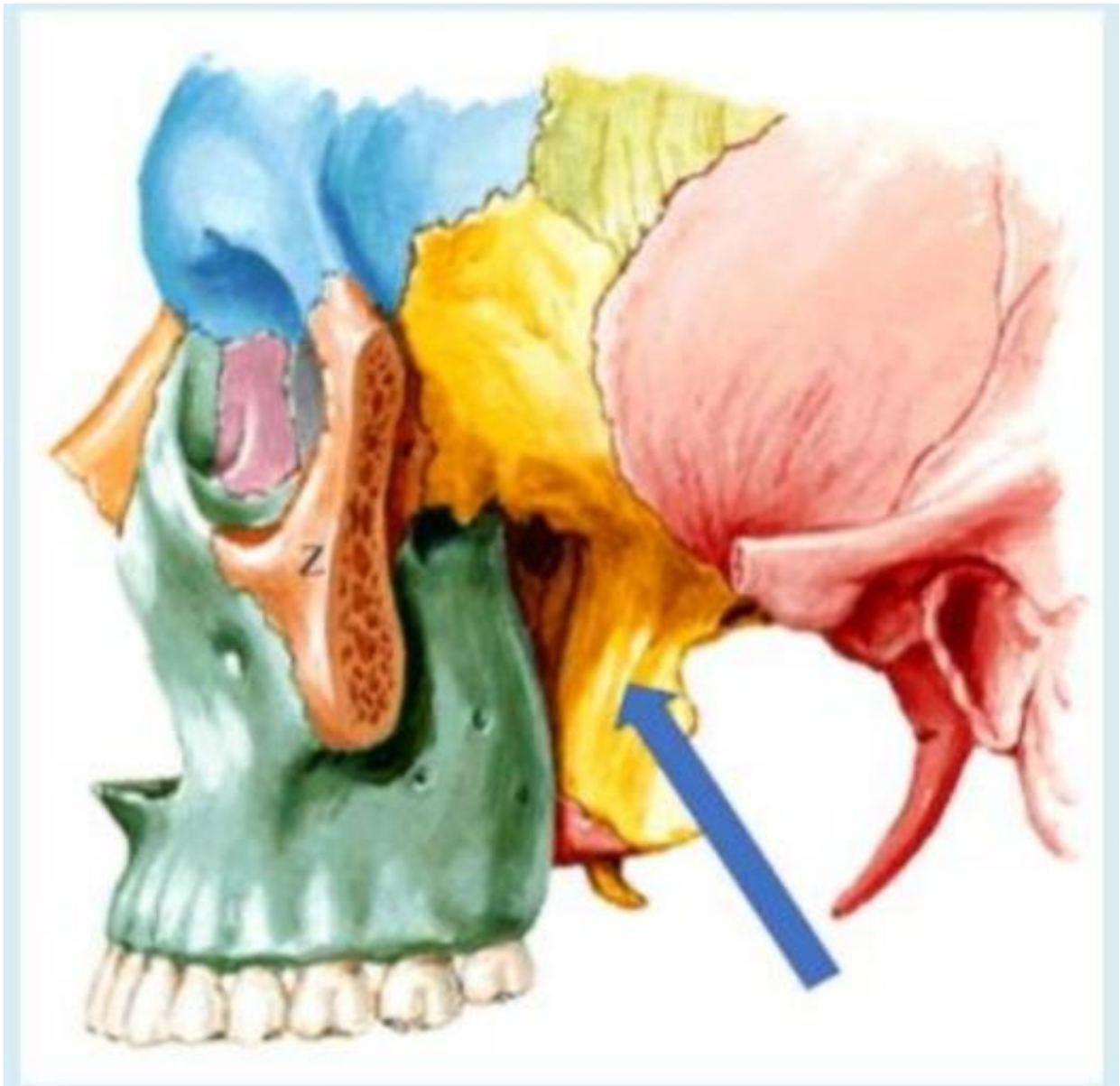

Select one :

- a. Exacerbation reaction due to scratching of the lesion
- b. Mast cell degranulation**
- c. Type II hypersensitivity reaction

- d. keratinocyte injury mediated by CD8+ cytotoxic T lymphocytes
- e. CD4+ T lymphocytes type IV hypersensitivity

Q.8 What is the labelled structure?



Select one :

a. Origin of lower head of lateral pterygoid muscles

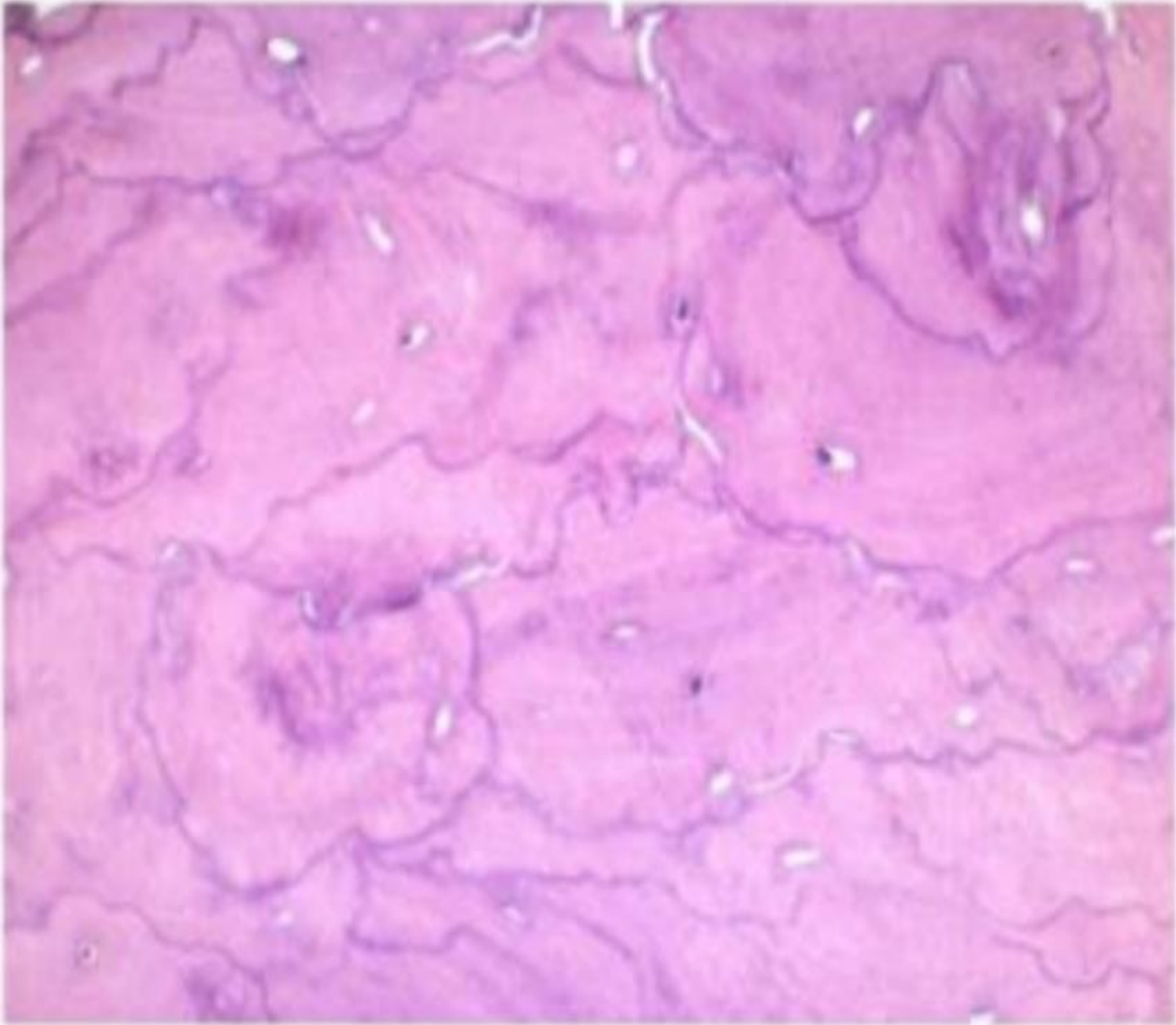
b. Origin of deep head of medial pterygoid muscles c. Origin of upper head of lateral pterygoid muscles

d. Origin of pterygomandibular ligament

e. Origin of superficial head of medial pterygoid muscles

Q.9

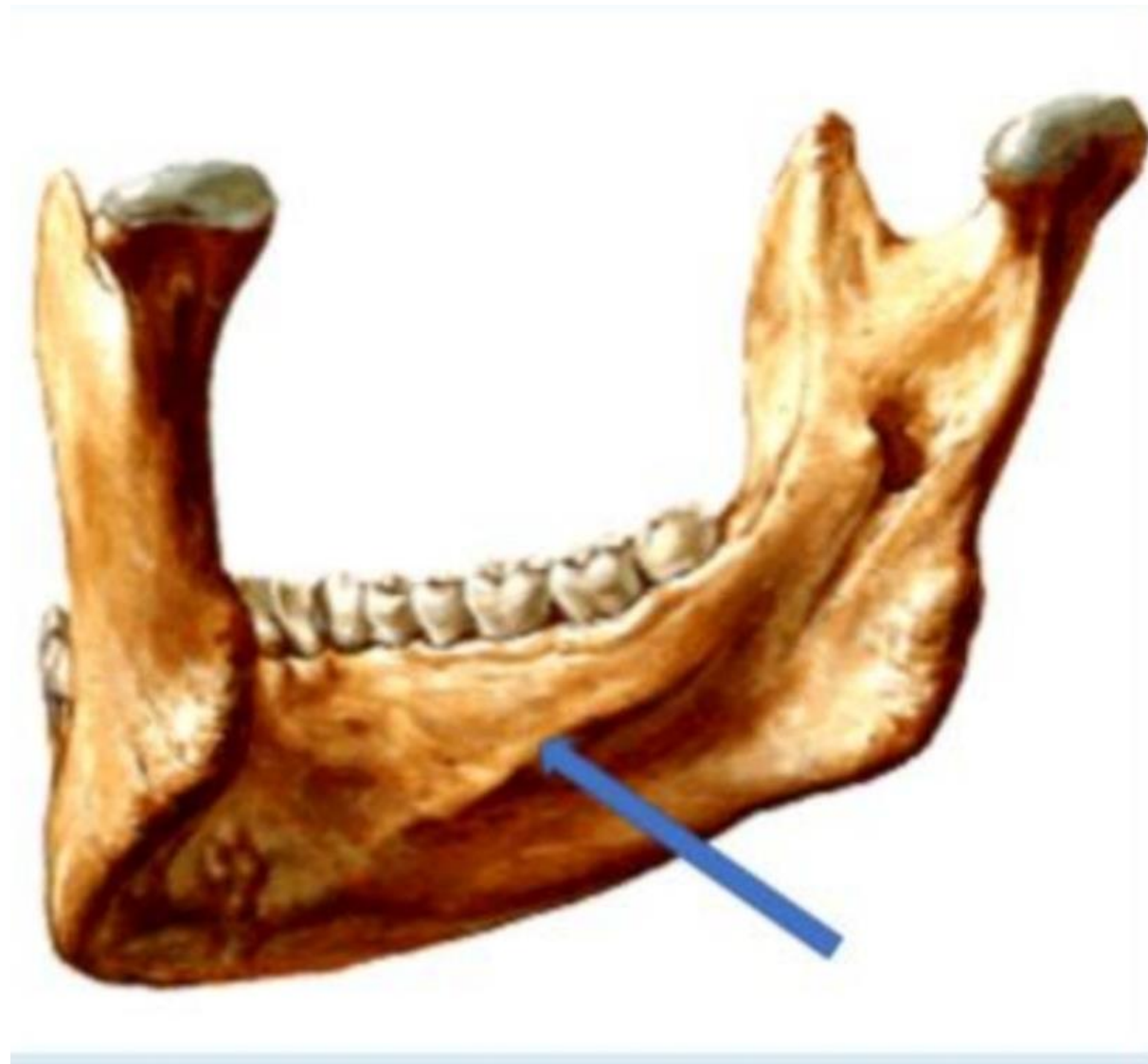A 70-year-old man complains of right hip and thigh pain of several months' duration. On physical examination he has reduced range of motion in both hips. Laboratory studies show elevated serum alkaline phosphatase level and a normal range of calcium and phosphorus. A bone biopsy is done; the figure shows the microscopic appearance of the specimen. What condition is most likely to produce these findings?



Select one:

- a. Osteochondroma
- b. Mixed phase of Paget disease of bone.
- c. Sclerotic phase of Paget disease of bone.**
- d. Osteoporosis.
- e. Lytic phase of Paget disease of bone

Q.10 What is the labelled structure?



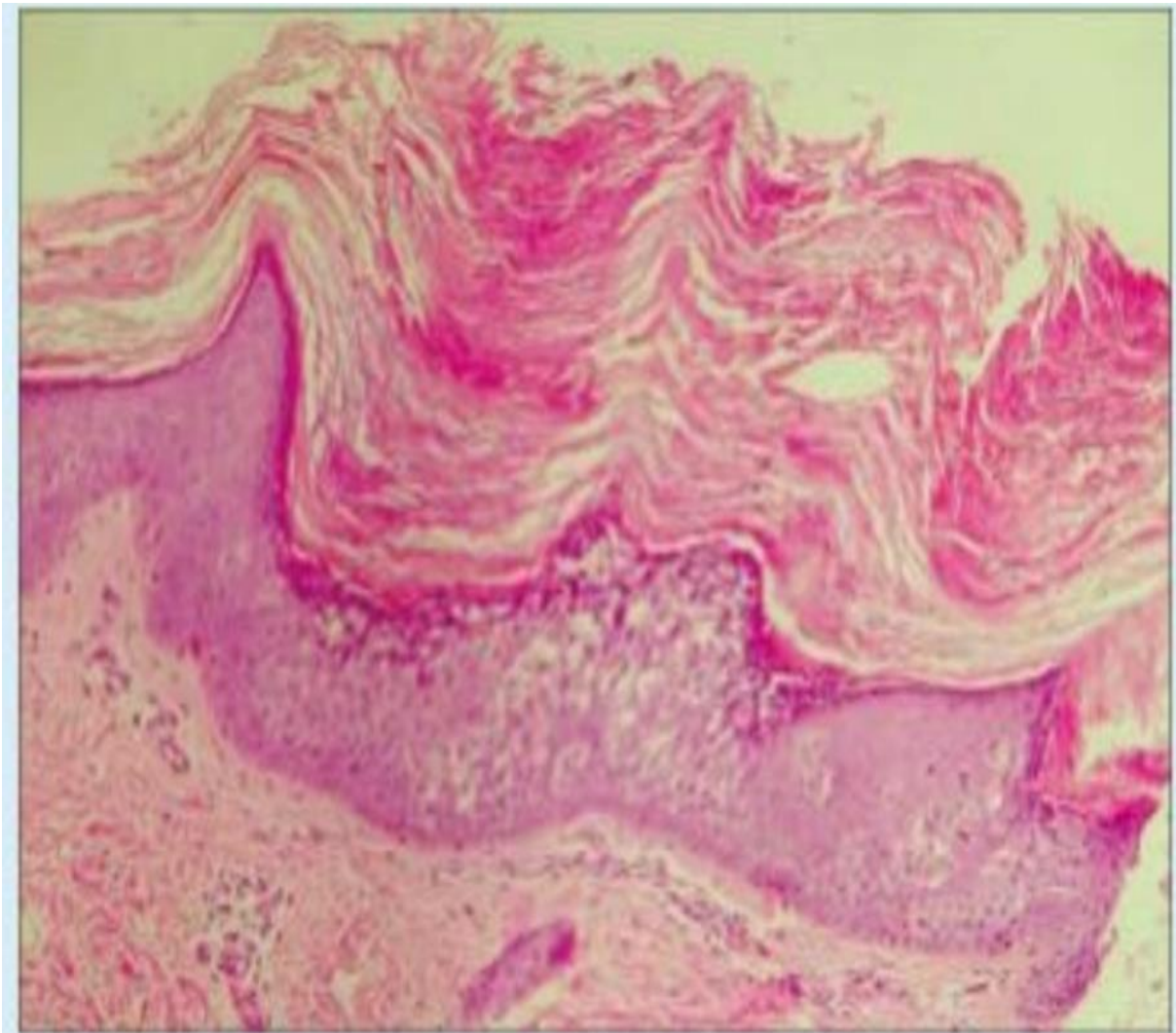
Select one :

- a. Origin of anterior belly of digastric
- B. Insertion of platysma
- c. Origin of mylohyoid**
- d. Origin of geniohyoid
- e. Origin of genioglossus

Q.11

Which of the following best describe the lesion seen in this photo?

صورة إضافية مش من الملفات



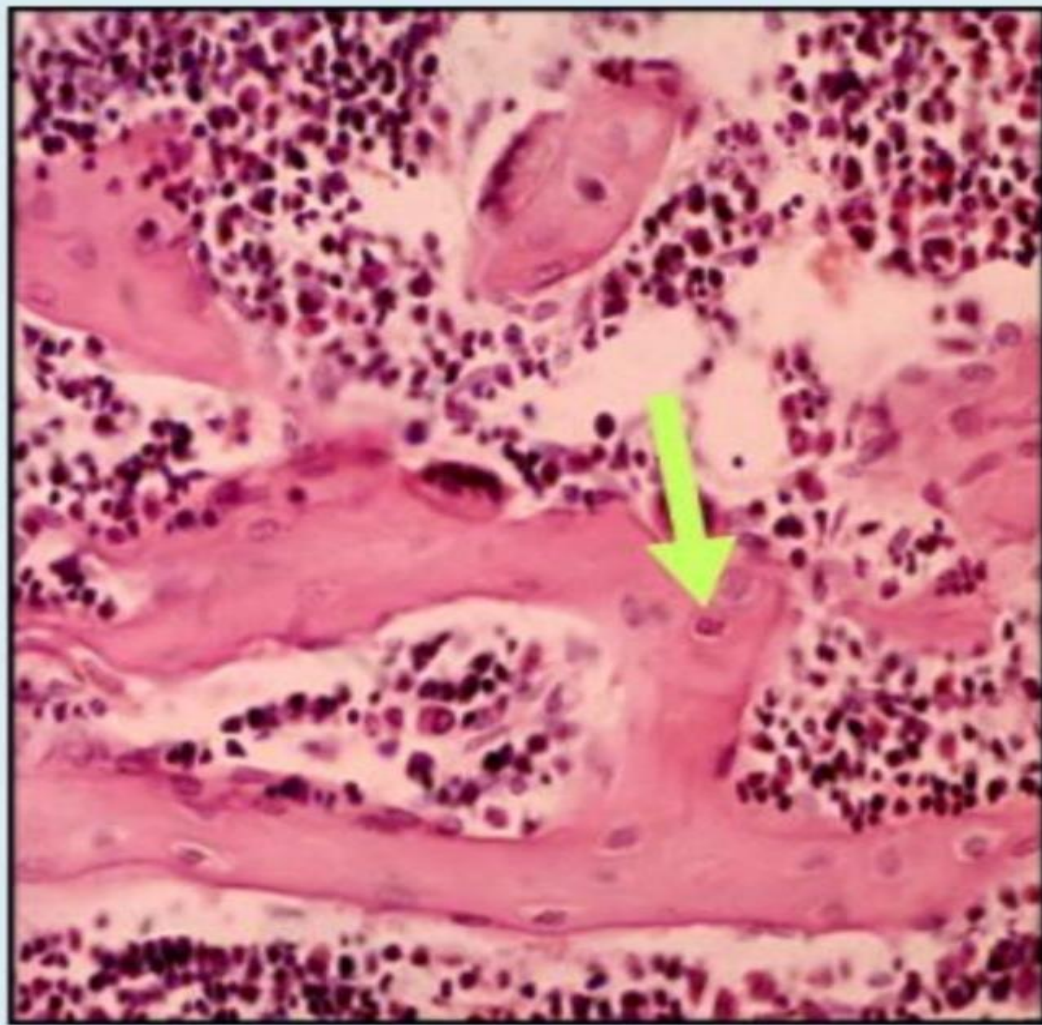
Select one :

- a. Acanthosis
- b. Hyperkeratosis**
- c. Parakeratosis

d. Spongiosis

e. Dermal-epidermal separation

Q.12 identify a cell type?



Select one :

a. Osteocyte

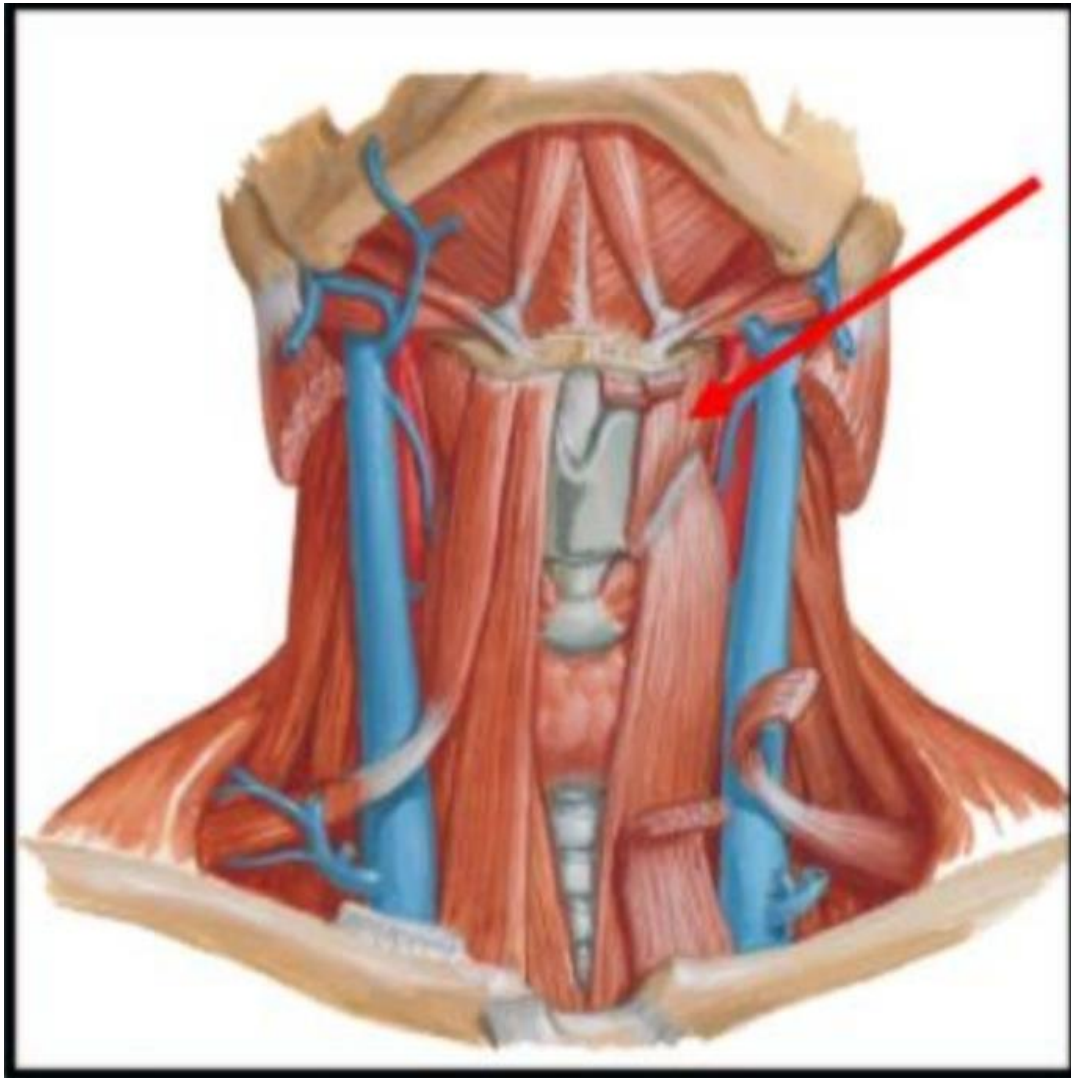
b. Osteoclast

c. Chondrocyte

d. Osteoblast

e. Osteoprogenitor Cell

Q.13 The indicated muscle is?



Select one :

a. Thyrohyoid

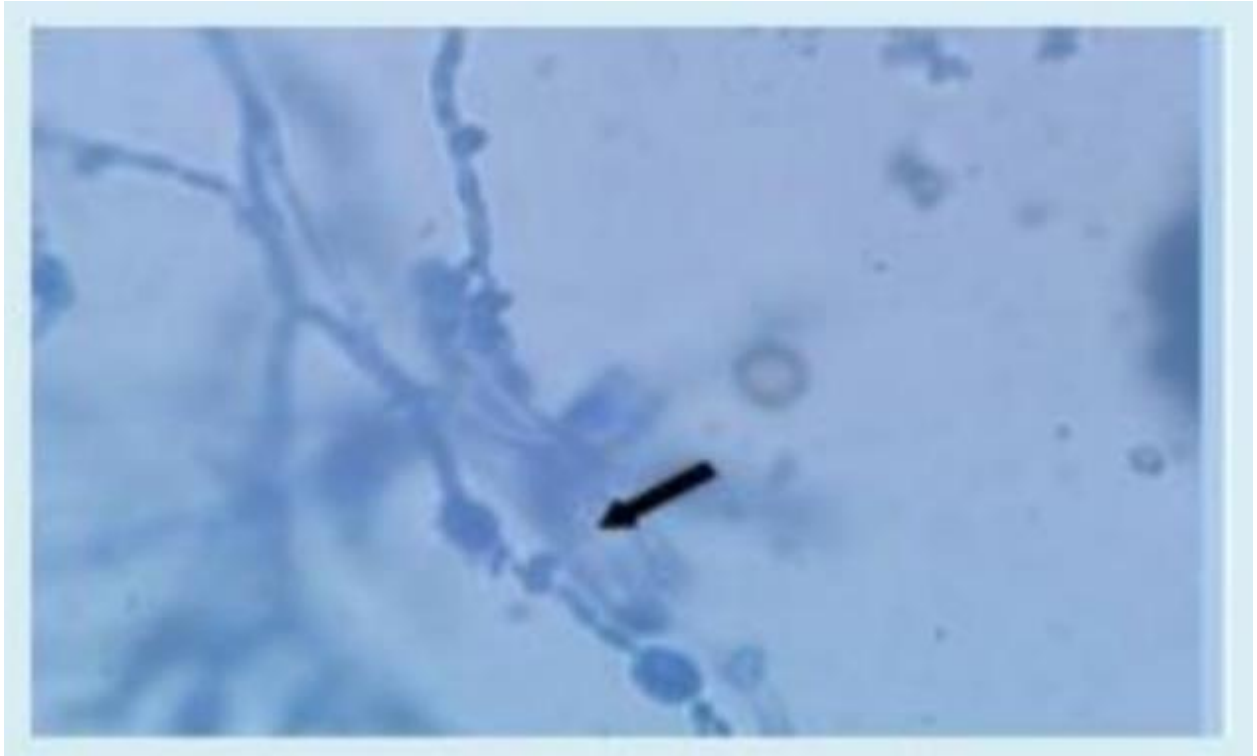
b. Omohyoid

c. Geniohyoid

d. Innervated by Ansa cervicalis, C1, 2, and 3

e. Sternothyroid

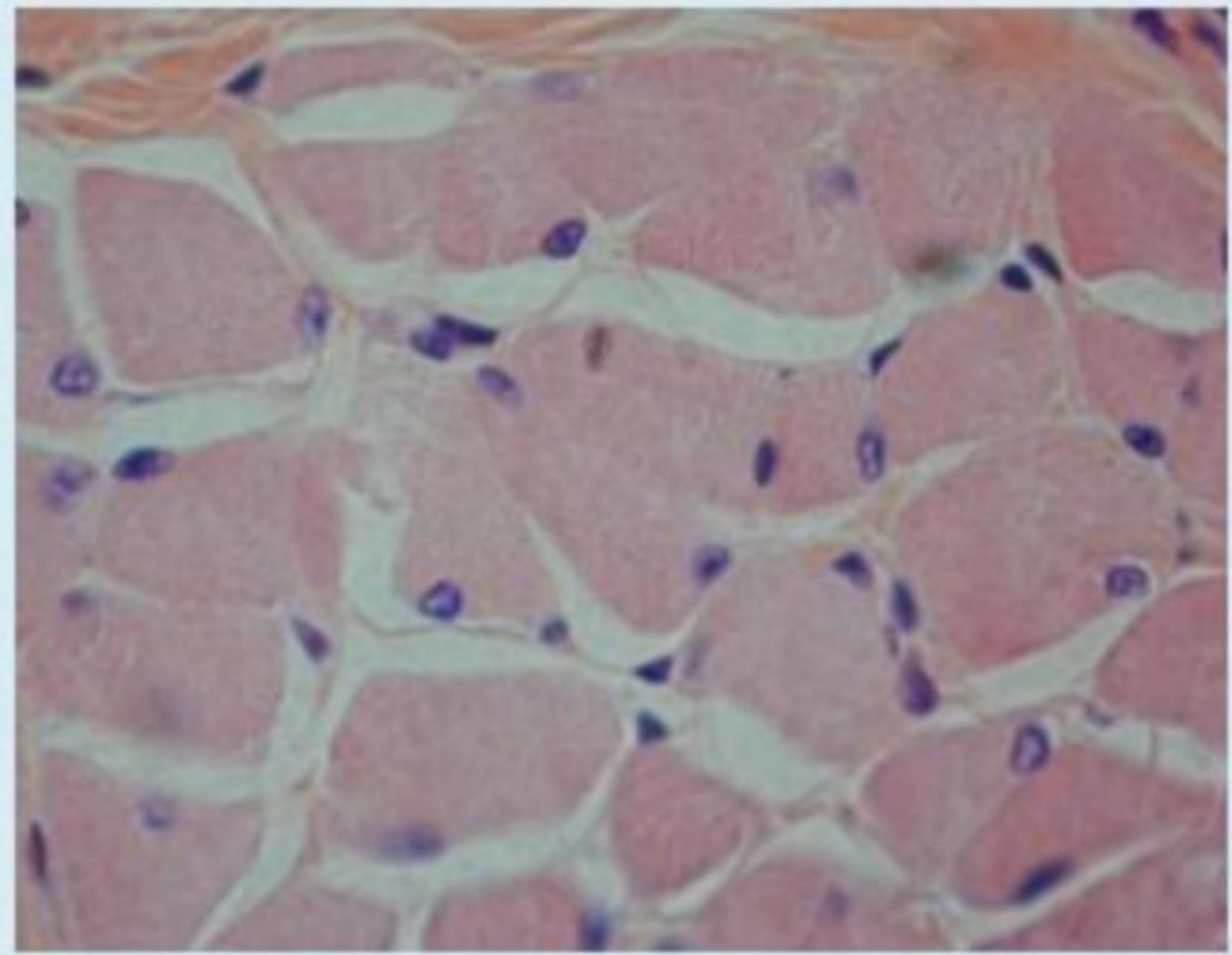
Q.14 The arrowed structure is commonly seen in? صورة من المحاضرة مش اللاب



Select one :

- a. *Candida albicans*
- b. *Microsporum*
- c. *Epidermophyton*
- d. *Trichophyton*
- e. ***Madurella mycetomatis***

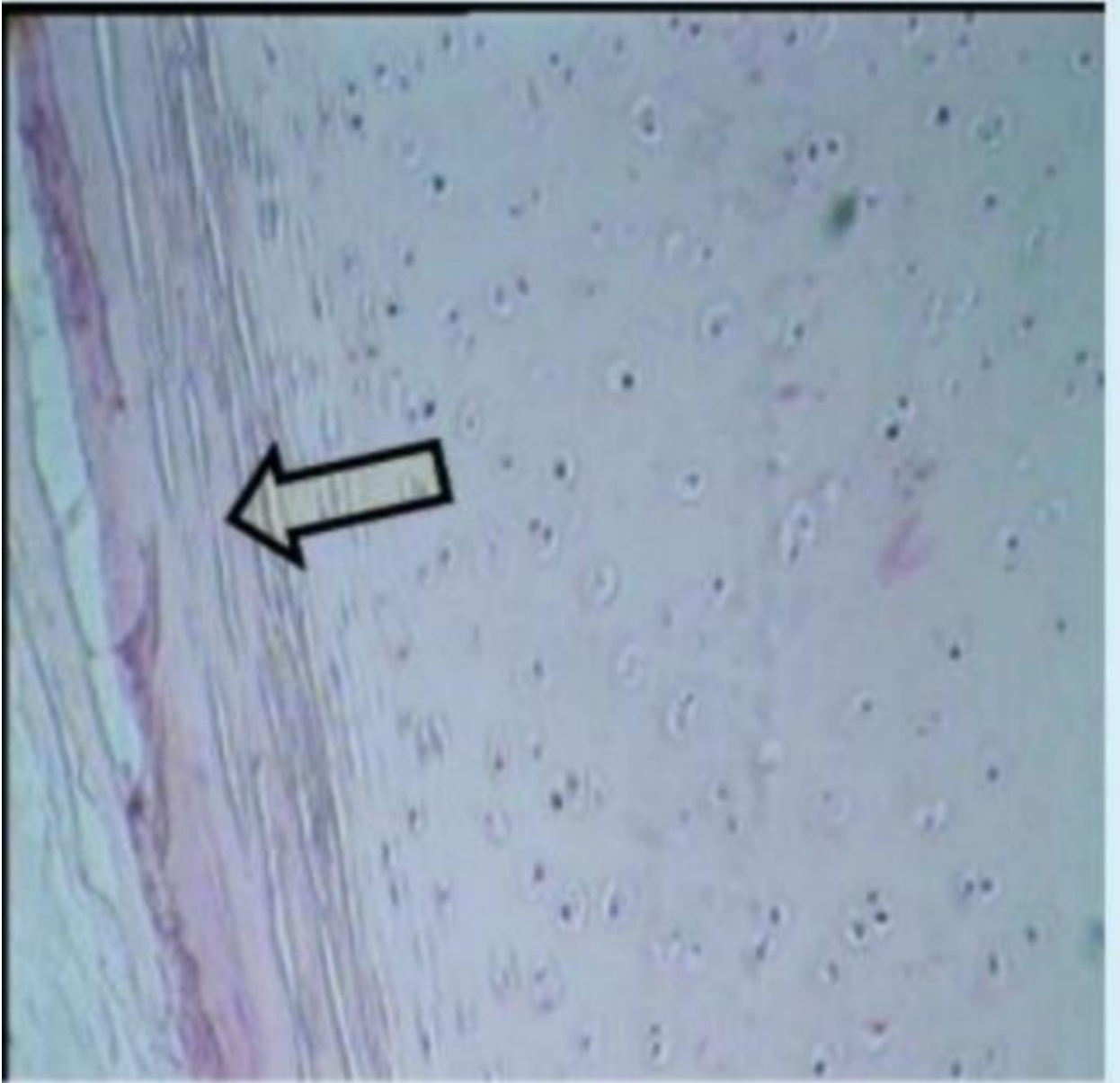
Q.15 Identify a tissue type?



Select one :

- A. L.S skeletal Muscie
- B. Territorial Matrix
- C. Lacunae
- D. TS skeletal Muscle**
- E. Articular Cartilage

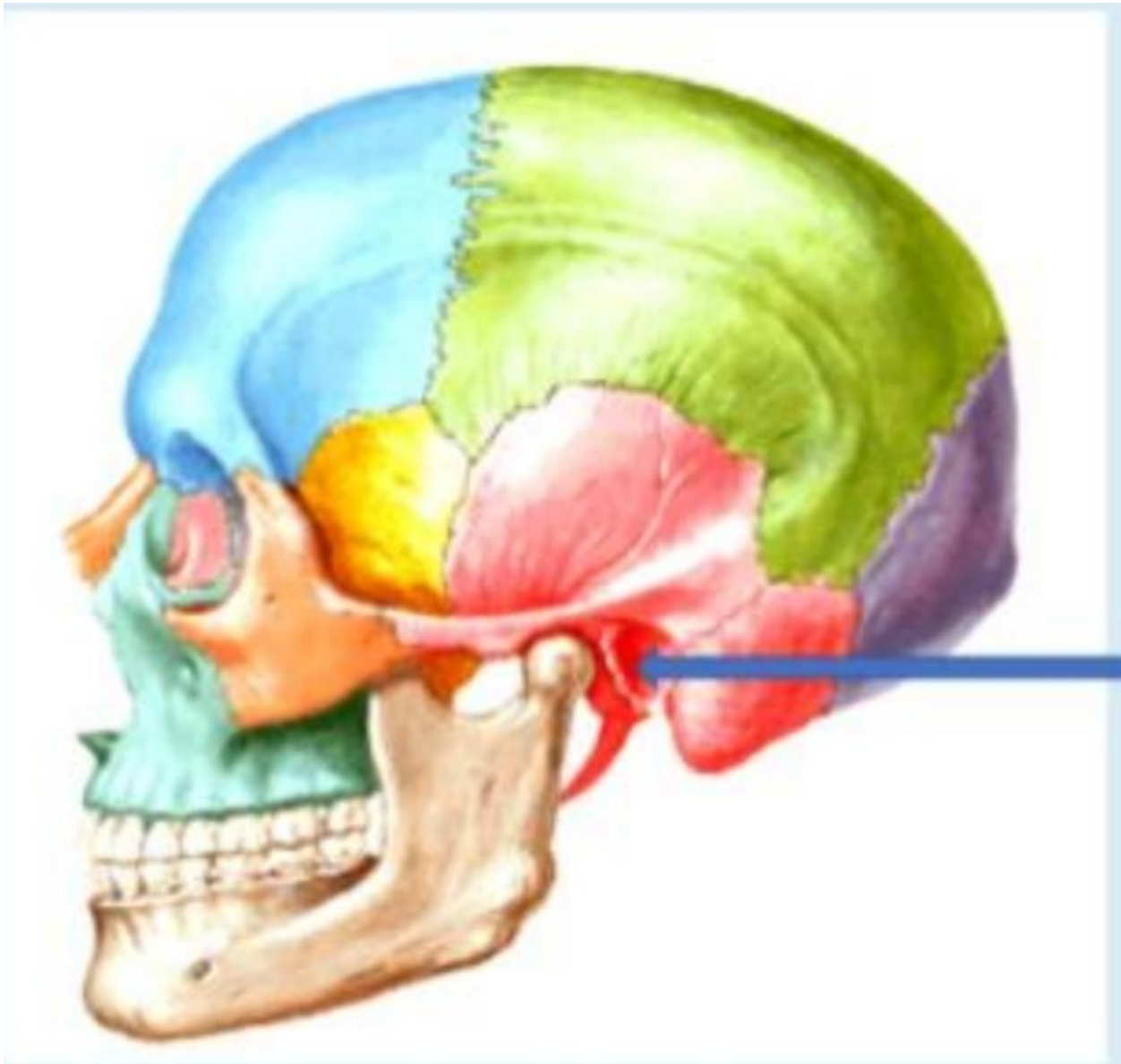
Q.16 Identify a histological feature? صورة من خارج ملفات اللاب



Select one:

- a. Nest Cell
- b. Perichondrium**
- c. Lacunae
- d. Territorial Matrix
- e. Articular Cartilage

Q.17 What is the labelled structure?

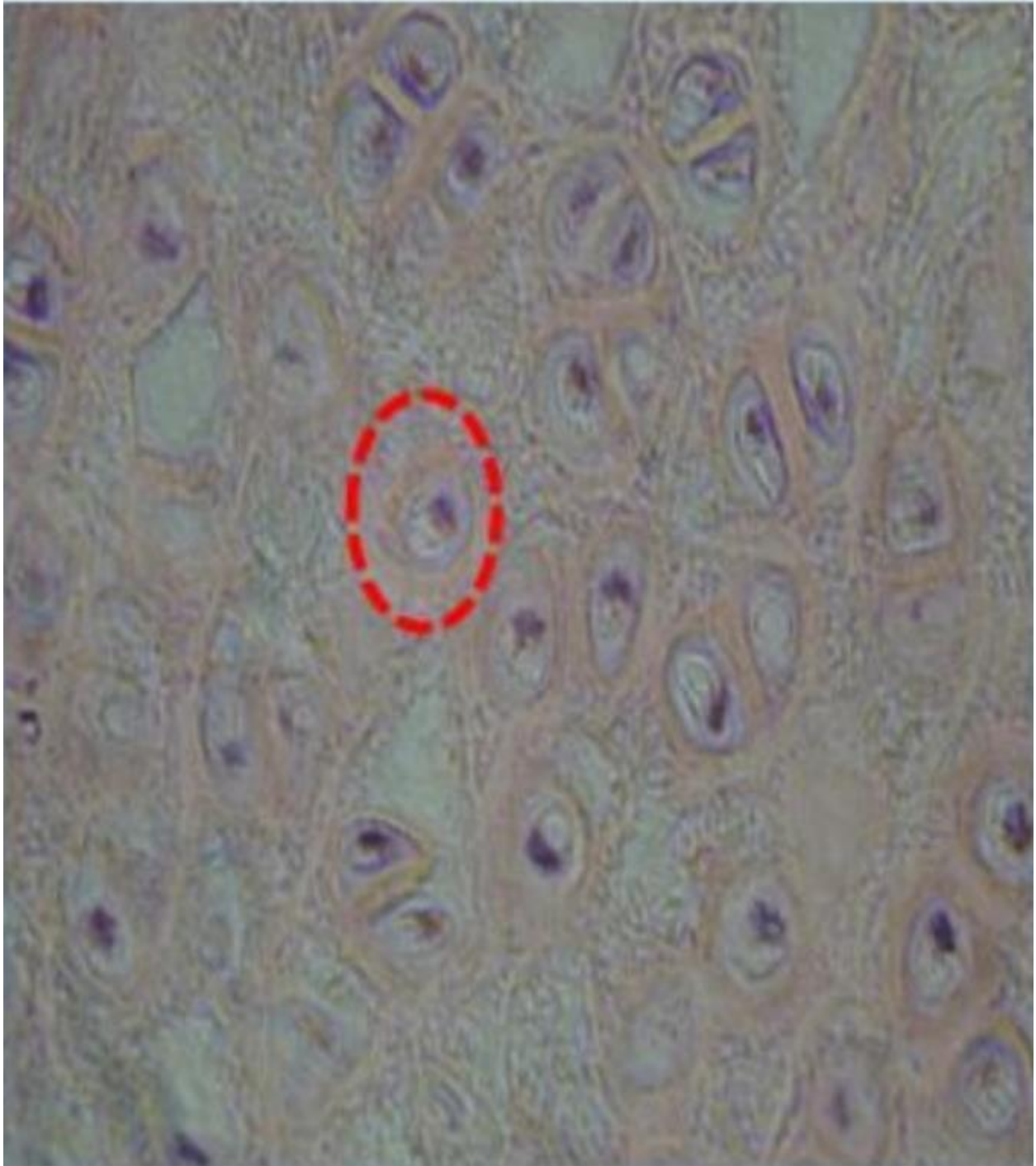


Select one :

- a. Mastoid process
- b. Styloid process
- c. Supramental triangle
- d. External auditory meatus**
- e. Zygomatic arch

Q.18

Identity a histological feature? صورة من خارج ملفات اللاب

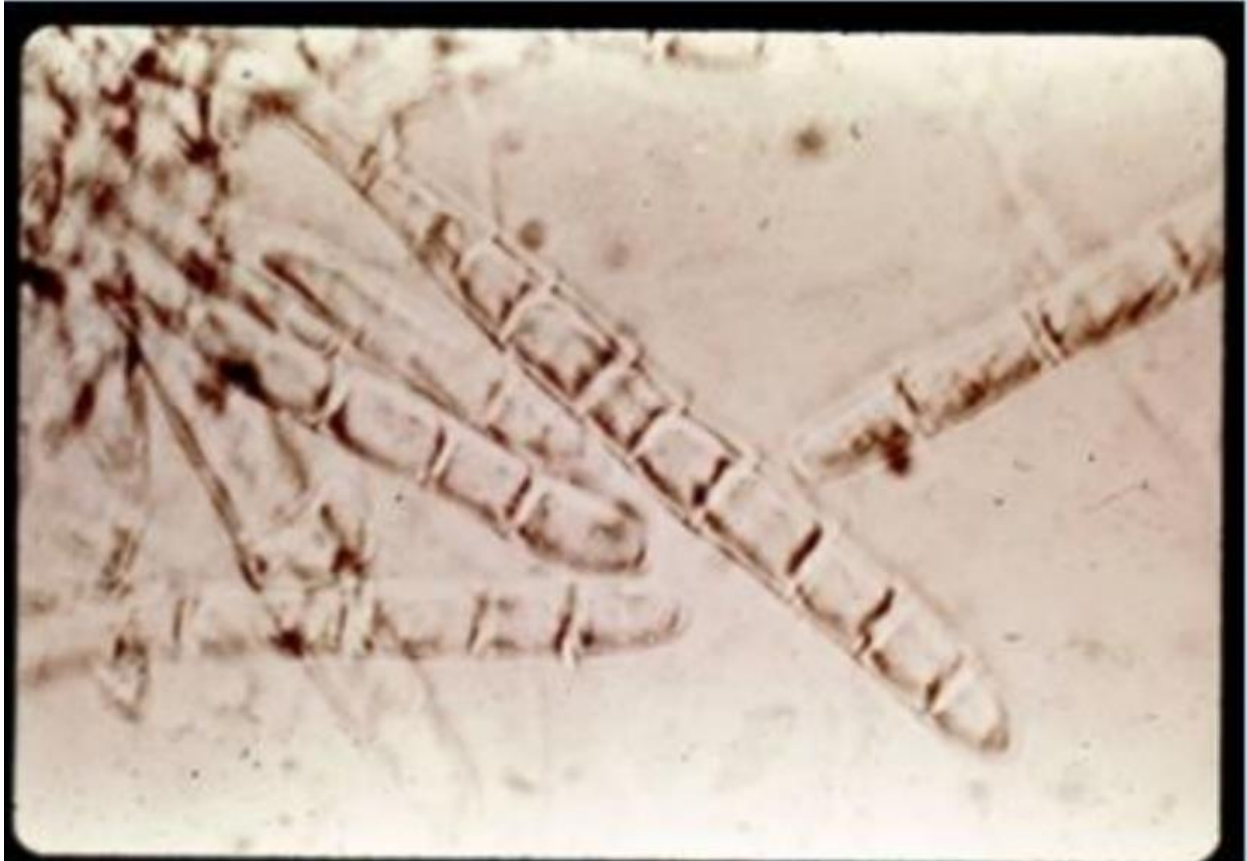

Select one :

A. Canaliculi

- b. Perichondrium
- c. Periosteum
- d. Chondrocyte
- e. Chondrogenic Cell

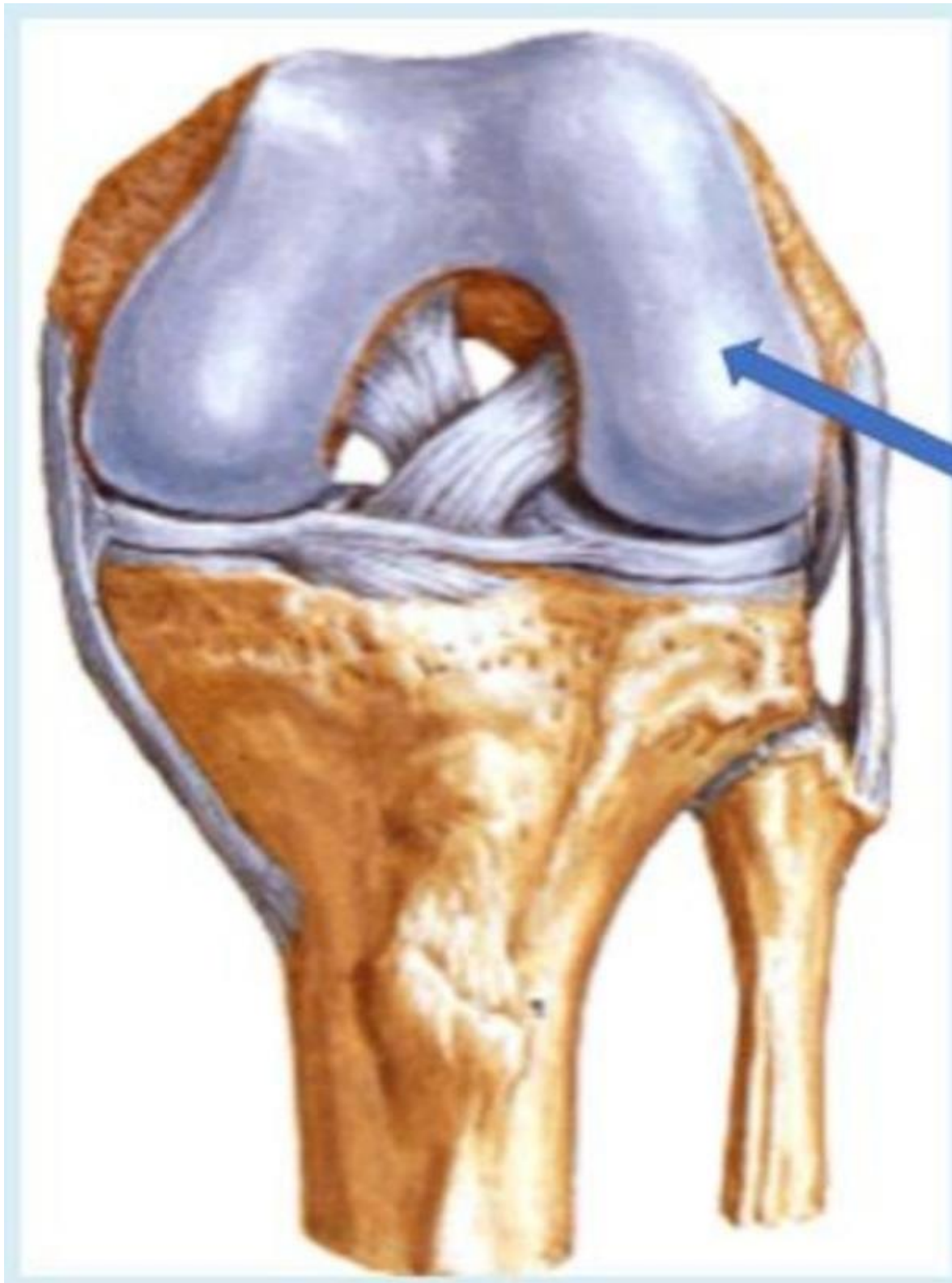Q.19 This dermatophyte is commonly associated with?



Select one:

- a. Tinea cruris
- b. Tinea corporis
- c. Tinea capitis
- d. Tinea pedis
- e. Tinea unguinum

Q.20 What is the labelled structure?

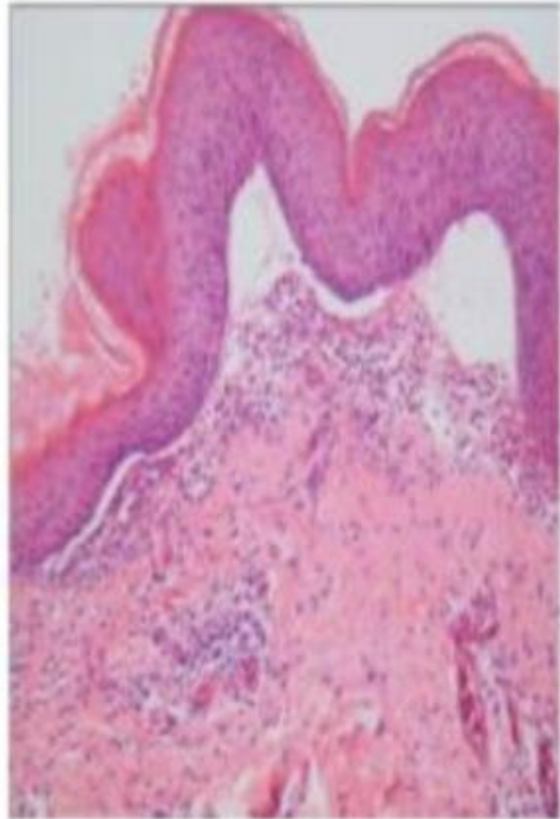
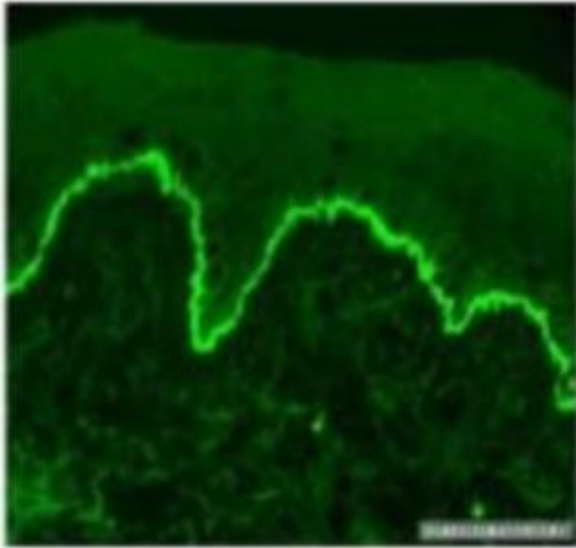


Select one:

- a. Lateral condyle**
- b. Anterior cruciate ligament
- c. Posterior cruciate ligament
- d. Popliteus muscles
- e. Medial condyle

Q.21

A 65-year-old woman complains of having an itchy rash for the past few months She said the lesions first appeared as red woen plaques on her ab and flexor aspect of her forearms Physical examination reveals large bullae on her abdomen and thighs Askin biopay shows a postve dredt immunofiuorescence test along with specific microscopic features as shown in the images. Which of the following is the appropriate diagposis?



Select one :

a. Allergic contact dermatitis

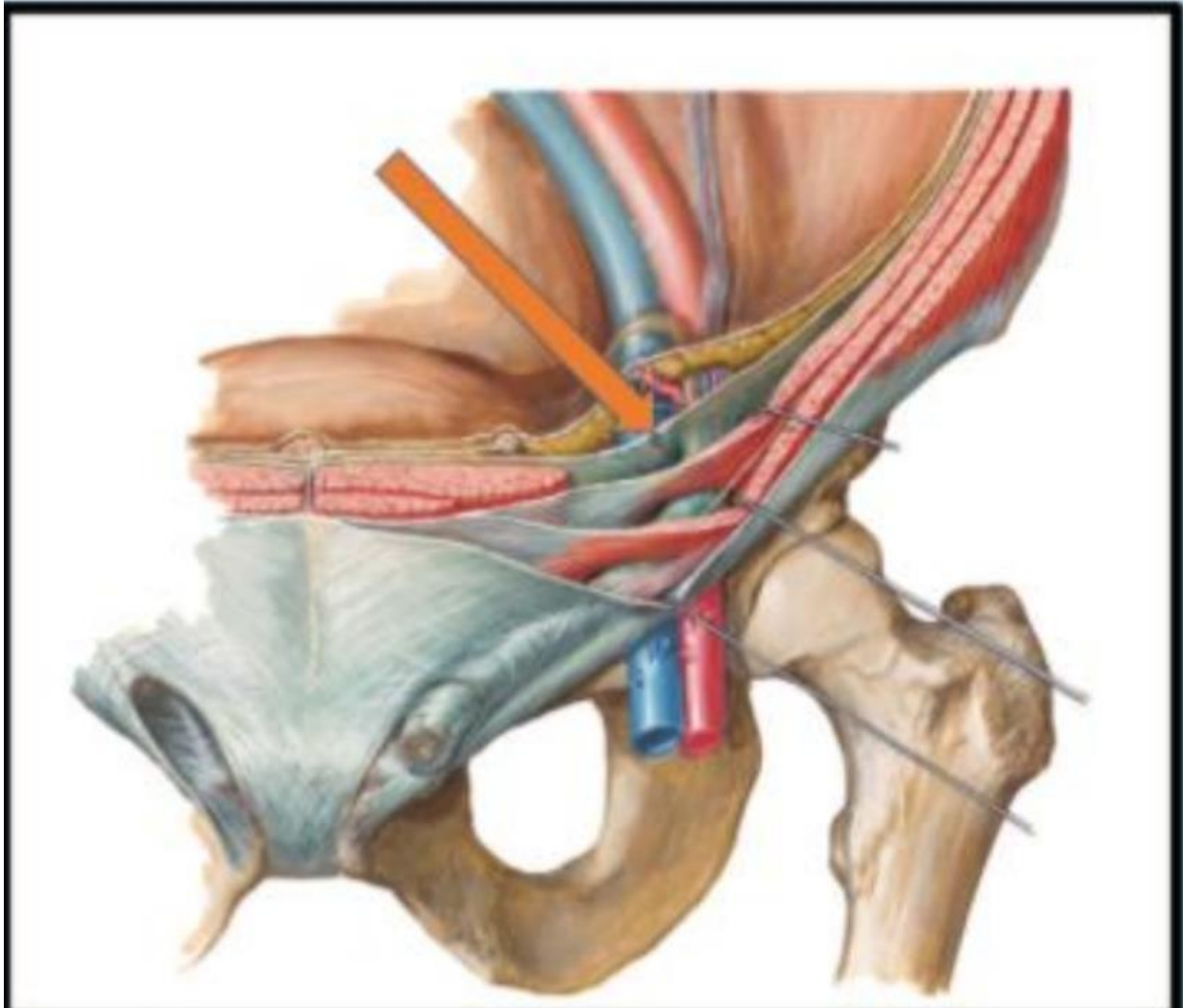
b. Bullous pemphigoid

c. Dermatitis herpetiformis

d. Epidermolysis bullosa

e. Pemphigus vulgaris

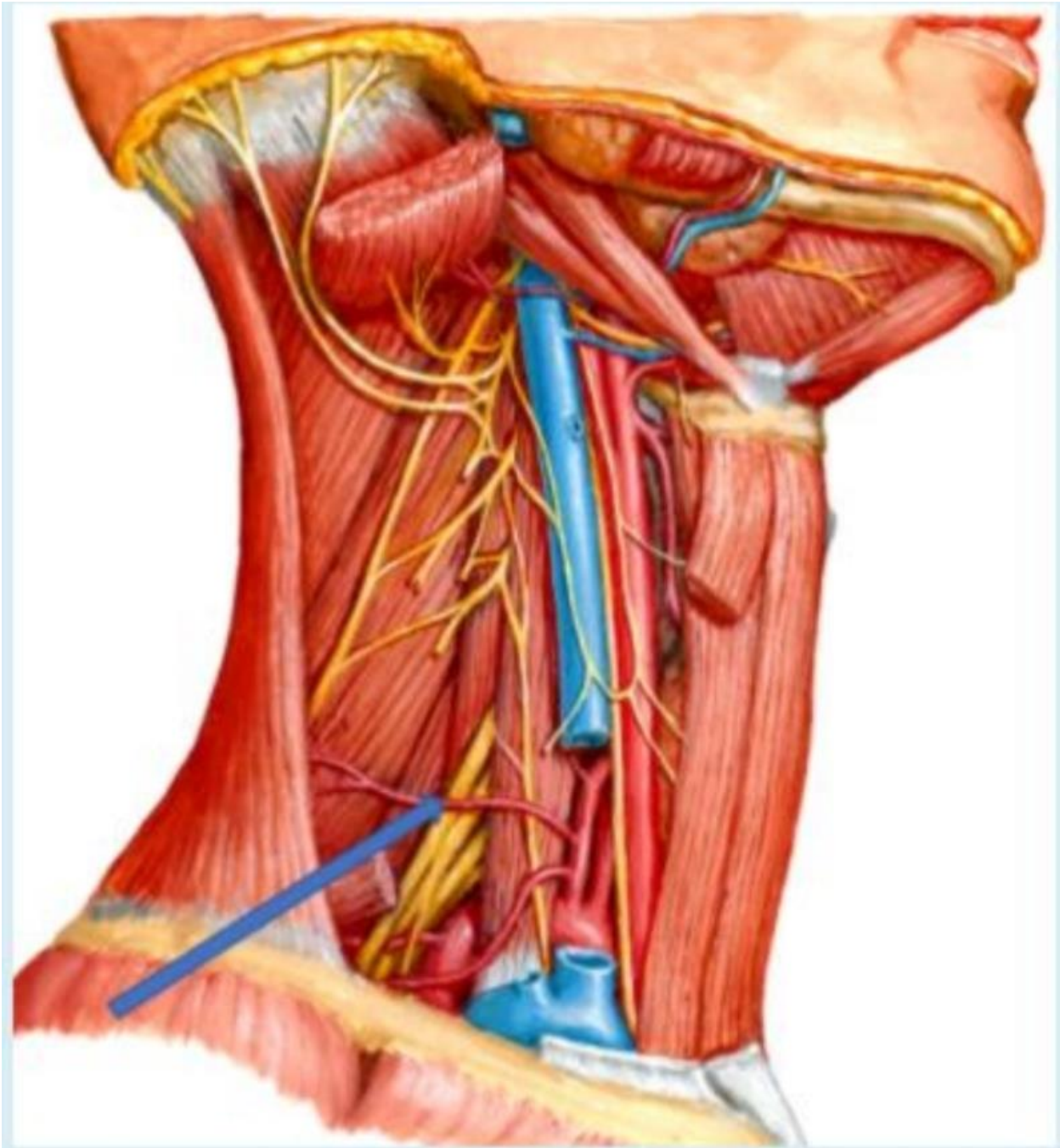Q.22 The indicated structure is?



Select one :

- a. The transversalis fascia
- b. The transversus abdominis muscle
- c. The aponeurosis of the internal abdominal
- d. The transverses aponeuroses
- e. Thoracolumbar fascia

Q.23 What is the labelled structure?



Select one:

- a. Transverse cervical artery
- b. Nerve to thyrohyoid
- c. Suprascapular artery

b. Flexor hallucis longus

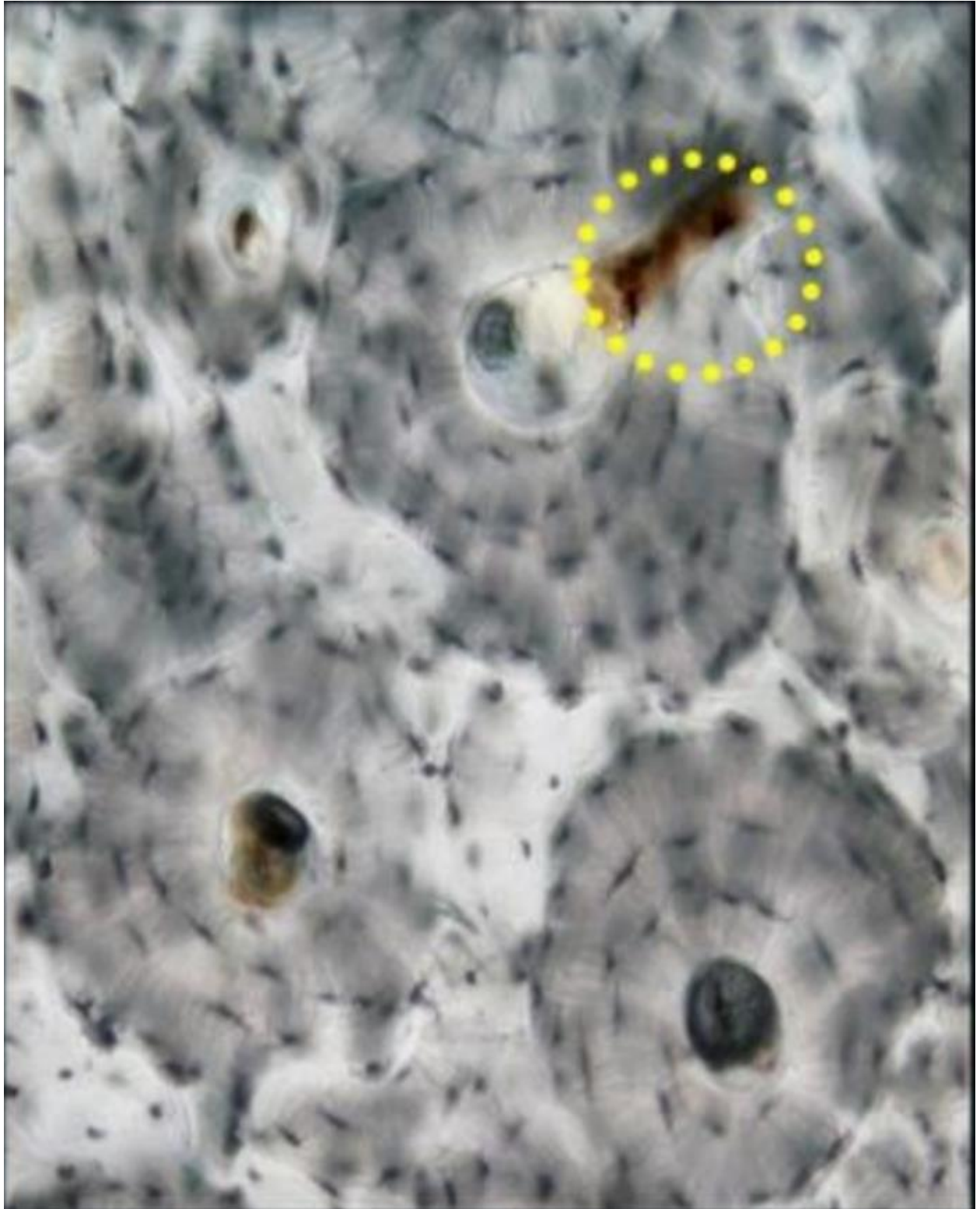
c. Flexor digitorum longus

d. Tibialis anterior

e. Extensor hallucis longus

Q.25 Identify a histological feature?

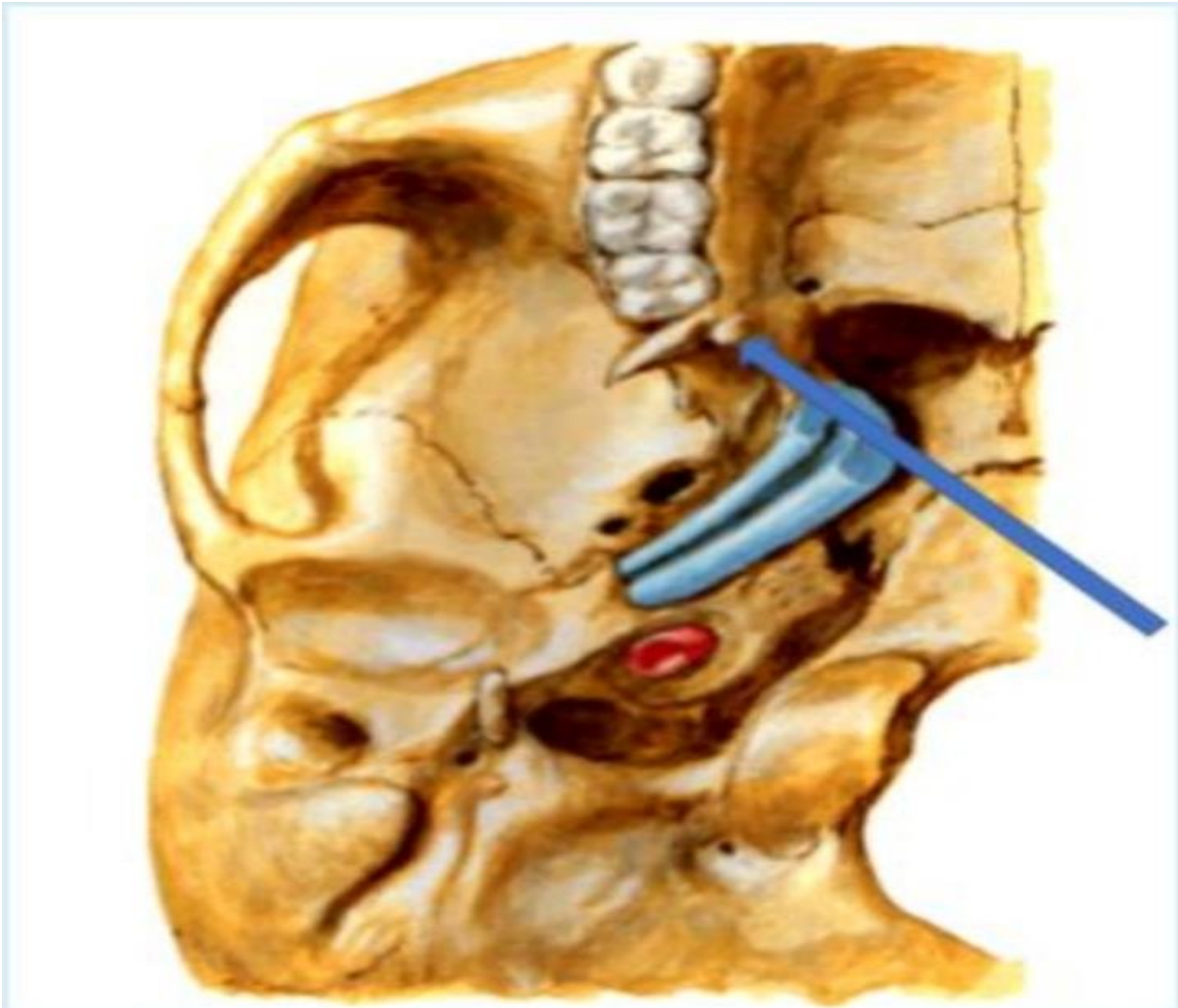
صورة من خارج ملفات اللاب



Select one:

- a. Central canal
- b. Osleon
- c. Volkman's canal
- d. Canaliculi
- e. Lacunae

Q.26 What is the labelled structure?

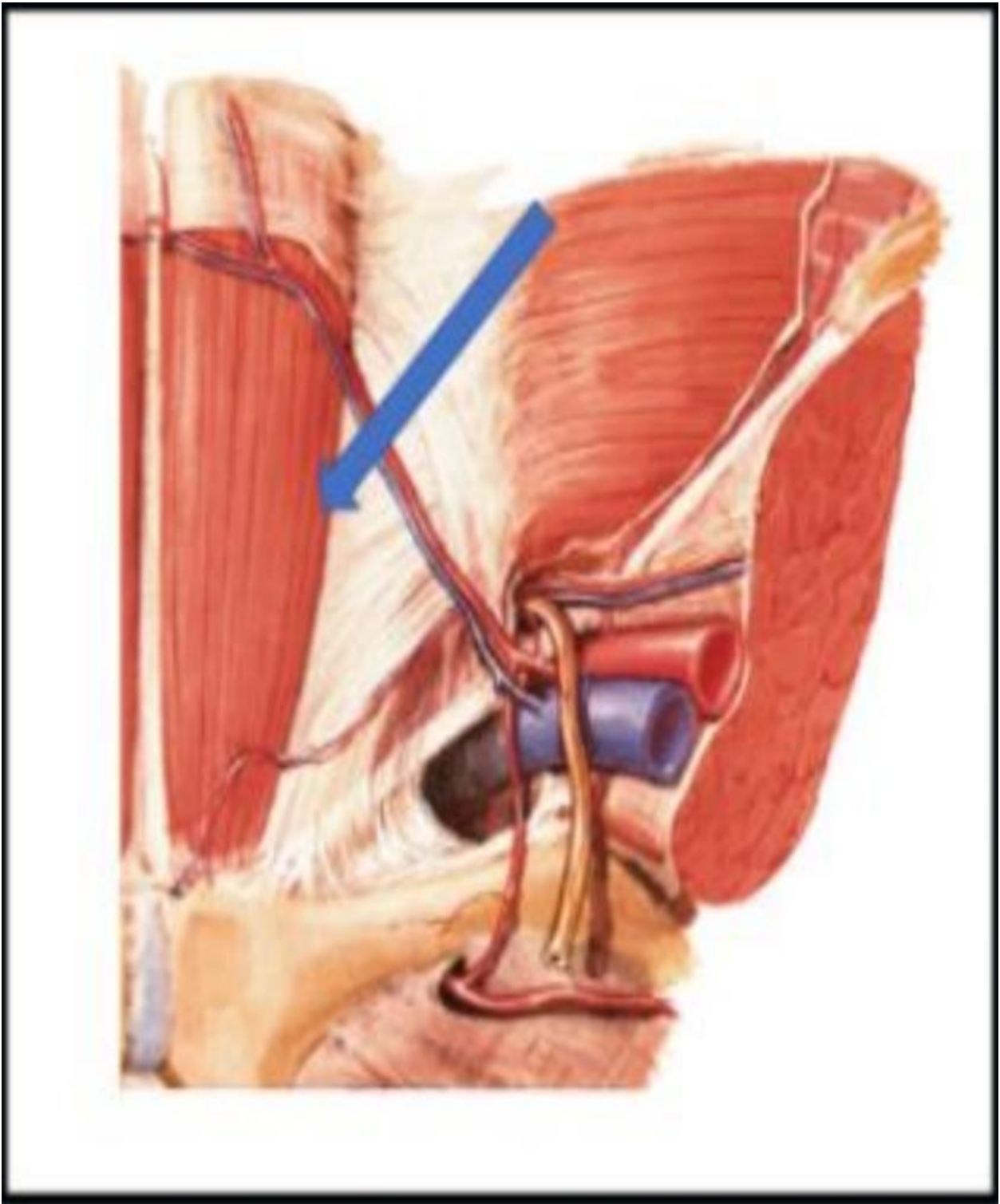


Select one:

- a. Origin of lower head of lateral pterygoid muscles
- b. Origin of deep head of medial pterygoid muscles
- c. Origin of upper head of lateral pterygoid muscles
- d. **Origin of pterygomandibular ligament**

e. Origin of superficial head of medial pterygoid muscles

Q.27 What is the labelled muscle?



Select one :

- a. External abdominal
- b. Internal abdominal

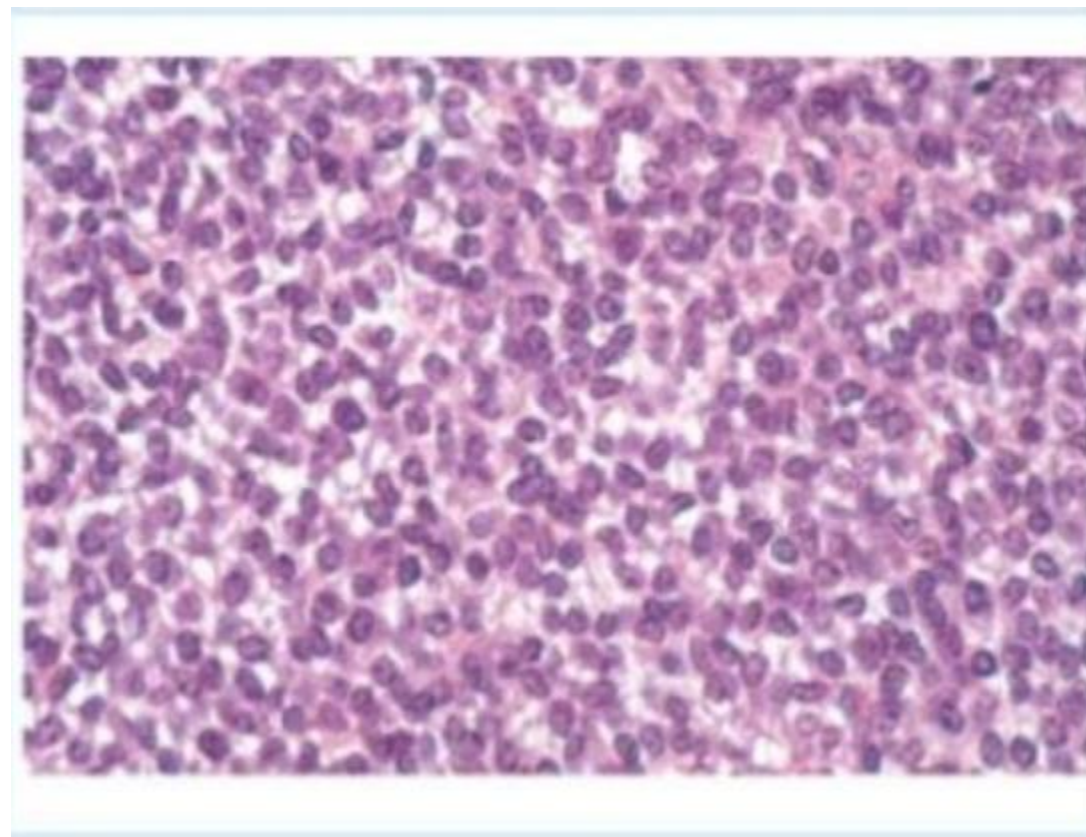
c. Rectus abdominus

d. Cremasteric

e. Transverse abdominal

Q.28 A 16- year od boy presents with swelling on his left tibia An X-ray of the leg shows a destructive process Hislologic eamination of a biopsy showed in this picture. All the following are characteristics of this lesion, except?

Select one :



A. They are primary malignant small round cell tumors of bone.

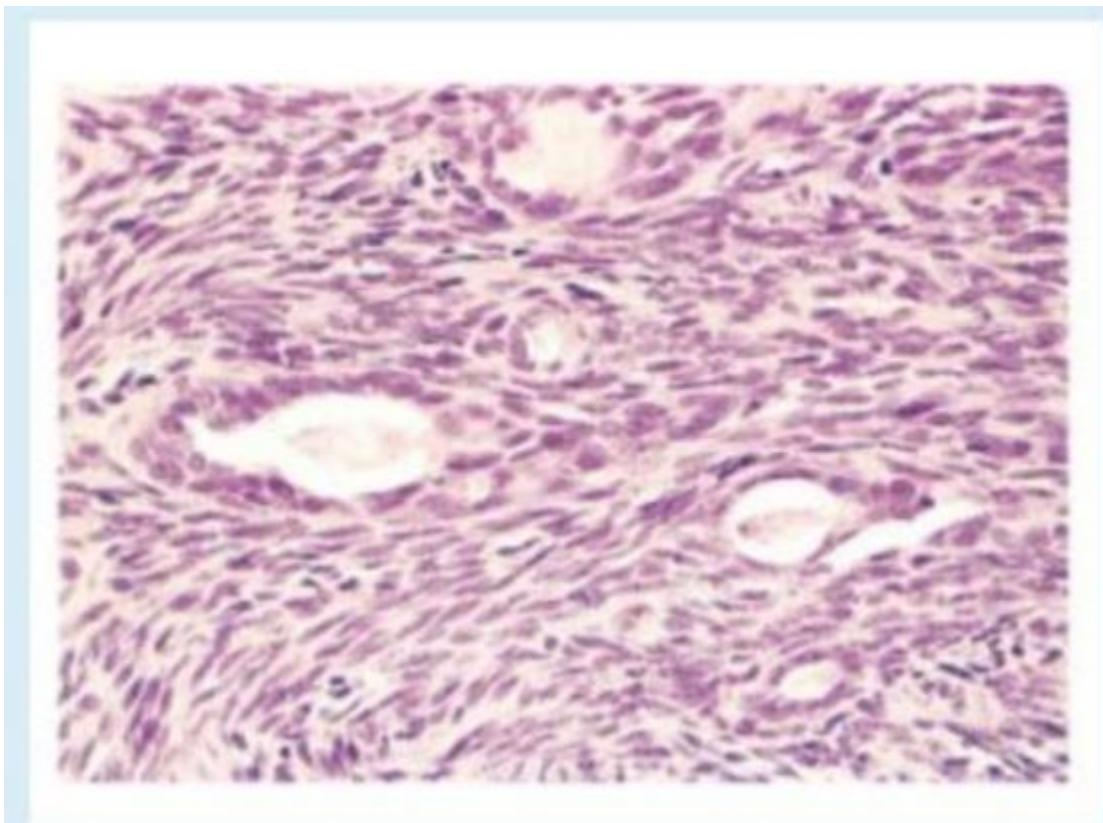
b. Most patients are 10 to 15 years of age, and 80% are younger than 20 years

c. These tumors have a translocation of t(2, 13)

d. It typically manifests as a painful enlarging mass in the diaphysis of long tubular bones.

e. Boys are affected slightly more frequently than girls

Q.29 A 45-year old male presents with swelling on his left tibia An X-ray of the leg shows a destructive process. Histologic examination of a biopsy showed in this picture Which of the following is the chromosomal alternation in of this lesion, except?



Select one

a. t(2,13)

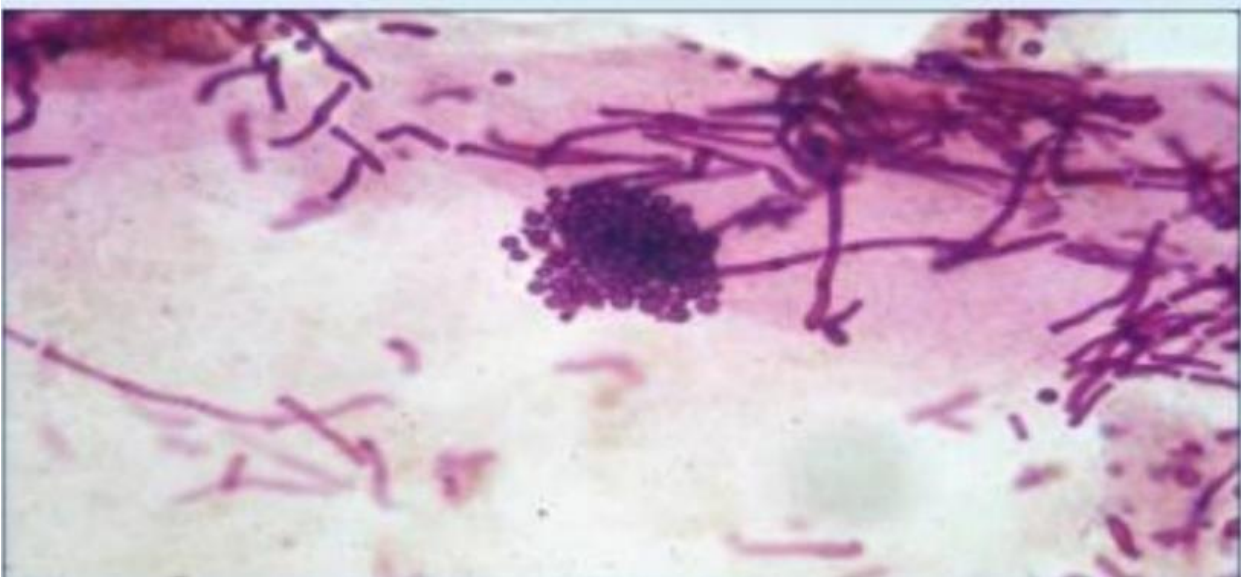
b. t(X,18)

c t(11,22)

d. t(2,13)

e. t(X, 19)

Q.30 One is TRUE regarding this yeast? مش من ملفات اللاب، المحاضرة



Select one :

الإجابة a

a. Lipophobic

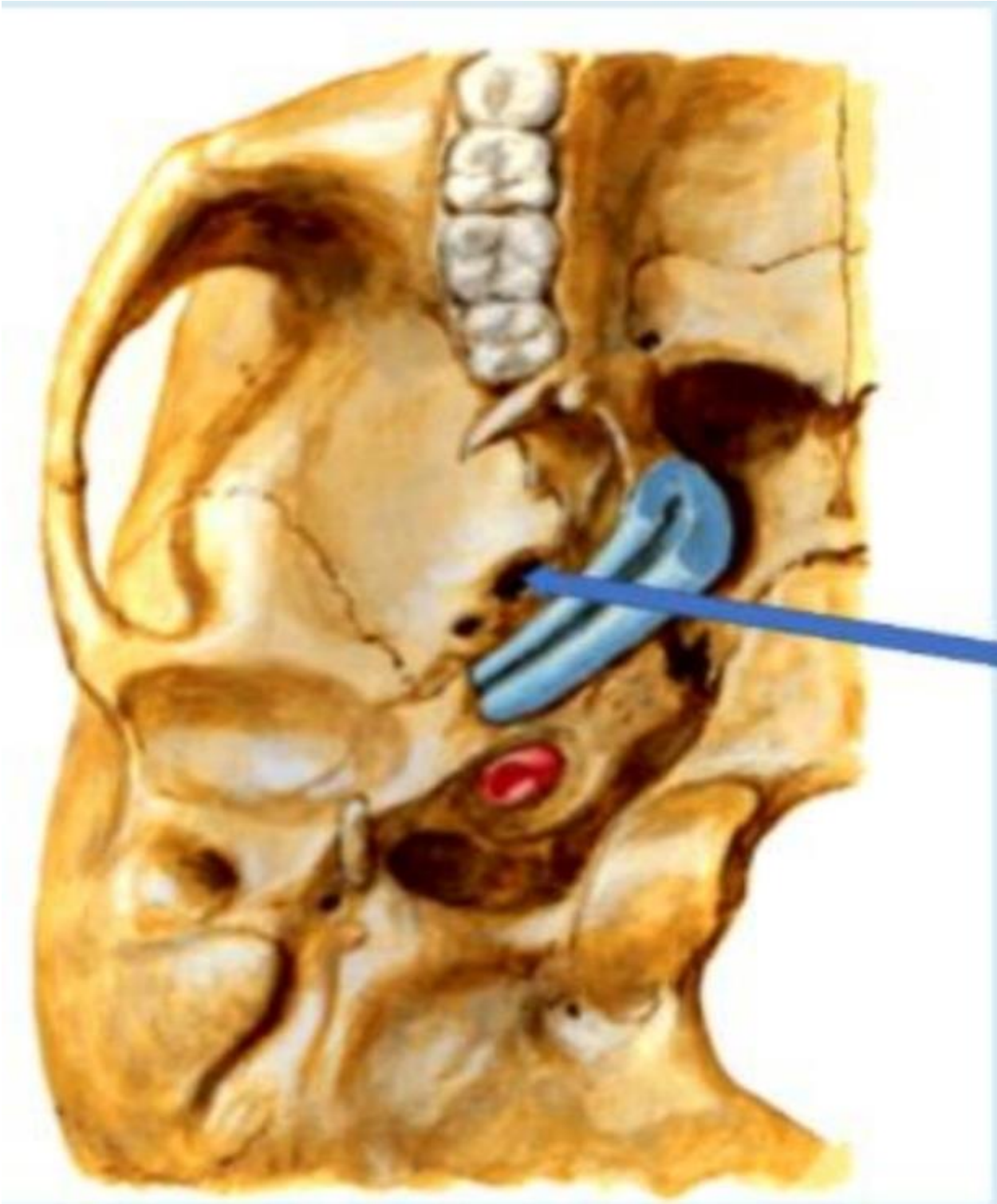
b. Normal flora a.k.a normal commensals

c. Infection might be associated with vaginal discharge

d. Causes very itchy lesions

e. Associated with esophageal infections in immunocompromised

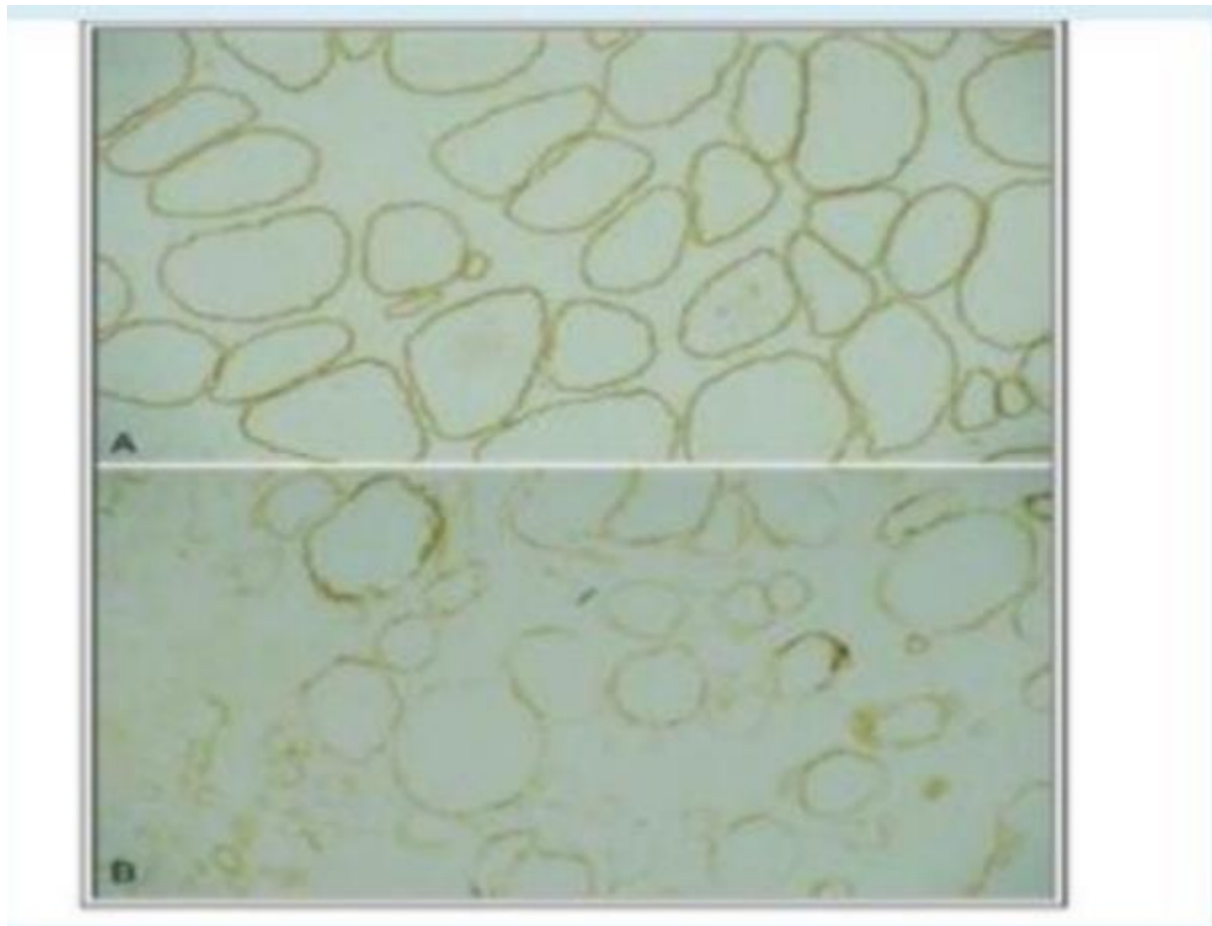
Q.31 What is the labelled structure?



Select one:

- a. Foramen lacerum
- b. Foramen jugular
- c. Foramen ovale**
- d. Carotid canal
- e. Foramen spinosum

Q.32 A 42-year-old man has recently had muscle weakness. On physical examination without muscle pain or loss of joint mobility. A chest radiograph shows cardiomegaly with pulmonary edema and pleural effusions. A muscle biopsy specimen is examined. The figure shows the immunohistochemical staining pattern with antibody to dystrophin (A normal, B. Patient) What is the most likely diagnosis?



Select one:

- a. Polymyositis
- b. Becker muscular dystrophy**
- c. Amyotrophic lateral sclerosis
- d. Myasthenia gravis
- e. Myotonic dystrophy

Q.33

A 25-year-old male, who is an I.V drug abuser, has had pain in the area of the right leg for the past 3 weeks. On physical examination, his temperature is 38 2'C. There is swelling with marked tenderness to palpation in the area of the right leg, pain, and reduced range of motion Which organism is most likely produce these pictures findings?



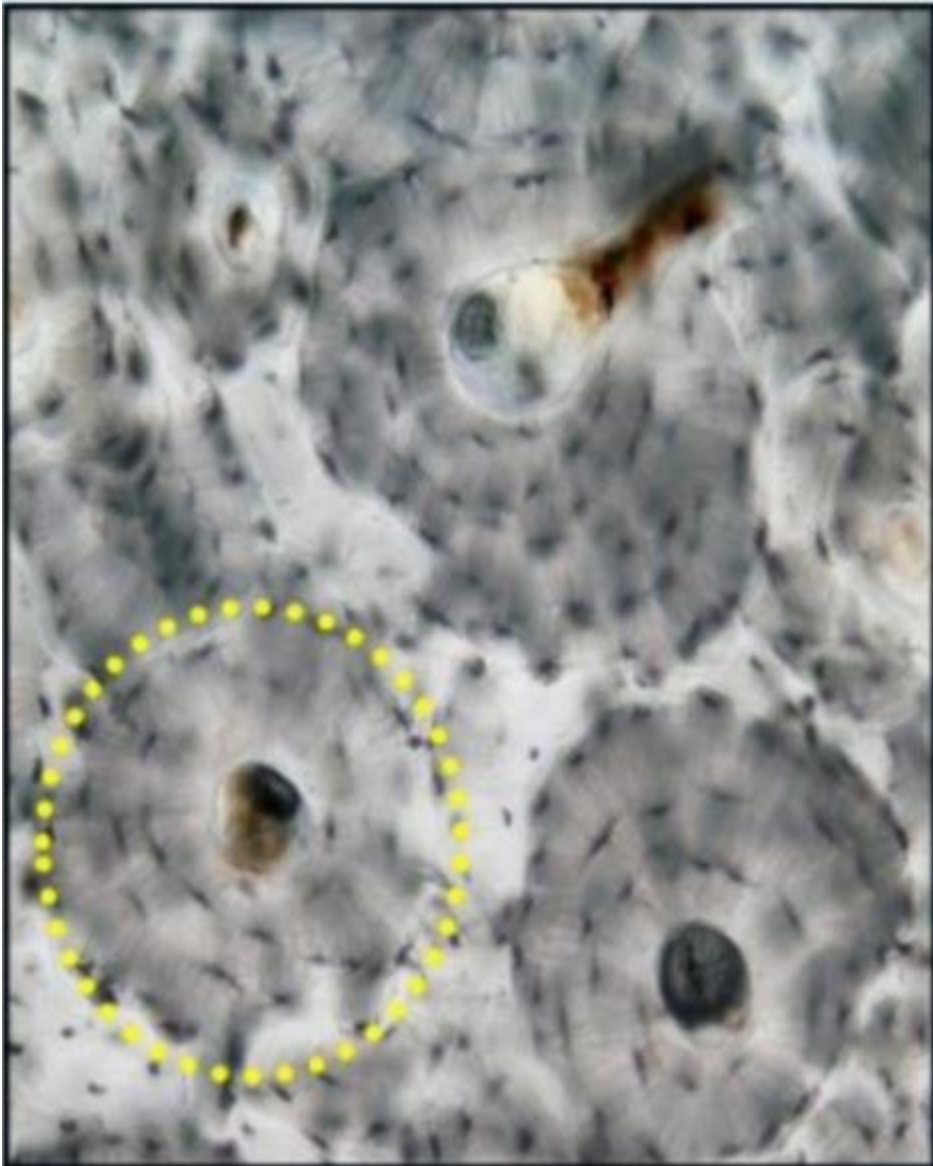
Select one:

- a. Staphylococcus epidermidis.
- b. Salmonella species
- c. Tuberculosis.
- d. Staphylococcus aureus.**

e. Pseudomonas

Q.34

Identify a histological feature? صورة إضافية مش ضمن ملفات اللاب



Select one:

a. Central canal

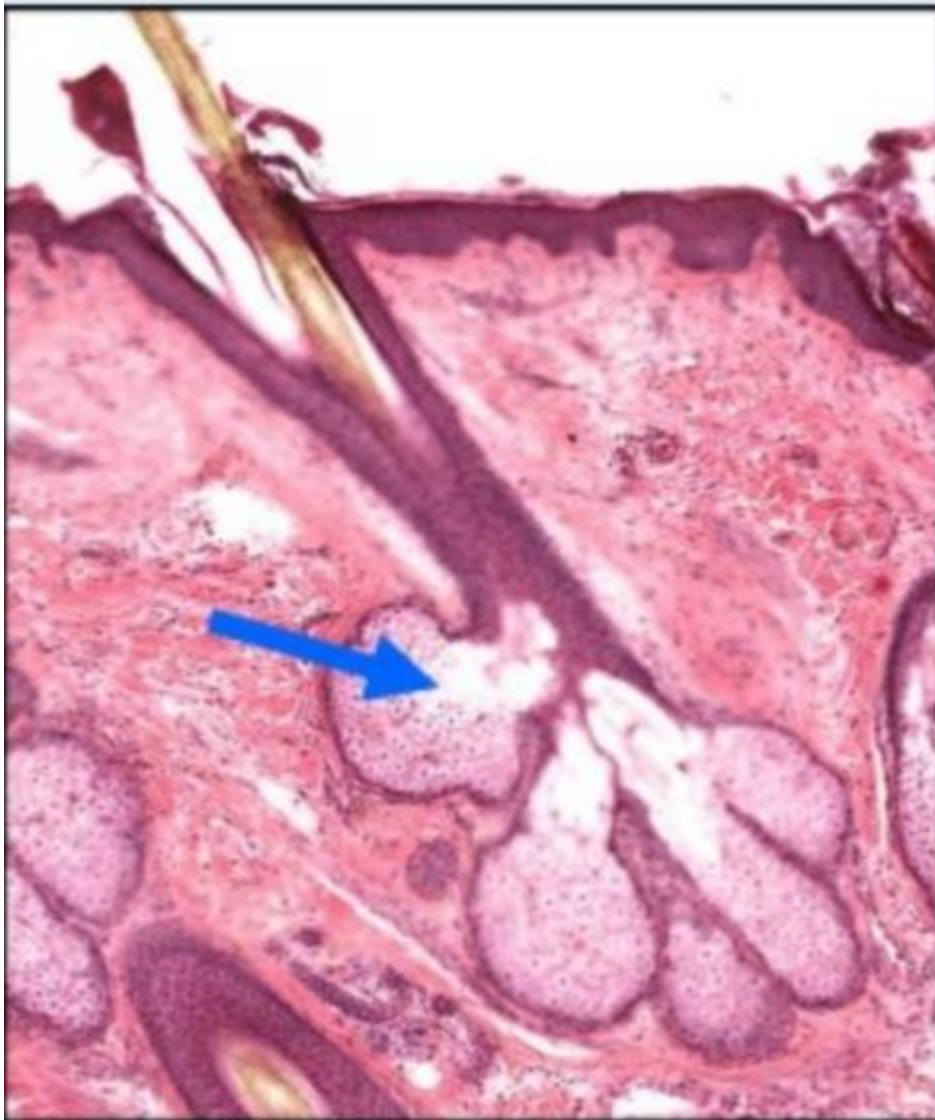
b. Osteon

c. Volkman's canal

d. Canaliculi

e. Lacunae

Q.35 Identify a histological feature?



Select one:

a. Sweat gland

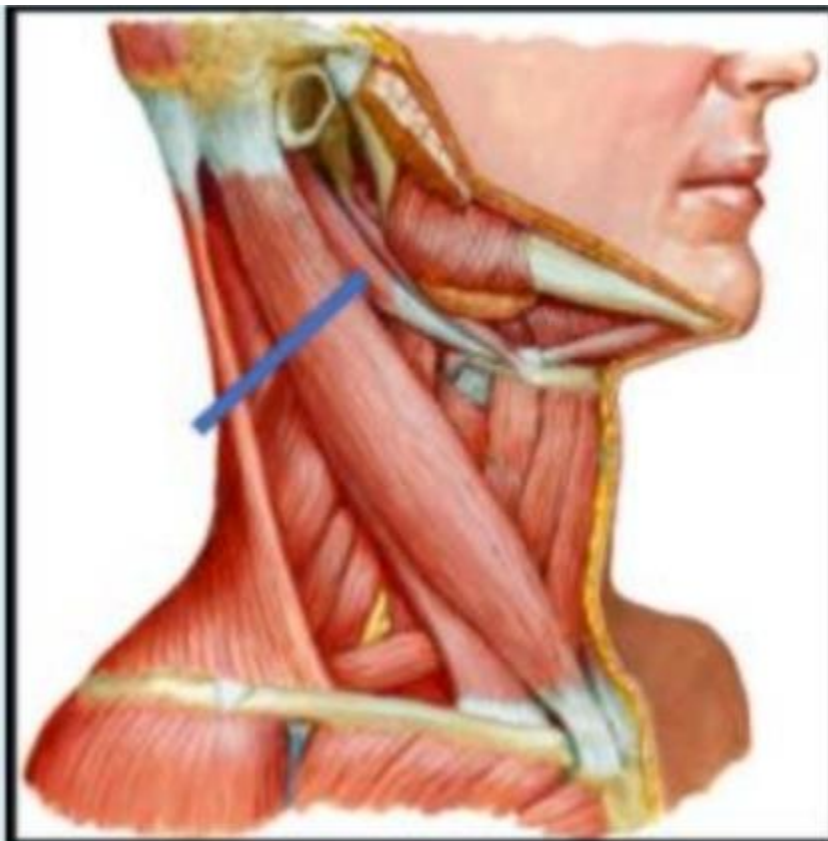
b. Sebaceous gland

c. Hair follicle

d. Keratin

e. Papillary

Q.36 What is the labelled structure?



Select one:

a. Anterior belly of digastric .

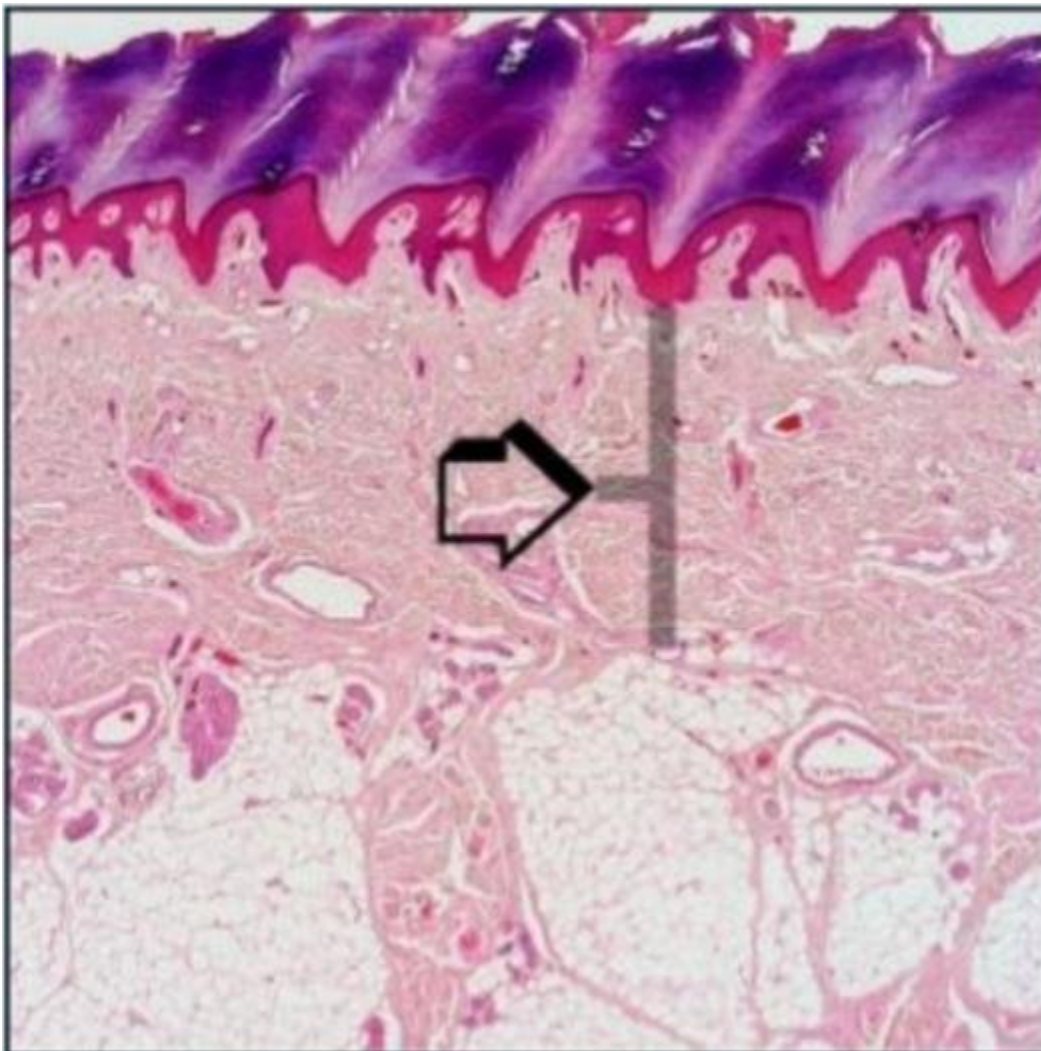
b. Platysma

c. Mylohyoid

d. Posterior belly of digastric

e. Genioglossus

Q.37 Identify a histological feature?

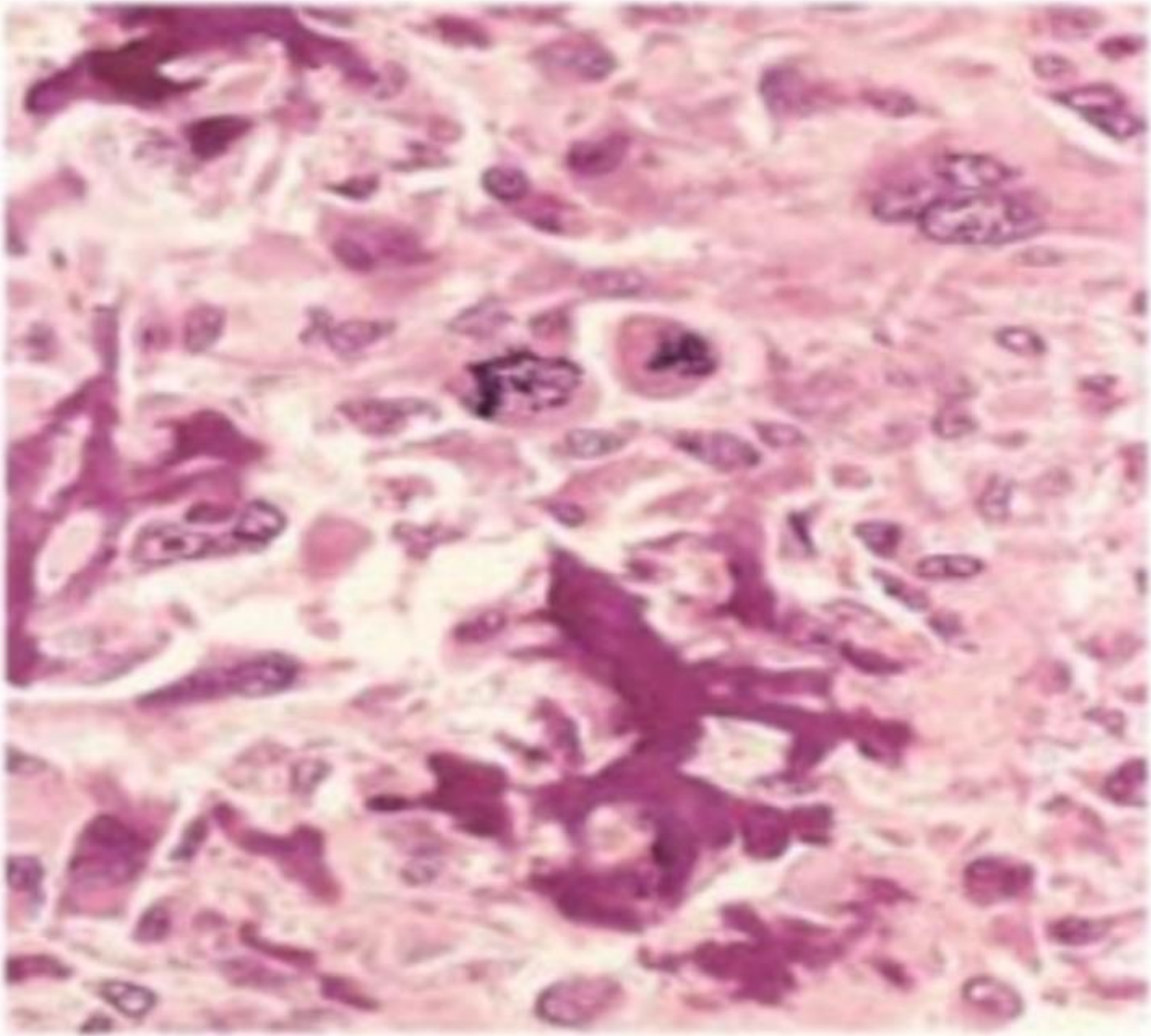


Select one :

- a. Stratum germinativum
- b. Stratum spinosum
- c. Reticular dermis
- d. Stratum lucidum
- e. Papillary dermis

Q.38

An 18-year-old man sees the physician because he has had pain around the right knee for the past 3 months. A radiograph of the right leg shows an ill-defined mass involving the metaphyseal area of the distal right femur, and there is elevation of the adjacent periosteum. A bone biopsy specimen (shown in the picture) What the most likely diagnosis?

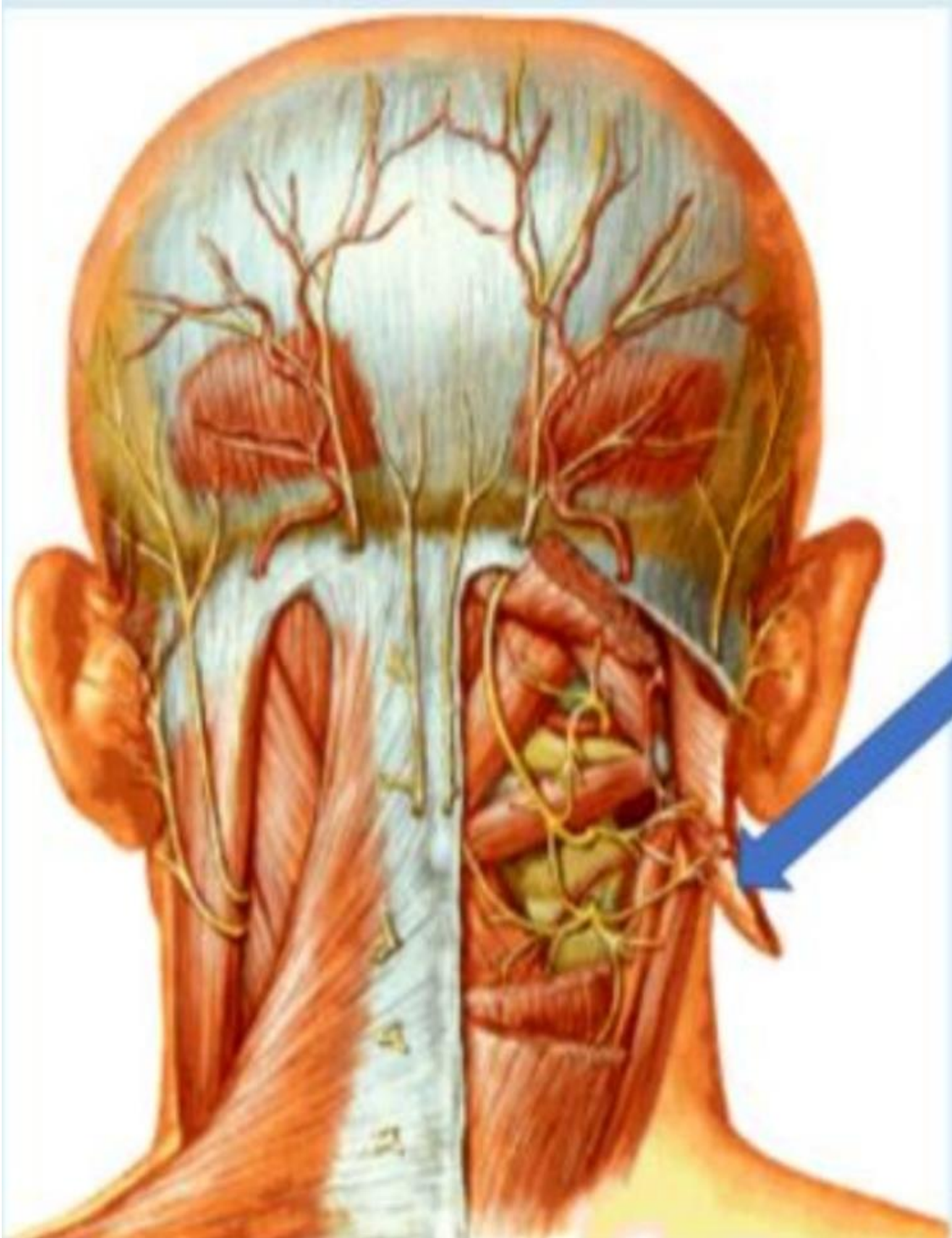


Select one:

- a. Ewing sarcoma
- b. Chondrosarcoma
- c. Giant-cell tumor of bone
- d. Fibrous dysplasia
- e. Osteosarcoma**

Q.39

What is the labelled structure?



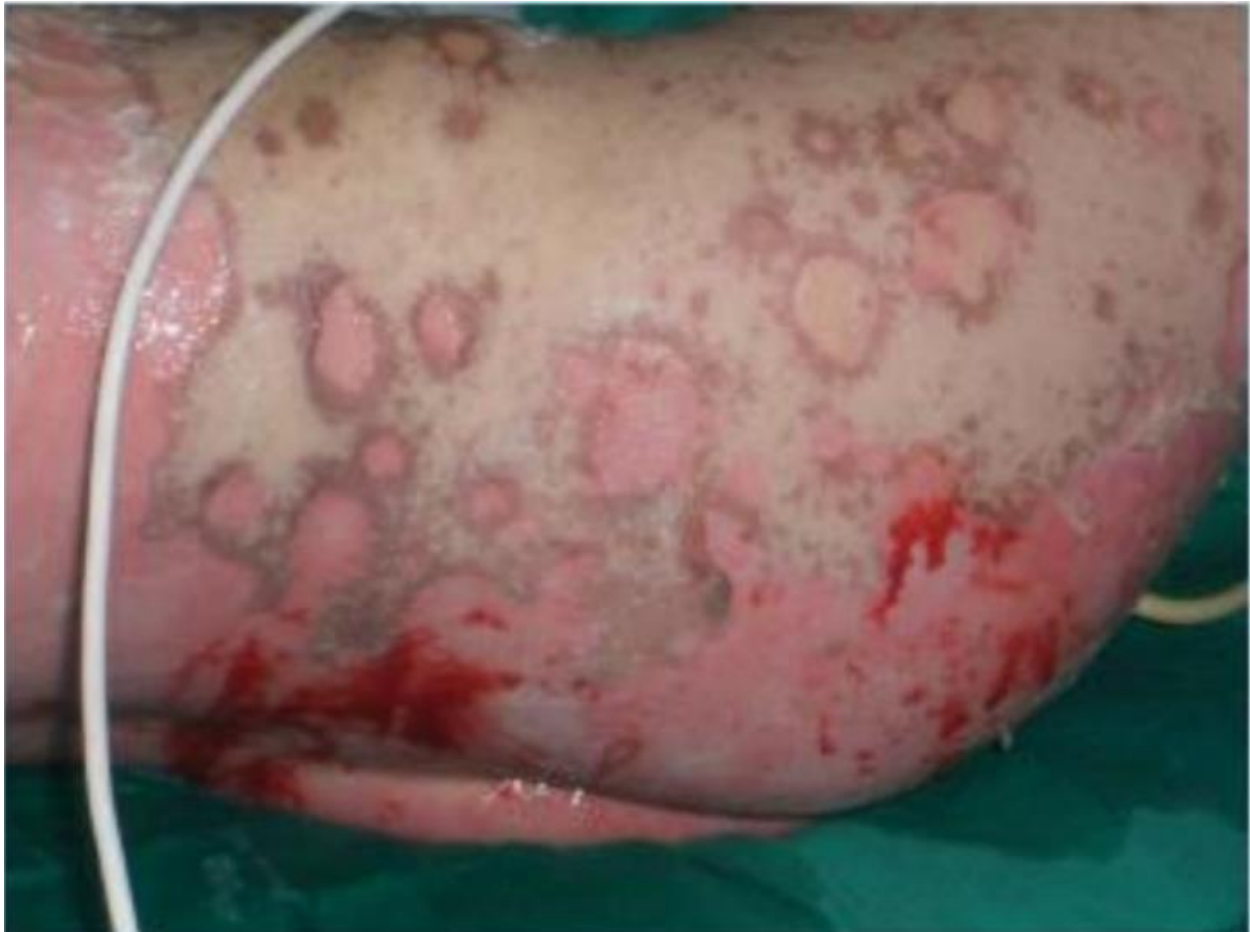Select one:

a. Splenius capitis

- b. Semispinalis capitis muscles
- c. Oblique capitis superior
- d. Rectus capitis posterior major
- e. Rectus capitis posterior minor

Q.40

Which of the following histopathologic finding would be most likely found when examining the patient's skin under the microscope?



Select one

- a. Hyperkeratotic and acanthosis.
- b. Lymphocytes along the dermoepidermal with apoptotic keratinocytes**
- c. Confluent zones of basal epidermal necrosis
- d. Minimal spongiotic dermatitis

e. A sparse superficial perivenular infiltrate of mononuclear cells