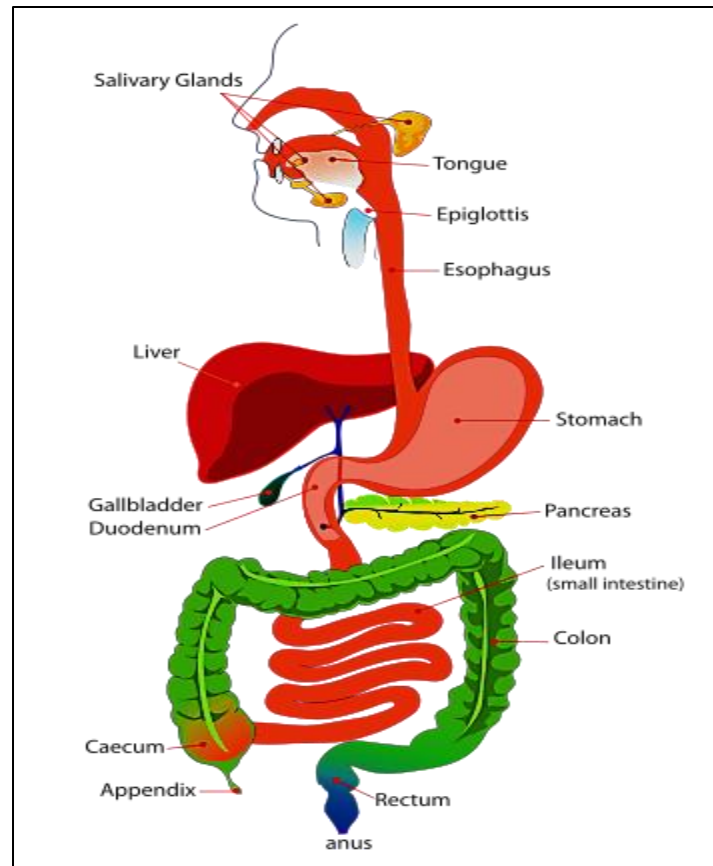


# The digestive system

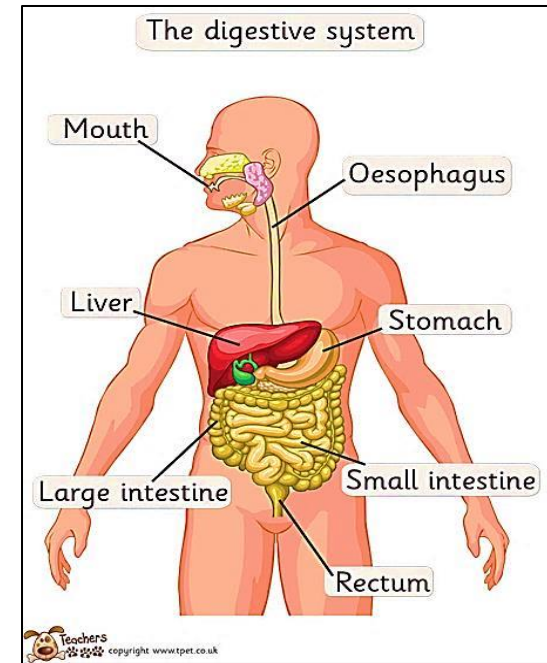


# Digestive system

1. Oral cavity

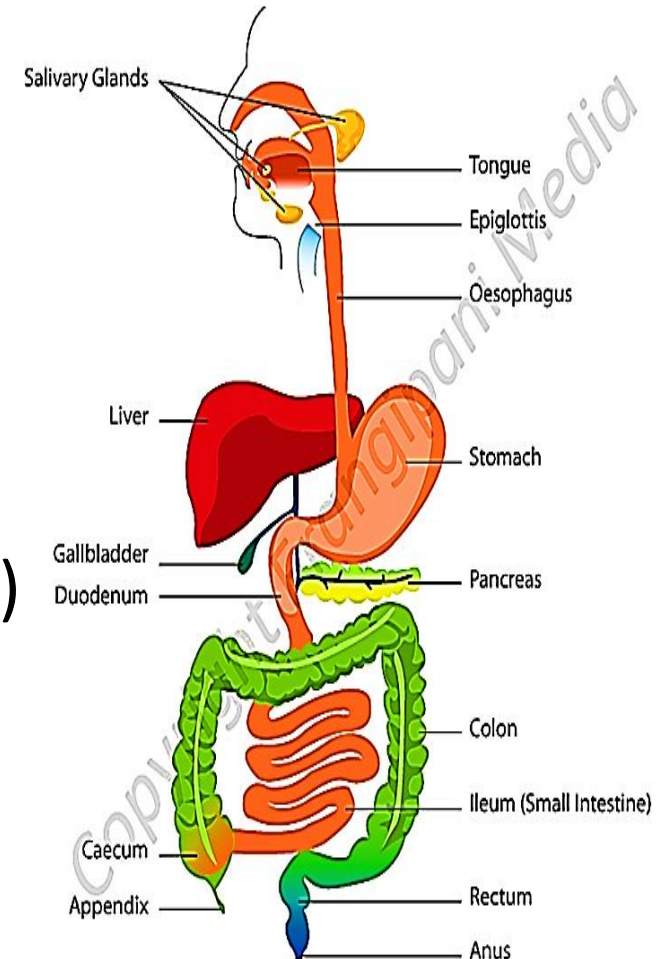
2. Digestive tract

3- glands



## Parts of the digestive system:

- **The oral cavity** ( lips, tongue, teeth & salivary glands)
- **The alimentary canal** ( esophagus stomach, small/ large intestine, & anal canal)
- **The associated glands** (liver, pancreas)



## Function of digestive system:

- **Ingestion & fragmentation of food**.....oral cavity
- **Digestion**..... oral cavity, salivary glands, stomach, small intestine, liver & pancreas
- **Absorption**..... small intestine (food) & large intestine (water)
- **Elimination of waste products**..... anal canal

# The mouth (oral) cavity

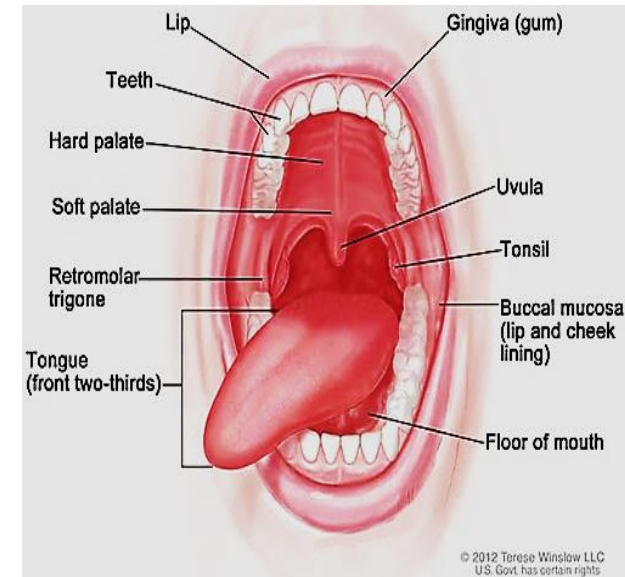
- contains the lips, tongue, gingiva , the teeth

- The ducts of **major & minor** salivary glands open into the oral cavity

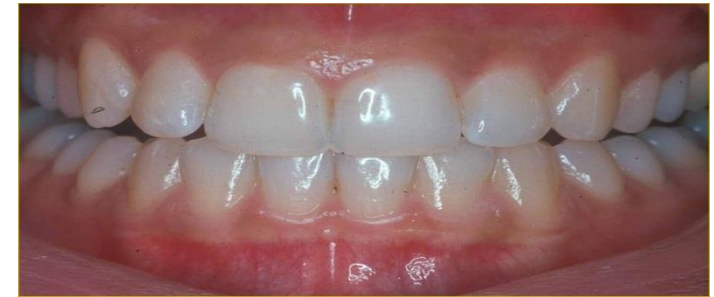- The oral cavity is lined by mucous membrane → formed of 2 layers:

a- Epith : stratified squamous. its cells rich in glycogen  
( Keratinized or non-keratinized)

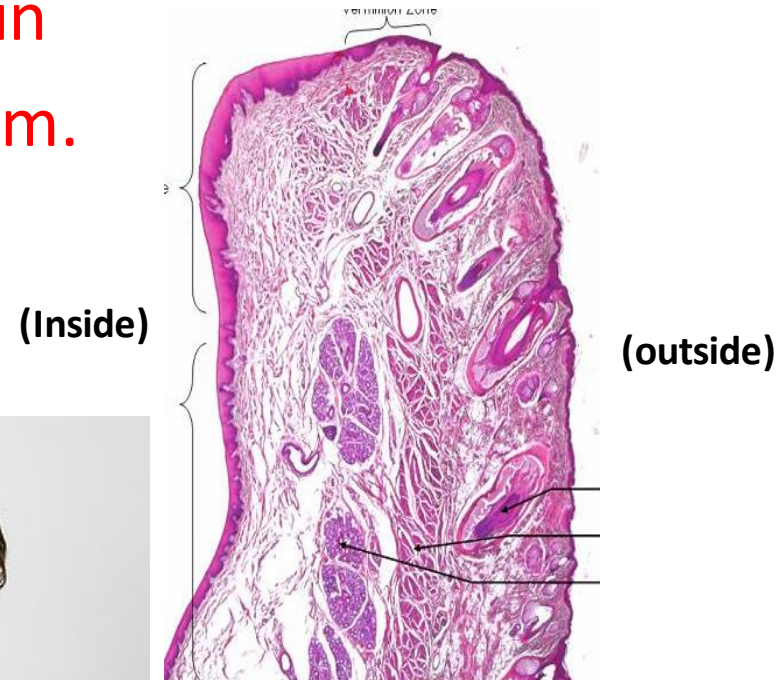
b- Lamina propria: loose C.T. under the epith. contains minor salivary glands , B.V. & lymphatics , nerves



- Gum (gingiva): is the mucous membrane (m.m.) which adherent to the periosteum of the alveolar bone of the teeth. Covered with **keratinized stratified squamous epithelium**



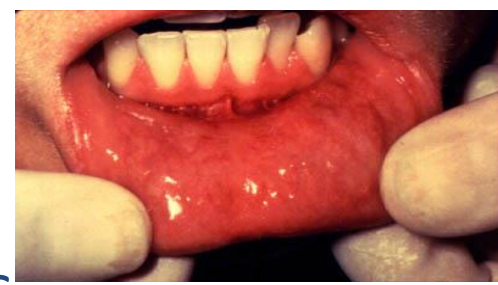- The lip: has
  - a- **External surface** covered by **skin**
  - b- **Internal surface** covered by **m.m.**
  - c- **The inside** of the lip contains bundles of skeletal ms (**orbicularis oris**) & fibro-elastic C.T.



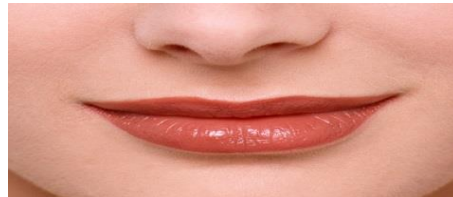## Structure of lip:

A- Internal surface: covered by **m. m.**

- **Epith**: Non-keratinized stratified squamous
- **Lamina propria**: loose C.T., contains **B.V.**, lymphatics, nerves, labial glands \*



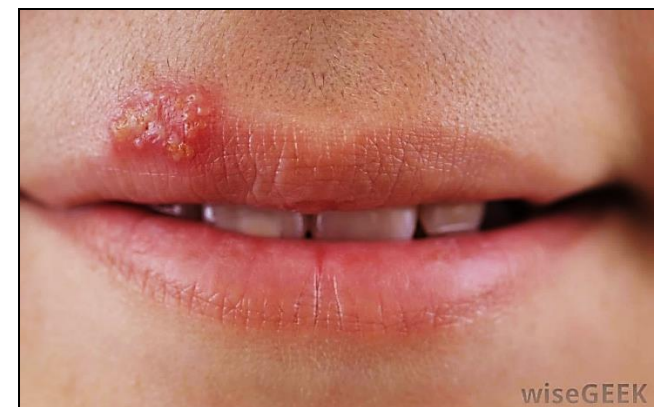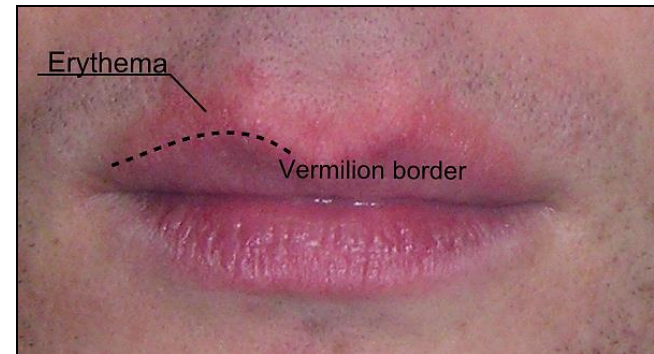
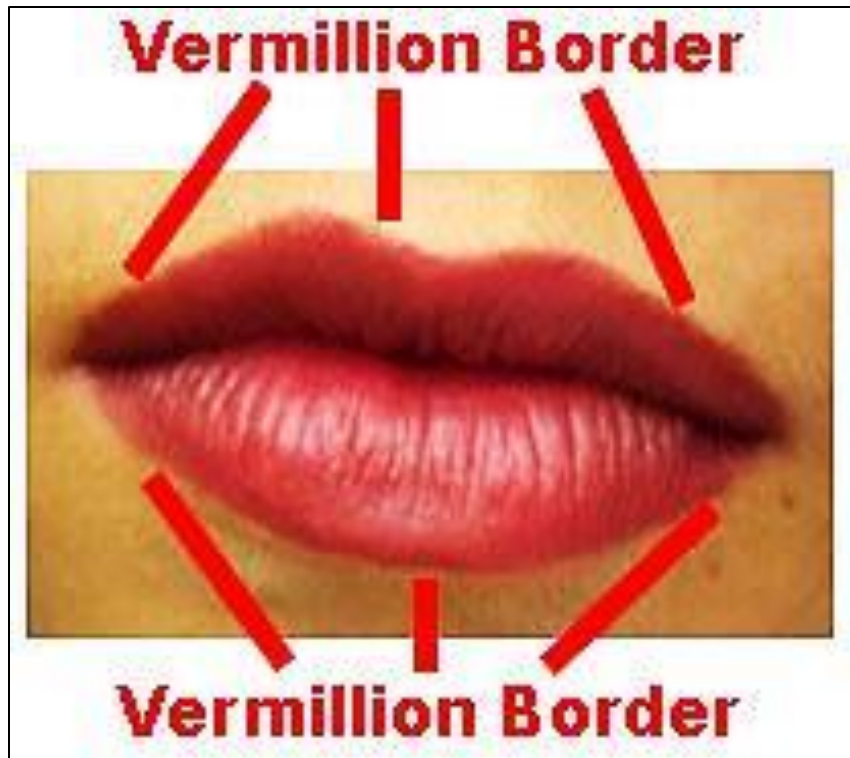B- External surface: covered with thin **skin** (keratinized stratified squamous epith. ) contains hair follicles, sebaceous, & sweat glands



C- Red margin of lip : covered with **modified skin**, *thin* (less keratinized, No hair follicles, No sebaceous or sweat gland. *Transparent. Red* due to the reflection of the underlying B.V.

The lip margin (**vermilion**) represent the change in the epidermis from highly keratinized face skin to less Keratinized lip skin. richly supplied e free nerve endings. So it is *highly sensitive*.

(herpetic stomatitis : HSV type I)





## The tongue: (highly mobile muscular organ)

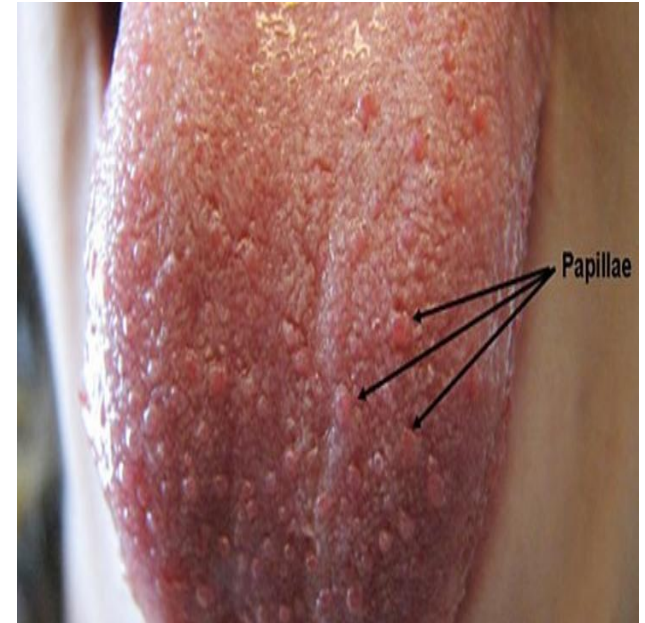
- Made of interlacing bundles of **skeletal ms.** ( 4 intrinsic & 4 extrinsic) covered on both surfaces with m.m.

### 1- *The dorsum* of the tongue

is covered e para-keratinized stratified squamous epithelium

firmly attached to underlying C.T. that contains B.V., nerves, lymphatics & minor Salivary glands

- The ant 2/3 of dorsum of the tongue contain projections called papillae
- while the post 1/3 contains lingual tonsil

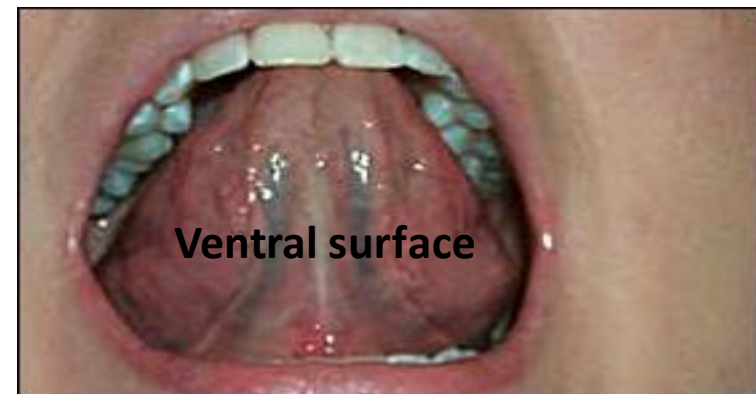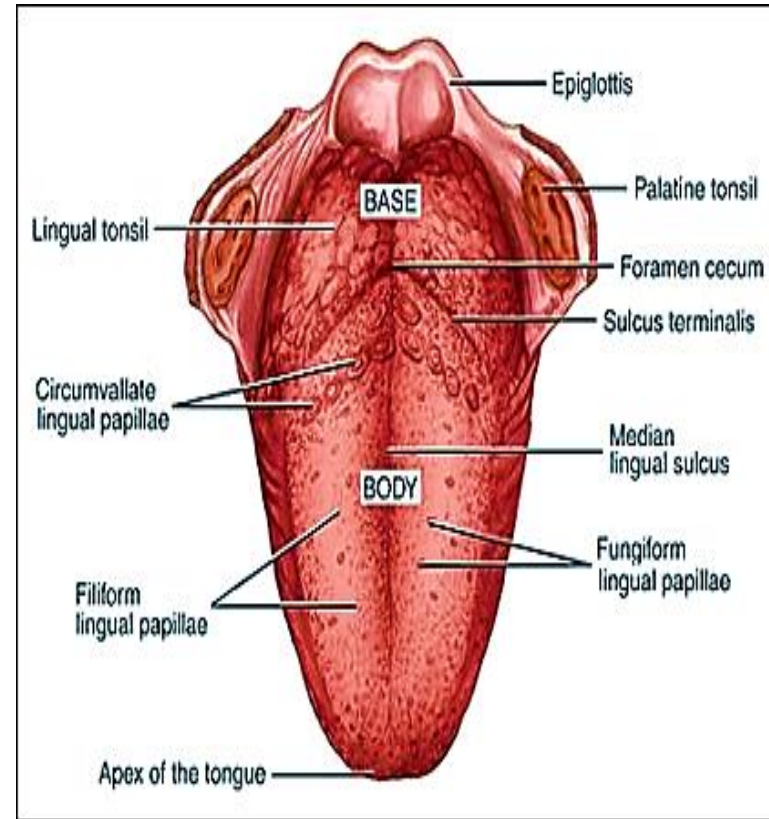


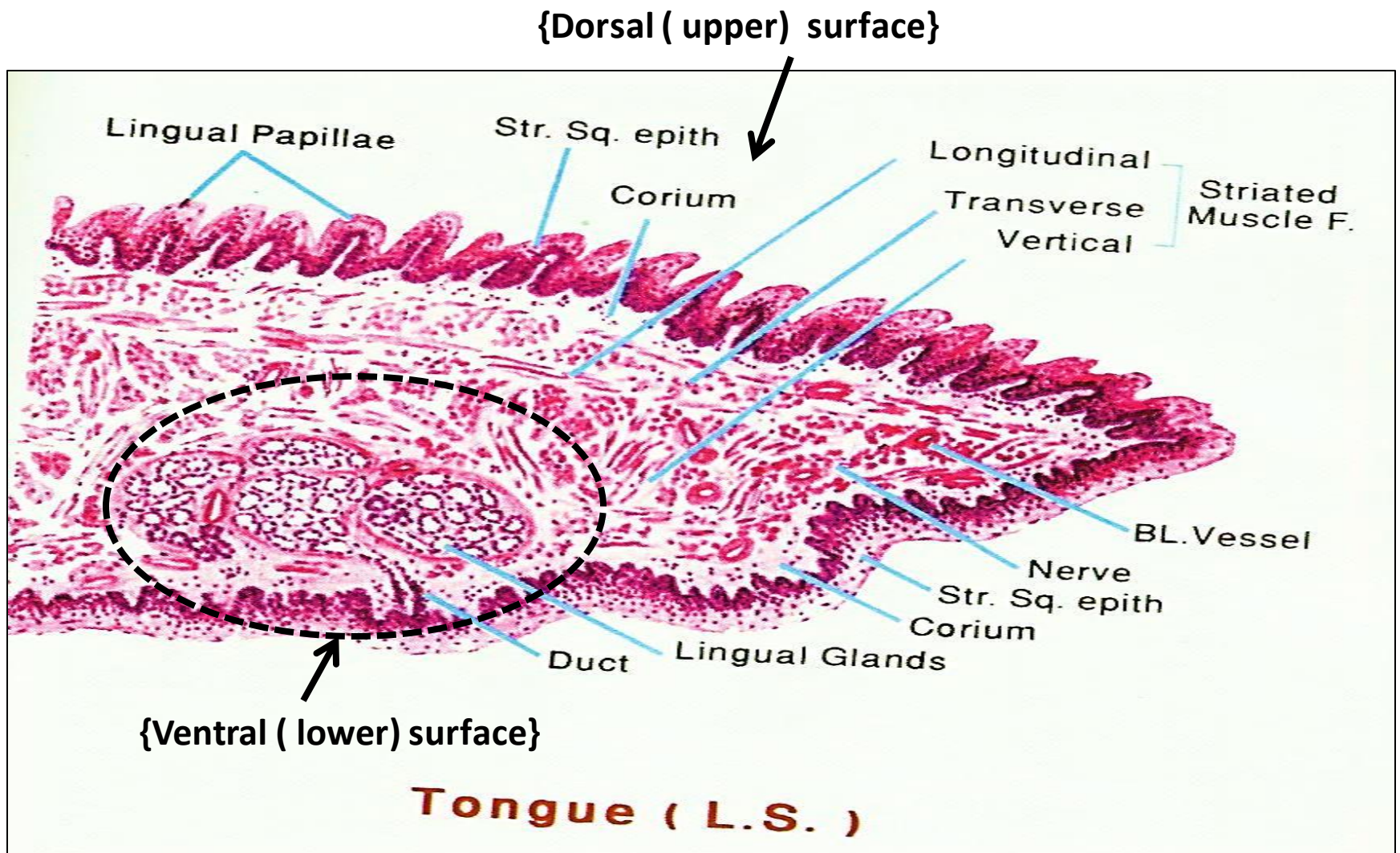
Sulcus terminalis: V- shaped groove on the dorsal surface of tongue

- It divides the tongue into:
  - body (oral): ant. 2/3
  - base (pharyngeal): post. 1/3

*2- The ventral surface* of tongue is covered e m.m. loosely attached to underlying C.T. e NO papillae & is covered with non- keratinized stratified squamous epithelium

- Lingual glands: are embedded in C.T. of ventral portion

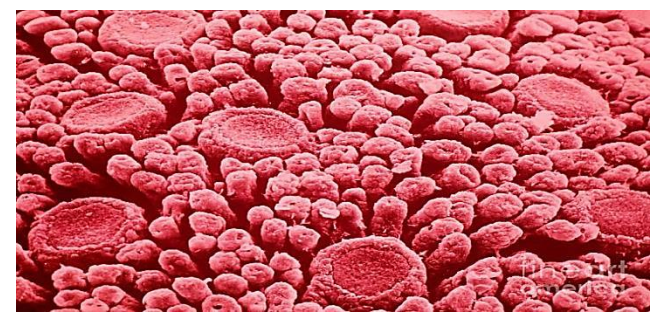




## Structure of the tongue

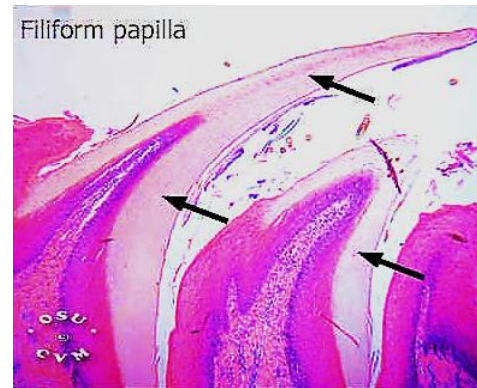
# Lingual papillae:

- Little projections of the m.m. of the dorsal surface of the tongue
- Each is formed of central core of C.T. covered with **stratified squamous epithelium**

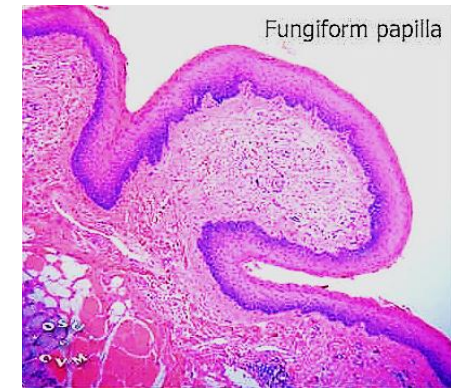

- There are 4 Types:

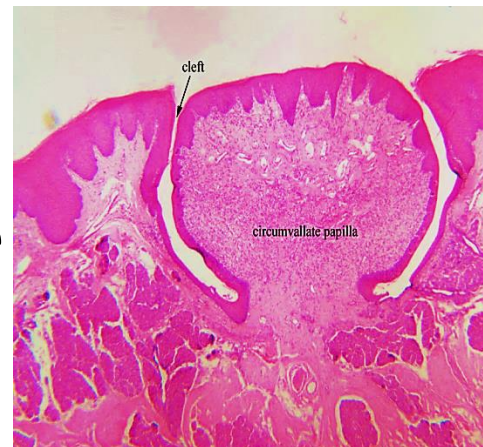1. Filiform papillae



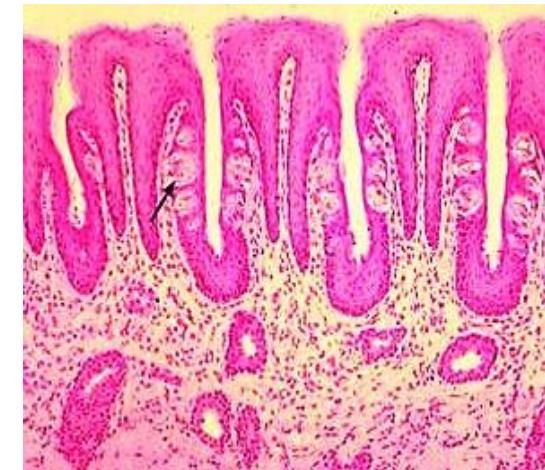2. Fungiform papillae



3. Circumvallate papillae

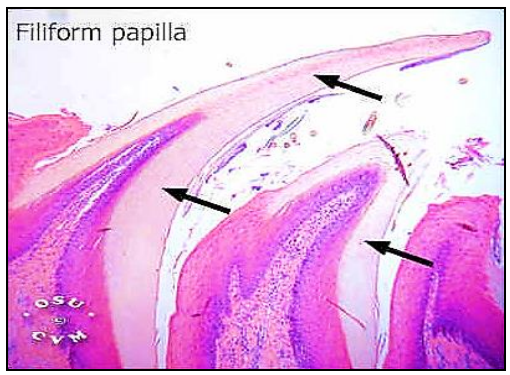


4. Foliate Papillae



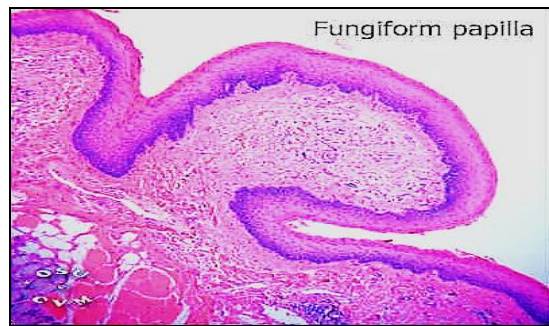
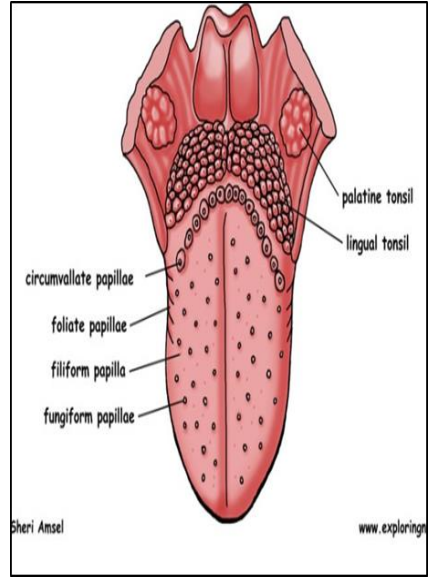
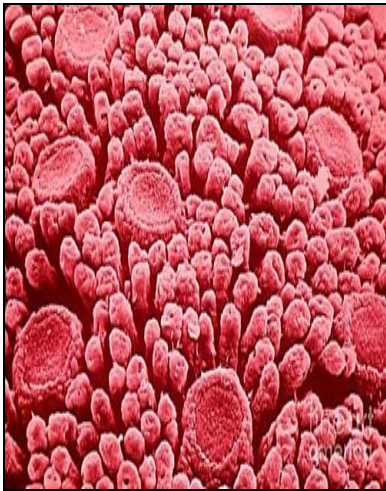○ Filiform papillae:

- Conical shape, contain NO taste buds
- Formed of C.T. core covered e keratinized stratified squ. epithelium
- Numerous in number found on ant. 2/3 of tongue



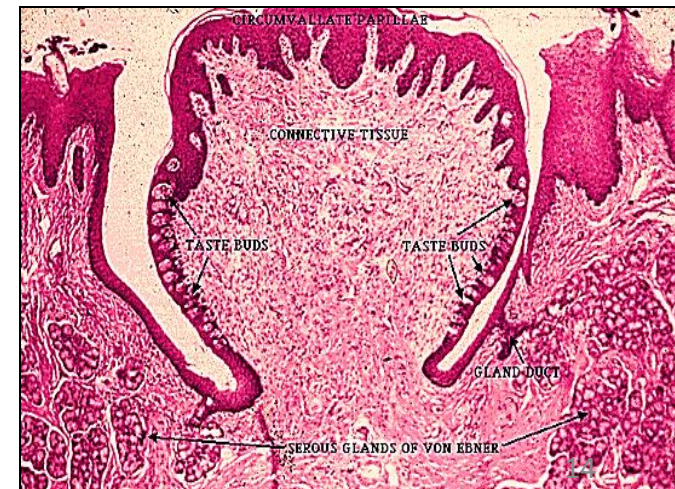
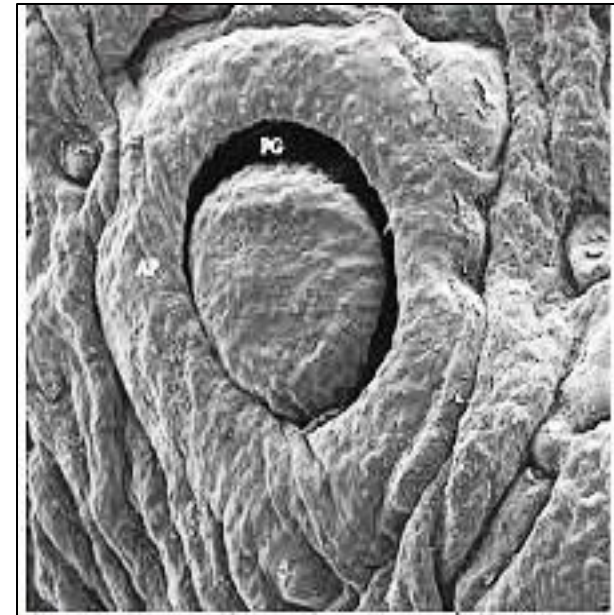
○ Fungiform papillae:

- Mushroom- shaped, very vascular found on ant 2/3 of tongue among Filiform papillae
- Their covering epith is Non- k.st.squ. red due to presence of many B.V. in underlying C.T.
- Contain taste buds on superior surface



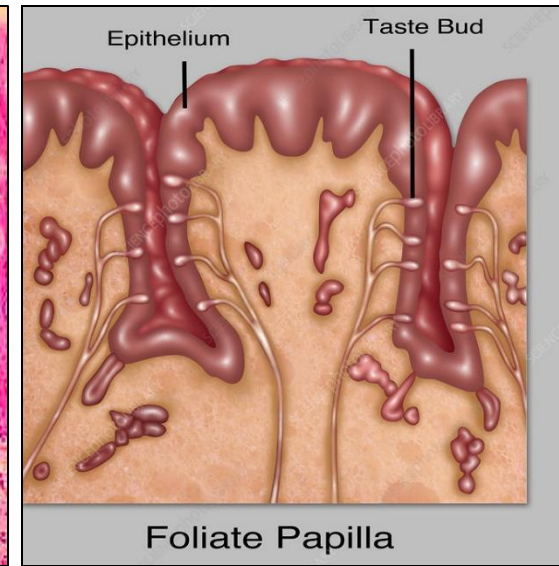
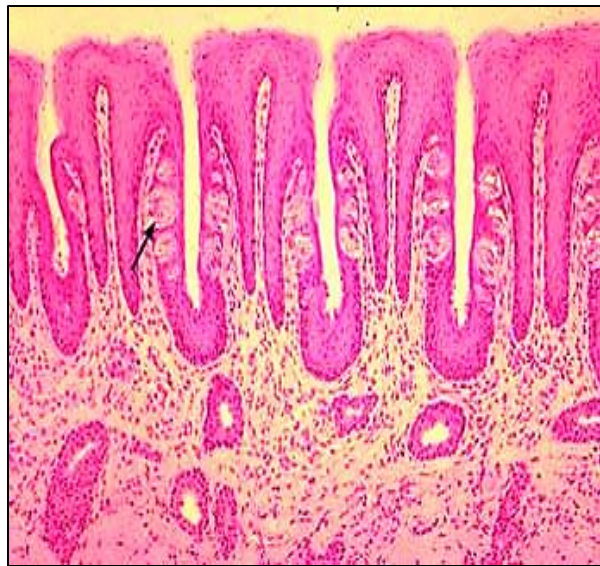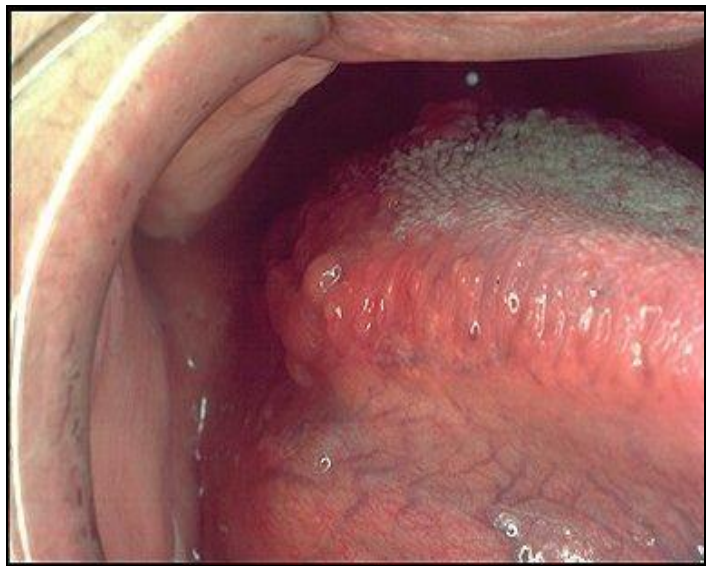
## ○ Circumvallate papillae:

- Largest, circular papillae, 10- 15 in # ,  
Found in front of the sulcus terminalis
- They don't project on the surface
- deep in their C.T.
- Each one is surrounded e groove ( trench = furrow)
- They contain Von Ebner glands (serous, begin lipid hydrolysis) in lamina propria
- They covered e Non- k.st.squ.epith
- Taste buds present on the lateral sides of these papillae



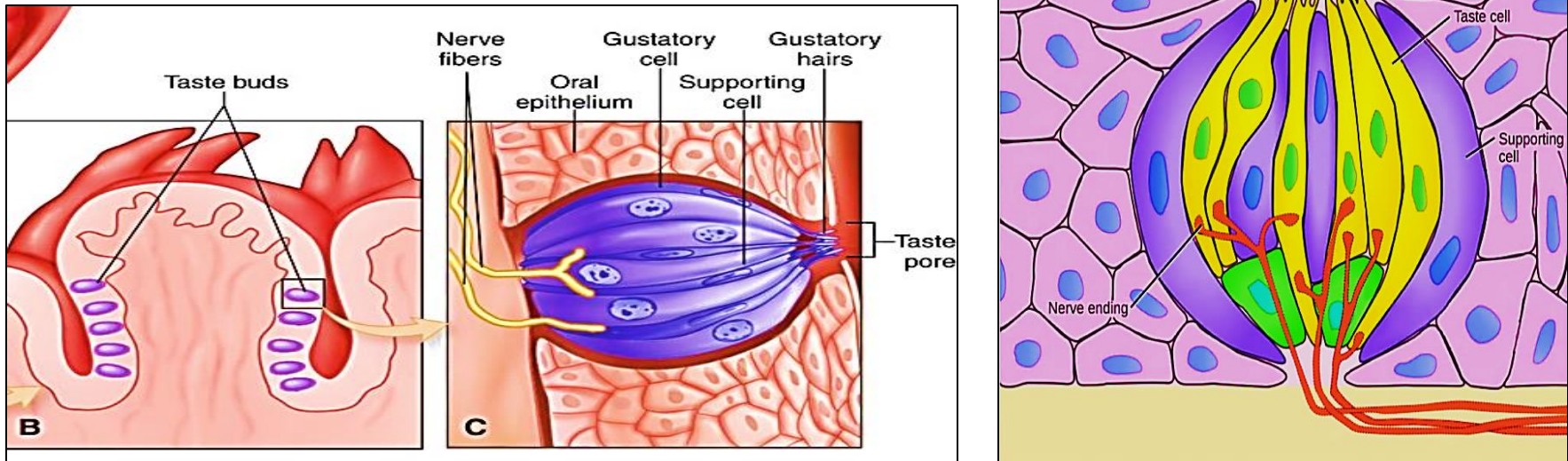
## ○ Foliate papillae:

- Formed of short vertical folds, found on sides of tongue
- covered e non- k. stratified squamous epithelium
- Each papillae is separated by groove and contains **many taste buds**
- This type is at high risk for oral cancer



# Taste buds (Neuroepithelium)

- Oval structures present on dorsal surface of tongue, in the lingual papillae (2000 – 8000)



- Each taste bud formed of **3 types of cells & taste pore** for passage of saliva:

- 1- **Sensory (taste, gustatory) cells: 50- 100 cells / bud**
- 2- **Supporting cells**
- 3- **Basal cells (stem cells)**



- Neuro-epithelial (taste, chemoreceptors) cells:
  - Tall columnar cells, central in position, 3 types I, II, III
  - Their apical surface terminate e fine filaments called gustatory hairlets which project into the gustatory pore
  - The base of the cells has vesicles that contain neurotransmitter & synapse with afferent nerve fibers

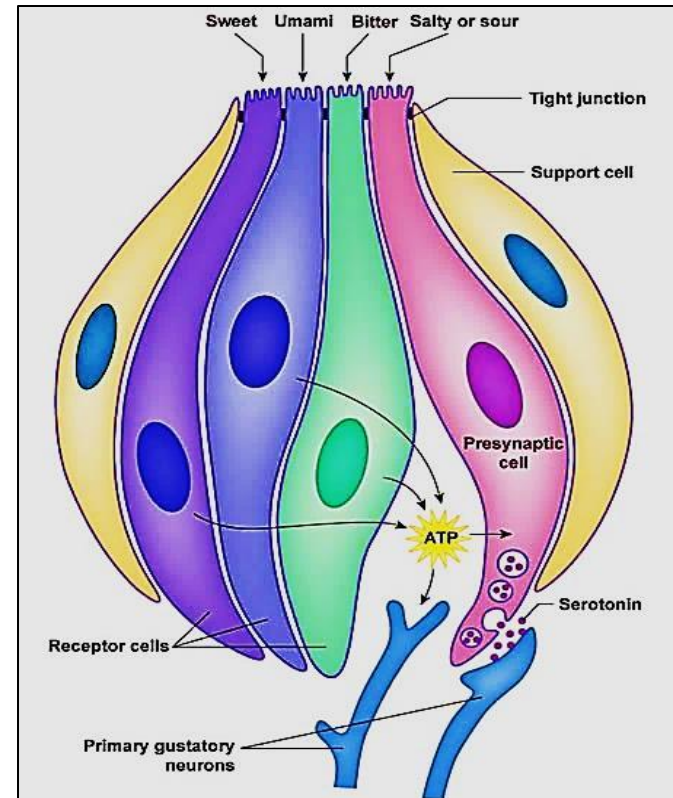
- The supporting cells

Tall columnar cells form the outer wall of the taste buds

- Basal cells:

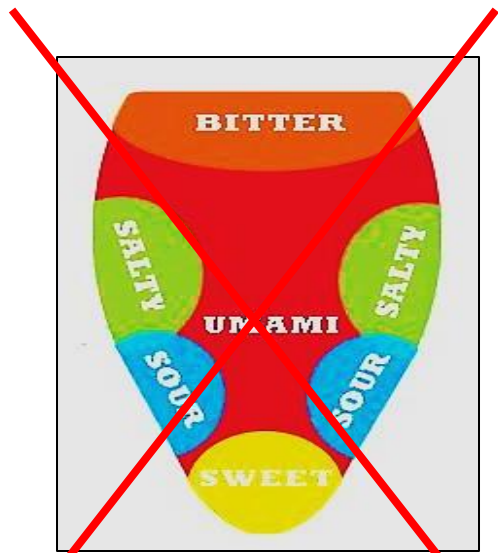
found at the base of taste bud act as a stem cells for regeneration

**The average life of a taste bud is 10 days**



The sensation of taste can be categorized into five basic tastes: **sweet, sour, salt, bitter, and umami.**

Each taste bud contains a variety of chemoreceptors that recognize all tastants then send signals to the brain that recognize the different tastants.



**Misconception of Tongue map**

### What is Umami?

- Umai – “delicious”
- Described as savory, brothy rich or meaty taste sensation.
- High level of glutamate
- It's a satisfying taste with distinctive qualities of aroma and mouthfeel.

A photograph of several mushrooms, some whole and some sliced, illustrating the source of umami taste.

- **is spicy a taste ?**
- Spiciness is not a taste



- **The spicy taste is a combination of hot and pain sensations**
- **The active ingredient in chilli peppers (spicy food) is called Capsaicin**
- This substance binds to receptor on the tongue called **vanilloid receptors** .. these receptors detect **pain and heat** and send signals to the brain... the brain send signals to numb the tongue
- Sometimes you may notice after you have eaten a lot of spicy food that the spiciness doesn't affect you as much because the receptor stop responding .. the phenomena is called **Capsaicin desensitization** .. **Spicy food does not damage the taste buds**
- Eating spicy food read by the body as a pain sensation your pituitary gland to release endorphins which make us enjoy eating spicy food

## Coated tongue

White tongue can happen when debris builds upon it. This will lead to delay shedding of and continual renewal of keratinized area on the dorsal surface of the tongue which cause accumulation of bacteria and inflammation

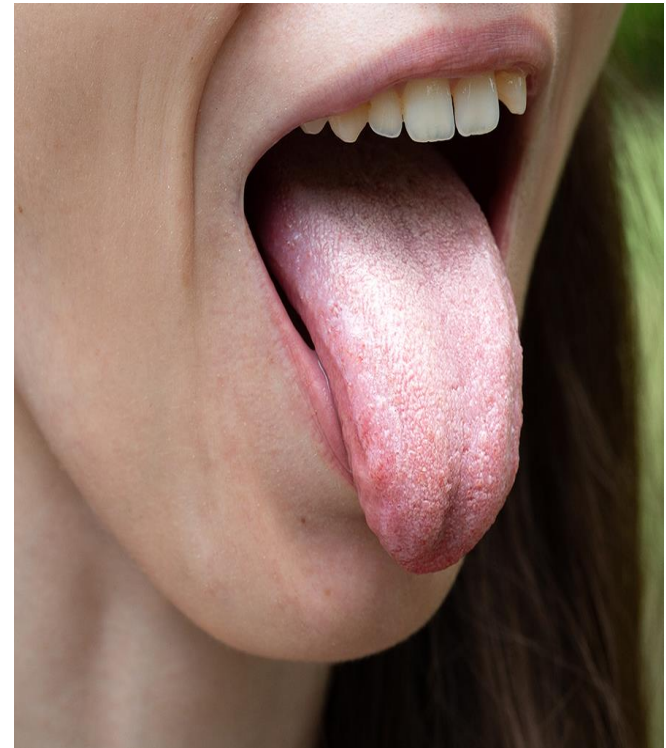
### Causes:

Bad oral hygiene

Dehydration, mouth breathing

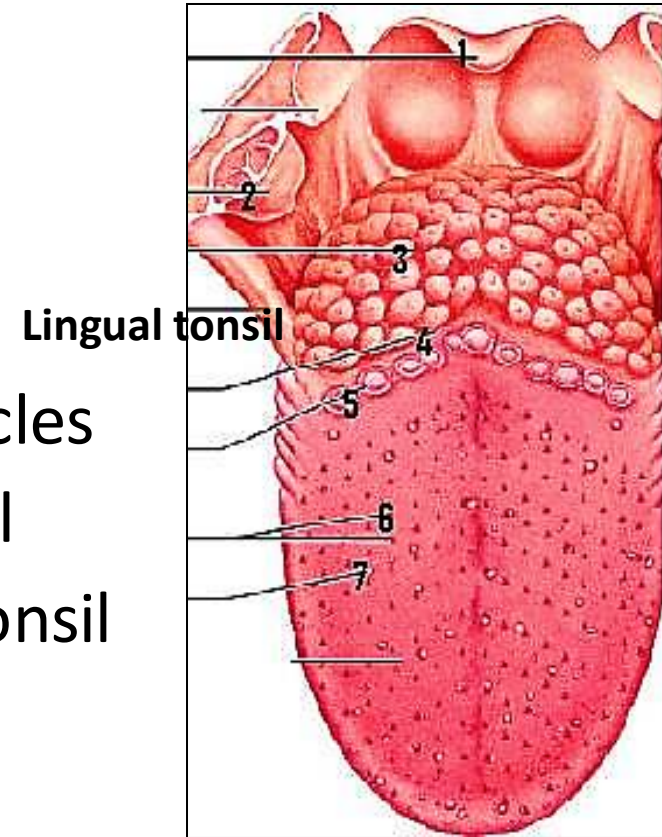
Tobacco smoking, drink alcohol

Oral candidiasis



## Lingual tonsil:

- The post 1/3 of tongue has No tongue papillae
- Covered with non-keratinized stratified squamous epithelial that invaginate inward forming crypts
- Is formed of groups of lymphoid follicles
- Mucous glands drain through several ducts into the crypts of the lingual tonsil which clean and wash off any debris
- Assist the immune system in the production of antibodies to fight invading bacteria or viruses



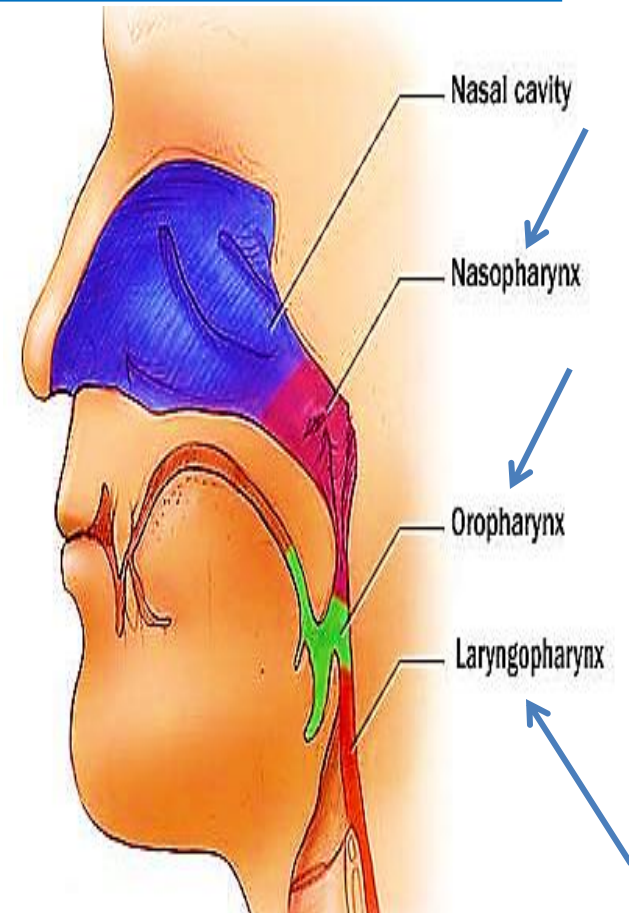
# Pharynx:

- Divided into 3 parts:

1- Nasopharynx: lined e pseudo- stratified columnar ciliated epith.

2- Oropharynx : lined e non- keratinized Stratified squamous epith.

3- Laryngo-pharynx: as oropharynx



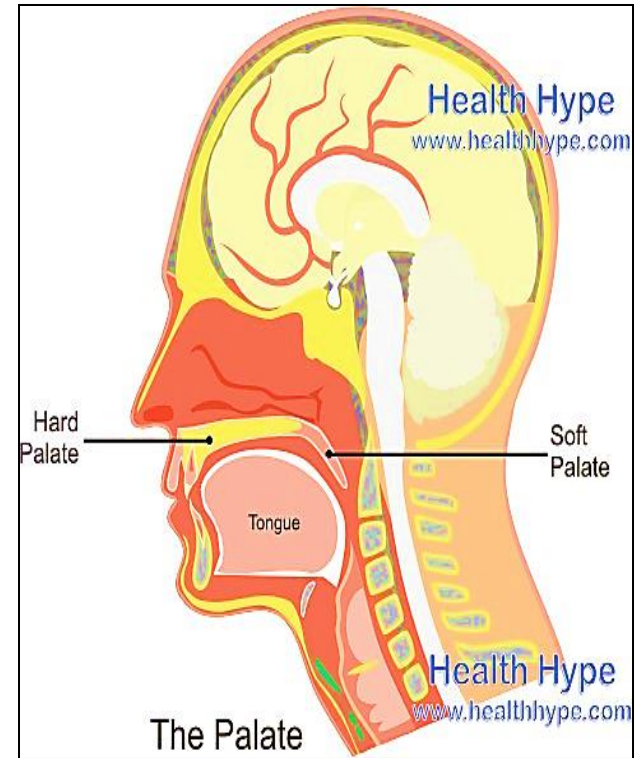
# The palate:

The roof of the oral cavity composed of:

- Ant part → hard palate
- Post part → soft palate

## Hard palate:

- Formed of bone lined e **keratinized stratified squamous epith.**



## Soft palate:

- Covered e **non – keratinized stratified squamous epith**

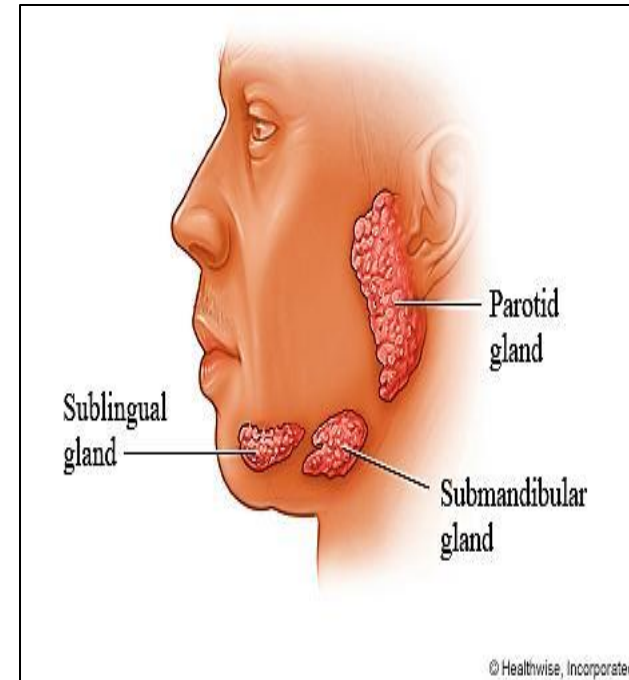
# The salivary glands

## Types of salivary gland:

- A. The main = large = extrinsic
- B. The accessory = small = Intrinsic

## A- The main salivary glands

- 2 Parotid glands in front of both ears
- 2 Submandibular gland: lie against the inner aspect of the mandible
- 2 Sublingual glands: lie below the tongue in the mucous membrane of the floor of the mouth





## B- Accessory salivary gland

➤ **Small, microscopic glands** scattered in the C.T. of the oral mucous membrane:

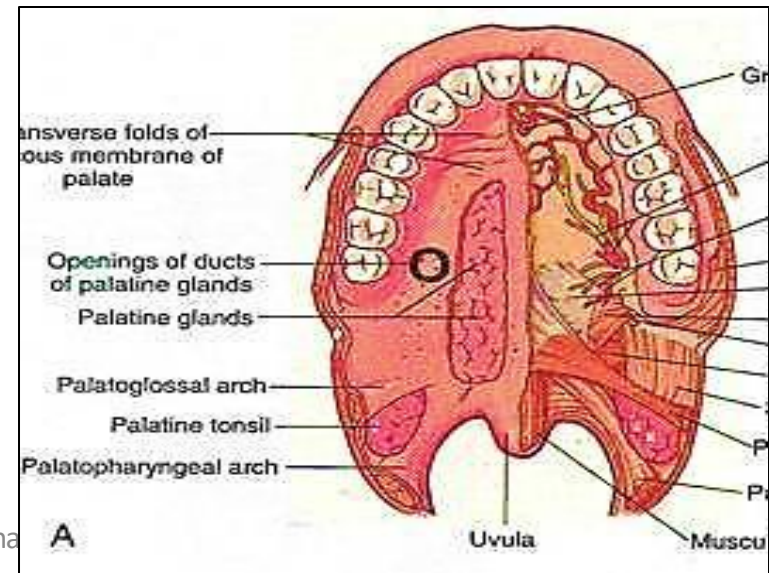
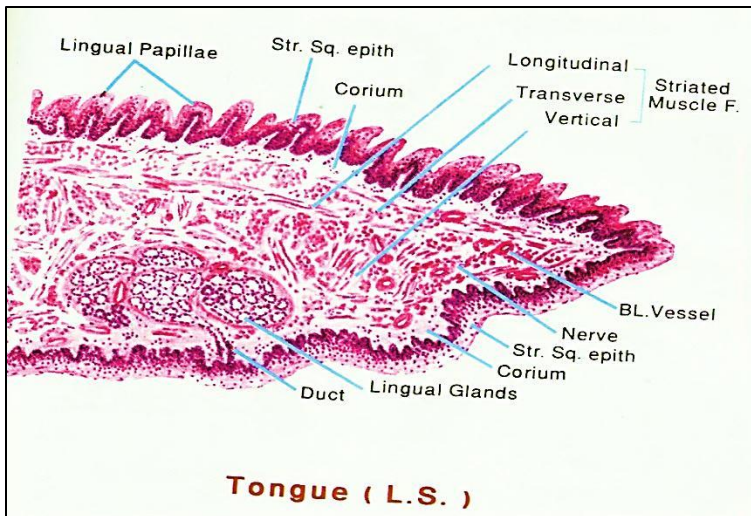
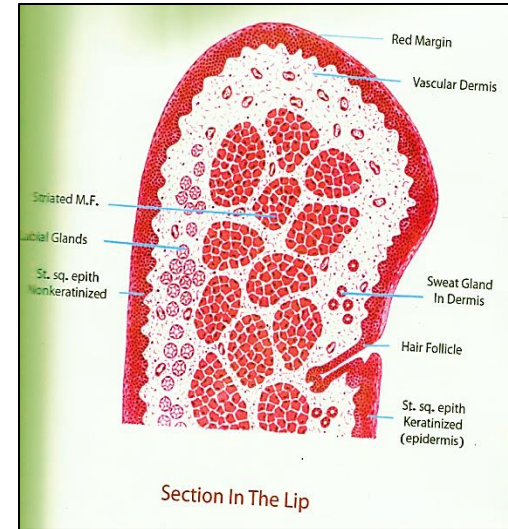
I. The lips → labial glands

II. Tongue → lingual glands

III. The palate → palatine glands

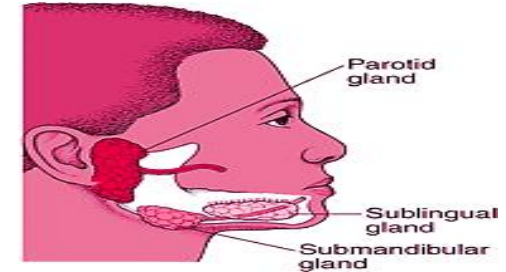
➤ They secrete saliva **(10%) constant rate**

➤ Their secretion is mainly mucous



# Salivary glands

- Exocrine glands, produce the saliva (90%) (pH 6.5 – 7.5)  
(99.5% :water & 0.5% : electrolytes, mucus, enzymes & Ab)



- Saliva has the following functions:

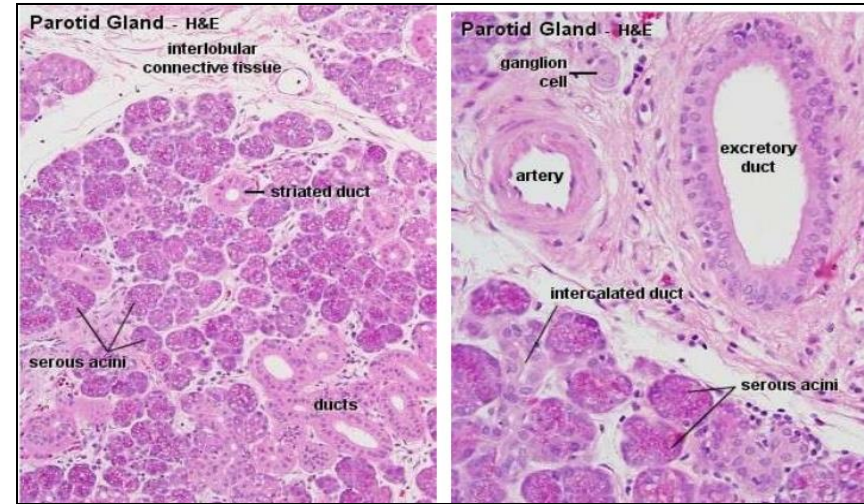
1. Lubricates & cleans the oral mucosa & the lips
2. Initiate digestion of carbohydrate & lipids (amylase & lipase)
3. Contains antimicrobial agents IgA, lysozyme, Lactoferrin that control the bacterial flora of the oral cavity
4. Act as solvent substance that stimulate taste buds
5. Assist in swallowing

# Structure of the salivary glands

## Stroma & Parenchyma

### A- Stroma

C.T. framework supports the gland and transmit the blood vessels ,nerves, lymphatics, & ducts



➤ It consists of:

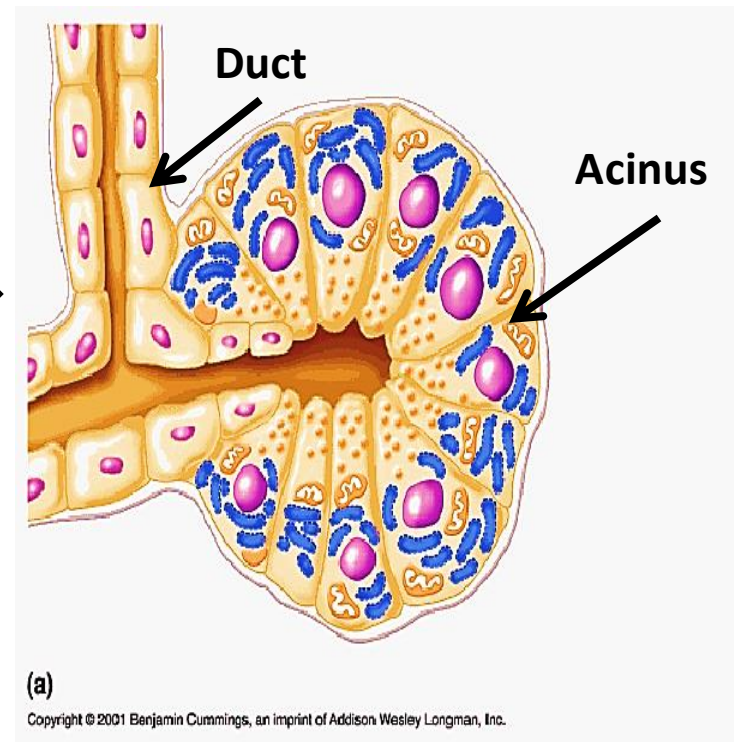
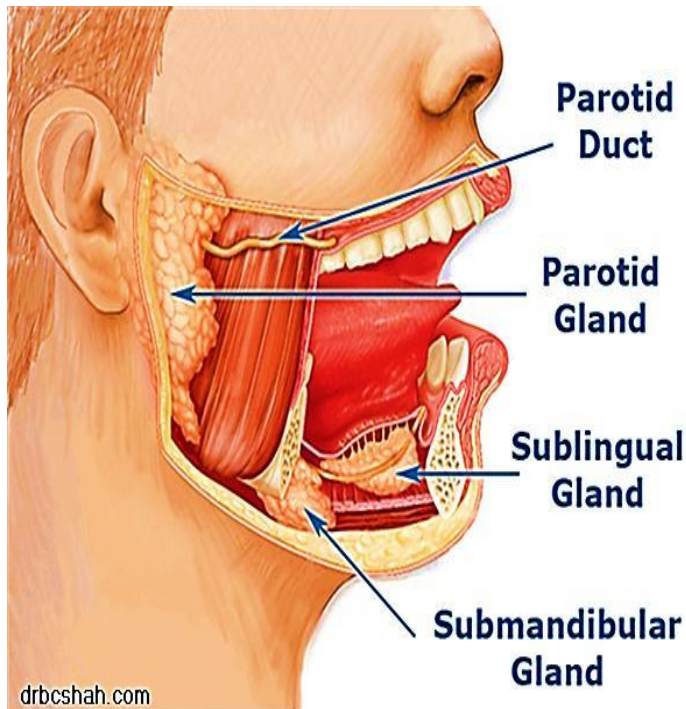
- **Capsule**: covers the gland from outside
- **Septa** : divide the glands into lobes & lobules
- **Reticular network**: present in the background of the gland (stained e Ag)

## B- Parenchyma

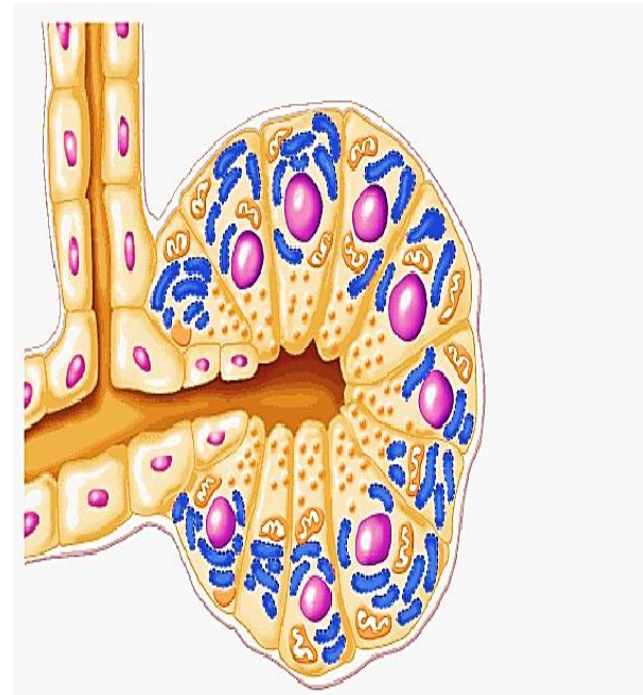
Includes:

**A- Secretory units** (salivary acini) → secrete saliva

**B- Duct system** → conduct saliva to the oral cavity

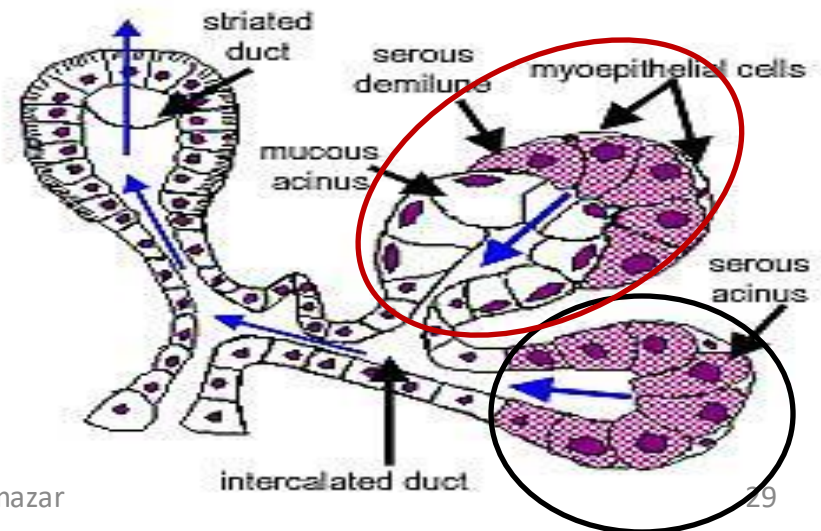


# A- Secretory acini



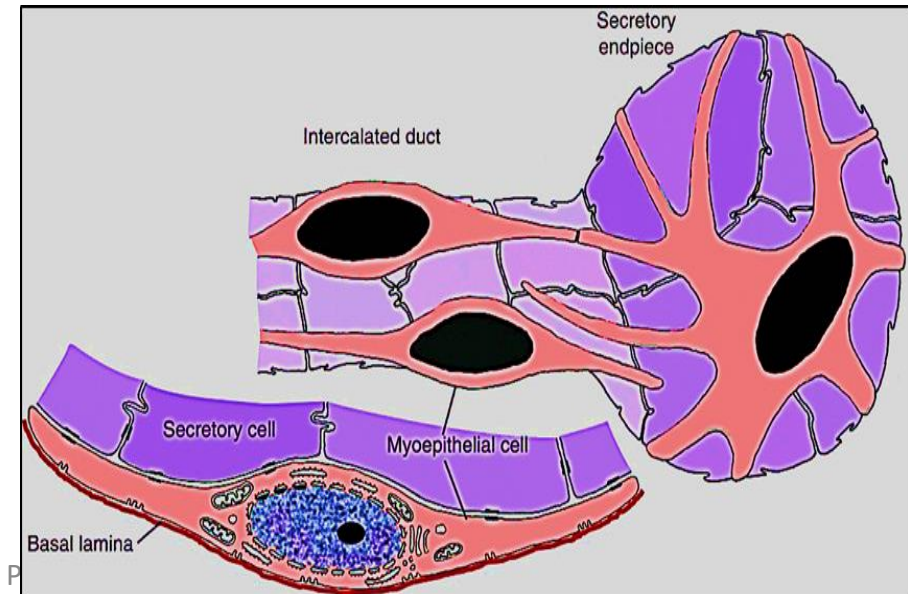
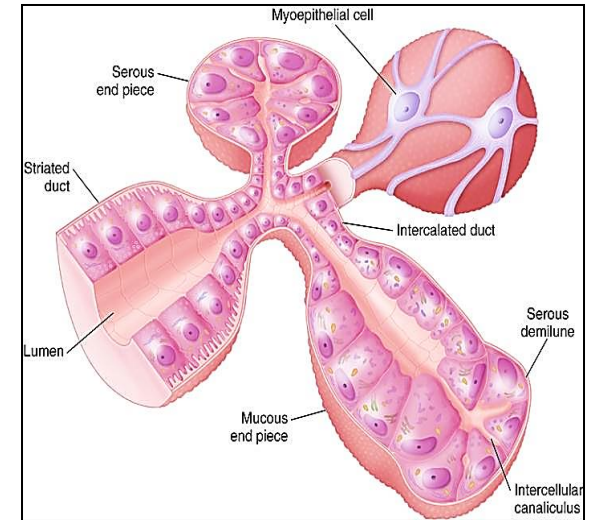
- Group of cells encircling a lumen
- 2 types of cells:
  - a- **Secretory cells** (serous or mucus)
  - b- **Non-secretory cells** (Myoepithelia)

- According to the type of secretion the acini divide into:
  1. serous
  2. mucous
  3. mixed (muco-serous)

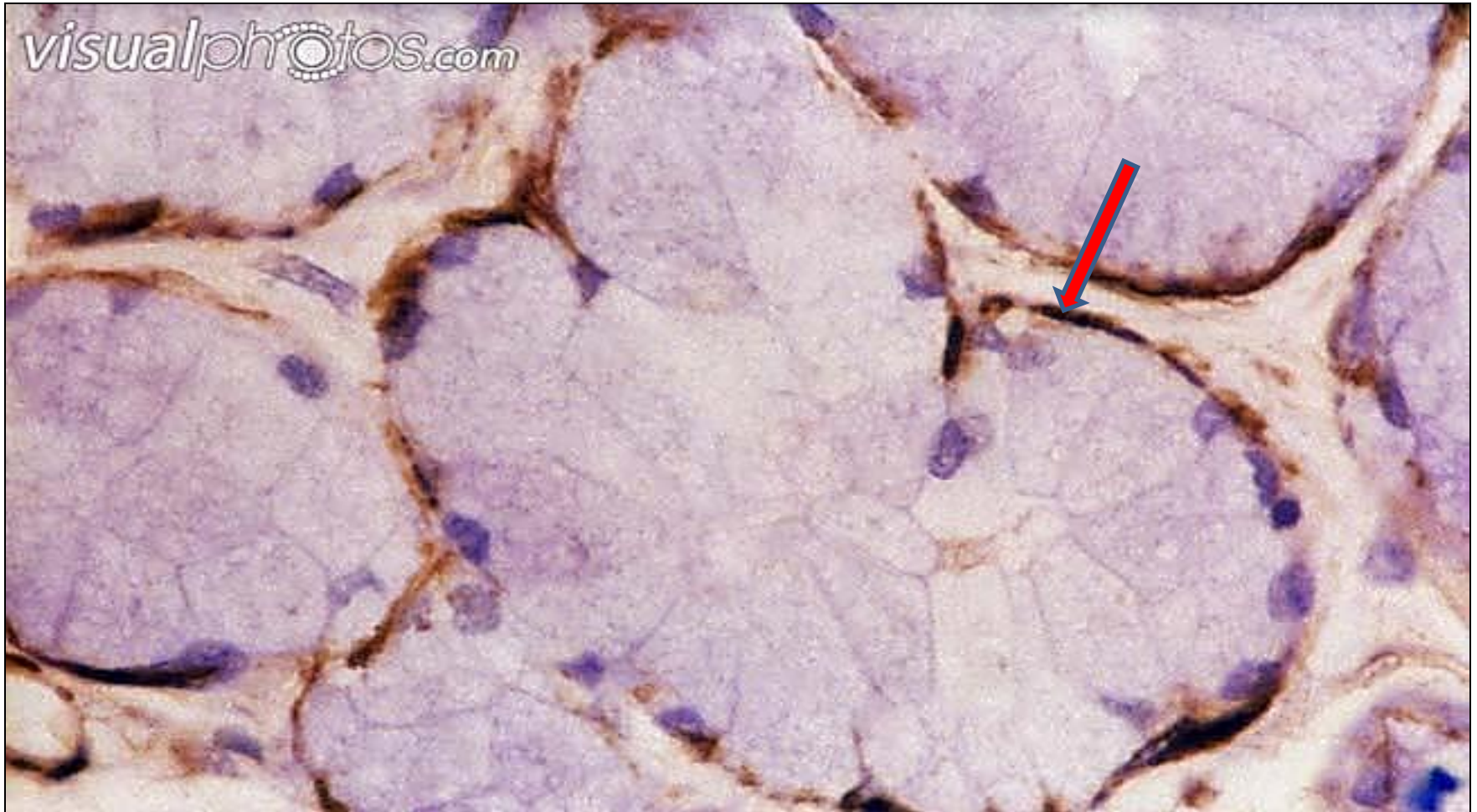

## Myoepithelial cells (Basket cells)

- Star-shaped cells present between the base of the secretory cells & their basement membrane \*\*
- They are branched cells, their cytoplasm contain actin & myosin filaments
- When contract → release secretion



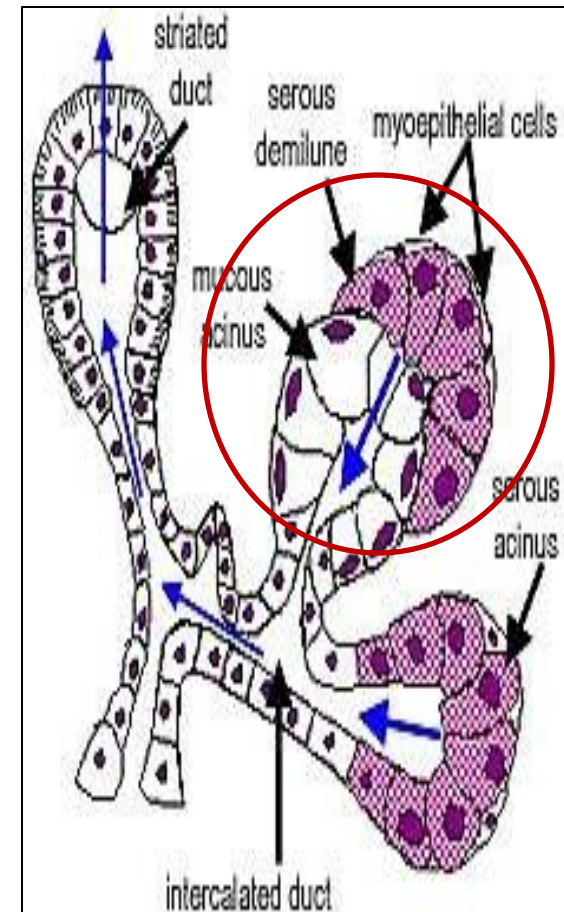
# Myoepithelial cells of salivary glands



**Immunohistochemical staining for the myofibrils within the myoepithelial cells**

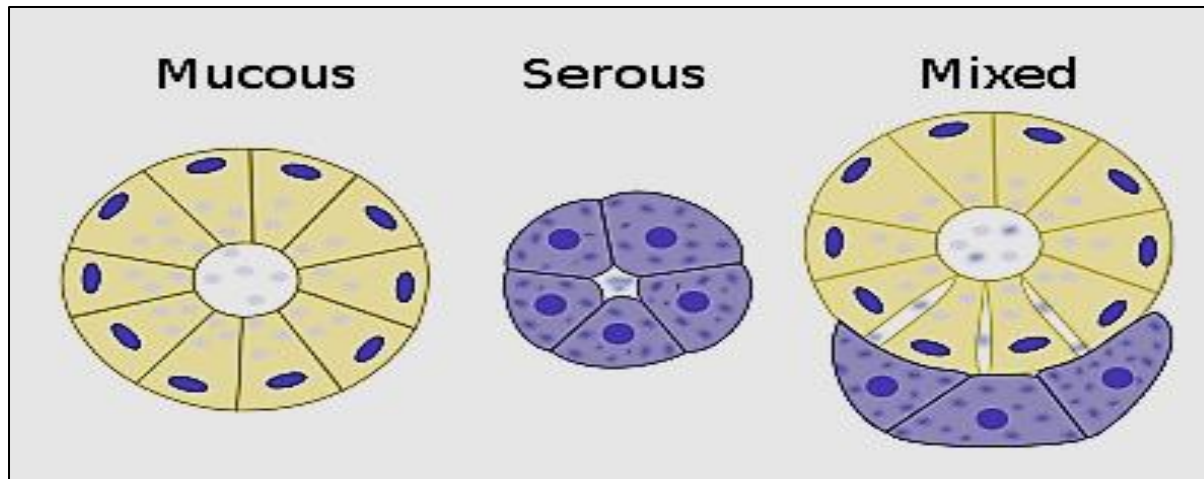
## Crescent of Gianuzzi (serous demilune):

- group of serous cells form a crescent at one side of a mucous acinus.
- The serous secretion of these cells reach the lumen of the acinus by passing through **intercellular canaliculi**
- Demilune cells secrete the proteins that contain the lysozyme & enzymes → add antimicrobial activity to mucus.





# Serous vs. Mucous acinus



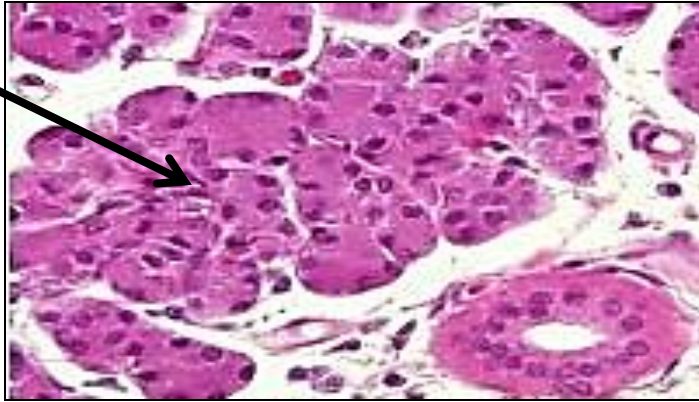
## Serous (Parotid)

- Small diameter
- Narrow lumen
- Lined e short pyramidal cells
- Nuclei are rounded & central

## Mucous (Sublingual)

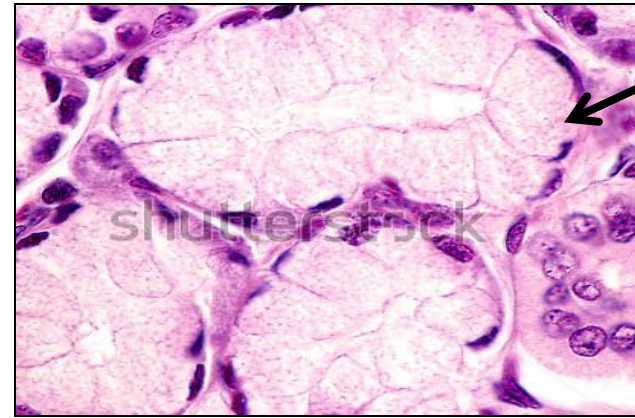- Larger in diameter
- Wide lumen
- Lined with tall cells
- Nuclei are flat & peripheral

Serous



Serous

Mucous



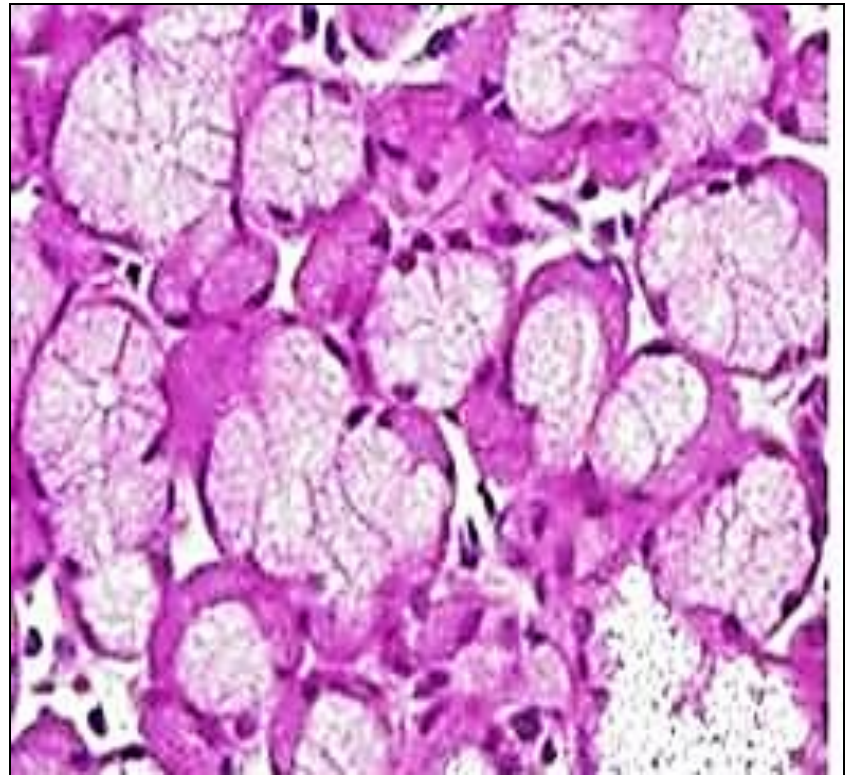
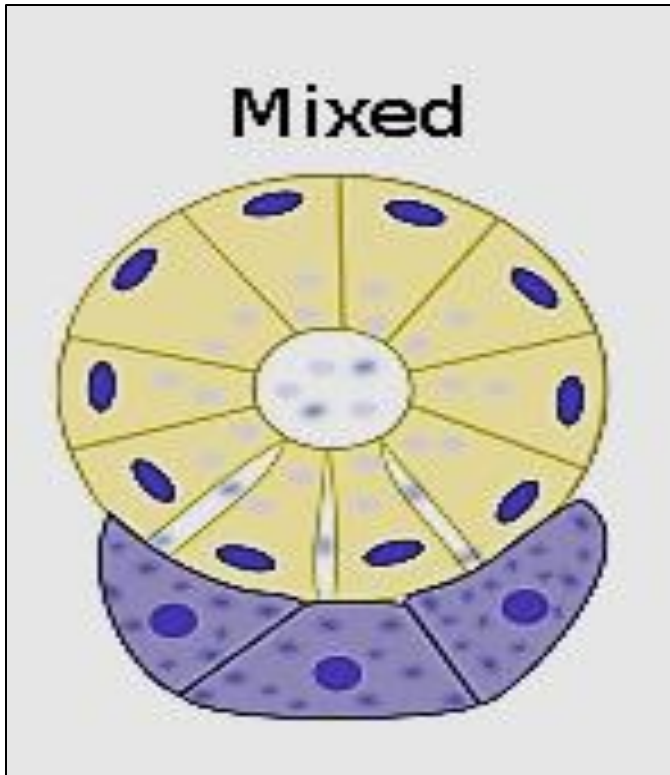
Mucous

- Basal cytoplasm is basophilic (↑ in rER )
- Basket cells are less
- Secrete fluid **serous**
- Secrete amylase aid in digestion of starch

- Cytoplasm is pale, foamy & vacuolated (dissolved mucus)
- Basket cell are more
- Secrete viscid **mucous**
- Secrete mucous for lubrication

## Mixed (muco-serous) acinus

Is essentially a mucous acinus which is capped by a group of serous cells forming → Crescent of Gianuzzi (serous demilune)



## B- the duct system ( branching system)

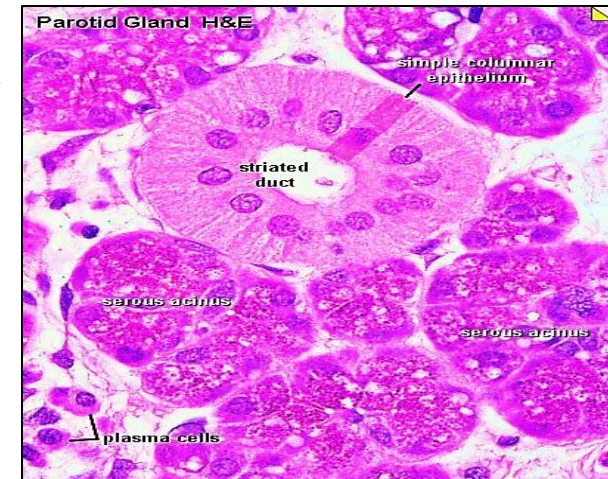
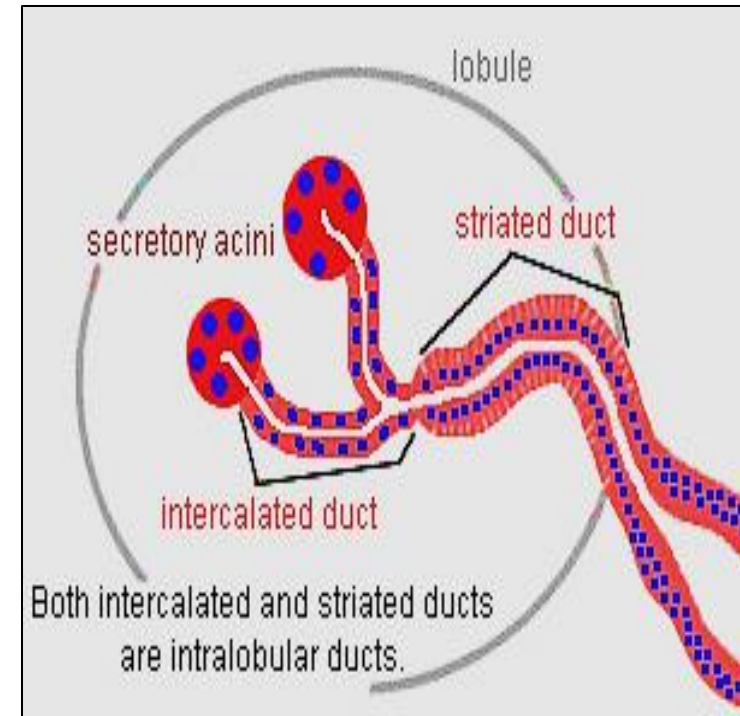
- **Intercalated ducts:**

thin ducts ,  
drain the secretory unit, lined  
with flat or cuboidal cells.

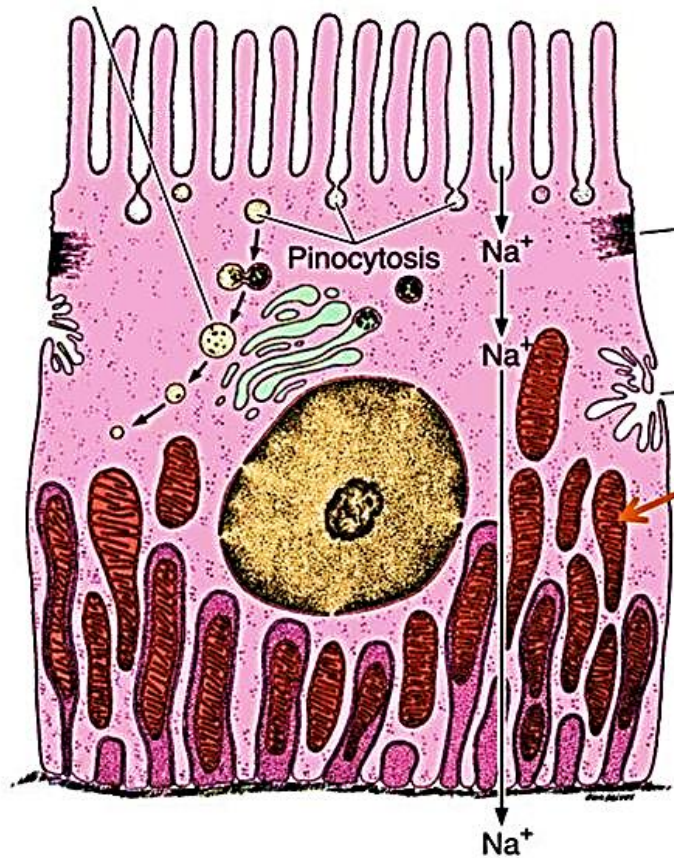
- **Striated (secretory) ducts:**

1. present inside the lobule
2. *take part in the secretion of saliva*
3. lined with low columnar cells
4. Their apical and basolateral membranes contain ion channels to transport ions as  $\text{Na}^+$ , &  $\text{K}^+$  (ion transporting cells)

Has acidophilic cytoplasm e basal acidophilic striations  
(infolded basal lamina e  $\uparrow$  mitochondria )  
**(Ion transporting cell)**



## Ion-transporting cells



- Deep invaginations of basal cell membranes
- Zonula occludens
- Mitochondria in basal cytoplasm provide energy for ion transport
- Examples: proximal tubules in kidney

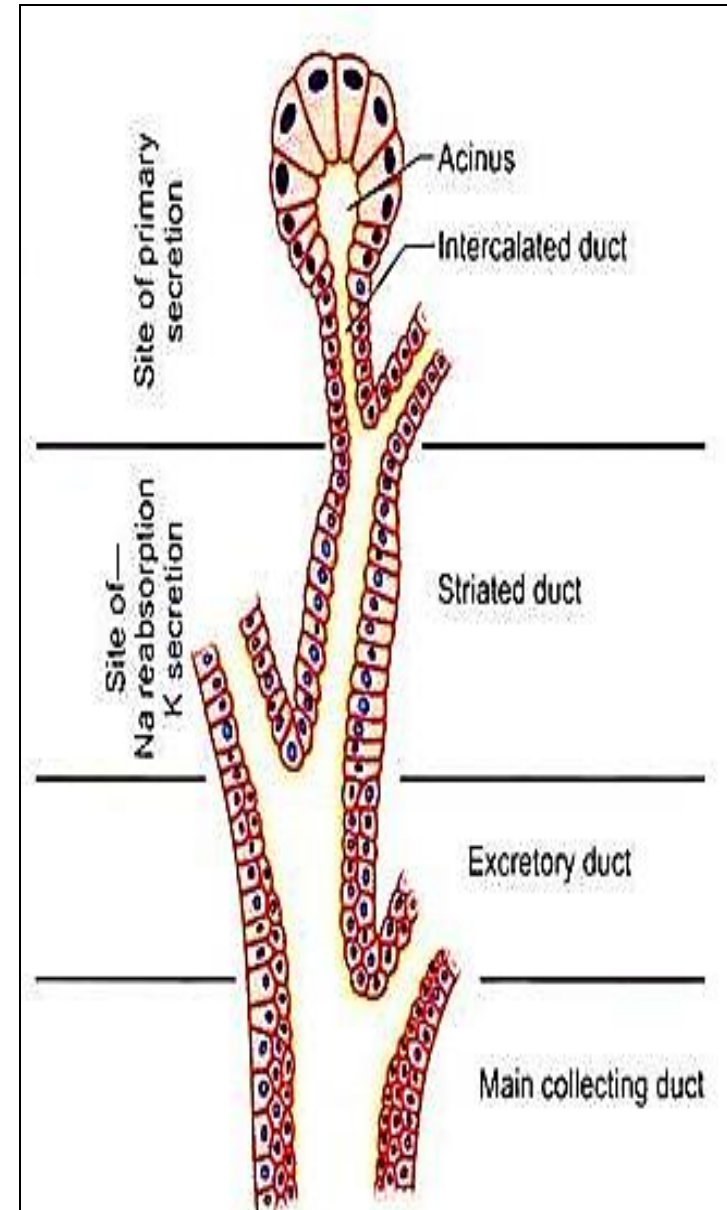
- **Inter-lobular ducts (excretory)**: in the septa between lobules lined e columnar cells → drain into



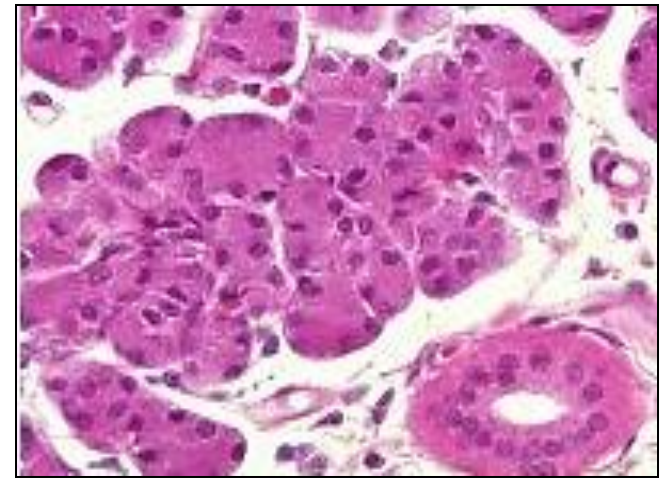
- **Inter-lobar ducts (excretory)**: in septa between lobes, lined e pseudo-stratified columnar epithelium →



- **the main duct**: drains secretion in oral cavity, lined 1<sup>st</sup> with stratified columnar → stratified squamous near its opening in mouth cavity



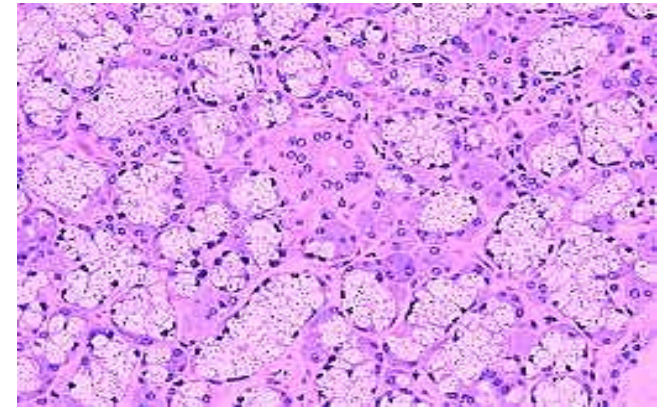
- Parotid gland: (100%)
- Acini: are **pure serous** Opens by parotid duct



- Sublingual gland: (95% + 5%)

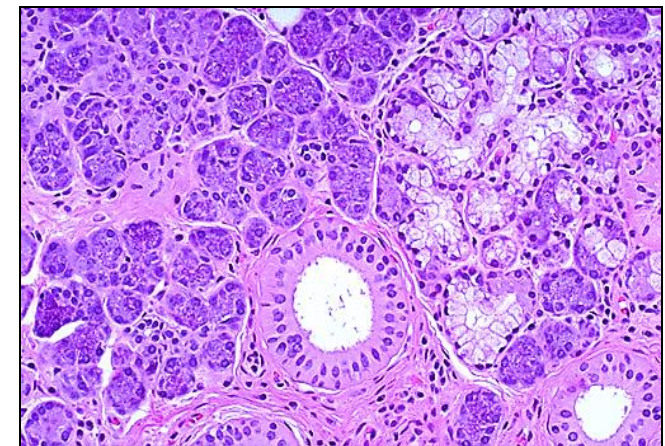
The smallest & the only unencapsulated

- Acini : mainly mucous cells capped with serous demilunes (**mixed**)
- Opens by 10-12 mini ducts



- Submandibular gland: (80% + 20%)

- Acini: **mixed serous & mucous acini**
- Opens by Wharton's duct



# Thank you

