

وسهلا

أهلا

يُمنع أخذ السلايدات بدون
إذن المحرر واي اجراء
يخالف ذلك يقع تحت
طائلة المسؤولية القانونية



الأستاذ الدكتور يوسف حسين

أستاذ التشريح وعلم الأجنة - كلية الطب - جامعة الزقازيق - مصر

رئيس قسم التشريح و الأنسجة و الأجنة - كلية الطب - جامعة مؤتة - الأردن

دكتورة من جامعة كولونيا المانيا

جروب الفيس د. يوسف حسين (استاذ التشريح)

Prof. Dr. Youssef Hussein Anatomy - YouTube

اليوتيوب د. يوسف حسين

<https://www.youtube.com/@ProfDrYoussefHusseinAnatomy/playlists>

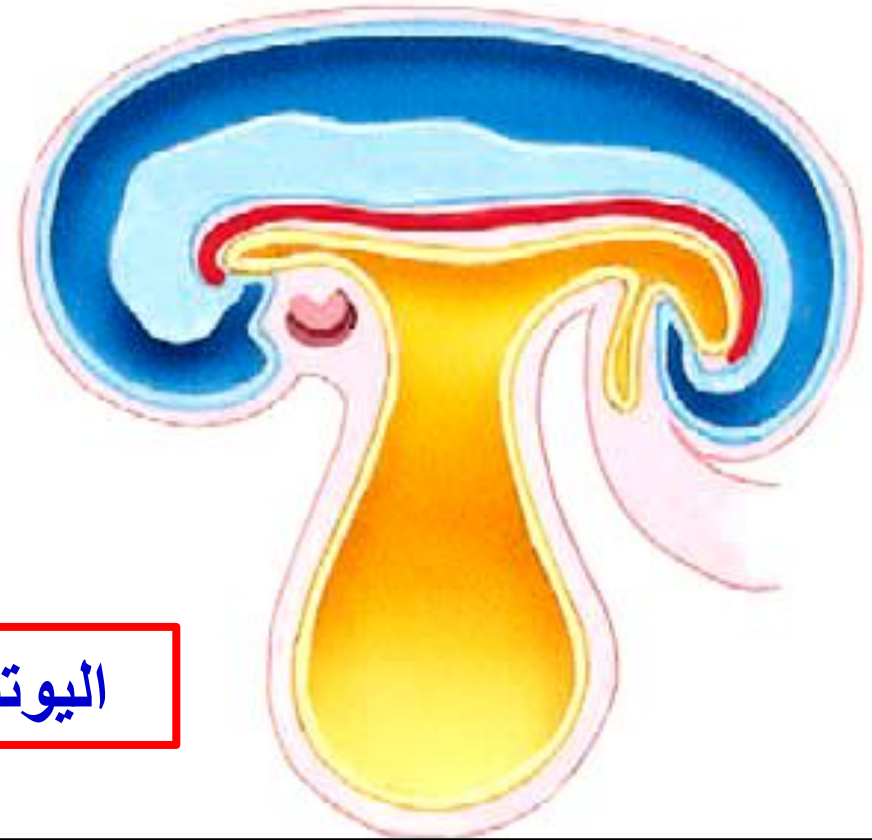

➤ Folding of Embryo

<https://www.youtube.com/@ProfDrYoussefHusseinAnatomy/playlists>

- **Folding of the embryo**
- **begins during 3rd week and completed at 4th week**

اليوتيوب د. يوسف حسين



**** Causes of folding:**

1. The most common cause is growth and development of the **somites**.
2. Rapid increase in the amount of **amniotic fluid** around the embryo.
3. Rapid growth of the cranial part of the **neural tube** than its caudal part.
4. Unequal rate of growth and development of the **internal organs**.

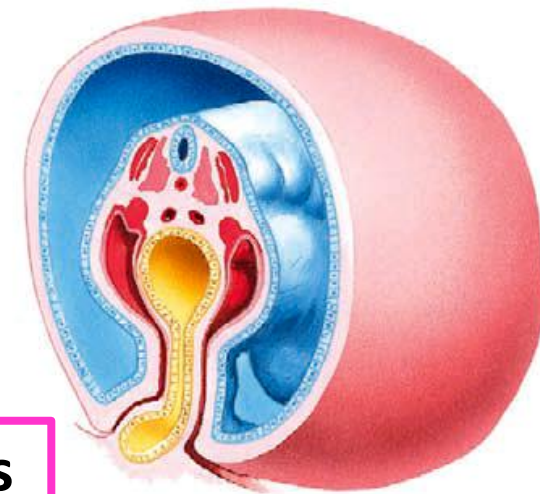
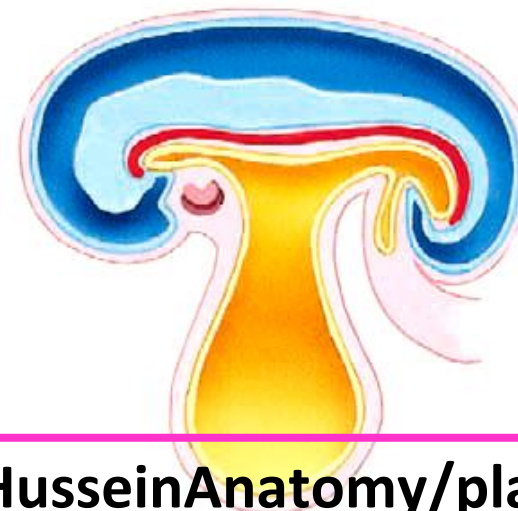Types of folding

Craniocaudal folding

- **Head fold**, cranial part of the embryo bends ventral to the cranial end of the notochord.
- **Tail fold**, caudal part of the embryo bends ventral to the caudal end of the notochord.

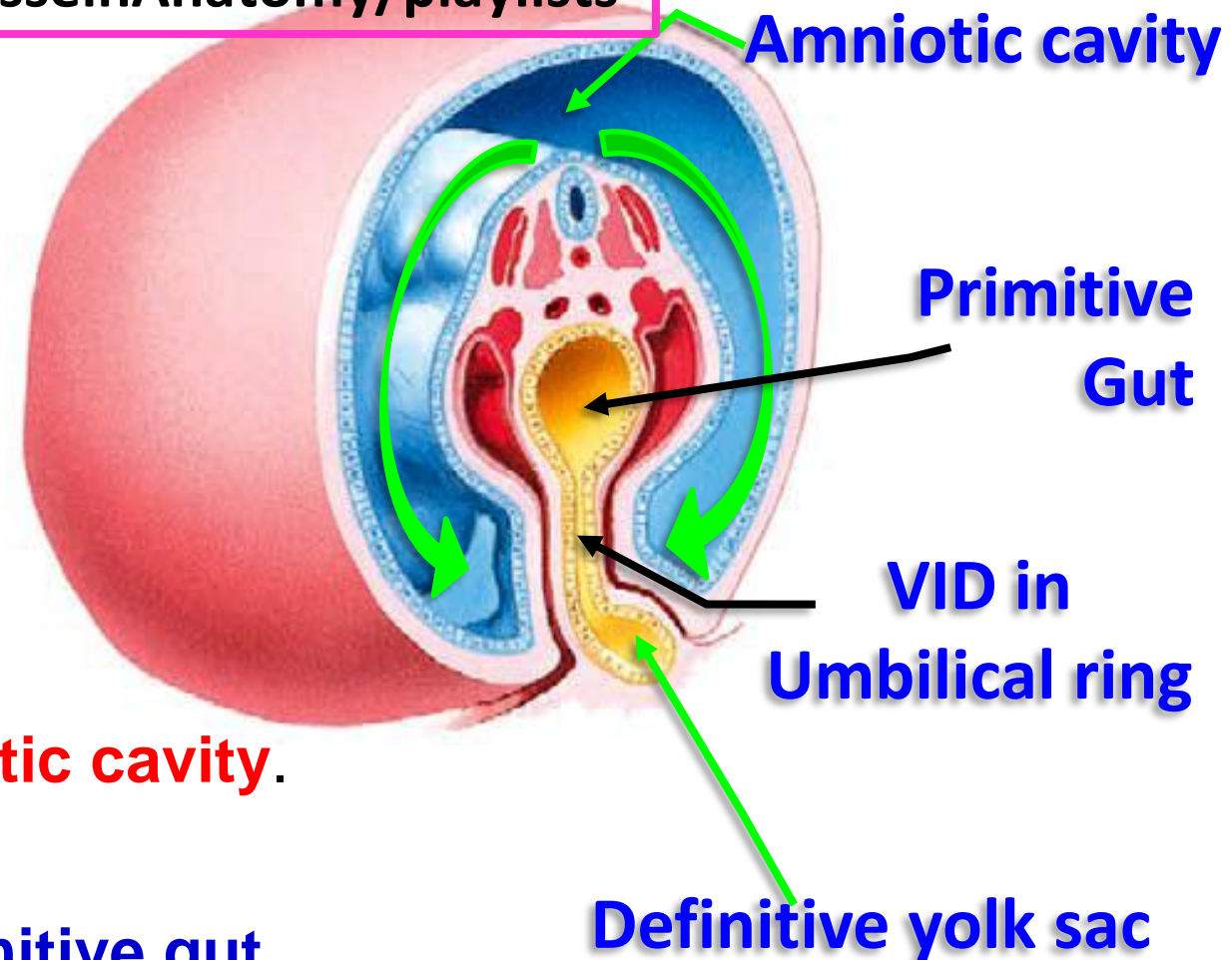
Lateral folding

- **Right and left Lateral folding**: The margins of the embryo bend ventrally.



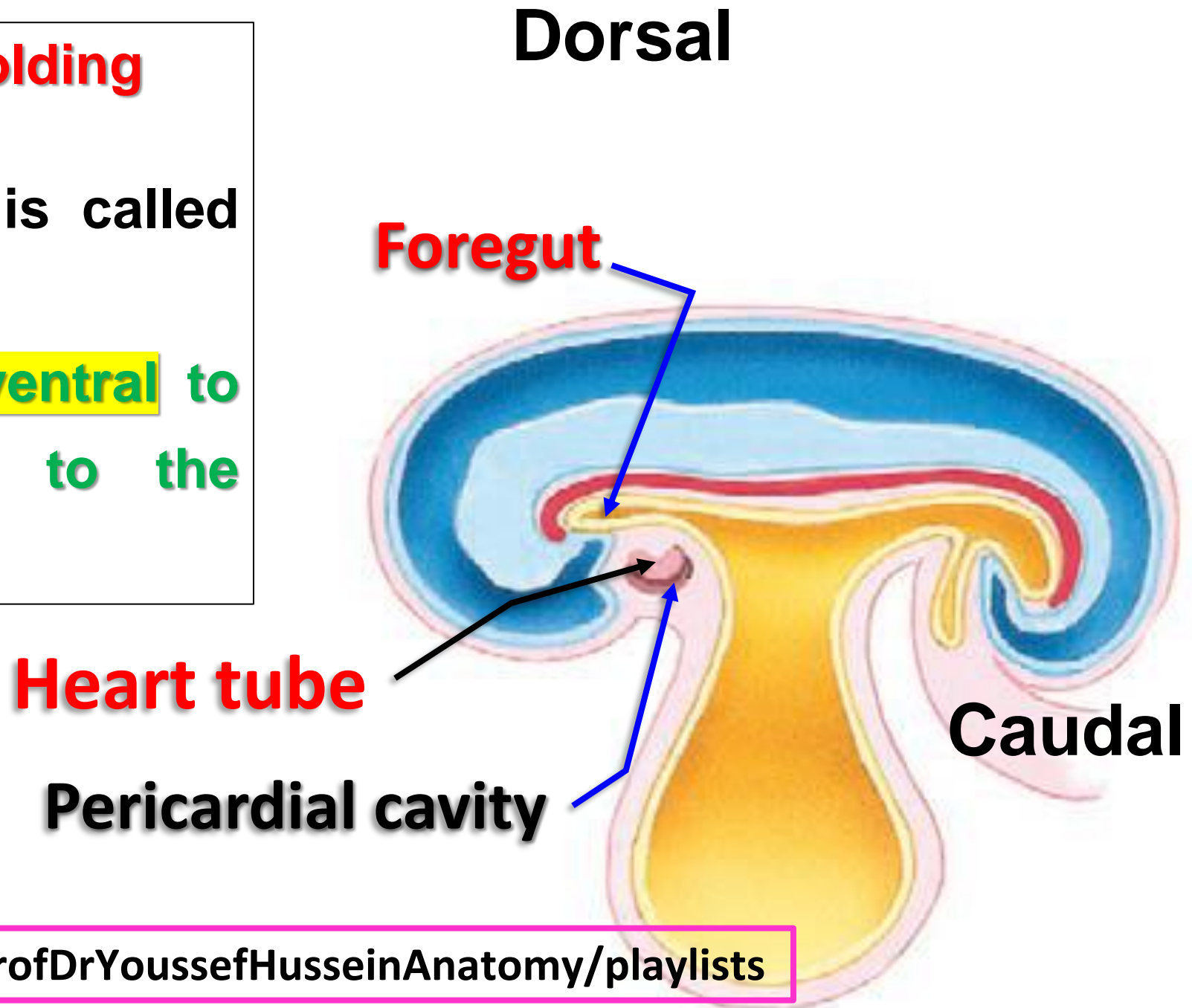
** Results of the folding

- The embryo becomes cylindrical in shape.
- The embryo is **surrounded by the amniotic cavity**.
- **The 2ry yolk sac** divides into:
 - a- Part inside the embryo forming the **primitive gut**.
 - b- Part remains outside the body called the **definitive yolk sac**.
- The 2 parts are connected at the **umbilical ring** by vitellointestinal duct (V.I.D).
- **The point of meeting** of the folds is the umbilical ring.



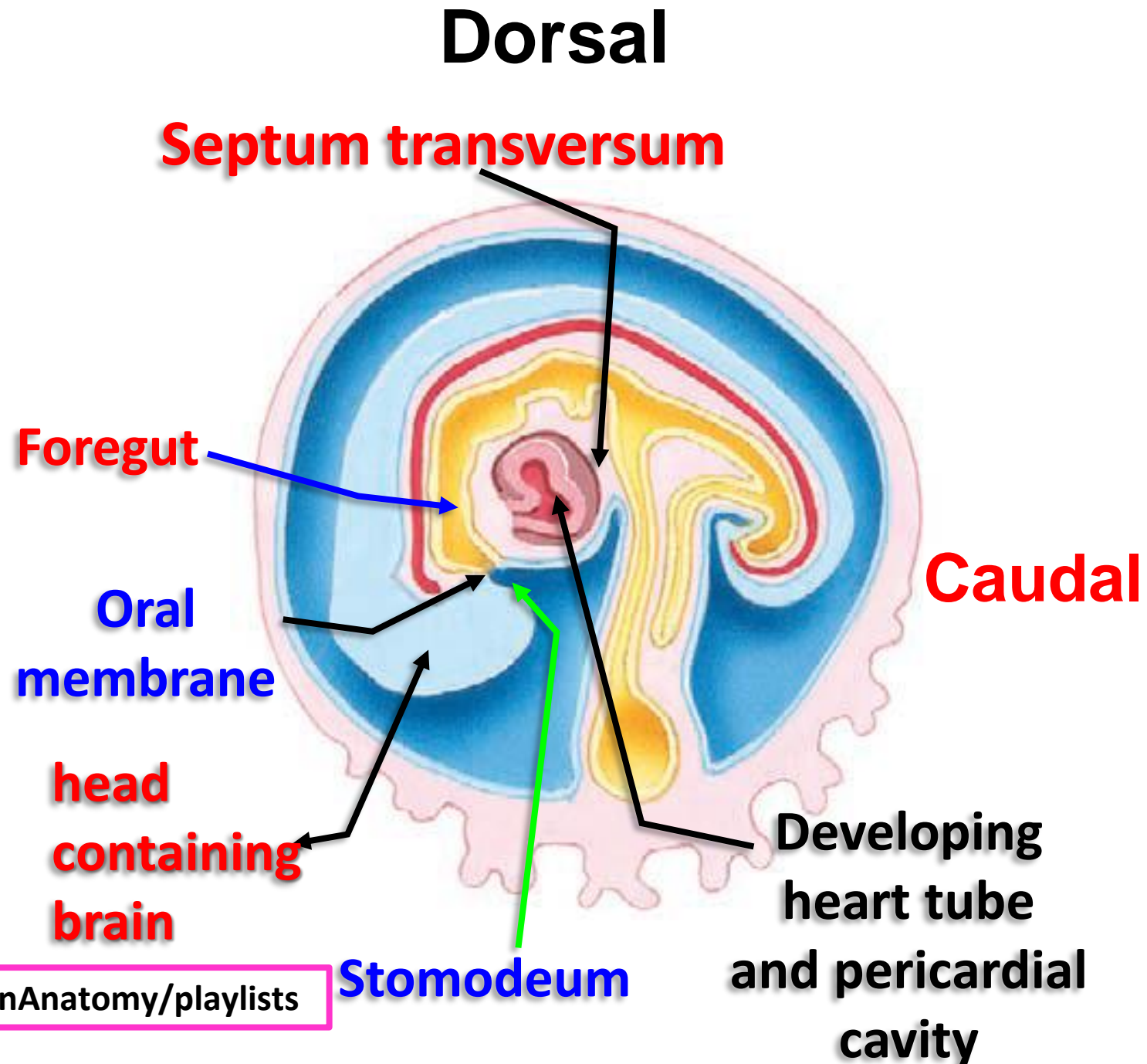
➤ Results of head Folding

- The part of the gut is called foregut
- The heart tube lies ventral to foregut and dorsal to the pericardial cavity



➤ Results of head Folding

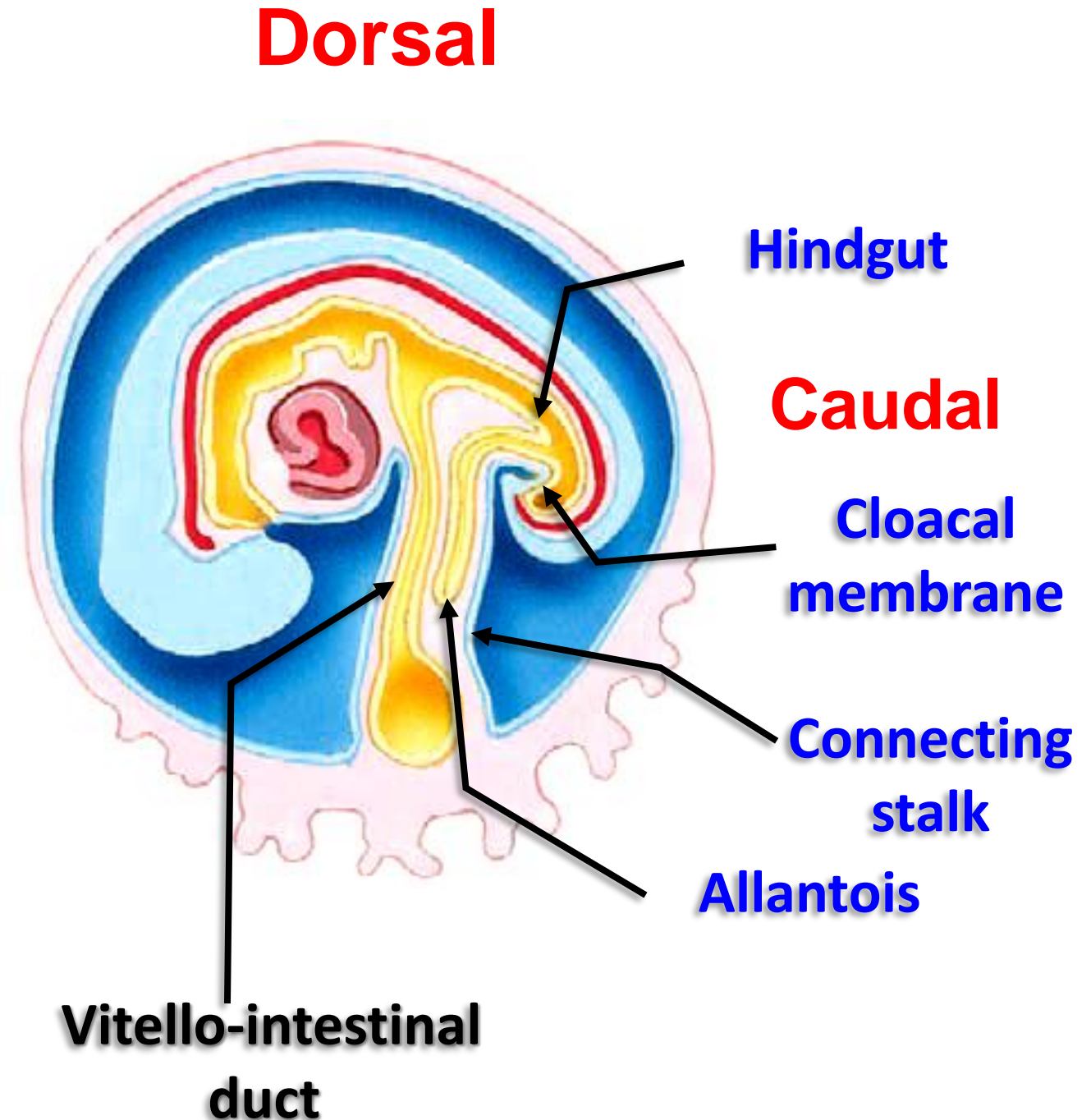
- The **septum transversum** lies **caudal** to the heart tube and pericardial cavity
- The **oral membrane** and **Stomodeum** (Primitive mouth cavity) **ventral** to the Heart tube & pericardial cavity
- The **head containing forebrain** become the most **ventral and cranial** part of the embryo.



➤ Results of tail Folding

- The part of the gut is called **hindgut** and its terminal dilated part called **Cloaca**
- The **cloacal membrane** ventral to caudal end of embryo and caudal to **allantois**
- The connecting stalk (**Future umbilical cord**) ventral to embryo and containing **allantois** (small diverticulum develops from caudal part of **hindgut**) and **vitellointestinal duct**

اليوثيوب د. يوسف حسين



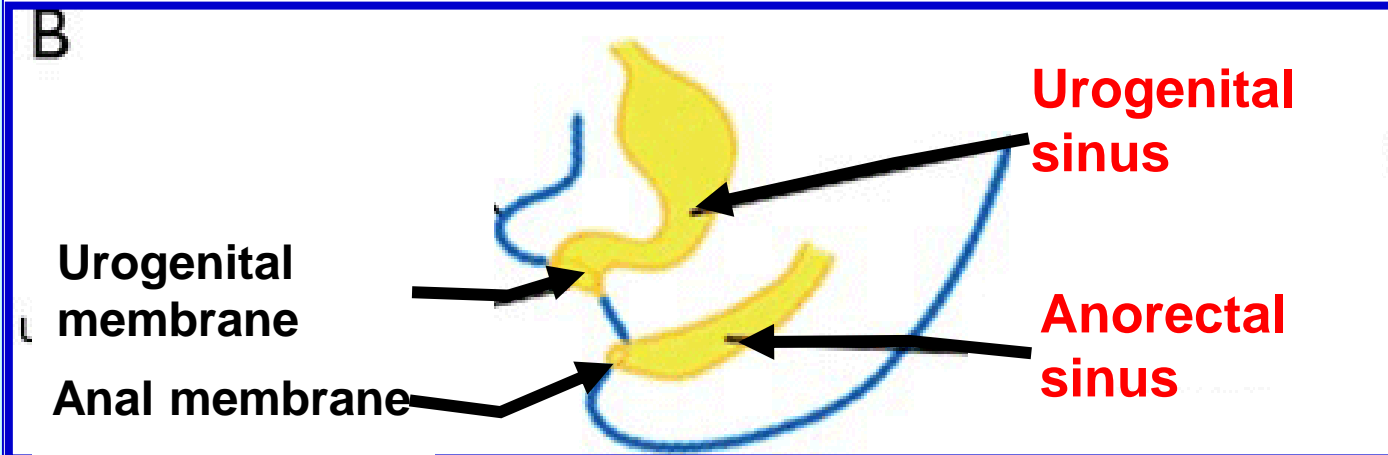
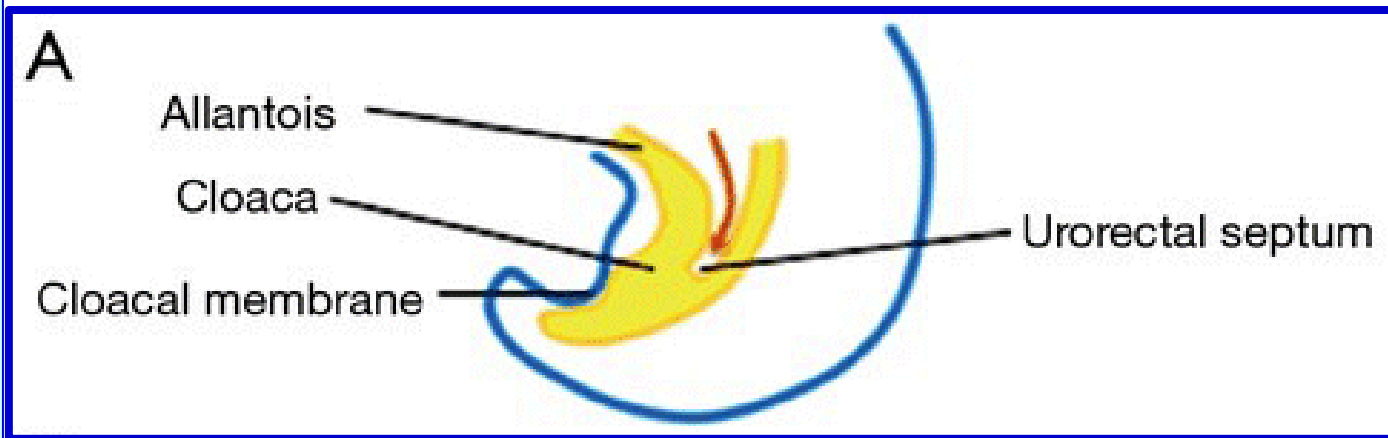
❖ Derivatives of cloaca

- The cloaca is the caudal dilated part of the **hindgut**, which is closed by the cloacal membrane and connected to umbilicus by **allantois (urachus)**.

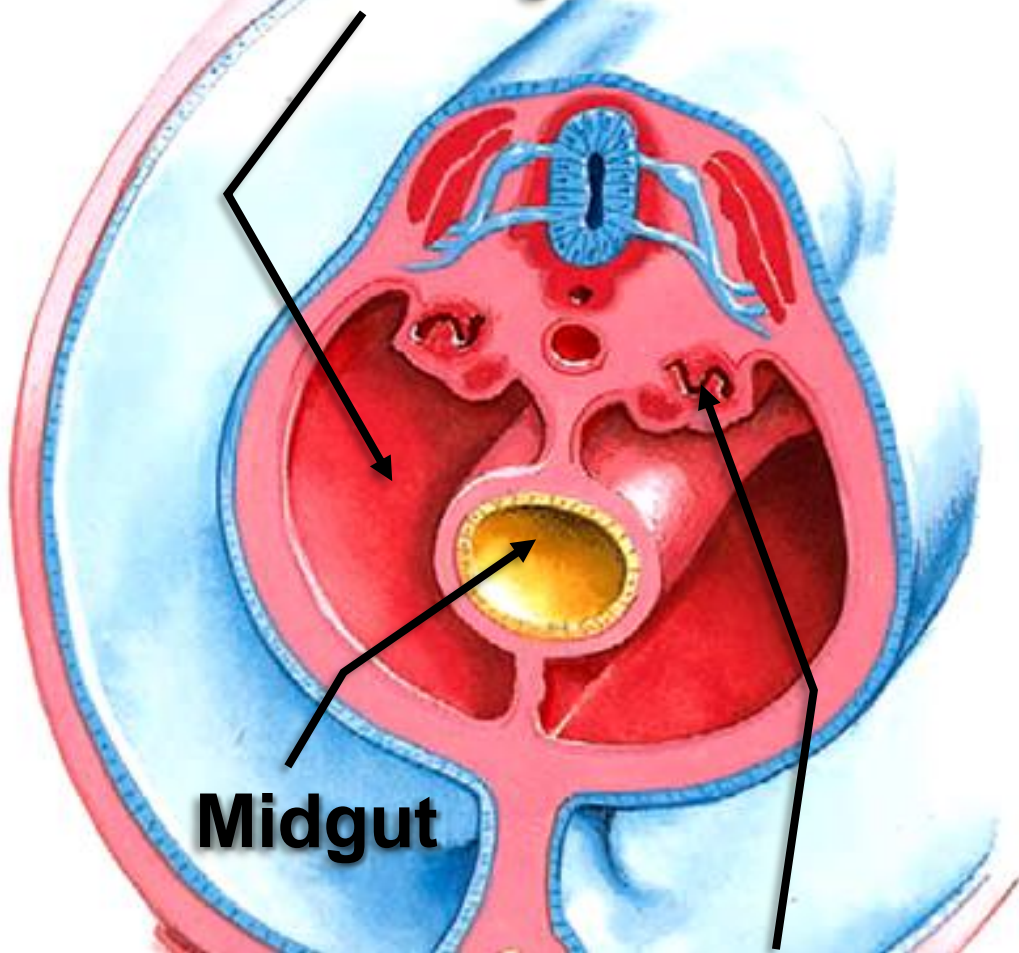
- It is divided by **Urorectal septum** into:

1- **Ventral part** called **urogenital sinus**, closed by urogenital membrane that forms the mucosa of the urinary bladder and urethra (and the upper part of the vagina in females).

2- **Dorsal part** called **anorectal sinus**, closed by **anal membrane**. forms the mucosa of the rectum and upper part of the anal canal.



Single peritoneal cavity



Midgut

Intermediate
mesoderm

➤ Results of lateral Folding


- The embryo becomes **cylindrical** in shape.
- The part of the gut is called **midgut** and connecting to the dorsal wall of the embryo by **dorsal mesentery**
- **Vitello-intestinal duct between midgut and definitive yolk sac**
- The caudal parts of the intraembryonic coelom fuse together to form **a single peritoneal cavity.**
- The **intermediate mesoderm** becomes dorsal to the peritoneal cavity.

اليوتيوب د. يوسف حسين

https://www.youtube.com/channel/UCVSNqbibj9UWYaJdd_cn0PQ

يُمنع أخذ السلايدات بدون
إذن المحرر واي اجراء
يخالف ذلك يقع تحت
طائلة المسؤولية القانونية

اليوتيوب د. يوسف حسين



Thank You

Questions

<https://www.youtube.com/@ProfDrYoussefHusseinAnatomy/playlists>