

وسهلا

أهلا

يُمنع أخذ السلايدات بدون
إذن المحرر واي اجراء
يخالف ذلك يقع تحت
طائلة المسؤولية القانونية



الأستاذ الدكتور يوسف حسين

أستاذ التشريح وعلم الأجنة - كلية الطب - جامعة الزقازيق - مصر

رئيس قسم التشريح و الأنسجة و الأجنة - كلية الطب - جامعة مؤتة - الأردن

دكتورة من جامعة كولونيا المانيا

جروب الفيس د. يوسف حسين (استاذ التشريح)

Prof. Dr. Youssef Hussein Anatomy - YouTube

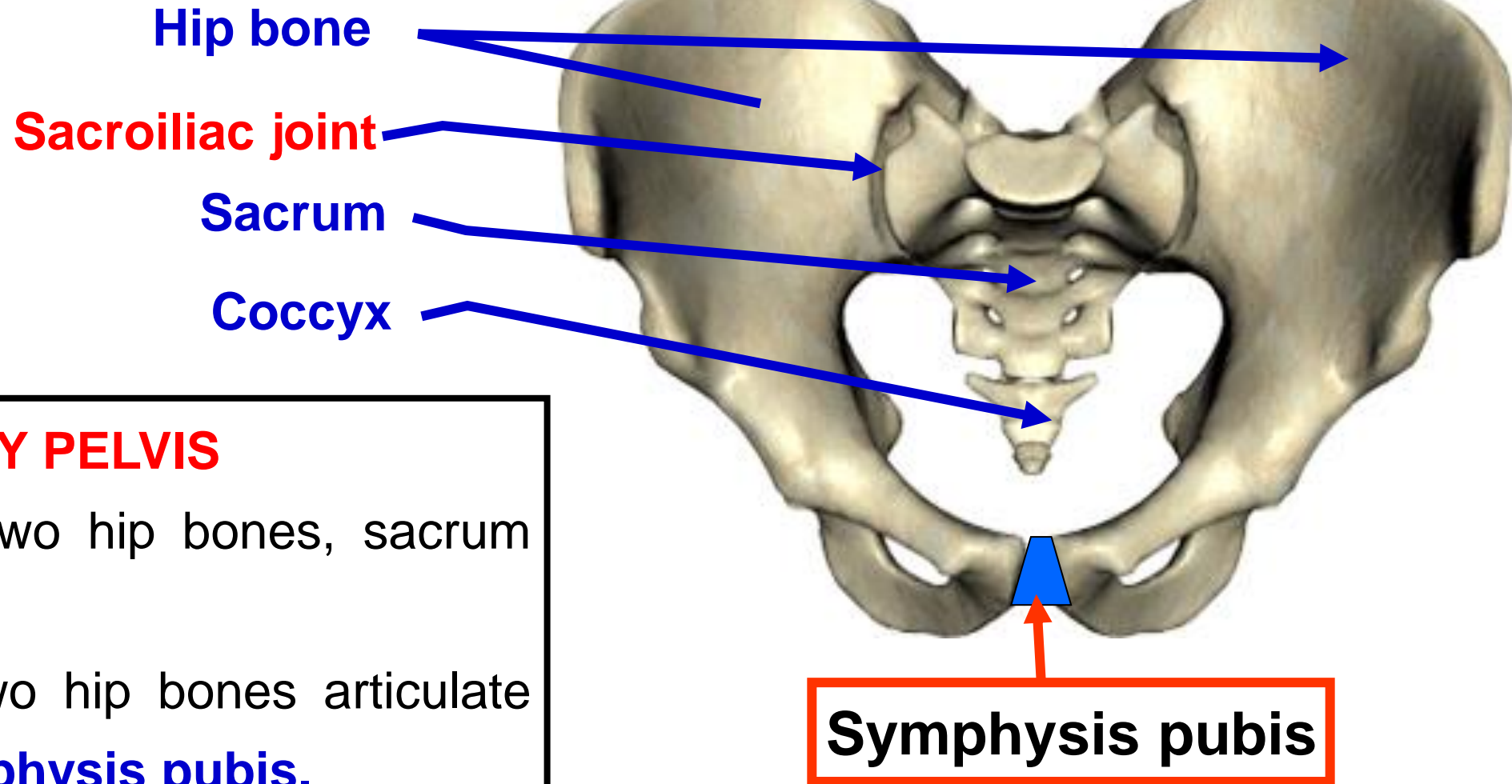
اليوتيوب د. يوسف حسين

<https://www.youtube.com/@ProfDrYoussefHusseinAnatomy/playlists>

dr_youssefhussein@yahoo.com

Female Bony Pelvis

[Prof. Dr. Youssef Hussein Anatomy - YouTube](#)



• **BONY PELVIS**

- It is formed by two hip bones, sacrum and coccyx
- **Anteriorly**, the two hip bones articulate together at the **symphysis pubis**.
- **Posteriorly**, the two hip bones articulate with the sacrum at the **sacroiliac joints**.

Anteroposterior diameter

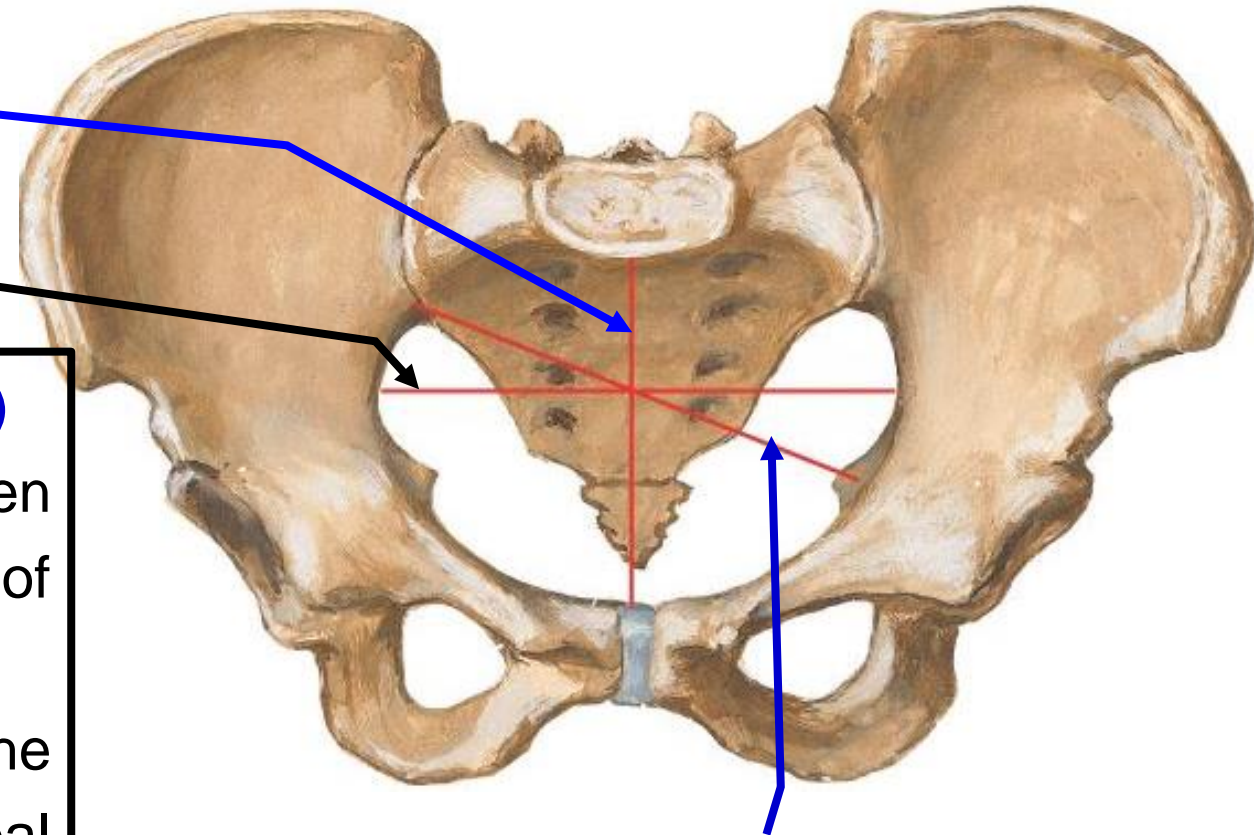
Transverse diameter

- **Diameters of the pelvic inlet (pelvic brim)**

1- Anteroposterior diameter (11 cm); between the tip of sacral promontory and upper border of symphysis pubis.

2- Oblique diameter (12 cm): between the sacroiliac joint of one side to the iliopectineal (iliopubic) eminence of the opposite side.

3- Transverse diameter (13 cm): between the most distant points on the lateral sides of the pelvic brim.

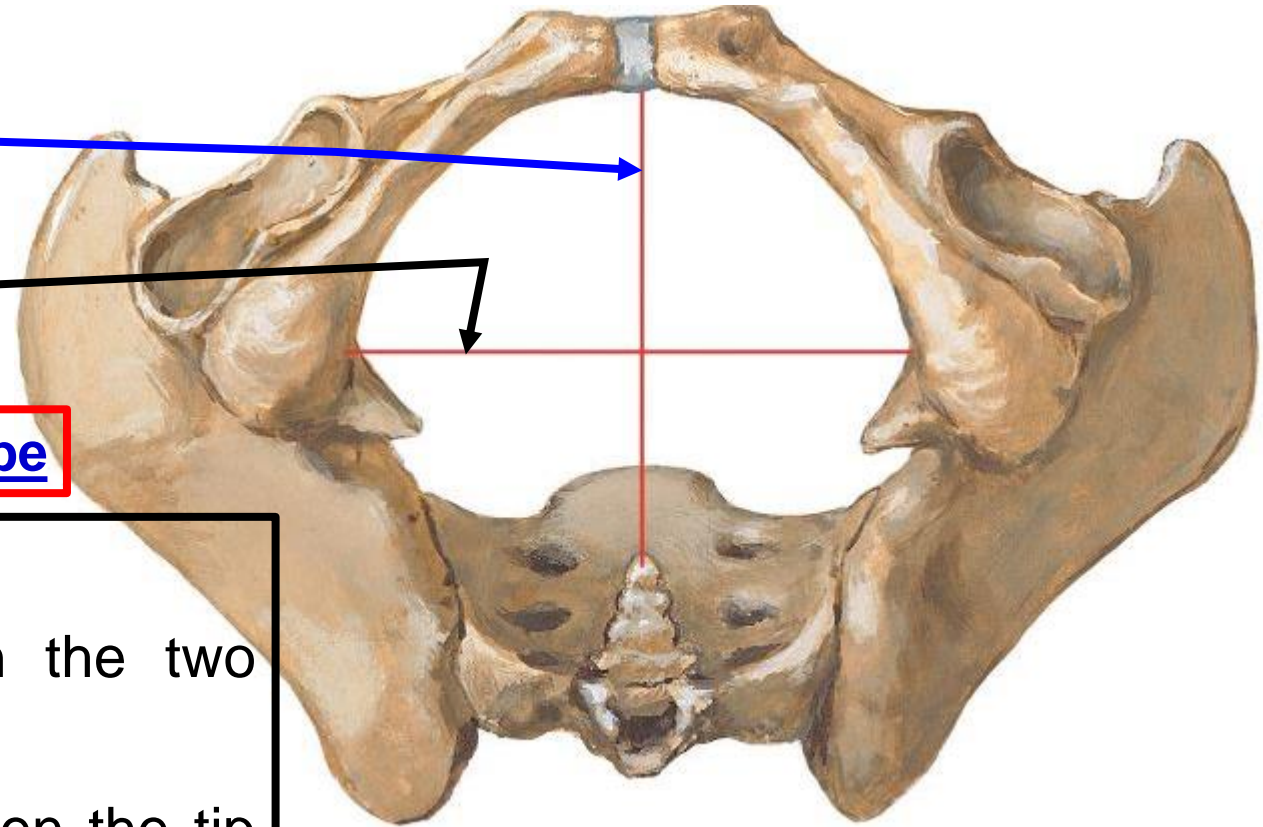


Oblique diameter

Anteroposterior diameter

Transverse diameter

[Prof. Dr. Youssef Hussein Anatomy - YouTube](#)



- **Diameters of the pelvic Outlet**

1- Transverse diameter (12 cm): between the two ischial tuberosities.

2- Anteroposterior diameter (13 cm): between the tip of the coccyx and the lower border of the symphysis pubis and.

- **Diameters of the foetal skull**

1- Transverse diameter (Biparietal) is 9.5 cm

2- Occipitofrontal is 11 cm

Remember sutures of the skull

• Types of female pelvis

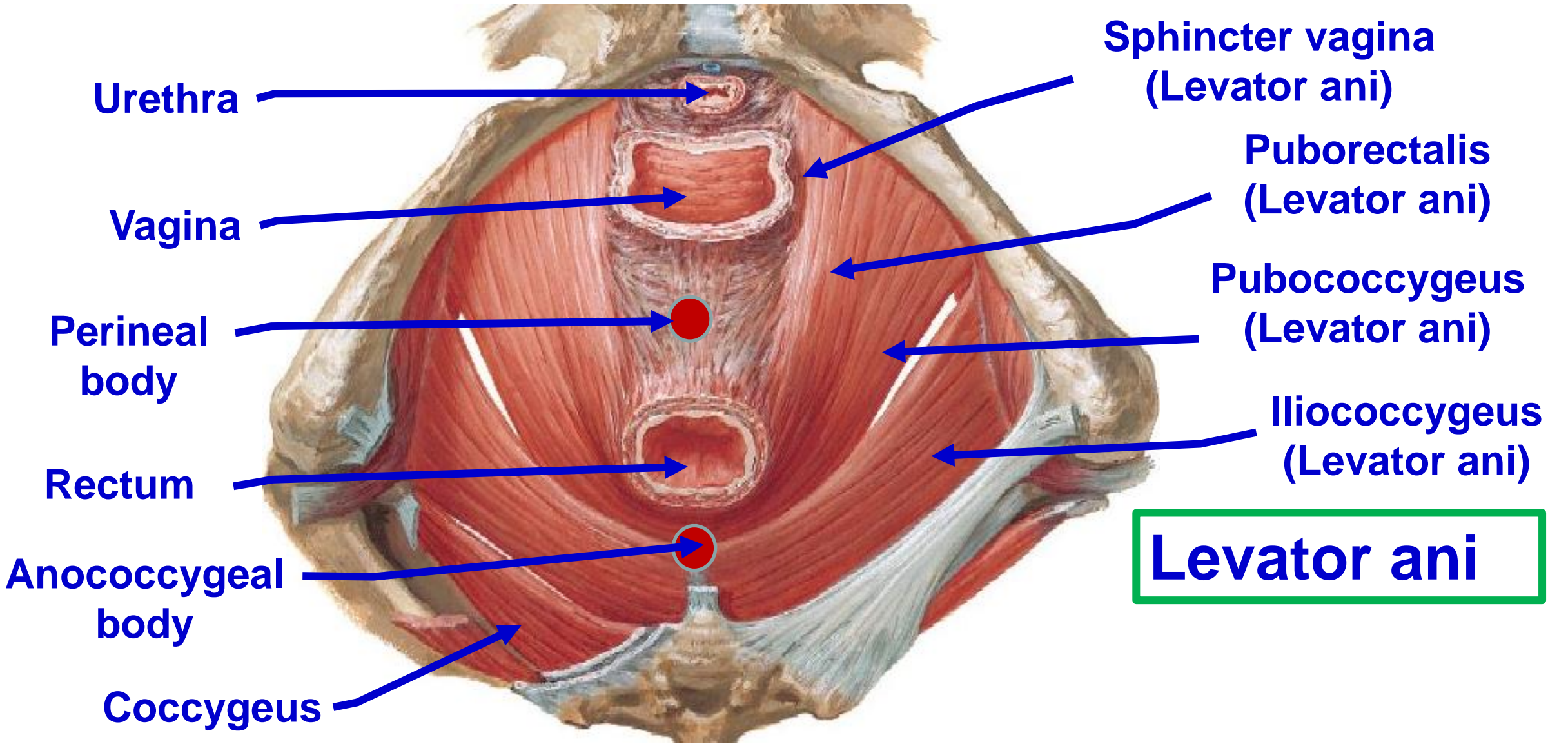
- **Gynaecoid pelvis(50%): normal female type.**
 - Inlet is slightly transverse oval.
 - Sacrum is wide and short.
 - Subpubic angle is 90-100°.
- **Anthropoid pelvis (25%): ape-like type.**
 - All anteroposterior diameters are long.
 - All transverse diameters are short.
 - Subpubic angle is narrow.
- **Android pelvis (20%): male type.**
 - Inlet is triangular or heart-shaped with anterior narrow apex.
 - Sacrum is long and narrow, pelvic surface is more curved
 - Subpubic angle is narrow <90°.
- **Platypelloid pelvis (5%): flat female type.**
 - All anteroposterior diameters are short.
 - All transverse diameters are long.
 - Subpubic angle is wide.

[Prof. Dr. Youssef Hussein Anatomy - YouTube](#)

dr_youssefhussein@yahoo.com

Pelvic diaphragm

[Prof. Dr. Youssef Hussein Anatomy - YouTube](#)



Urethra

Vagina

Perineal
body

Rectum

Anococcygeal
body

Coccygeus

Sphincter vagina
(Levator ani)

Puborectalis
(Levator ani)

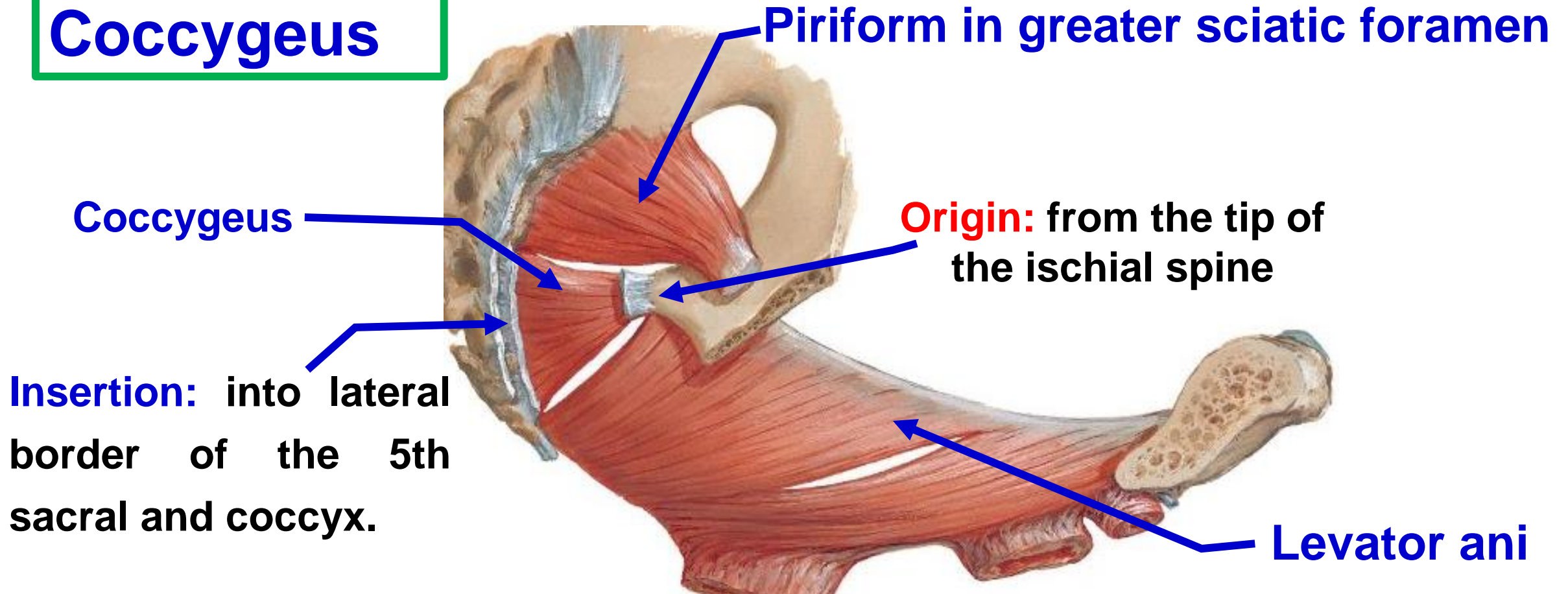
Pubococcygeus
(Levator ani)

Iliococcygeus
(Levator ani)

Levator ani

Prof. Dr. Youssef Hussein Anatomy - YouTube

Coccygeus



**** Nerve supply:** ventral rami S4 & S5.

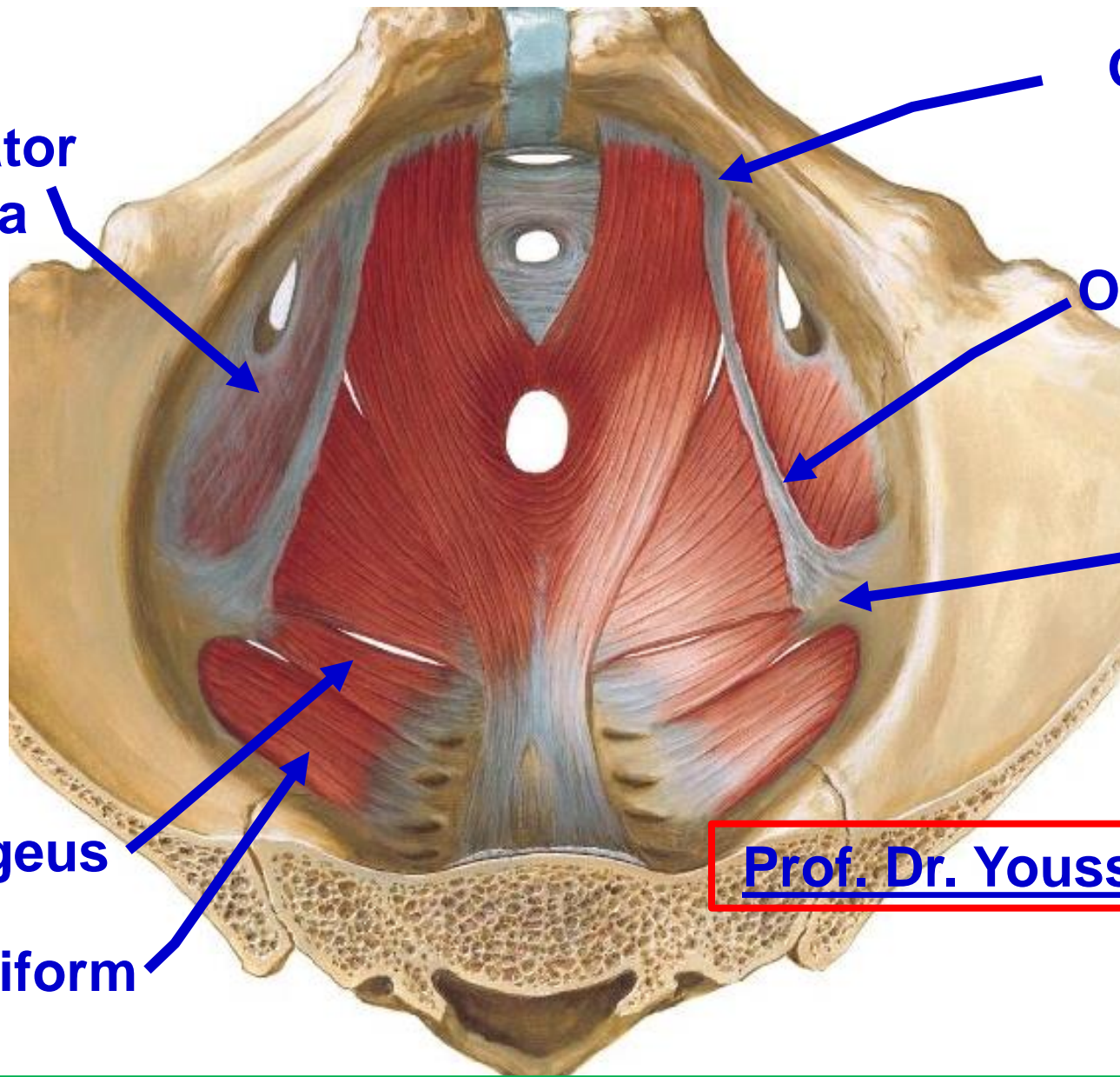
**** Actions:**

[Prof. Dr. Youssef Hussein Anatomy - YouTube](#)

1- It forms the posterior part of the pelvic floor.

2- It pulls the coccyx forwards after defecation and labor

Obturator fascia



Origin from the back of the body of the pubis

Origin from white line (tendinous arch) of the obturator fascia

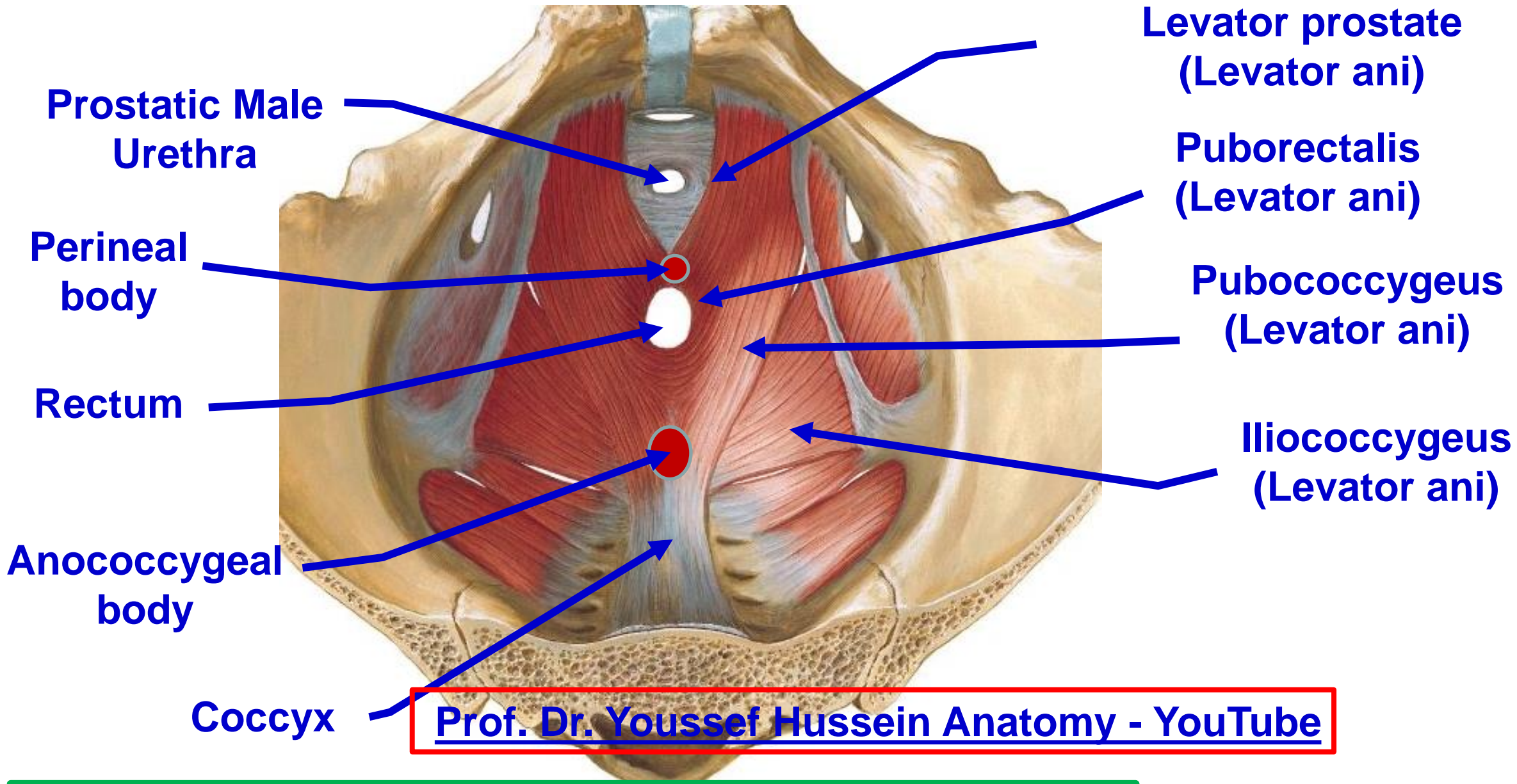
Origin from the Inner surface of the base of ischial spine

Coccygeus

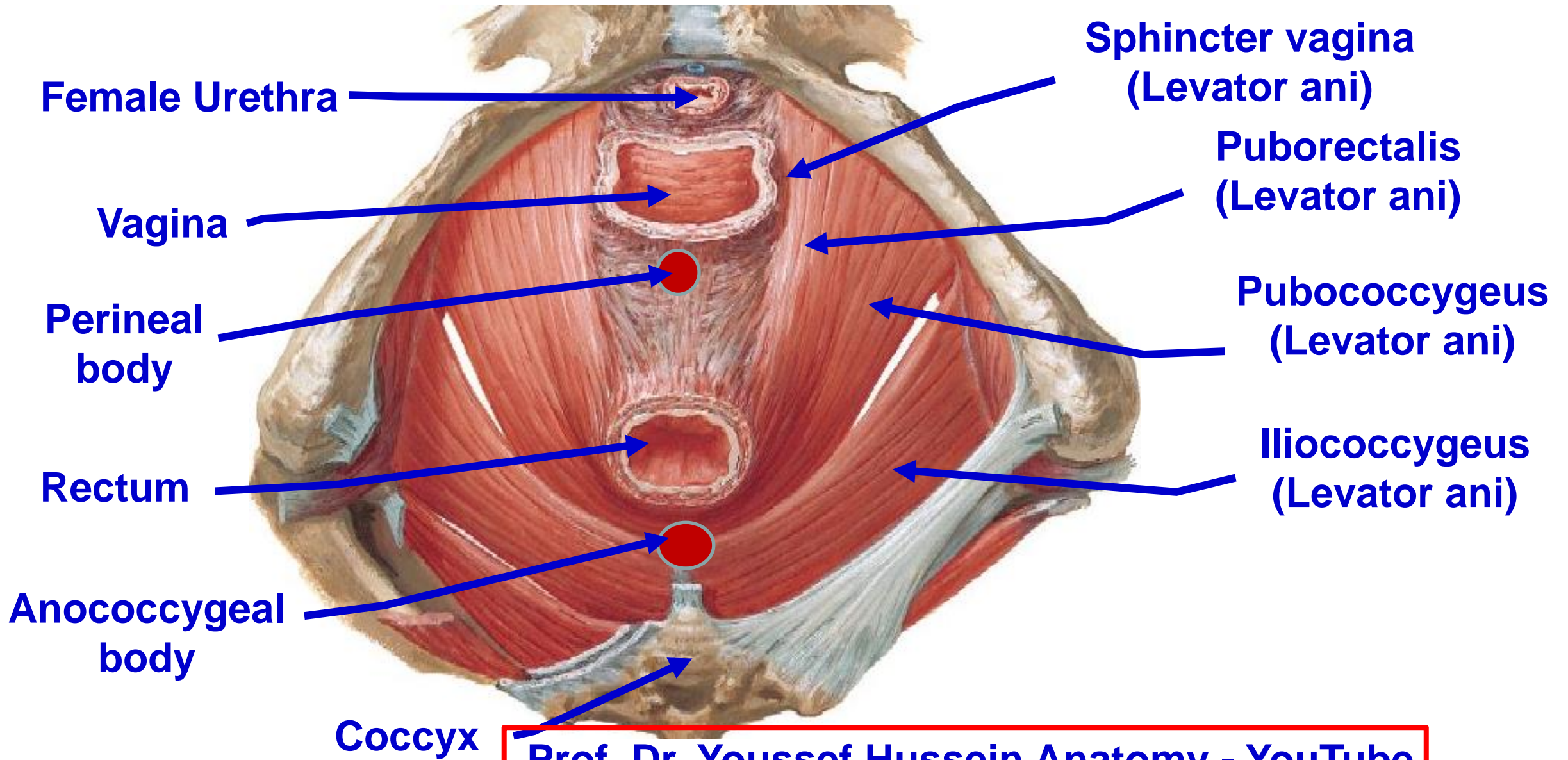
Piriform

Prof. Dr. Youssef Hussein Anatomy - YouTube

Origin of levator ani muscle



Insertion of levator ani muscle male



[Prof. Dr. Youssef Hussein Anatomy - YouTube](#)

Insertion of levator ani muscle female

**** Insertion of levator ani**

- The fibers pass backward, downward and medially

A- Anterior fibres, to the perineal body forming U shaped.

1) **In male**: around the prostate gland (called **Levator prostate**).

2) **In female**: the side of the vagina (called **Sphincter vagina**).

B- Intermediate fibers (Puborectalis): to unite with the band of the opposite side forming U-shaped sling around the anorectal junction.

C- Posterior fibers (Pubococcygeus) to anal canal, anococcygeal body and coccyx.

D- Most posterior (Iliococcygeus) to anococcygeal body and coccyx.

[Prof. Dr. Youssef Hussein Anatomy - YouTube](#)

**** Nerve supply:**

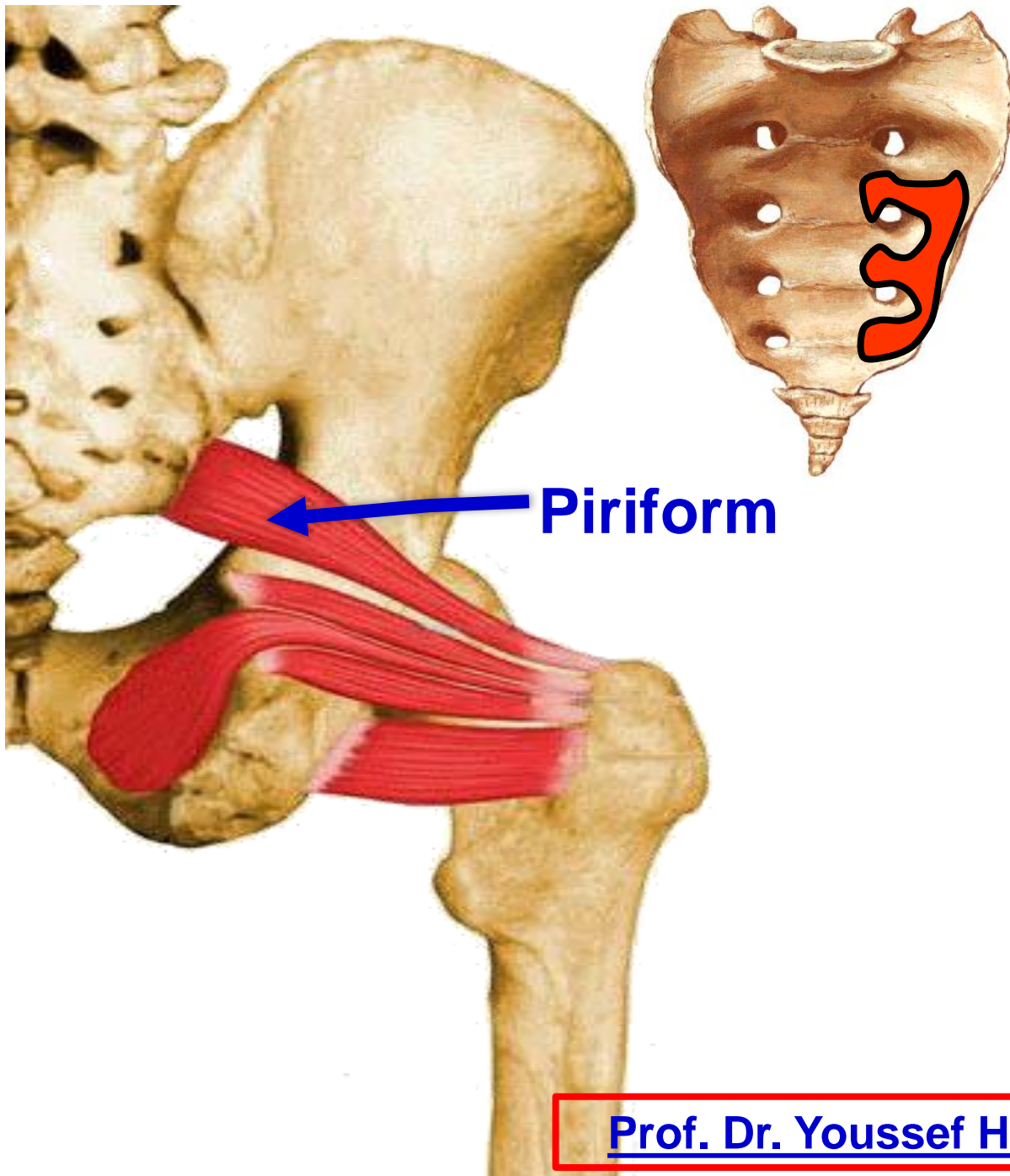
- **a- Pelvic (Upper) surface:** from the sacral plexus **S4 & S5**
- **b- Perineal (Lower) surface:** inferior rectal nerve and perineal nerve (pudendal nerve).

**** Actions:**

- 1- **Support** the pelvic organs.
- 2- Increase the intra abdominal pressure.
- 3- **Levator prostatae** elevates the prostate in male.
- 4- **Sphincter vagina** acts as a sphincter for the vagina (proper sexual function).
- 5- **Puborectalis** acts as sphincter to the anorectal junction.
- 6- **Pubococcygeus** pulls the coccyx forwards after defecation

- **Levator ani syndrome**
- **Tight pelvic floor muscle (not relaxed)**
- **Causes: unknown**, spasm of muscle , after hemorrhoid surgery, irritable bowel syndrome, anal fissure, prolonged sitting.
- **Symptoms**
 - Rectal pain
 - Pain with sitting
 - Excessive discomfort after bowel movement
 - Urine incontinence
 - Pain is aggravated by sexual activity

Weakness or injury of levator ani during vaginal deliveries leading to uterine prolapse (uterus protrudes in vagina)



❖ Piriformis

** **Origin:** from the pelvic surface of the middle 3 pieces of the sacrum.

** **Insertion:** The muscle passes out through the greater sciatic foramen and inserted into the **top** of the greater trochanter.

** **Nerve supply:** ventral rami of S1, 2.

** **Action:**

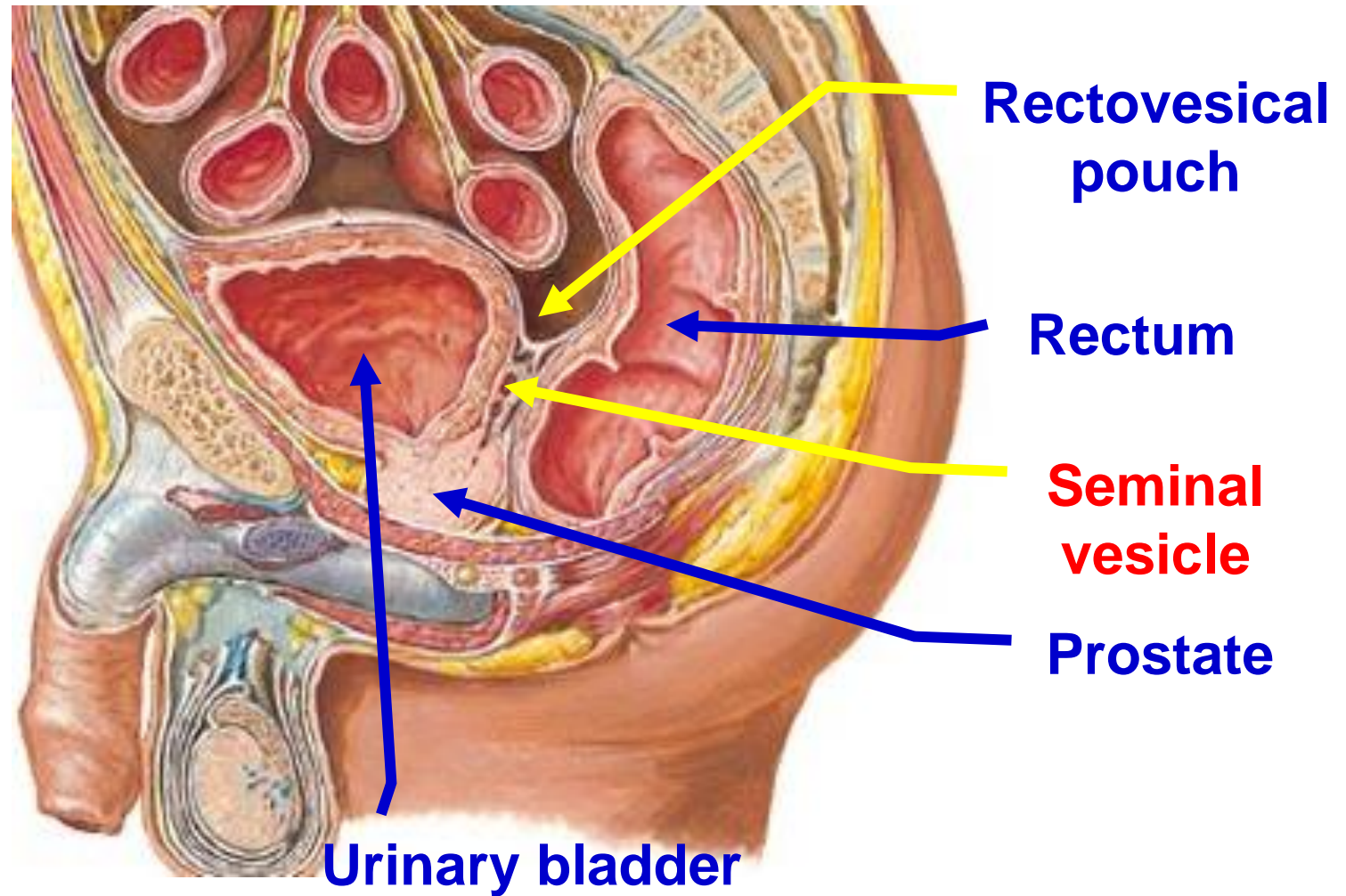
- 1- Lateral rotation of the extended thigh.
- 2- Stabilization of the hip joint.



**Pelvic
peritoneum**

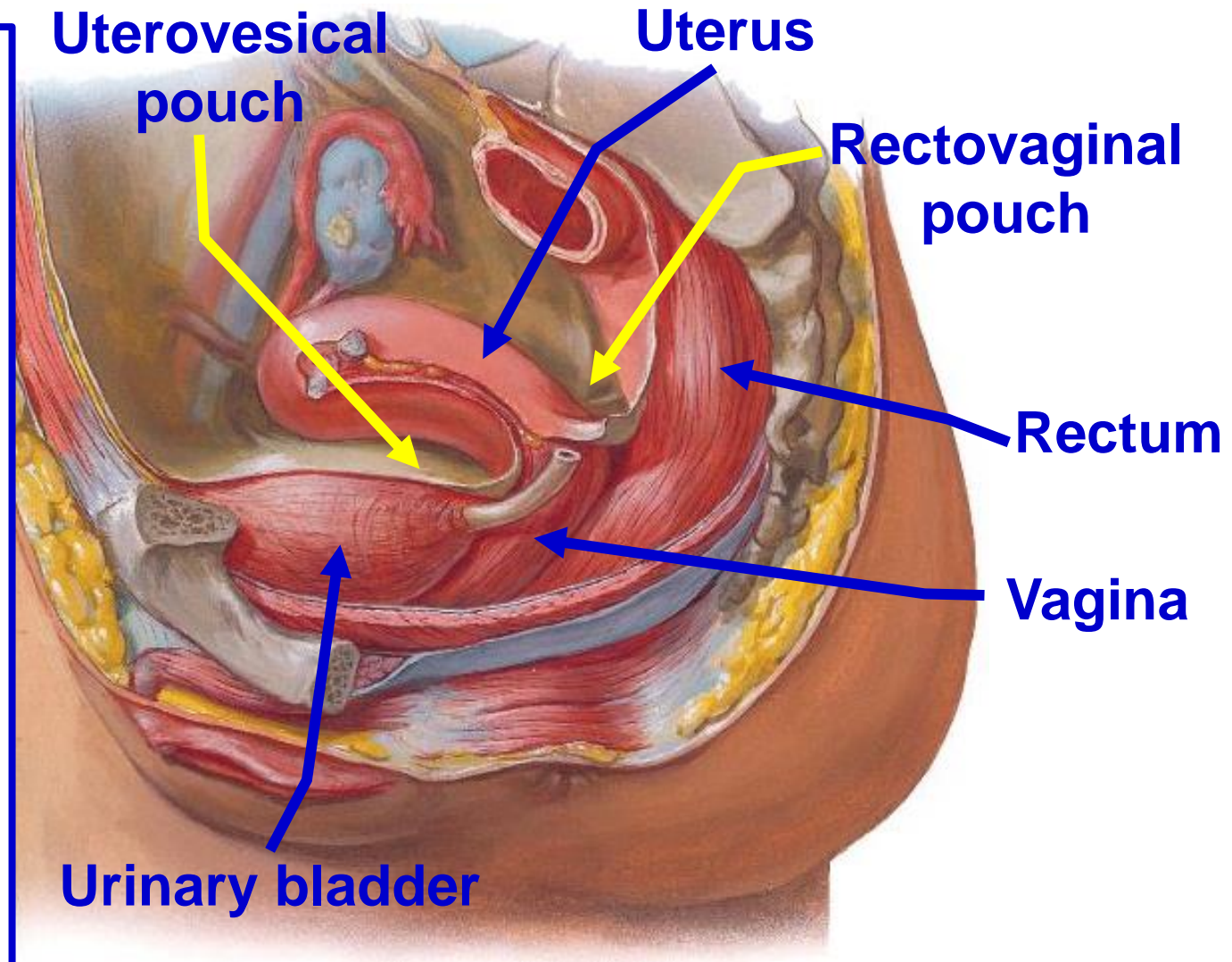
- **Pelvic peritoneum of the male**

- Reflection of peritoneum at junction of middle and lower 1/3 to upper part of base of urinary bladder to form **recto-vesical pouch**
- **Then covers** superior surface of UB and then upwards to continue with the peritoneum lining the anterior abdominal wall.
- Peritoneum is **closed sac**.



- **Pelvic peritoneum of the female**


- Reflection of peritoneum from rectum to upper part of posterior wall of the vagina form **rectovaginal, or Douglas pouch**.
- It covers the posterior surface of the cervix and body of the uterus.
- Then, it covers the fundus and anterior surface of the body of uterus.
- A reflection of peritoneum occurs at the junction of body with cervix to upper surface of the urinary bladder form **uterovesical pouch**.
- Then, upwards to continue with the peritoneum lining anterior abdominal wall.
- Peritoneum contains the **openings** of the lateral ends of both uterine tubes.



https://www.youtube.com/channel/UCVSNqbibj9UWYaJdd_cn0PQ

يُمنع أخذ السلايدات بدون
إذن المحرر واي اجراء
يخالف ذلك يقع تحت
طائلة المسؤولية القانونية

اليوتيوب د. يوسف حسين



Thank You

Questions

<https://www.youtube.com/@ProfDrYoussefHusseinAnatomy/playlists>