

وسهلا

أهلا



الأستاذ الدكتور يوسف حسين

يُمنع أخذ السلايدات بدون
إذن المحرر واي اجراء
يخالف ذلك يقع تحت
طائلة المسؤولية القانونية

أستاذ التشريح وعلم الأجنة - كلية الطب - جامعة الزقازيق - مصر

رئيس قسم التشريح و الأنسجة و الأجنة - كلية الطب - جامعة مؤتة - الأردن

دكتورة من جامعة كولونيا المانيا

جروب الفيس د. يوسف حسين (استاذ التشريح)

Prof. Dr. Youssef Hussein Anatomy - YouTube

<https://www.youtube.com/@ProfDrYoussefHusseinAnatomy/playlists>

dr_youssefhussein@yahoo.com

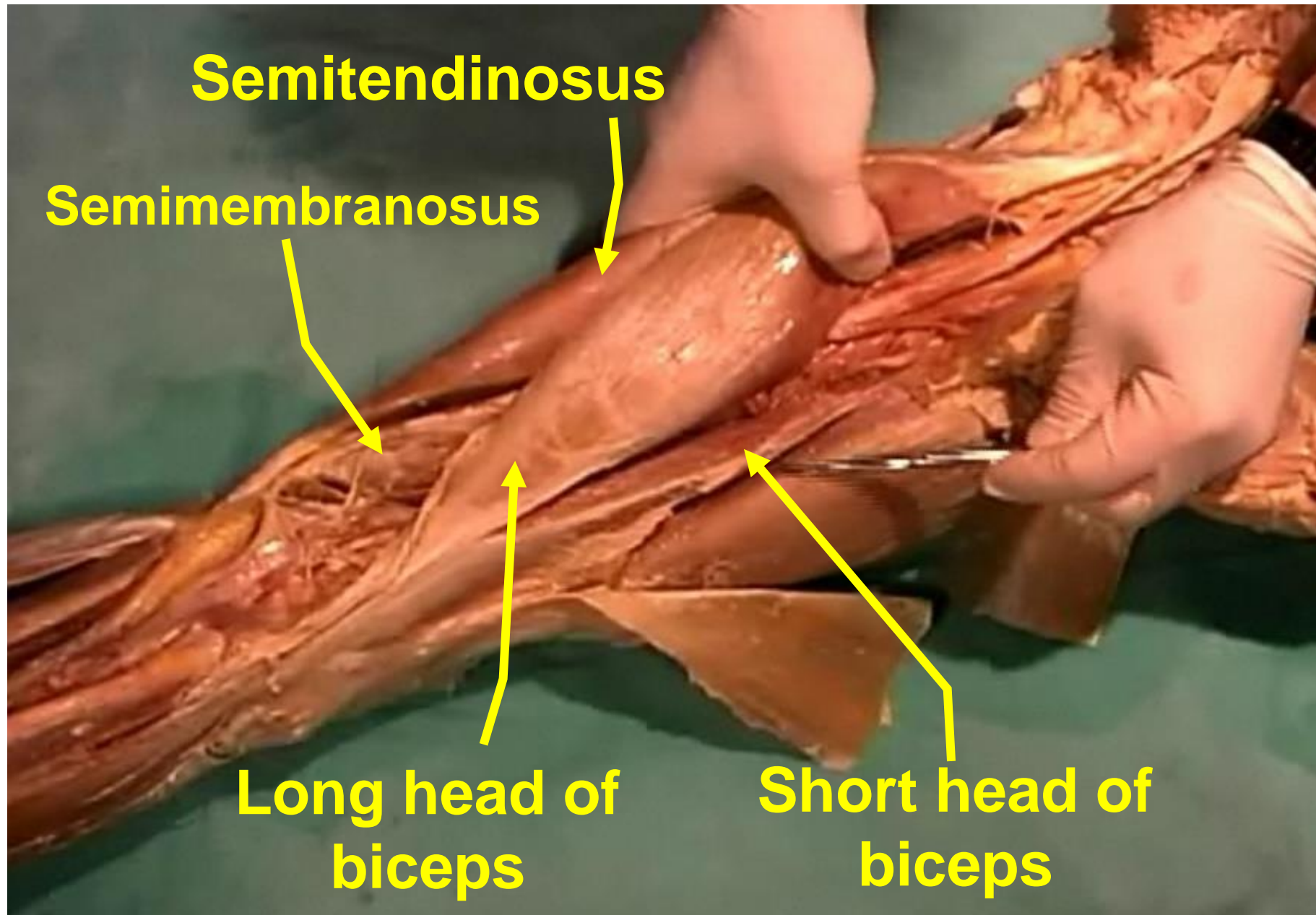
- Muscles of the posterior compartment of the thigh.
- **Hamstrings** because they have a long course from origin to insertion form **cord** (**string**) descending down to the popliteal region (**Ham**).
- **Origin** ischial tuberosity.
- **Nerve:** **sciatic** nerve.

**** Actions:**

- 1- Extension of the hip Joint
- 2- Flexion of the knee joint.



<https://www.youtube.com/@ProfDrYoussefHusseinAnatomy/playlists>

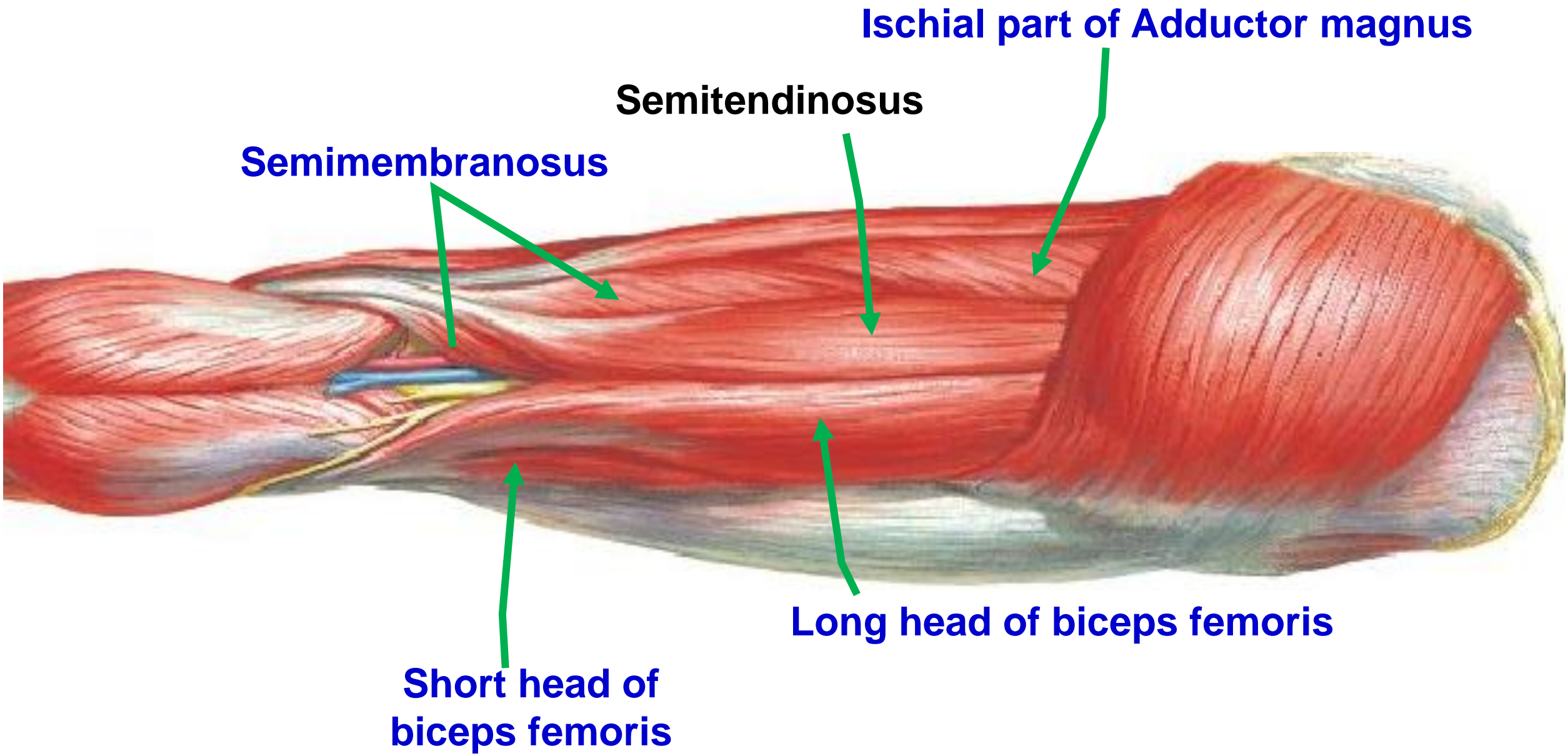


Semitendinosus

Semimembranosus

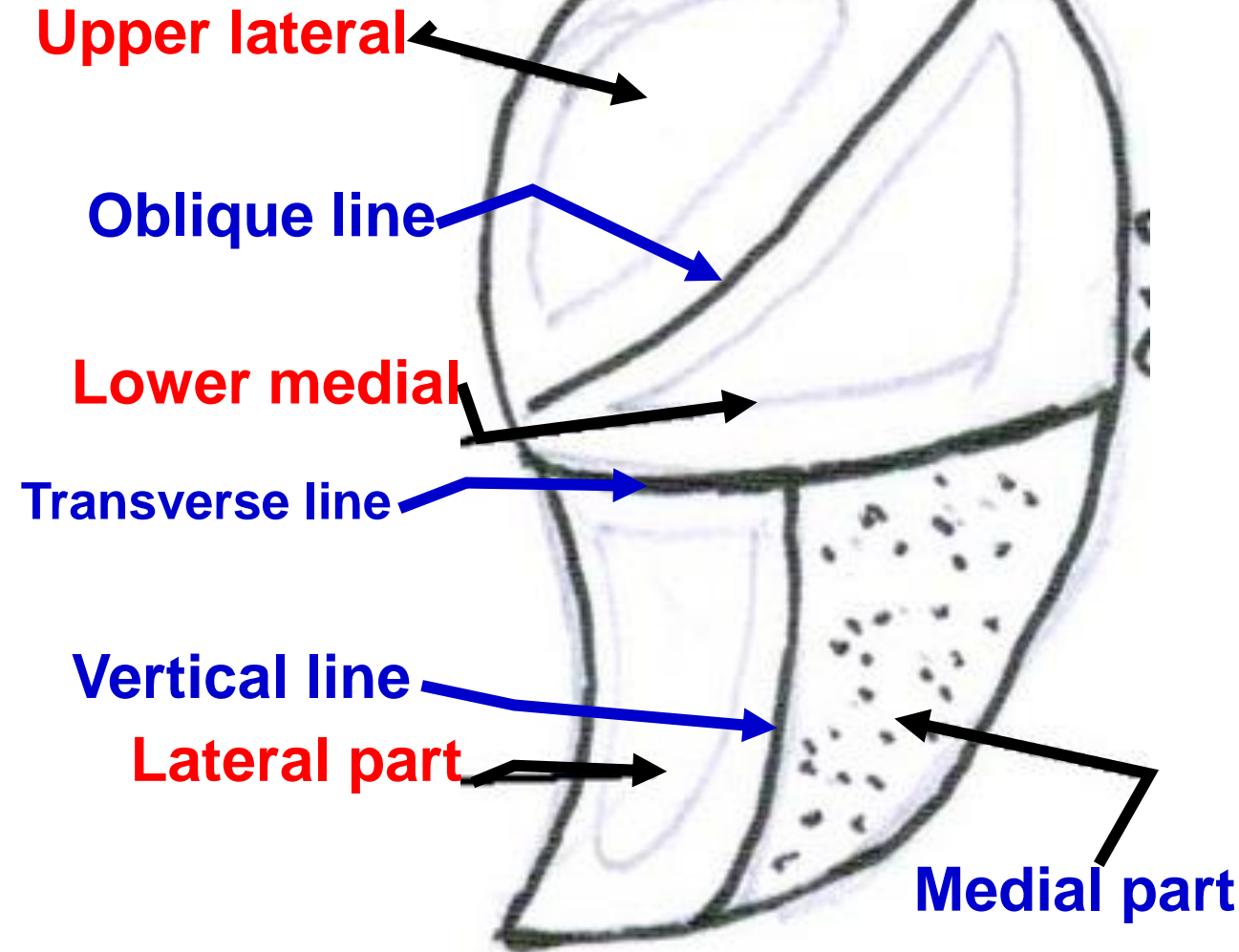
**Long head of
biceps**

**Short head of
biceps**

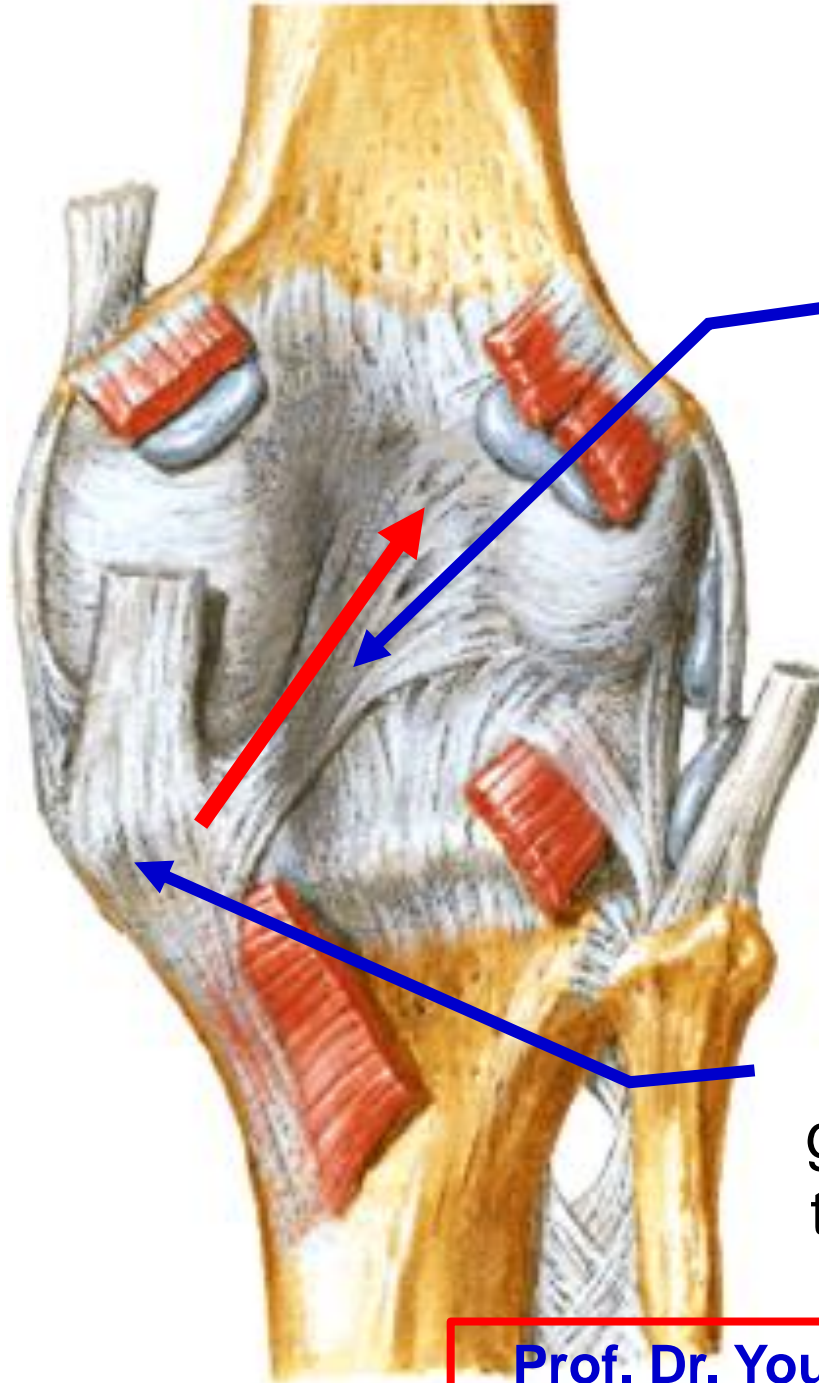


Origin of hamstring muscles

- Ischial tuberosity
- **Upper lateral part of the Upper area** (origin of semimembranosus)
- **Lower medial part of Upper area** (origin of semitendinosus and long head of biceps femoris) .
- **Lateral part of the lower area** (origin of ischial part of adductor magnus)



Left ischial tuberosity

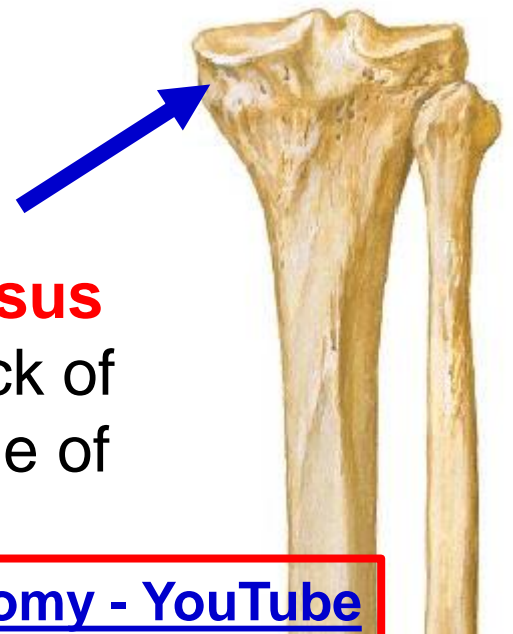


Insertion of Semimembranosus

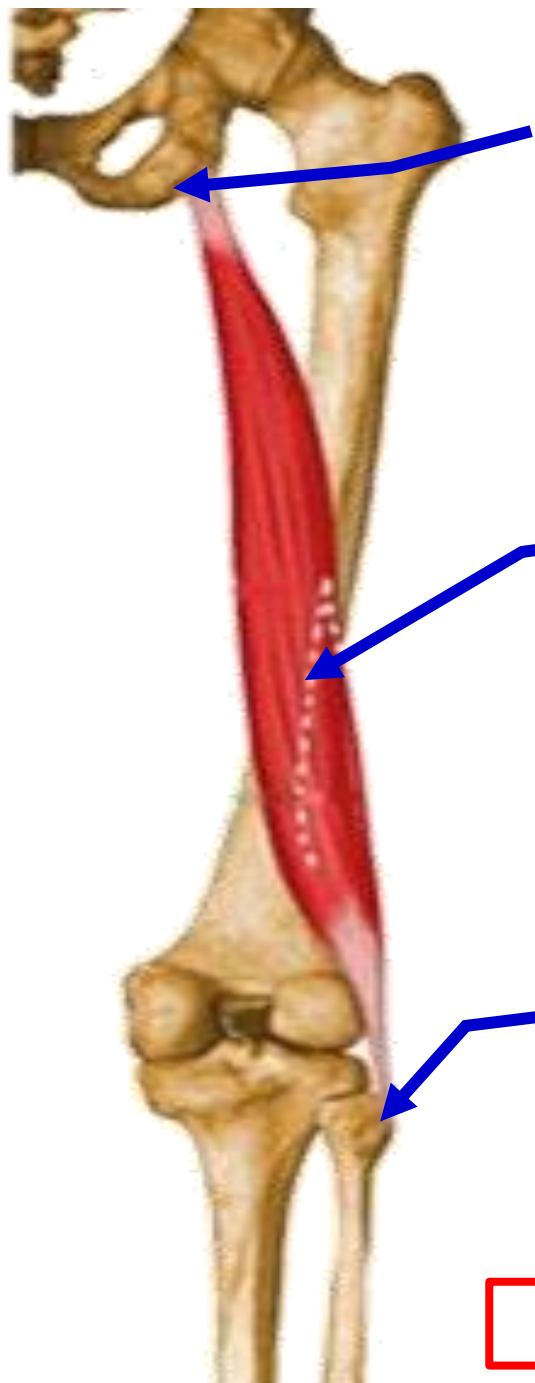Some fibers are reflected upwards and laterally to form the **posterior oblique ligament** of knee joint.

Insertion of Semimembranosus

groove on the back of the medial condyle of the tibia.



- **Semitendinosus**
- **Semimembranosus**
- **Nerve supply** sciatic nerve.
- ** Actions:**
- 1- Extension of the hip Joint
- 2- Flexion of the knee joint.
- 3- Medial rotator of the semi flexed leg.**



Origin of Long head of biceps (Lower medial part of Upper area)

Origin of Short head of biceps from lower part of the linea aspera and upper part of the lateral supracondylar line

Insertion of biceps apex of head (styloid process of the fibula)

• **Biceps Femoris**

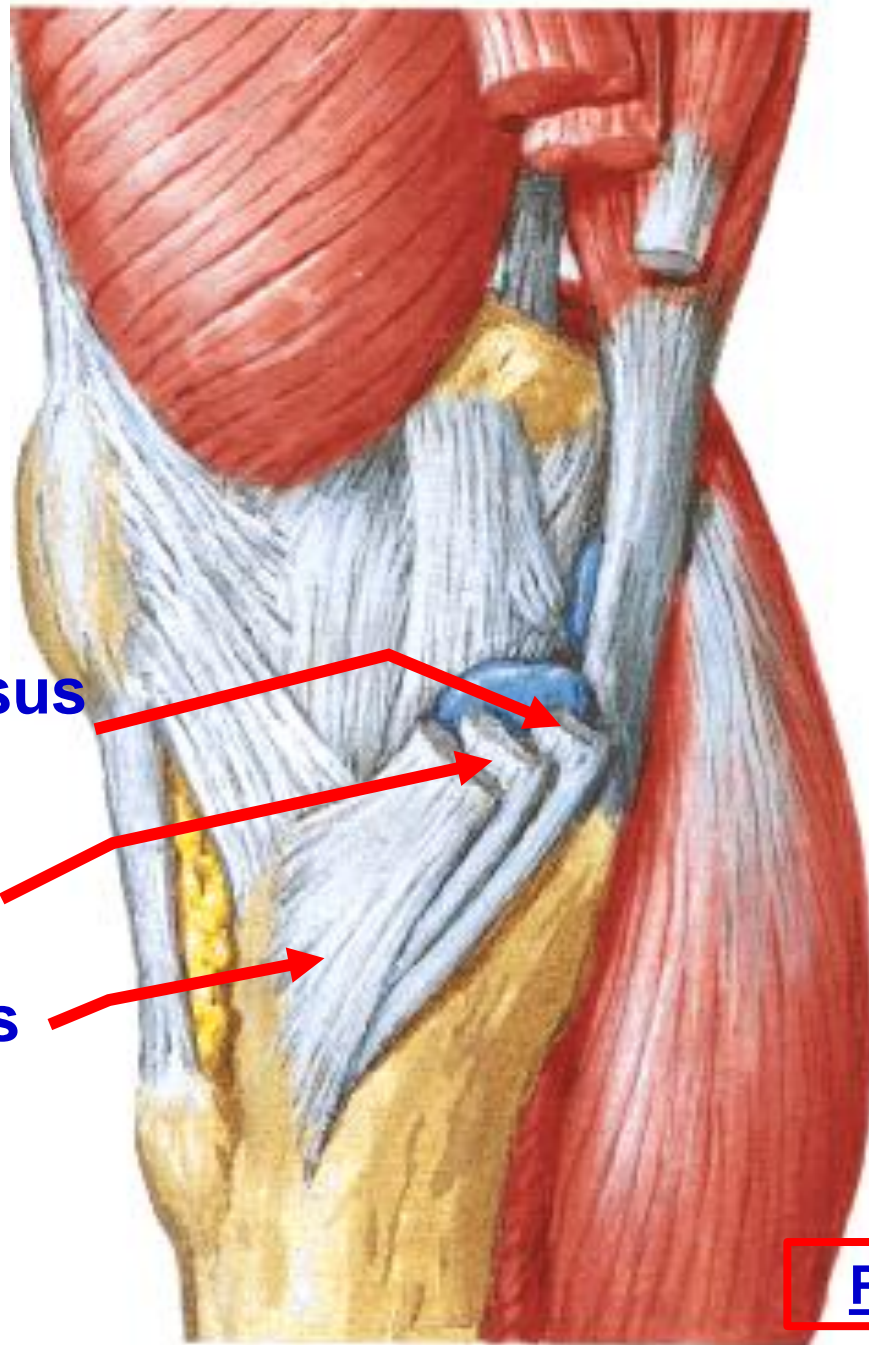
** **Nerve supply:**

- 1- Long head by sciatic nerve.
- 2- Short head by sciatic nerve through common peroneal nerve.

** **Actions:**

- 1- Extension of the hip Joint (long head).
- 2- Flexion of the knee joint.
- 3- **Only Lateral rotator of the semi flexed leg.**

S
G
S



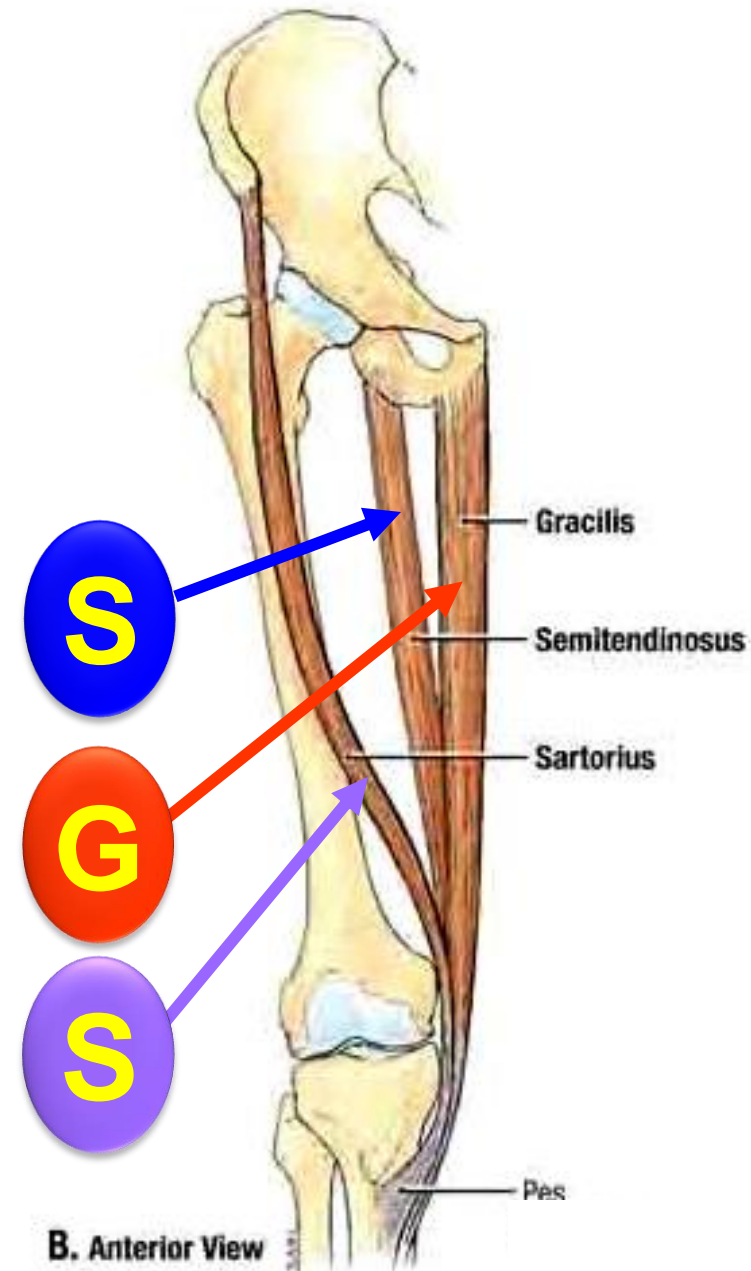
Semitendinosus

Gracilis

Sartorius

- **Insertion of Semitendinosus**
- **Pes anserinus** ("goose foot") refers to the conjoined tendons of three muscles (**S.G.S**) that **insert into upper part of the medial surface of the tibia** (sartorius, gracilis and semitendinosus from superficial to deep).

- Three muscles (SGS) form an inverted “**tripod**” with its base separated at the hip bone and its apex attached to upper part of the medial side of tibia
- Helping to stabilize the bony pelvis during standing.



dr_youssefhussein@yahoo.com

Popliteal fossa

[Prof. Dr. Youssef Hussein Anatomy - YouTube](#)

** Boundaries

**Upper
medial**

Semimembranosus

Semitendinosus

**Lower
medial**

**Medial head of
gastrocnemius**

Upper lateral

Biceps femoris

Plantaris

**Lateral head of
gastrocnemius**

**Lower
lateral**

**** Roof:** skin, superficial fascia and deep fascia.
- It is pierced by posterior cutaneous nerve of thigh

**** Site,** intermuscular space in the back of the lower part of the thigh, knee and upper part of the leg.

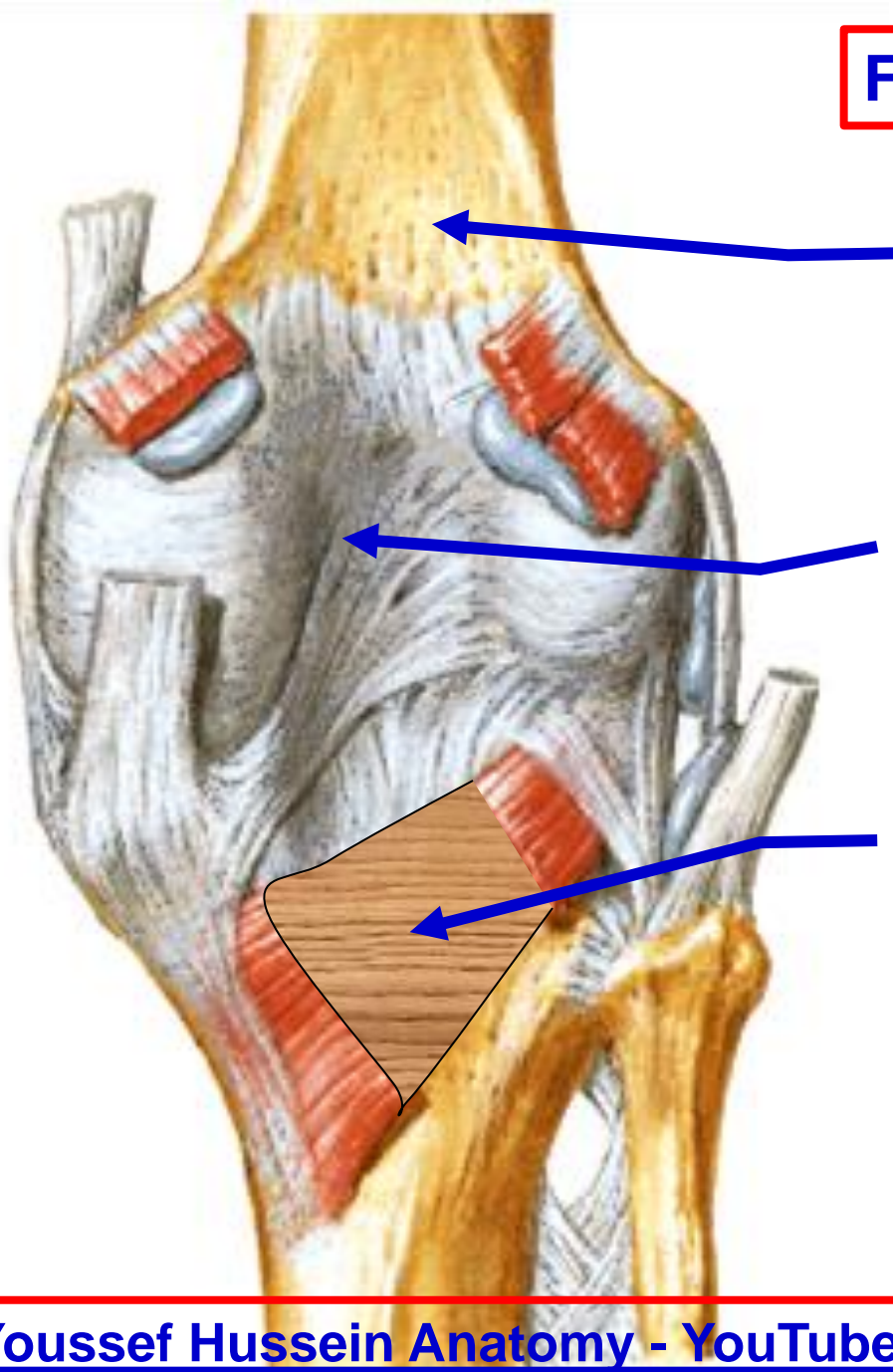
**** Shape,** diamond-shape.

Floor of popliteal fossa

Upper part is formed by the popliteal surface of the femur.

Middle part is formed by the back of the capsule of knee joint.

Lower part is formed by the fascia covering the popliteus muscle.



- The distal border of the popliteus forms the lower limit of the fossa.
- When the knee is **flexed**: the fossa will **form a hollow** because the tendons of the upper boundaries stand away from the femur.
- When the knee is **extended**: the fossa bulge backward as the tendons lie close to the femur.

Popliteal vein
Popliteal artery

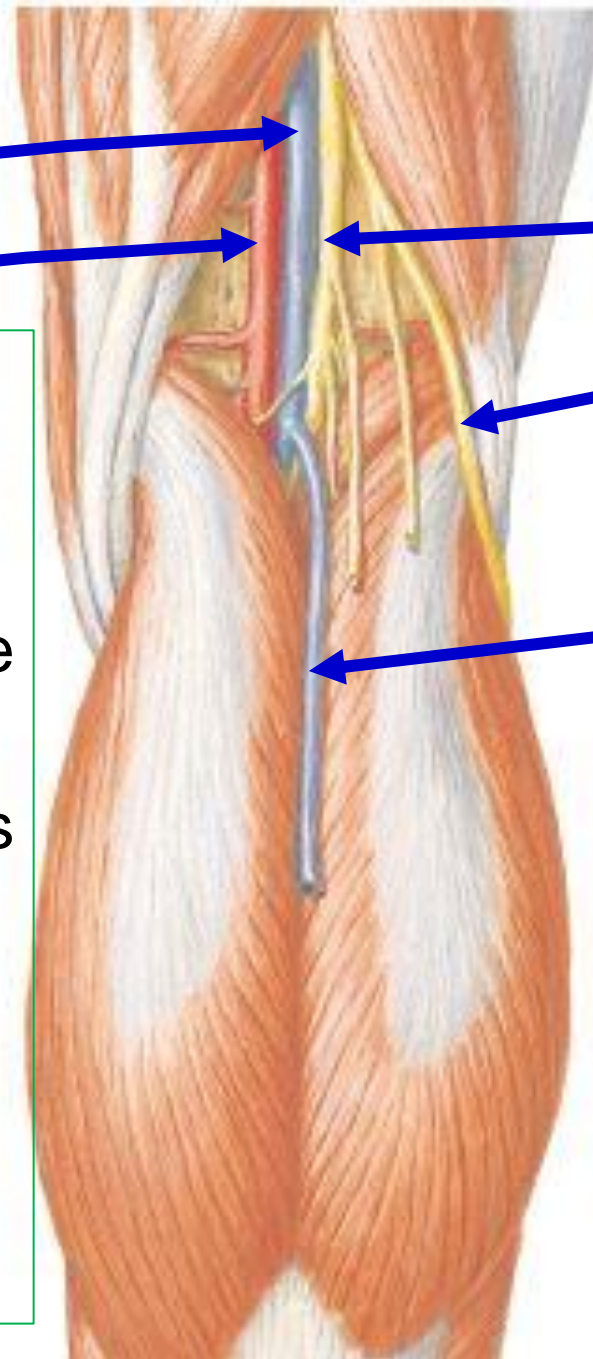
Tibial nerve

Common peroneal nerve

Small saphenous vein

**** Contents**

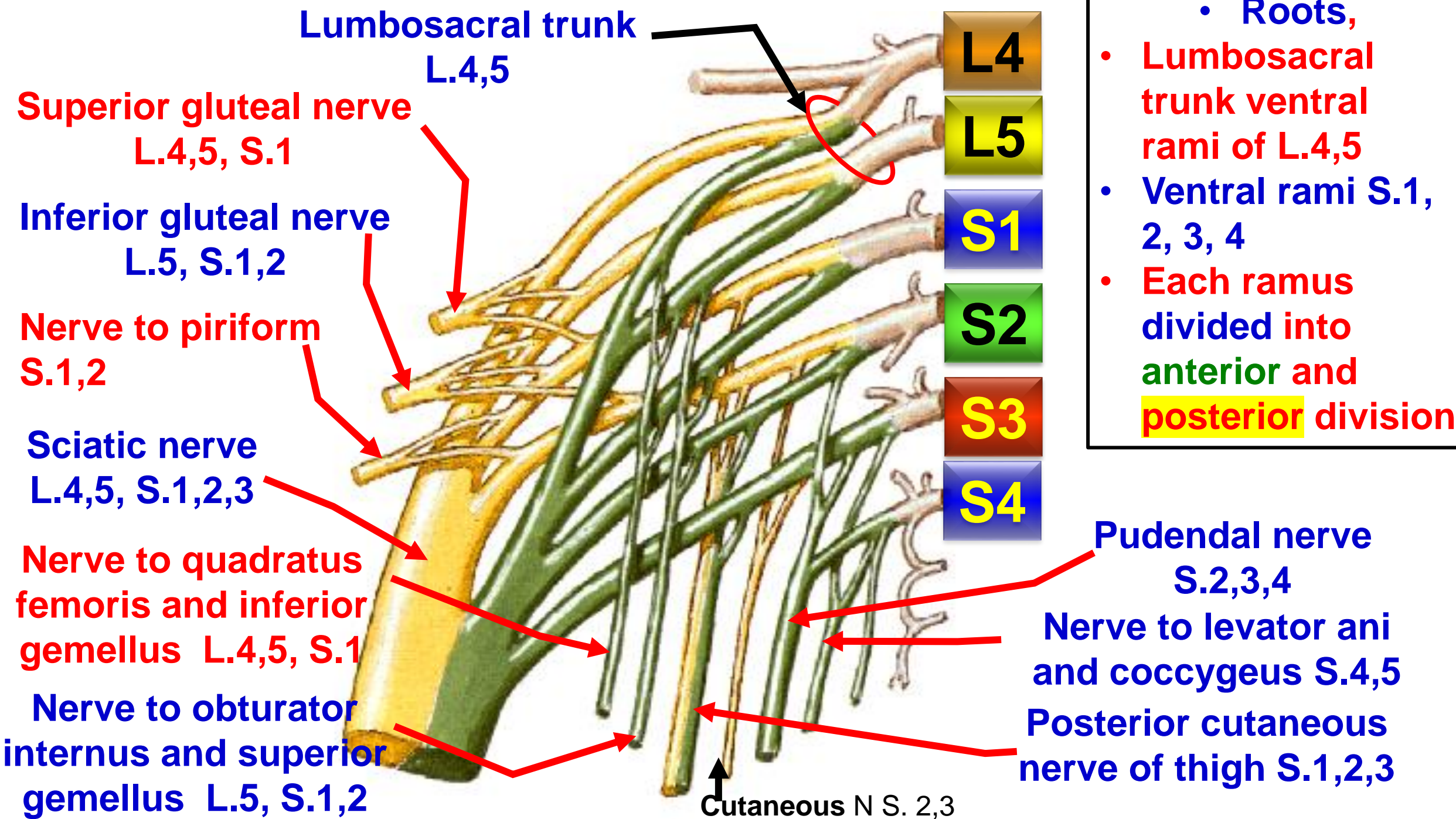
- 1- **Tibial nerve** and its branches.
- 2- **Common peroneal nerve** and its branches.
- 3- **Popliteal artery** and its branches (the deepest structures).
- 4- **Popliteal vein** and its tributaries (it lies superficial to the artery).
- 5- **Popliteal lymph nodes.**
- 6- **Popliteal fat.**
- 7- **Posterior cutaneous nerve of the thigh.**
- 8- **Small saphenous vein.**





Sacral plexus

[Prof. Dr. Youssef Hussein Anatomy - YouTube](#)





Posterior cutaneous nerve of thigh

[Prof. Dr. Youssef Hussein Anatomy - YouTube](#)

Posterior cutaneous nerve of the thigh

Gluteus maximus

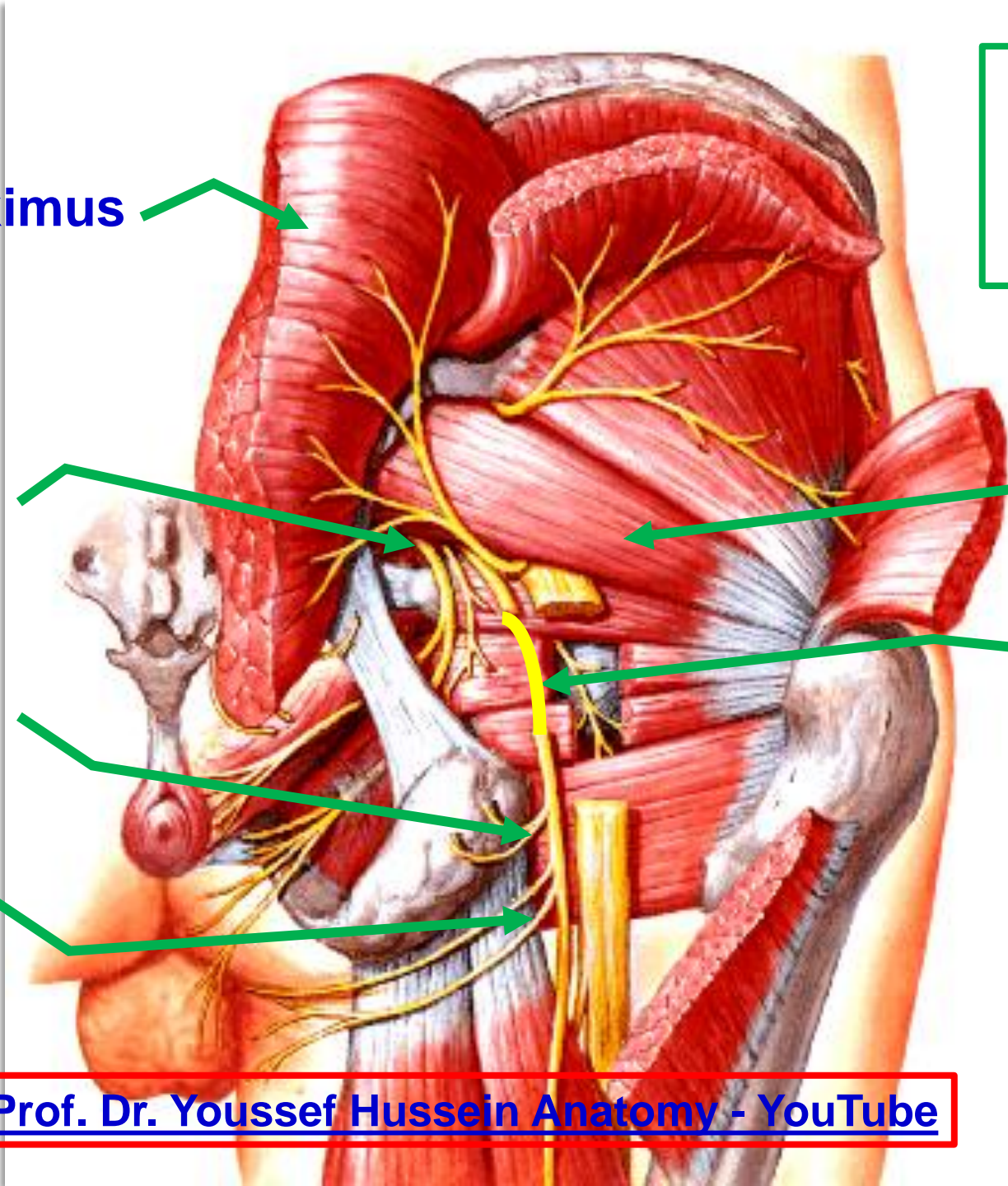
Greater sciatic foramen

Gluteal branch

Perineal branches

Piriform

Posterior cutaneous nerve of thigh



- **Posterior cutaneous nerve of the thigh (S1, 2, 3)**

* **Roots;** from anterior divisions (S.2,3) and posterior divisions (S.1,2) of sacral plexus.

* **Course and relations;**

- It comes out from the **greater sciatic foramen below the piriformis.**

- It descends **under cover of the gluteus maximus** then under cover of the **deep fascia in the back of the thigh.**

- It **pierces** the deep fascia covering the **popliteal fossa** and terminates by supplying the skin of the upper part of the calf.

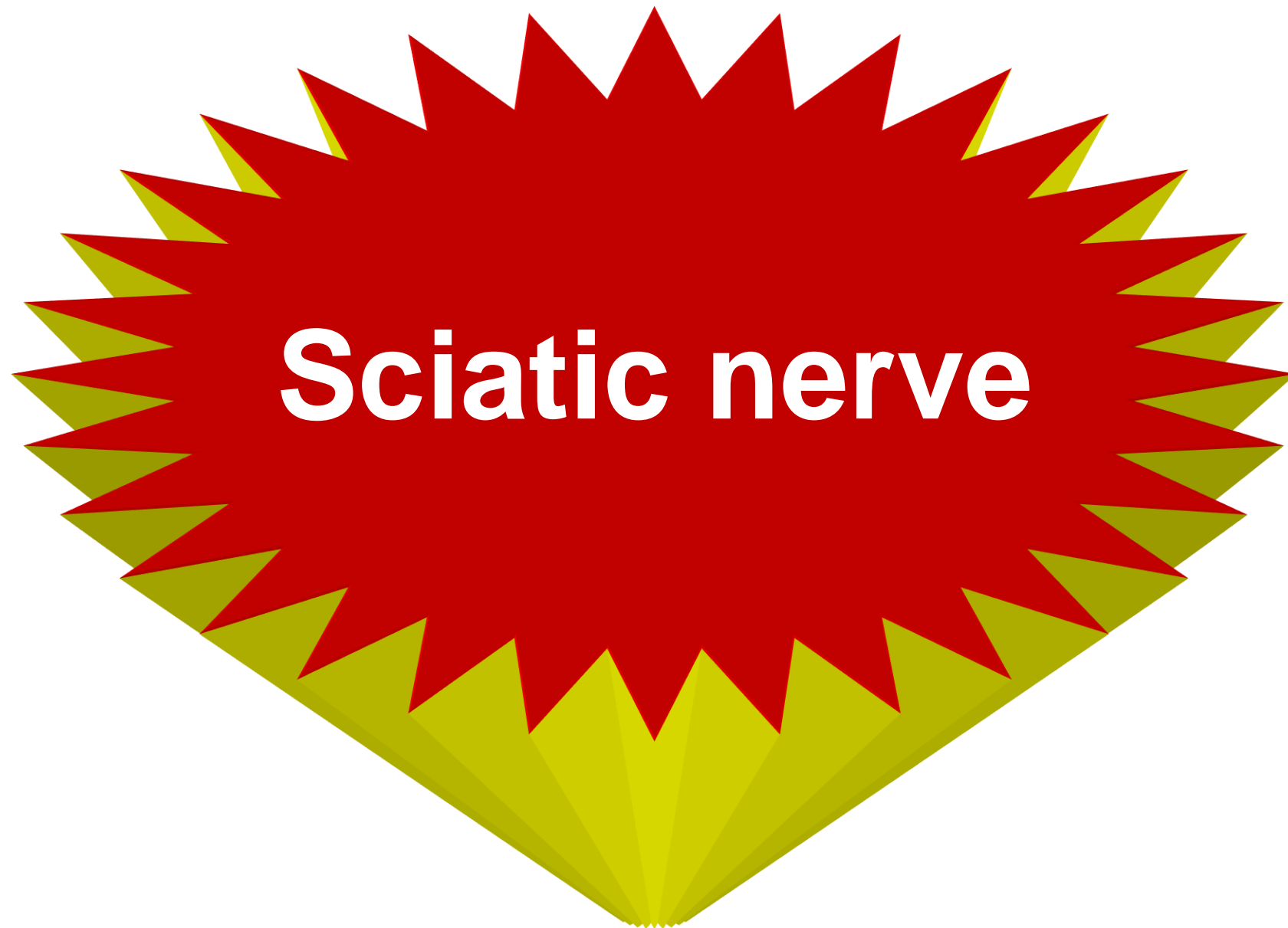- **It descends on** Superior gemellus muscle, Tendon of obturator internus muscle, Inferior gemellus muscle, Quadratus femoris muscle.

* **Branches:**

1- Gluteal branch to skin of lower part of the gluteal region.

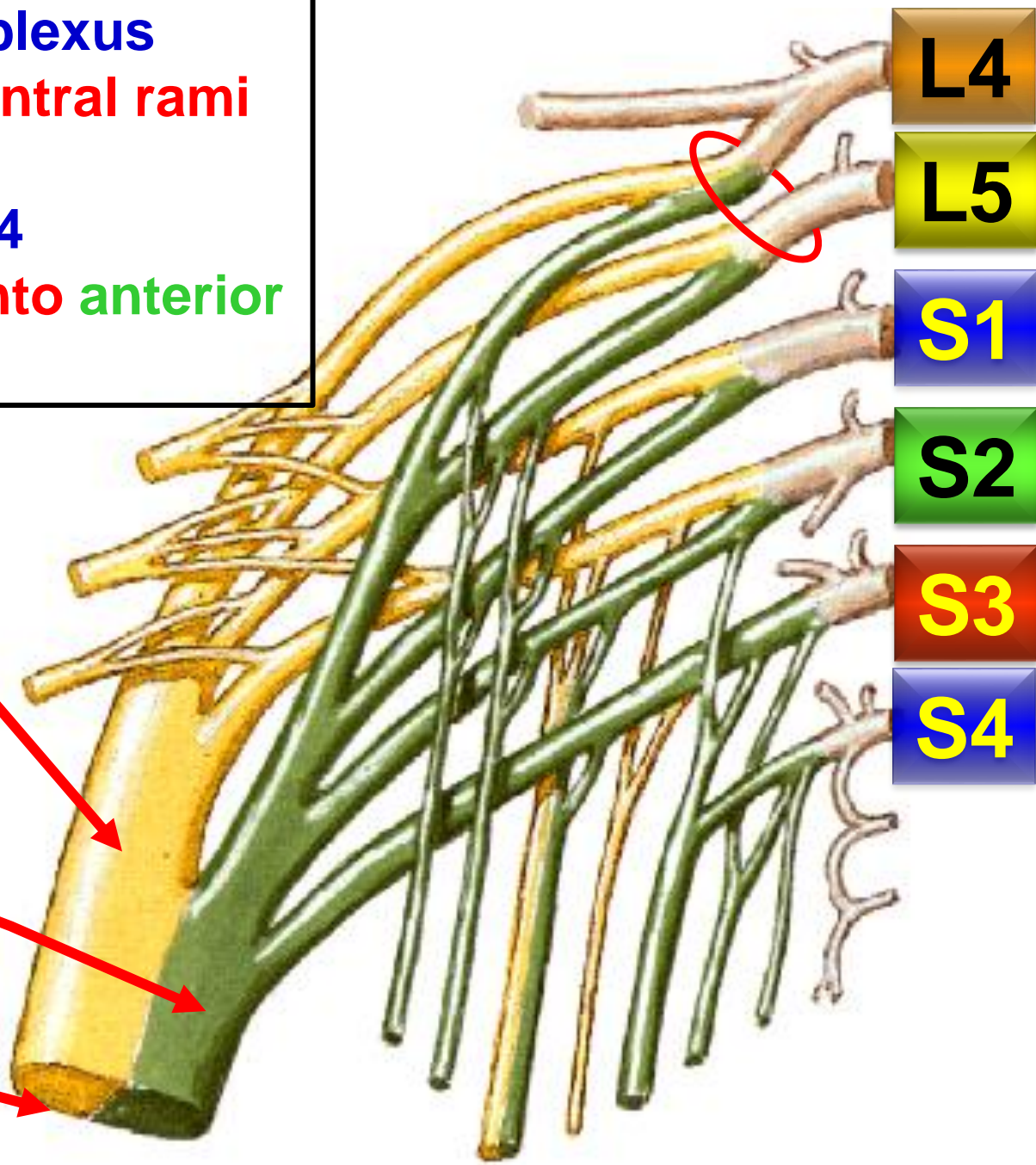
2- Perineal branch; to the skin of the perineum.

3- Cutaneous branches: to the back of the thigh, roof of the popliteal fossa and upper part of the calf.



<https://www.youtube.com/@ProfDrYoussefHusseinAnatomy/playlists>

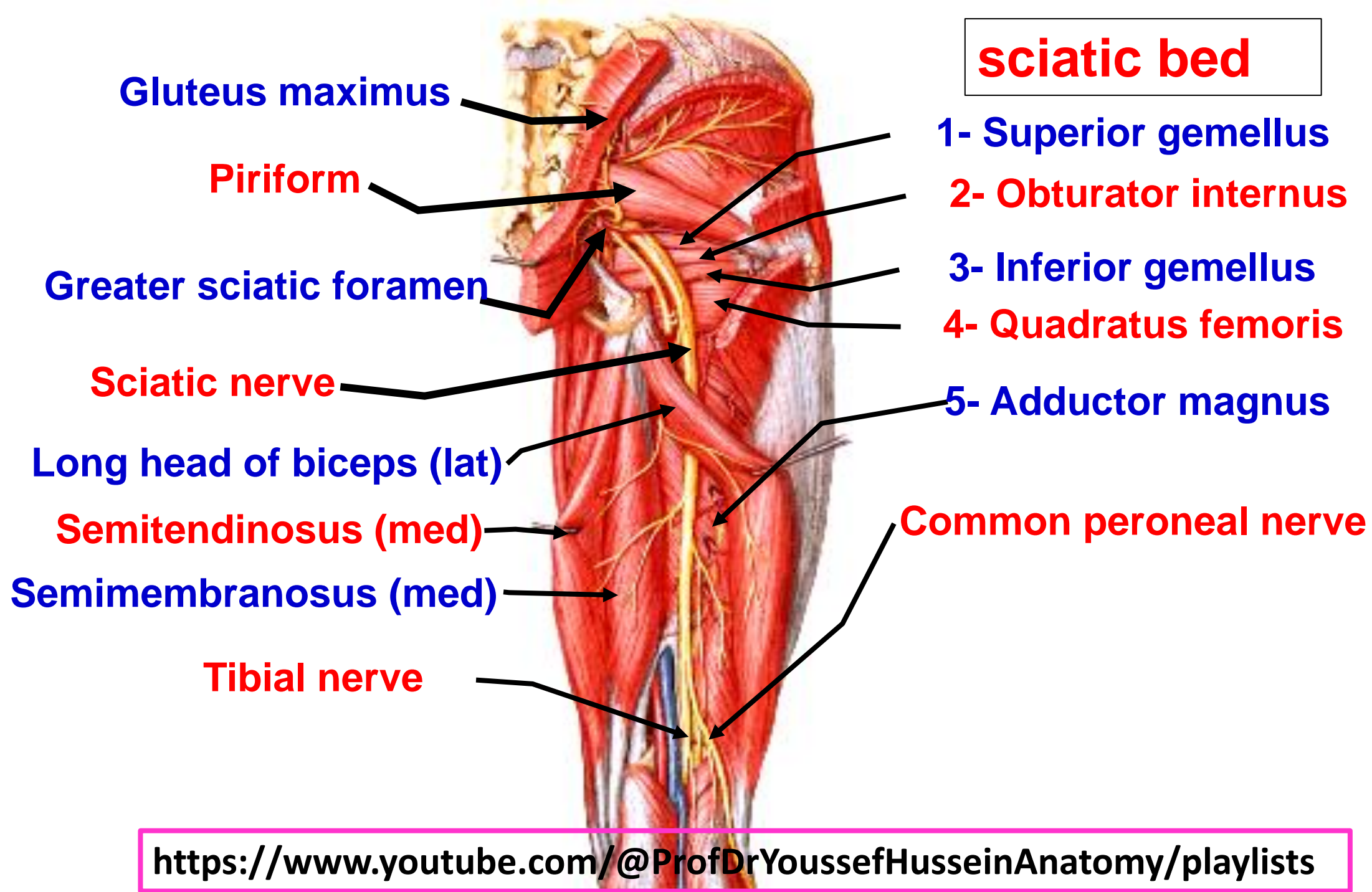
- **Roots of sacral plexus**
- **Lumbosacral trunk ventral rami of L.4,5**
- **Ventral rami S.1, 2, 3, 4**
- **Each ramus divided into anterior and posterior division**



Common peroneal (fibular) nerve L.4,5, S.1,2

Tibial nerve L.4,5, S.1,2,3

Sciatic nerve L.4,5, S.1,2,3



sciatic bed

Gluteus maximus

Piriform

Greater sciatic foramen

Sciatic nerve

Long head of biceps (lat)

Semitendinosus (med)

Semimembranosus (med)

Tibial nerve

1- Superior gemellus

2- Obturator internus

3- Inferior gemellus

4- Quadratus femoris

5- Adductor magnus

Common peroneal nerve

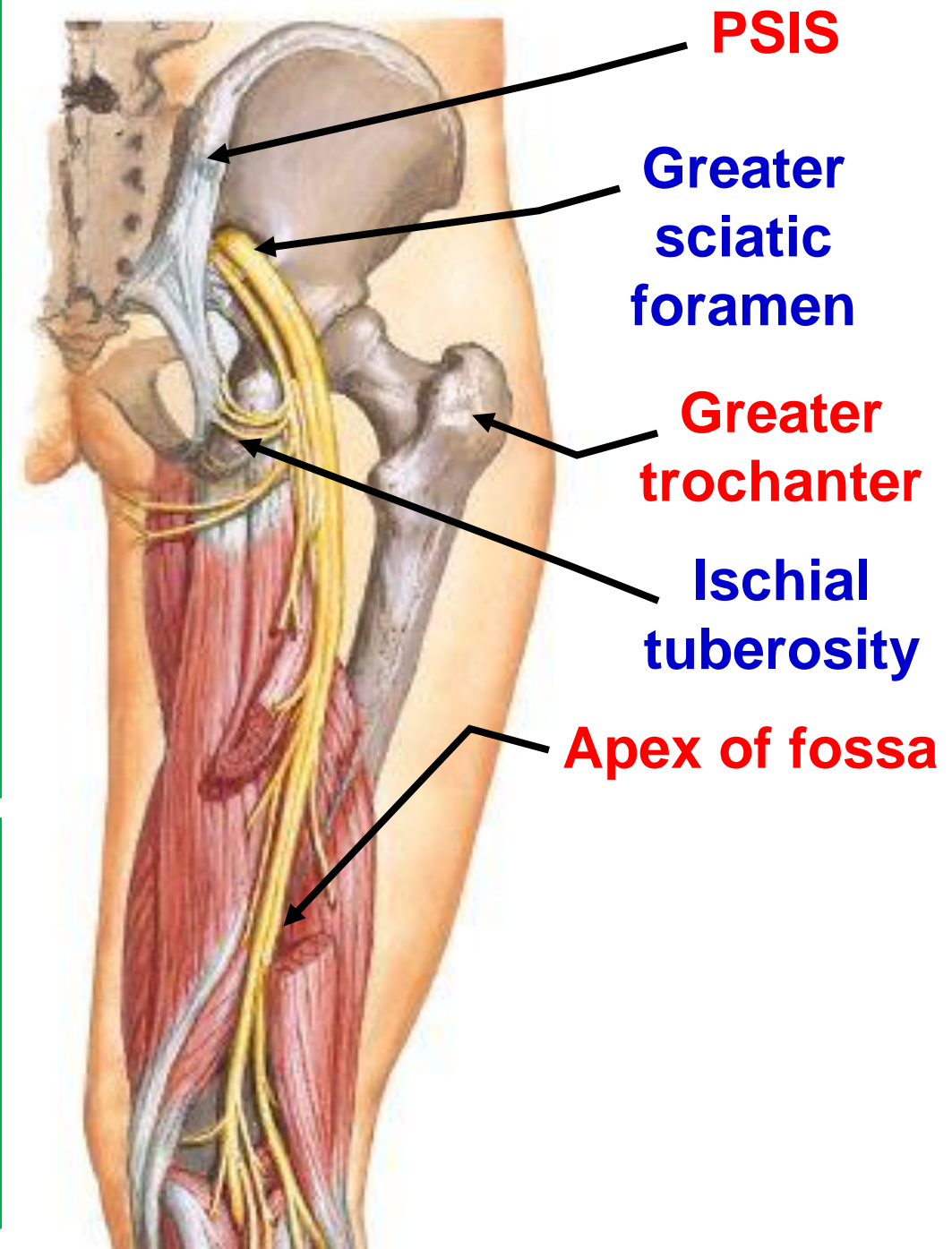
**** Surface marking of sciatic nerve**

1- A point at junction of upper 1/3 and lower 2/3 of a line between **posterior superior iliac spine** (PSIS) and **ischial tuberosity** (**Exit from greater sciatic foramen**).

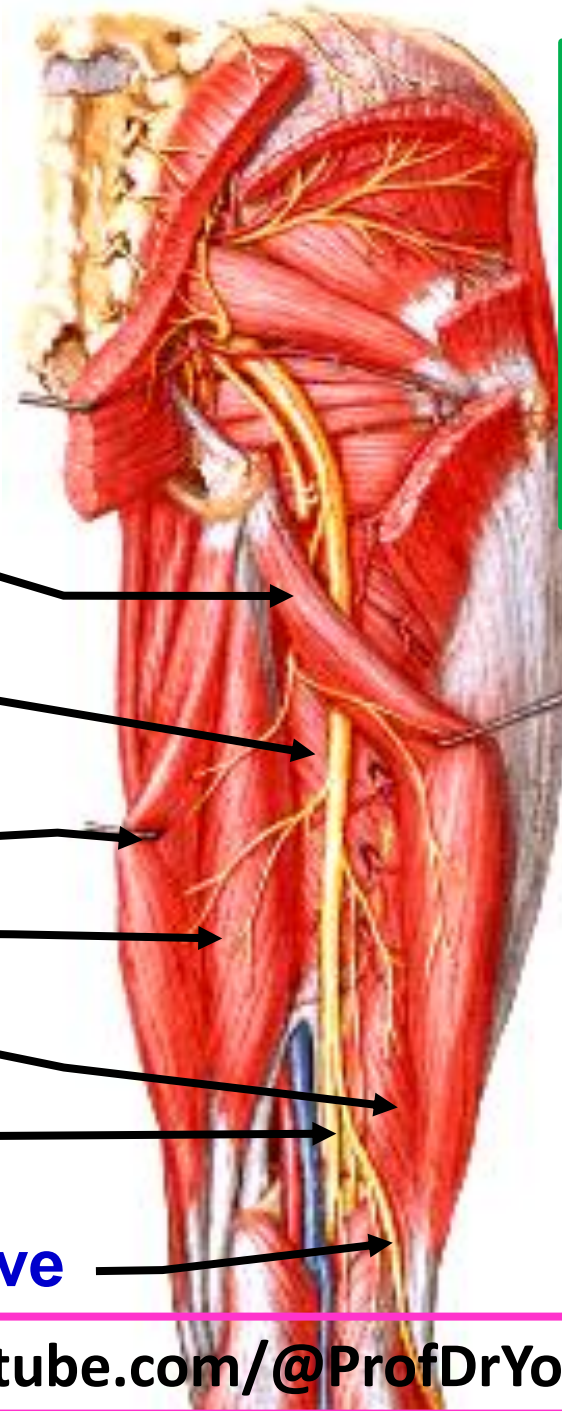
2- A point nearly **midway** between the **ischial tuberosity** and **greater trochanter**.

3- A point in the back of the thigh at the **apex of the popliteal fossa** where divided into tibial nerve and common peroneal nerve

**** During an above knee amputation**, The nerve is accompanied by an artery called **companion artery of sciatic nerve** (**a branch from inferior gluteal artery**). This artery must be ligated to avoid severe bleeding.



Branches of sciatic nerve



Long head of biceps

Ischial part of Adductor magnus

Semitendinosus

Semimembranosus

Short head of biceps

Tibial nerve

Common peroneal nerve

1- Muscular branches

2- Articular branches to the hip joint.

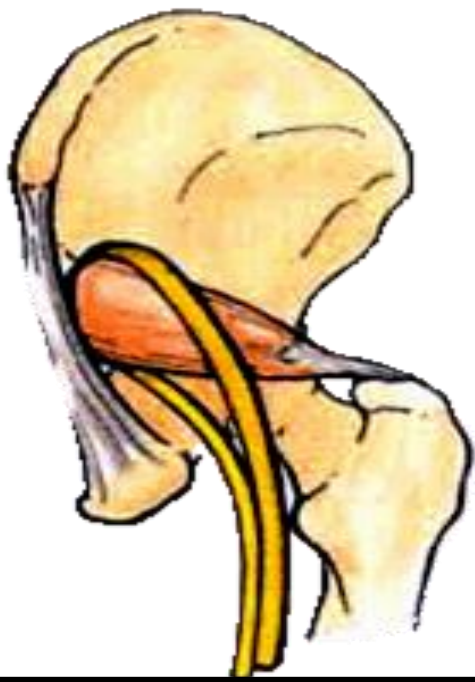
3- Terminal branches

1- Tibial nerve (medial).

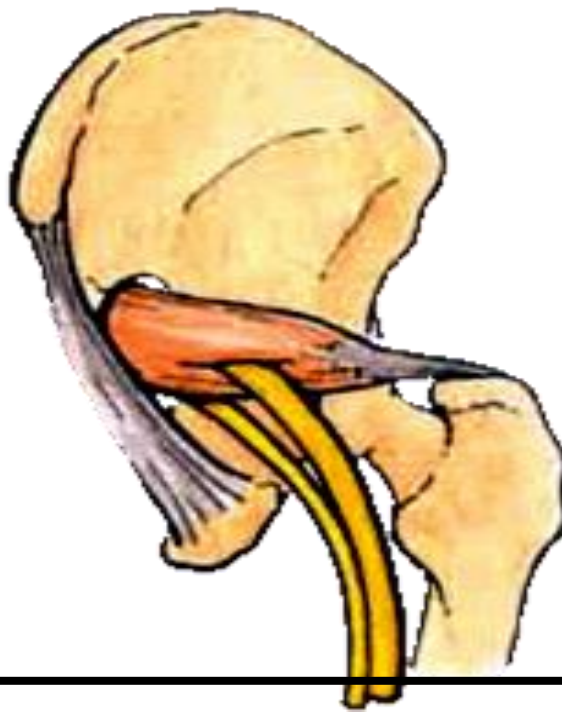
2- Common peroneal nerve (lateral).

**** During operation the nerve exposed from the lateral side** because all muscular branches arise from **medial side** except branch to the **short head of the biceps**.

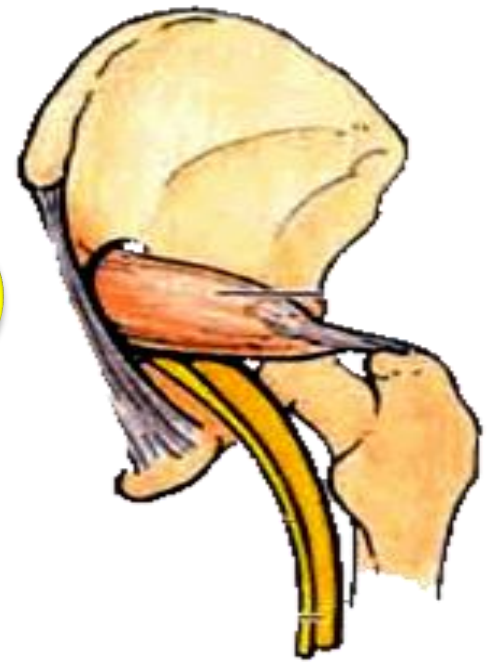1



2



3



**** Variation of the sciatic nerve:**

- The nerve may leave the pelvis as two separate parts:

a- Tibial nerve passes **below** the piriformis muscle and takes course of the sciatic nerve.

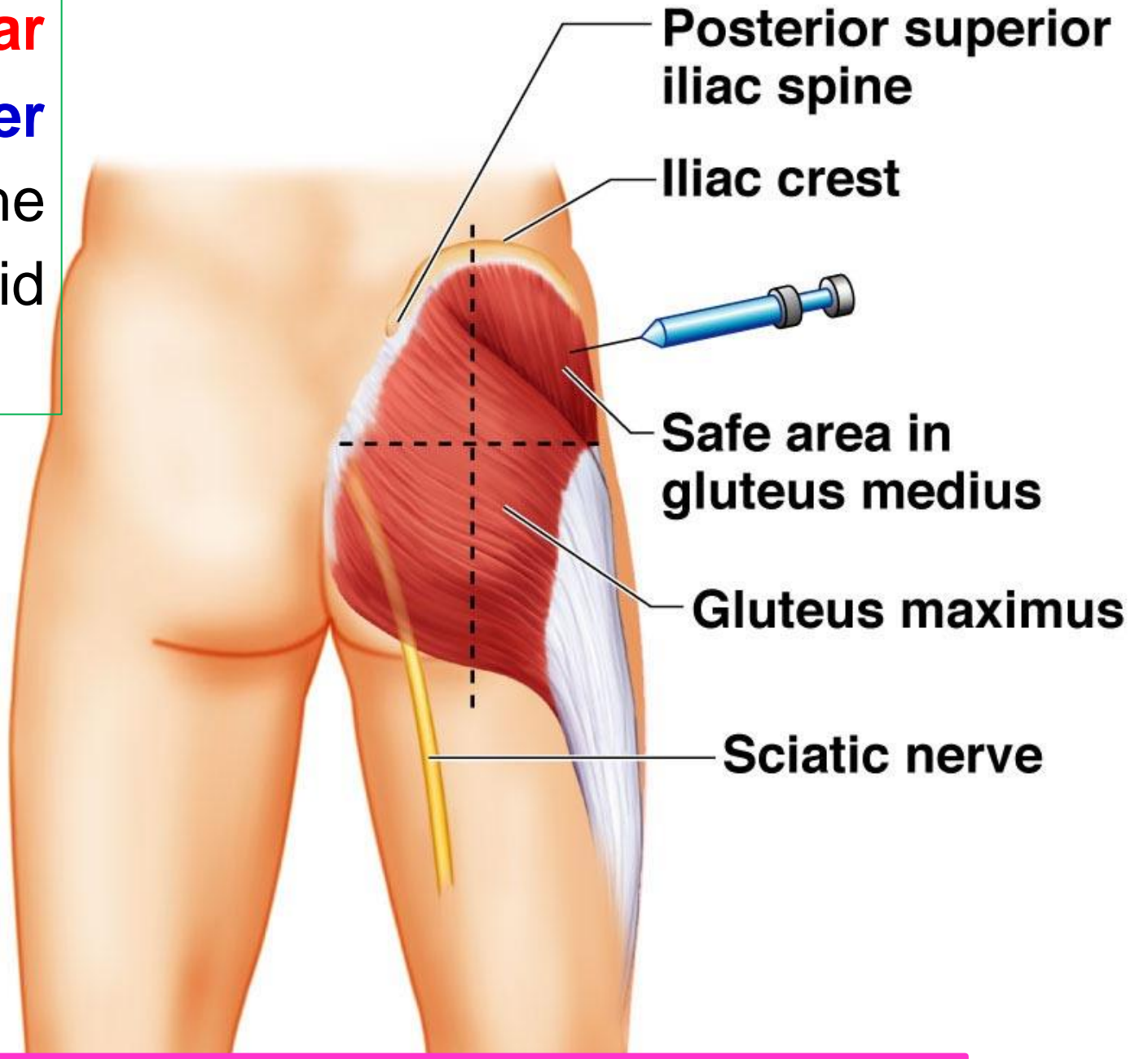
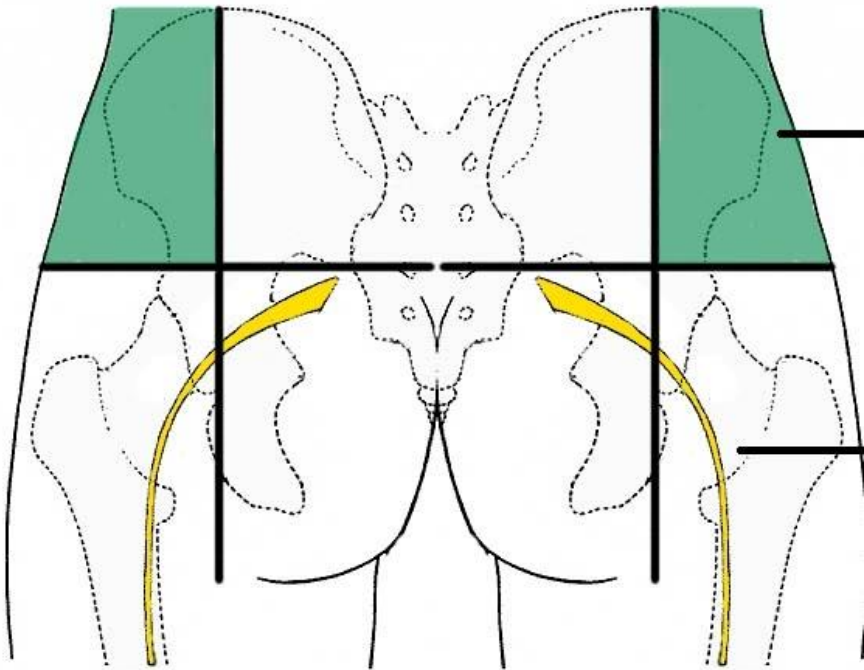
b- Common peroneal nerve passes **either**

1- Above the **piriformis** muscle.

2- Through the **piriformis** muscle.

3- Below the **piriformis** muscle..

**** Intramuscular Injections** in the **upper lateral quadrant** of the gluteal region to avoid Injection in **sciatic nerve**.



❖ **Sciatica** (a herniated disk that causes pressure on the nerve roots.)

- Sudden and severe pain in low back (lumbar)
- Pain radiates to buttock, down to back of leg and foot (along the nerve pathway) Sciatica usually affects only one leg at a time
- The pain vary widely, from a mild to sharp, burning sensation or severe pain.
- Sometimes it can feel like an electric shock.
- Numbness and tingling sensation along the nerve pathway
- Muscle weakness

❖ **Injury of the sciatic nerve**

1- Motor; foot drop (resulting from the effect of gravity)

a- Paralysis of the hamstring muscles.

c- Complete paralysis of all muscles of the leg and foot.

2- Sensory; Loss of cutaneous sensations of the leg and foot except

a- **Medial** side of leg and foot supplied by **saphenous** nerve (femoral N).

b- Upper part of calf supplied by **posterior cutaneous nerve** of the thigh.

<https://www.youtube.com/@ProfDrYoussefHusseinAnatomy/playlists>



Tibial nerve

[Prof. Dr. Youssef Hussein Anatomy - YouTube](#)

• Tibial Nerve

**** Origin:** one (larger) of the two terminal branches of the sciatic nerve.

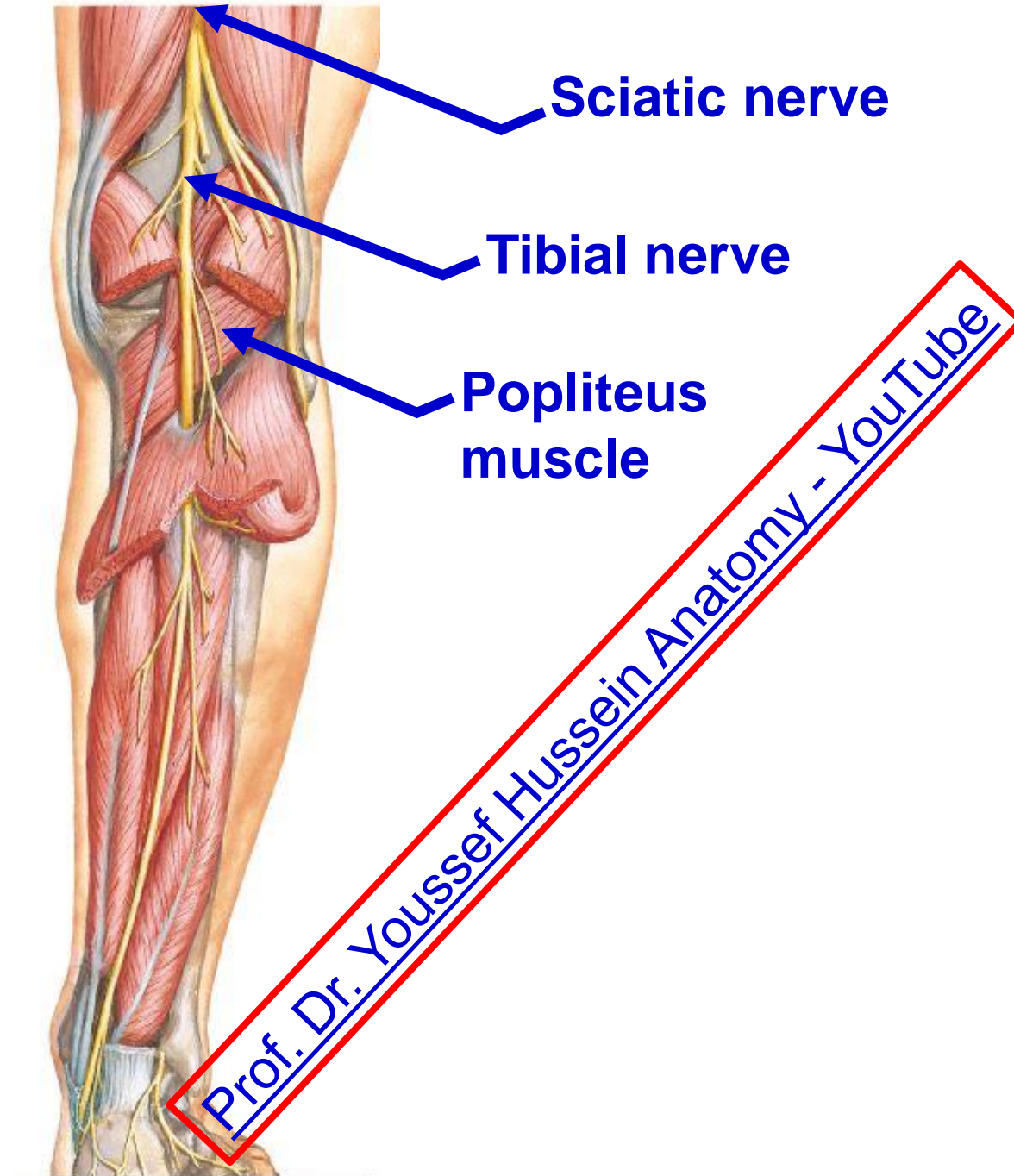
**** Roots:** L. 4, 5, S. 1, 2,3

**** Course:**

- It **enters** the popliteal fossa at its upper angle and **leaves** it at its lower angle.

- It passes **superficial** to popliteus muscles

**** Ends:** At the distal border of popliteus (floor of popliteal fossa) and continues as **posterior tibial nerve**.



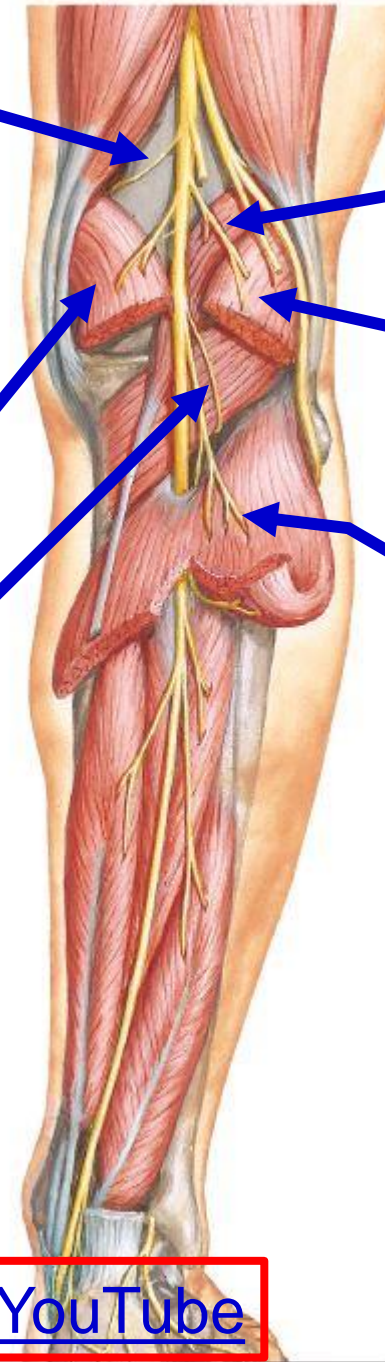
- **Articular branches**

- 1- **Superior medial genicular** nerve.
- 2- **Middle genicular nerve** (supply the cruciate ligaments).
- 3- **Inferior medial genicular** nerve.

Medial head of gastrocnemius

Popliteus (The nerve descends superficial to the muscle and then hooks on its lower border to supply the muscle **through its deep surface**).

[Prof. Dr. Youssef Hussein Anatomy - YouTube](#)

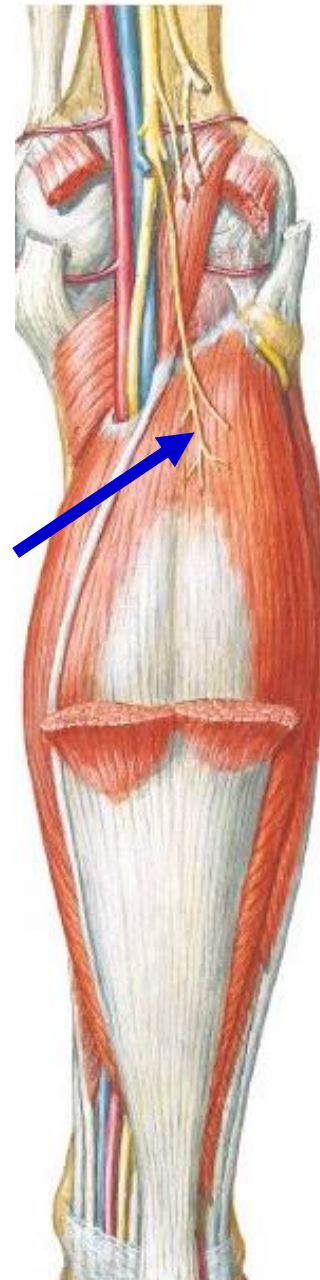

Plantaris

Lateral head of gastrocnemius

Soleus supplies the muscle through its posterior surface

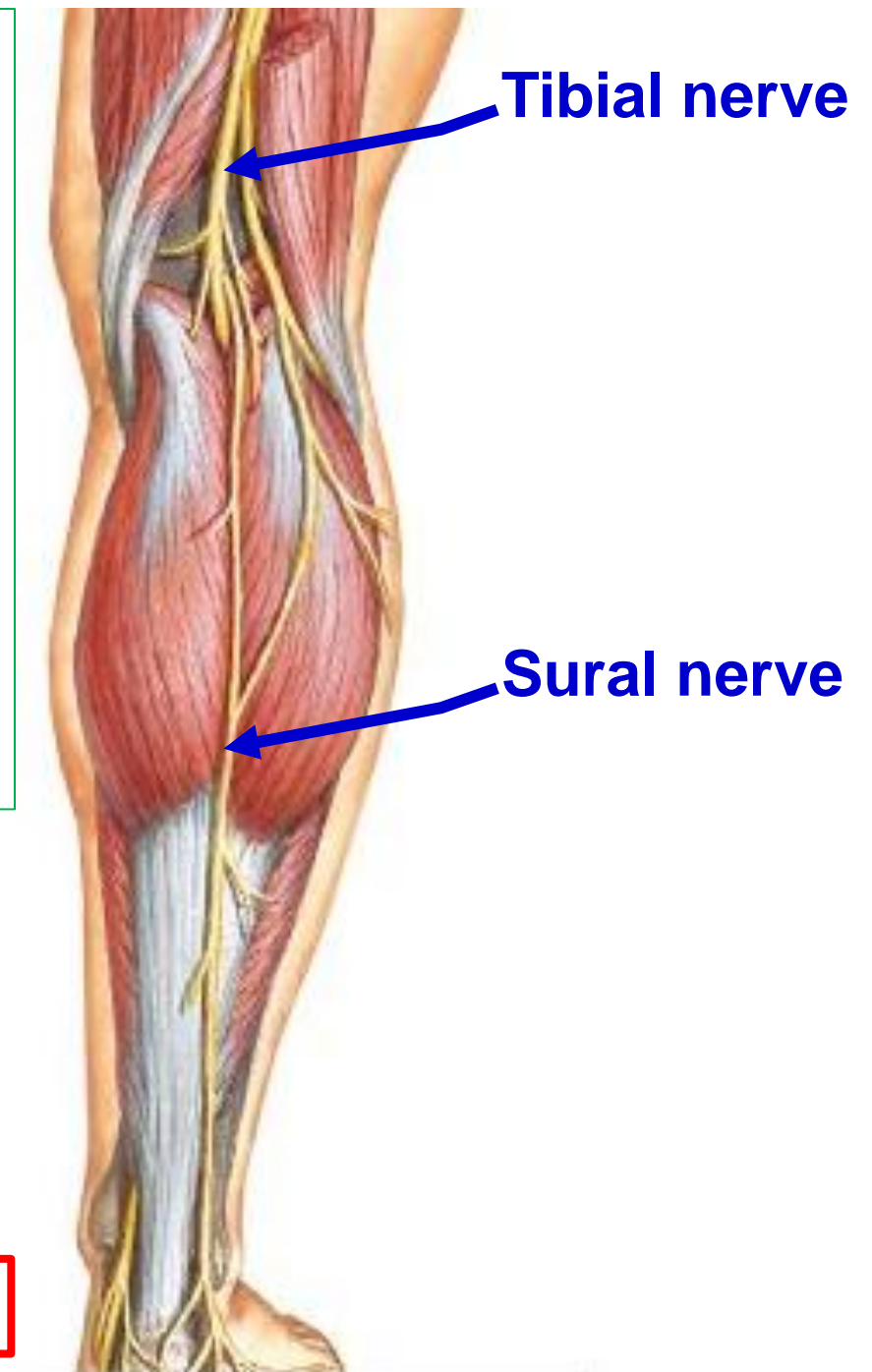
❖ **Muscular branches**



- **Cutaneous branch of tibial nerve**

- **Sural nerve**

- It descends in the back of the leg.
- It curves **behind and below the lateral malleolus** to continue forwards along the lateral border of the dorsum of the foot to **end in the lateral side of the little toe**.
- **It supplies** the back of the leg, lateral border of the foot and lateral side of the little toe.



dr_youssefhussein@yahoo.com

dr_youssefhussein@yahoo.com



Common peroneal nerve

<https://www.youtube.com/@ProfDrYoussefHusseinAnatomy/playlists>

- **Common Peroneal Nerve**

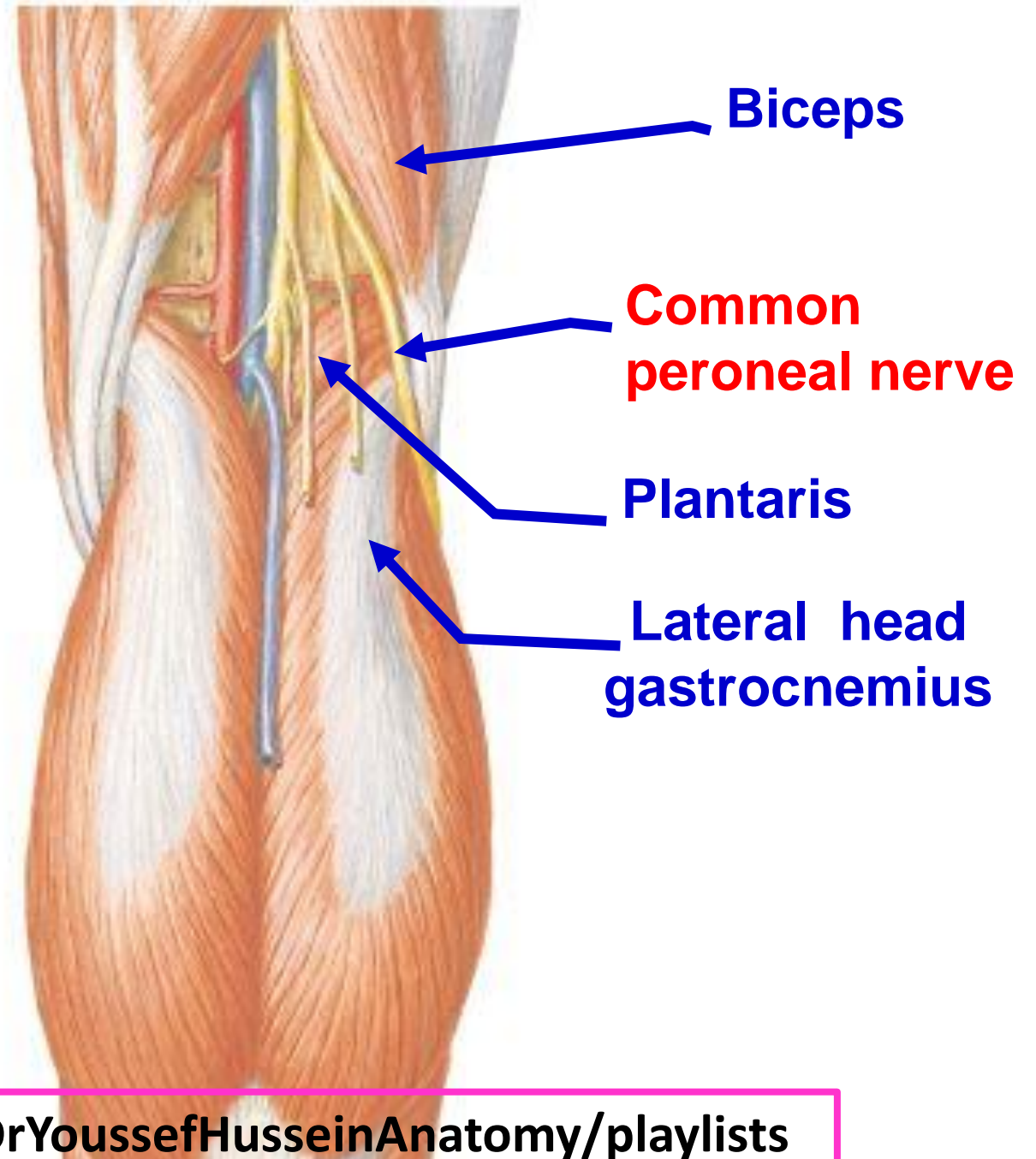
**** Origin:** one of the two terminal branches of the sciatic nerve (Smaller).

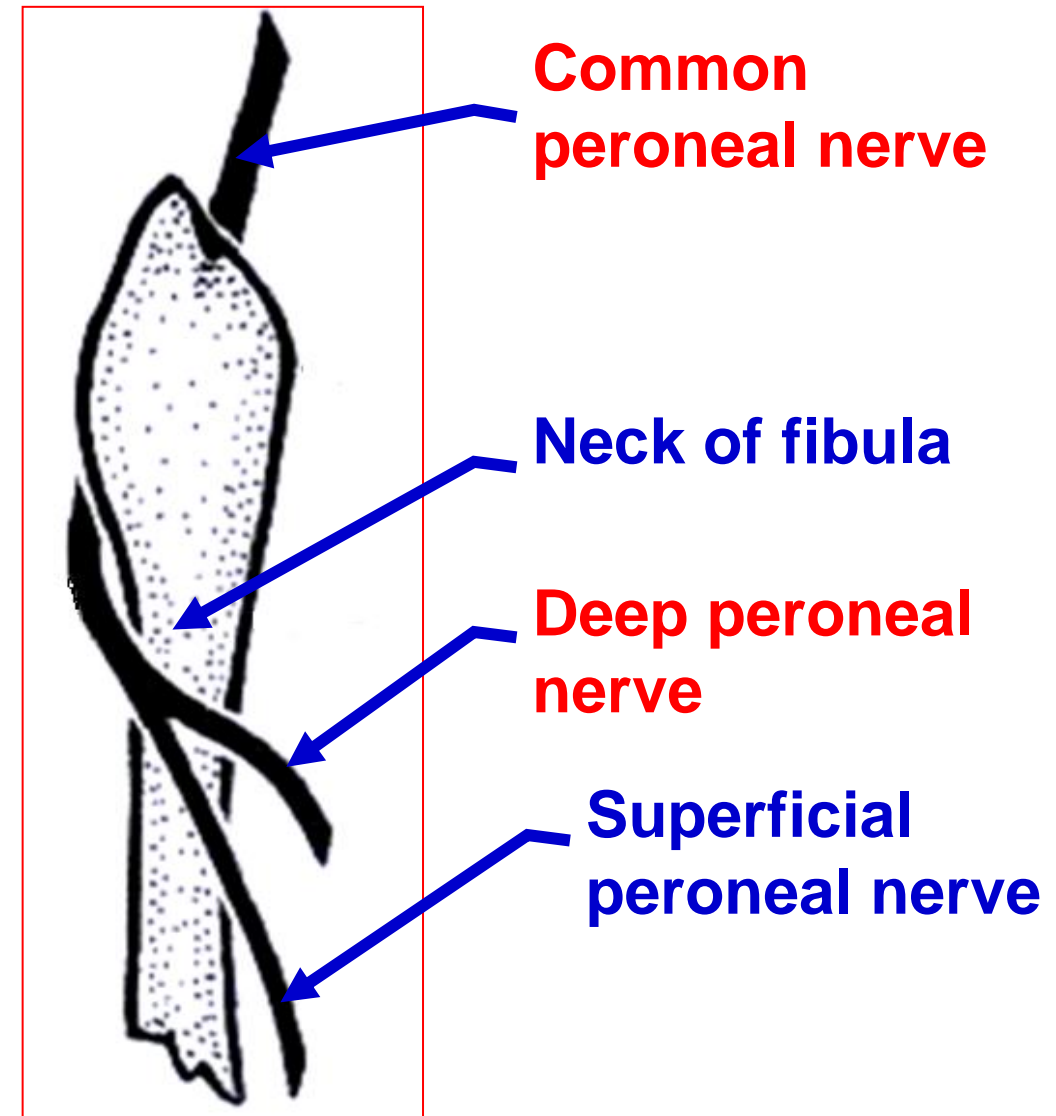
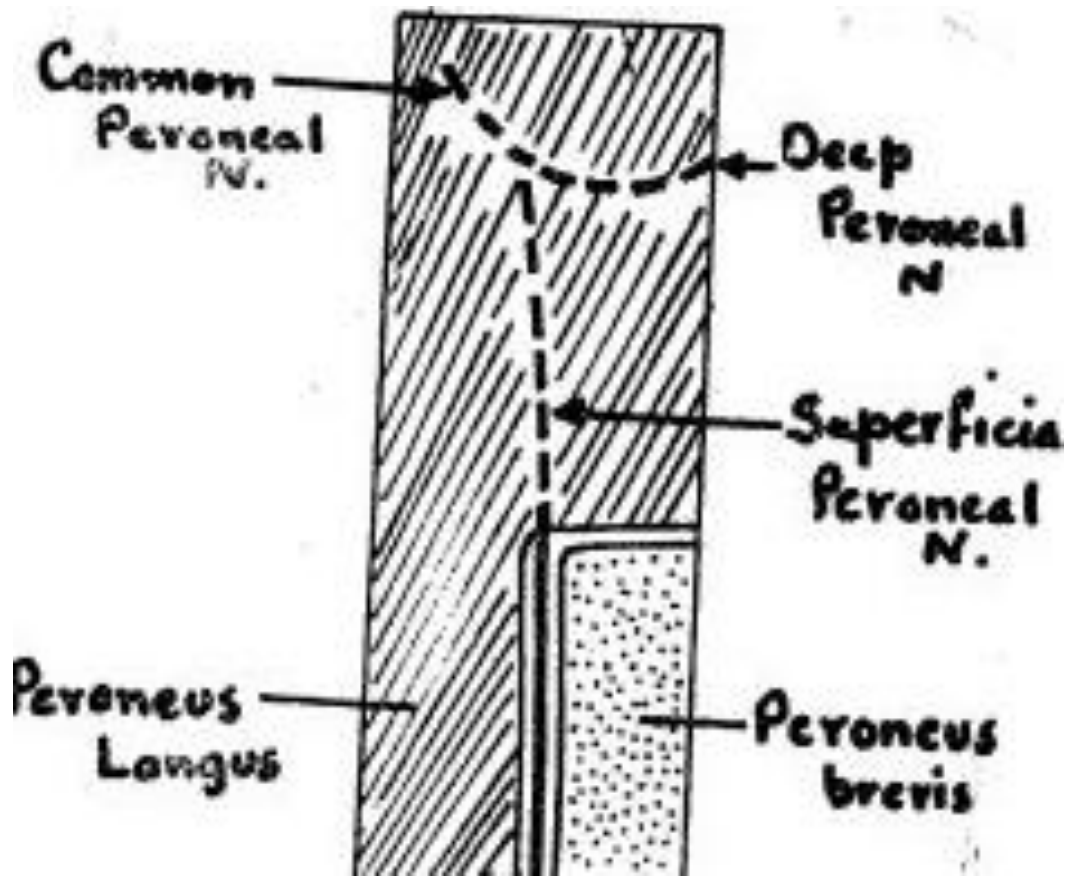
**** Roots:** It arises from **L. 4, 5, S. 1, 2**

**** Course;**

- **It enters the popliteal fossa** at its upper angle and descends downwards and laterally close to the medial side of the biceps femoris.

- **It leaves the fossa** through its lateral angle where it crosses plantaris and lateral head of gastrocnemius.





- **Ends:** it curves on the lateral side of the **neck of the fibula** (the commonest site of injury) then, divides into deep and superficial peroneal nerves, inside the peroneus longus,

<https://www.youtube.com/@ProfDrYoussefHusseinAnatomy/playlists>

**** Branches of Common Peroneal Nerve**

I- No muscular branches in the popliteal fossa.

II- Articular branches to the knee joint.

1- **Superior lateral genicular nerve.**

2- **Inferior lateral genicular nerve.**

3- **Recurrent genicular nerve.**

III- Cutaneous branches:

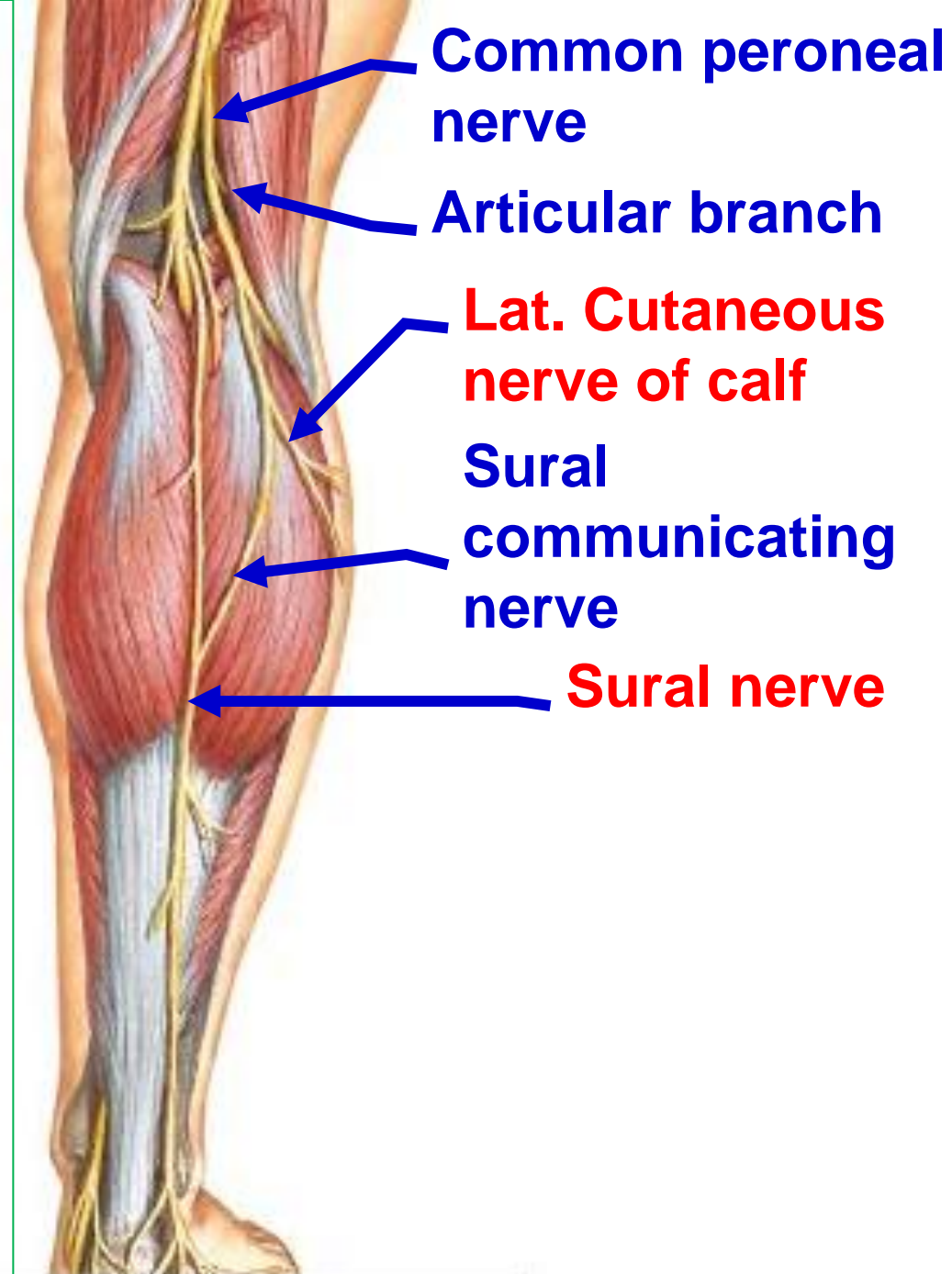
a. Lateral cutaneous nerve of the calf; supplies the skin of the lateral, and anterior surfaces of the **upper part of the leg.**

b- Sural communicating nerve.

IV- Terminal branches:

1- Deep peroneal (anterior tibial) nerve to the **anterior compartment** of the leg.


2- Superficial peroneal (musculocutaneous) nerve to the **lateral compartment** of the leg.



https://www.youtube.com/channel/UCVSNqbibj9UWYaJdd_cn0PQ

يُمنع أخذ السلايدات بدون
إذن المحرر واي اجراء
يخالف ذلك يقع تحت
طائلة المسؤولية القانونية

اليوتيوب د. يوسف حسين



<https://www.youtube.com/@ProfDrYoussefHusseinAnatomy/playlists>