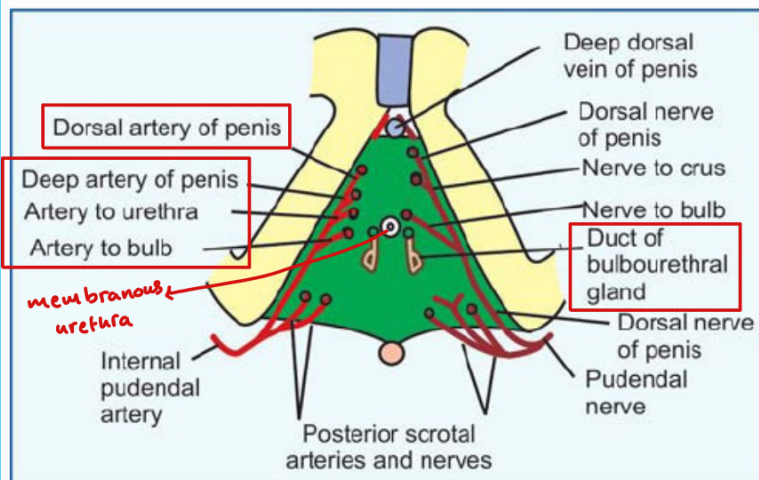


The structures piercing the perineal membrane

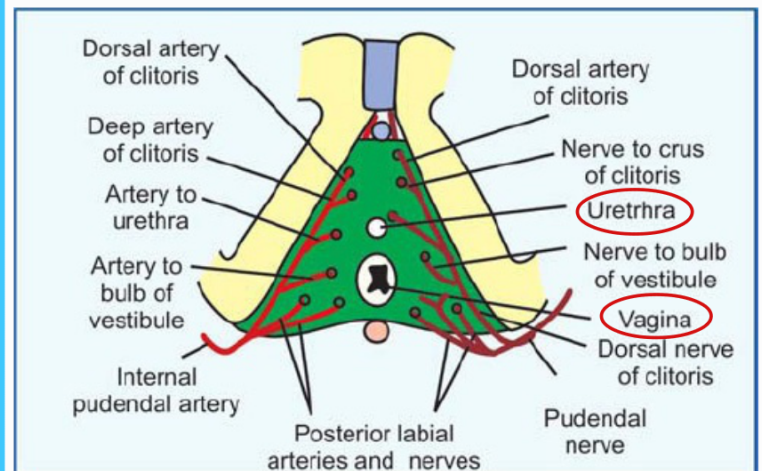
In male

- 1- Membranous Urethra.
- 2- Ducts of the bulbo-urethral glands
- 3- Artery of the urethra.
- 4- Artery of the bulb
- 5- Deep artery of the penis.
- 6- Dorsal artery of the penis.
- 7- Dorsal nerve of the penis



In female

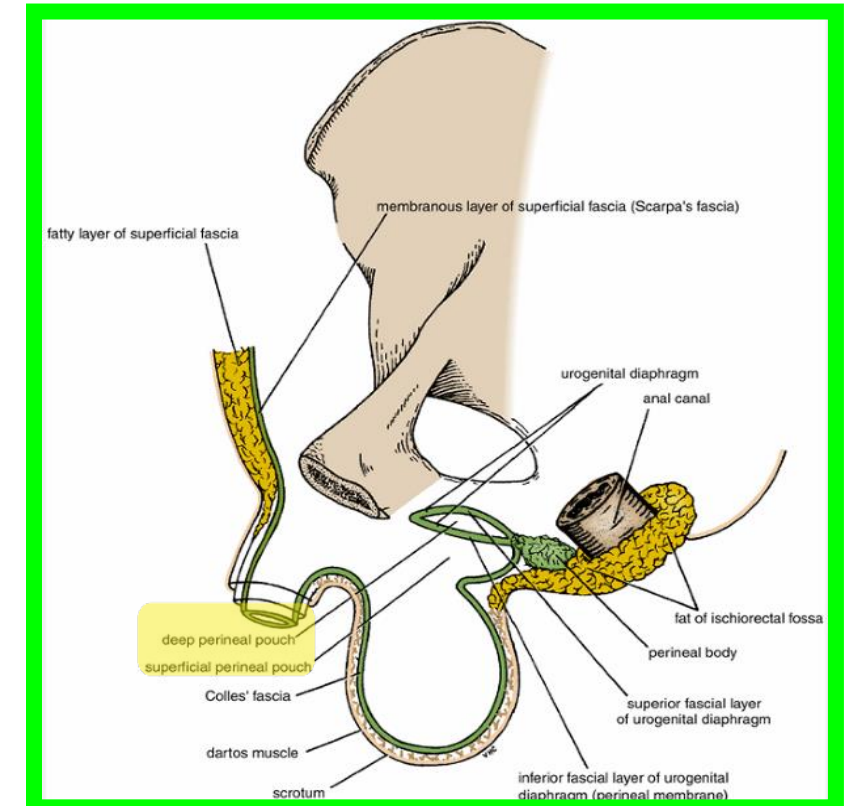
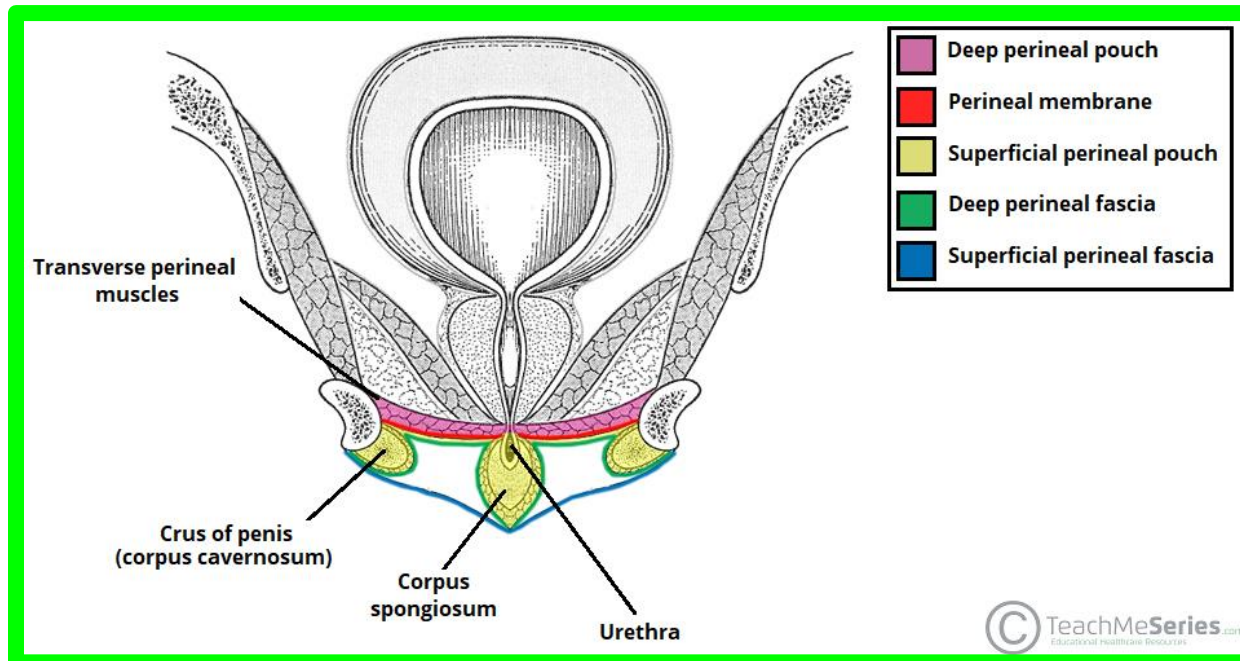
- 1- Urethra
- 2- Vagina behind the urethra.
- 3- Artery of the urethra.
- 4- Artery of the bulb
- 5- Deep artery of the clitoris.
- 6- Dorsal artery of the clitoris.
- 7- Dorsal nerve of the clitoris.



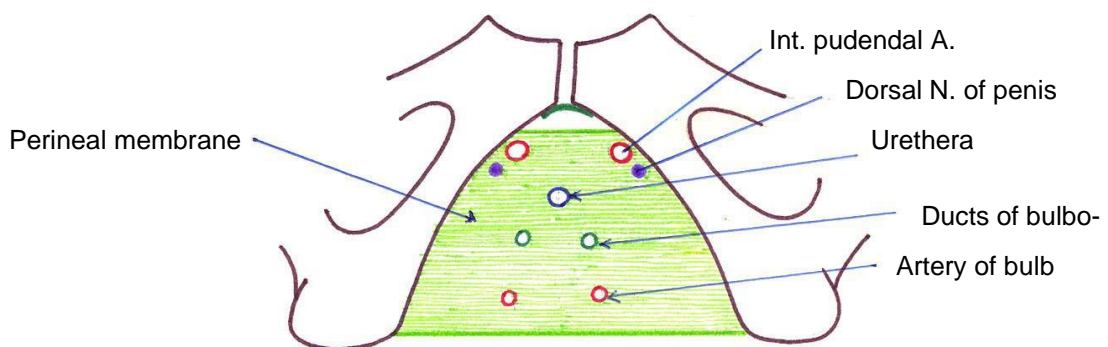
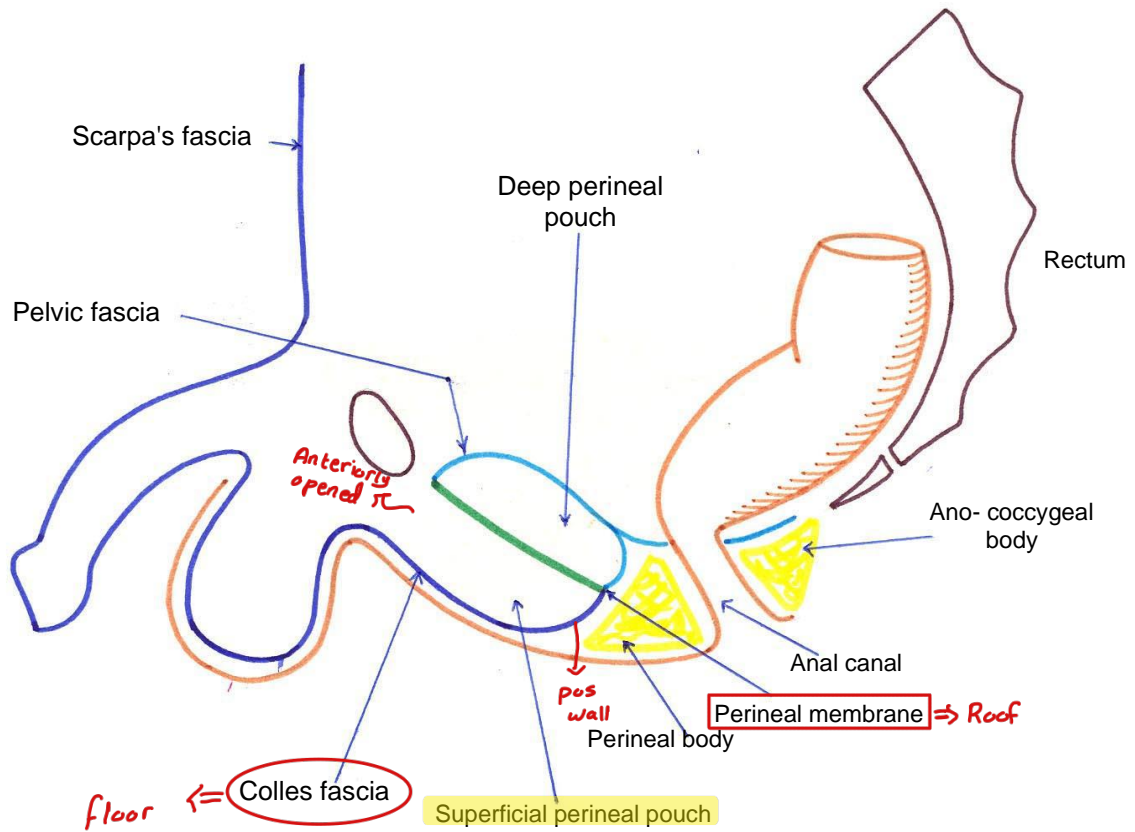
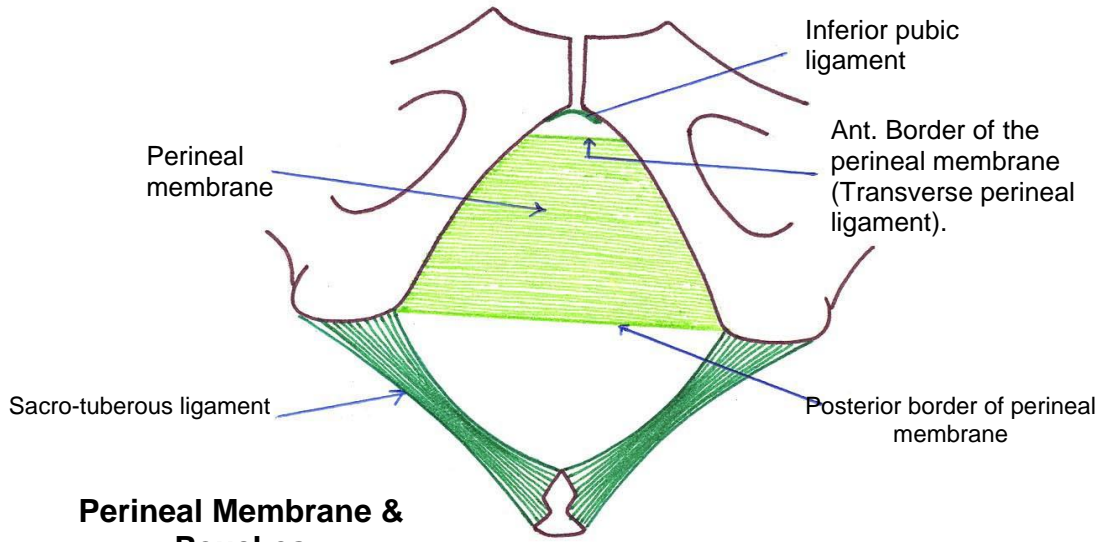
• Superficial Perineal Pouch

** Boundaries

- 1- **Floor:** membranous layer of superficial fascia (**Colle's fascia**).
- 2- **Roof:** perineal membrane.
- 3- **On each side:** pubic arch.
- 4- **Posteriorly:** closed by the attachment of the roof and floor.
- 5- **Anteriorly:** opened.



Perineum

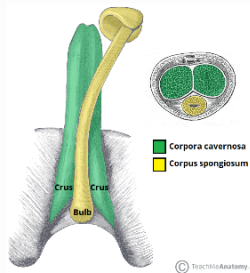


Structures piercing the perineal membrane in male

Contents of Superficial Perineal Pouch

In male

- **Root of the penis**
1. **Bulb of the penis:** is the posterior part of the corpus spongiosum.
 2. **2 Crura of the penis:** is the posterior part of the corpus cavernosum.
 3. **Penile urethra inside the bulb of the penis.**



In female

- **Root of the clitoris.**
- **Vestibule of the vagina and greater vestibular glands**

- **Superficial perineal muscles (right and left)**

- **Superficial transversus perinei muscles**

Action: fixation of the perineal body.

- **Bulbospongiosus muscles**

Action → Empty the urethra (contract at the end of micturition or ejaculation).

- **Ischio-cavernosus muscles.**

Action, maintain erection of the penis.

- **Superficial perineal muscles (right and left)**

- **Superficial transversus perinei muscles**

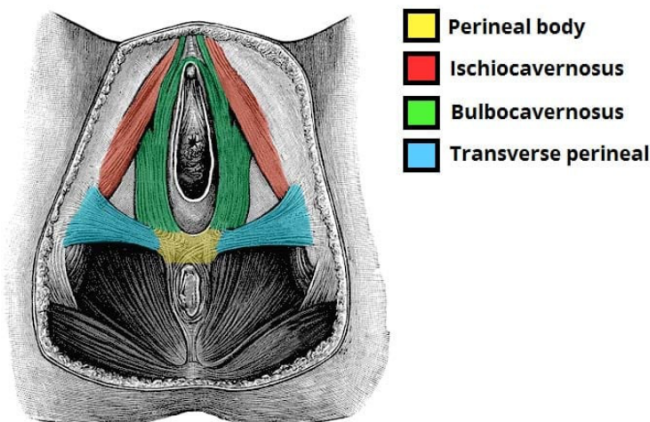
Action: fixation of the perineal body.

- **Bulbospongiosus muscles**

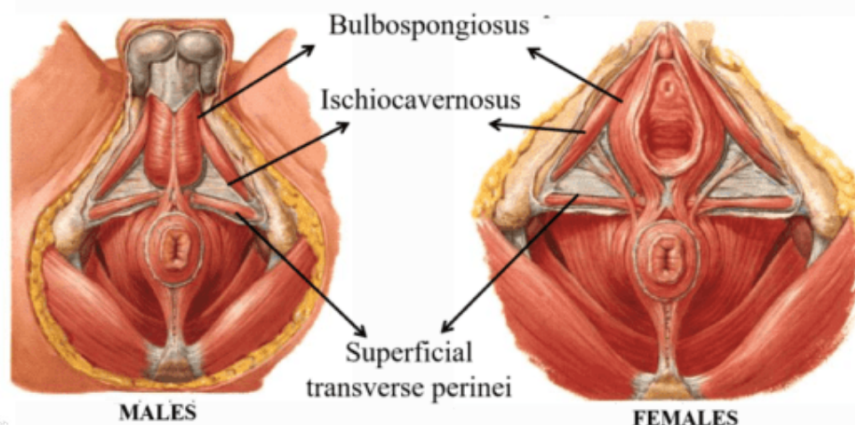
Action: Empty the urethra (contract at the end of micturition).

- **Ischio-cavernosus muscles.**

Action, maintain erection of the clitoris.



Muscles in Superficial Perineal Pouch

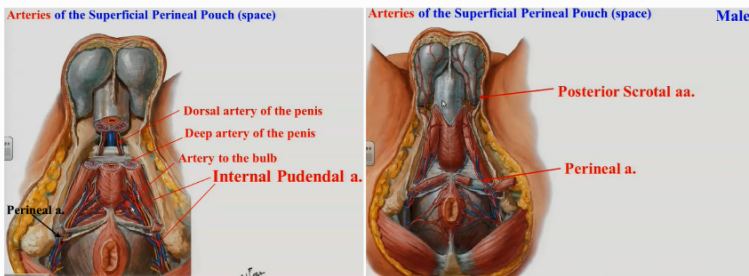


Contents of Superficial Perineal Pouch

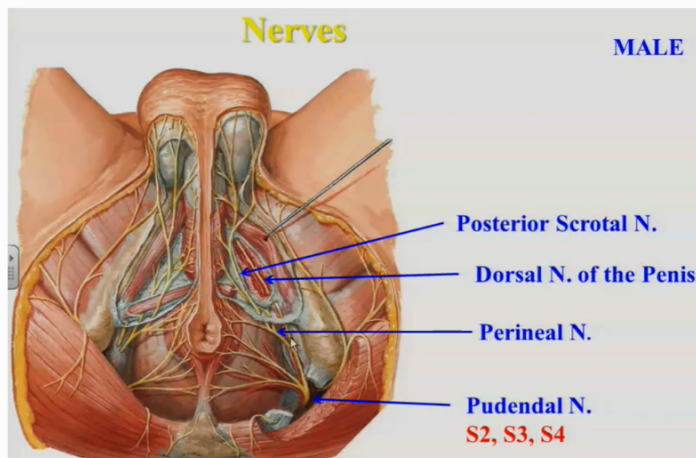
In male

• Nerves and vessels

1. **Posterior scrotal** from the perineal branch of the internal pudendal artery.
2. **Deep artery of the penis** one of the two terminal branch of internal pudendal artery.
3. **Dorsal artery of the penis** one of the two terminal branch of internal pudendal artery.
4. **Artery of the bulb of the penis** .



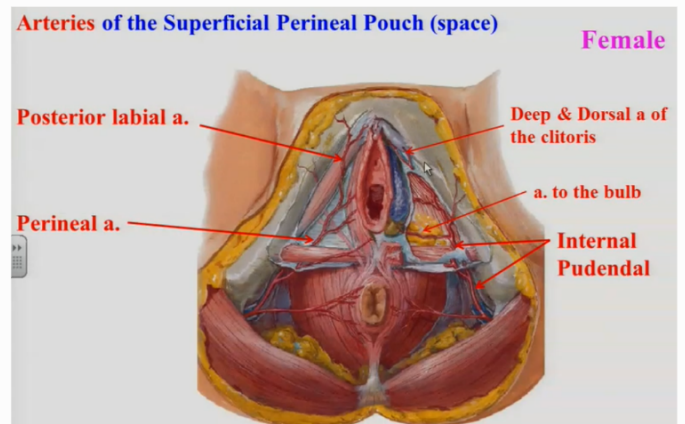
1. **Posterior scrotal nerves.**
They arise from the perineal branch of pudendal nerve to the scrotum .
- 2- **Dorsal nerve of the penis :**
one of the two terminal branch of pudendal nerve .



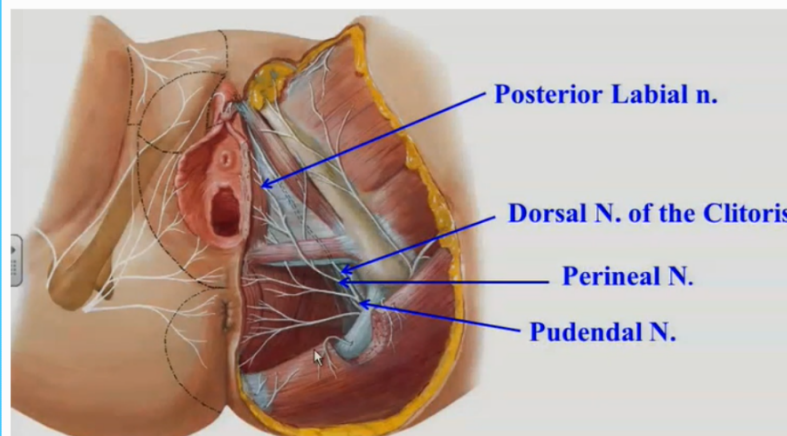
In female

• Nerves and vessels

1. **Posterior labial artery**, from the perineal branch of the internal pudendal artery.
2. **Deep artery of the clitoris** one of the two terminal branch of internal pudendal artery.
3. **Dorsal artery of the clitoris** one of the two terminal branch of internal pudendal artery.
4. **Artery of the bulb of vestibule of the vagina** .



1. **Posterior labial nerve :** Arise from the perineal branch of pudendal nerve to the labia majora
2. **Dorsal nerve of the clitoris:** one of the two terminal branch of pudendal nerve .

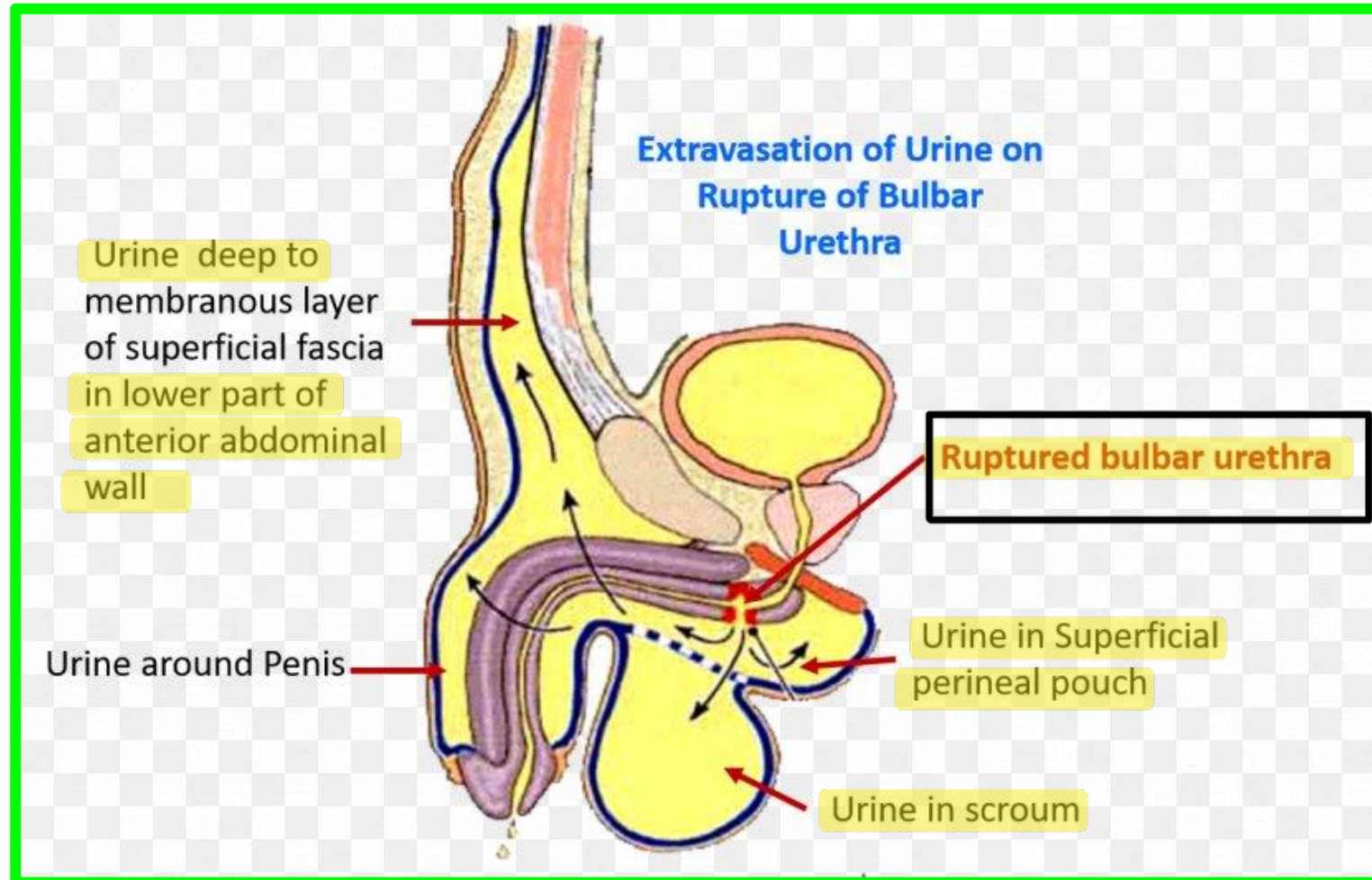


• Superficial Perineal Pouch

- **Superficial perineal pouch** is opened anteriorly where it is continuous with the space deep to the membranous layer of the superficial fascia of the anterior abdominal wall.

Rupture of the urethra leading to extravasations of urine into the superficial perineal pouch → to the anterior abdominal wall.

The urine also desends to the front of the thigh till the fusion of membranous layer of superficial fascia with the deep fascia.

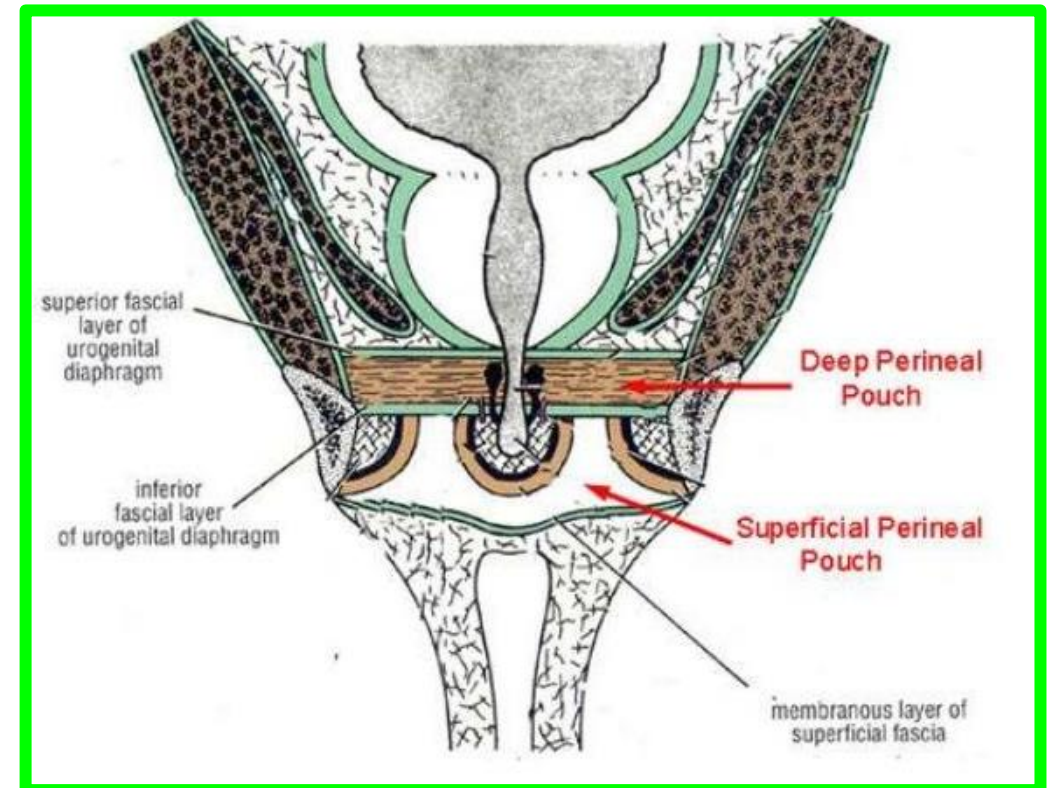
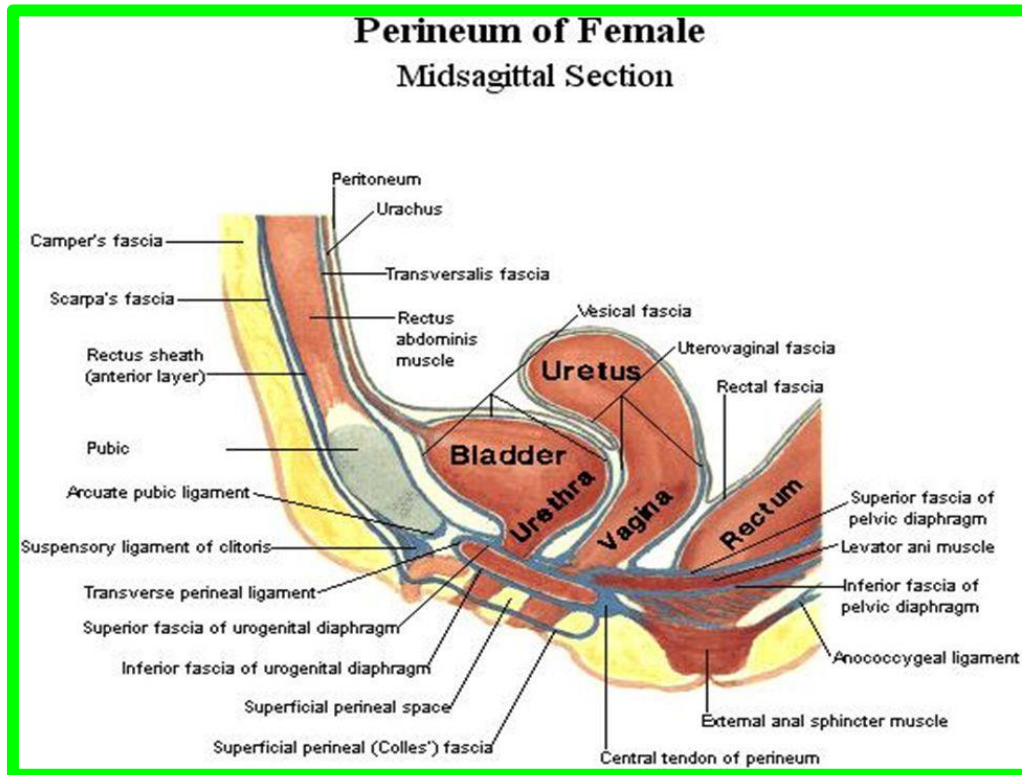


• Deep Perineal pouch

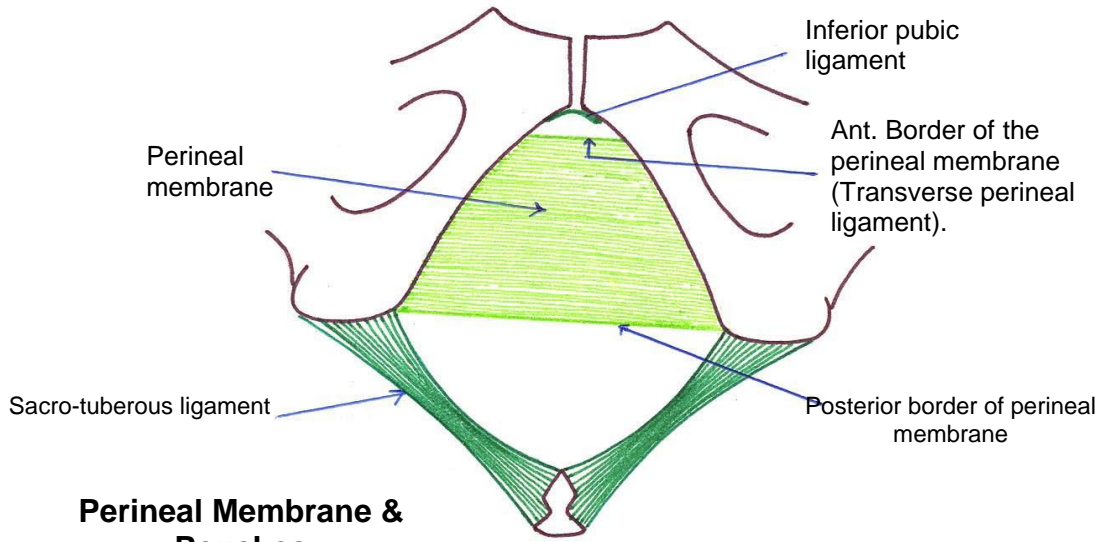
→ Closed space

** Boundaries

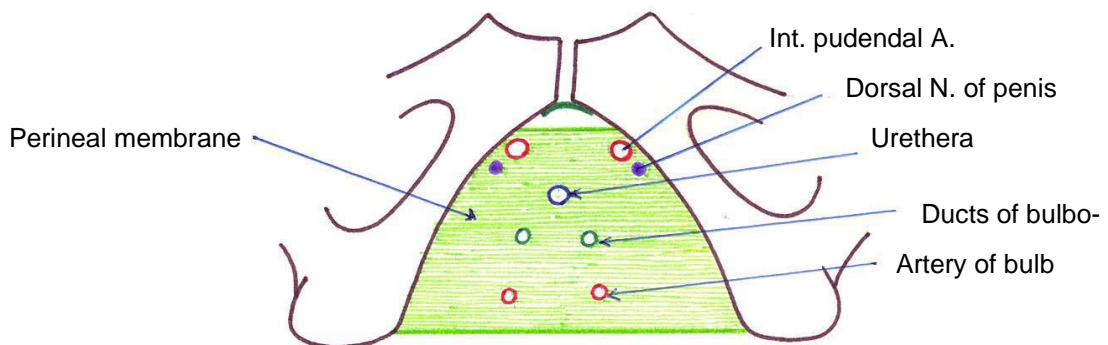
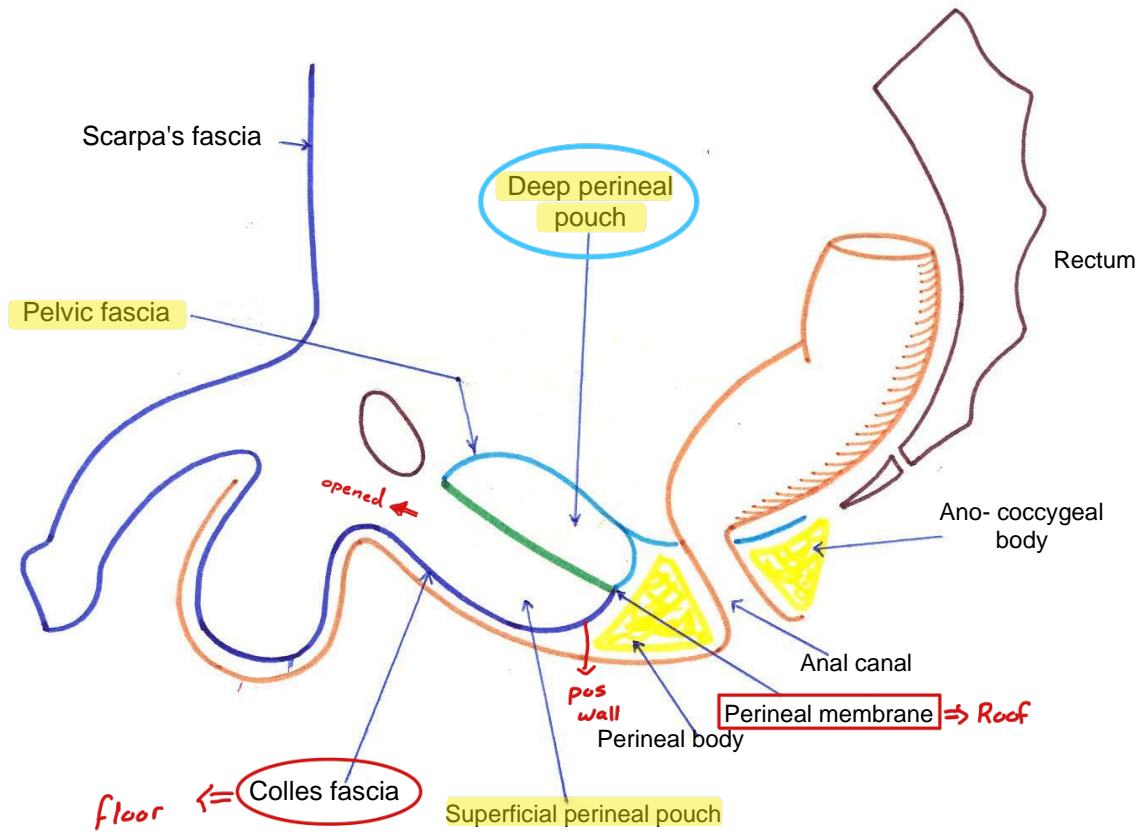
- 1- **Roof:** superior fascia of the pelvic diaphragm.
- 2- **Floor:** perineal membrane (inferior fascia of the pelvic diaphragm).
- 3- **On each side:** pubic arch.
- 4- **Anteriorly and posteriorly:** closed by the fusion of the roof and floor.



Perineum



Perineal Membrane & Pouches

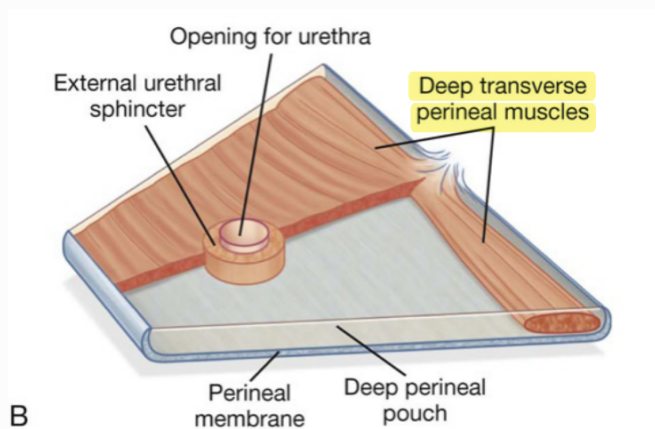


Structures piercing the perineal membrane in male

Contents of Deep Perineal Pouch

In male

1. Membranous urethra.
2. Bulbourethral glands and their ducts open into the spongy urethra.



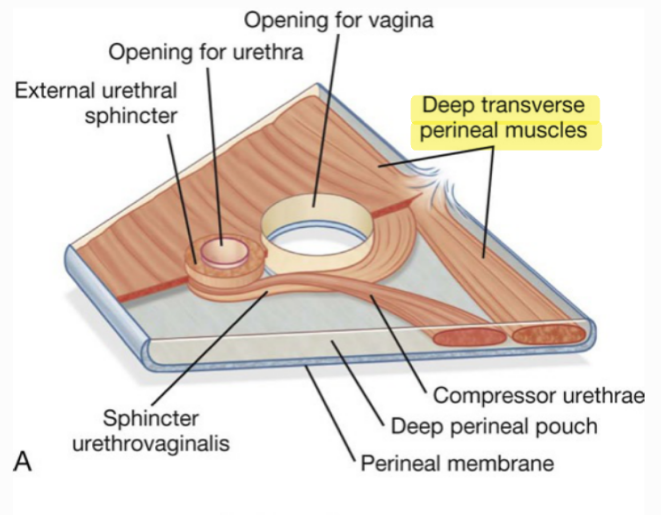
1. Sphincter urethrae.
2. Deep transversus perinei muscles: one on each side.

Nerves and vessels :

1. Dorsal nerve of the penis .
2. Internal pudendal artery.

In female

1. Urethra:
In the median plane closely anterior to the vagina.
2. Vagina: In the median plane.



1. Sphincter urethrae.
2. Deep transversus perinei muscles: one on each side.

Nerves and vessels

1. Dorsal nerve of the clitoris.
2. Internal pudendal artery.

Ischio-rectal Fossa :

Shape: a wedge-shaped

Position: space on each side of the anal canal.

Boundaries (walls):

- **Lateral wall: vertical.**

It is formed by :

1. The obturator internus
2. Obturator fascia
3. Ischial tuberosity

Obturator fascia is split to form the pudendal canal (its contents pudendal nerve and internal pudendal vessels).

- **Medial wall: sloping**

1. Upper part: the levator ani muscle.
2. Lower part: the external anal sphincter.

- **The base:**
- Directed downward and is formed by the peri-anal skin and fascia.

- **The apex:**
- Is directed upward and is formed by the meeting obturator internus and levator ani muscles.

- **Anterior boundary :**
- Superficial and deep perineal pouches and their contents.

- **Posterior boundary:**
- Sacrotuberous ligament and gluteus maximus muscle.

Contents :

- **Ischio-rectal pad of fat**
Allows distension of the anal canal during defecation.
- **Pudendal canal and its contents**
- **Inferior rectal vessels**
The artery arises from the internal pudendal artery in the pudendal canal.
It crosses the fossa to reach the anal canal.

- **Inferior rectal nerve:**
It is a branch of the pudendal nerve in the pudendal canal.
It crosses the fossa to supply the levator ani, and external anal sphincter.
- **Perineal branch of the 4th sacral nerve.**
- **Posterior scrotal nerves and vessels: to the scrotum (in male)**
- **Posterior labial nerves and vessels: to the labia majora (in female).**

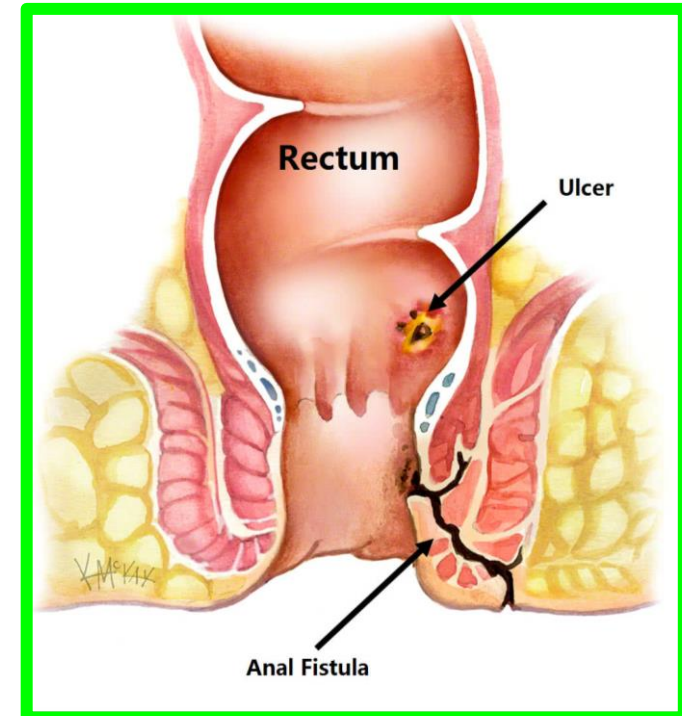
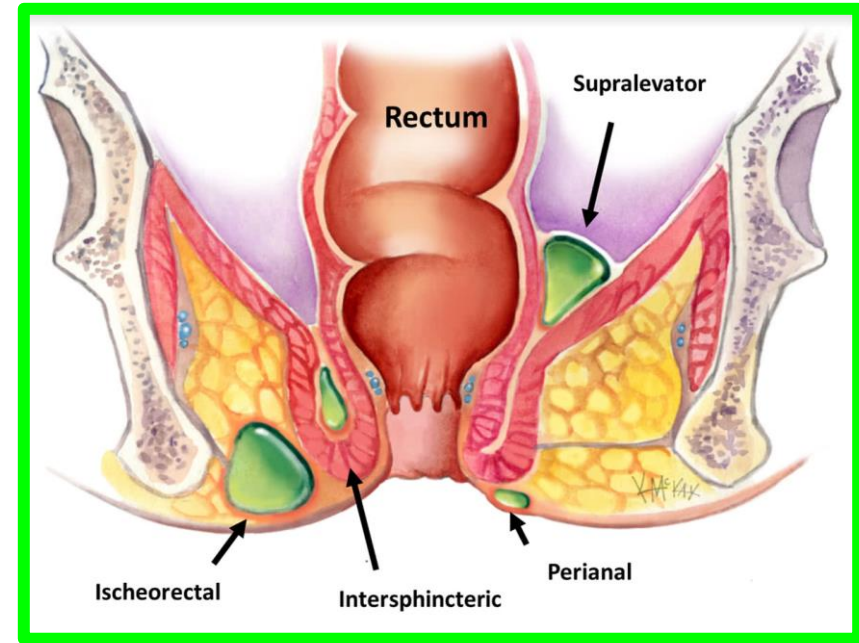
Ischiorectal Fossa

** Applied anatomy:

1- Infection of the ischiorectal fossa leading to an **ischiorectal abscess**.

2- If the abscess opens into the anal canal, it produces **anal fistula**.

3- If the abscess opens into the skin, it produces **an external sinus**.



Ischio-anal Fossae / ischio-rectal

See also Plates 296, 388

