

وسهلا



أهلا

يُمنع أخذ السلايدات بدون
إذن المحرر واي اجراء
يخالف ذلك يقع تحت طائلة
المسؤولية القانونية
جميع المعلومات للاستخدام
التعليمي فقط

الأستاذ الدكتور يوسف حسين

أستاذ التشريح وعلم الأجنة - كلية الطب - جامعة الزقازيق - مصر

رئيس قسم التشريح والأنسجة والأجنة - كلية الطب - جامعة مؤتة - الأردن

دكتوراه من جامعة كولونيا المانيا

جميع المعلومات المنشورة هي فقط للاستخدام التعليمي

اليوتيوب د. يوسف حسين

Prof. Dr. Youssef Hussein Anatomy - YouTube

https://www.youtube.com/channel/UCVSNqbibj9UWYaJdd_cn0PQ

YOUTUBE. يوسف حسين

Ulnar Artery

[Prof. Dr. Youssef Hussein Anatomy - YouTube](#)

• Ulnar Artery

** **Beginning:** the larger of two terminal branches of brachial artery in the cubital fossa at the level of the neck of radius.

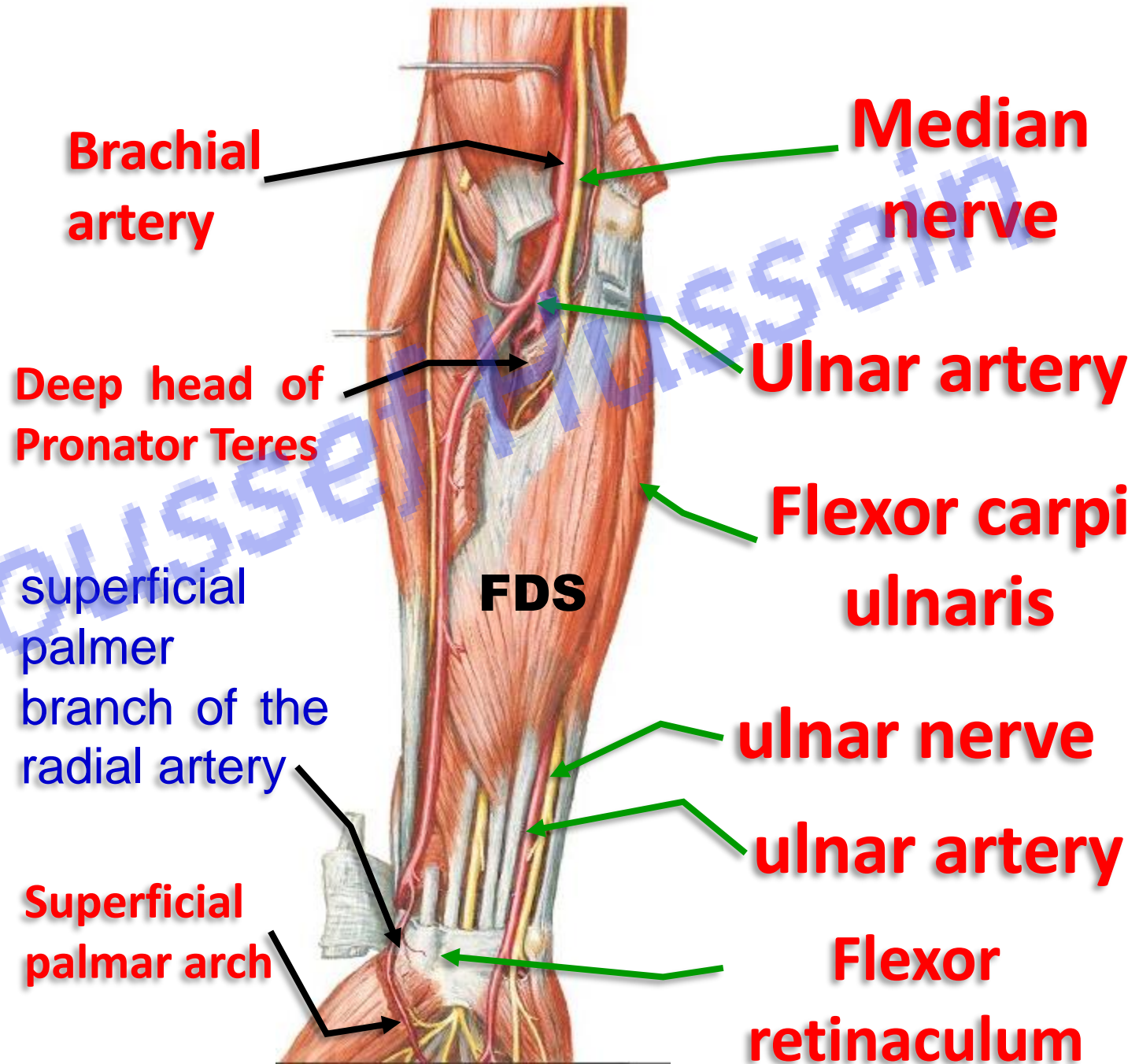
** **Course:**

- It descends medially deep to the deep head of pronator teres that separates it from the median nerve.

- It descends vertically deep to Flexor carpi ulnaris and lateral to ulnar nerve.

- **Above wrist joint:** between Flexor carpi ulnaris and flexor digitorum superficialis, covered by skin, superficial fascia, deep fascia (**dangerous position**). FDP (post)

- It **enters the hand** superficial to flexor retinaculum and anastomosis with superficial palmar branch of radial artery to form **superficial palmar arch**.



(in front medial epicondyle)

behind medial epicondyle

anterior branch of inferior ulnar collateral artery

Superior ulnar collateral artery

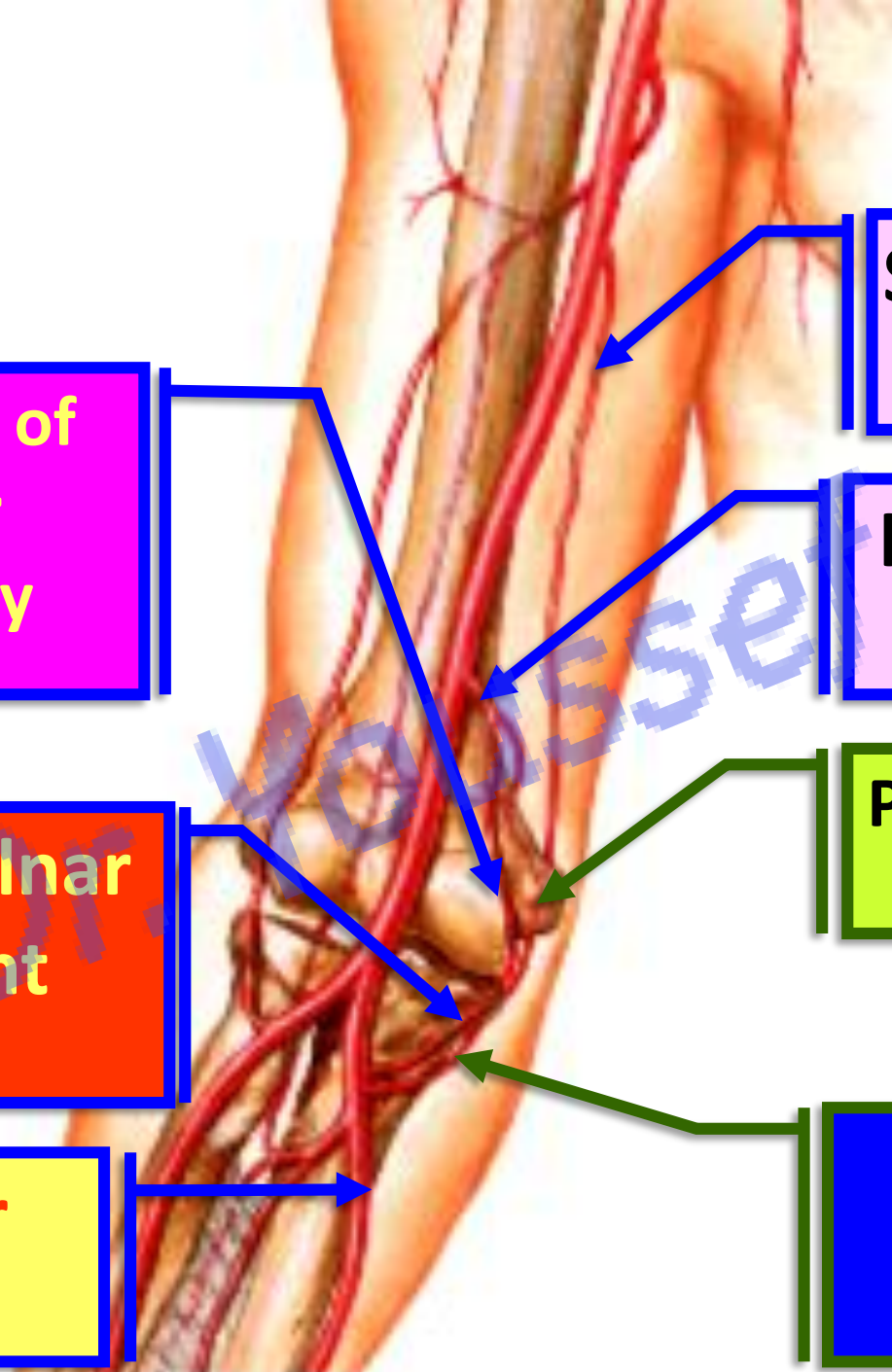
Inferior ulnar collateral artery

Anterior ulnar recurrent artery

Posterior branch of inferior ulnar collateral artery

Branches of Ulnar artery

Posterior ulnar recurrent artery



Branches of Ulnar artery

Behind lateral epicondyle

Profunda brachii

Posterior descending branch (Middle collateral artery)

Interosseous recurrent artery

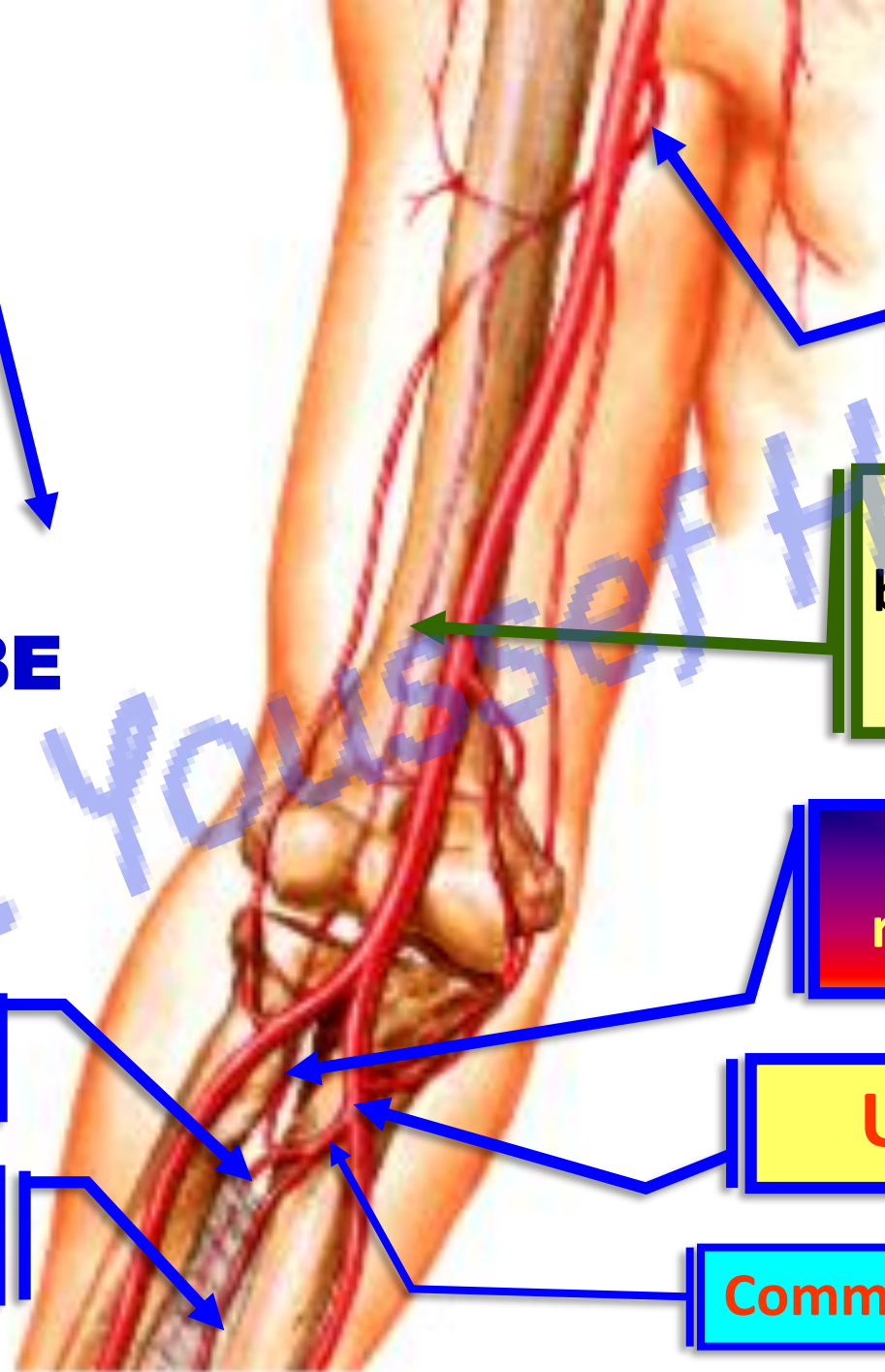
Ulnar artery

Common interosseous artery

Post. interosseous artery

Ant. interosseous artery

YOUTUBE. يوسف حسين



**** Branches of ulnar artery in the Forearm**

1- Anterior ulnar recurrent artery anastomoses with **the anterior branch of the inferior ulnar collateral artery** in front of the medial epicondyle.

2- Posterior ulnar recurrent artery anastomoses with the **superior ulnar collateral and posterior branch of the inferior ulnar collateral arteries** behind the medial epicondyle.

3- Common interosseous artery passes to upper border of the interosseous membrane where it divided into:

a) Anterior Interosseous artery

****** It descends on the **front** of the interosseous membrane

- At the upper border of the pronator quadratus, it **pierces** the interosseous membrane to reach the back of the forearm. The artery passes deep to the extensor retinaculum in the **4th compartment**.

- It ends in the dorsal carpal arch.

**** Branches**

1- Median artery passes with the median nerve.

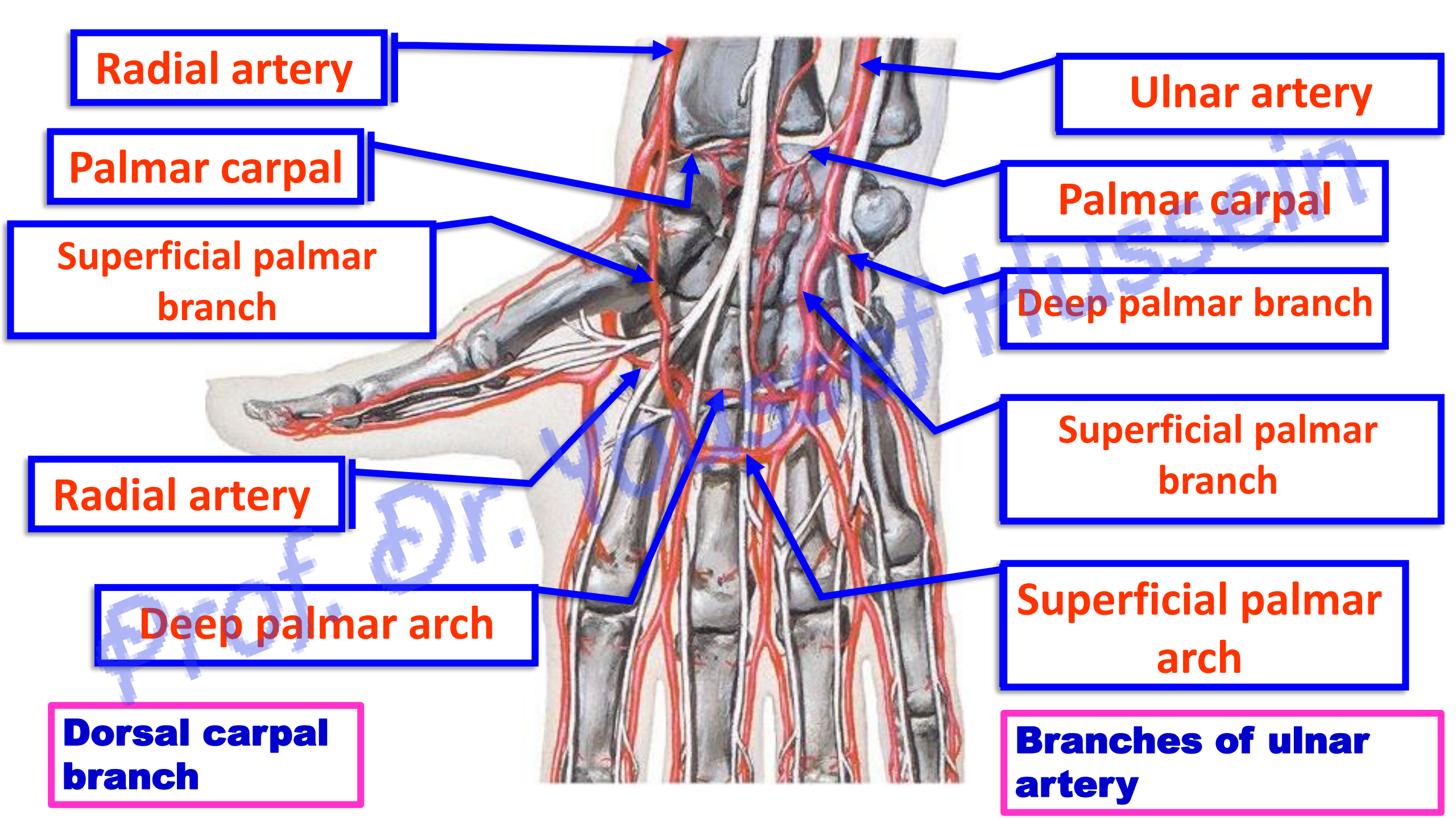
2- Nutrient arteries of the radius and ulna (**To the elbow I go from the knee I escape**).

3- Muscular branches.

د. يوسف حسين YOUTUBE

b) Posterior Interosseous artery

****** it gives **Interosseous recurrent artery** anastomose with the posterior descending branch of the profunda brachii artery **behind** the lateral epicondyle.



Radial artery

Ulnar artery

Palmar carpal

Palmar carpal

Superficial palmar branch

Deep palmar branch

Radial artery

Superficial palmar branch

Deep palmar arch

Superficial palmar arch

Dorsal carpal branch

Branches of ulnar artery

** Branches of ulnar artery in the Forearm

4- Muscular branches.

5- Palmer carpal branch anastomoses with the palmar carpal branch of the radial artery to form the **palmar carpal arch**.

6- Dorsal carpal branch anastomose with the dorsal carpal branch of the radial artery to form the **dorsal carpal arch**.

** Branches in the hand

a- Deep palmar branch: anastomosis with the radial artery to form the **deep palmar arch**.

b- Superficial palmar branch anastomosis with the superficial palmer branch of the radial artery to form the **superficial palmar arch**.

YOUTUBE د. يوسف حسين

Radial Artery

Prof. Dr. Youssef Hussein Anatomy - YouTube

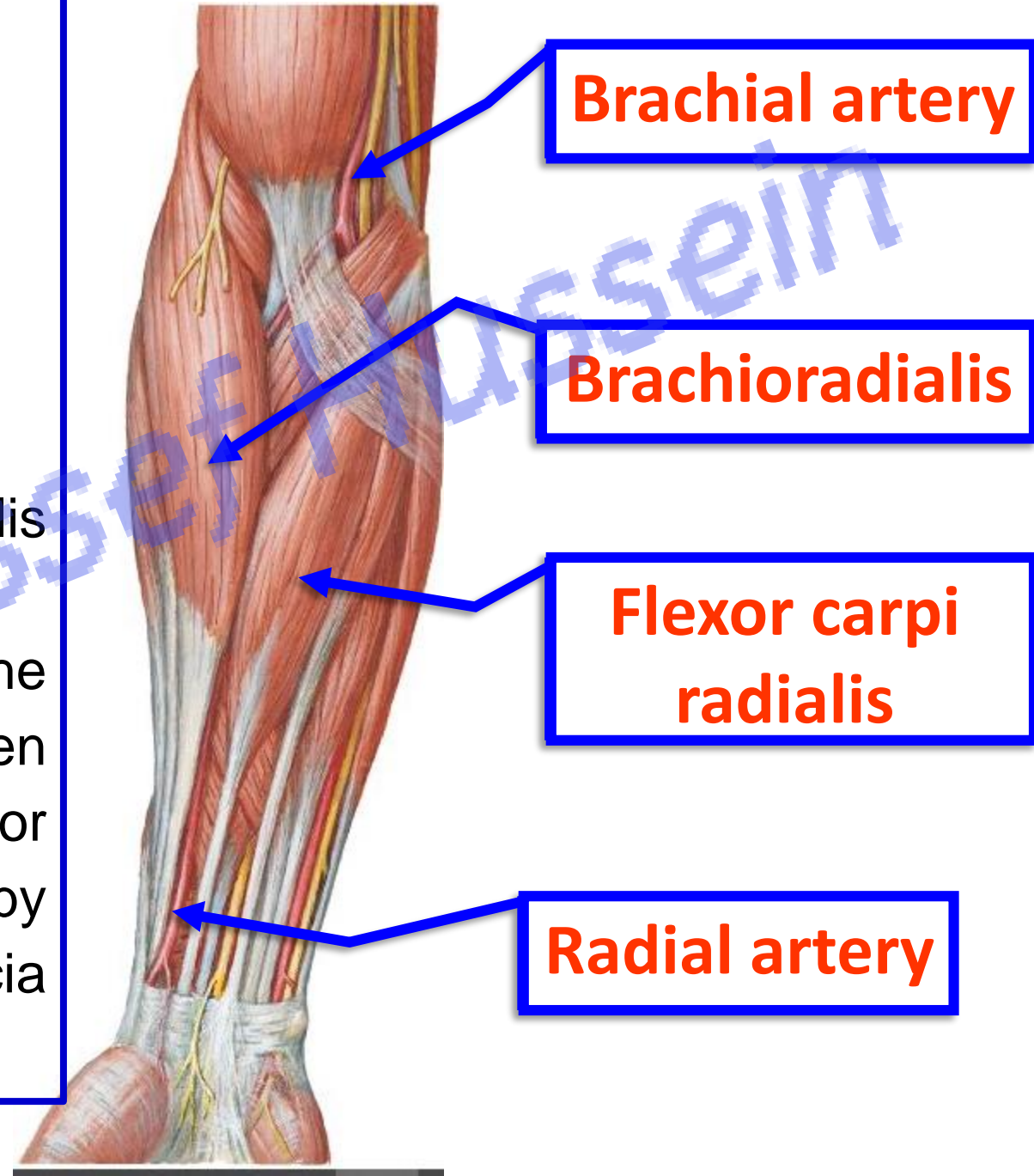
- **Radial Artery of the forearm**

** **Begin**: one of the two terminal branches of the brachial artery in the cubital fossa at the level of the neck of the radius.

** **End**; in the palm of the hand as **deep palmer arch**.

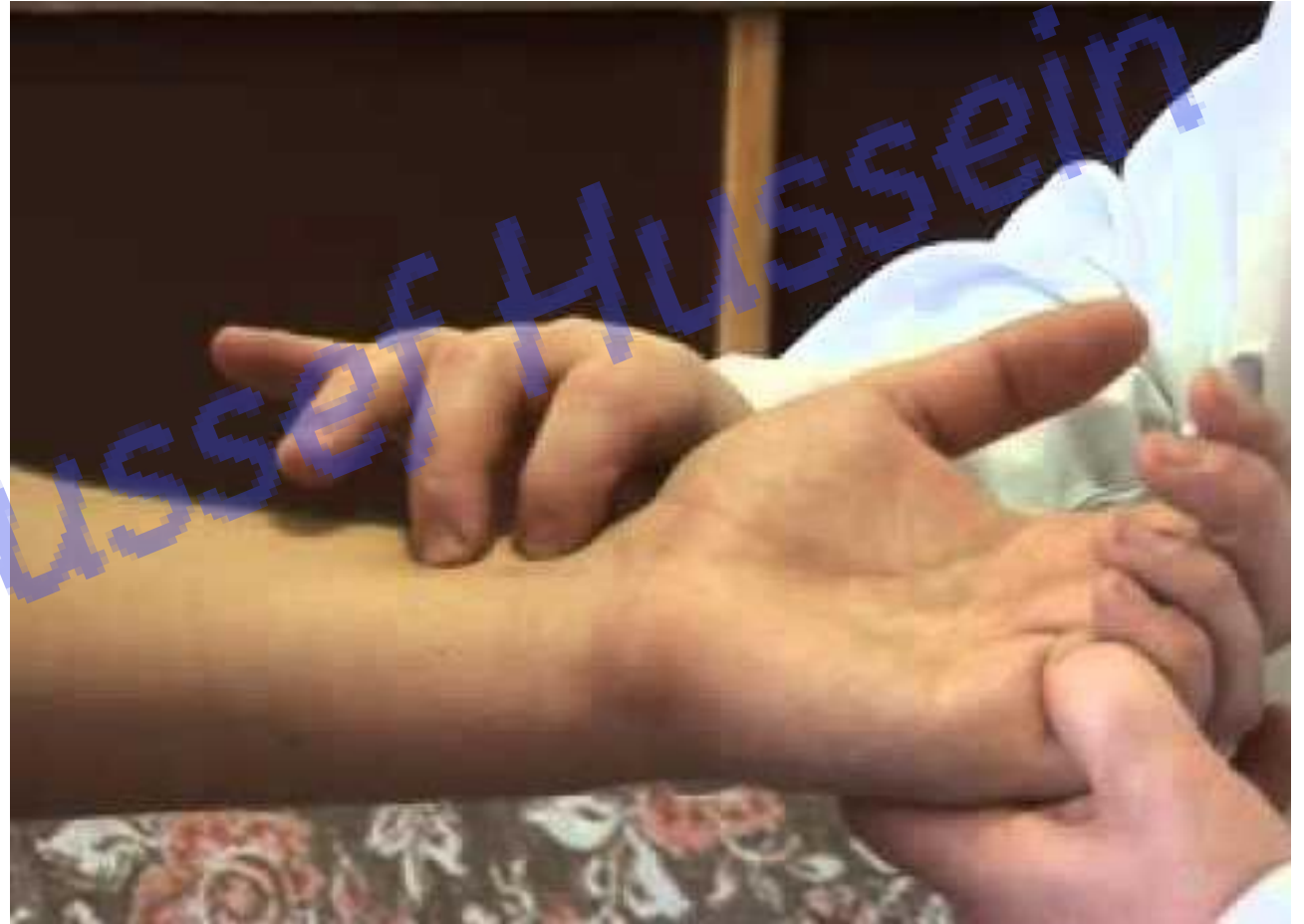- **Course**: It passes deep to brachioradialis muscle with the radial nerve

- **In the lower one third**, it descends on the distal end of the radius between brachioradialis muscle (**laterally**) and flexor carpi radialis (**medially**) and covered only by skin, superficial fascia and deep fascia (**where you can feel arterial pulsation**).



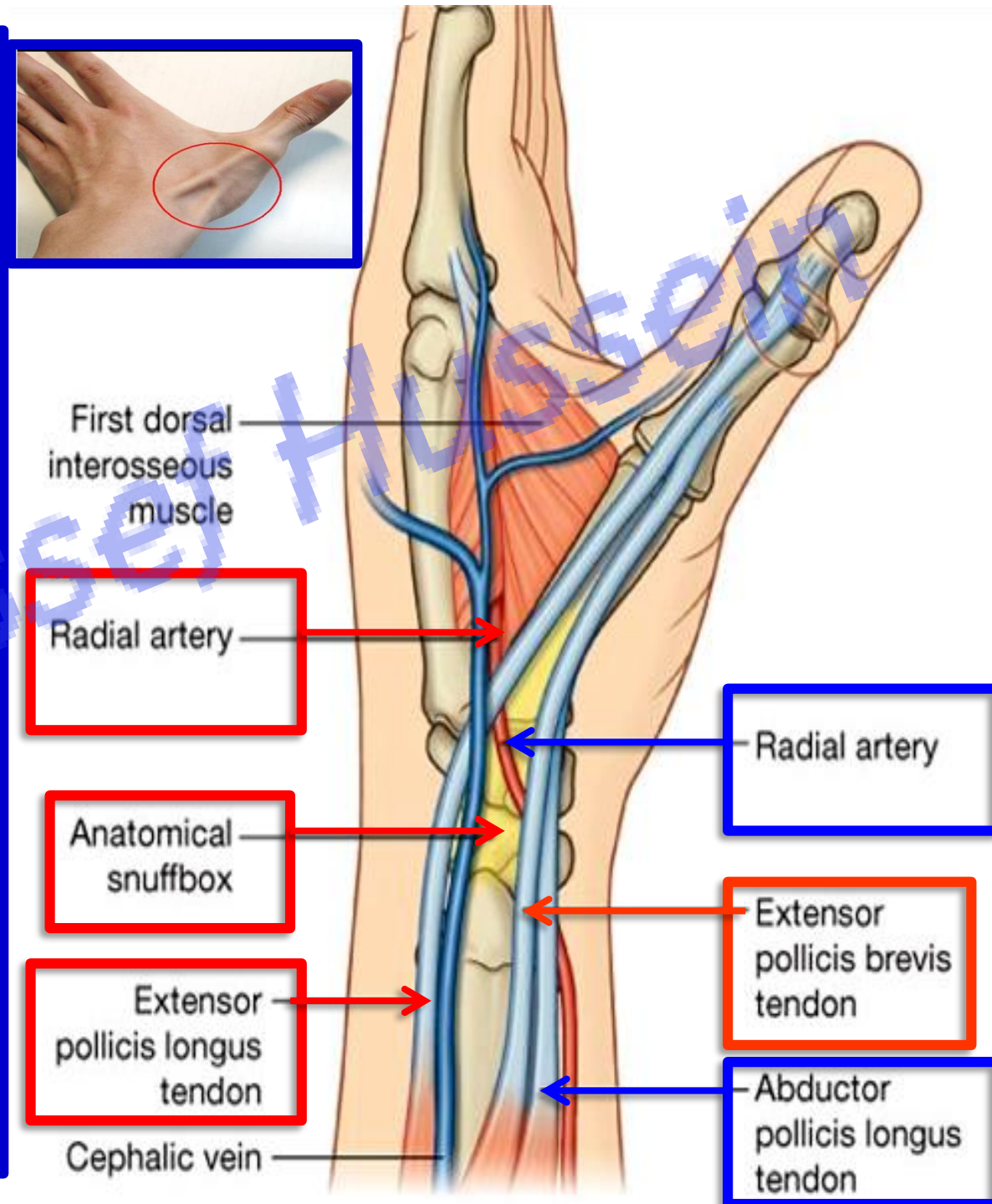
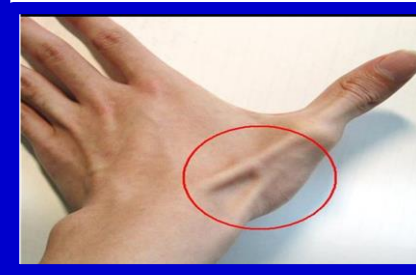YOUTUBE. يوسف حسين

- The radial pulse is the most commonly used one for feeling and counting the arterial pulsations.
- Pulsations of the radial artery are easily palpated when the artery is compressed by the tips of the fingers against the distal end of the radius (Bone).



- **Radial Artery in the hand**

- It turns backwards and laterally **deep** to tendons of abductor pollicis longus and extensor pollicis brevis to reach **anatomical snuff-box**.
- **In box**, it is covered by skin and fascia.
- It **leaves** **anatomical snuff-box** by passing **deep** to the tendon of extensor pollicis longus.
- It reaches the **palm of the hand** through the first interosseous space.
- Then, it passes medially to anastomosis with the deep palmar branch of the ulnar artery to form the **deep palmar arch**.





**Anterior descending
branch (radial
collateral artery)**

**Radial recurrent
artery**

Radial artery

Profunda brachii

**** Branches of the radial artery in
forearm**

- **Radial recurrent artery:** It ascends upward to anastomose with the anterior descending branch of the profunda brachii artery in front of the lateral epicondyle.
- **Muscular** branches.

Radial artery

Ulnar artery

Palmar carpal

Palmar carpal

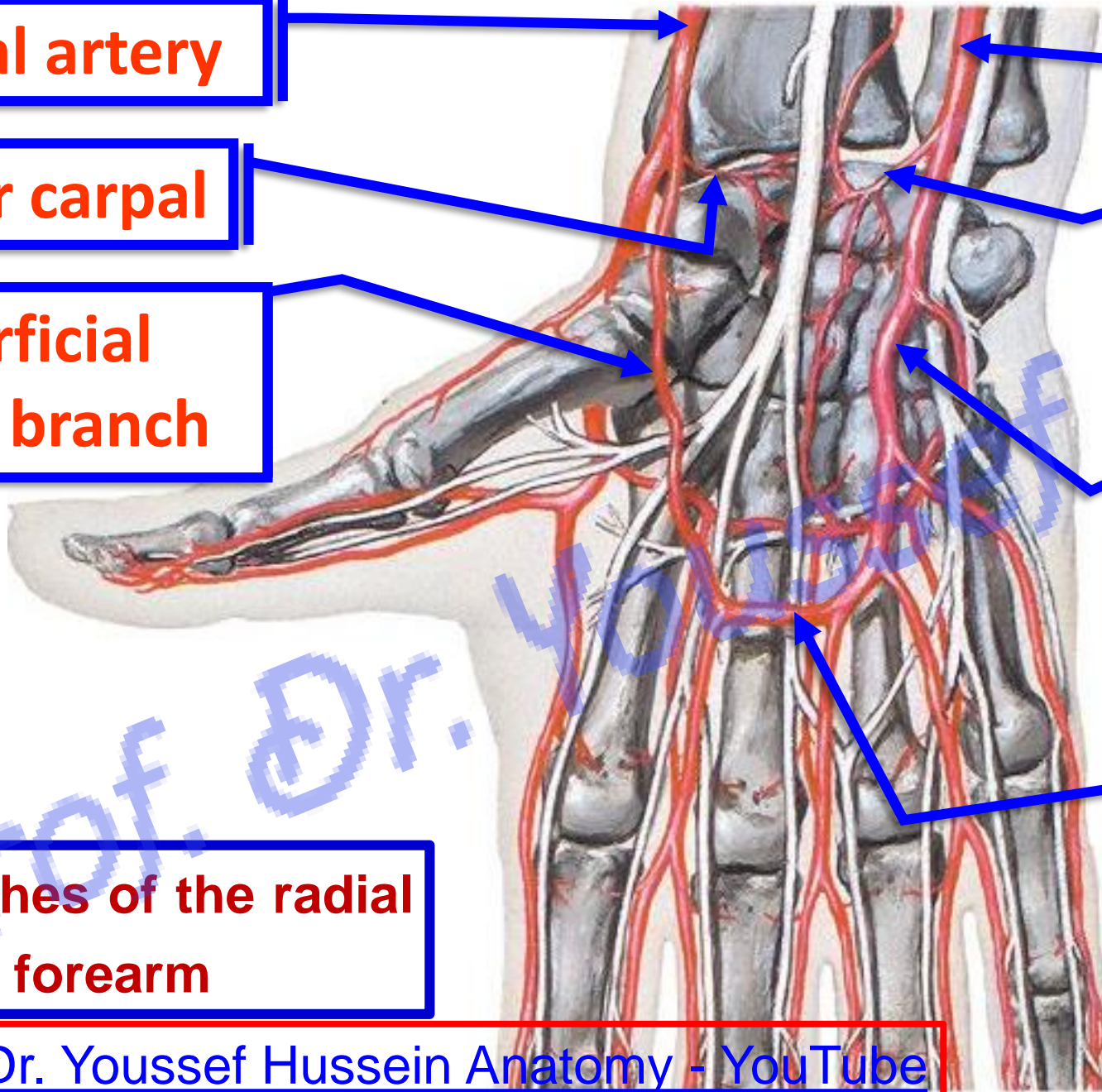
**Superficial
palmar branch**

**Superficial palmar
branch**

**** Branches of the radial
artery in forearm**

**Superficial palmar
arch**

Prof. Dr. Youssef Hussein Anatomy - YouTube



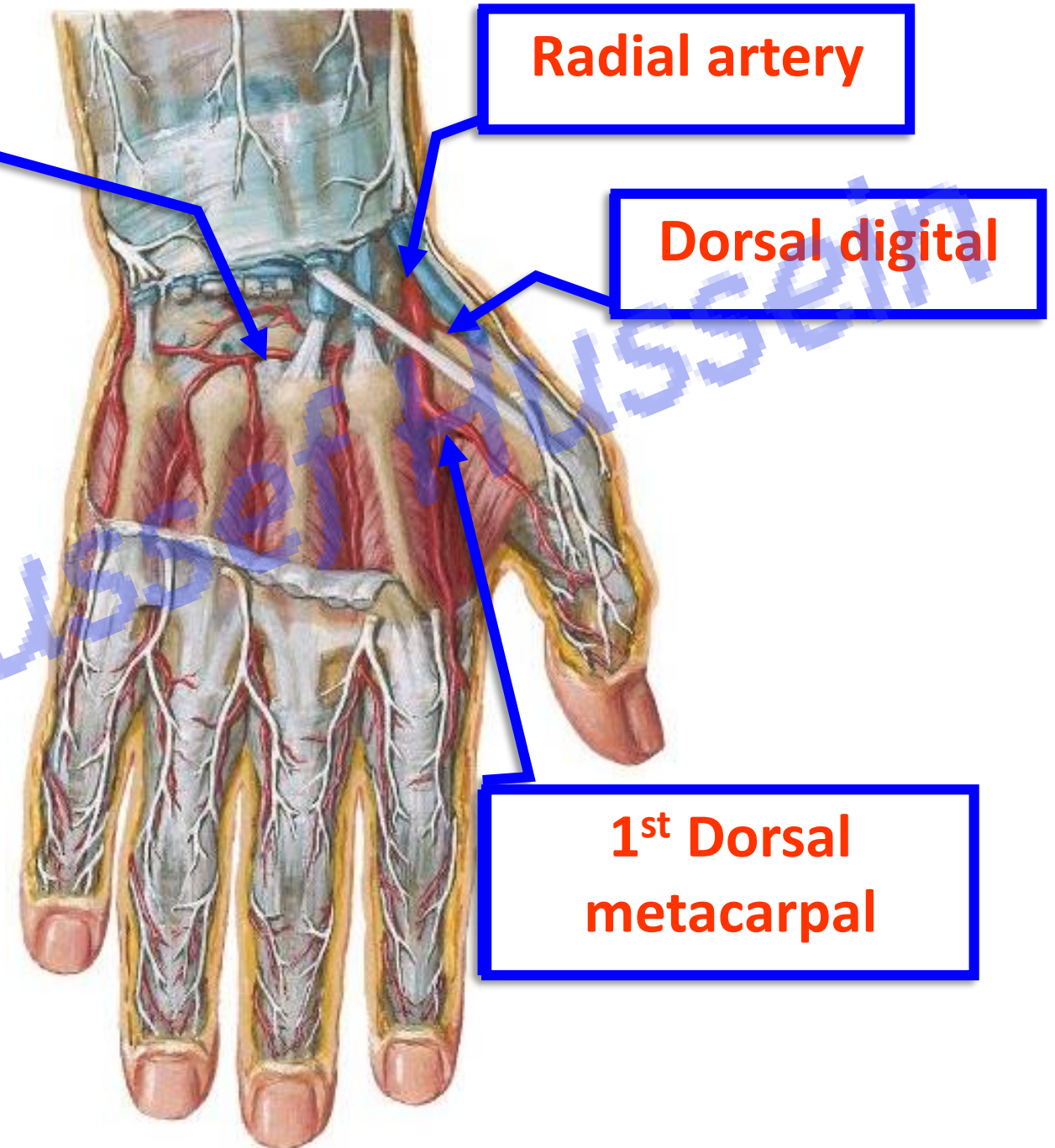
Dorsal carpal arch

- **Branches of radial artery in the dorsum of the hand:**

1- **Dorsal carpal branch:** anastomoses with the dorsal carpal branch of the ulnar artery to form the **dorsal carpal arch**.

2- **Dorsal digital branch** to the **lateral** side of the thumb.

3- **First dorsal metacarpal artery** to the adjacent sides of the thumb and index.



• **Branches of radial artery in Palm of the hand:**

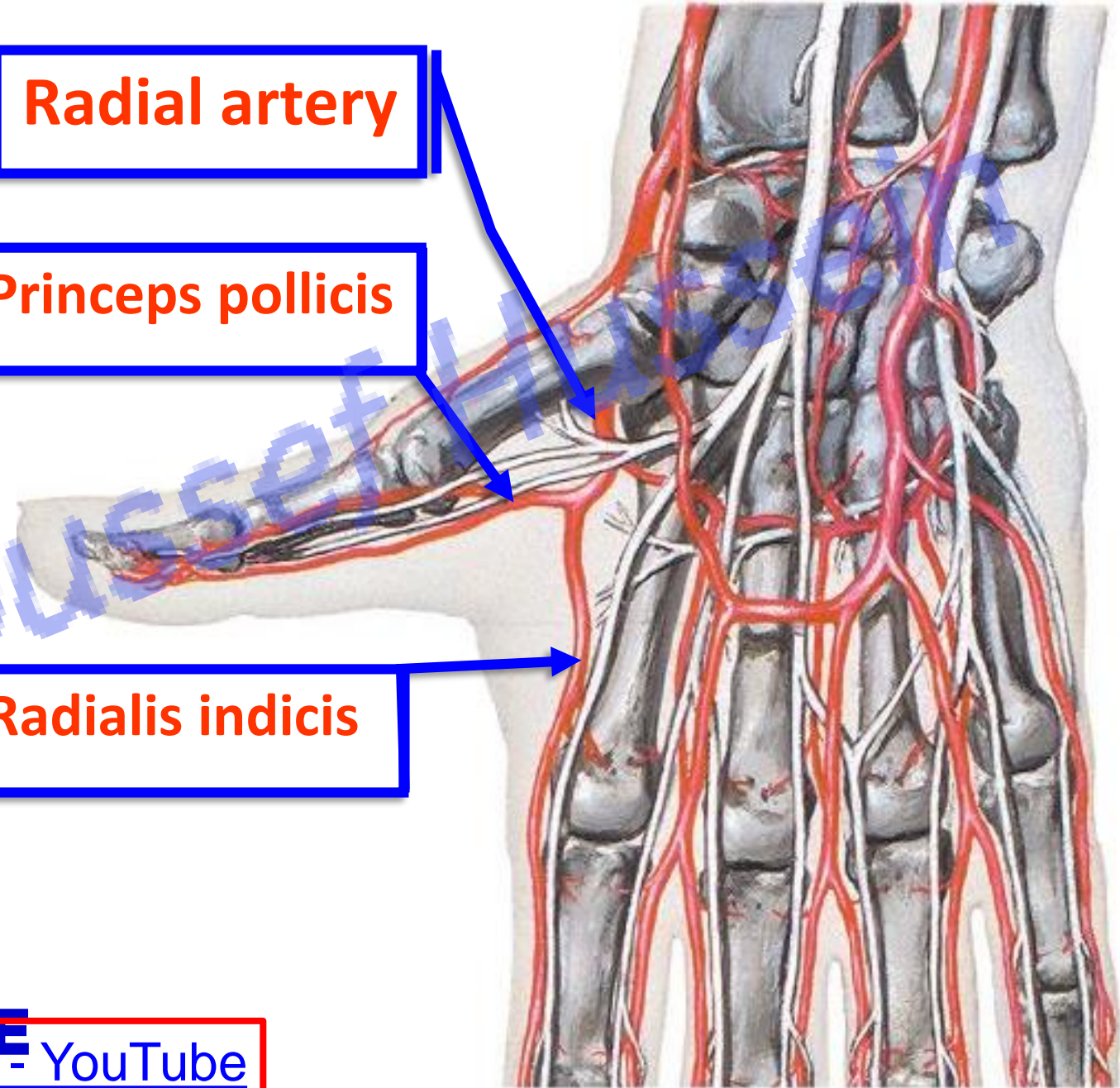
1- Princeps pollicis artery to the palmar aspect of the thumb.

2- Radialis indicis artery: to the radial side of the index finger.

Radial artery

Princeps pollicis

Radialis indicis



Branches of radial artery

A- in the forearm

- 1- Radial recurrent artery
- 2- Palmar carpal branch
- 3- Superficial palmar branch

B- in the dorsum of the hand

- 1- Dorsal carpal branch
- 2- Dorsal digital branch
- 3- First dorsal metacarpal artery

C- in the palm of the hand

- 1- Princeps pollicis artery
- 2- Radialis indicis artery

D- End of the radial artery

Branches of ulnar artery

• A- in the forearm

- 1- Anterior ulnar recurrent artery
- 2- Posterior ulnar recurrent artery
- 3- Common interosseous artery
- 5- Palmer carpal branch
- 6- Dorsal carpal branch

B- in the palm of the hand

- 1- Superficial branch
- 2- Deep branch

Arch

Arch

Arch

Arch

Dorsal Carpal Arch

Dorsal carpal arch

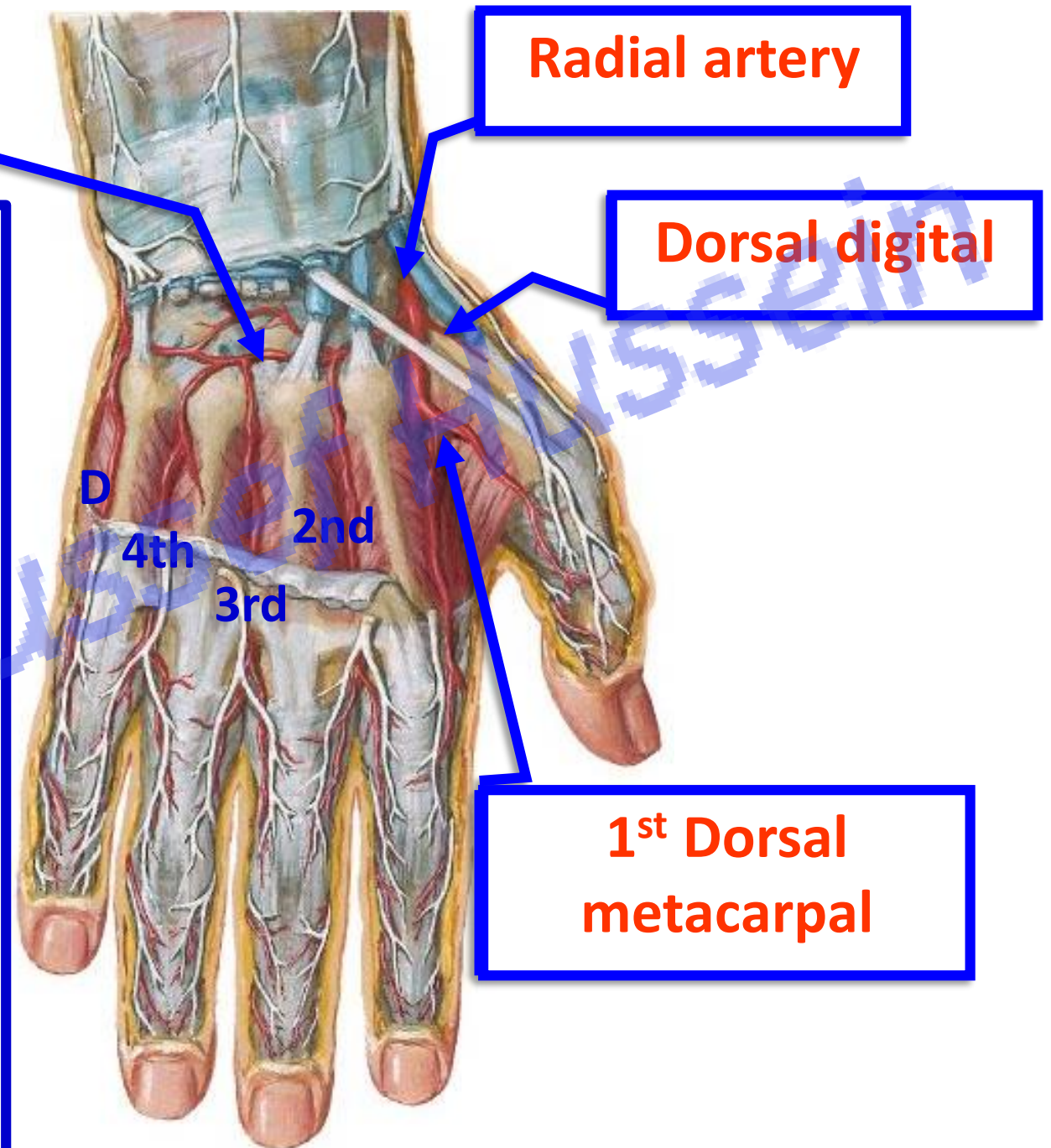
- **Dorsal Carpal Arch**

* **Formation**; union of:

- 1- Dorsal carpal branch of radial artery.
- 2- Dorsal carpal branch of ulnar artery.
- 3- Termination of anterior interosseous artery.

* **Branches**

- 1- 2nd, 3rd and 4th dorsal metacarpal arteries to the adjacent sides of the medial 4 fingers.
- 2- **Dorsal digital artery** for the medial side of little finger.



Superficial Palmar Arch

Radial artery

Ulnar artery

Superficial palmar branch

Superficial palmar branch

Princeps pollicis

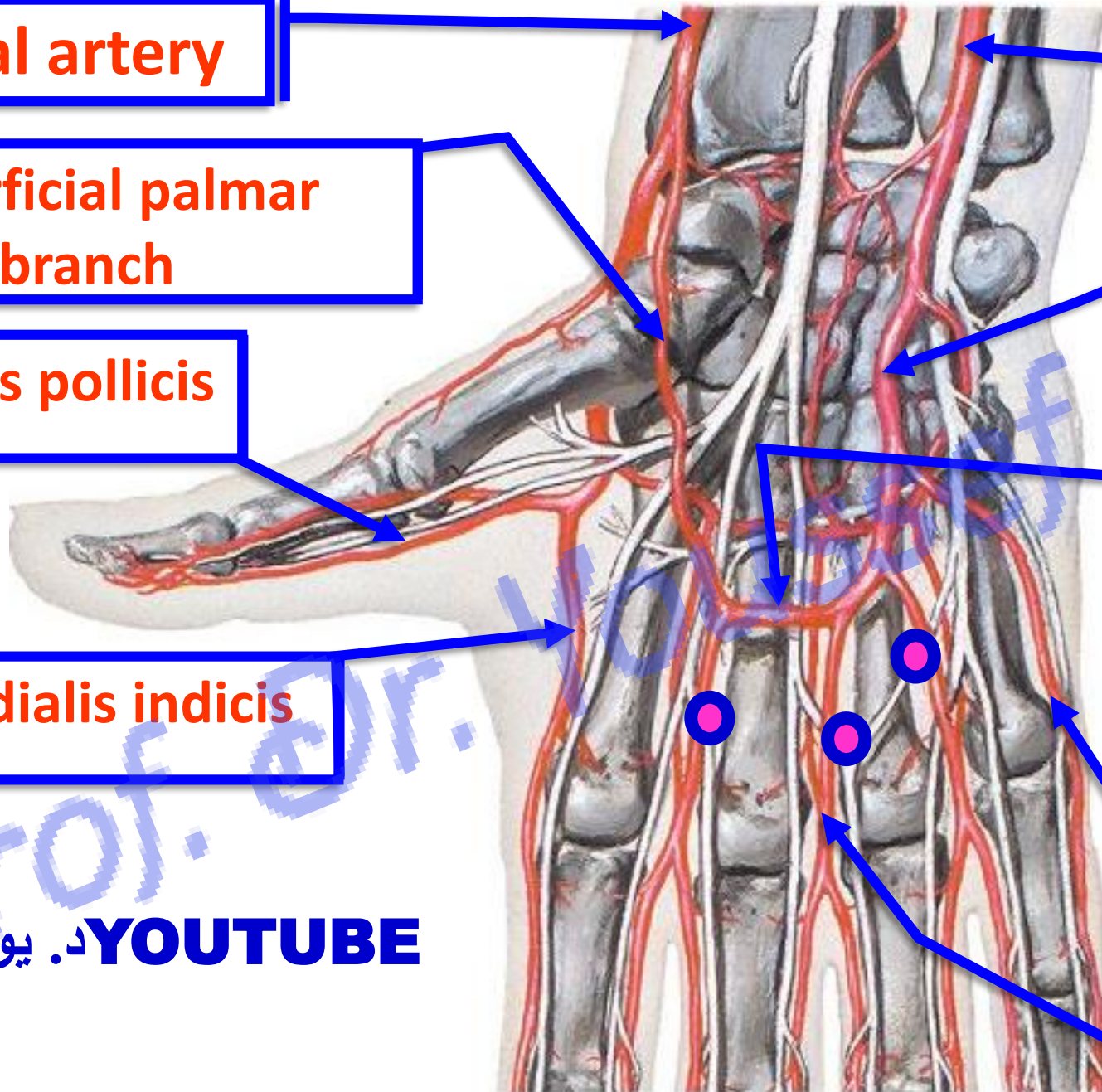
Superficial palmar arch

Radialis indicis

Palmar digital artery

YOUTUBE د. يوسف حسين

3 Palmar digital arteries



- **Superficial palmar arch**

** **Site:** superficial to the flexor tendons.

- It is **distal** to the deep palmar arch.

** **Formation;**

1. Superficial terminal branch of the ulnar artery (**mainly**).

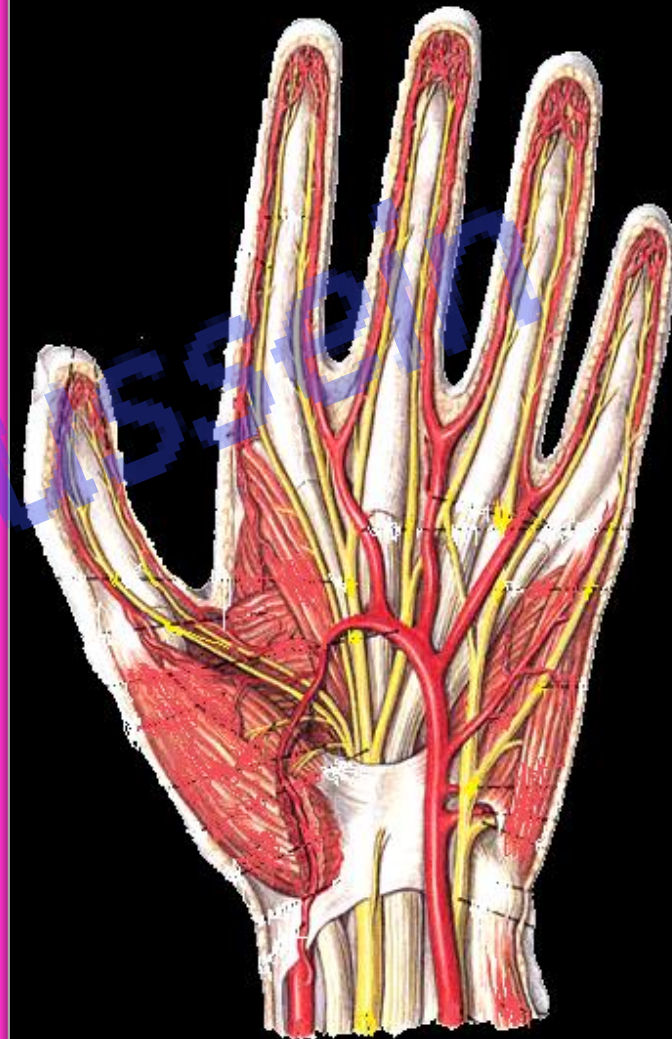2. Superficial palmar branch of the radial artery.

** **Branches:**

1- 3 Palmar digital arteries for the adjacent sides of medial 4 fingers

2- Palmar digital artery for the medial side of the little finger.

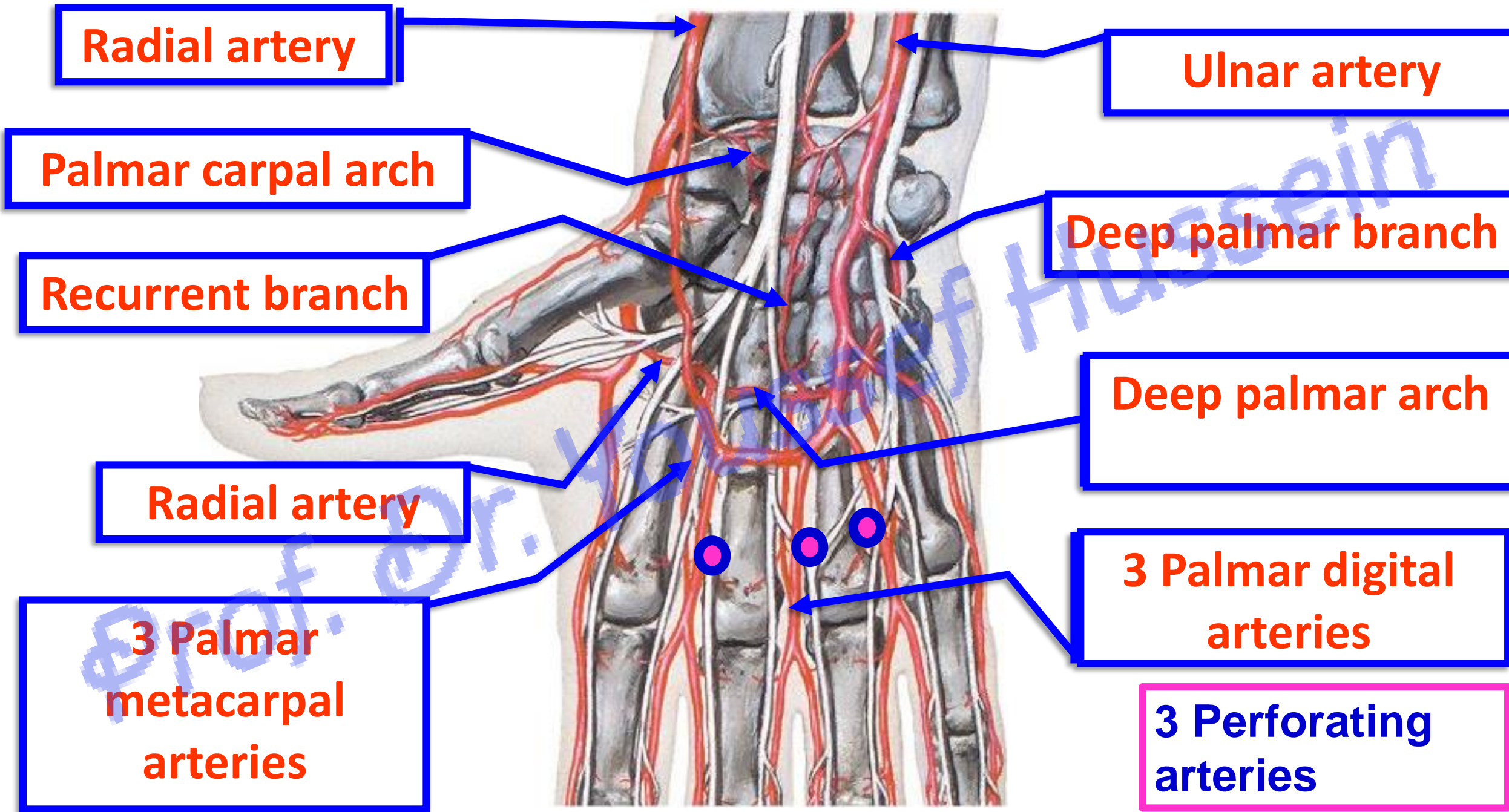
- **Pulp Spaces** are fibrofatty compartments on the palmar surface of the distal phalanges distal to the insertion of the flexor tendons. They contain ramification of the digital arteries (artery of pulp). Infection of the pulp space is painful. Obstruction of these arteries leading to necrosis.



YOUTUBE. يوسف حسين

Deep Palmar Arch

[Prof. Dr. Youssef Hussein Anatomy - YouTube](#)



- **Deep palmar arch**

** **Site**; deep to the flexor tendons and lumbrical muscles.

** **Formation**;

1- The continuation of the radial artery (**mainly**).

2- The deep terminal branch of the ulnar artery.

** **Branches**

1- 3 palmar metacarpal arteries join palmar digital arteries of **superficial palmar arch**.

2- 3 Perforating branches: pass through the 2nd, 3rd and 4th interosseous spaces to join the 2nd, 3rd and 4th dorsal metacarpal arteries of **dorsal carpal arch**.

3- Recurrent branches to join **the palmar carpal arch**.

- In cases of **hemorrhage** of the hand press the radial artery against lower end of the radius to identify the source of bleeding;

a- If it becomes **weak**, the source of bleeding is the **deep** palmar arch.


b- If **not changed**, the source of bleeding is the **superficial** palmar arch.

د. يوسف حسين YOUTUBE

https://www.youtube.com/channel/UCVSNqbibj9UWYaJdd_cn0PQ

يُمنع أخذ السلايدات بدون
إذن المحرر و اي اجراء
يخالف ذلك يقع تحت طائلة
المسؤولية القانونية
جميع المعلومات للاستخدام
التعليمي فقط

اليوتيوب د. يوسف حسين



Thank You

Questions

<https://www.youtube.com/@ProfDrYoussefHusseinAnatomy/playlists>