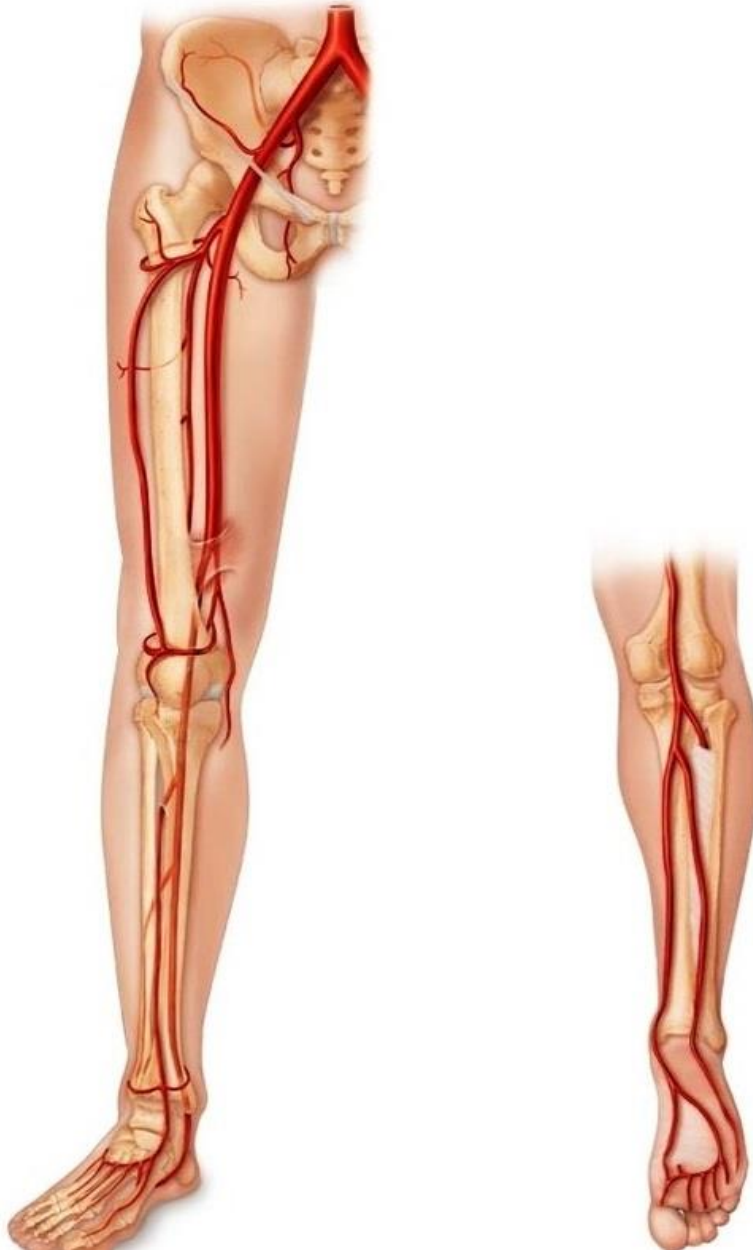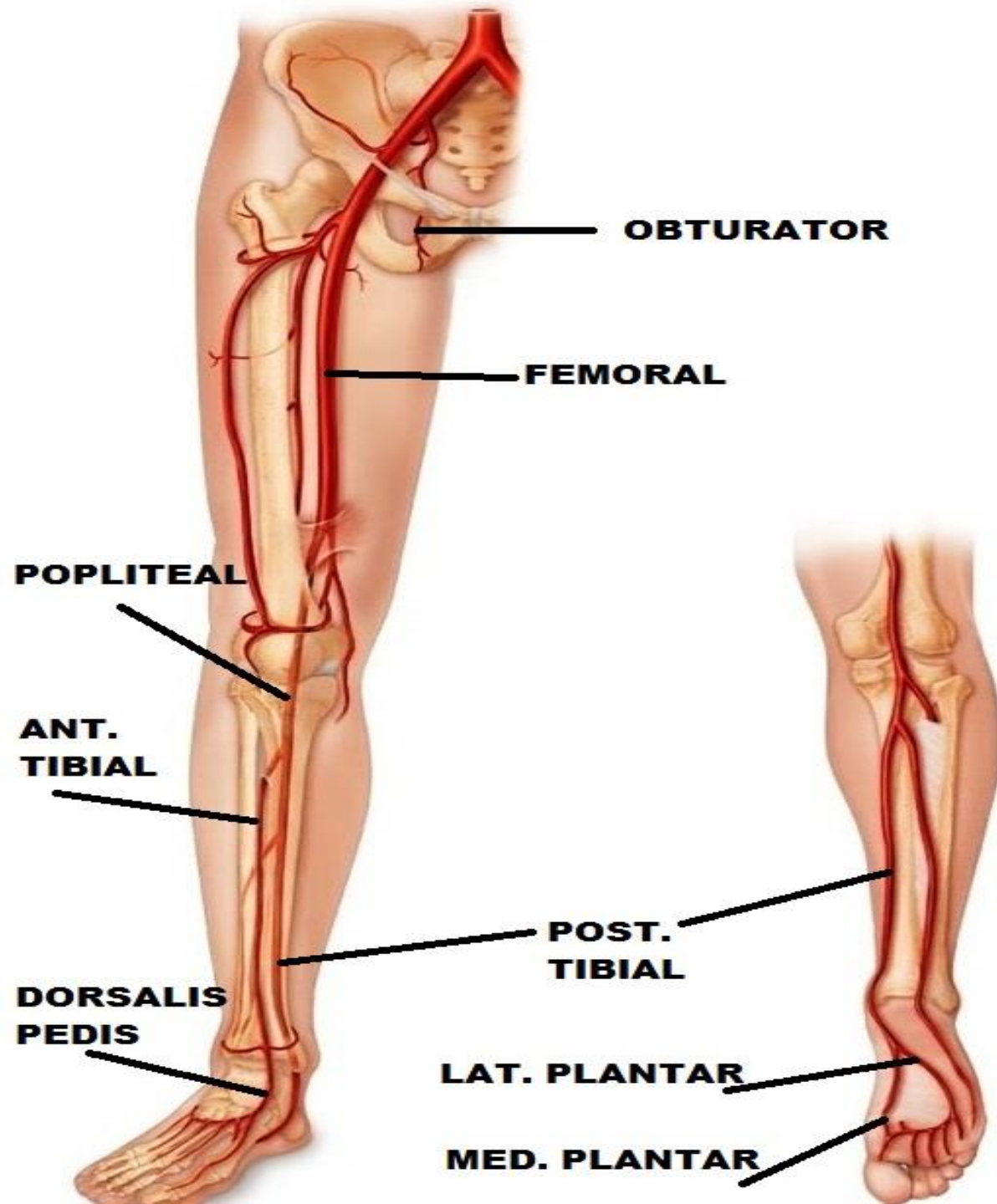


ARTERIES OF LOWER LIMB

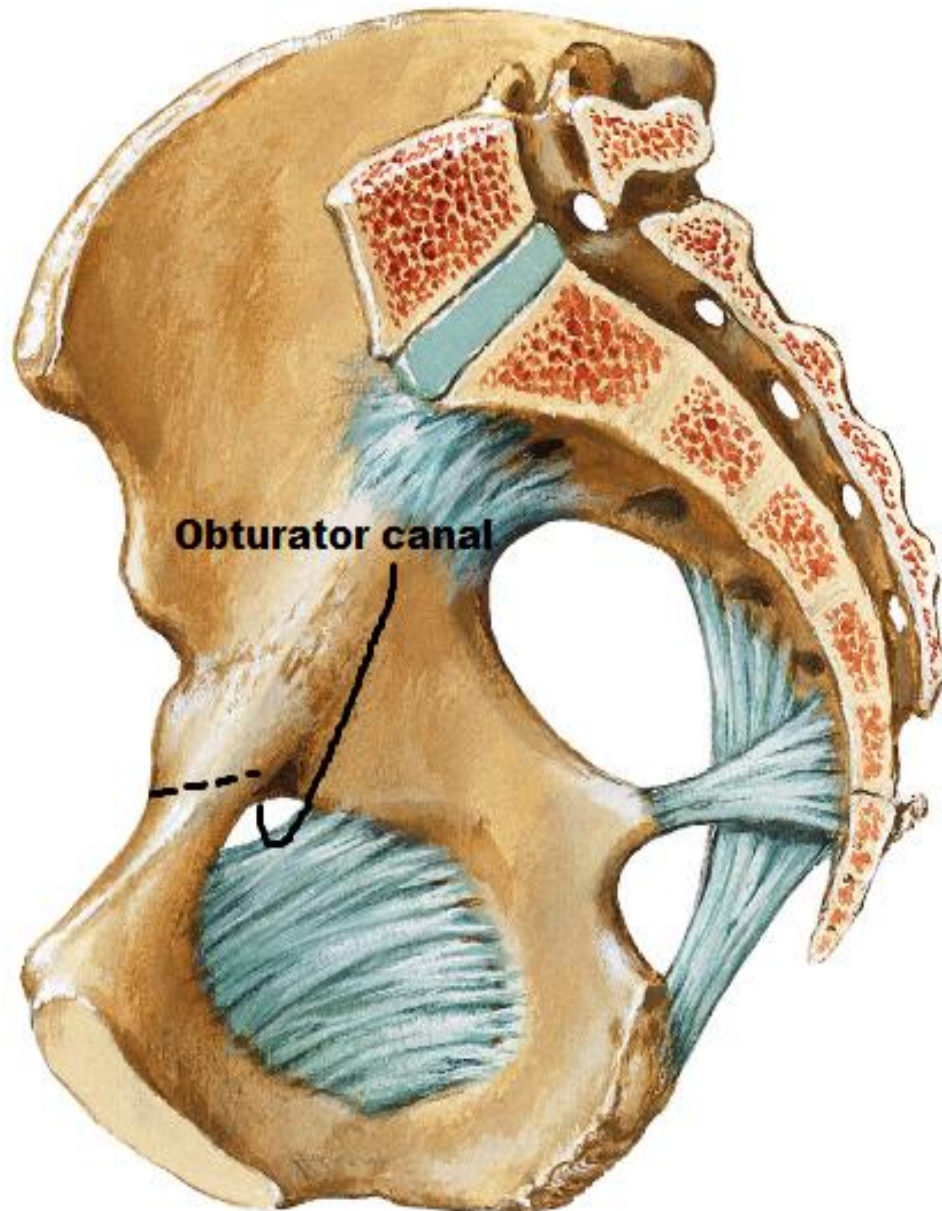


BY

DR ABULMAATY MOHAMED
ASSISTANT PROFESSOR
ANATOMY & EMBRYOLOGY
MUTAH UNIVERSITY



REV.



OBTURATOR ARTERY

O. :- br. from ant. division of int. iliac art.

Inside the pelvis

C. & r. :

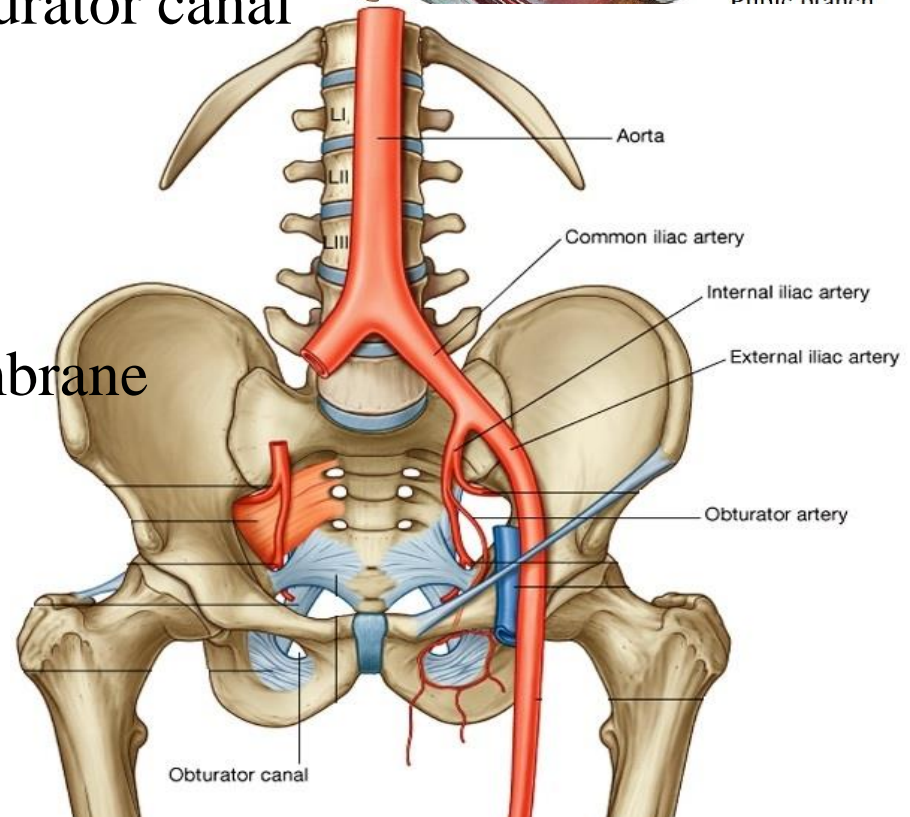
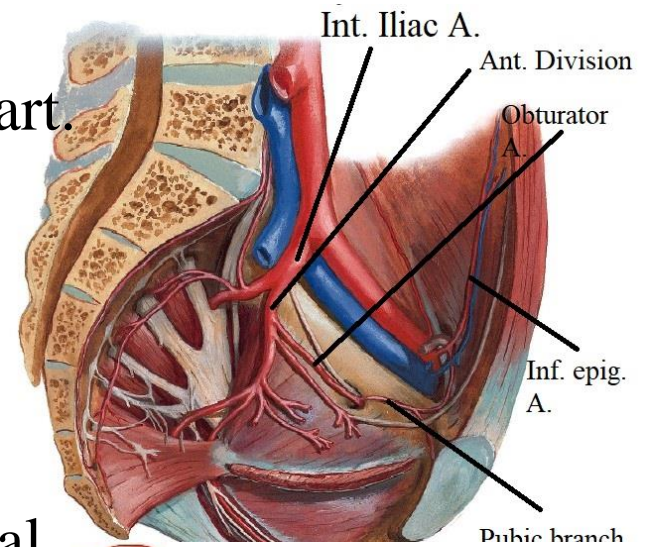
- runs on the side wall of the pelvis between the obturator nerve and vein
- enters the thigh through obturator canal

-at ant. end of canal →

medial & lateral divisions

that form arterial circle

at margins of obturator membrane



OBTURATOR ARTERY

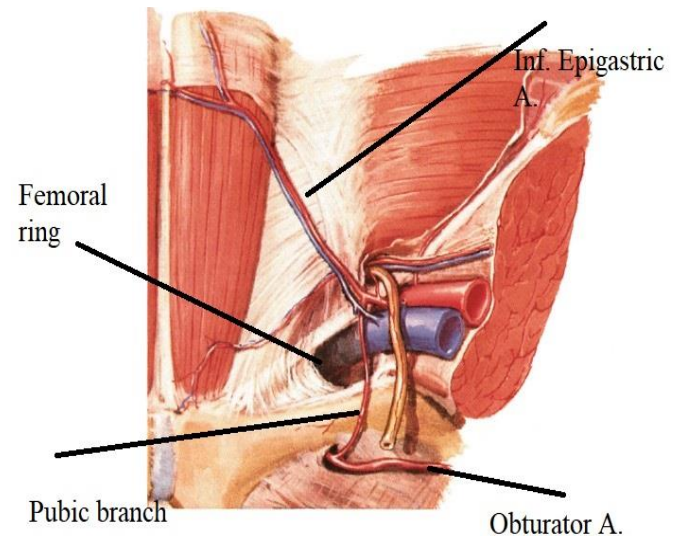
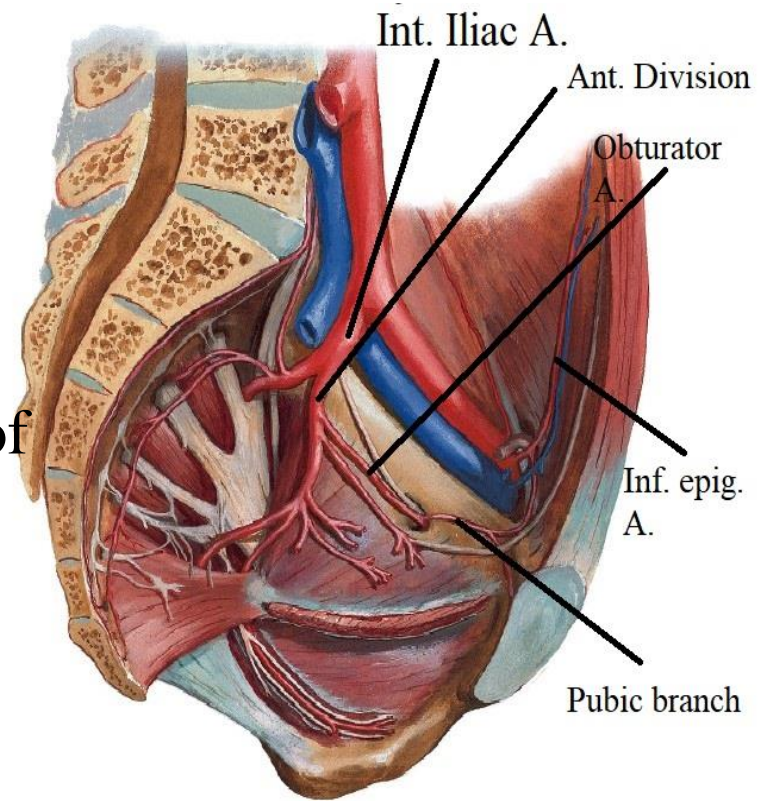
branches :

-pubic branch-

-arises just before the obturator artery leaves the pelvis.

-It ascends on the pelvic surface of the pubis to anastomose with the pubic branch of the inferior epigastric artery.

N.B.;-In 20% of people, an aberrant or accessory obturator artery arises from the inferior epigastric artery and descends into the pelvis along the usual route of the pubic branch. Surgeons performing hernia repairs must keep this common variation in mind



OBTURATOR ARTERY

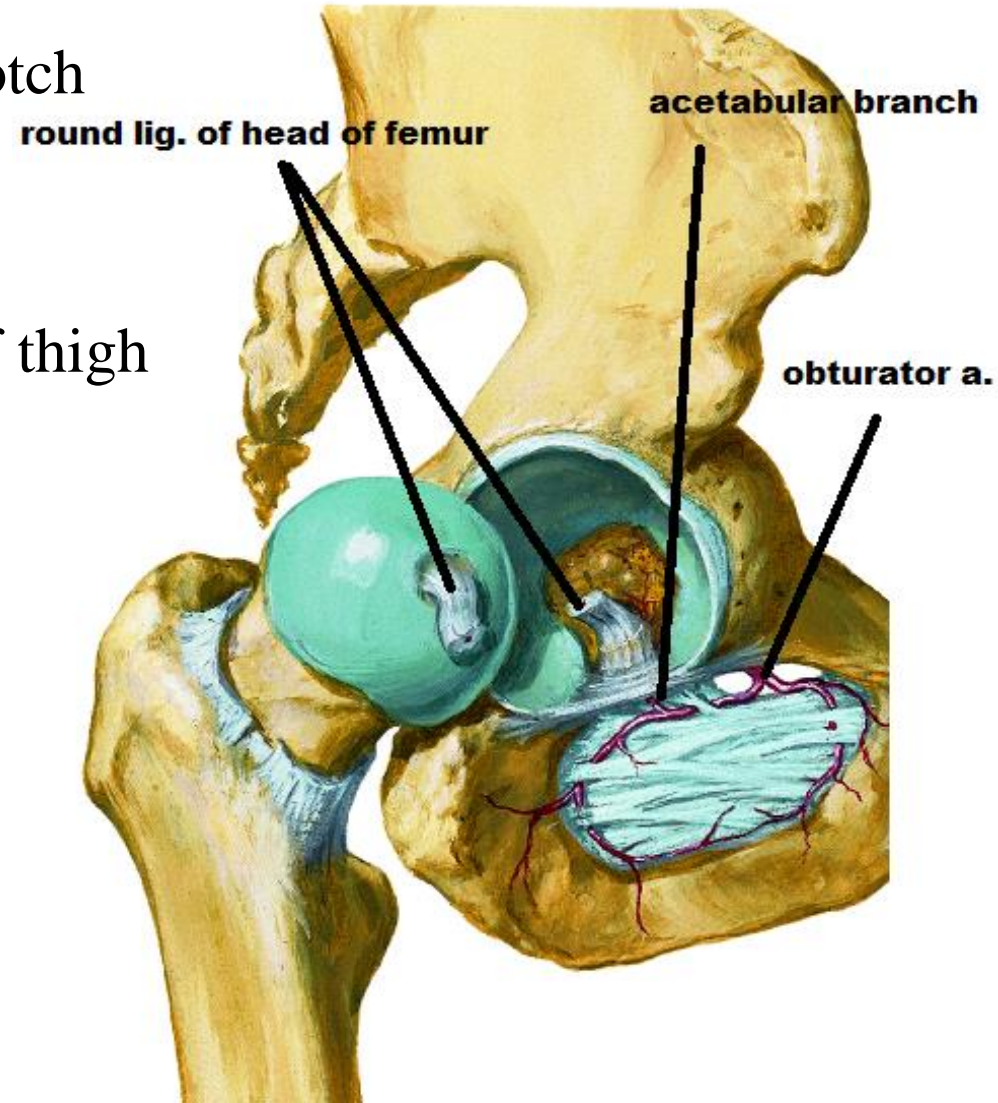
branches :

-acetabular br.:-

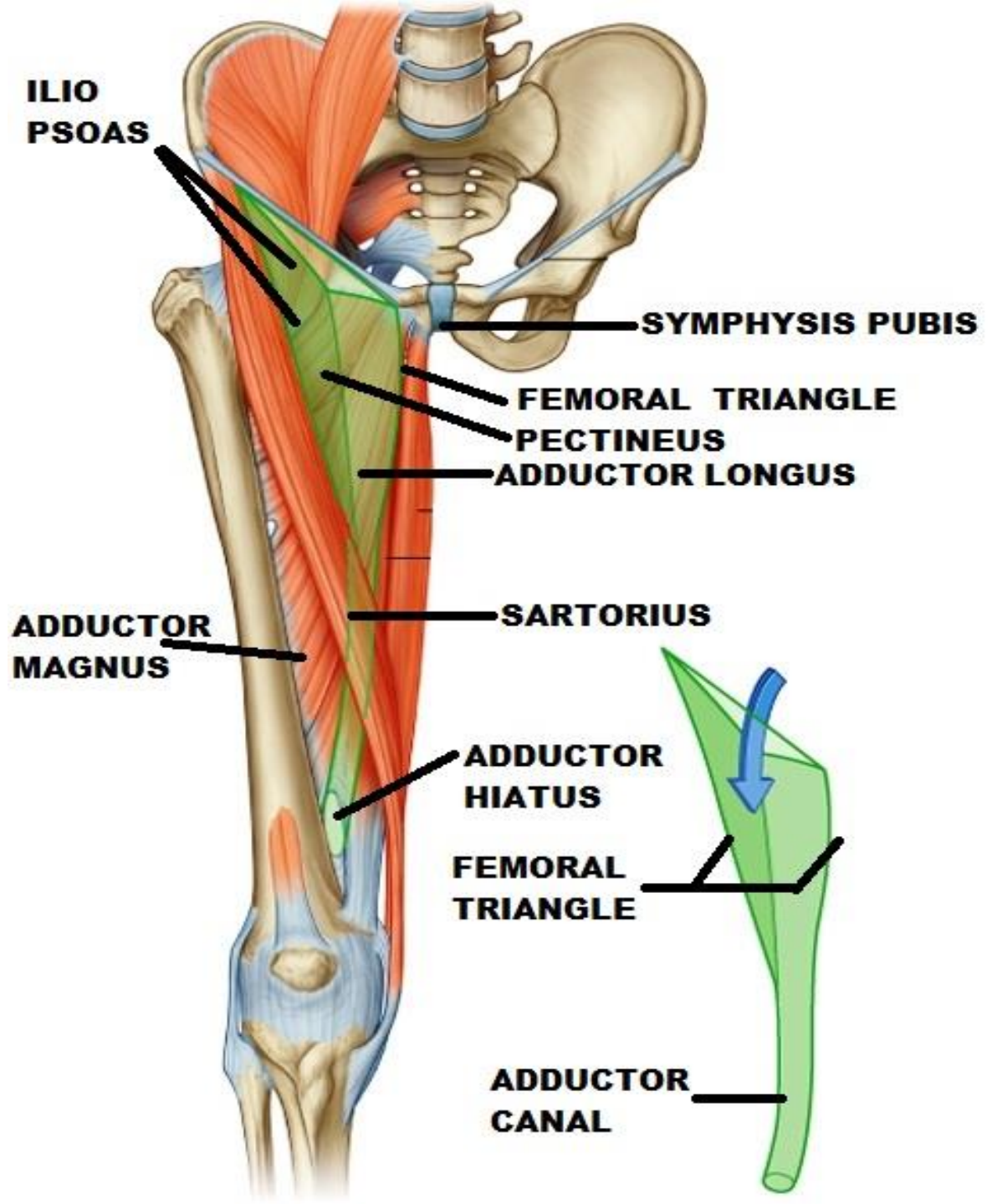
pass through acetabular notch
to supply head of femur

-muscular branches:-

to medial compartment of thigh



REV.



FEMORAL ARTERY

Origin:-

continuation of ext. iliac art. deep to inguinal lig

at midinguinal point (midway between ASIS & symphysis pubis)

Course:

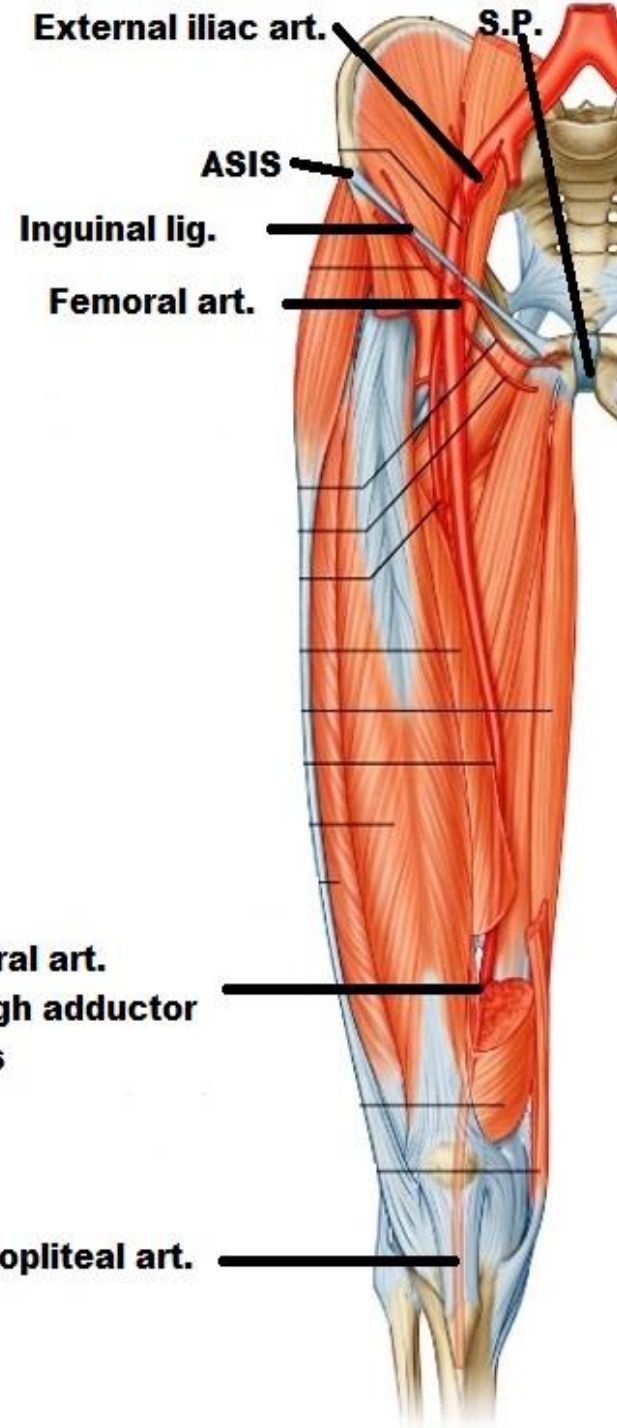
descend vertically

-upper part (superficial) in femoral Δ from base to apex

-lower part (deep) in adductor canal
From upper end to lower end

End: -

at adductor opening (hiatus) to continue as popliteal art.



FEMORAL ARTERY

Relations:

medial: Femoral V.

Lateral:- Femoral n.

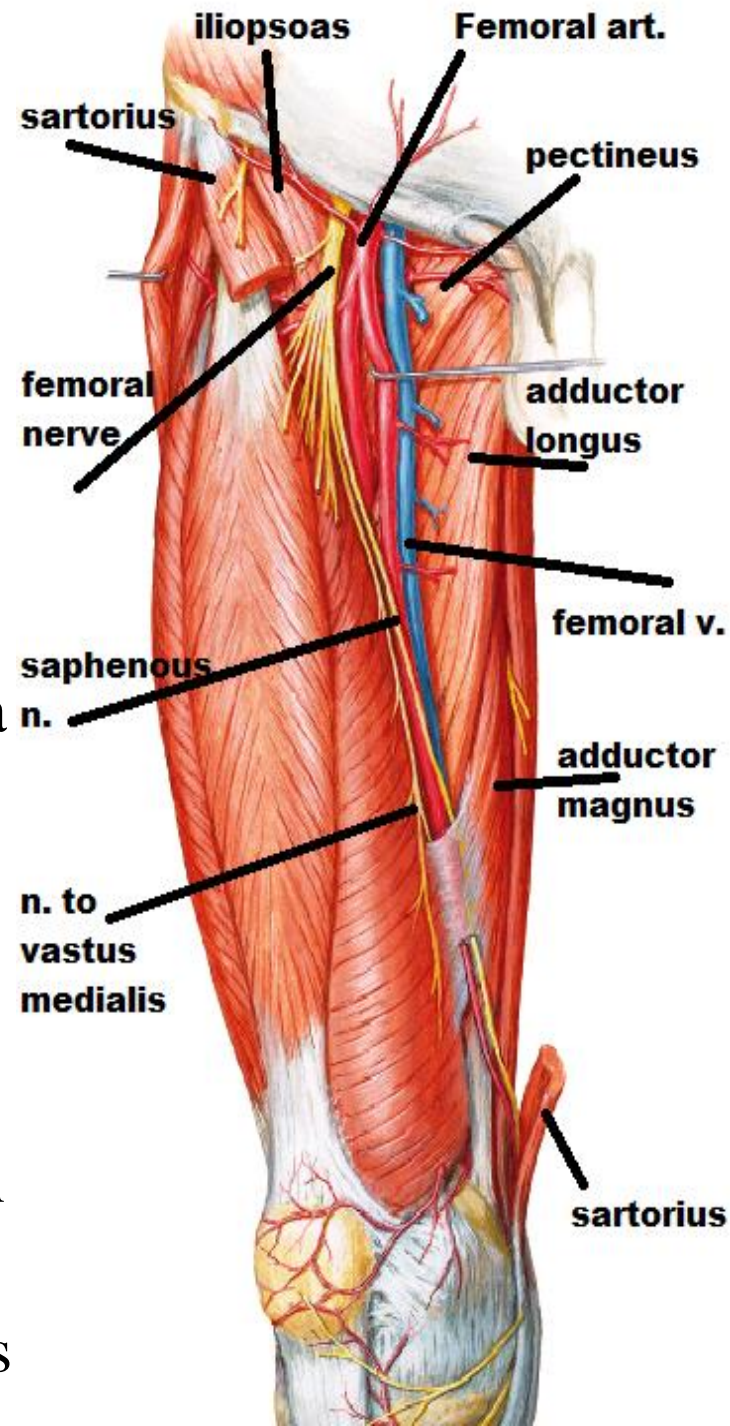
- saphenous n.,
- nerve to vastus medialis

superficial (ant.) -skin

- superficial fascia
- deep fascia
- Sartorius

deep (post.)

- iliopsoas separates it from hip joint
- pectineus: with profunda femoris in between
- adductor longus -Adductor magnus



FEMORAL ARTERY

Branches :

Superficial brs:(Superf. inguinal arteries)

1-superficial circumflex iliac :

to anastomose around ASIS

2-superficial epigastric :

cross the inguinal ligament to enter the ant. abd. Wall till umbilicus

3-superficial ext. pudendal :

to ext. genitalia (scrotum or labia majora)

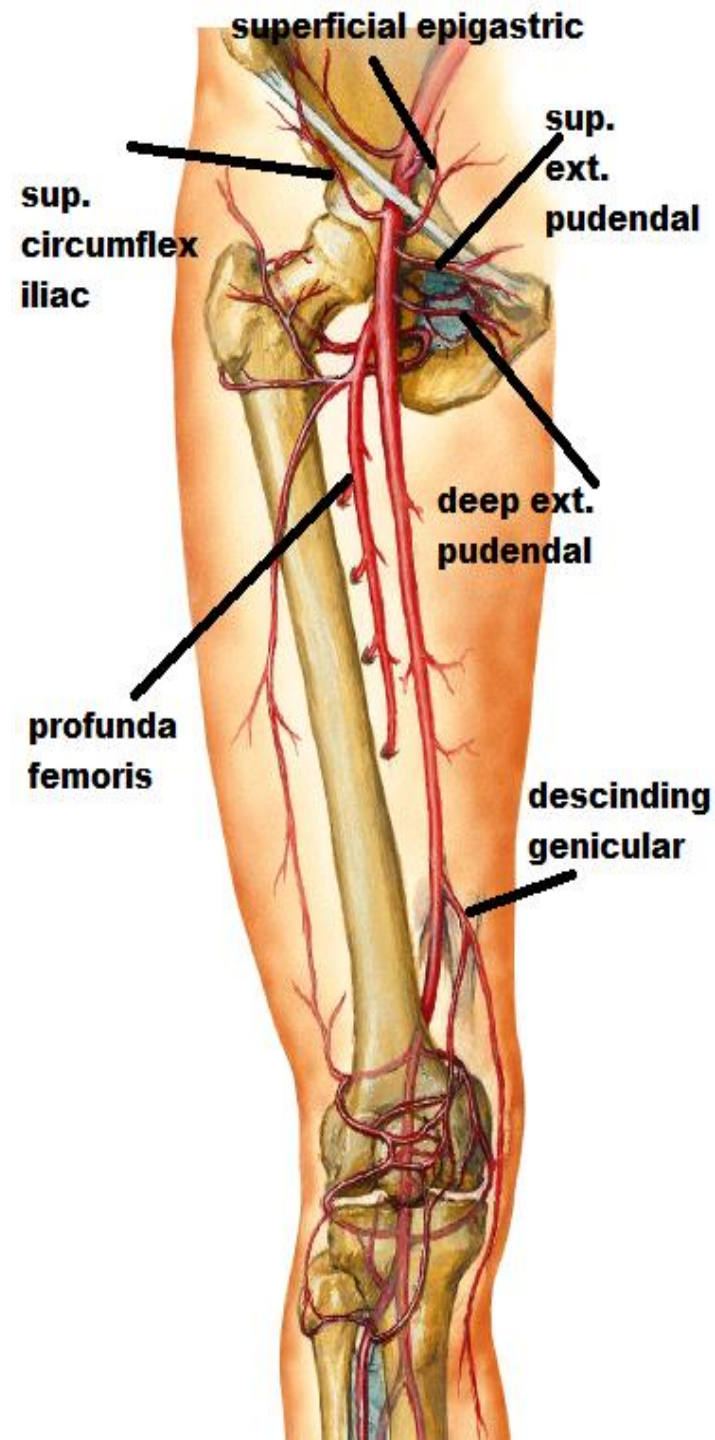
Deep brs:

4-deep ext. pudendal :

To ext. genitalia

5-descending genicular :

Only br. of femoral art. Inside adductor canal.it ends by sharing in anastomosis around knee



FEMORAL ARTERY

Branches :

Deep brs:

6-Profunda femoris art (the art. To thigh)

O.:- lateral side of femoral art

4 cm below ing. lig.

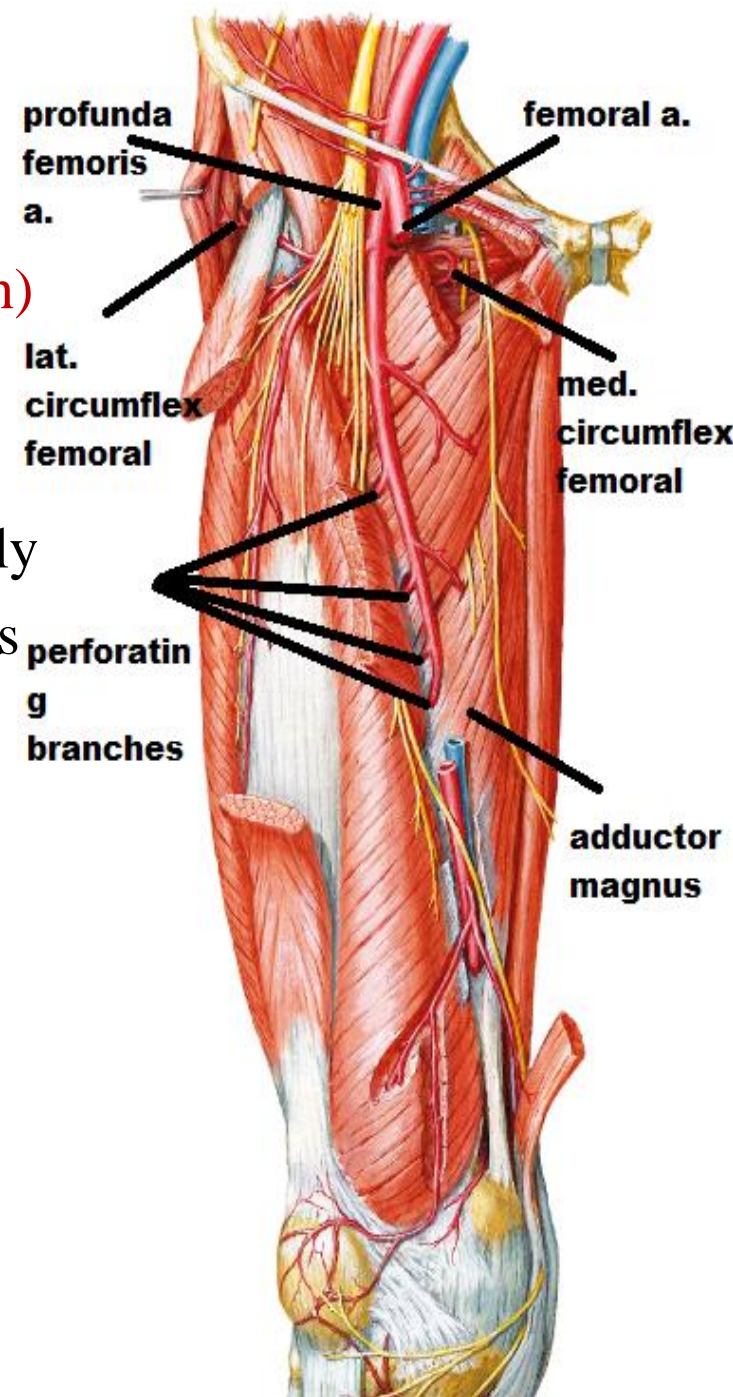
C & R:- -descend downward & medially

() femoral vessels & pectineus

- () adductor longus & brevis

- then on adductor magnus

E: perforate adductor magnus near its insertion as the 4th perforating art.



FEMORAL ARTERY

Branches :

Deep brs:

6-Profunda femoris art (the art. To thigh)

Branches :

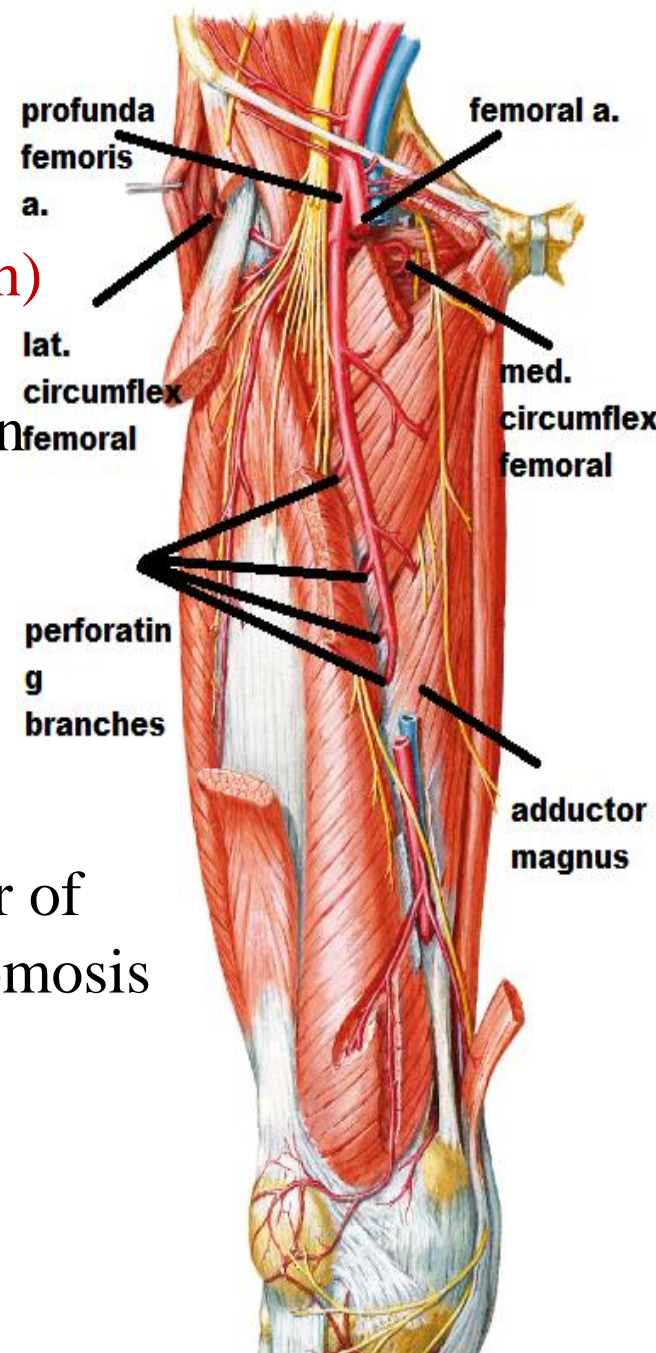
lateral circumflex femoral:- at the origin

•give : 3 brs :

-**ascending** :ascend to anastomosis
around ASIS

-**transverse**: circle around femur
to cruciate anastomosis.

-**descending**: descend along ant. border of
vastus lateralis to anastomosis
around knee



FEMORAL ARTERY

Branches :

Deep brs:

6-Profunda femoris art (the art. To thigh)

Branches :

medial circumflex femoral:-at the origin

•give 3 brs :

-**acetabular** :

-**ascending** : to trochanteric anastomosis:

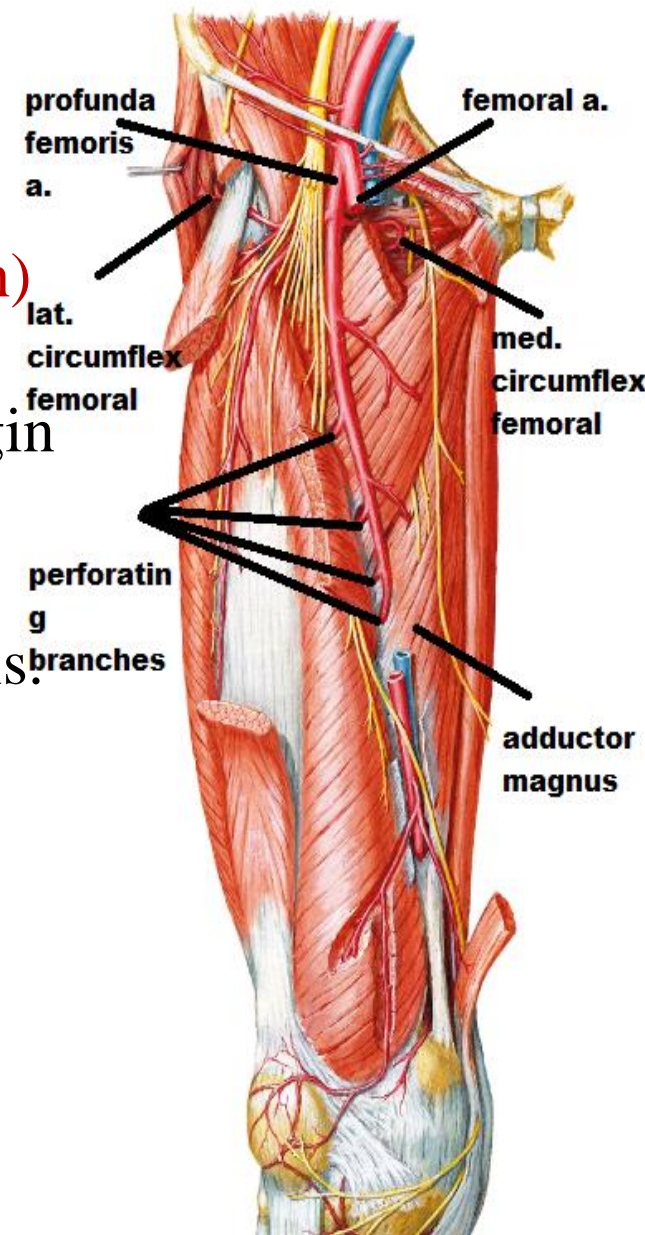
-**transverse** : to cruciate anastomosis.

3perforating branches:

Perforate insertion of adductor magnus

The perforating arteries

form longitudinal chain anastomosis to supply back of thigh



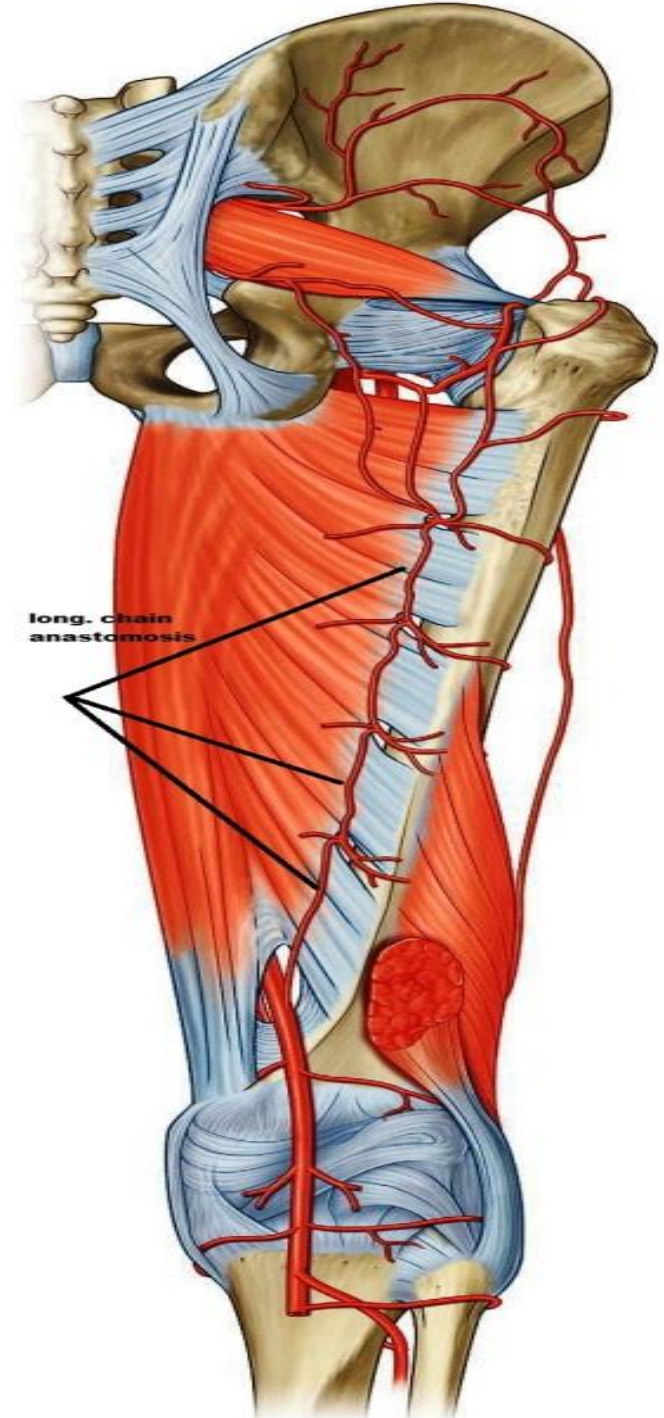
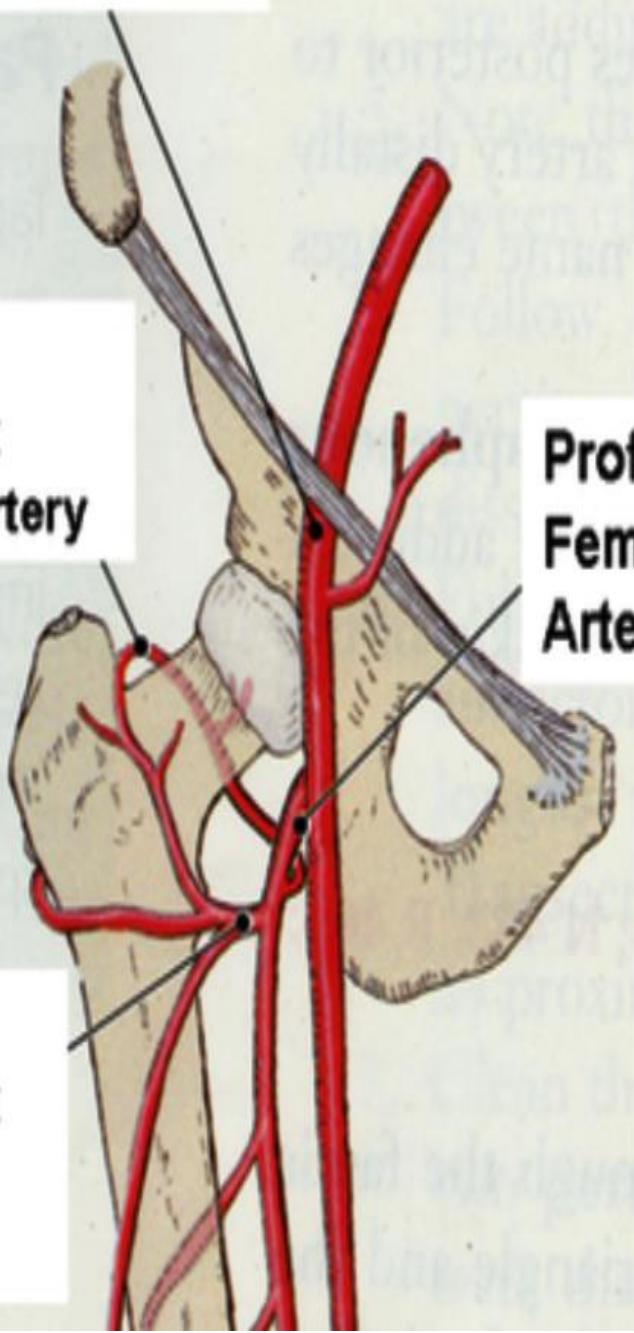
Femoral Artery

Medial Circumflex Femoral Artery

Lateral Circumflex Femoral Artery

Profunda Femoris Artery

long. Chain anastomosis



FEMORAL ARTERY

Trochanteric anastomosis

-It is the main blood supply to the head of the femur

-formed by Superior, inferior gluteal arteries &

Medial, lateral circumflex femoral arteries

cruciate anastomosis

-Between internal iliac & femoral

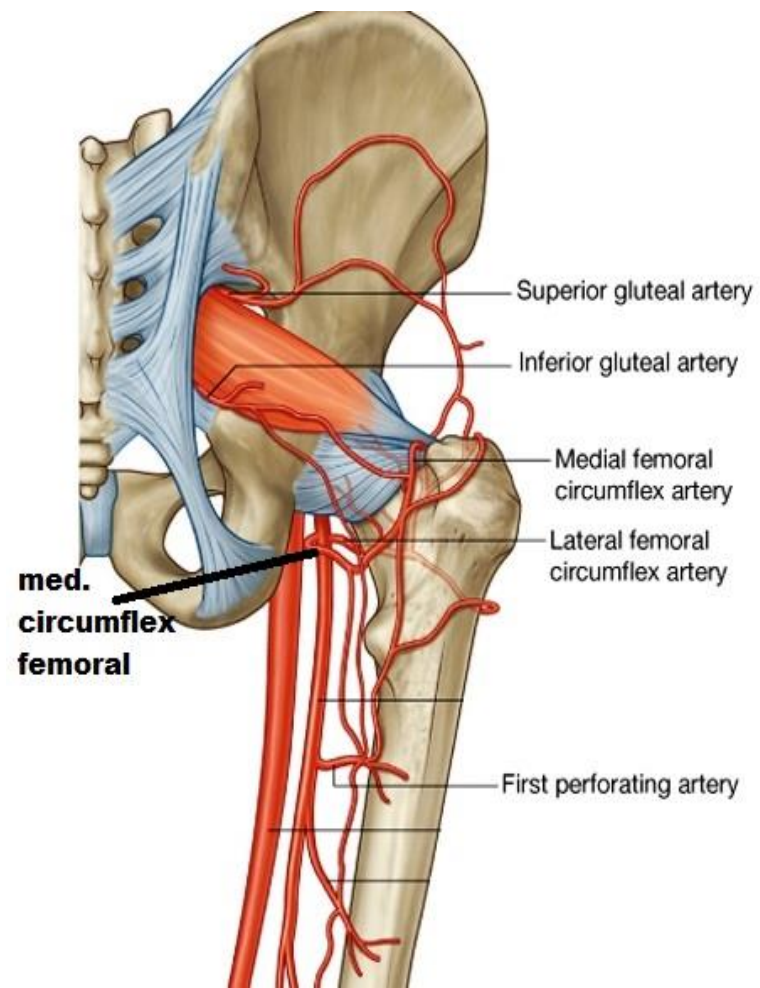
-formed by

1-1st perforator of profunda

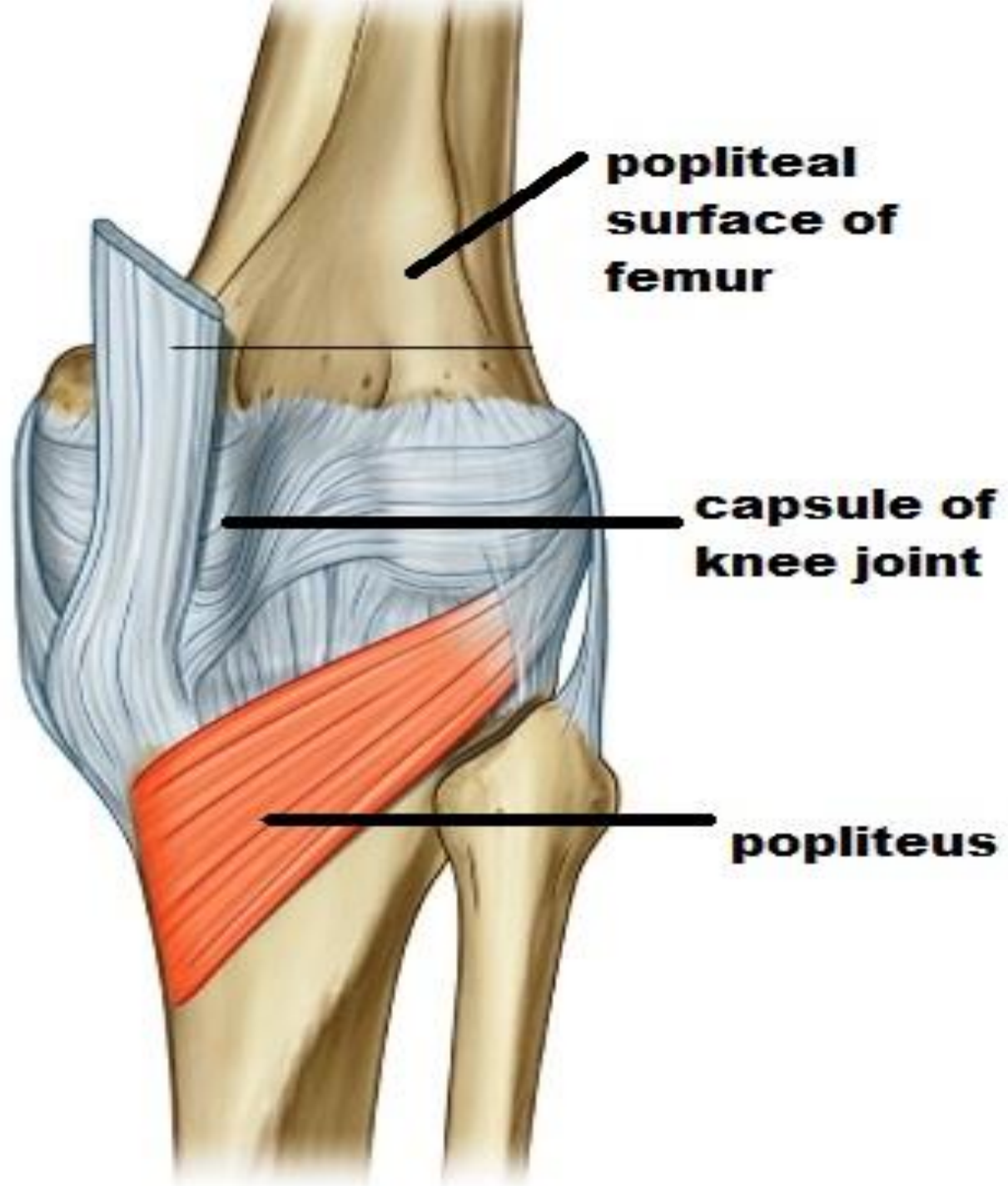
2-inferior gluteal

3-Medial circumflex femoral

4-lateral circumflex femoral

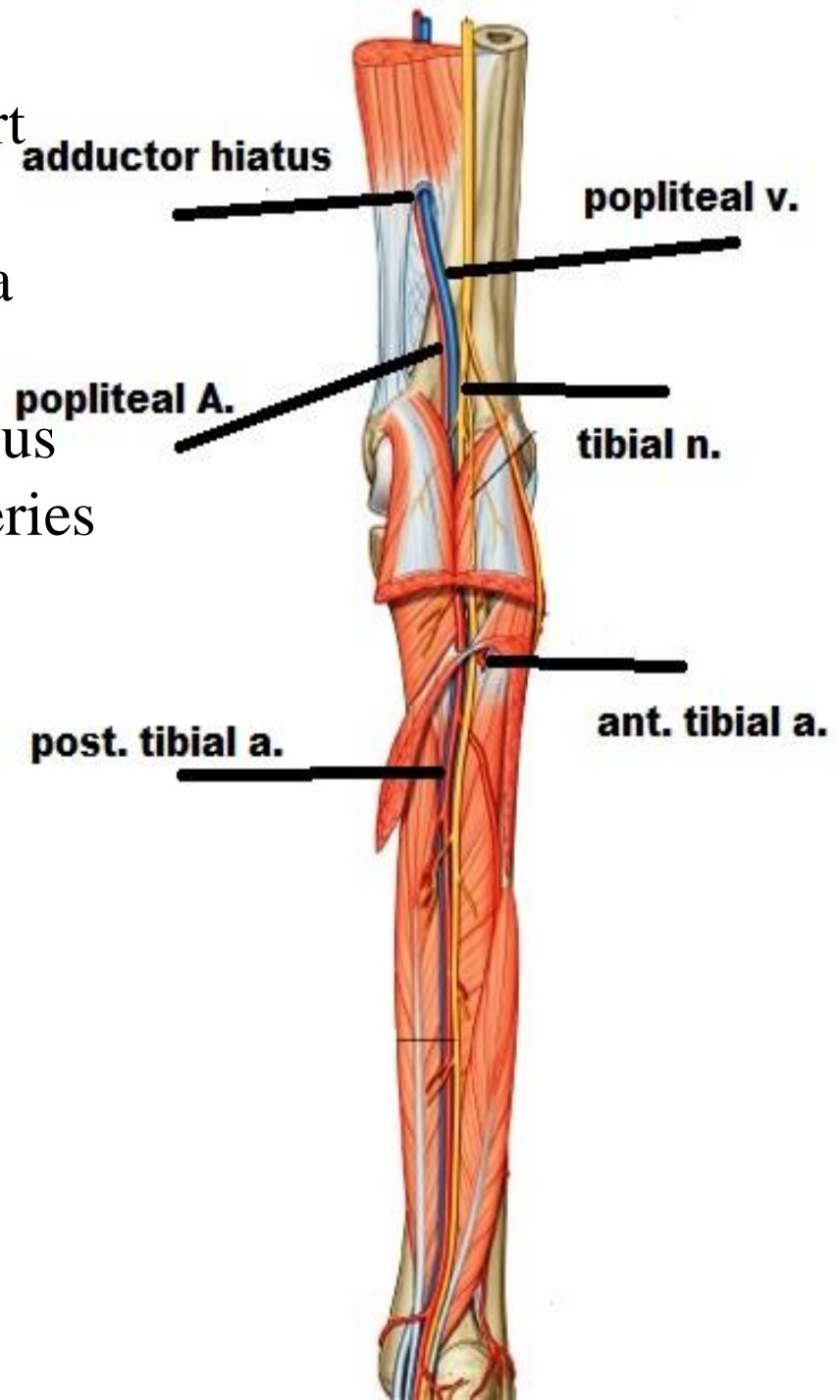


REV.



POPLITEAL ARTERY

- O** : -continuation of femoral art
-at adductor opening
- C.** : descends in popliteal fossa
as deepest structure
- E.** : -at lower border of popliteus
-give ant. & post tibial arteries
- R.:**
crossing over
popliteal surface of femur
capsule of knee joint
popliteus muscle
- crossed superficially by
popliteal v & tibial n
fasciae & skin
-separated from the tibial n
by popliteal v



POPLITEAL ARTERY

branches :

A-muscular brs : to near muscles

B-genicular brs : 5

superomedial , superoLateral

inferomedial , inferolateral

middle

they share in anastomosis

around knee joint

anastomosis around knee

descending genicular (femoral)

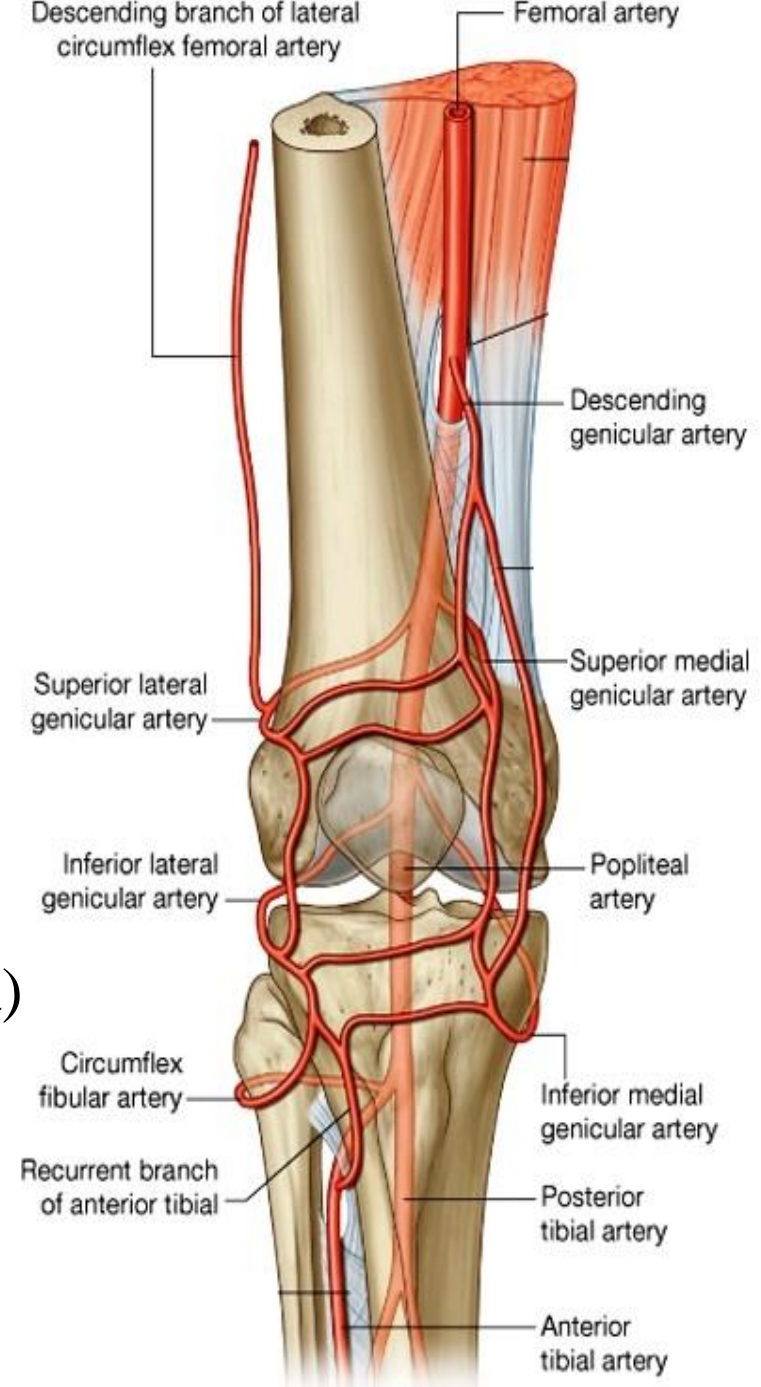
br of lateral cir femoral (profunda)

5 genicular branches (popliteal)

ant. & post. tibial recurrent

(ant. tibial)

circumflex fibular (post. tibial)





THANQ