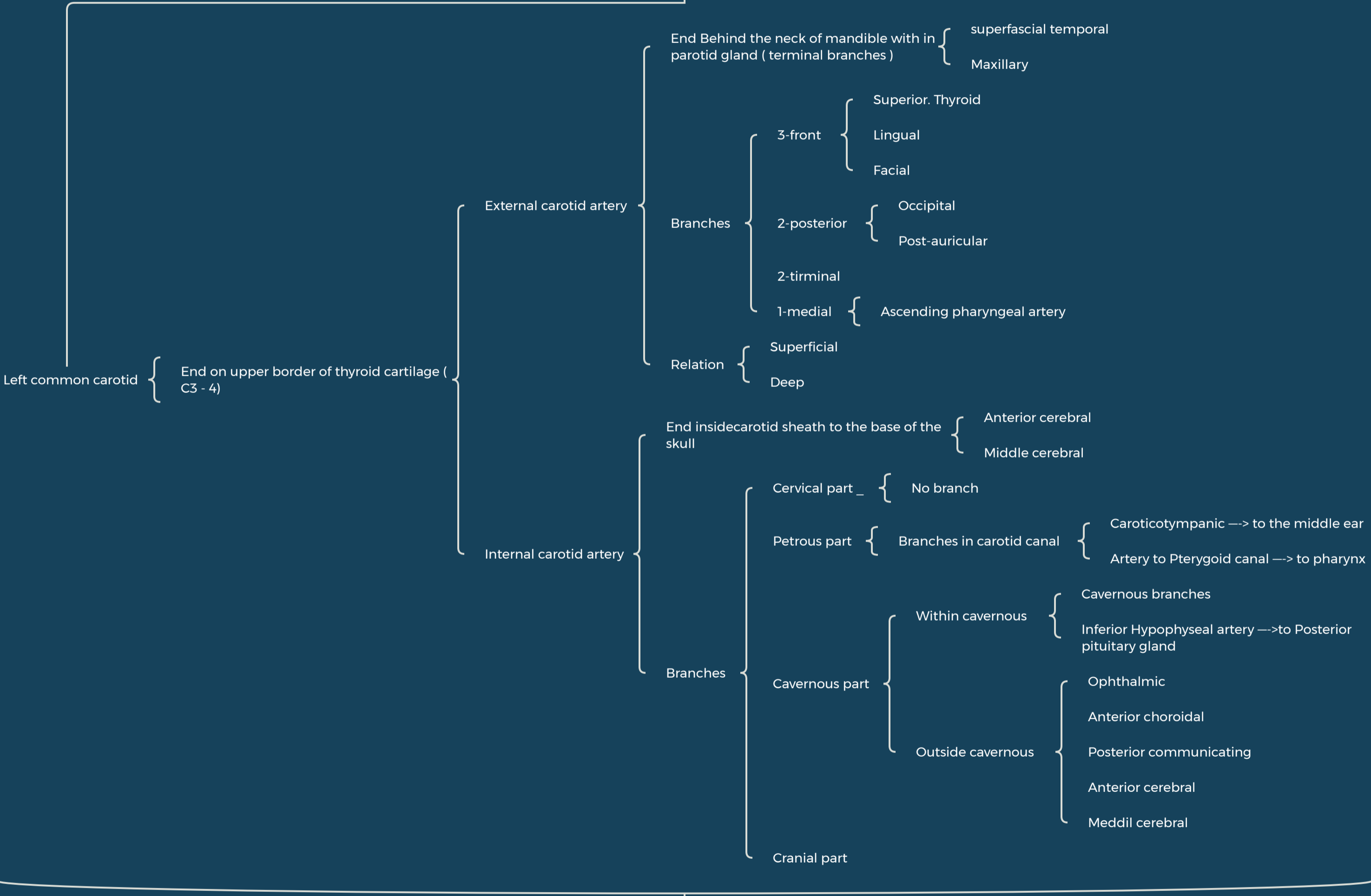


The Arteries of the head and neck

Arch of Aorta

Brachio cephalic

Right common carotid Right subclavian



Anastomosis between ECA&ICA

Occipital A. ECA & Post. Cerebral A. ICA

Angular A. ECA & Ophthalmic A ICA

Middle Meningeal Artery ECA & Ant. Cerebral A. ICA

Superficial Temporal A, ECA & Supra trochlear and Supra orbital A. of ICA

