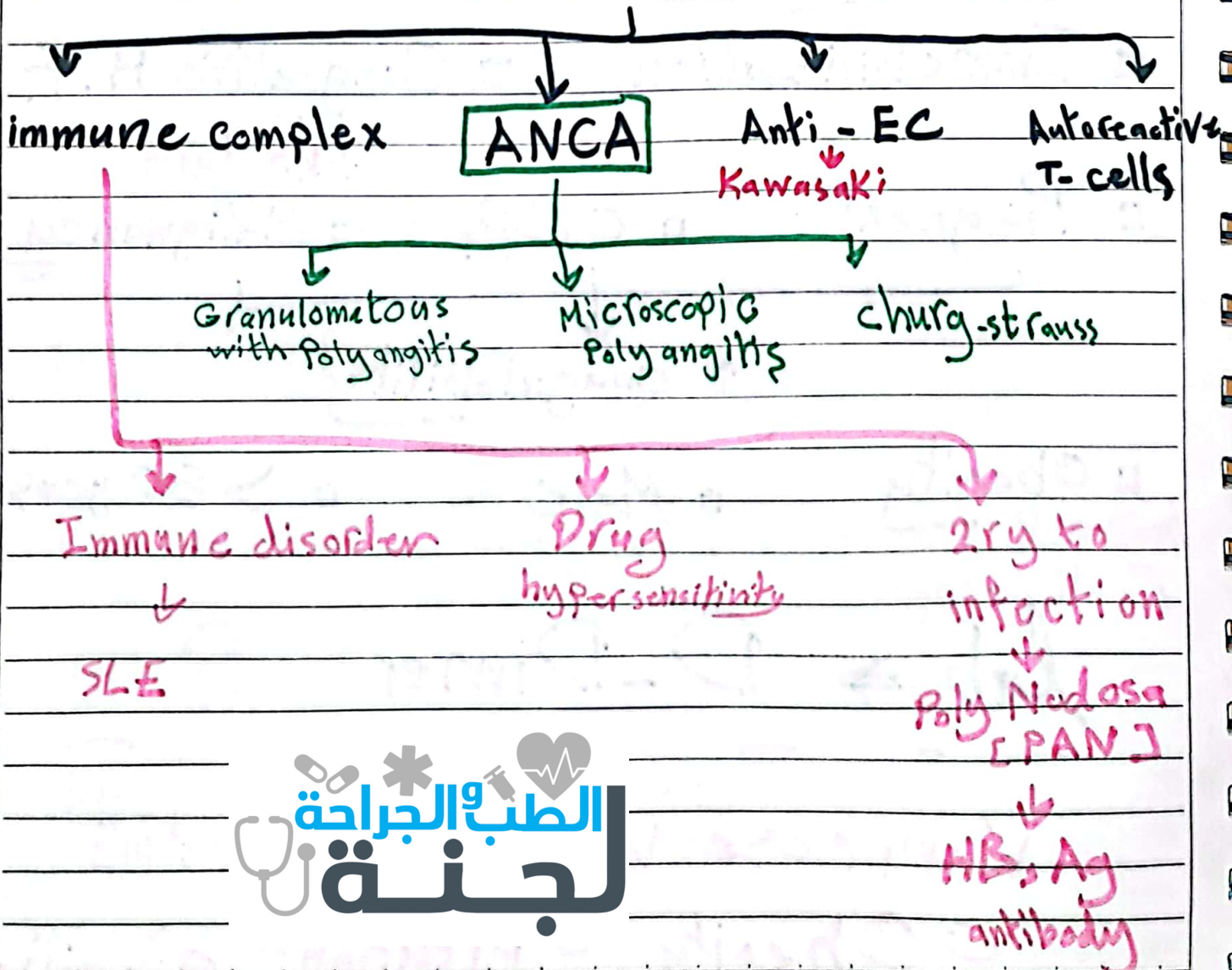


Vasculitis :

| Large vessels | Medium | small |
|----------------------------|------------|---|
| → Giant cell | → Kawasaki | Churg Strauss ^{asthma, Eosino} |
| → Takayasu هجوم العالقة | → PANodosa | Granulomas with Polyangitis |
| | | Microscopic Polyangitis |

Non infectious vasculitis



ANCA : autoantibody

against Neutrophils 1ry Granules
or Monocyte lysosomes

CANCA [PR3]

→ Granulomatosis with
Polyangiitis □
→ Against Neutrophilic granules

P-ANCA [MPO]

→ Microscopic Polyangiitis □
→ Churg-Strauss □
→ Against MPO
on monocyte
lysosomes

NO Immune Comp. Circulating
" Pauci immune "

Giant cell arteritis [Temporal]

△ Old adult >50 Left or
right

△ Granulomatous inflammation

△ [Temporal, vertebral, Ophthalmic]

△ T-cell mediated {mechanism}

△ clinically: Facial pain & Headache
Diplopia

△ Diagnosis: biopsy from Temporal vessel

△ Transmural inflammation

△ Disrupted Internal Elastic Lamina



inflammation

Takayasu [Pulseless disease]

△ Granulomatous inflammation

△ Ocular disturbance + weak pulses to upper limbs

△ Transmural

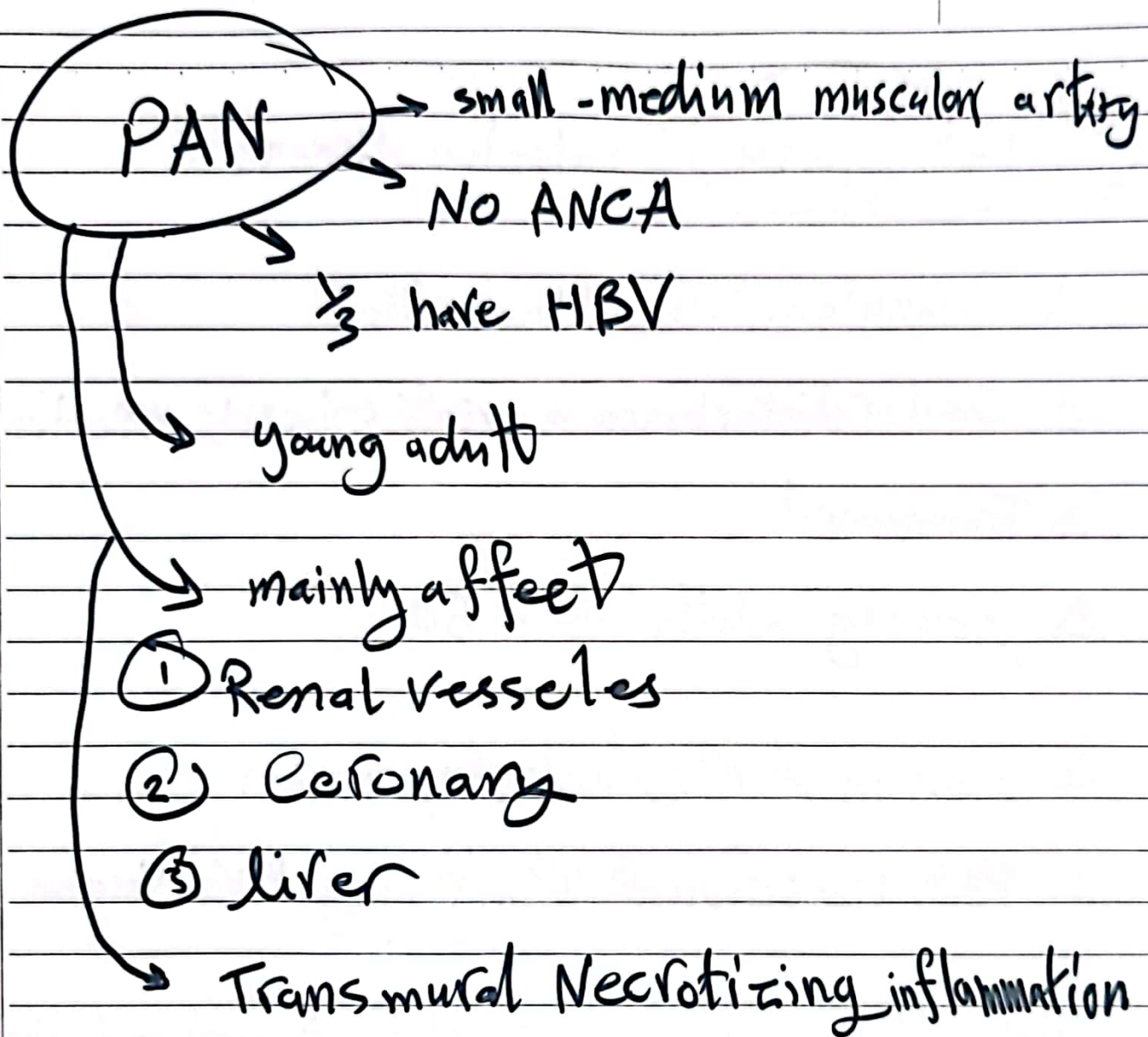
△ young adults < 50

△ seen in Aortic Arch Angiogram

△ Perivascular cuffing & Vas Vasorum

clinically: ↓ Pulse & BP to upper limbs





Kawasaki

- childhood < 4 years
- Triggered by [Mostly Viral infection]
- B-cell activation → Auto antibodies to EC, & SMC,

Anti-EC

clinically: Red eye, swollen L.N, Peeling skin!

Cracked lips, Rash

Coronary artery Aneurysms



lead to Thrombus, MI

Microscopic Polyangitis [Leukocytoclastic]

- affect capillary
- Immune-complex deposition

→ seen in: Henoch-Schonlen Purpura

- Involve Kidney - Lung

clinically: Palpable Purpura

Granulomatosis with Polyangitis

Triad

↑ sinusitis, Nose ulcer

→ Necrotizing Granuloma of URT or LRT

↓ nodules

→ Necrotizing or Granulomatous Vasculitis

→ **Focal Necrotizing "crescentic"**
glomerulonephritis ↑

↑ لازم تلاقي هذه العلاجات الثلاث ↑

so clinically :

Lung Nodules , Sinusitis

mucosal ulceration , Renal disease

Churg - Strauss syn.

→ small vessel

→ p-ANCA

→ Asthma + Rhinitis + Eosinophilia

→ [Palpable Purpura, glomerulo sclerosis]

→ Allergy



"لا يوجد في
هذه الحياة
كلمة أكثر رافة
ورحمة من كلمة
-يارب- ونبرة
الالتجاء
المصاحبة لها..
أن تترك العالم
كله، وتبتعد عن
الأهل والصحب،
وتنادي -يارب-،
بيقين أنه
يسمعك ويفهم
كل ما تخبئه وراء
هذه الكلمة..
الحمد لله
الرؤوف الرحيم."

يارب