

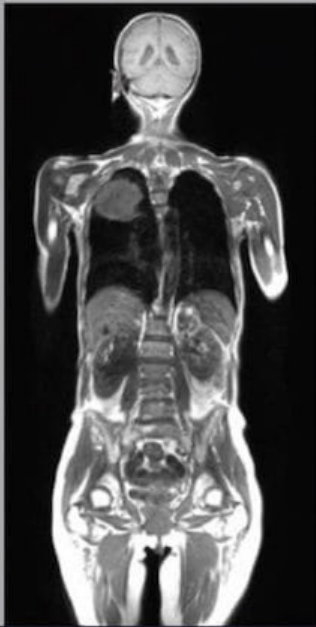
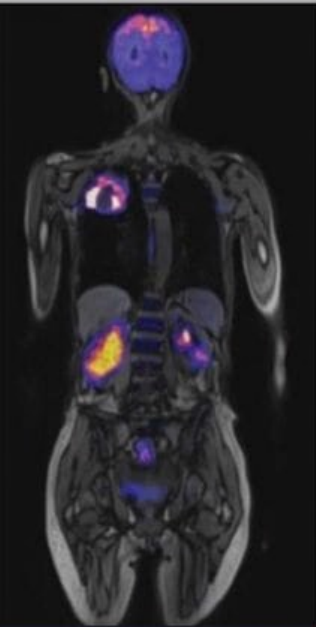
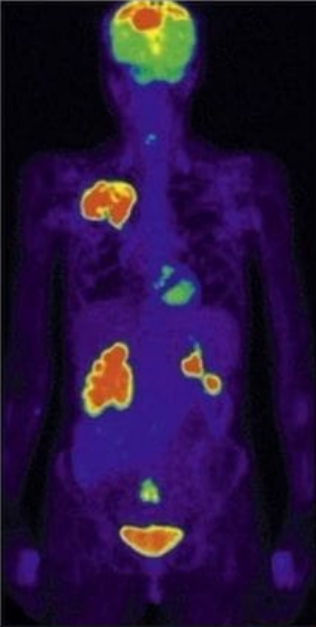
WHAT IS NUCLEAR MEDICINE

نظائري isotopes
نتيجة المسارح النووية
تنتج عن طريق...

- Nuclear medicine is the branch of medicine that uses radionuclides in medicine for diagnosis, staging of disease, therapy and monitoring the response of a disease process. It is also used in the basic sciences such as biology, in drug discovery and in pre-clinical medicine.
- DIAGNOSTIC nuclear medicine involves the use of radioactive tracers to image and/or measure the global or regional function of an organ.
- The radioactive tracer (radiopharmaceutical) is given to the patient by intravenous injection, orally or by other routes depending on the organ and the function to be studied. The uptake, turnover and/or excretion of the tracer substance is then studied with a gamma camera, positron emission tomography (PET) camera or another instrument, such as a simple stationary radiation detector. The uptake of the tracer is generally a measure of the organ function or metabolism or the organ blood flow.

* نظائري صناعية ← نوى العنصر - بس الا أكثر من شكل مختلف جدر

النيوترونات أو اللامبات النووية

	MRI	CT	PET
BOOKMERILAB.COM			
Tech	Magnets + radio waves	X-rays (3D)	Radiation traces with CT Scan
Detect	Soft Tissue, Tendon, Ligament, Brain	Bony structure and blood vessels	Cancer, Heart, Brain
Procedure Time	30 min	5 - 10 Min	60 - 90 Min

سکائیز

PET-CT

PET-MRI

WHAT IS NUCLEAR MEDICINE

- **THERAPY** using unsealed radioactive sources includes treatment of the **thyroid** (hyperthyroidism and thyroid cancer) using radioactive iodine, pain palliation of **bone** metastasis using radioactive bone seeking agents and others. Research is under way to develop new radiopharmaceuticals to treat different tumours. This section provides you with the information about basic safety considerations for both general and specific therapy.
- Since nuclear medicine involves exposure of patients, the general principles of **radiation protection** should be applied.

عن

A BIT OF HISTORY....

- **Radioactivity was discovered by Henri Becquerel in 1896, whilst investigating phosphorescence in uranium salts. Following the work of Röntgen, Becquerel wrapped a fluorescent substance, potassium uranyl sulphate, in photographic plates and black material in preparation for an experiment, but prior to actually performing the experiment, Becquerel found that the plates were fully exposed. This led Becquerel to investigate nuclear radiations, and in 1903 he shared the Nobel Prize for physics with the Curies**

A BIT OF HISTORY....

- **Nuclear medicine first became recognized as a potential medical specialty in 1946. Nuclear medicine began more than 70 years ago and is now a vital medical specialty for both diagnosis and therapy of serious disease. During the mid 1960s, the use of nuclear medicine as a specialty discipline began to see exciting growth with significant advances in nuclear medicine technology. Today, there are approximately 100 different nuclear medicine imaging procedures are in use and Nuclear medicine is now an integral part of patient care and is extremely valuable in the early diagnosis, treatment and prevention of numerous medical conditions.**

* radioactive ← هو اذیون (نوی) بعالج (cancer)

RADIOISOTOPES AND RADIOPHARMACEUTICALS


Nuclear medicine
Radio-logy
عنوان کی حیاتیہ استعمال میں جان الا سہلہ بسکی کام. سواد

- ❖ **RADIOISOTOPES** are the unstable form of an element that emits radiation to become a more stable form — they have certain special attributes. These make radioisotopes useful in areas such as medicine, where they are used to develop radiopharmaceuticals, as well as many other industrial applications.
- Radioisotopes can occur naturally or be produced artificially, mainly in research reactors and accelerators.
- The most common radioisotope used in diagnosis is **technetium-99 (Tc-99)**, with some 40 million procedures per year, accounting for about 80% of all nuclear medicine procedures and 85% of diagnostic scans in nuclear medicine worldwide.

They are used in various fields, including nuclear medicine, where radiopharmaceuticals play a major role.

RADIOISOTOPES AND **RADIOPHARMACEUTICALS**

- ❖ **RADIOPHARMACEUTICALS** are substances that contain a radioisotope, and have properties that make them effective markers in medical diagnostic or therapeutic procedures. The chemical presence of radiopharmaceuticals can relay detailed information to medical professionals that can help in diagnoses and treatments.
- ❖ Globally, the number of medical procedures involving the use of radioisotopes is growing, with an increasing emphasis on radionuclide therapy using radiopharmaceuticals for the treatment of cancer.

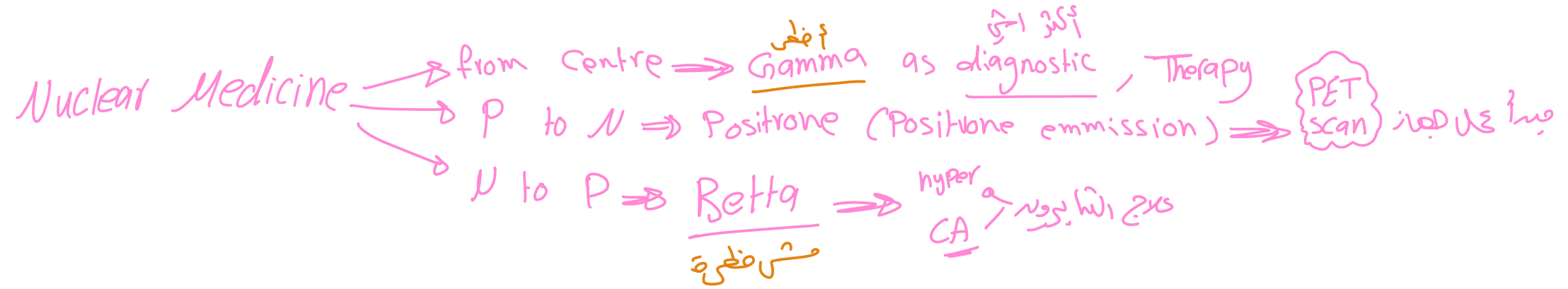


NUCLEAR MEDICINE VS. OTHER SCAN-TECHNIQUES

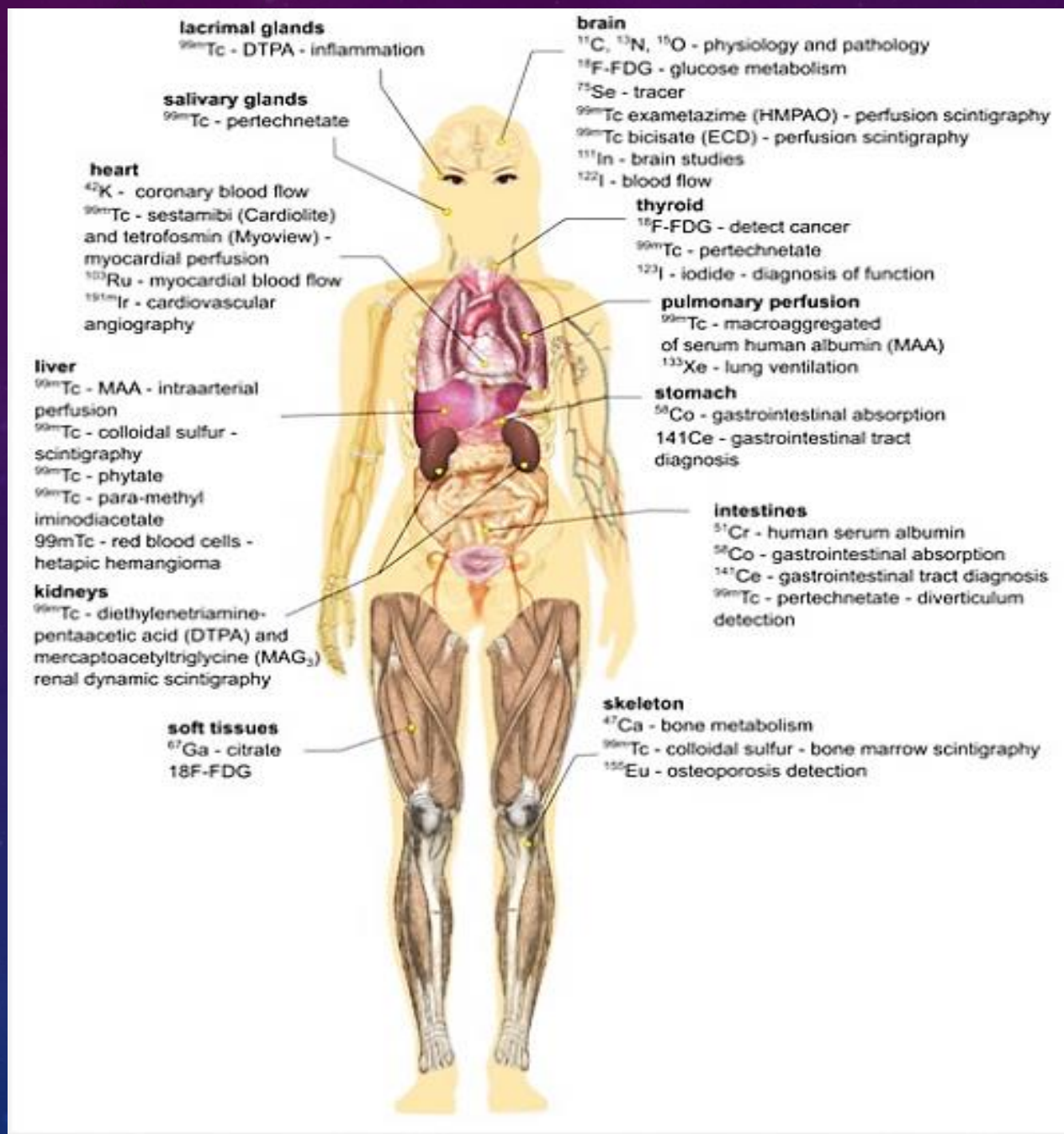
- POSITIONING OF THE RADIATION SOURCE WITHIN (RATHER THAN EXTERNAL TO) THE BODY IS THE FUNDAMENTAL DIFFERENCE BETWEEN NUCLEAR MEDICINE IMAGING AND OTHER IMAGING TECHNIQUES .
- Diagnostic techniques in nuclear medicine use radioactive tracers which emit GAMMA RAYS from within the body. Gamma imaging by either method described provides a view of the position and concentration of the radioisotope within the body. Organ malfunction can be indicated if the isotope is either partially taken up in the organ (cold spot), or taken up in excess (hot spot). If a series of images is taken over a period of time, an unusual pattern or rate of isotope movement could indicate malfunction in the organ.
- A distinct advantage of nuclear imaging over X-ray techniques is that both bone and soft tissue can be imaged very successfully. This has led to its common use in developed countries where the probability of anyone having such a test is about one in two and rising.

X-Ray → العلاقة الإلكترونية في الحارات

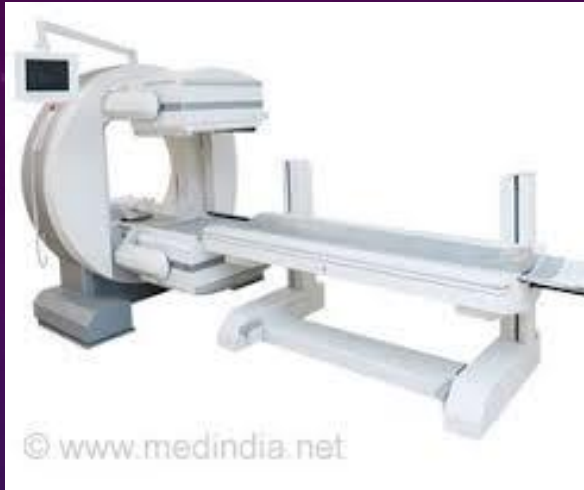(radiology)



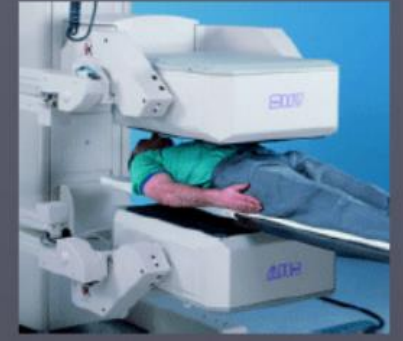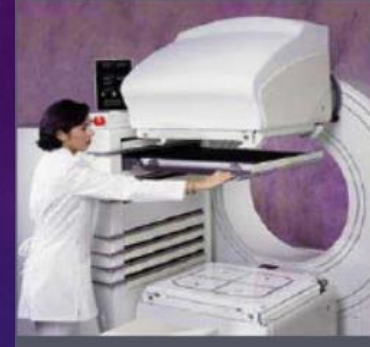- Every organ in the body acts differently from a chemical point of view. Doctors and chemists have identified a number of chemicals which are absorbed by specific organs.
- The thyroid, for example, takes up iodine,
- whilst the brain consumes quantities of glucose.
- With this knowledge, radiopharmacists are able to attach various radioisotopes to biologically active substances. Once a radioactive form of one of these substances enters the body, it is incorporated into the normal biological processes and excreted in the usual ways.
- Diagnostic radiopharmaceuticals can be used to examine blood flow to the brain, functioning of the liver, lungs, heart, or kidneys, to assess bone growth, and to confirm other diagnostic procedures. Another important use is to predict the effects of surgery and assess changes since treatment.



Single-photon emission computed tomography (SPECT)



Scintigraphy (SPECT): imaging device



Nuclear Medicine Imaging Devices

PET scanner with
BGO scintillation
detector modules



NUCLEAR MEDICINE IMAGING DEVICES

Major imaging systems categories

GAMMA CAMERA SYSTEMS

- ❑ Planar gamma cameras (2-D images)
- ❑ Single photon emission computed tomographic systems
 - SPECT (3-D images) *360° rev.*

POSITRON EMISSION TOMOGRAPHY SYSTEMS

- ❑ Tomographic systems
 - PET (3-D images)

MULTIMODALITY SYSTEMS

- ❖ SPECT/CT
- ❖ PET/CT

The CT images provide an anatomical reference frame for the functional images and allow for attenuation correction

NUCLEAR MEDICINE EXAMINATIONS ARE PERFORMED USING GAMMA CAMERA

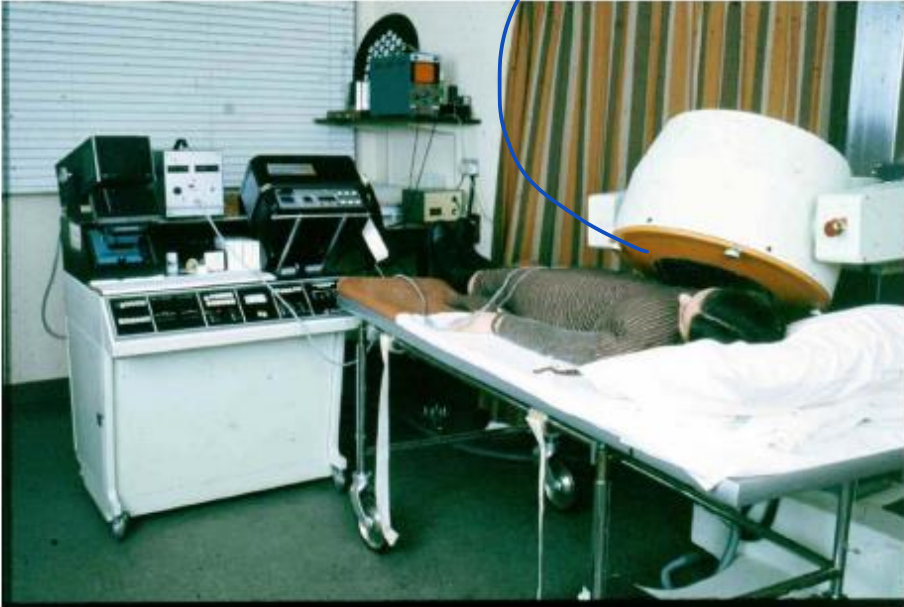- **The first scintillation camera was developed by Hal Anger in 1958.**
- **📖 principles of the Anger camera are still used in modern gamma cameras**



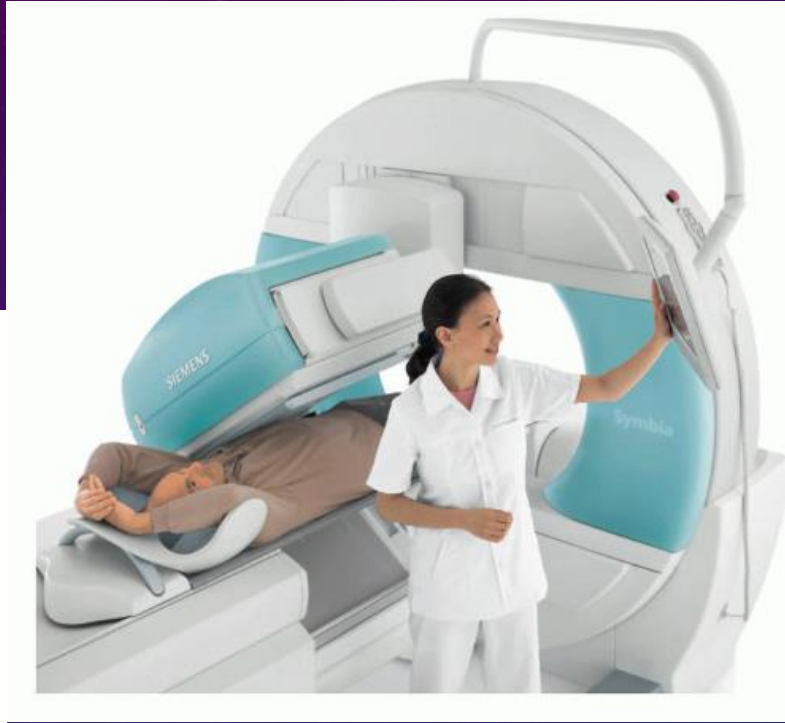Hal Anger with his invention

GAMMA CAMERA

الكاميرا الحثوية



Gamma camera 1973



الكاميرا الحثوية

iodide sodium + barium

crystals

→ less thickness in CT scan
(high radiation)

--- CT scan) | no Si

→ thickness
gamma Si no

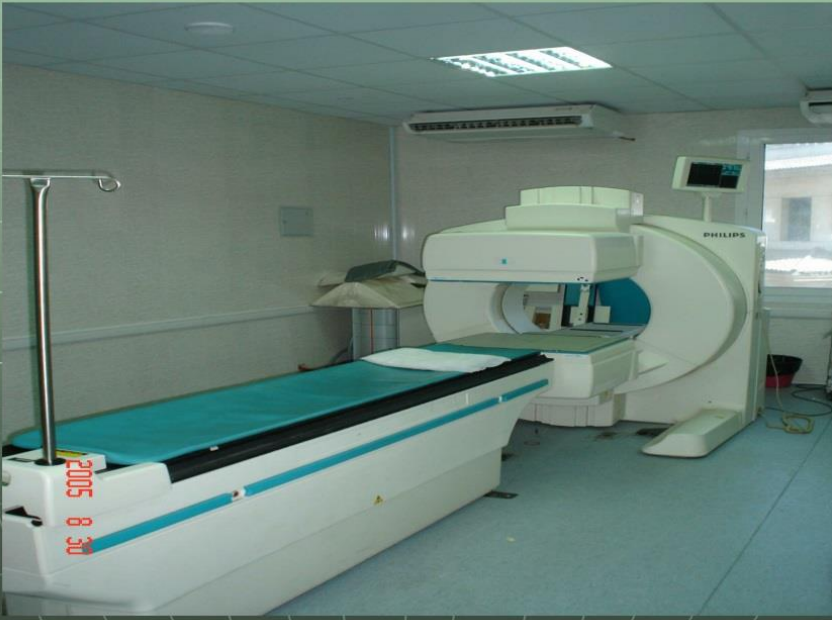in PET scan

511

X-ray less

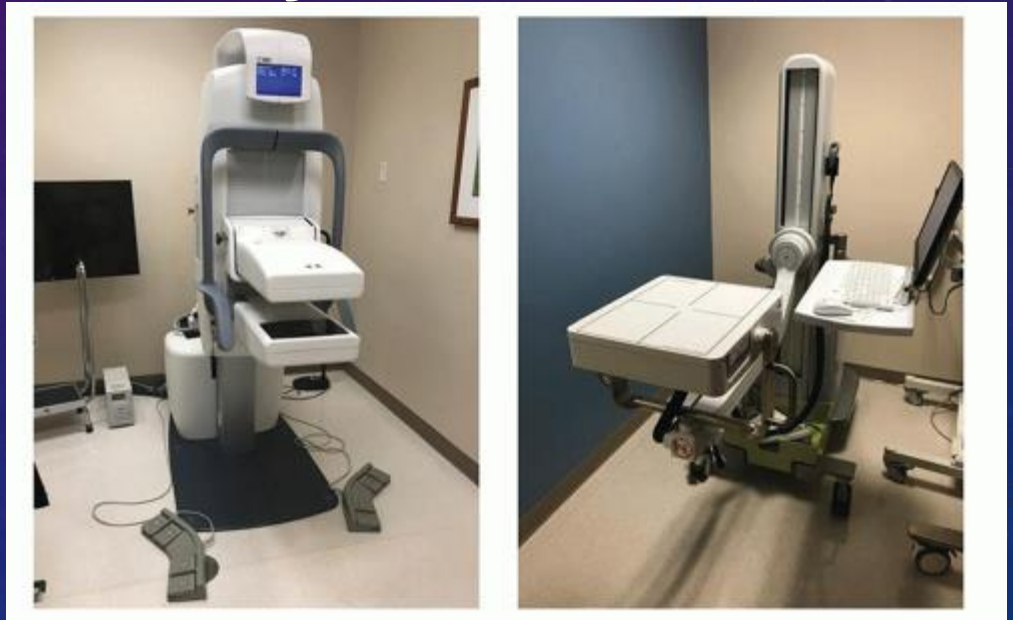Uranium or أي ايزوتوب مشع \Rightarrow after 10-half life \Rightarrow safety

Gamma Camera

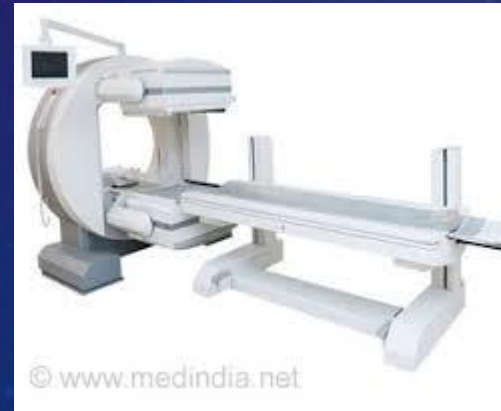

* Tc-99 (half-life 6 hours) $\Rightarrow 6 \times 10 = \underline{\underline{60}}$
نيز مشع (Metastable)

بفترة القامة
الوقتية ويجوز
isotope
نيز مشع



Modern multielement gamma cameras.
GE NM 750b molecular breast imager (left)
and Digirad Ergo portable (right)



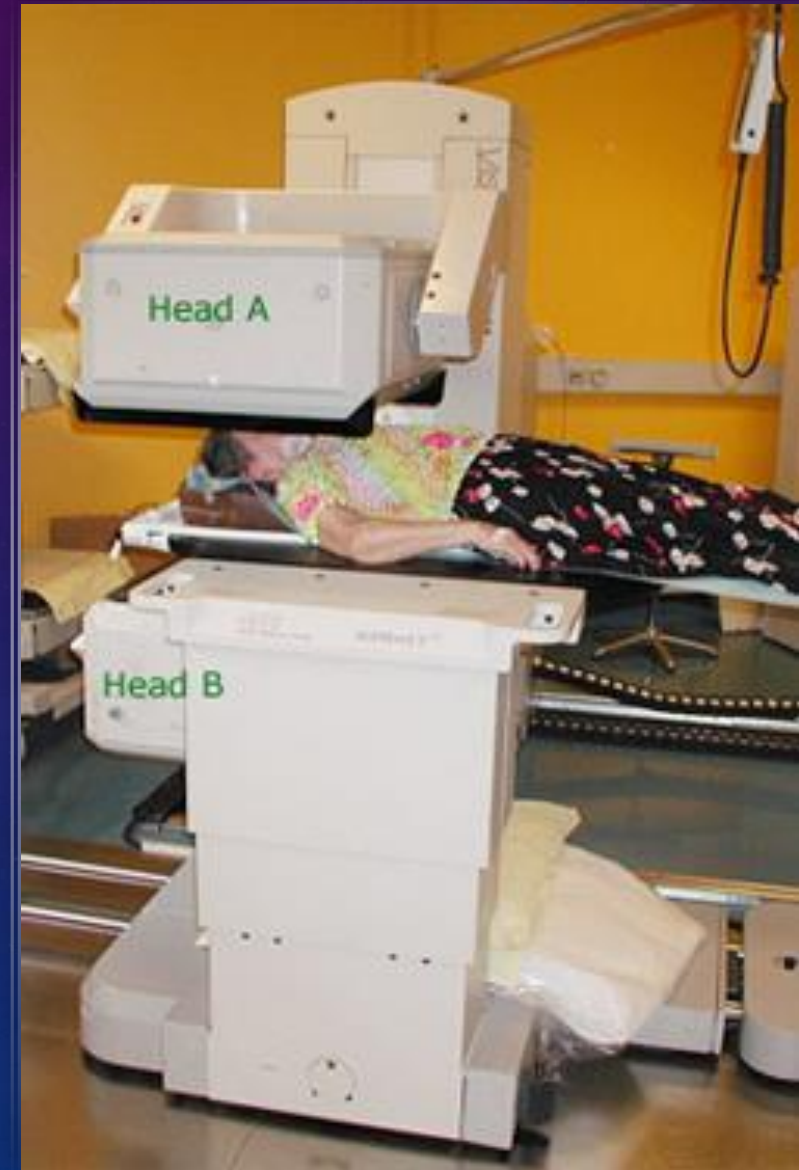© www.medindia.net

Scintillation Gamma camera

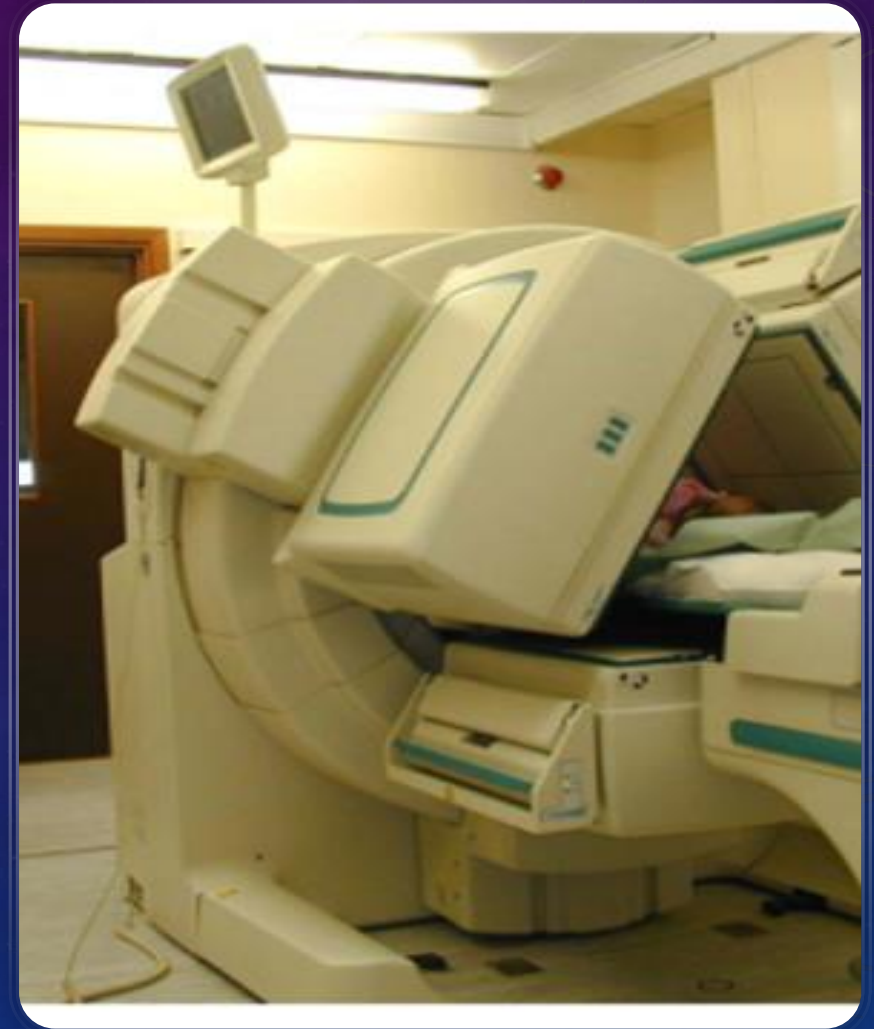DOUBLE-HEADED GAMMA CAMERA

This gamma camera is equipped with two heads capable of detecting the presence of radiation. The lower head is partly concealed under the bed, and the whole apparatus can be moved along horizontally to obtain a full-body scintigraphy.

By doubling the number of gamma rays used, a face scintigraphy can be performed at the same time as a back scintigraphy for the same amount of radioisotope ingested. By comparison with a PET scanner, a gamma camera requires much less equipment and is more easy to set up.



MODERN TRIPLE-HEADED SPECT-CAMERA



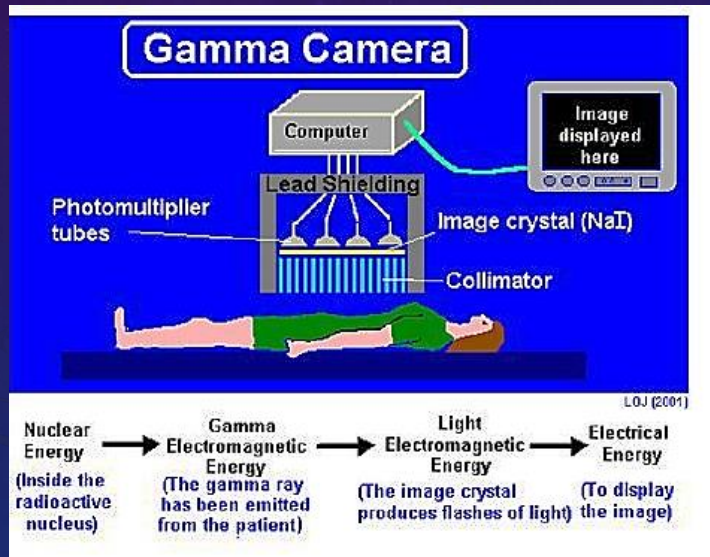
WORKING PRINCIPLE OF GAMMA CAMERA

- A radioactive tracer is injected to the patients body.
- The most commonly used tracer is 'Technetium-99m'.
 - It is a metastable nuclear isomer.
 - It has a relatively long half life of 6 hours.
 - It has ability to be incorporated into a variety of molecules in order to target different systems within the body.

- The tracer emits radiation in all directions as it travels through the patients body.
- The gamma camera gets hit by the gamma rays that emitted.
- Gamma rays pass through the collimator.
- Then the gamma rays hit the scintillator.
- The scintillator absorbs the gamma energy and turns it into multi-photon flashes of light.

- Then light photons are delivered to the PMT.
- At the PMT, the photocathode comprises a photosensitive coating.
- The light photons that penetrate the PMT liberate low-energy (1 eV or less) electrons from the cathode.

- The collected signal is processed in the computer to produce the image.
- The produced image is displayed on the screen.



TYPES OF GAMMA CAMERA'S EXAMINATIONS

د لمرینا کیس میں
دوبیس آرگن لوین

سٹان بومل آر
Maximum conc.

❖ Static study

ex. bone → سکینٹ → diffusion بصری

• Wholebody

ex. thyroid → سکینٹ

• targeted

→ for system سکینٹ

Dynamic renography

❖ Dynamic study.

or functional (function of system سکینٹ)

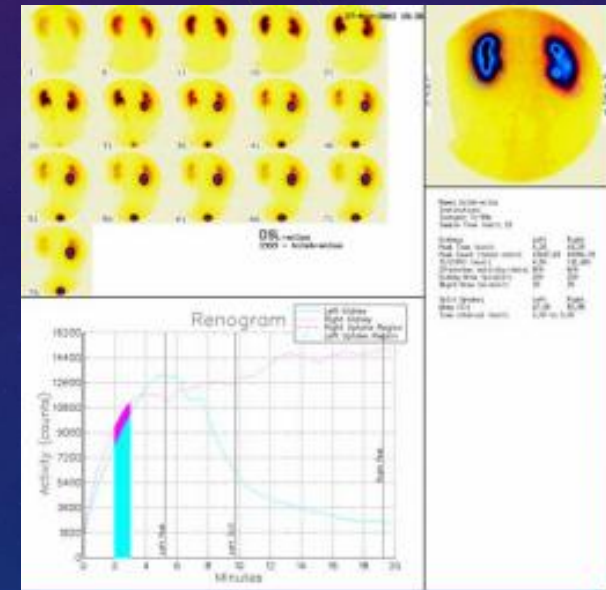
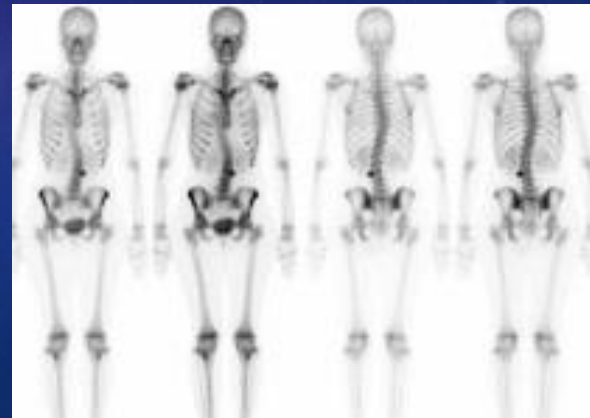
- dynamic
- gated

Bone Scinti

❖ Tomographic study

- SPECT

Gated study

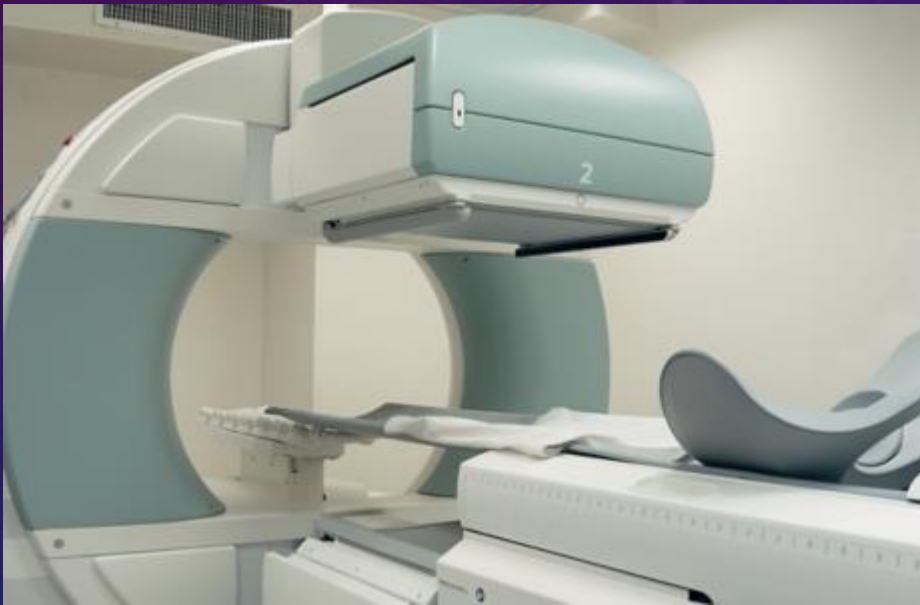

COMMON TYPES OF NUCLEAR MEDICINE PROCEDURES :

- ❖ BONE SCANS—used to assess a joint replacement; detect cancer, fracture, sports injury or tumor; or evaluate unexplained bone pain
- ❖ RENAL SCANS. These are used to examine the kidneys and to find any abnormalities. These include abnormal function or obstruction of the renal blood flow.
- ❖ GASTROINTESTINAL SYSTEM SCANS
 - HEPATOBILIARY (GALLBLADDER) SCAN—used to evaluate gallbladder function
 - GASTRIC EMPTYING EXAM—used to measure how quickly food empties from the stomach; performed when a patient has nausea, abdominal pain, vomiting or diarrhea after eating
- ❖ THYROID SCANS
 - THYROID UPTAKE AND SCAN—provides information about the structure (size, shape, position) and function of the thyroid gland
 - THYROID THERAPY—used to treat hyperthyroidism (overactive thyroid), including Graves' disease; also used to treat thyroid cancer
- ❖ HEART SCANS *infarction, ischemia*
- ❖ BRAIN SCANS
- ❖ BREAST SCANS

HIDA scanning hepatobiliary iminodiacetic acid (HIDA)
↳ *isotope + chemical*

Single-photon emission computed tomography (SPECT) and SPECT/CT



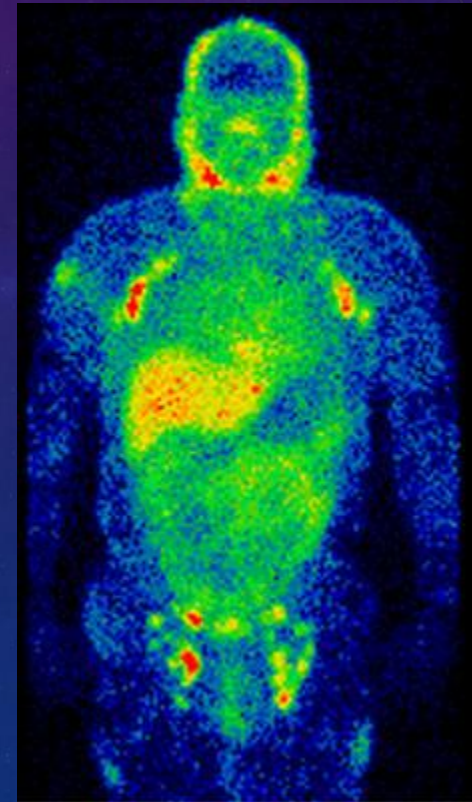
- A single-photon emission computerized tomography (SPECT) scan lets the doctor analyze body's organs, tissue and bones.
- A SPECT scan is a type of nuclear imaging test, which means it uses a radioactive substance and a special camera to create 3D pictures

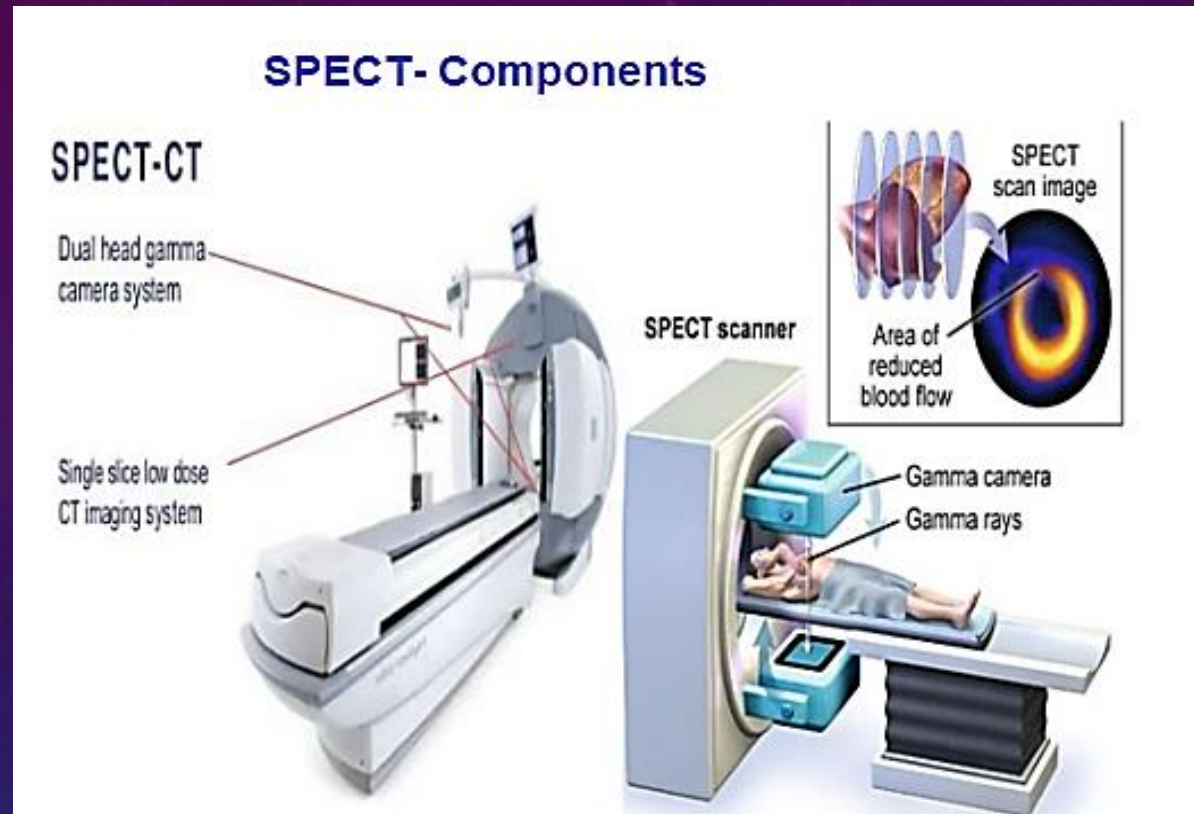
more isotope ^{99m}Tc \Rightarrow infection, inflammation, CA

- Furthermore, scintigraphies taken at different angles is obtained by rotating the camera.
- Then, by combining these planar images, it is possible to reconstruct, thanks to computer science, tomographies, 3-dimensional spatial images.
- This technique based on gamma-cameras scintigraphies is called

Single-photon emission computed tomography (SPECT).

- The basic information is typically presented as cross-sectional slices through the patient





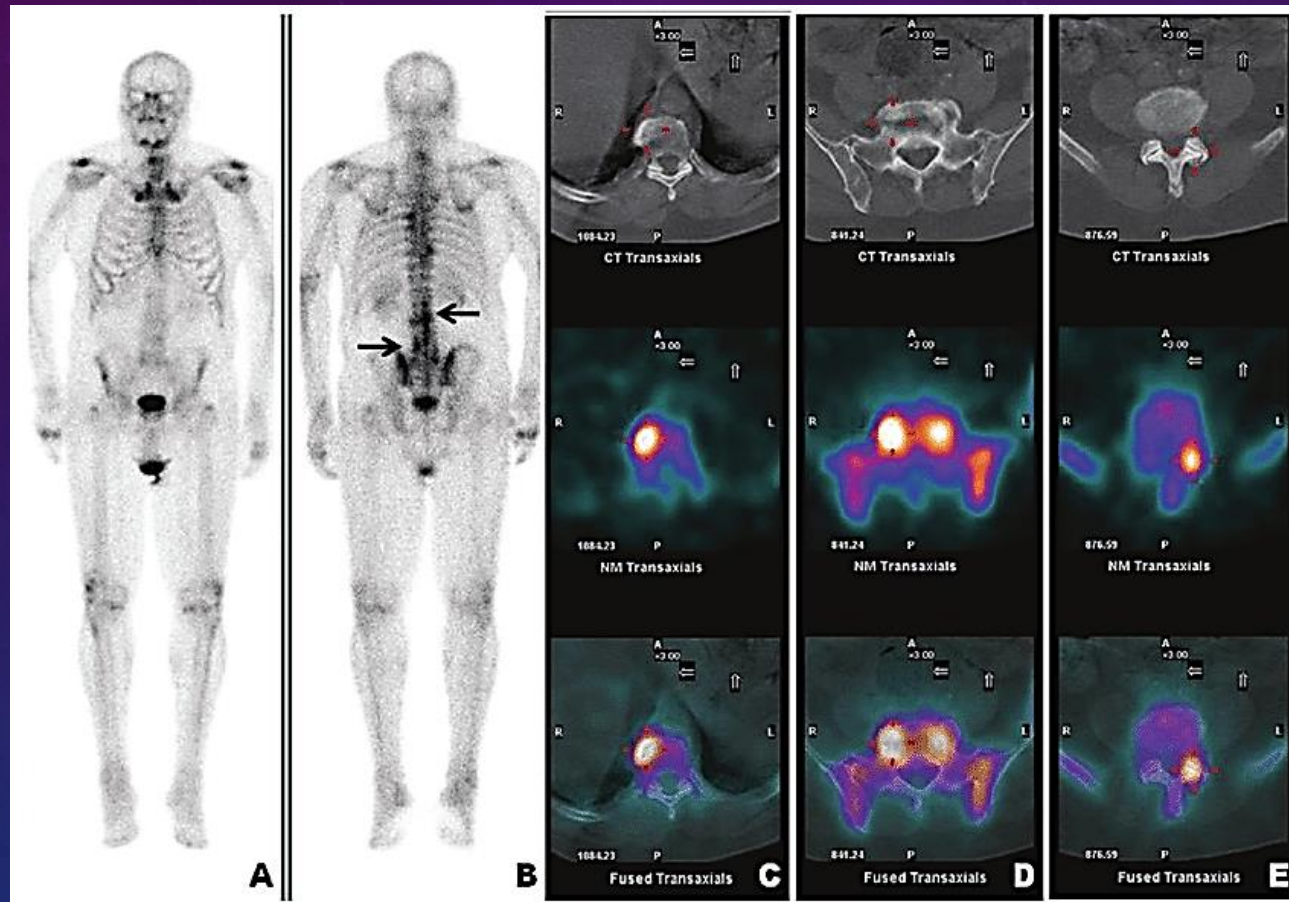
- **A SPECT-CT scan is a type of nuclear medicine scan where the images or pictures from two different types of scans are combined together. The combined scan can provide precise information about how different parts of the body are working and more clearly identify problems.**
- **WHAT ARE THE BENEFITS OF A SPECT-CT SCAN?**
- **Combining the information from a nuclear medicine SPECT scan and a CT scan allows information about body ‘function’ from the nuclear medicine scan to be easily combined with the information about where and how the body structure ‘looks’ in the CT scan.**

اسرع و ارزهر ← Combination

Indications for SPECT/CT include but are not limited to imaging of the following:

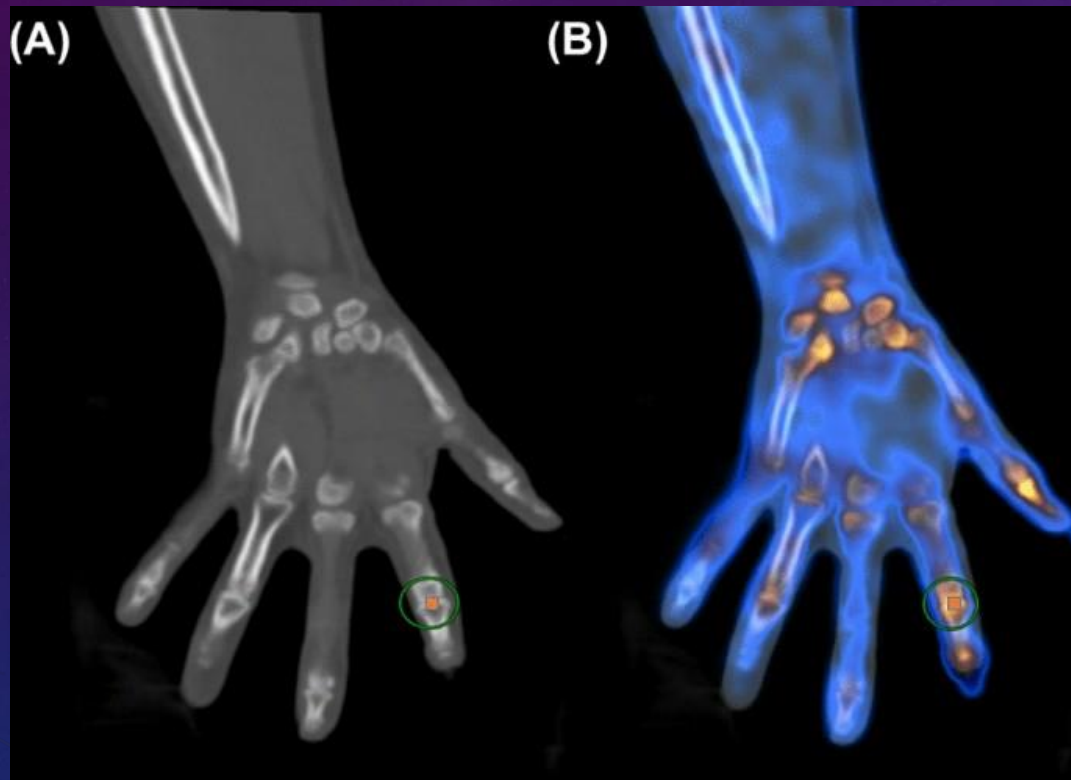
- A. Tumors
- B. Thyroid disorders
- C. Parathyroid disorders
- D. Skeleton disorders
- E. Inflammation or infection
- F. Lymphatic system
- G. Heart disorders
- H. Brain disorders
- I. Other organs

COMBINATION SPECT/CT



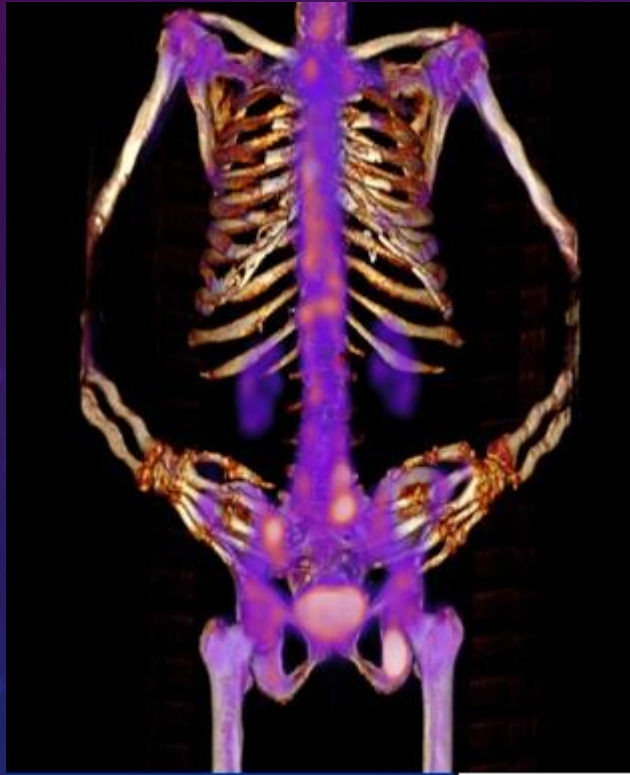Planar whole body bone scan images (A & B) show foci of uptake in the thoracic and lumbar spine. SPECT/ CT localizes foci of increased uptake to degenerative osteophytes (C & D) and facet joint arthritis (E), ruling out osteoblastic bone metastases.

COMBINATION SPECT/CT



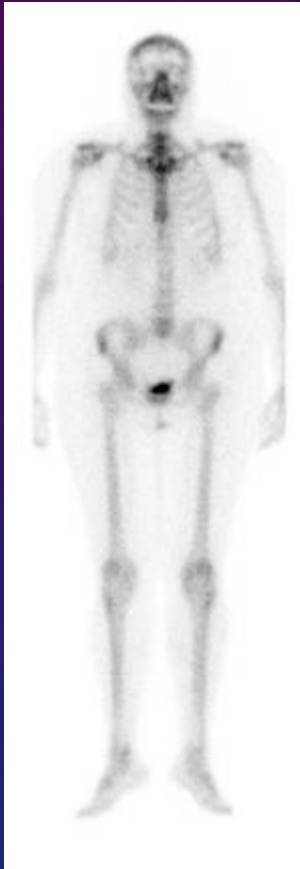(A) CT and (B) SPECT/CT images demonstrate how the SUV was measured at the hand joint. The SUVmax was derived from a spherical VOI drawn over the periarticular region, placing the joint space at the center of the VOI.

COMBINATION SPECT/CT

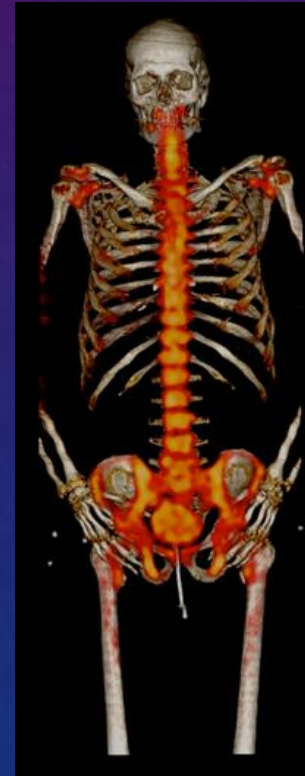


**Whole-Body Bone SPECT-CT Scans For Cancer Staging
Improves Accuracy of Diagnosis**

COMBINATION SPECT/CT



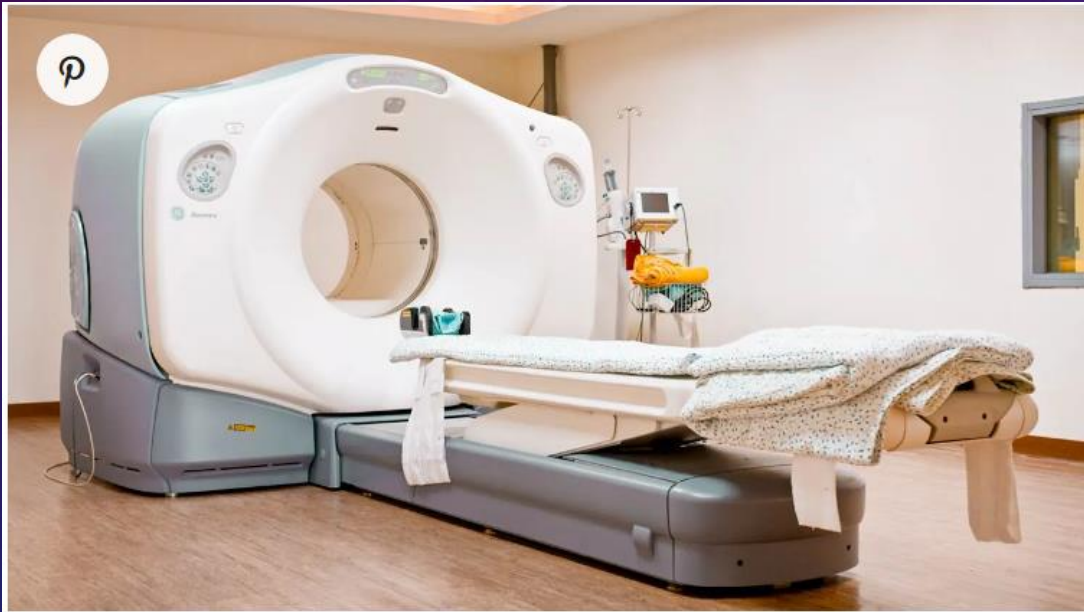Planar whole body bone scan



3D volume rendered fused SPECT-CT

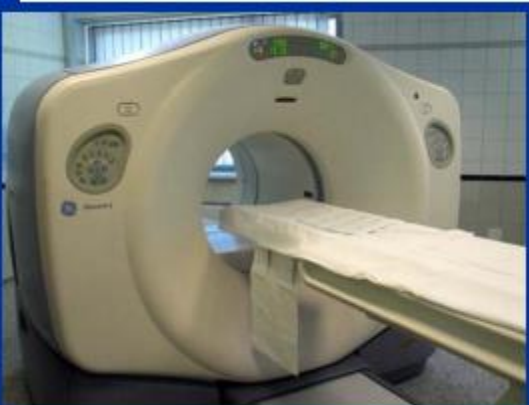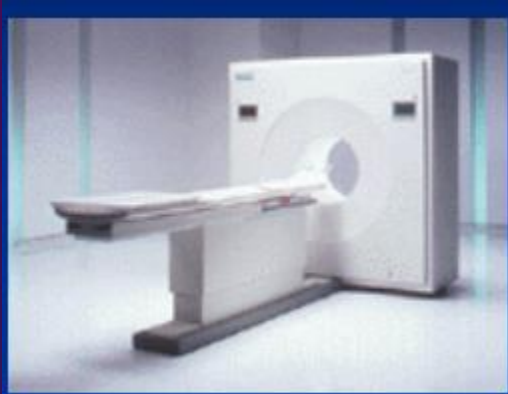POSITRON EMISSION TOMOGRAPHY SYSTEMS

نظام التصوير
بالتصوير



- In general, PET scans may be used to evaluate organs and/or tissues for the presence of disease or other conditions.
- PET may also be used to evaluate the function of organs, such as the heart or brain.
- The most common use of PET is in the detection of cancer and the evaluation of cancer treatment.

PET



Radiopharmaceutical	Half-time
^{18}F	109.8 min
^{11}C	20.3 min
^{15}O	122 s
^{13}N	9.96 min

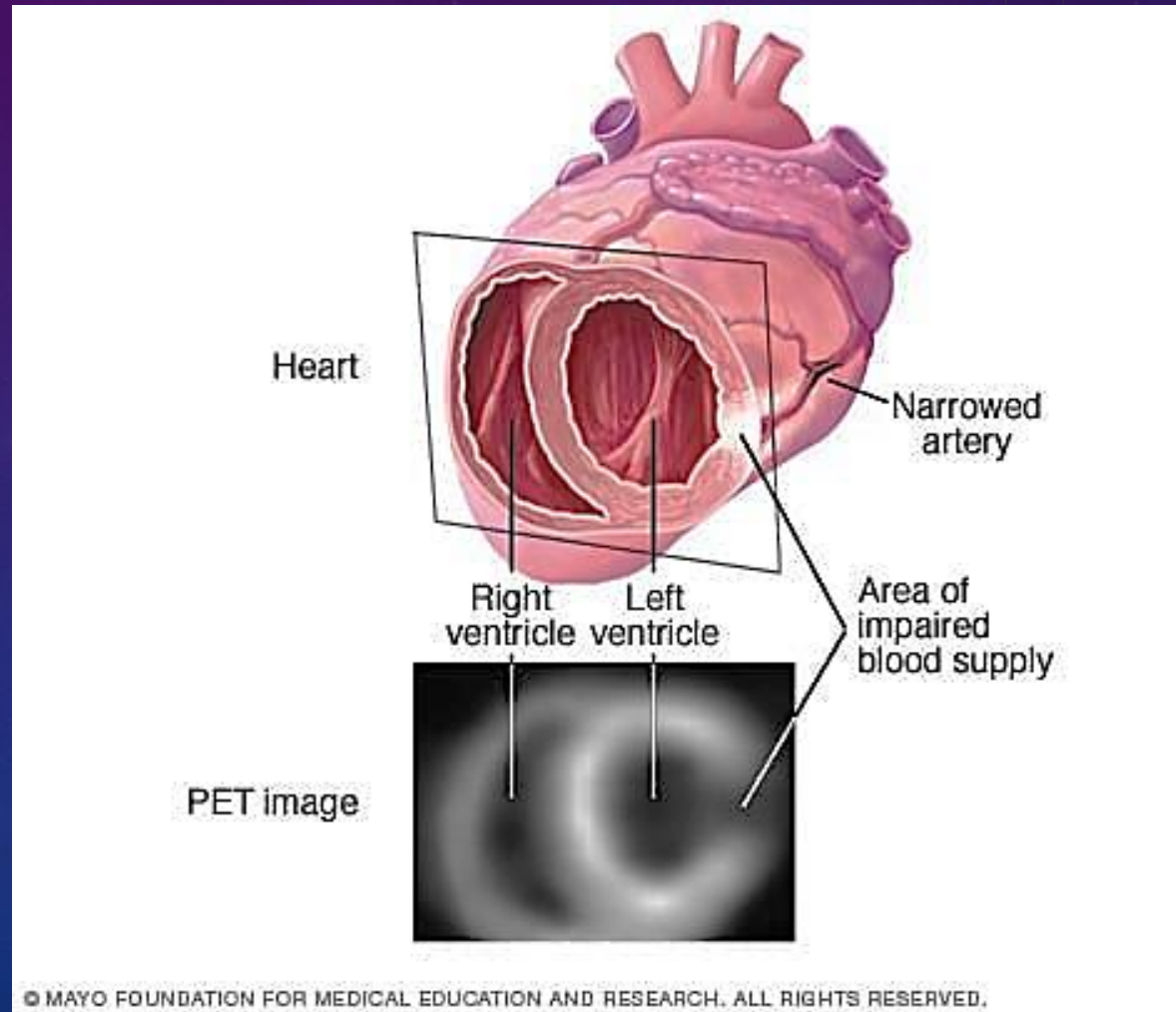
- PET scans use radiopharmaceuticals to create three-dimensional images .
- The main difference between SPECT and PET scans is the type of radiotracers used. While SPECT scans measure gamma rays, the decay of the radiotracers used with PET scans produce small particles called positrons.

Basic Principle of PET (Positron Emission)

- Positron Emission occurs when the Proton rich isotope (Unstable Parent Nucleus) decays and a Proton decays to a Neutron, a Positron and a Neutrino. After traveling a short distance (3-5mm), the positron emitted encounters an electron from the surrounding environment. The two particles combine and "annihilate" each other, resulting in the emission of two gamma rays in opposite directions of 0.511 MeV each.

PET SCAN -HEART DISEASE

- This PET image shows an area of reduced blood flow from one of the arteries that feeds the heart.
- This information may help doctors decide whether to suggest bypass surgery or angioplasty to restore that blood flow.



PET SCANS ARE USED TO HELP DIAGNOSE AND MANAGE MANY CNS DISORDERS

- **Alzheimer's disease**
- **depression**
- **epilepsy**
- **head trauma**
- **Parkinson's disease**

isotope fluoride

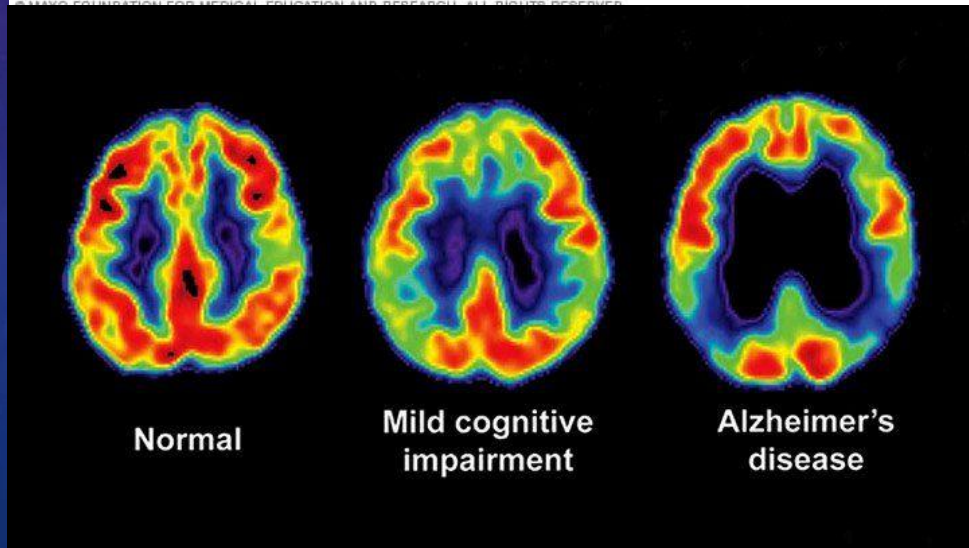
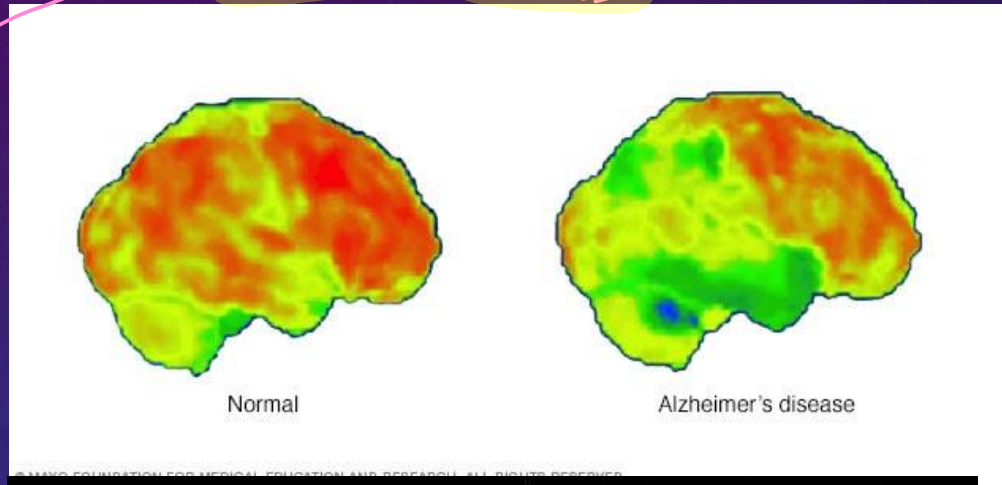
half-life → 110 دقائق

PET SCAN-BRAIN DISORDERS

Just Lev Pathology

+ dexagluose (كشانه تانتس) diffuse مع التلابة

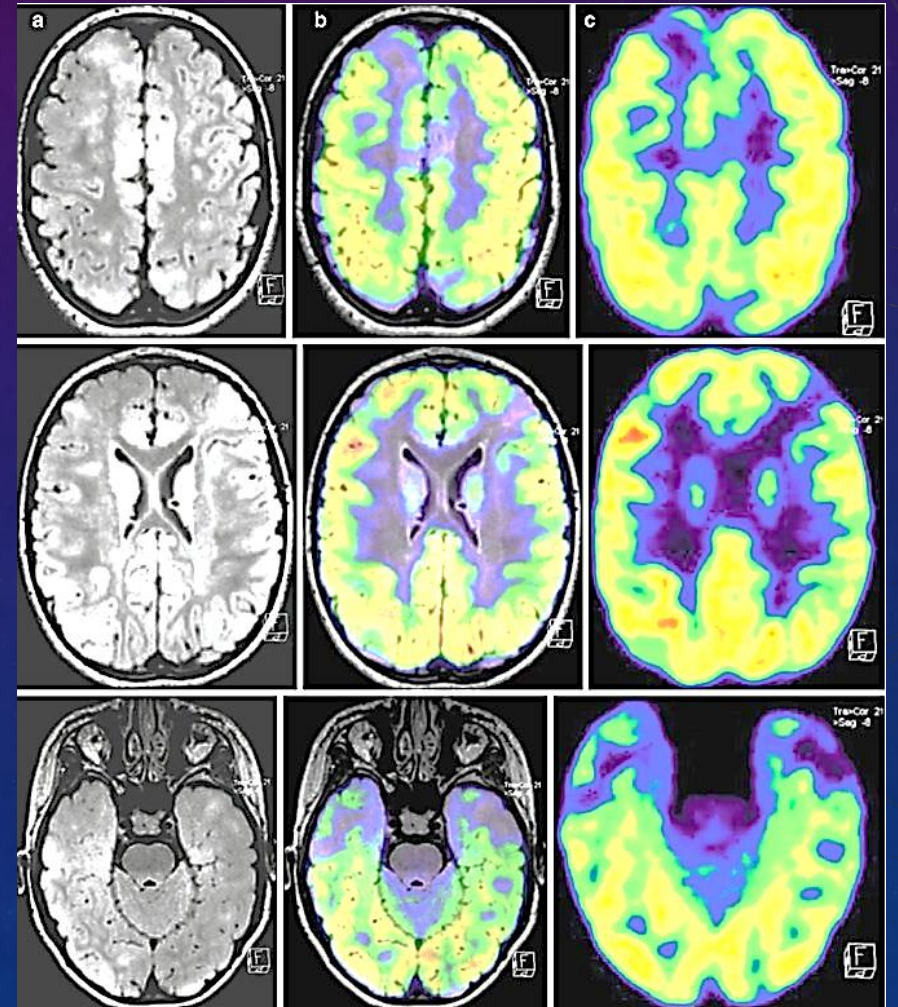
- A PET scan can compare a normal brain (left) with one affected by Alzheimer's disease (right).
- The loss of red color with an increase in yellow, blue and green colors shows areas of decreased metabolic activity in the brain due to Alzheimer's disease.



صبر انتفاكي المسننه بعضه
على activity التلابة

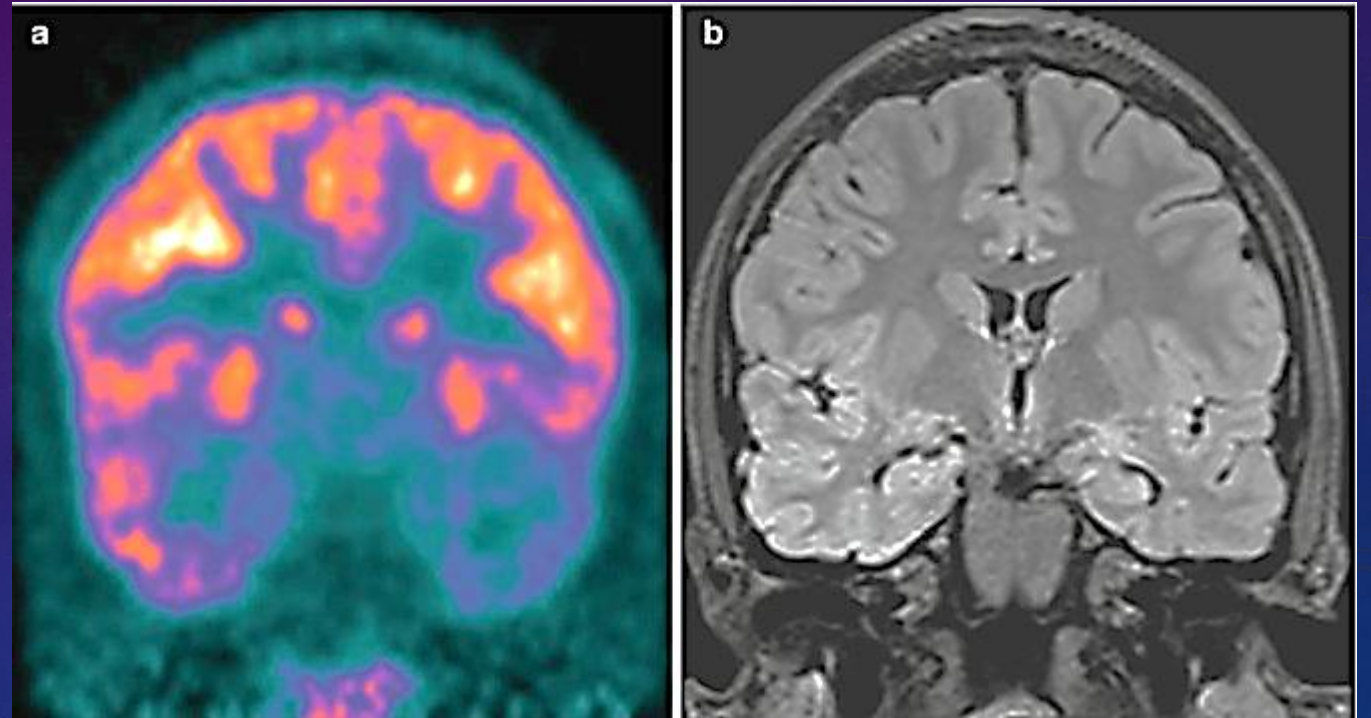
PET SCAN

- A 5-year-old girl who at the age of 5 months was diagnosed with tuberous sclerosis and generalized epileptic seizures.
- (a) Axial MRI,
- (b) PET/MRI fusion, and
- (c) PET images.
- The PET/MRI fusion images show multiple cortical lesions in the two hemispheres, typically hypometabolic on FDG–PET imaging. However, these imaging modalities do not allow localization of the lesion generating the epileptic seizures. Instead, promising results were obtained using α -[11C]methyl-l-tryptophan (AMT), a tracer specific for the serotonergic system



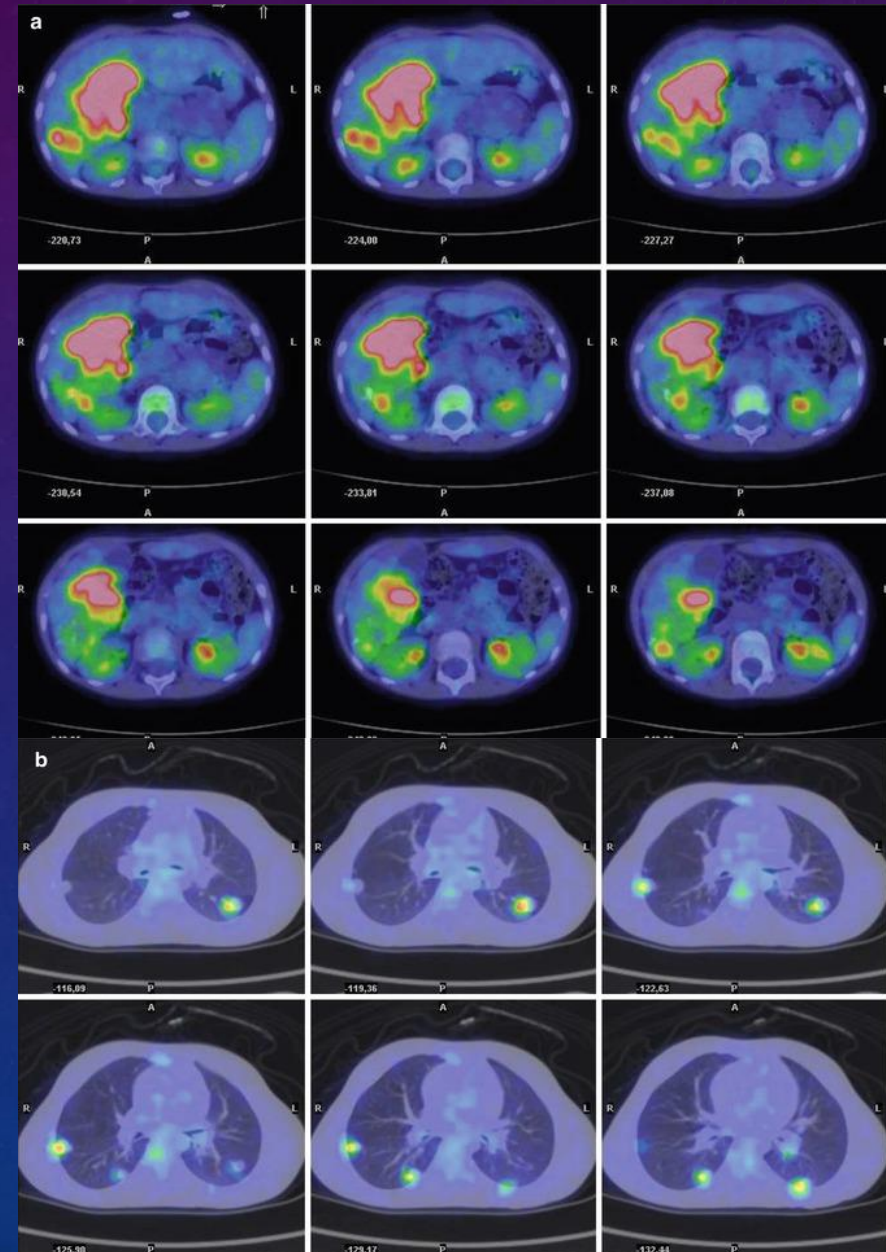
PET SCAN

- A 13-year-old boy with partial complex epileptic seizures.
- (a) Coronal PET image,
- (b) MRI image.
- MRI does not show any clear abnormality, while on the PET image, there is marked hypometabolism in the left temporal pole. A repeated MRI investigation identified an area of probable cortical dysplasia. A left anterior temporal lobectomy was planned



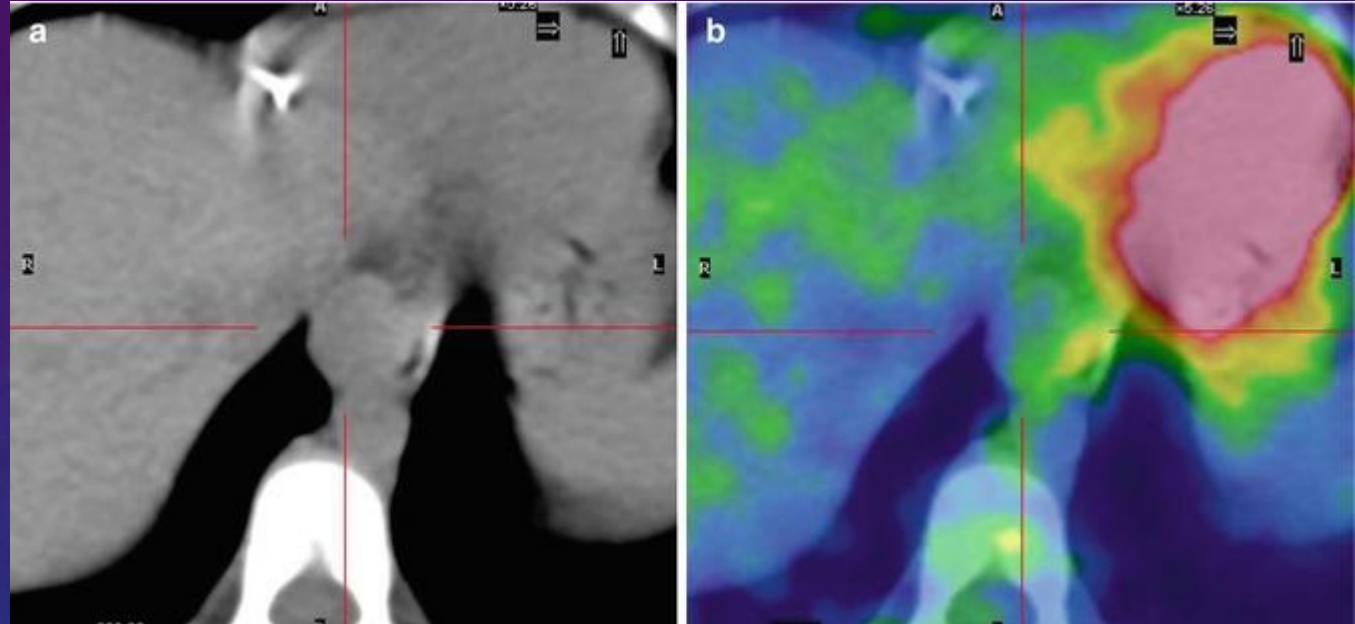
CANCER DIAGNOSIS

- A 4-year-old boy with hepatoblastoma. PET evaluation to determine liver transplantation eligibility.
- Axial PET/CT fusion images show FDG-avid lesions in the liver (a) and lungs (b).
- The patient was referred for chemotherapy



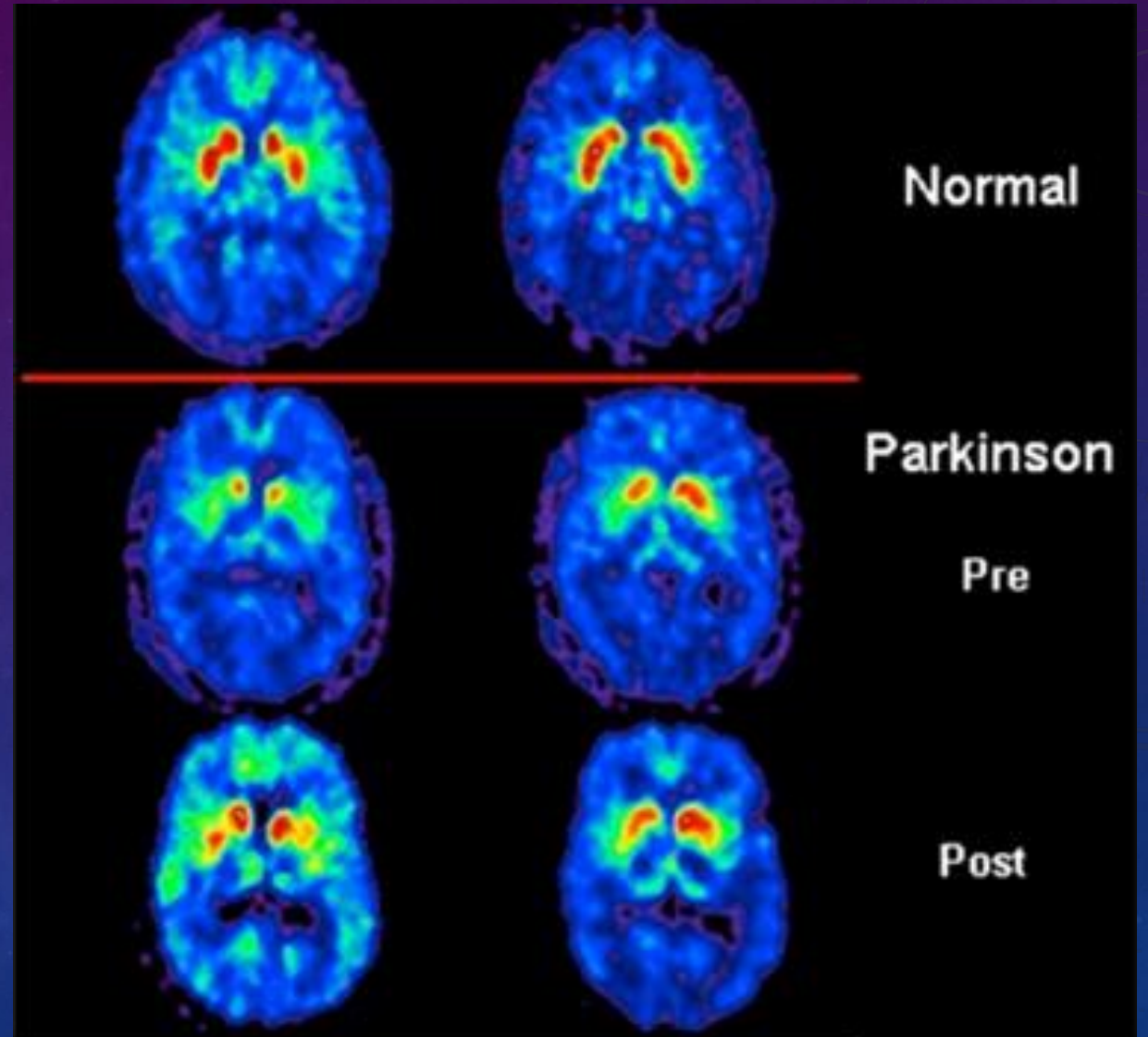
PET SCAN

- An 8-year-old boy treated for hepatoblastoma.
- PET evaluation following increased alpha-fetoprotein levels. Axial CT (a) and CT/PET fusion (b) images show no FDG uptake in a small cardiac lesion seen on CT. The patient underwent surgery; the histological finding was HEPATOCARCINOMA

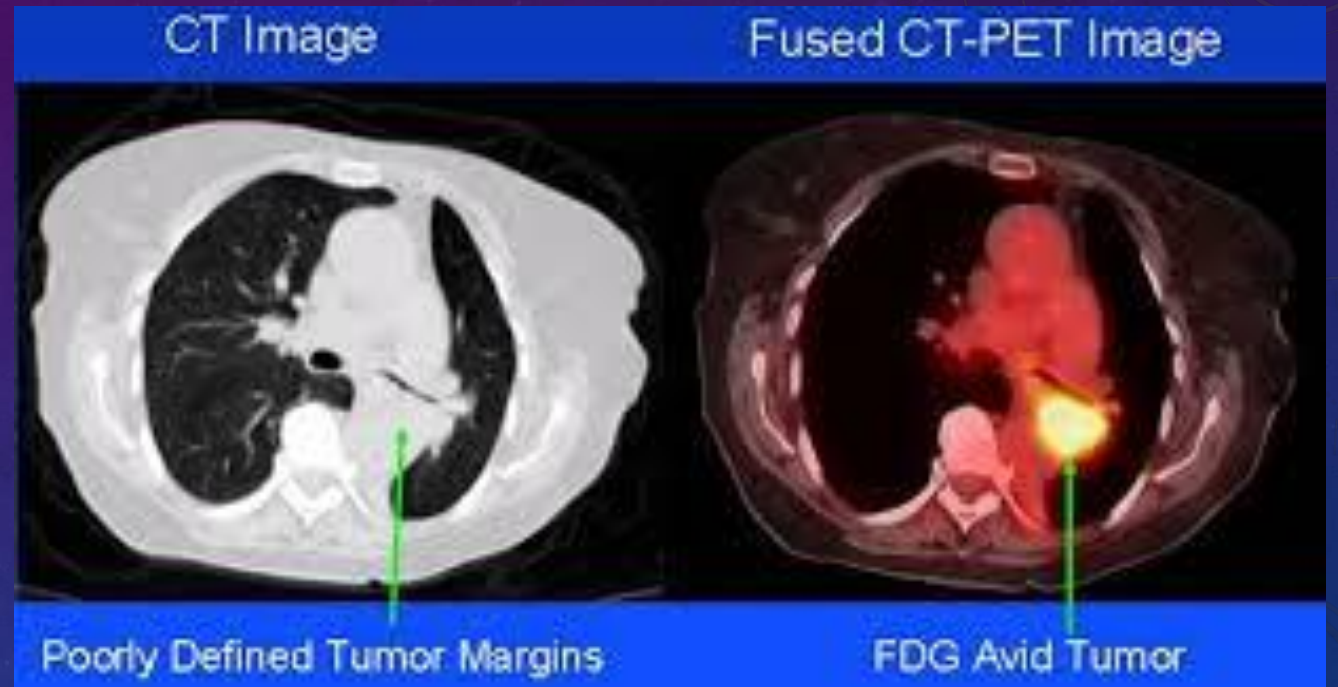
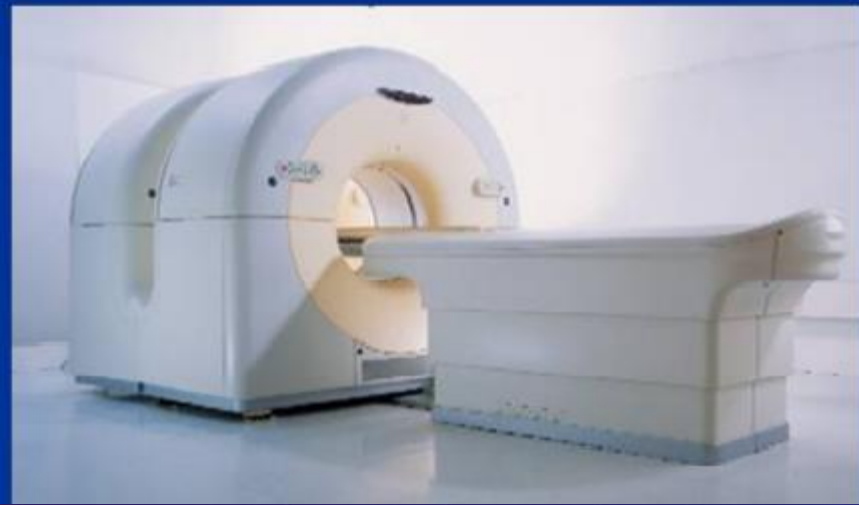


PET SCAN

- An example of a PET scan is below and it reveals: in the top panel a normal scan, in the middle panel abnormalities in the putamen (red uptake in the figure) in a patient with Parkinson's disease, and in the lower panel a return to an almost normal scan following the introduction of levodopa.



COMBINATION PET/CT



INCIDENTAL FINDINGS OF COVID-19 IN PET/CT IMAGING

- A 75-year-old male with diffuse large B-cell lymphoma (DLBCL)—6 months post-therapy following 3 cycles of a chemotherapy regimen—underwent PET/CT imaging to assess residual disease for subsequent treatment strategy.
- Approximately 1 hour following the intravenous (IV) injection, a single-scan, whole-body acquisition was conducted on a TM scanner.
- As observed in Figures 1 and 2, the PET/CT of the lungs shows bilateral, hypermetabolic ground-glass opacities (GGOs) on CT that correlate to PET tracer uptake.
- In consideration of the ongoing COVID-19 pandemic, these incidental findings were deemed suspicious and the patient was referred for COVID-19 testing.
- Test results confirmed the patient was positive for COVID-19.
- **PET/CT imaging is not indicated for the diagnosis of COVID-19. Only in-vitro diagnostic testing is currently the definitive method to diagnose COVID-19.**

INCIDENTAL FINDINGS OF COVID-19 IN PET/CT IMAGING

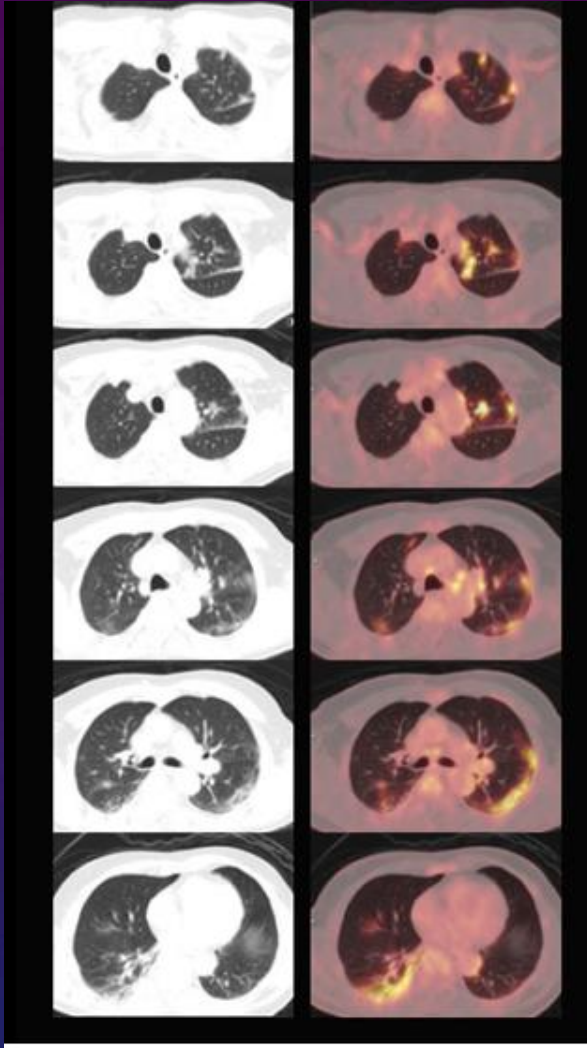


Fig1: Axial CT and PET/CT show multiple bilateral consolidations of ground-glass opacities

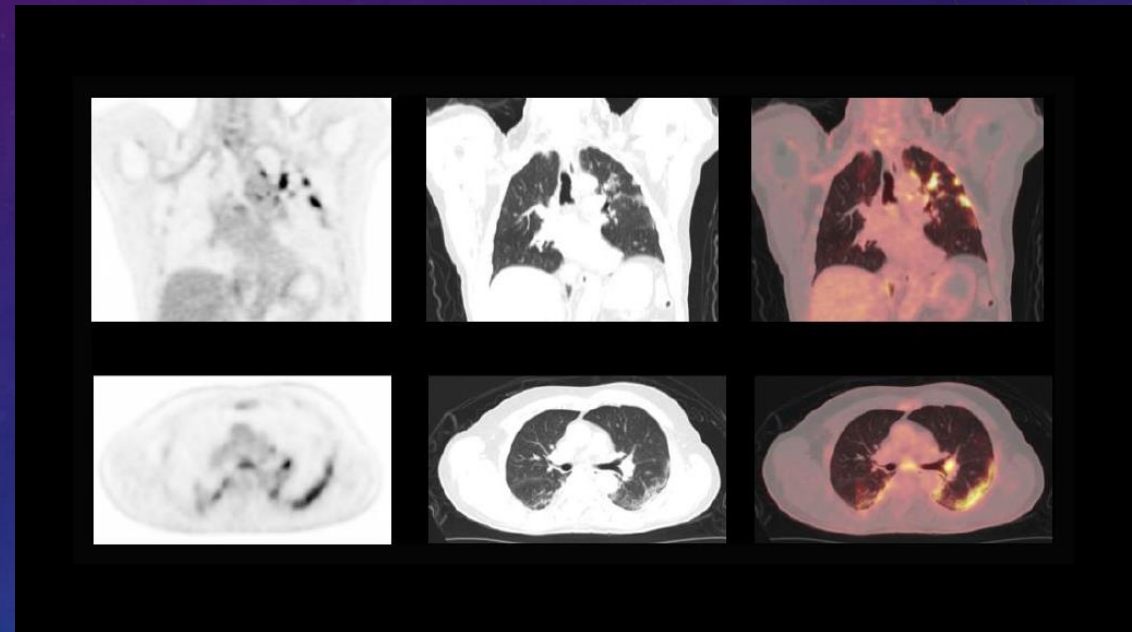
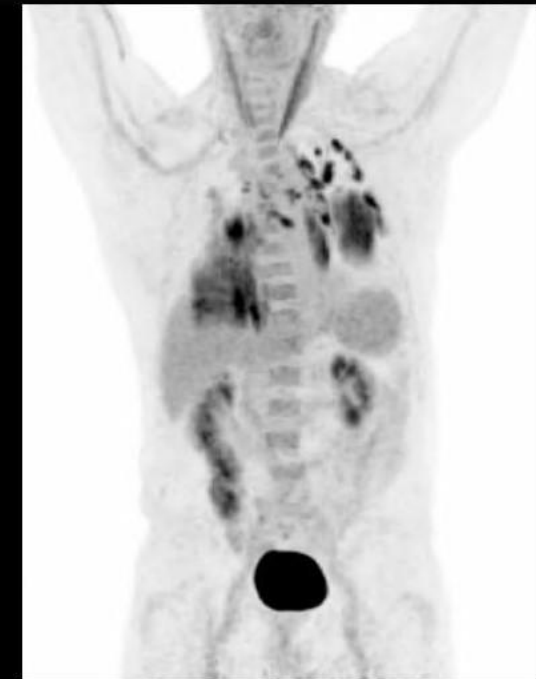
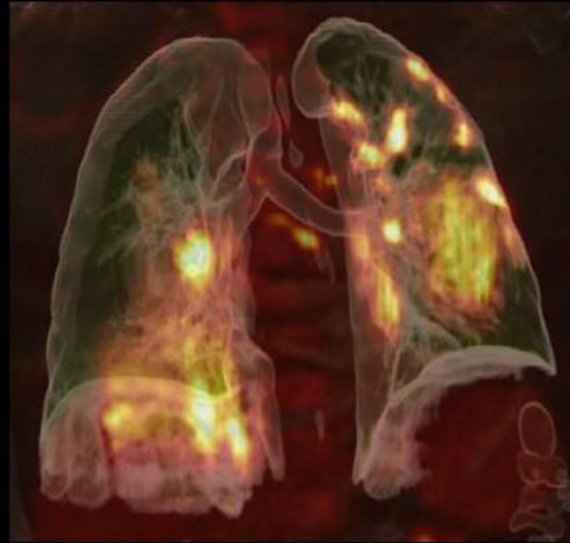
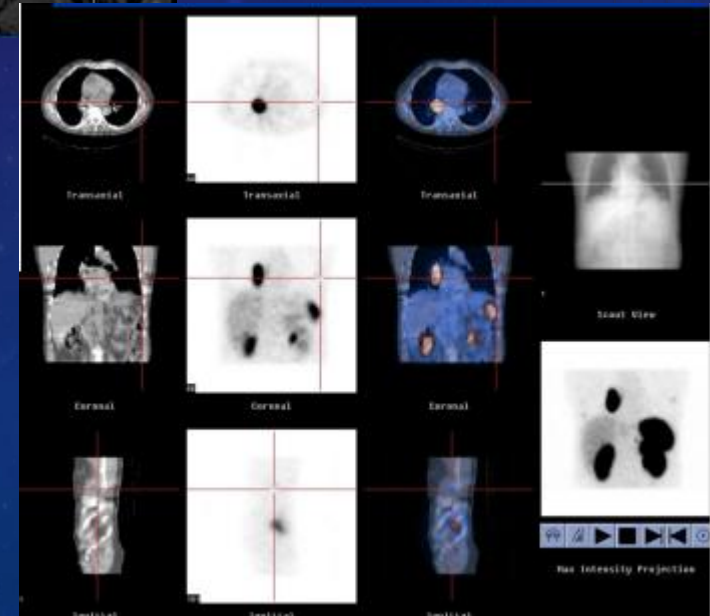
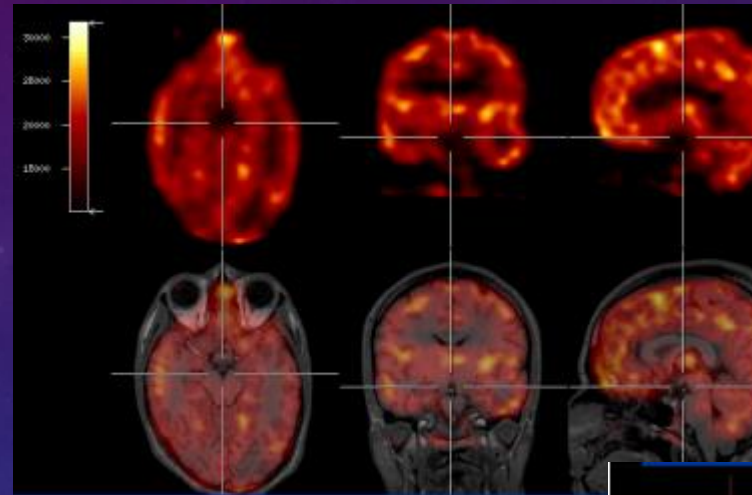
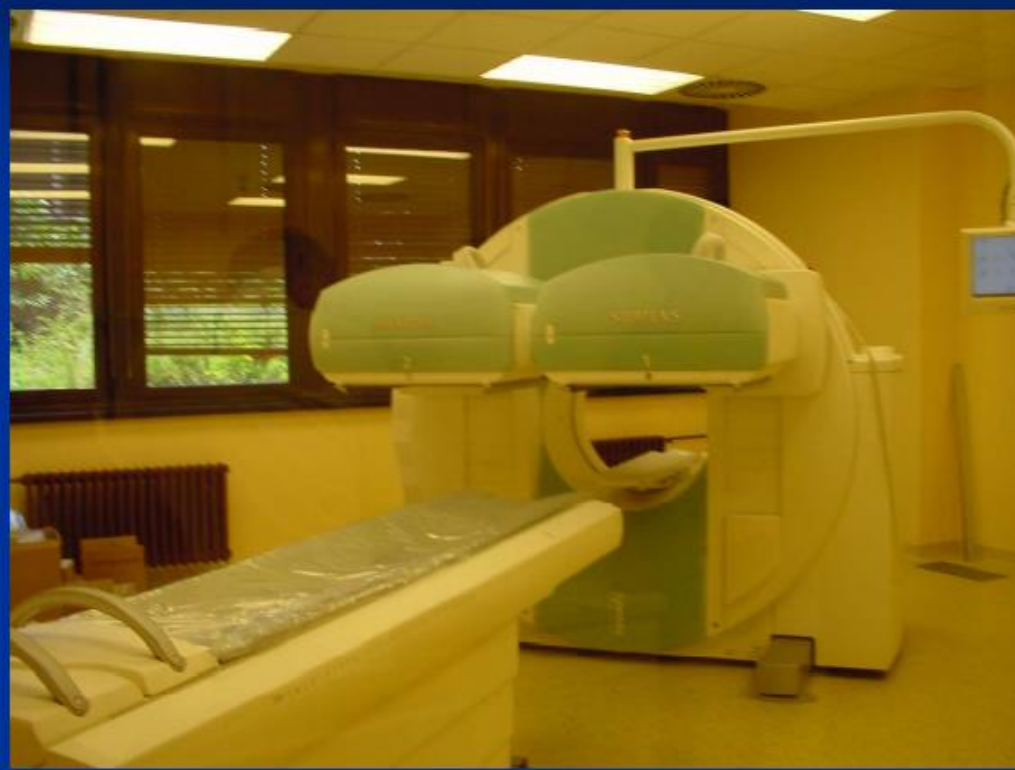Fig 2 Coronal views of PET, CT and PET/CT images (top row) and as well PET, CT and PET/CT images (the bottom row) depict hypermetabolic parenchymal foci

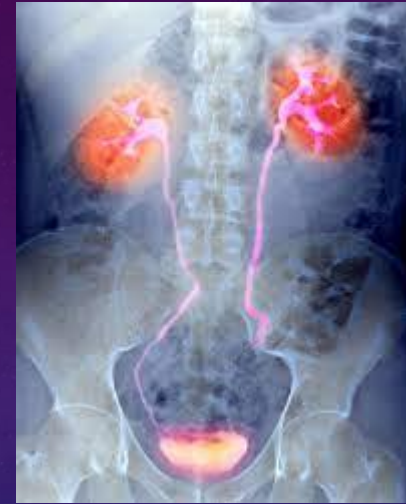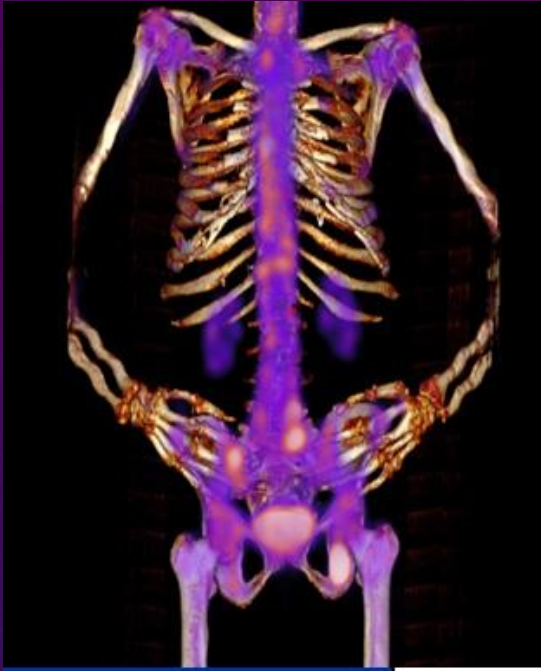INCIDENTAL FINDINGS OF COVID-19 IN PET/CT IMAGING

Fig 3: Volume rendering technique (VRT) (left) and maximum intensity protection (MIP) (right) images demonstrate hypermetabolic parenchymal foci which is indicative of an infectious or inflammatory process

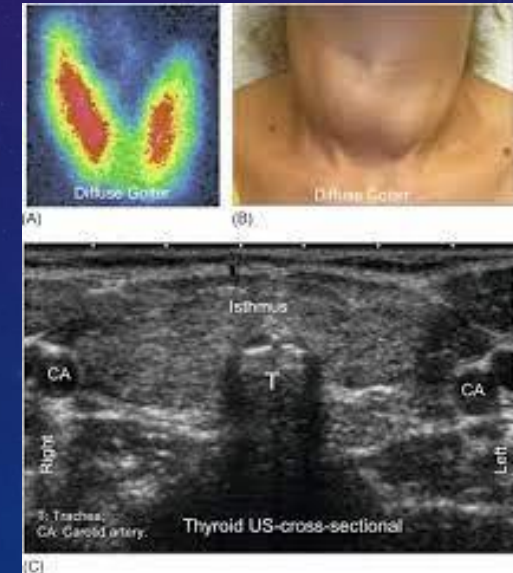

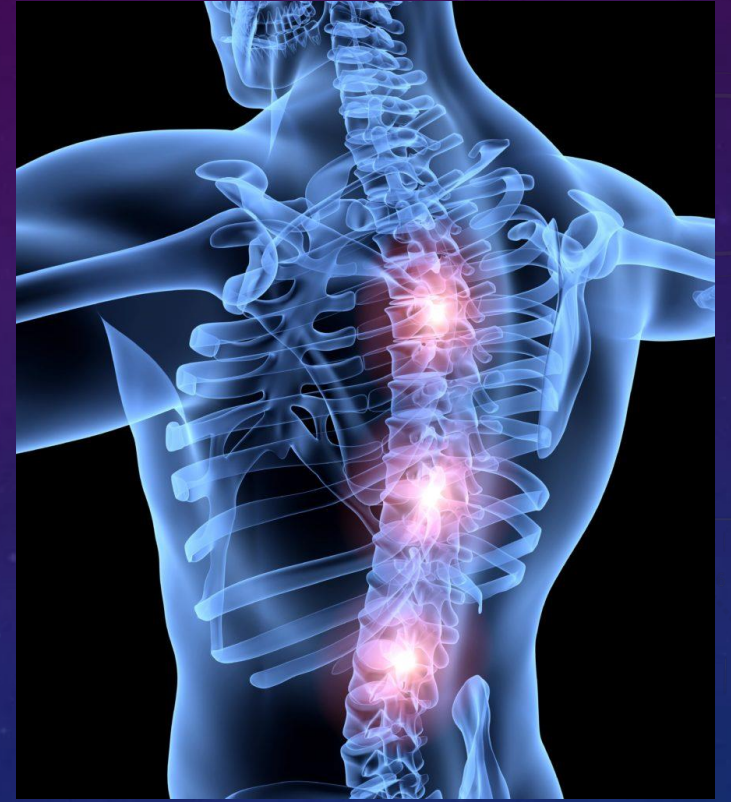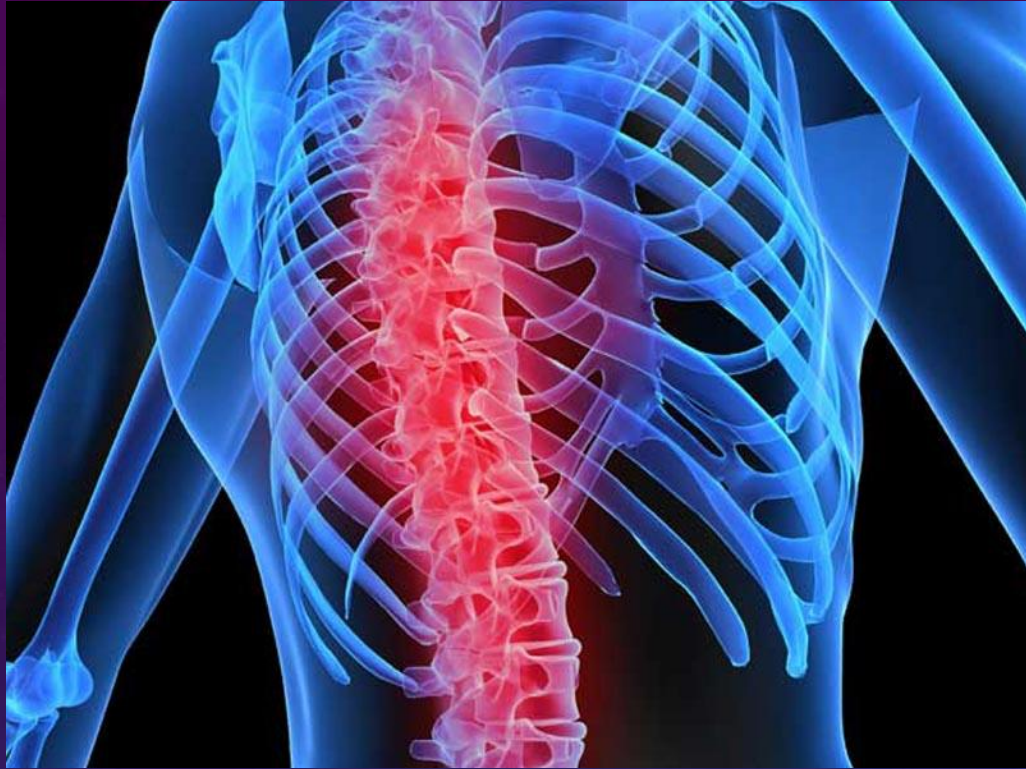COMBINATION SPECT/CT





BODY SYSTEMS IMAGING





Bone scan

3 Phase bone scan
ثلاث مراحل

BONE SCAN

- complicated fracture
- infection

2 PHASES ← 5m, 1m خلا

static : injection , فحص , تصوير → imaging

→ isotope به لیس → cellular & soft tissue
 → isotope به لیس → CA , inf. in bone

Bone scans may reveal bone problems associated with the following conditions:

- **ARTHRITIS**
- **AVASCULAR NECROSIS** (when bone tissue dies due to a lack of blood supply) *بسی جمع به شقی*
- **BONE CANCERS** *osteogenesis → infection → revascularization → all isotope in hip - bone*
- **CANCER THAT HAS SPREAD TO THE BONE FROM OTHER PARTS OF THE BODY**
- **FIBROUS DYSPLASIA (A CONDITION THAT CAUSES ABNORMAL SCAR-LIKE TISSUE TO GROW IN PLACE OF NORMAL BONE)**
- **FRACTURES**
- **INFECTION INVOLVING THE BONE**
- **PAGET'S DISEASE OF THE BONE (A DISEASE THAT CAUSES WEAK, DEFORMED BONES)**

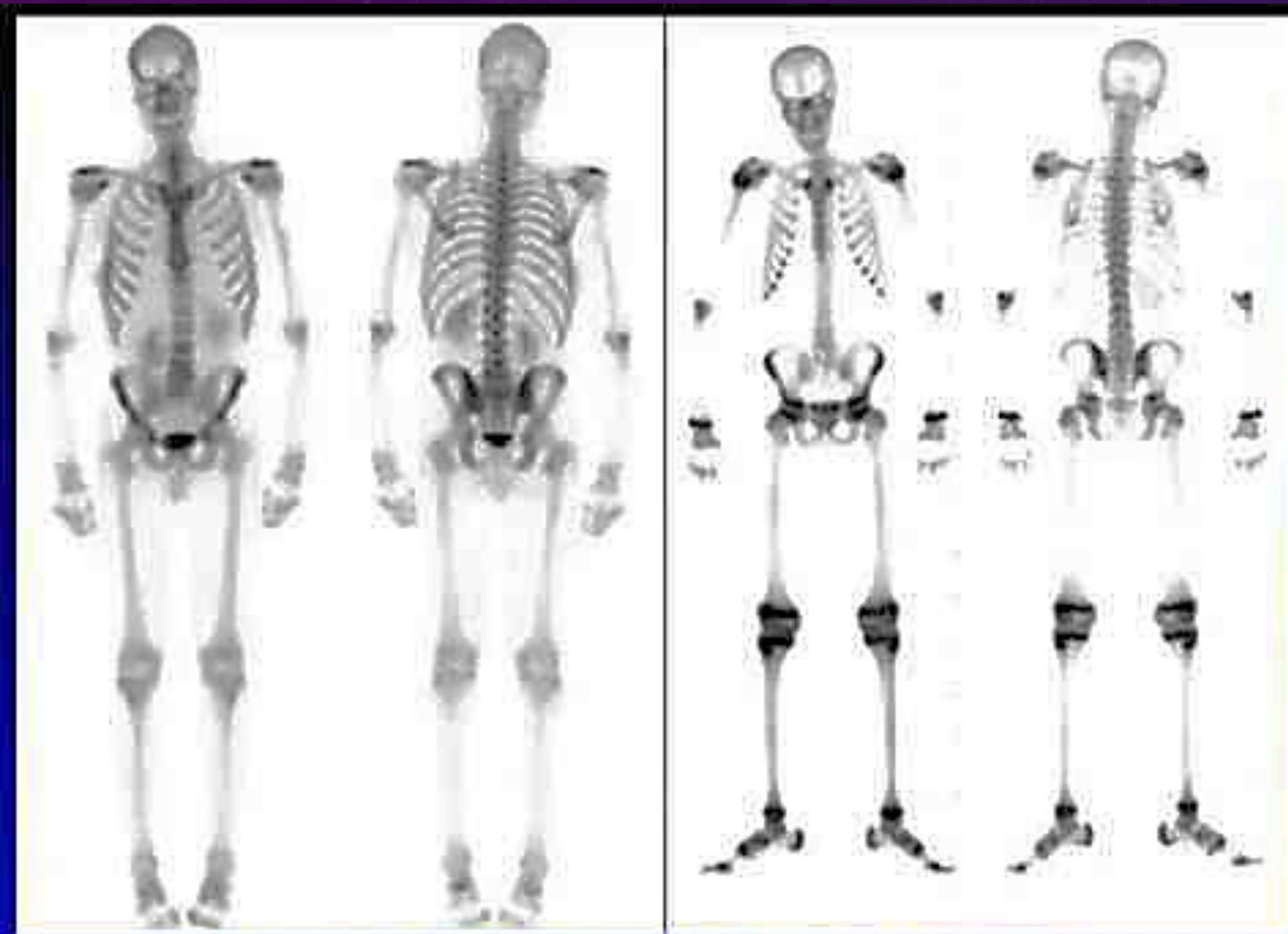
BONE SCAN

There are two main types of bone exams.

- ❖ A three-phase bone scan is a nuclear imaging test that shows how the bones process an injected agent.
- ❖ A DEXA bone scan is a type of X-ray that tests bone strength and density to diagnose osteoporosis.

iodine-95 ⇒ ٩٥ يوم وهو مسح

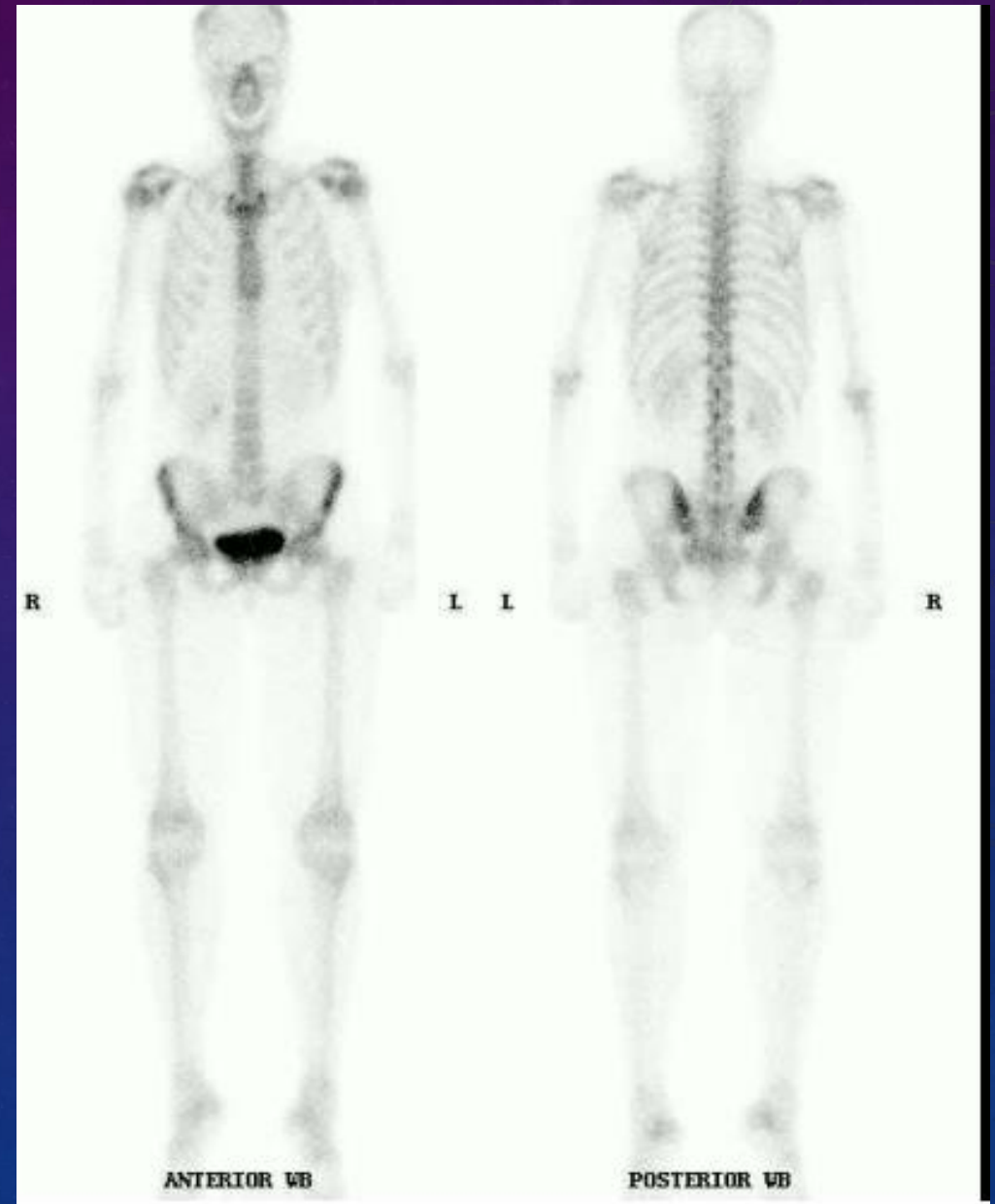
BONE SCAN



Normal bone scans in adult and teenager

symmetry of LG & RT لى تىف سى

A patient who has been injected with A radio-active tracer is slightly radio-active, but the activity is constantly falling, both due to the physical T1/2 of the isotope, but also due to breakdown and excretion of the carrier molecules (the biological T1/2).

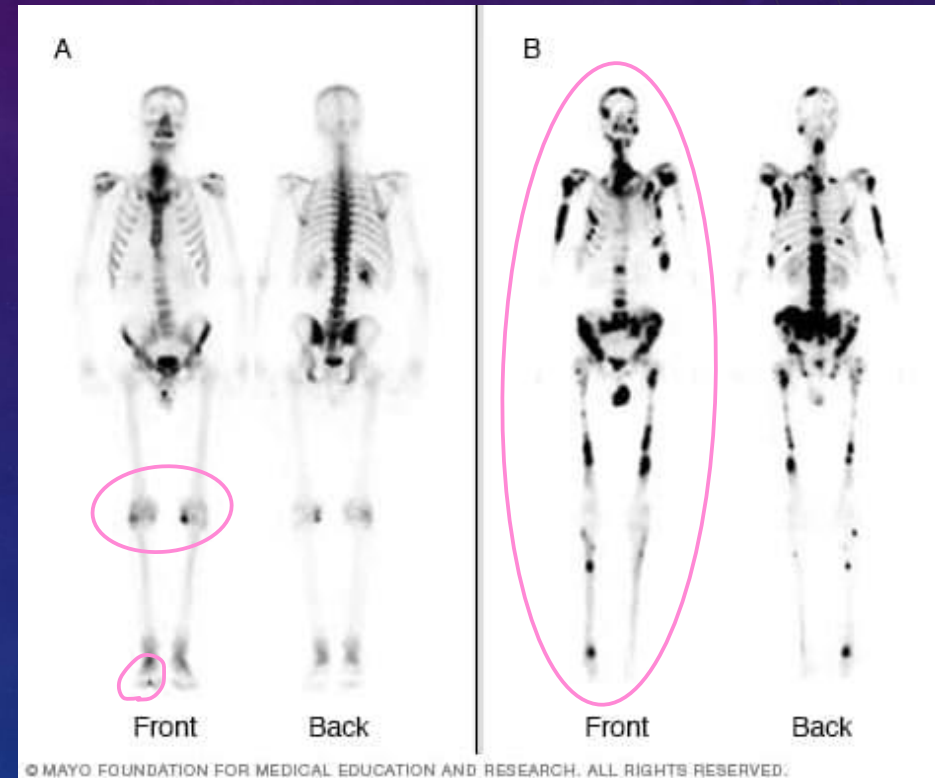


NORMAL ADULT BONE SCAN - FAIRLY ANATOMICAL

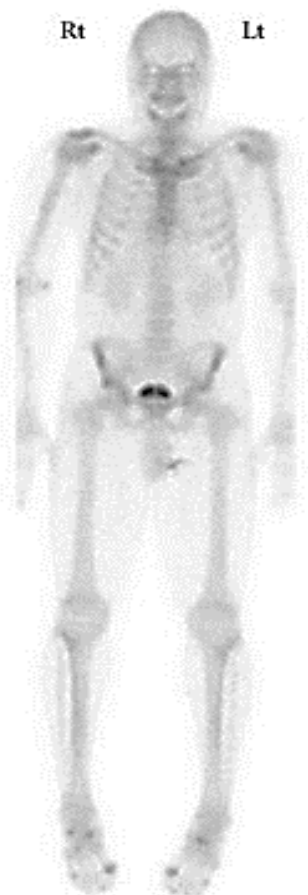BONE SCAN

HOT SPOTS

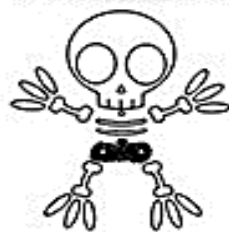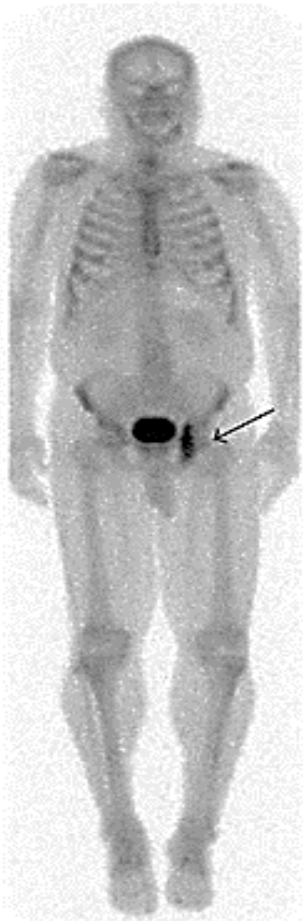
- **Scan A shows hot spots (dark areas) in both knees, a sign of arthritis, and a possible fracture in the second toe of the right foot. Otherwise, it shows typical bone metabolism.**
- **Scan B shows numerous bone hot spots, a result of cancer that has spread to multiple locations.**



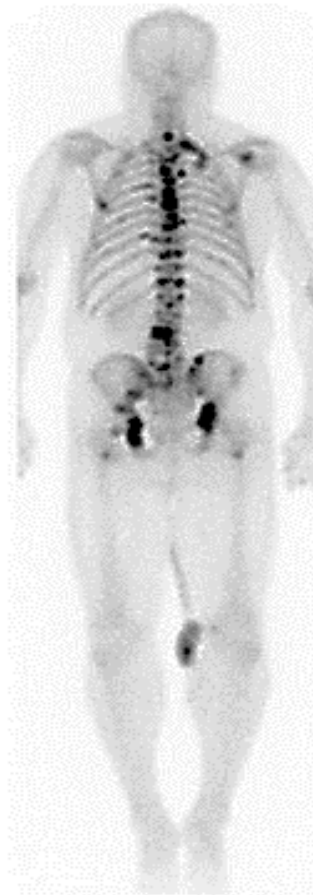
BONE SCAN



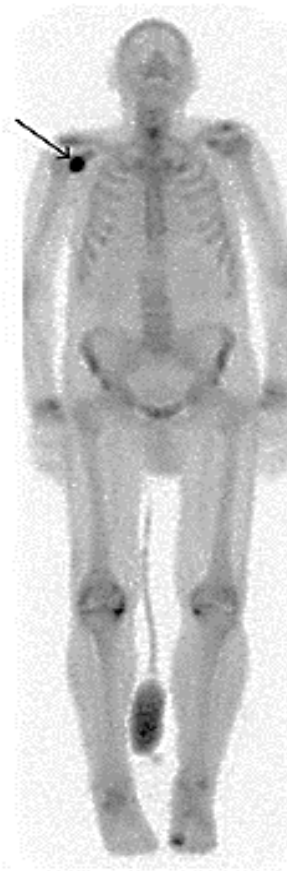Group 1
Normal bone scan



Group 2
Metastases only in pelvis and lumbar spine

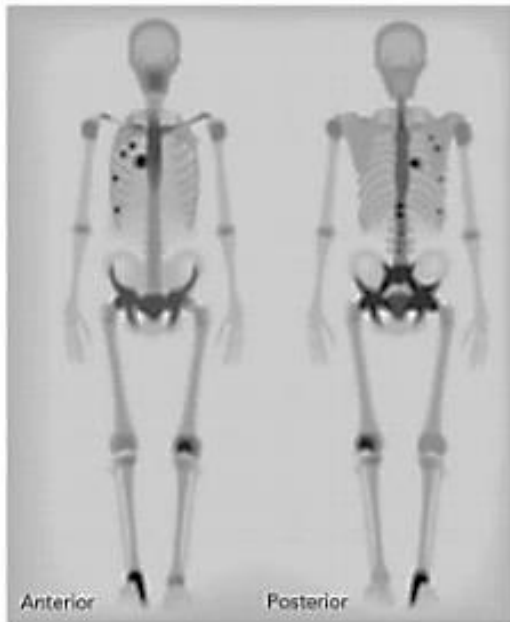

Group 3
Widespread metastasis including pelvis and lumbar spine

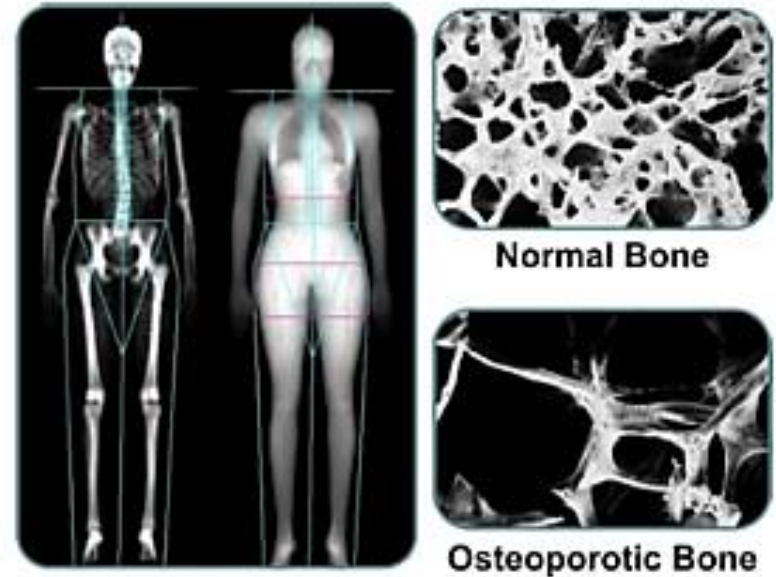


Group 4
Distant metastases without pelvic or lumbar spine abnormalities

BONE SCAN



Bone Scan – looks for cancer in bone

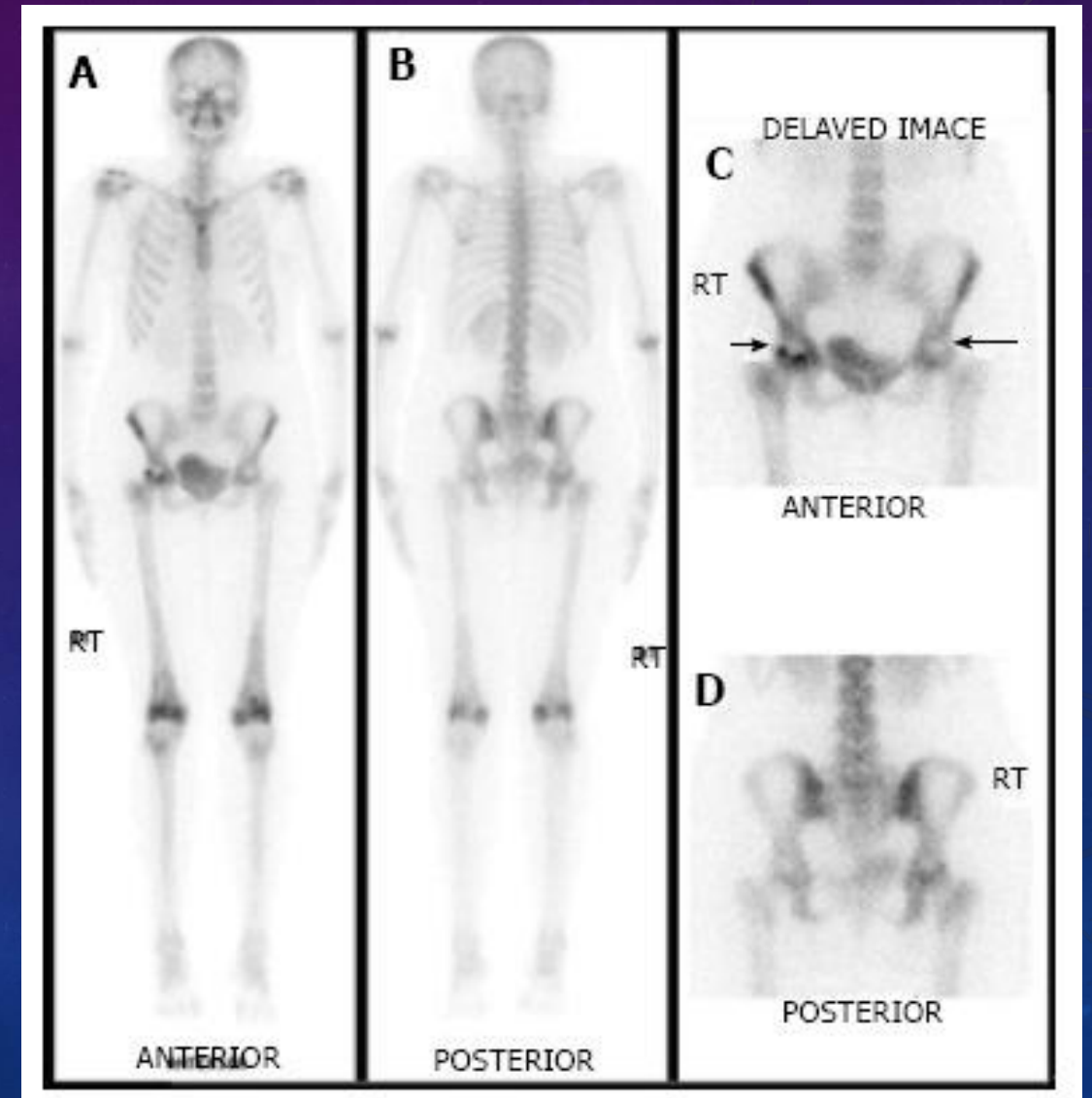


Bone Mineral Density Test –
looks for osteoporosis

NUCLEAR MEDICINE IMAGING IN OSTEONECROSIS OF HIP

A 30-year-old female treated with chemotherapy for breast cancer was referred for ^{99m}Tc -MDP bone scan to evaluate cause of disabling hip pain.

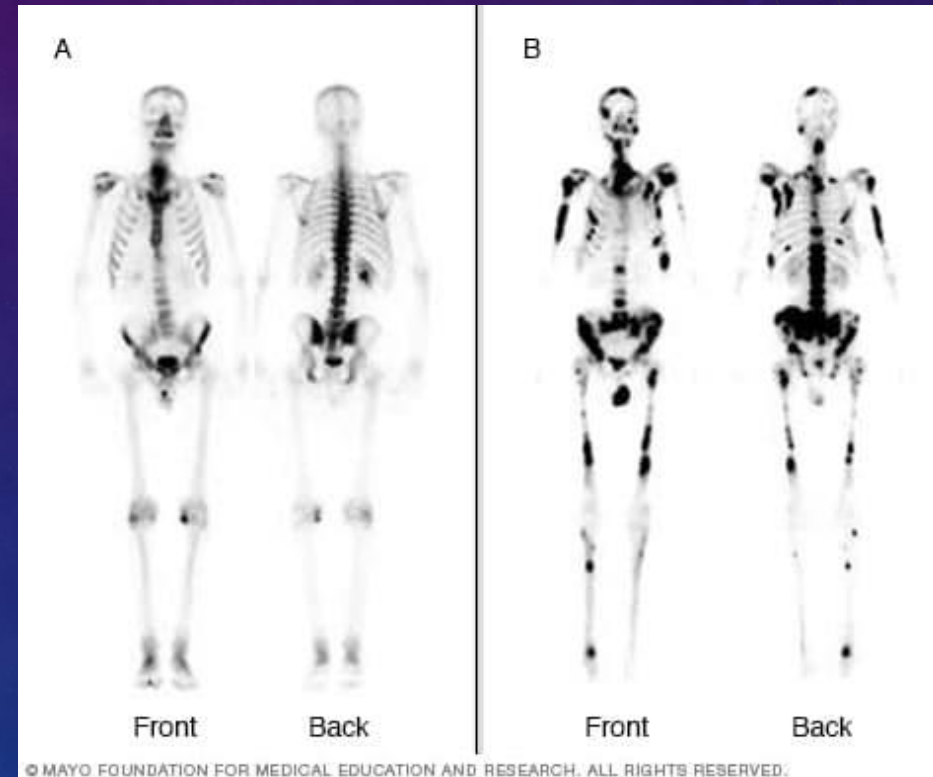
Whole body (A and B) and delayed images (C and D) demonstrate photopenic areas in bilateral femoral heads (arrows) with increased osteoblastic activity surrounding the photopenic region in the right femoral head, suggestive of bilateral avascular necrosis. Increased osteoblastic activity in bilateral distal femora is likely due to biomechanical stress reaction due to altered gait.



BONE SCAN

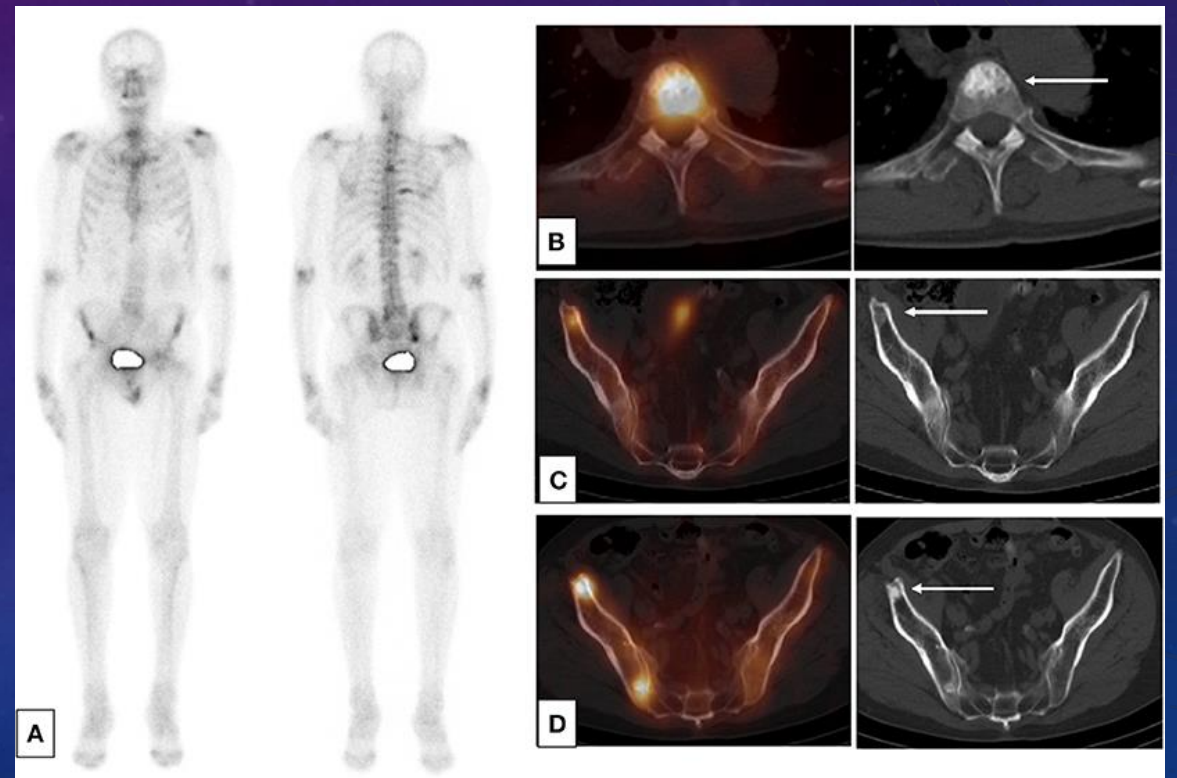
A 30-year-old female treated with chemotherapy for breast cancer was referred for ^{99m}Tc -MDP bone scan to evaluate cause of disabling hip pain.

Whole body (A and B) and delayed images (C and D) demonstrate photopenic areas in bilateral femoral heads (arrows) with increased osteoblastic activity surrounding the photopenic region in the right femoral head, suggestive of bilateral avascular necrosis. Increased osteoblastic activity in bilateral distal femora is likely due to biomechanical stress reaction due to altered gait.



IMAGING FOR METASTASIS IN PROSTATE CANCER

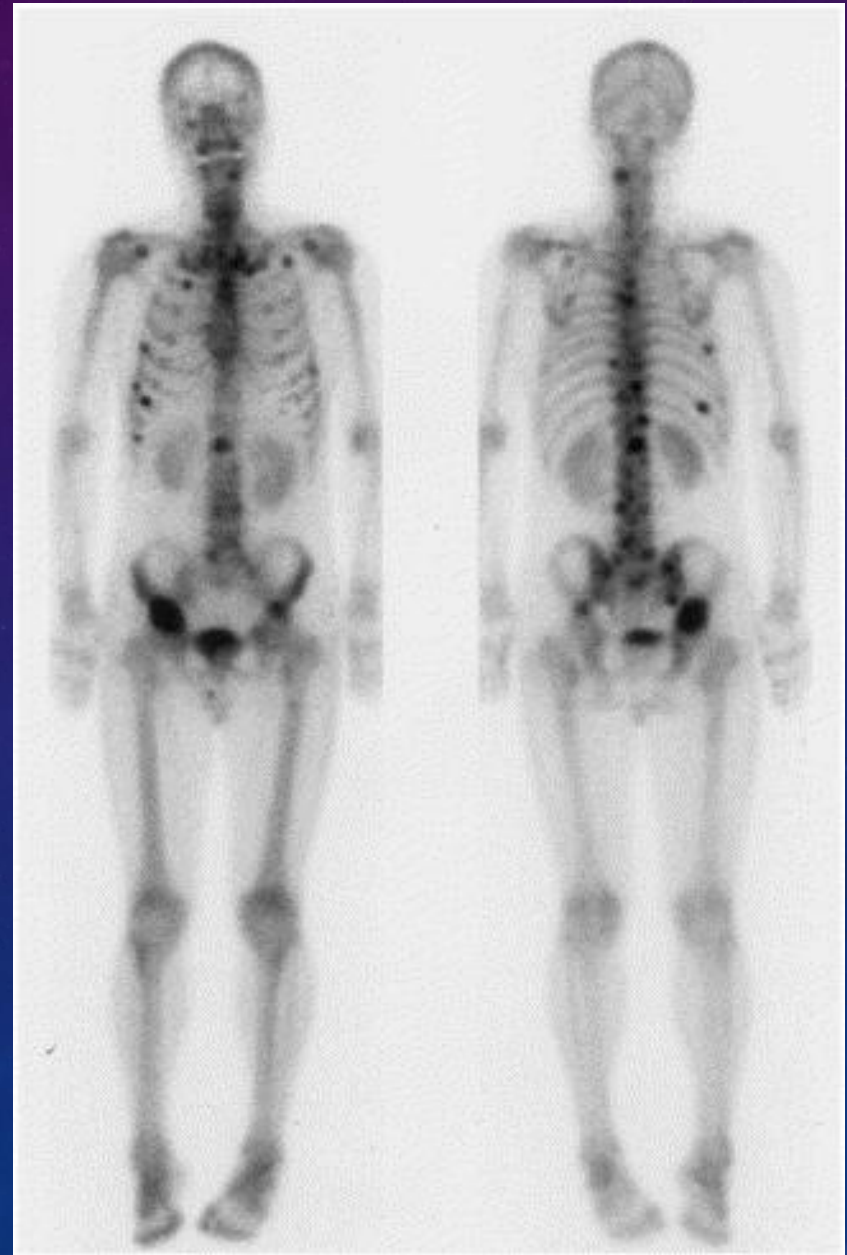
- **SPECT-CT: condensation of bone lesions under treatment. Occurrence of a prostate adenocarcinoma, Gleason 6 (3 + 3) on a biopsy, unoperated, treated by hormone therapy and HIFU therapy in a patient.**
- **(A) Baseline planar bone scan**
- **(B,C) Baseline SPECT-CT and CT (axial slices) of lesions of T4 (B) and right ilium (C).**
- **(D) SPECT-CT and CT after 1 year of treatment by leuprorelin acetate showing an osteosclerotic reaction in the right ilium.**



- **Modern PET/CT imaging techniques provide better sensitivity and specificity of metastasis detection, especially in cases of biochemical recurrence with low values of prostate specific antigen.**

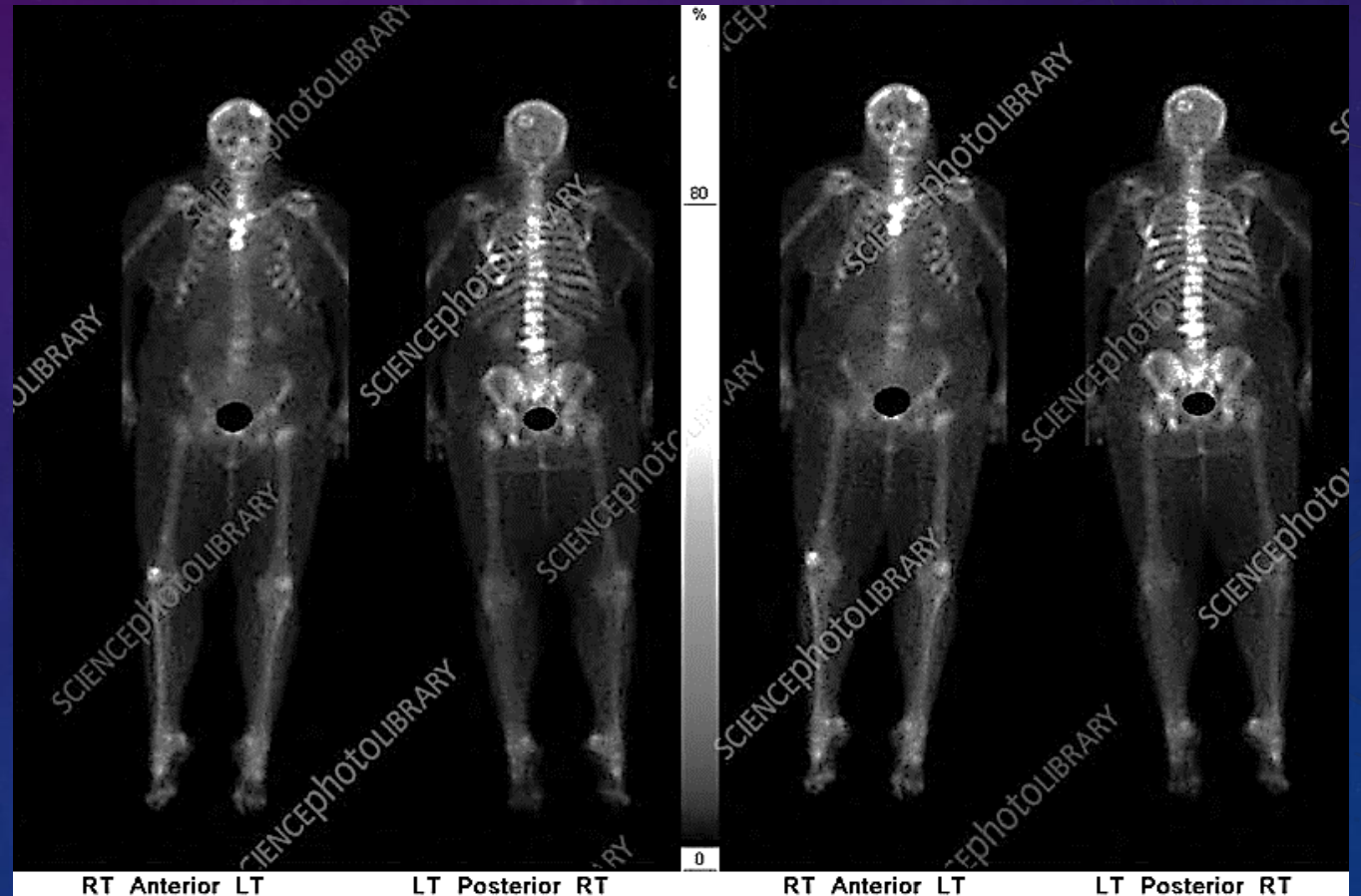
BONE SCAN

Impact of abnormal uptakes in bone scan on the prognosis of patients with lung cancer



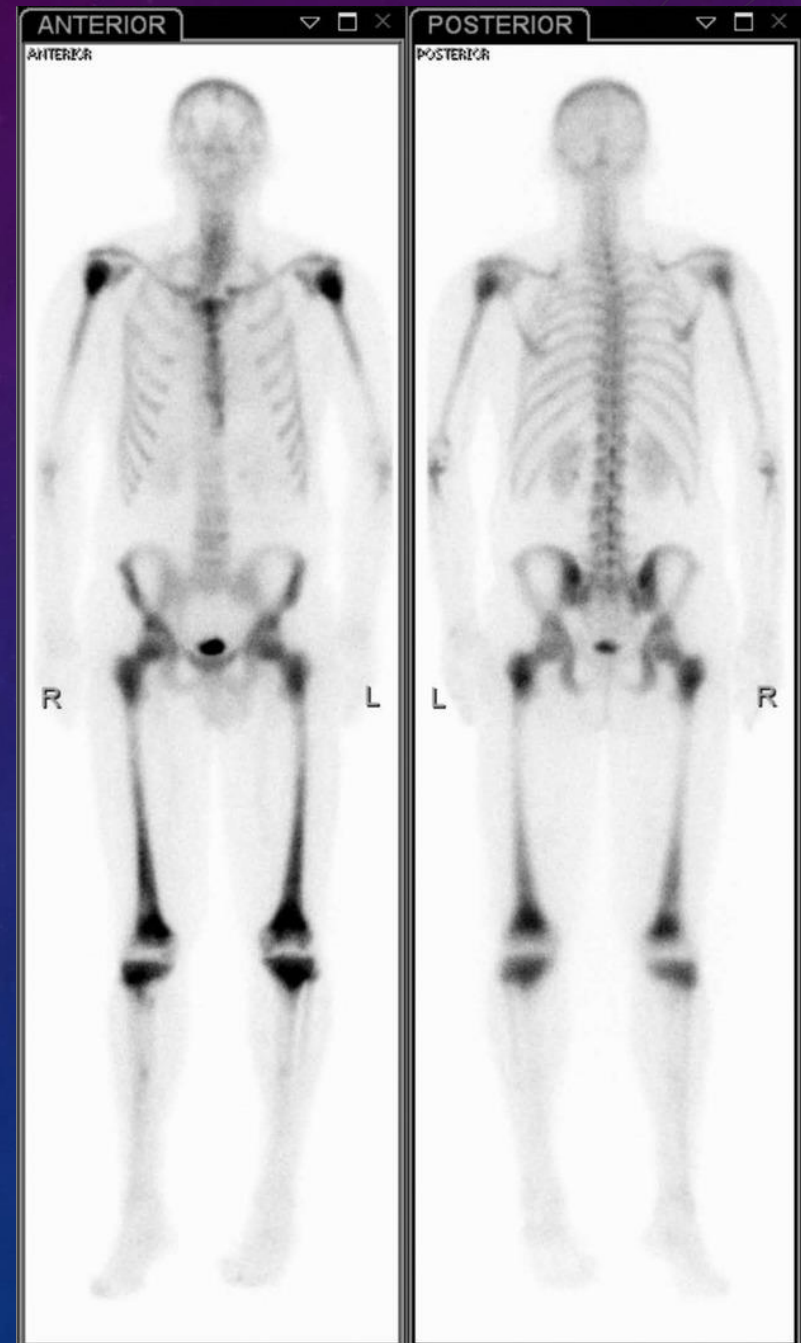BONE SCAN

- 66 year old female with metastatic breast carcinoma. Bone scan reveals abnormal radionuclide activity from metastases throughout the spine, rib, pelvis, hips and skull.



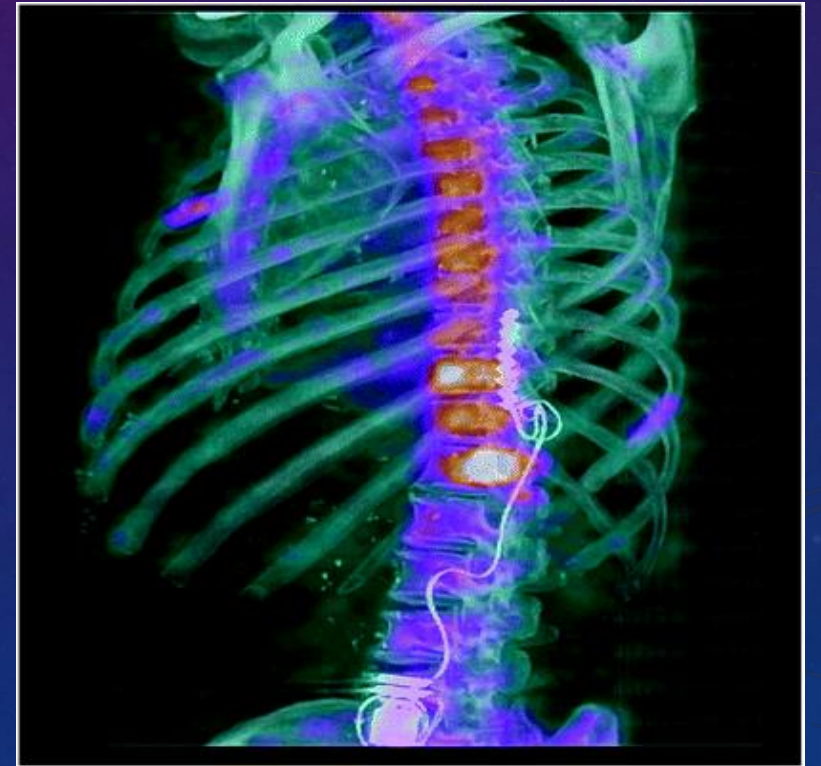BONE SCAN

- **Leucoerythroblastic anaemia, abnormal bone scan and prostate cancer with a primary haematological diagnosis**



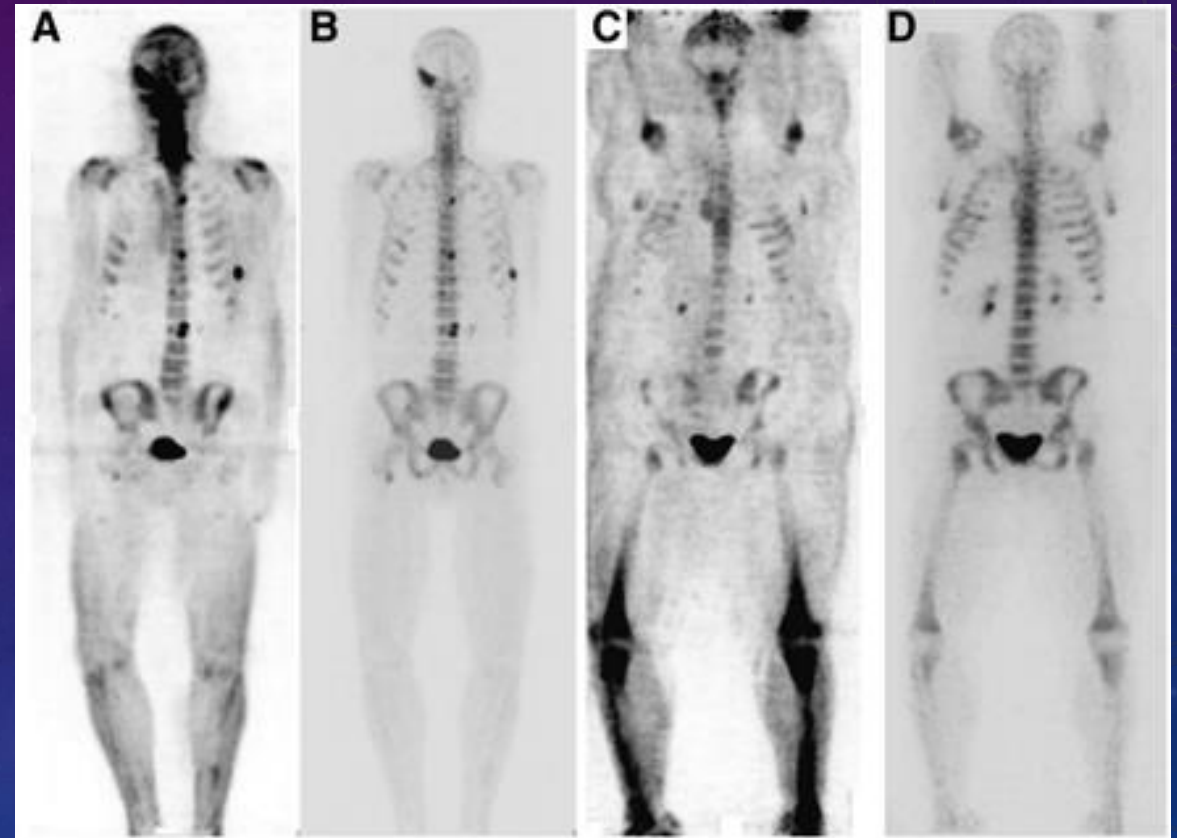
Na¹⁸F Bone Scintigraphy

- **3D 18F-FDG PET/CT fused image showing rib and vertebral metastases. Electronic pain control module and electrodes are present.**



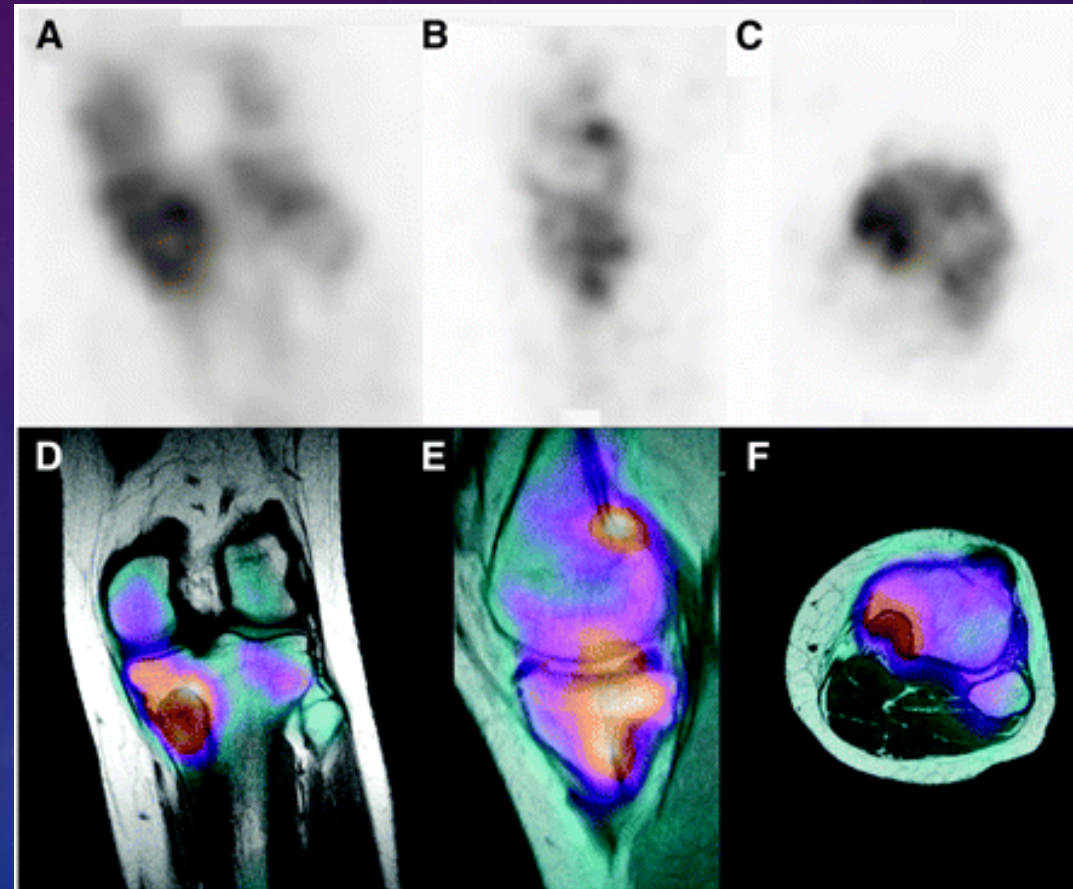
Na¹⁸F Bone Scintigraphy

- ¹⁸F bone scan MIP images without and with attenuation correction for small and very large patients.
- (A and B) Emission-only and attenuation-corrected anterior view of small-framed patient.
- (C and D) Emission-only and attenuation-corrected anterior view of obese patient. Attenuation correction is vital for detection of small lesions and provides excellent imaging of very large patients.
- PET is more sensitive than single-photon imaging to attenuation effects.



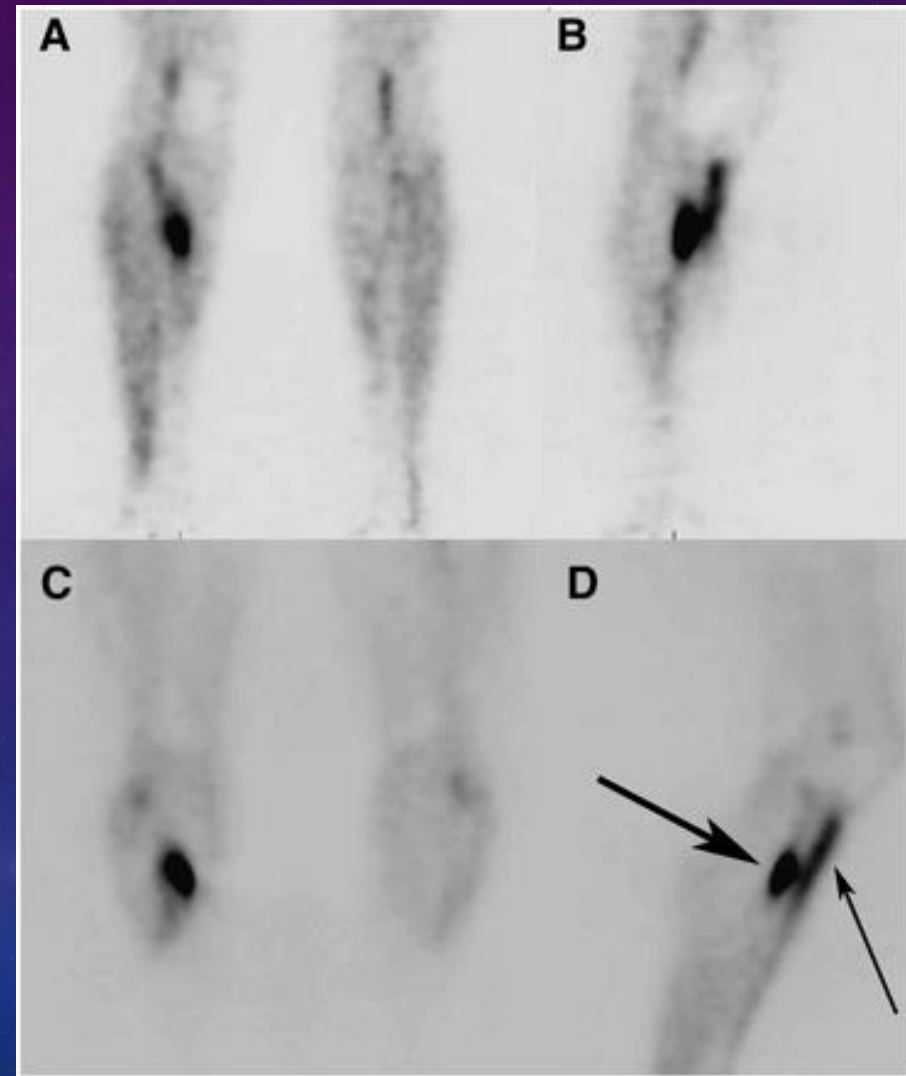
Na¹⁸F Bone Scintigraphy

- Medial tibial lesion in runner: positive ¹⁸F scan followed by MRI.
- (A–C) Coronal, sagittal, and axial images of main lesion and uptake in plateau, adjacent medial femoral condyle, and gastrocnemius origin.
- (D–F) Complementary images from fusion with MRI clarify extent and distribution of uptake.
- Principal uptake is due to weakened plateau from underlying benign tumor.



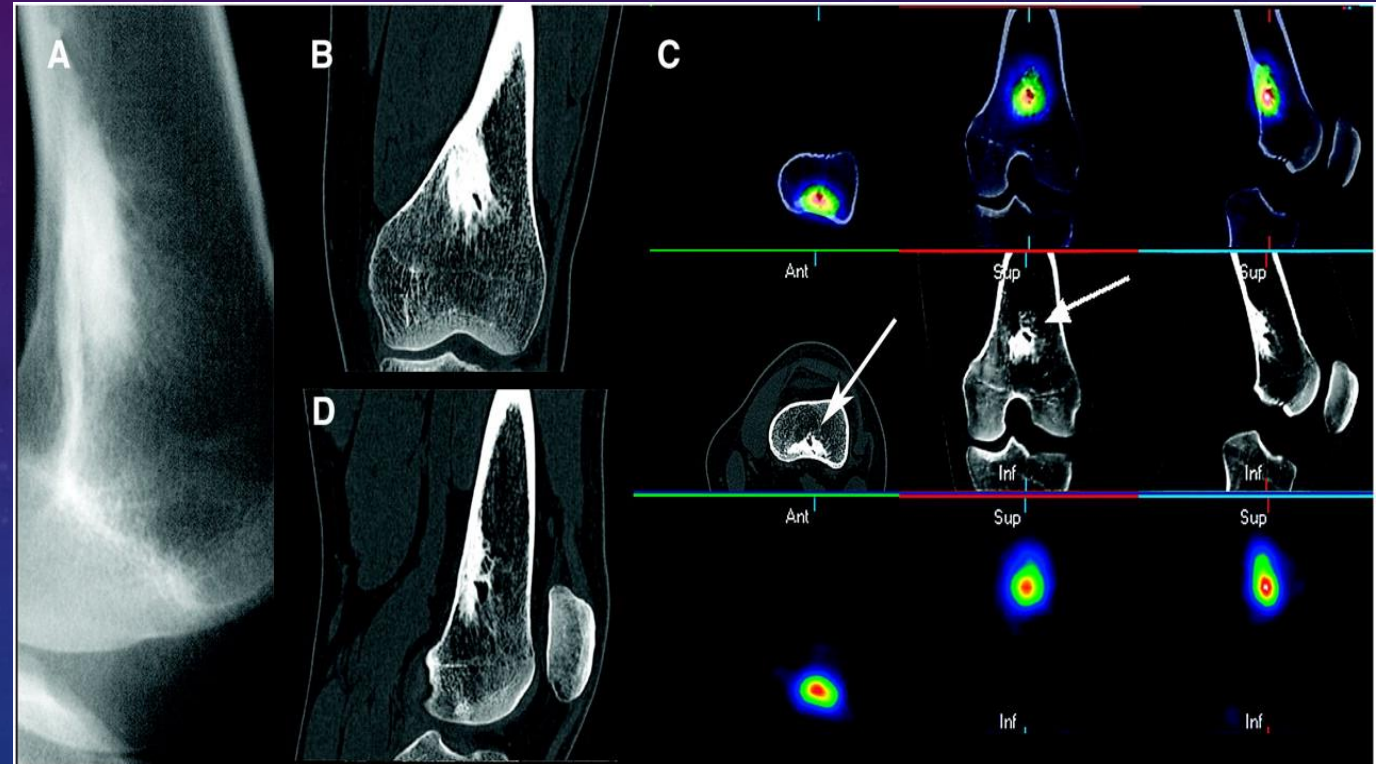
Na¹⁸F Bone Scintigraphy

- Stress fracture and shin splints of lower leg.
- (A and B) Blood-pool scan showing posterior stress fracture and anterior shin splints.
- (C and D) Delayed-image scan of stress fracture (large arrow) and shin splints (small arrow).



Na18F Bone Scintigraphy

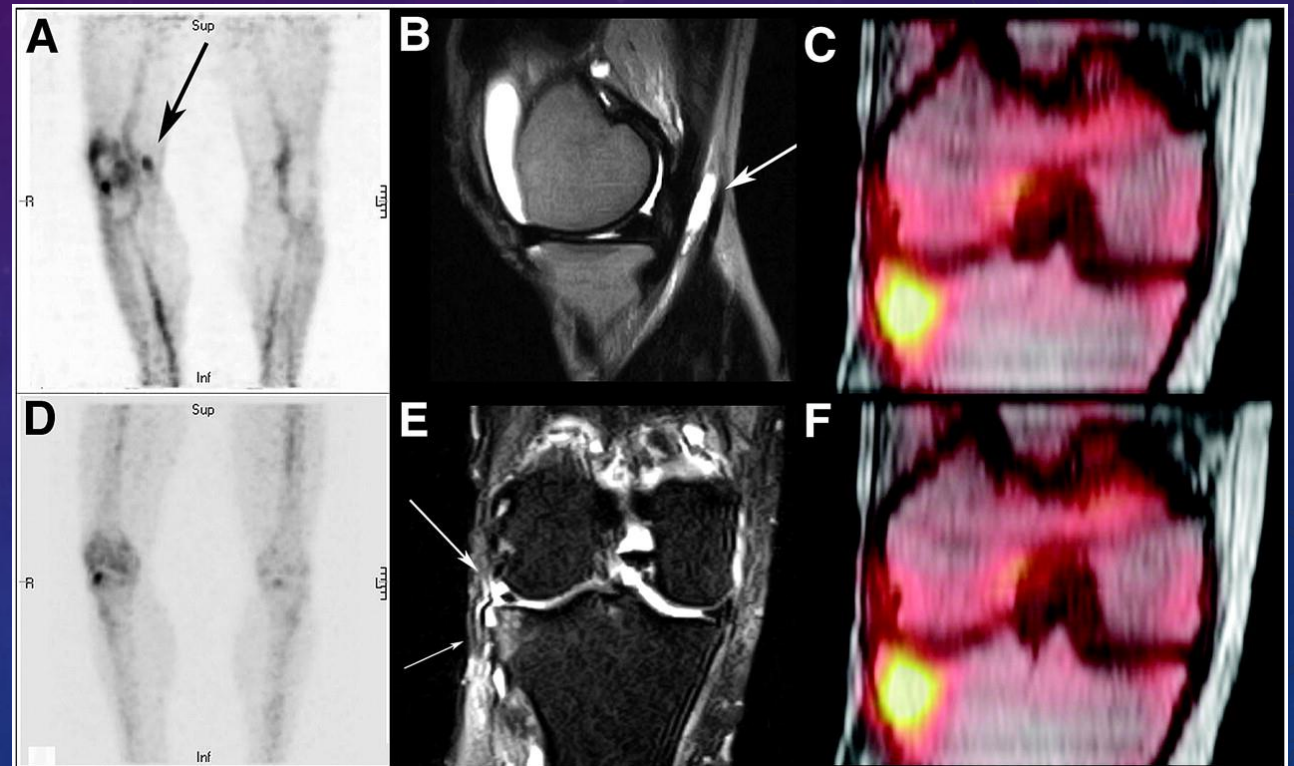
- Deep knee pain in young woman: osteoid osteoma.
- (A) Radiograph of irregular, highly sclerotic endosteal/trabecular lesion of distal femur.
- (B and D) Coronal and sagittal CT slices of highly sclerotic lesion with cystic internal margin.
- (C) Three-axis montage of fused PET bone/CT, CT, and PET bone scan of lesion (arrows) showing greatest uptake at margin of cystic area.



Na18F Bone Scintigraphy

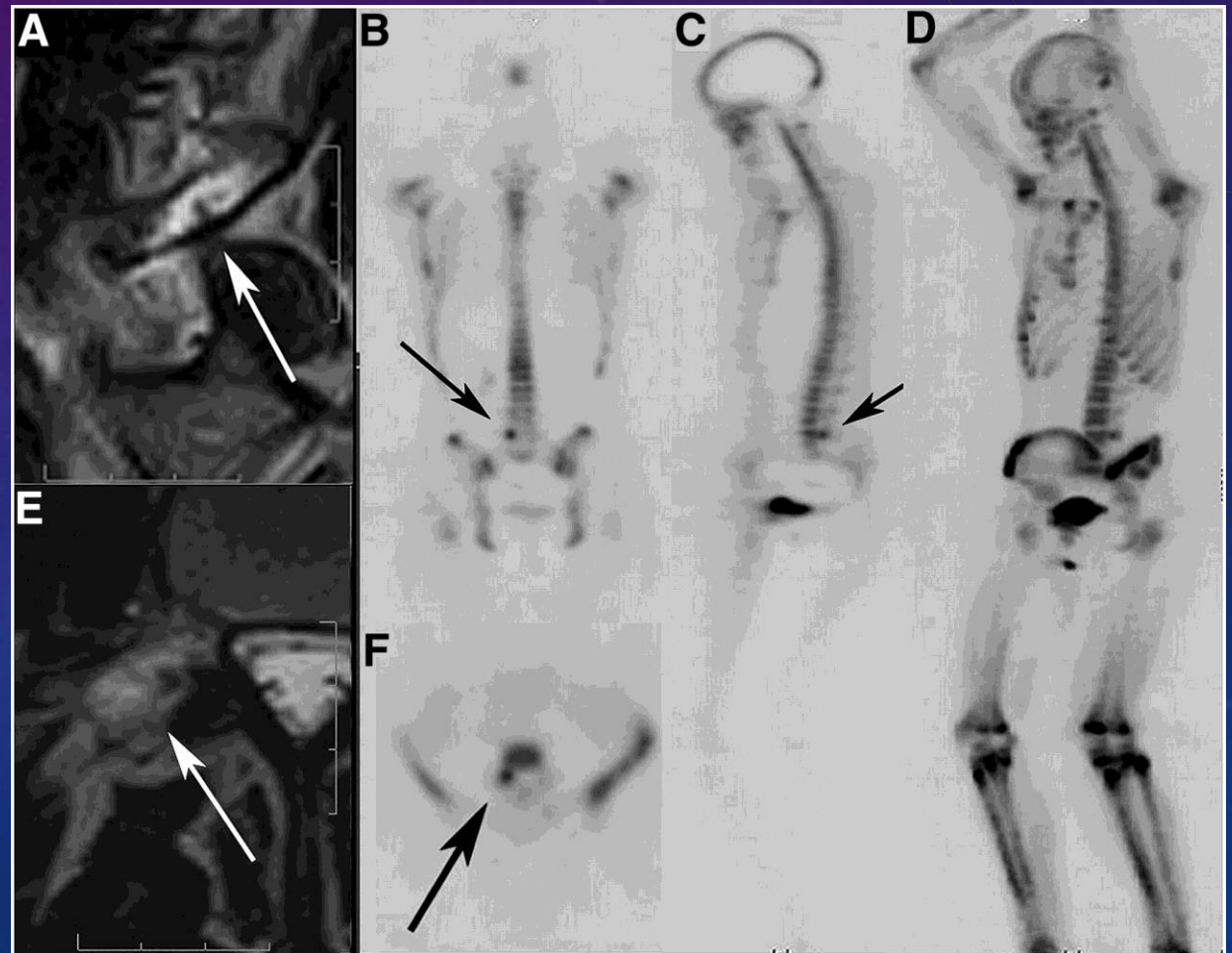
LATERAL KNEE PAIN WITH PREVIOUS LATERAL MENISCECTOMY.

- (A) Blood-pool scan showing hyperemia of synovial lining (pes anserine bursitis) and bony lateral tibial plateau. Arrow points to bursitis.
- (B) Large joint effusion and anserine bursitis (arrow) in same medial area of knee as in A.
- (D) Delayed image showing only single remaining hot area for lateral plateau.
- (E) Coronal short- τ inversion recovery MR image showing intact meniscal remnant (large arrow) and lateral tibial plateau signal abnormality (small arrow).
- (C and F) Fused 18F scan and MR image of knee localizing and confirming lateral plateau injury.

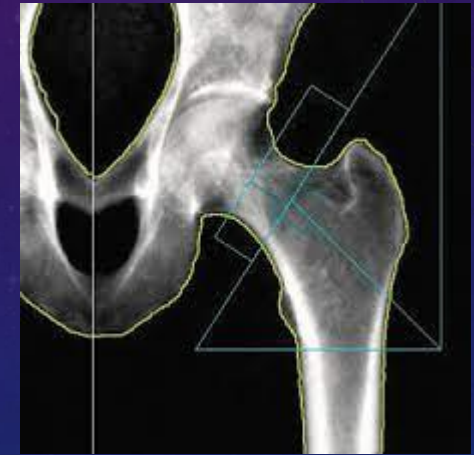
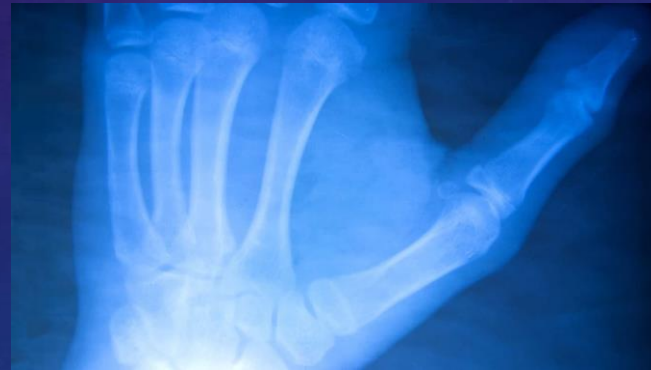
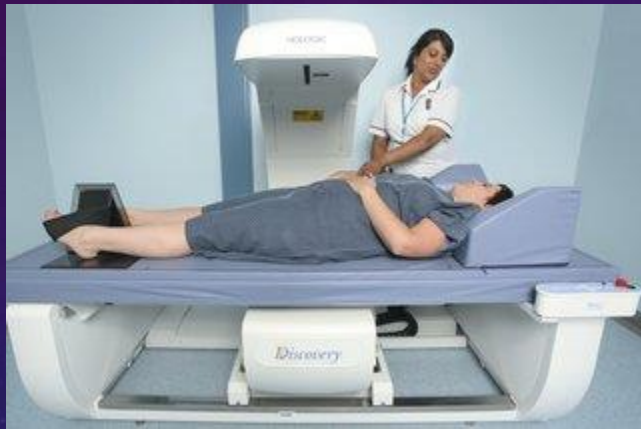Na¹⁸F Bone Scintigraphy

- Incipient fracture of right L5 pedicle/pars interarticularis area in young athlete.
- (A and E) Sagittal and transaxial T2-weighted MR images of incipient pars fracture.
- Arrows point to incomplete linear defect within, surrounded by edema. (B, C, and F)
- Bone scan localizing and confirming lesion in right L5 pars interarticularis area (arrows).
- (D) MIP of emission-only scan of patient. Note sharply defined lesion not obscured by bone edema.

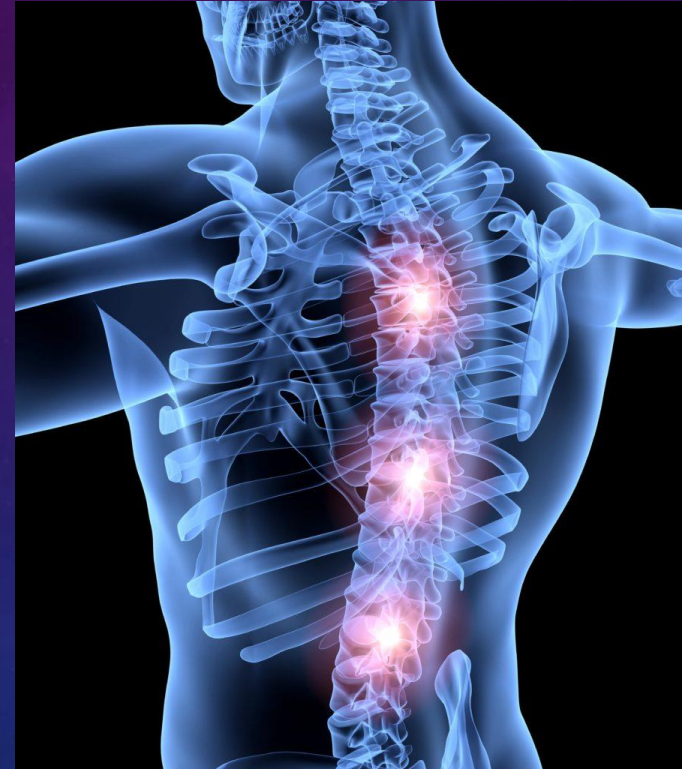


Dual-Energy X-Ray Absorptiometry DEXA-SCAN



DEXA SCAN

- A DEXA scan is an imaging test used to measure bone mineral density. In this type of bone density scan, two x-ray beams are aimed at the bones. The amount of radiation absorbed indicates how tightly packed minerals are inside the segment of bone tested.
- To get the most accurate results, radiologists focus DEXA scans on parts of the body most vulnerable to breaks from osteoporosis, primarily the hip and spine. If you cannot have a scan directed at the hip or spine — due to a hip replacement, for example — the scan will target the forearm instead.
- DEXA scans are recommended for women over age 65, men over age 70 and anyone with risk factors for osteoporosis.



- A T-score greater than -1 is considered normal
- A T-score between -1 and -2.5 indicates osteopenia
- A T-score lower than -2.5 indicates osteoporosis

DEXA SCAN

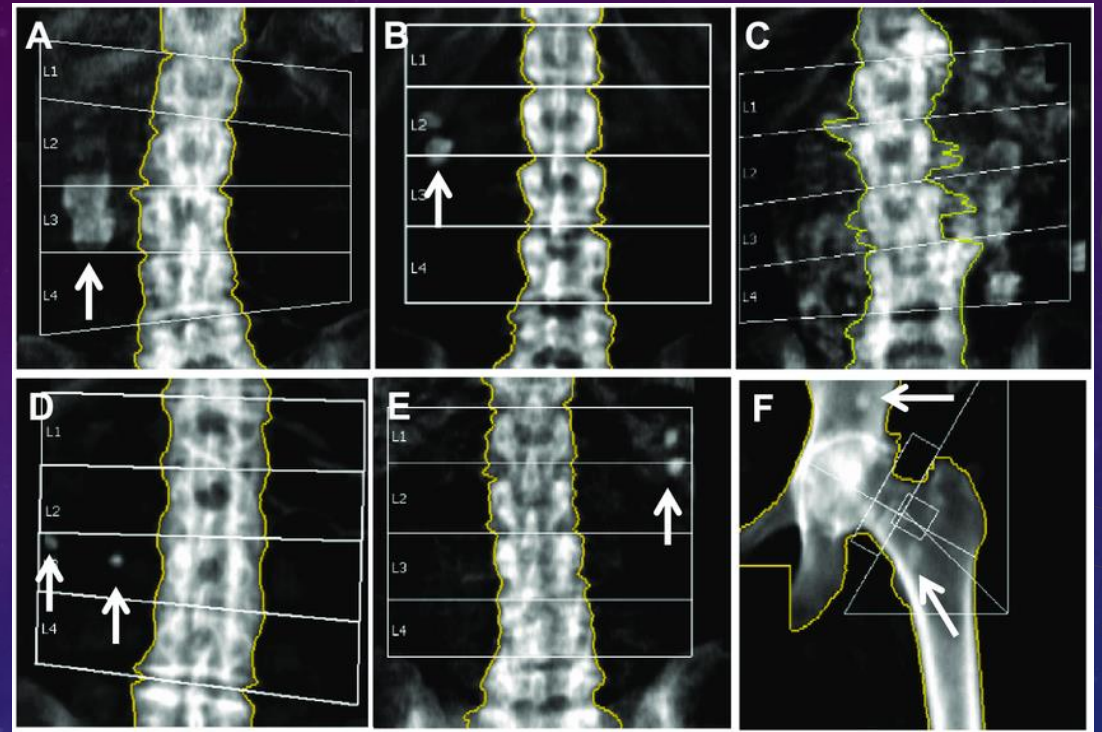
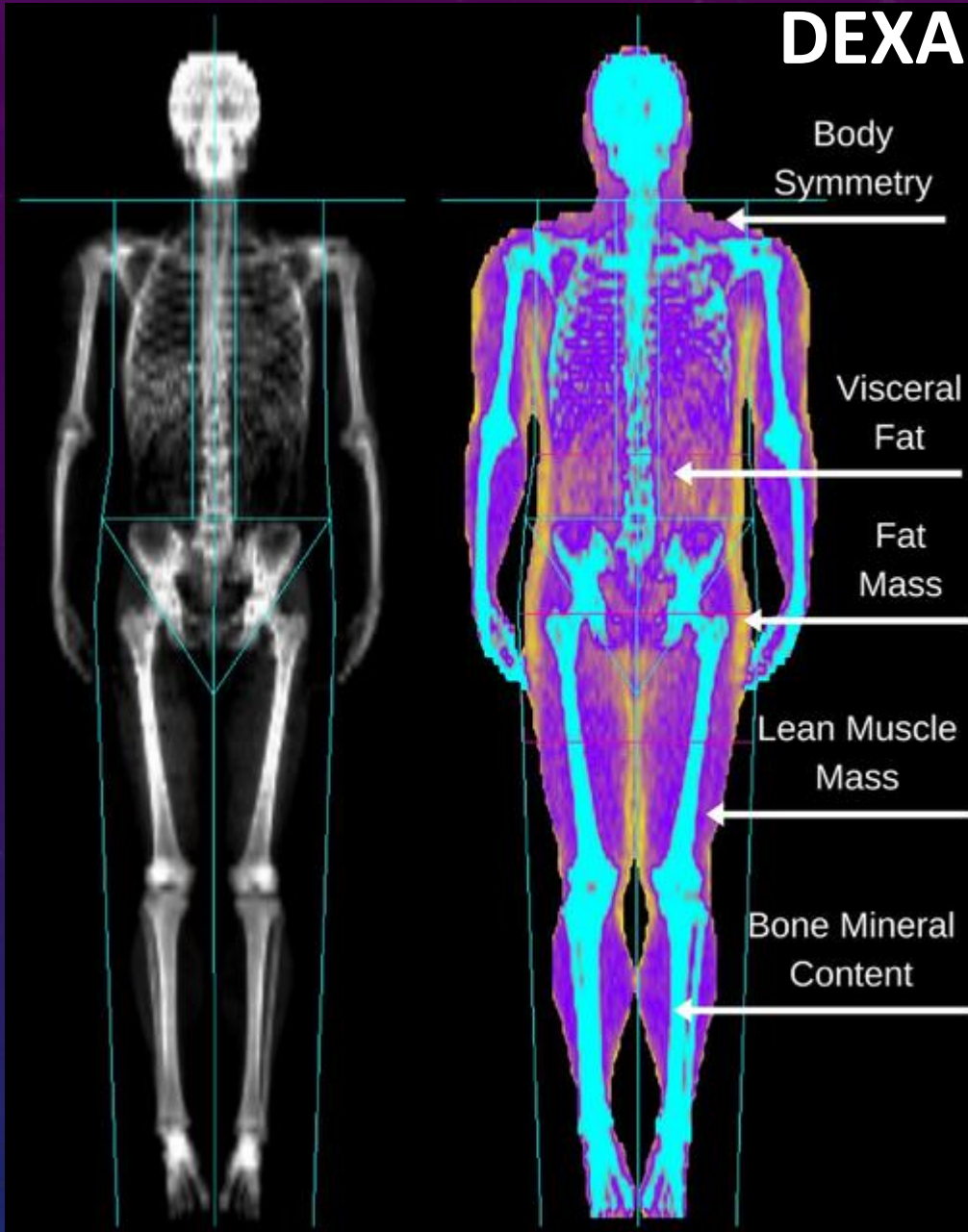
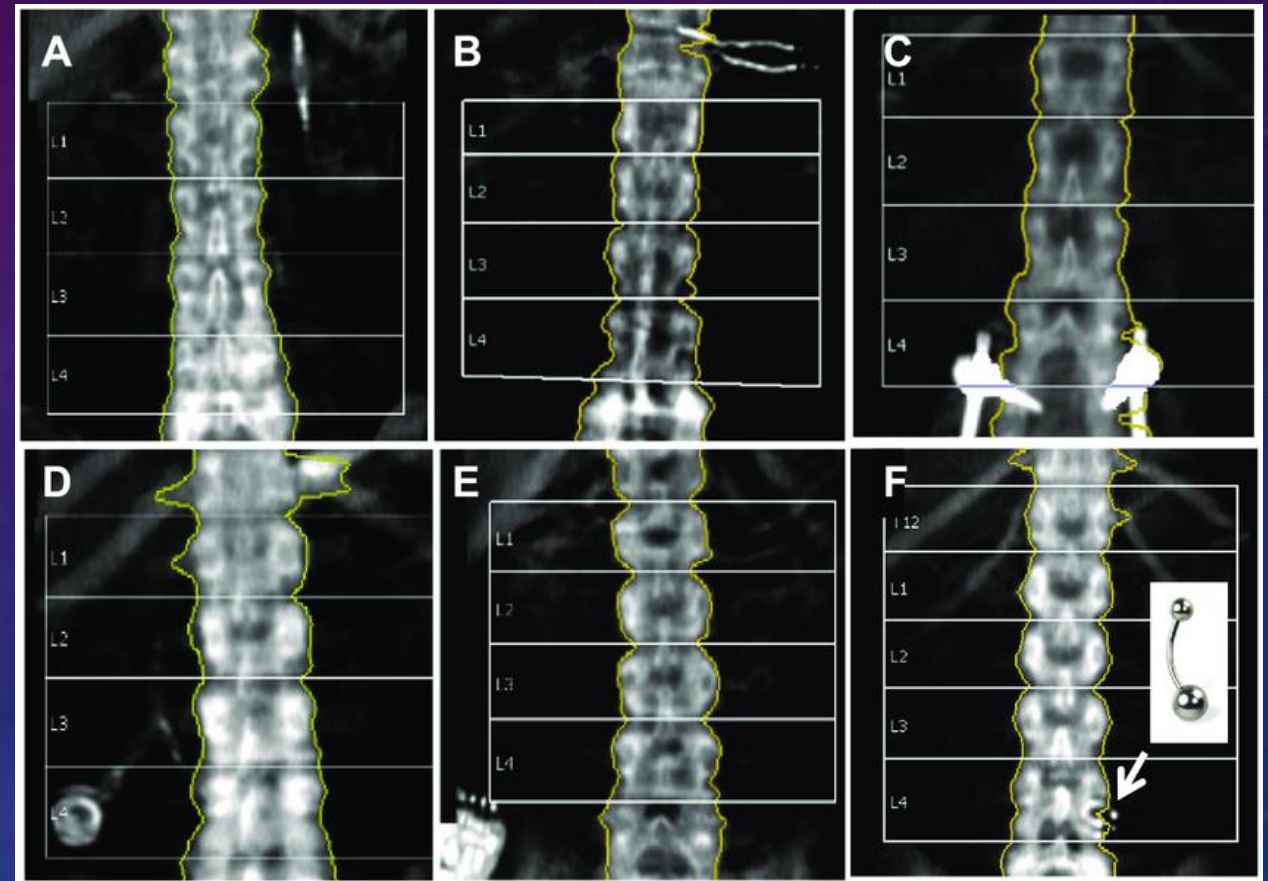


ILLUSTRATION OF SIX EXAMPLES OF CALCIFICATION ON DEXA IMAGING (ARROWS):

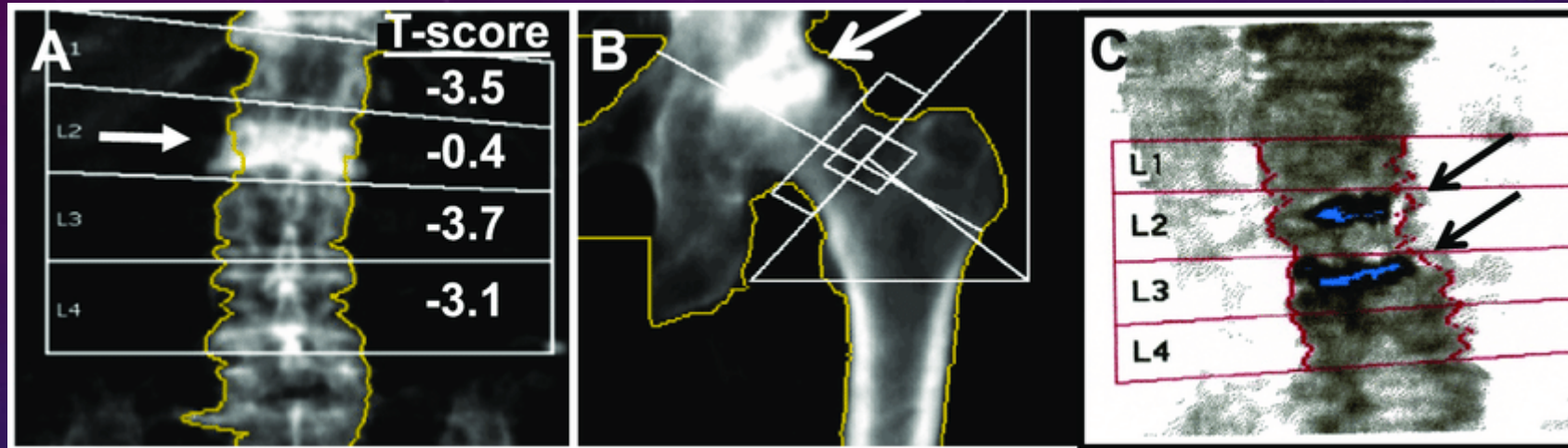
- (A) Porcelain gall bladder,
- (B) gallstones,
- (C) huge leiomyofibroma with extensive calcifications overlapping lumbar spine,
- (D) calcified retroperitoneal lymph nodes,
- (E) left renal stones, and (F) buttock granulomata overlying hip ROIs.

DEXA SCAN

- Illustration of six examples of metallic hardware.
- (A) Ventriculo-peritoneal shunt connector (right upper corner),
- (B) ventricular pacemaker wire (right upper corner),
- (C) L4-L5 fusion hardware,
- (D) lap-band port (left lower corner),
- (E) sacral nerve stimulator (left lower corner), and
- (F) body piercing jewelry (see insert).
- In (C) and (F), the densities overlies the spine ROI, which necessitates editing to eliminate the offending artifacts.

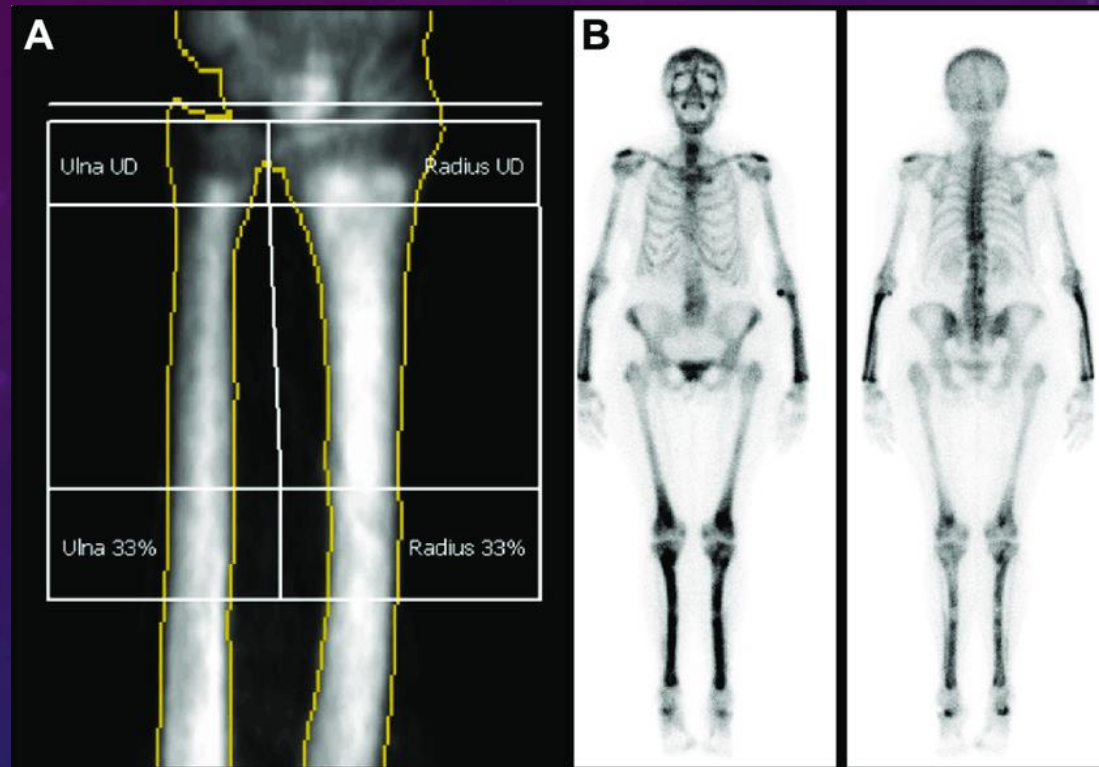


DEXA SCAN



- (A) An 88-year-old woman with fracture of the L2 vertebral body (arrow) demonstrates diffusely decreased BMD with exception of the level of the compression fracture.
- (B) A patient with avascular necrosis of the left femoral head (arrow). The femoral head appears dense and is associated with flattening and deformity.
- (C) DEXA image in a patient status post vertebroplasty of L2 and L3 with introduction of radiopaque cement preparation (arrows).

DEXA SCAN



Metabolic and genetic causes of diffusely increased BMD are distinctly uncommon and can be due to a host of different conditions.

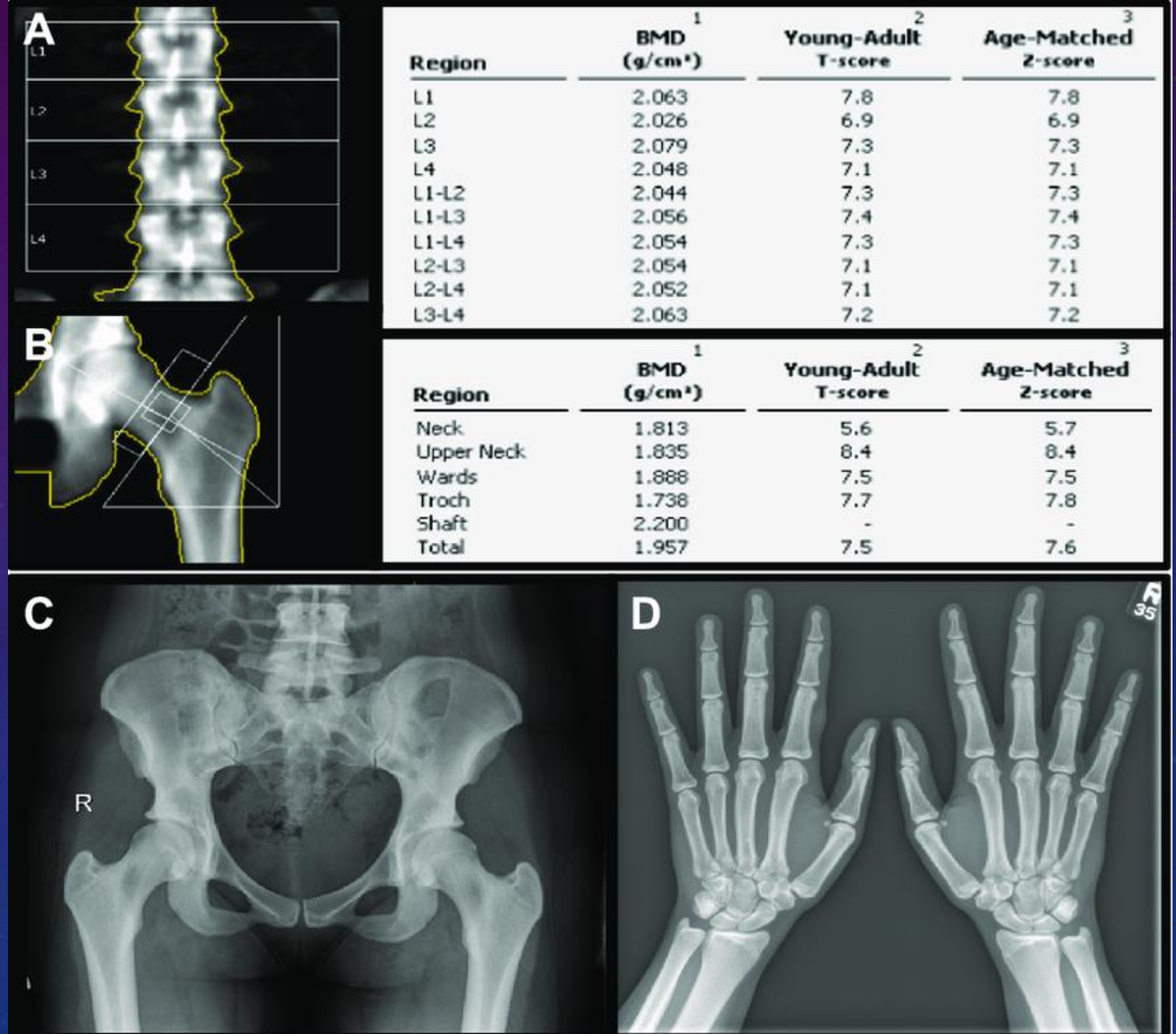
(A) Diffuse sclerotic changes within the trabecular bone of the distal forearm. Radionuclide bone scan

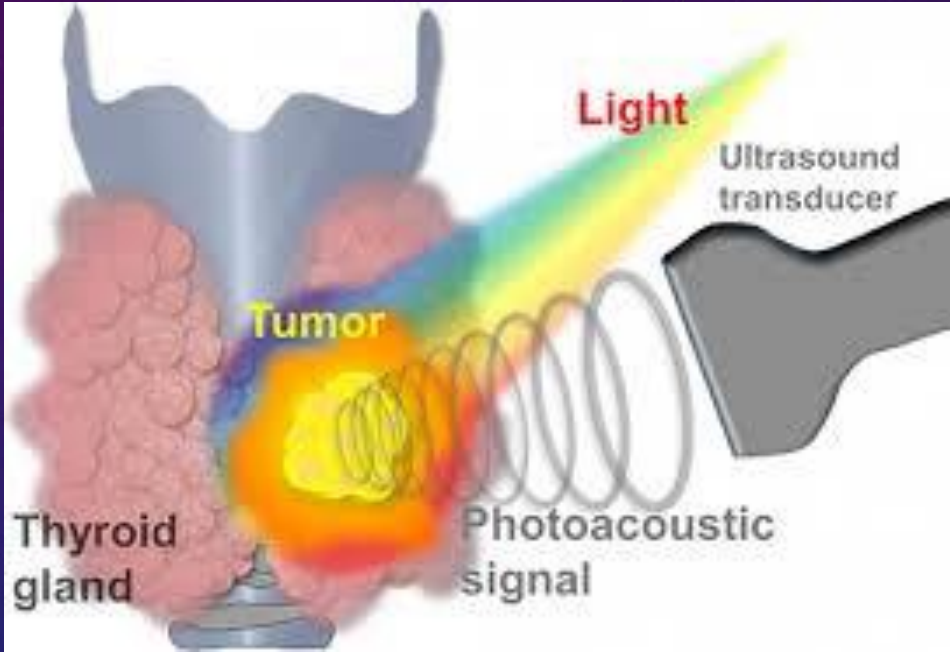
(B) demonstrates symmetric, increased osteoblastic activity in multiple distal long bones.

The patient is diagnosed with **Camurati-Engelmann disease.** ↑ thickness of bones (hyperostosis)

DEXA SCAN

- A female patient in her third decade demonstrates markedly increased BMD
- in the spine(A) and hip (B), with Z scores in the 7-8 range.
- Review of the patient's imaging (C and D)
- and medical history resulted in a diagnosis of **AlbersSchonberg** disease (osteopetrosis, autosomal dominant type 2).





homogenous
(normal)

non-homo
(tumor)

Thyroid imaging

THYROID IMAGING

سكانا 24 سبب
Per-PS

24 سبب

- **THYROID UPTAKE AND SCAN**—provides information about the structure (size, shape, position) and function of the thyroid gland


The radioactive iodine uptake test (RAIU) is also known as a thyroid uptake. It is a measurement of thyroid function, but does not involve imaging.

iodine 151 Microcuri

$$\frac{1}{10^6}$$

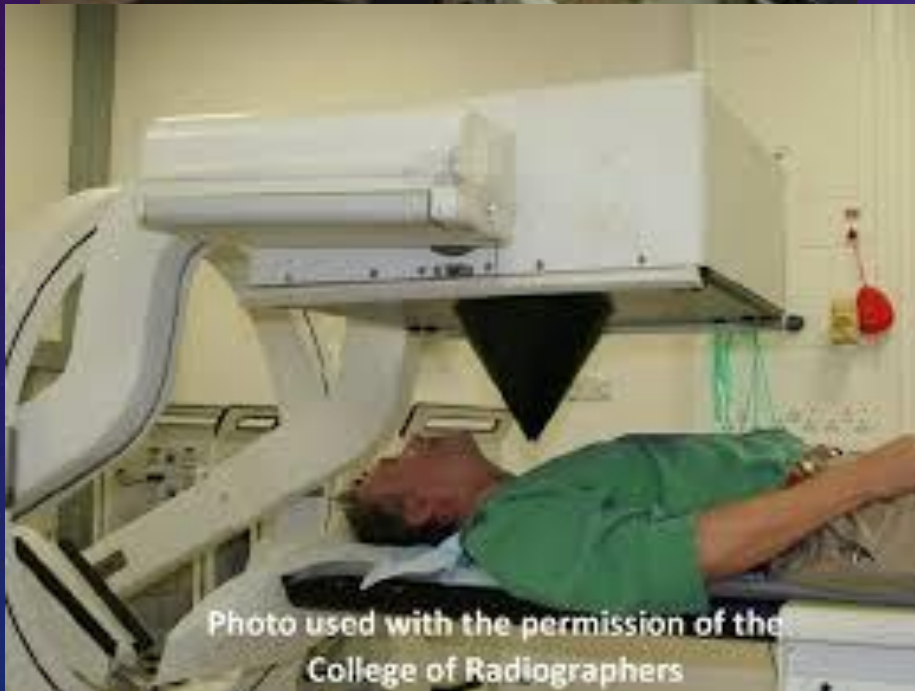
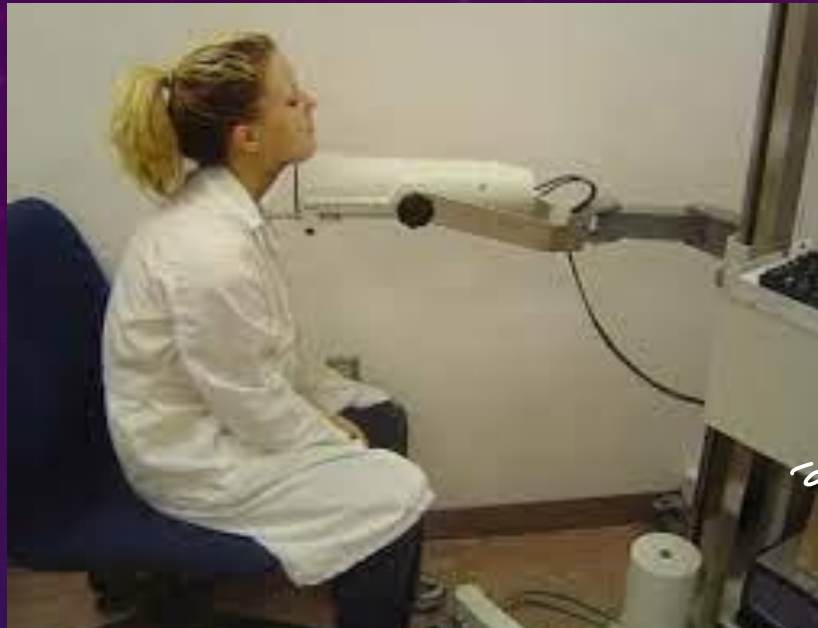
Photo used with the permission of the College of Radiographers



دولہ
dose: 3-5 kuri

8 (ماہی) کی تالی (ماہی)

in scan 50-100 micro-curi

THYROID IMAGING

- A thyroid scan (thyroid scintigraphy) is a diagnostic nuclear medicine test that provides information about the structure and function of the thyroid.
- The nuclear medicine physician is able to see the size, shape, function, and position of the thyroid gland.

* isotobas انجاشي نوزيب ال

homogenous (even)
non ~
equal in both sides
unequal

position

Anterior RAO LAO

Normal Thyroid Scan

Thyroid ب

Thyroid/salivary/stomach
الكلية/البنكرياس

isolated
الكلية
salivary

mouth
c. neck



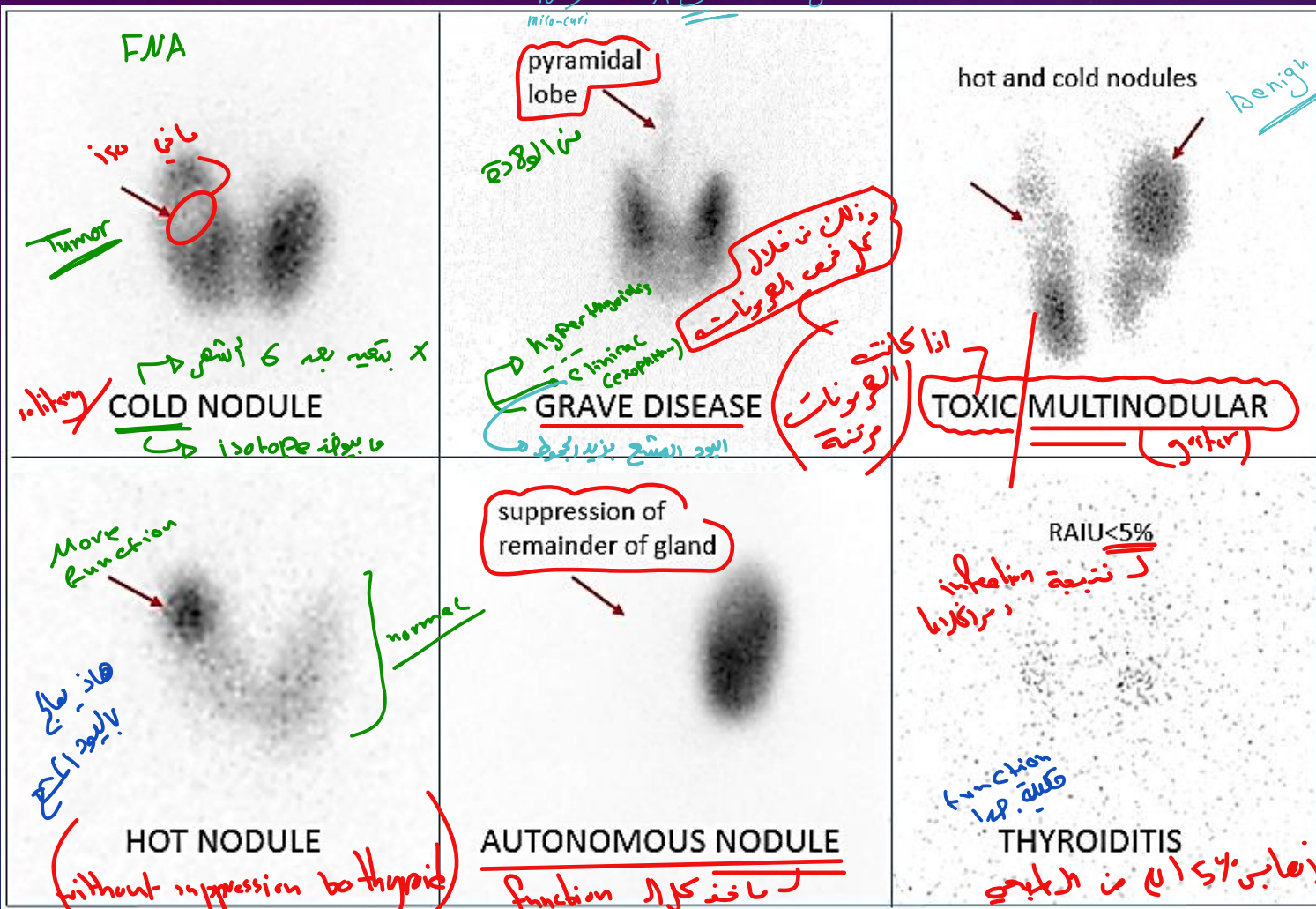
homogenous

Localization
size

home
equal
نوزيب

البيوت بورد مع شاكله
كمبرلات (5)

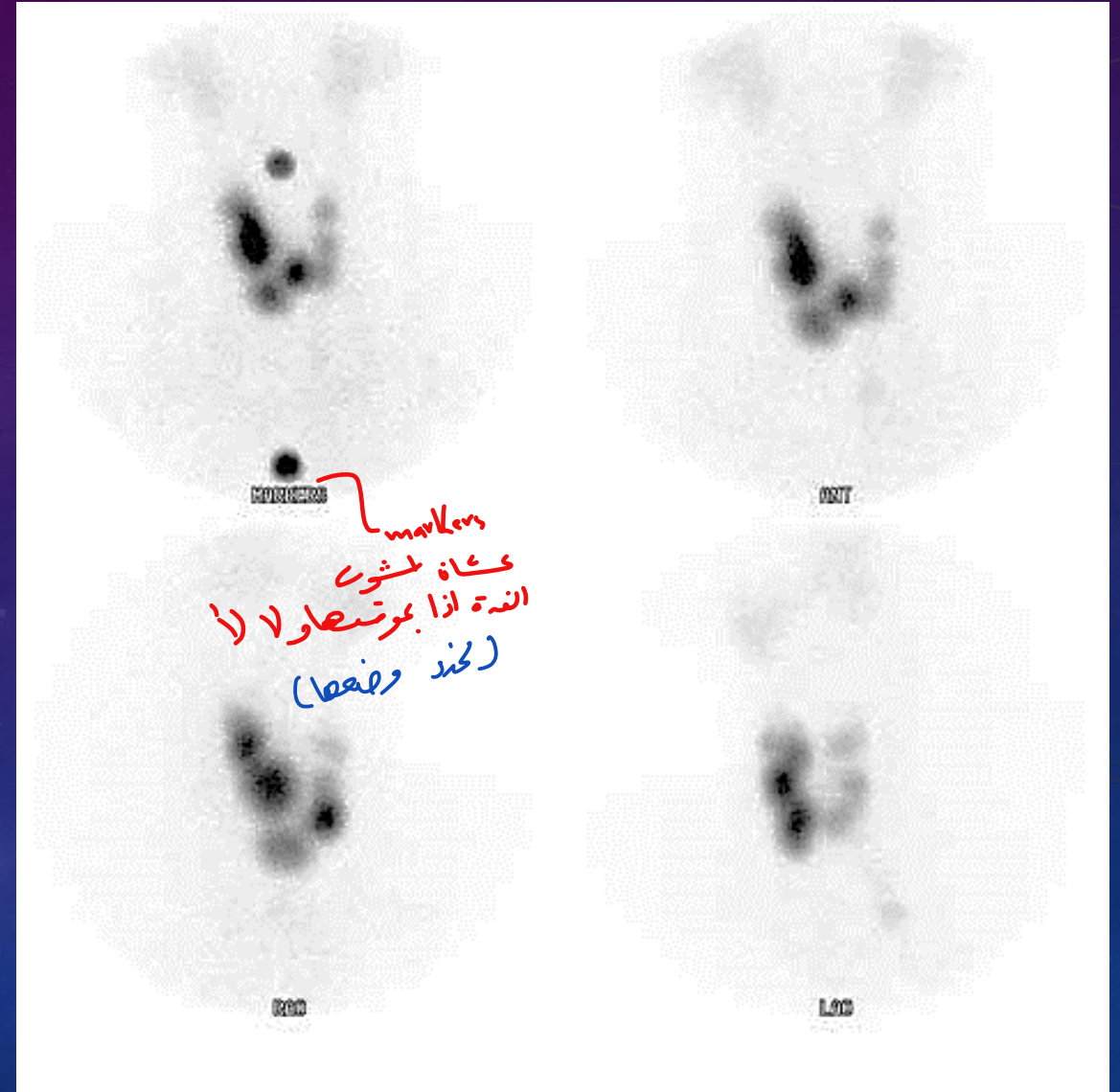
THYROID IMAGING



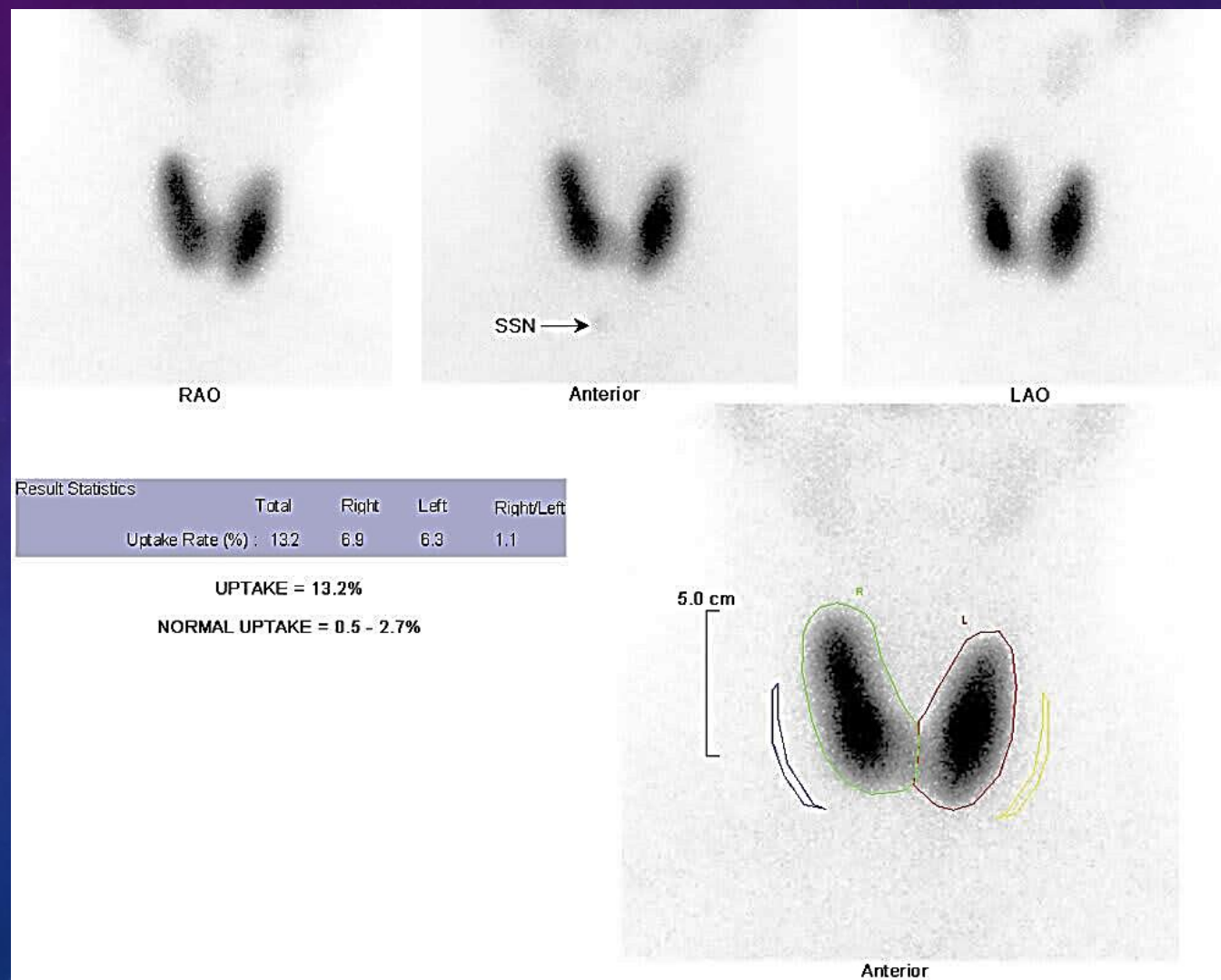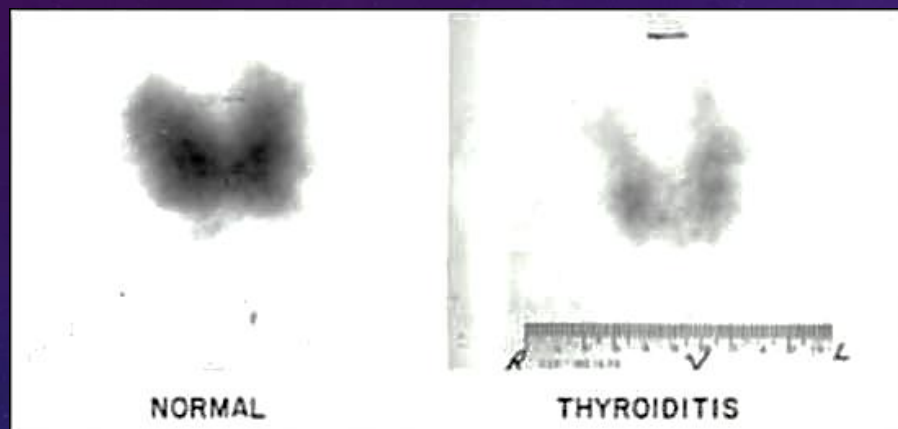
THYROID IMAGING

- This is a thyroid scan that shows multiple irregular rounded bright areas within the thyroid. This represents a 'multi-nodular' goiter.

localization



THYROID UPTAKE



THYROID IMAGING

Types of Thyroid Toxicity (and Normal)

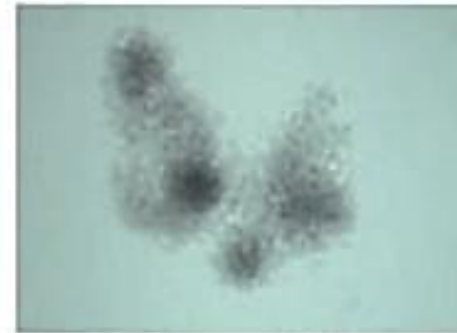


Normal Uptake



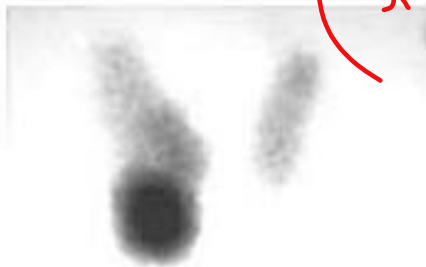Graves Disease

hyperthyroidism with exophthalmos

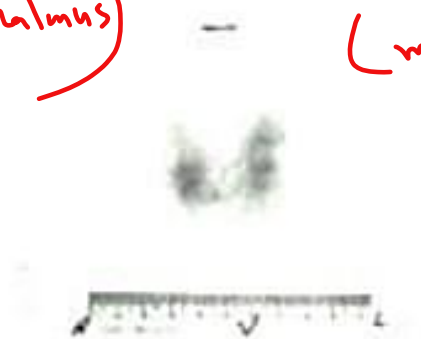


Thyroiditis "Hashimoto's"

multi-nodular goiter



Autonomous Nodule "Plummer's"



Multinodular Goiter

بوخذ المربز جرعة ثابتة في الامه كروي

(من البرد)

كارت م س بي
مقطع ضيق

- ايم جوية ممكن
اعطيا في
بأ سبب كروي، الانبي
حالة ال cancer
ان يعطين اكثر

هذا المربز
كالسك توكه اقبه
ممكن زرع اولو زي ال
normal
الدمك

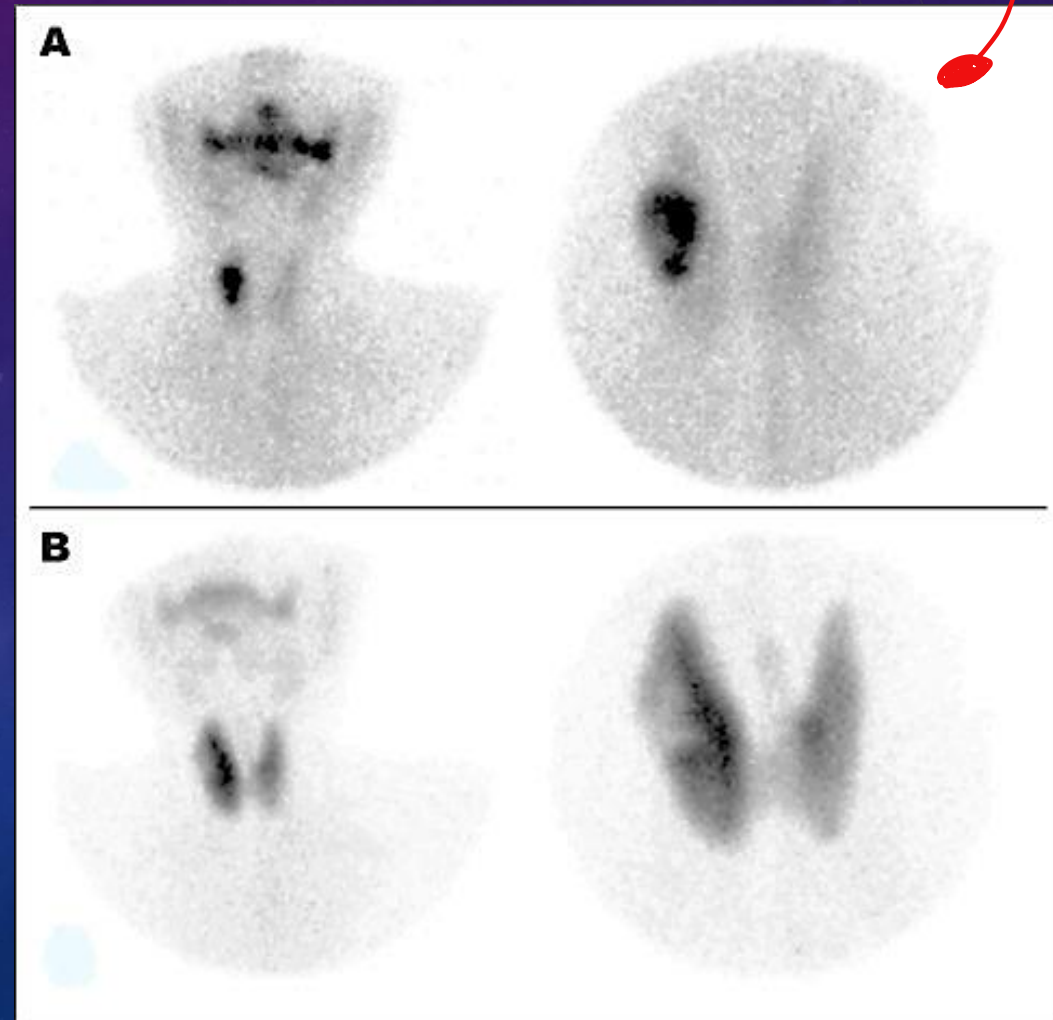
THYROID IMAGING

Diagnosis of Postpartum Thyroiditis and Co-Existing Thyroid Nodule

- Following oral administration of a standard dose (5 to 9 uCi) of ^{131}I sodium iodide, the activity in the thyroid gland was counted at 24 hours and the uptake calculated.
- Thyroid pinhole scintigraphy was performed after administration of 10 mCi $^{99\text{m}}\text{Tc}$ -pertechnetate intravenously (A). the majority of the nodule is relatively "hot."
- $^{99\text{m}}\text{Tc}$ -pertechnetate thyroid scan showed a large nodule with intense radiotracer uptake

ملاحظة

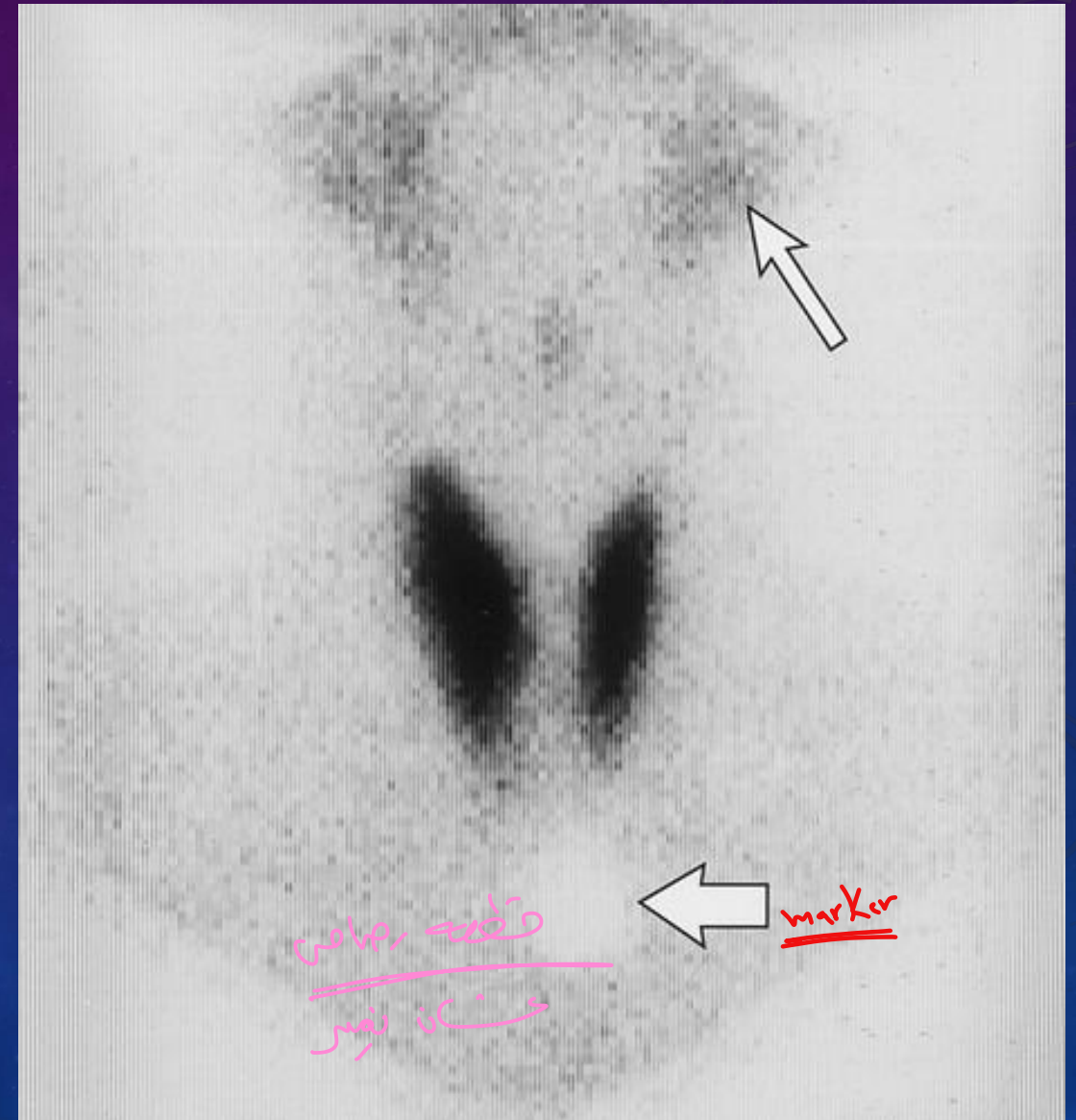
POSTPARTUM THYROIDITIS



THYROID IMAGING

- Silent thyroiditis in a 28-year-old woman with hyperthyroidism. Laboratory values were as follows: T4 = 21 $\mu\text{g/dL}$, T3 = 289 $\mu\text{g/dL}$, and TSH < 0.02 $\mu\text{IU/mL}$. RAIU was less than 1% at 24 hours.
- (a) On a distant anterior scintigram, the thyroid is barely visible (broad arrow at left). The round photopenic area (thick arrow) represents a 2-cm lead marker placed at the suprasternal notch. The dark structures (thin arrow) represent the salivary glands. Because of associated thyromegaly and the patient's morbid fear of thyroid cancer (as diagnosed in a sibling), large-core needle biopsy was performed.
- (b) Photomicrograph (original magnification, $\times 150$; hematoxylin-eosin [H-E] stain) demonstrates mild lymphocytic infiltration within the thyroid parenchyma.

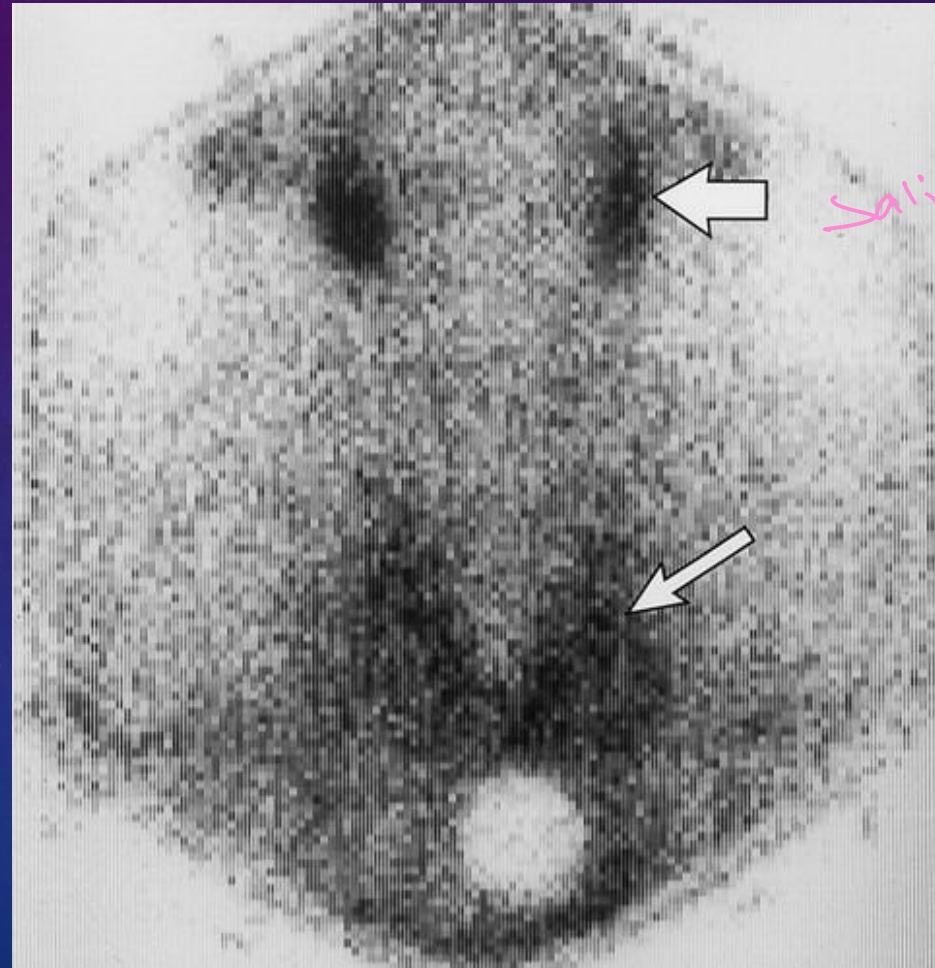
AUTOIMMUNE THYROIDITIS



THYROID IMAGING

- **Postpartum thyroiditis** in a 27-year-old woman who was experiencing palpitations, nervousness, and insomnia 2 months after giving birth. At physical examination, the patient's thyroid felt enlarged and nodular. Laboratory values were as follows: T4 = 17.3 $\mu\text{g/dL}$, FT4 = 2.4 ng/dL, and TSH < 0.02 $\mu\text{IU/mL}$.
- The 24-hour RAIU was 2%. Anterior image shows an enlarged thyroid with poor radiotracer concentration (thin arrow) .
- Thick arrow indicates the salivary glands.

بعد الولادة
تتصرف الحامل
بشكل / زيادة

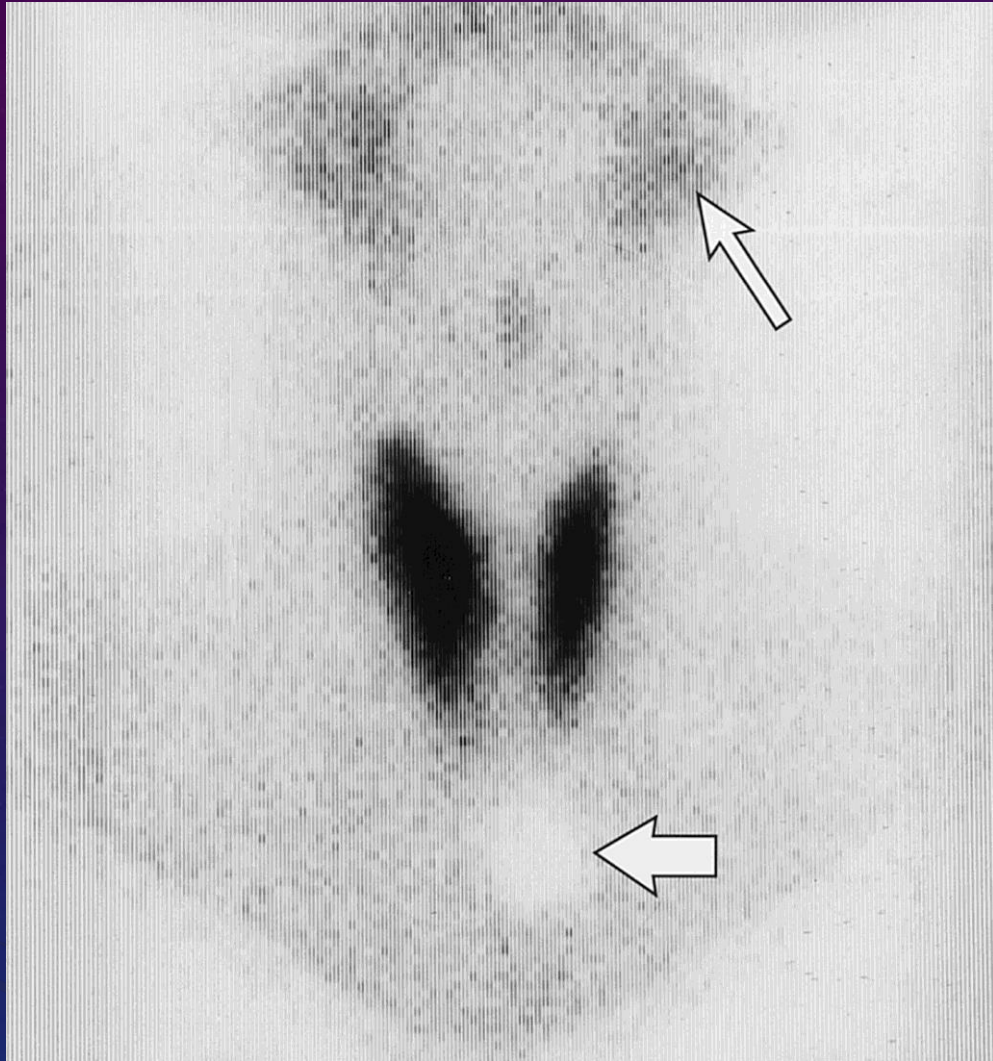


Salivary gland

THYROID IMAGING

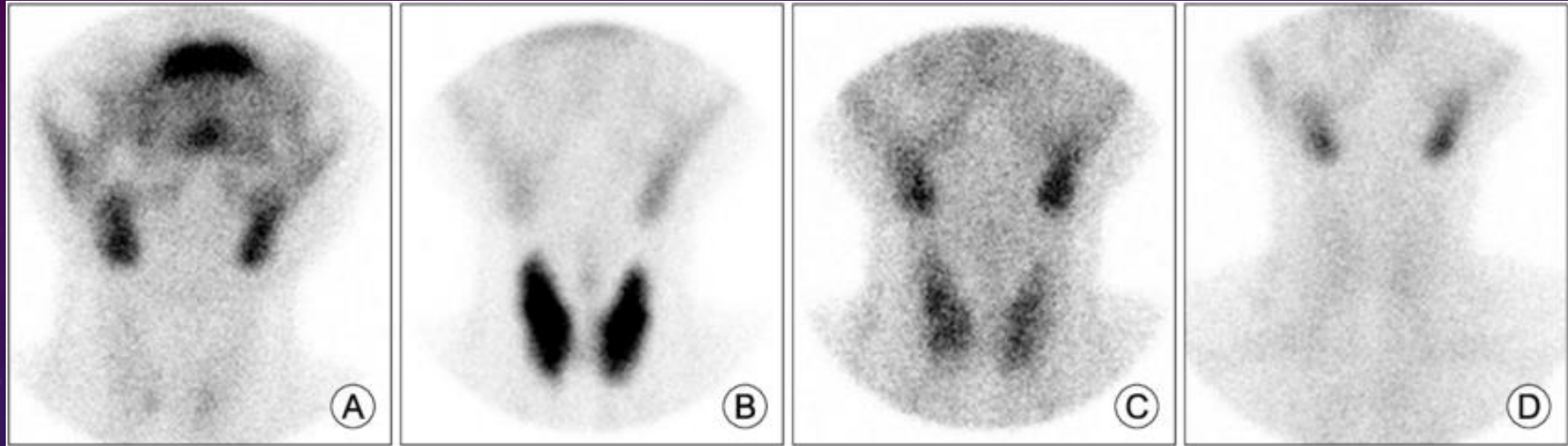
صحيح بالعمرة مية امثل

نكلا نكلا (normal)



- Early-stage Hashimoto thyroiditis in a 42-year-old woman who presented with goiter as well as firmness of the right thyroid lobe. Laboratory values were as follows: T4 = 7.6 $\mu\text{g/dL}$, T3 = 121 ng/dL, and TSH = 5.5 $\mu\text{IU/mL}$. The 24-hour RAIU was mildly elevated at 39%.
- (a) Anterior scintigram demonstrates an enlarged thyroid with diffusely increased radiotracer uptake (high target-to-background activity), findings that are similar to those in a diffuse toxic goiter. Note the decreased background activity as shown by the low radiotracer concentration in the salivary glands (thin arrow). The photopenic area (thick arrow) represents the cold sternal marker.

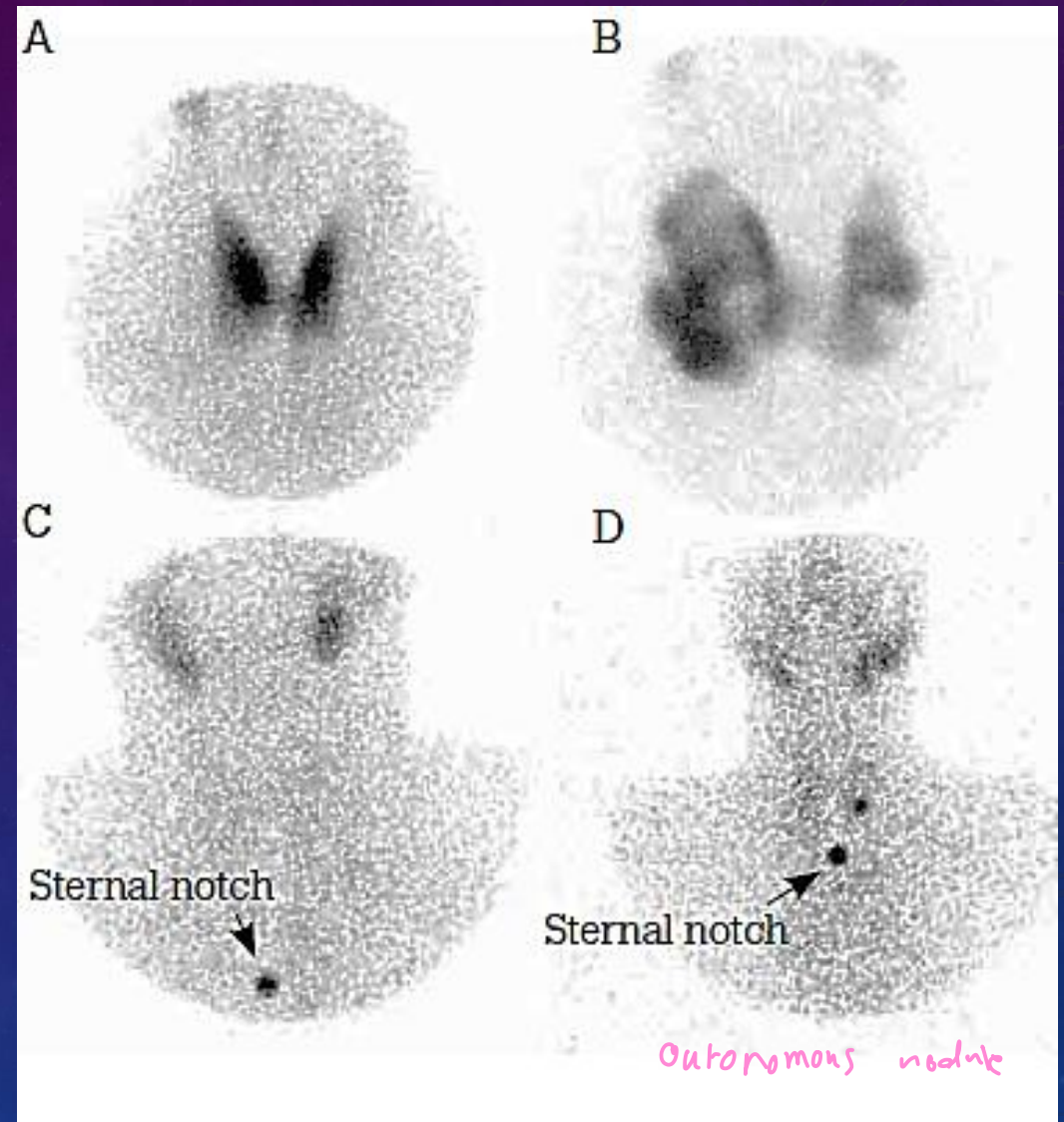
THYROID IMAGING



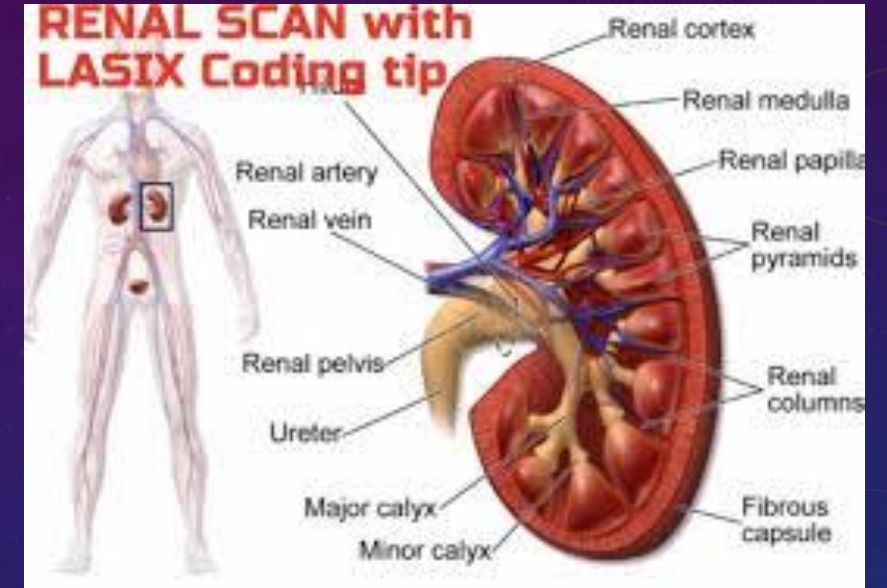
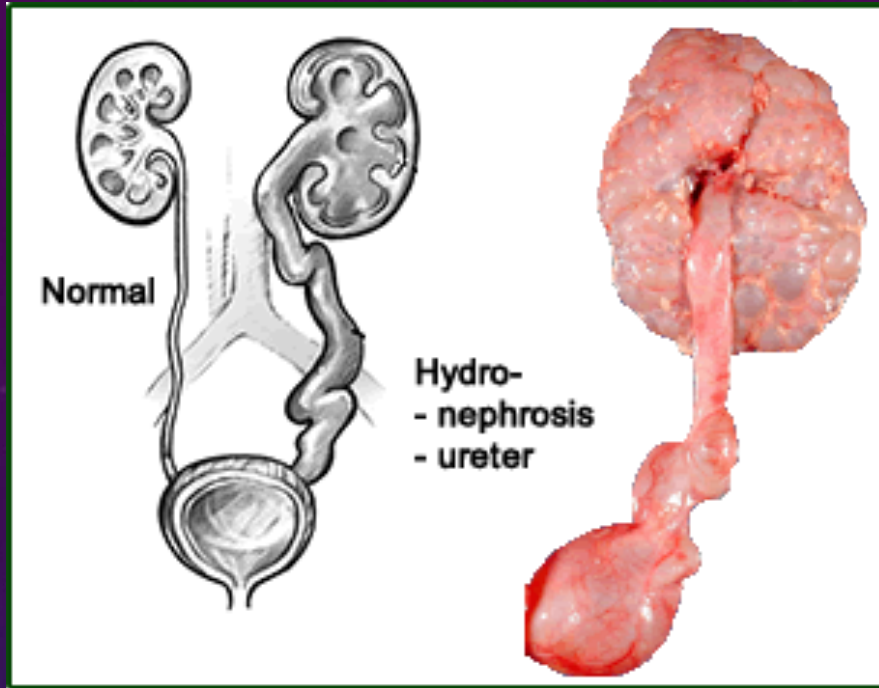
- Anterior view images of a Tc-99m pertechnetate scan in thyrotoxic phase.
- (A) Postpartum thyroiditis,
- (B) The first episode of hyperthyroidism,
- (C) The second episode of hyperthyroidism,
- (D) A relapse of postpartum thyroiditis.
- The normal range of thyroid trapping index in the laboratory is 2.5-6.0. In this case, they were 1.2 (A), 11.3 (B), 3.4 (C), and 1.1 (D).

THYROID IMAGING

- Typical scan appearances of common causes of thyrotoxicosis
- A) Graves disease;
- B) Multinodular goitre;
- C) Thyroiditis;
- D) Autonomous nodule

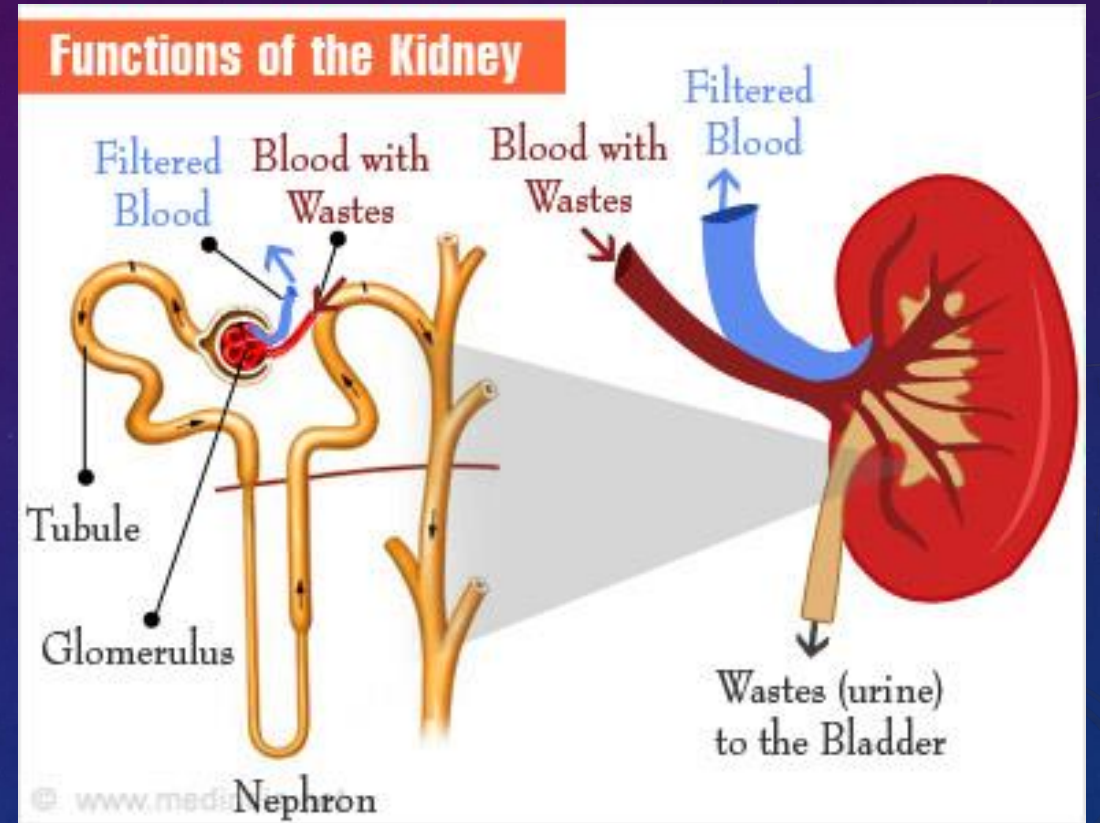
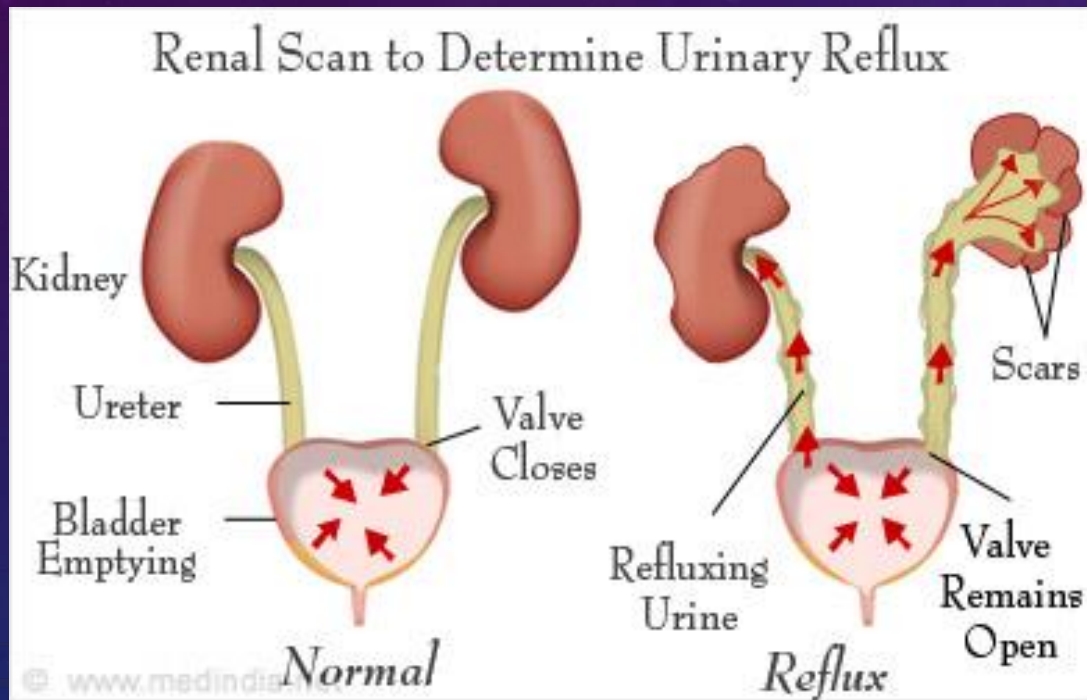


- most (>90%) 'cold' lesions are due to benign processes (eg. thyroiditis, cyst, adenoma)
- if a 'cold nodule' is found on thyroid scan, further investigation, such as ultrasound and/or fine needle biopsy, is recommended



Renal imaging

RENAL IMAGING



الدوائي

RENAL IMAGING

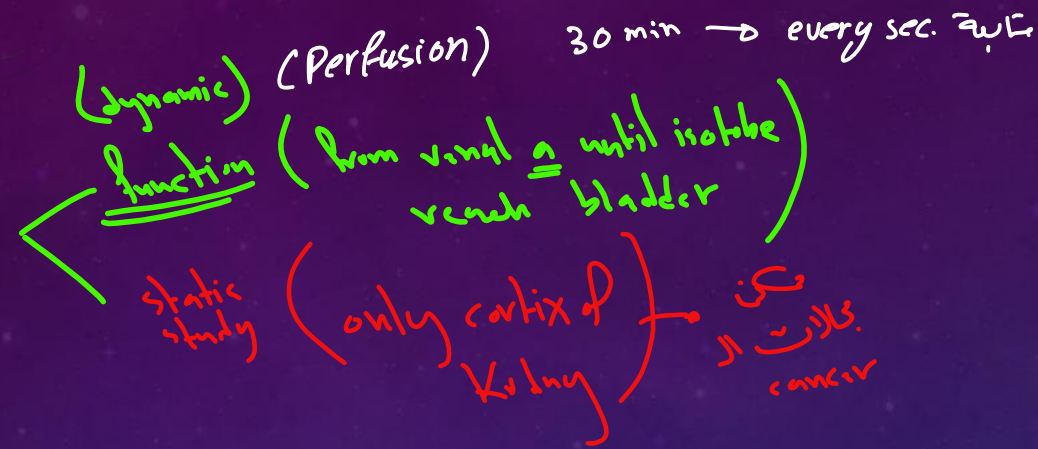
اي حالة نحتاج الى
toxicity/allergy in radiology
حار

نحوها
لل
nuclear medicine

- The radioactive tracer has to be guided to the kidneys so that kidney function can be assessed. For this reason, it is attached to a carrier molecule like DMSA (2, 3-dimercaptosuccinic acid), diethylenetriamine pentaacetic acid (DTPA), mercaptoacetyltriglycine (MAG3), or iodine-131 or iodine-123 *function* orthoiodohippurate (OIH), which takes it to the kidneys. The preferred carrier molecule is determined by the suspected underlying kidney pathology.
- This guiding molecule differs from organ to organ. For example, ligand methylene-diphosphonate (MDP) is preferentially taken up by bone and attaching it to technetium-99m, the radioactivity can be transported to bones for a scan to detect tumor or fractures.

حار دواء
المرئى
منه
نحوها

RENAL IMAGING



- Renal imaging in nuclear medicine is a method to assess the kidneys and collecting systems via multiple different radioactive tracers.
- Dynamic renal imaging is performed using Tc-99m MAG3 or Tc-99m DTPA,
- and static renal imaging is performed with Tc-99m DMSA. → ١٧ → بـفـيـب → --
- In addition, Tc-99m DTPA can be used to calculate glomerular filtration rate (GFR) washout without an accompanying imaging study.

ROLE OF NUCLEAR MEDICINE IN EVALUATION OF RENAL SYSTEM

Clinical query	Tracer
Perfusion (<u>Function</u>)	<u>DTPA</u> , EC, <u>MAG3</u> , GHA
Morphology (<u>Anatomy</u>) cortex	<u>DMSA</u> , GHA
<u>Obstruction</u> laxix administration	<u>DTPA</u> , EC, <u>MAG3</u> , GHA
Relative function (تخمینہ کل کلی / بقیہ کلی)	DTPA, EC, MAG3, GHA, DMSA
<u>GFR quantification</u>	DTPA, Cr-51 EDTA
<u>ERPF quantification</u>	EC, MAG3
Infection (عسی معروف سگنل / Maybe in CA)	<u>Ga-67</u> , <u>Tc99m/In-111-WBC scan</u>

ERPF: Effective renal plasma flow, DTPA: Diethylenetriaminepentaacetic acid, MAG3: Mercaptoacetyl triglycine, EC: Ethylene dicysteine, OIH: Orthoiodohippurate, DMSA: Dimercaptosuccinic acid, GHA: Glucoheptonic acid, GFR: Glomerular filtration rate, WBC: White blood cells, EDTA: Ethylenediaminetetracetic acid

الاحسن
ذات جینٹ
partial/comple

(50%, 60%)

(غیا مالزنت / معینہ)

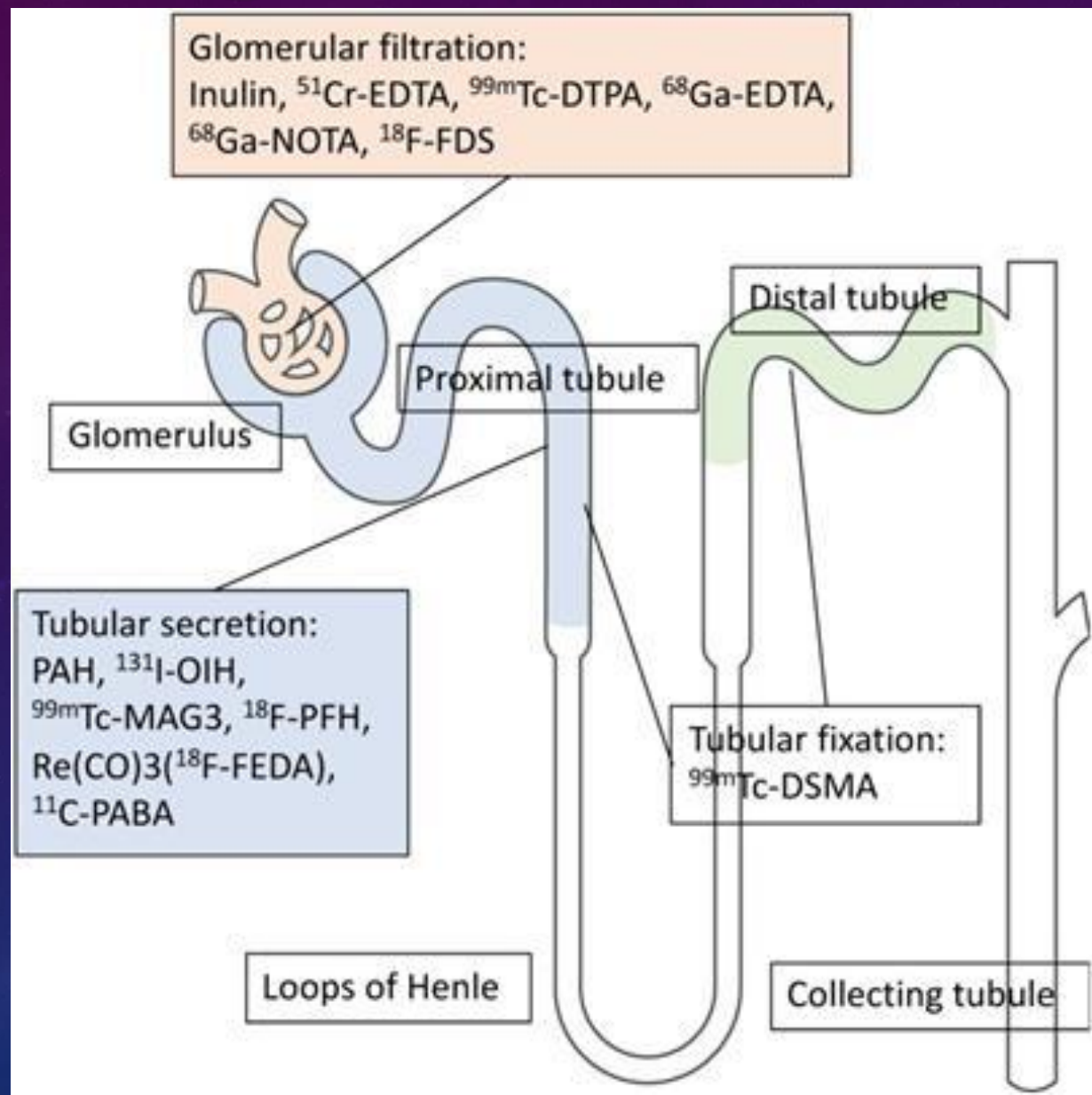
(الاشعری)

تخمینہ کل کلی / بقیہ کلی

عسی معروف سگنل / Maybe in CA

RENAL SCANS CAN IDENTIFY AND EVALUATE:

- **decreased blood flow to the kidneys**
- **renovascular hypertension, which is high blood pressure in the renal arteries**
- **tumors or cysts**
- **abscesses**
- **kidney disease**
- **the success of kidney treatments**
- **the rejection of a kidney transplant**



TYPES RENAL SCANS

الامراض - قسط

DTPA - Scan

DiethyleneTriamine PentaAcetic acid scan is regularly monitored for the assessment of any potential modifications in treatment responses or kidney functions in the pediatric population.

DMSA - Scan

DMSA, or DiMercaptoSuccinic Acid, is bound to technetium 99m to form the radiopharmaceutical, 99m-Tc DMSA

DMSA -MAG3- Scan

Tc-99m mercapto acethyl triglycine -3

المشاكل
Kidney impairment
بجانب
حجرة اكل

Functional study
تقسيم
DTPA
مش
موسم
بالادوية

مغناطيس
الادوية
التي
تستخدم

DMSA - SCAN

cortex

الكلوانه بالا جانل

بالباني لازم بظل ثابت وما يتحرك
واذا التحرك بتعبه الصورة
هون لا بدليه الا 5% لم بغيره
سابقه وبتين بغيره

- DMSA, or DiMercaptoSuccinic Acid, is bound to technetium 99m to form the radiopharmaceutical, **99m-Tc DMSA**.
- After intravenous injection, the isotope is allowed to circulate through the body anywhere between 90 minutes and 4 hours. During this time, 95% of the radiopharmaceutical is bound to the renal cortex and the remaining 5% is usually excreted into the urine. Modern gamma cameras, particularly those capable of performing single-photon emission tomography (SPECT), are able to reconstruct 3-dimensional images of the kidneys.
- **There are no absolute contraindications.**

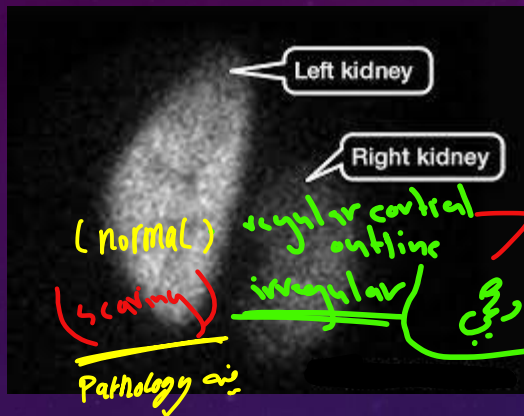
البيروت التحق
abs. contra
Lactation

No. abs. contra.

باني انتفاحي السه :-
Safety
بس ينقله او dose

DMSA

RENAL IMAGING



DMSA renal scan

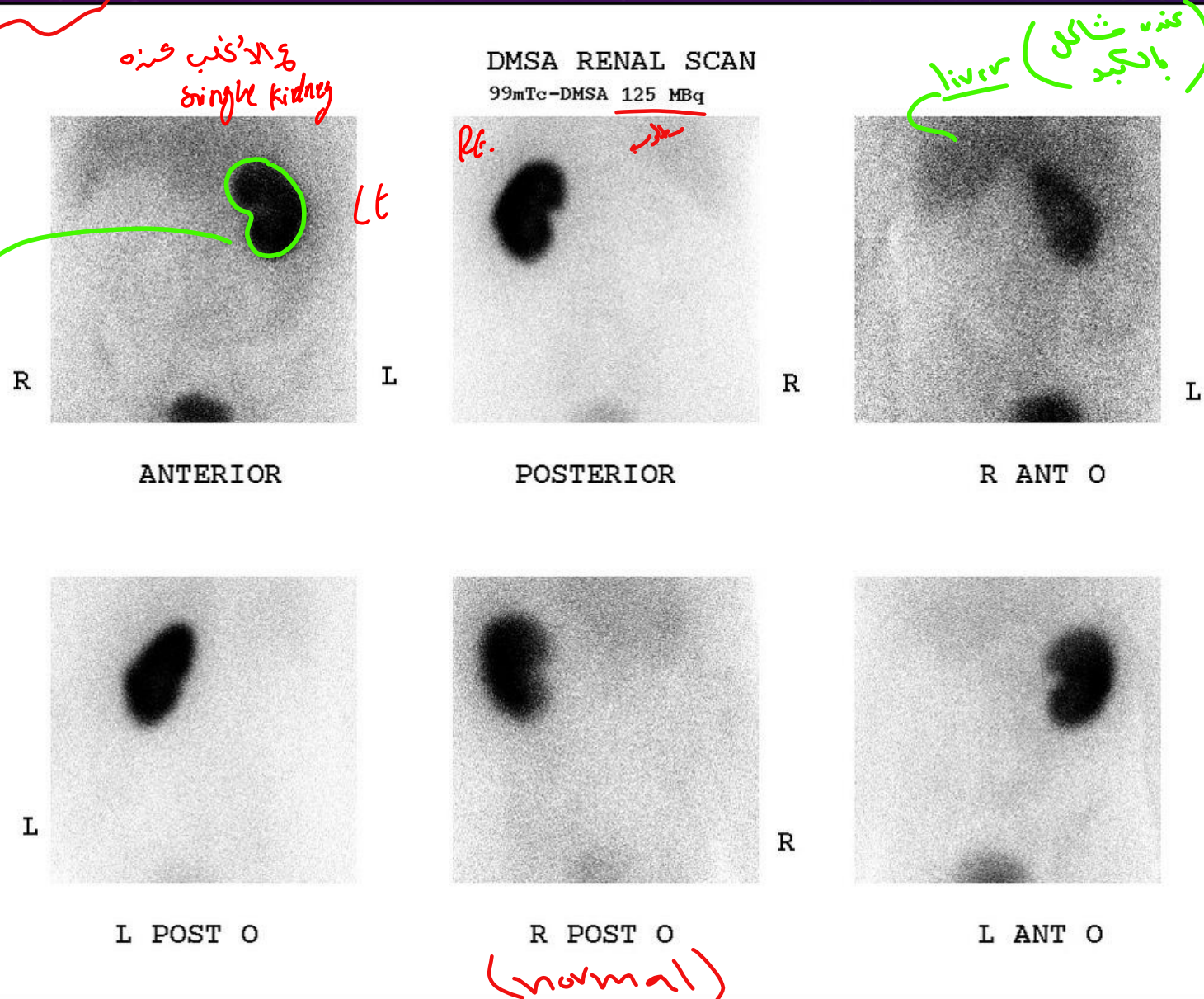
No radiotracer activity is noted in the region of right kidney (non-functioning right kidney). Left kidney shows homogeneous radiotracer uptake.

localize size

نوزبير ال

الكتور برك زعارجي

في اليمين عنده single kidney



ممنه مثالي باليكيد liver

DMSA RENAL SCAN
99mTc-DMSA 125 MBq

ANTERIOR

POSTERIOR

R ANT O

L POST O

R POST O

L ANT O

(normal)

معدل الفاعل بنفسه %١٥

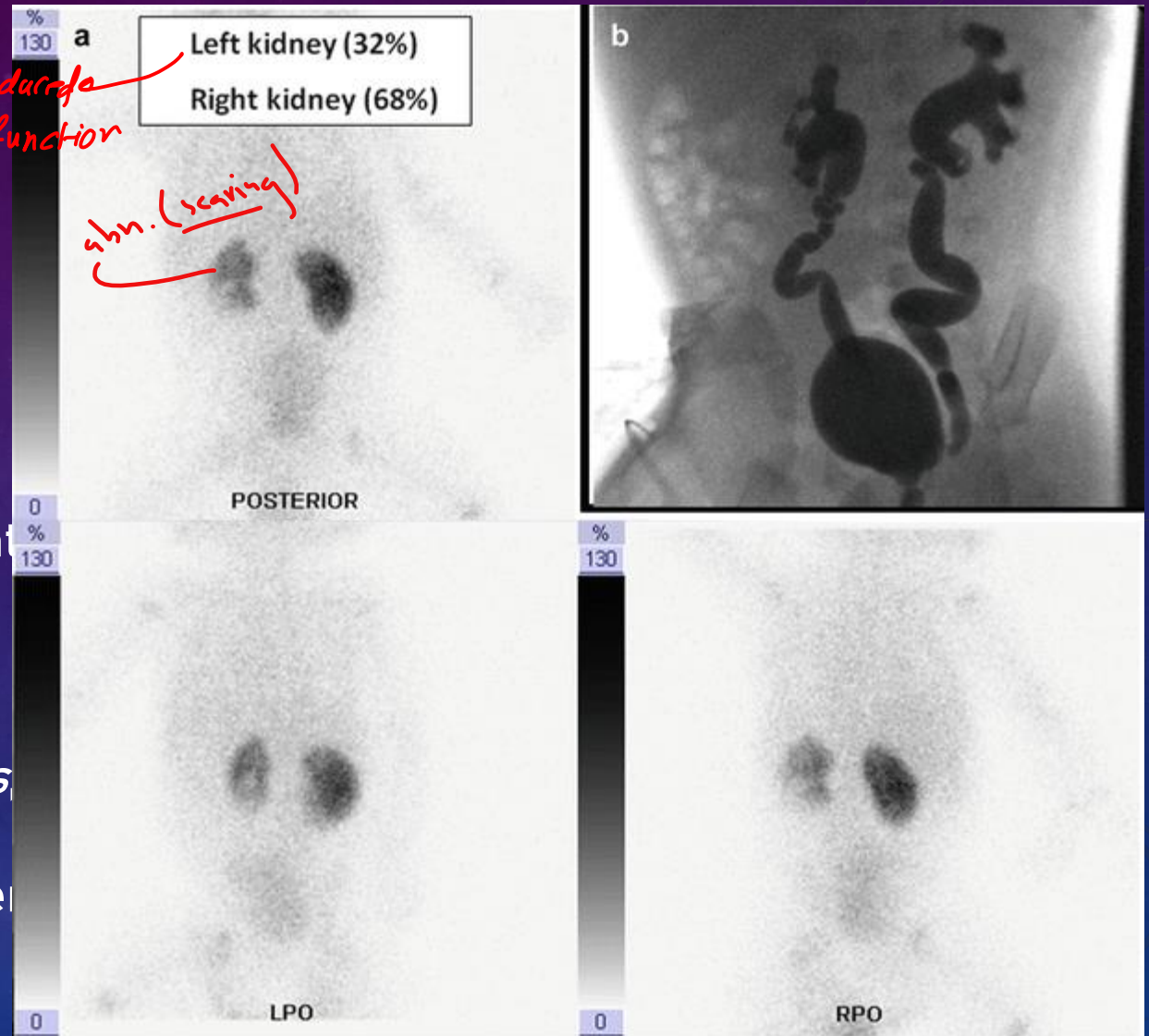
RENAL IMAGING

DMSA

reduced function
shn. (scarring)

(a) DMSA renal scan (posterior view, LPO view, and RPO view):
left kidney is smaller than the other one, with global reduction of radiotracer uptake (acute flogosis); two cortical defects are evident one in the *upper pole* and the larger one in the *lower pole*, respectively;
right kidney shows good uptake of radiotracer with decreased uptake in *upper and lower poles* without cortical defects.
A very low target/background ratio is also evident

(b) Cystography: bilateral high-grade vesicoureteral reflux (Grade IV)



3D volume rendered fused SPECT-CT

RENAL IMAGING

normal in size

كل وقت
مينه بنفوس
لوانه دمانف

normal ال
function
of DTPA
الحاله
مايقصروا

لانه بالكله ال طبيعي
بكد dilution لا بالاله
اذا
ماصغروا

في شك
بال vector
اد الحانه
فالننتج
طبيعي
لانه هو 100%
وسرع كد (10%)
بعترو
normal

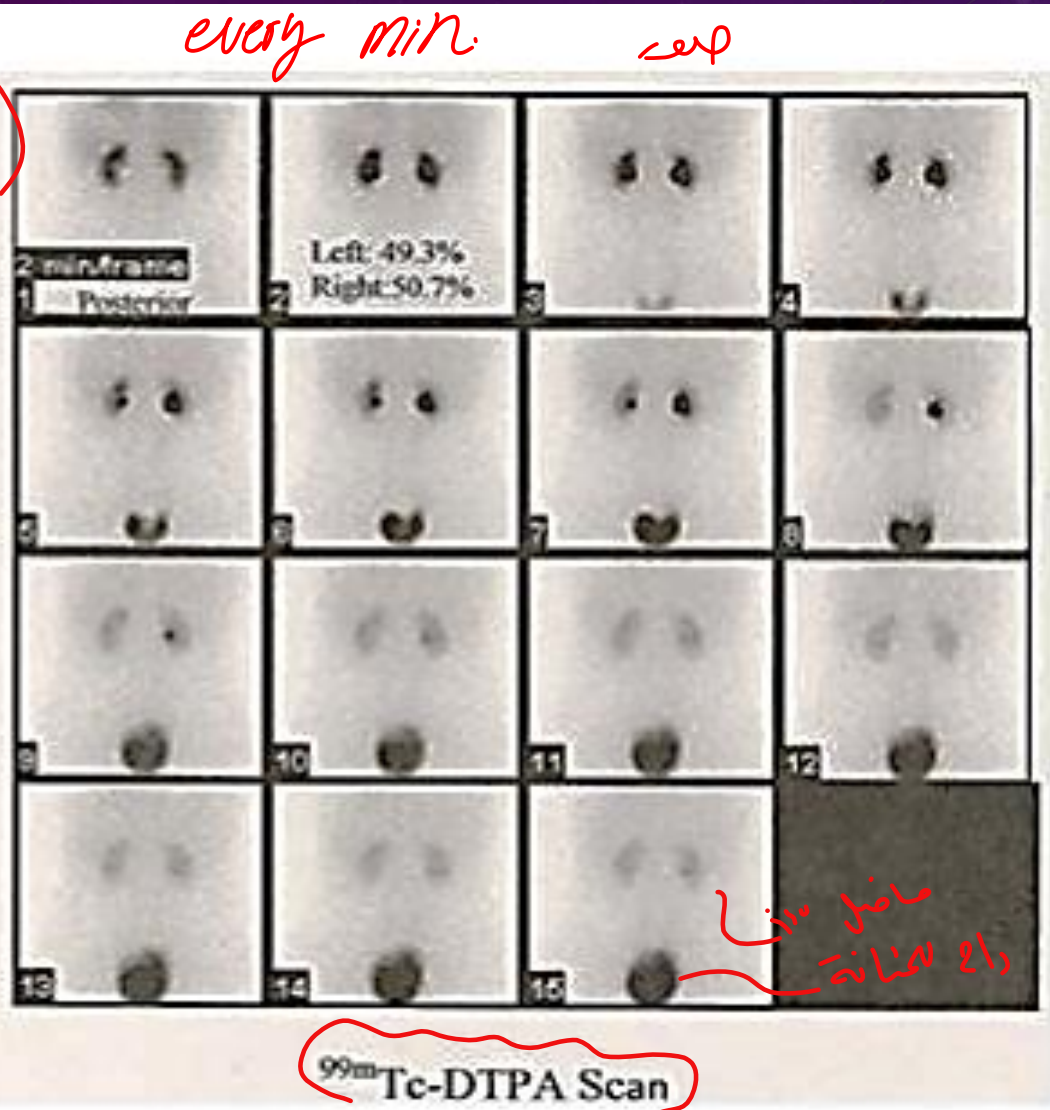


Figure 1. Renal ^{99m}Tc-DMSA and ^{99m}Tc-DTPA scan of a 7-year-old boy with bilateral collecting system dilatation on ultrasonography.

ماينركز في السائز مع
بسر ال function

dilatation, peristalsis
ureter مايبين

RENAL IMAGING

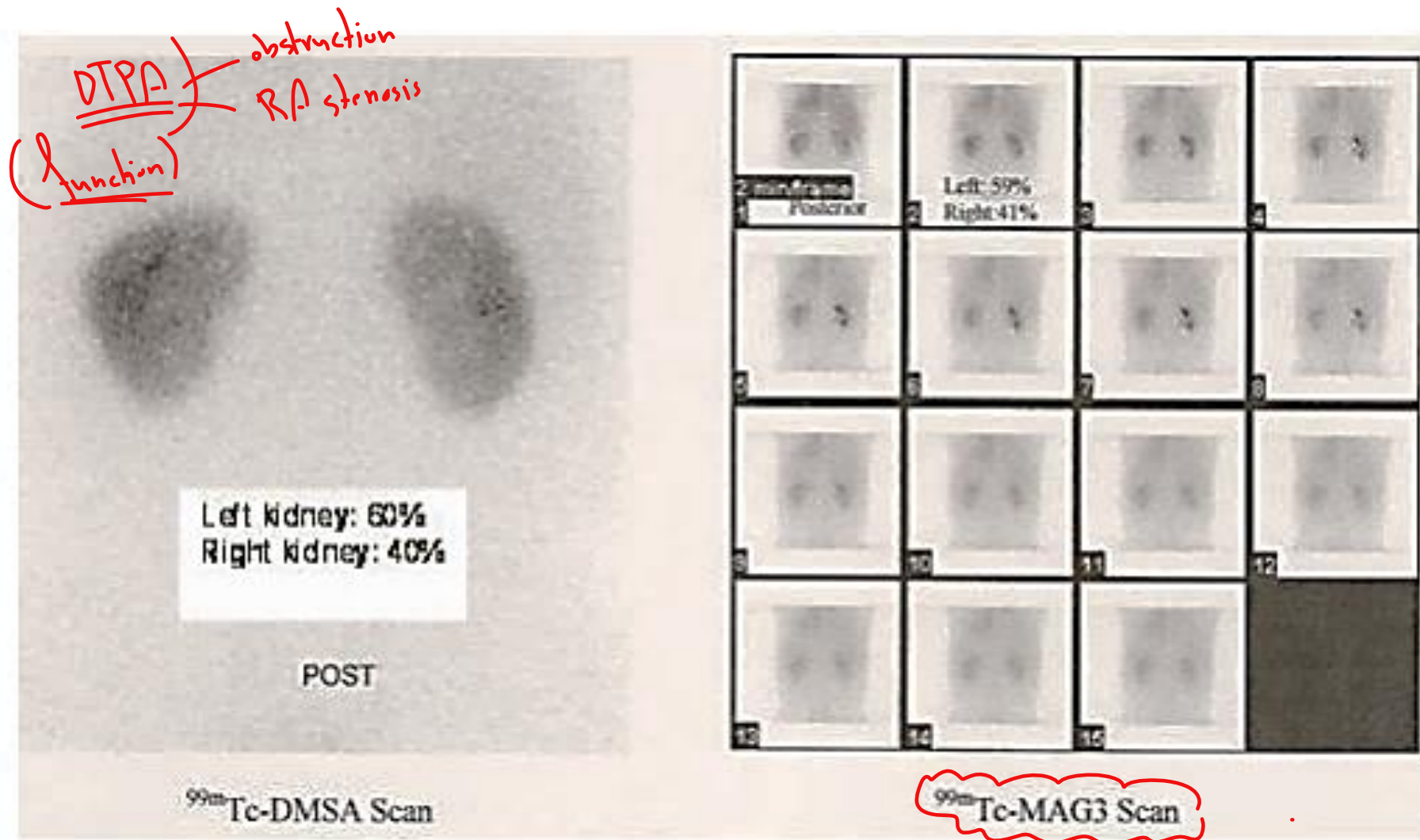
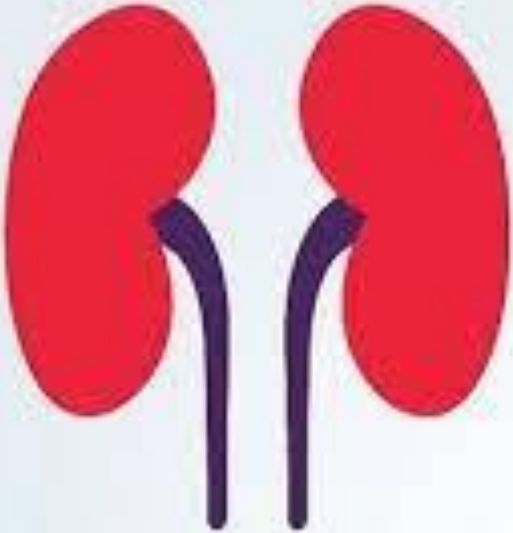


Figure 2. Renal ^{99m}Tc-DMSA and ^{99m}Tc-MAG3 scan of a 9-year-old boy with left collecting system dilatation on ultrasonography and suspicion of renal functional impairment.

RENAL IMAGING

DTPA


- There are so many things that make renal DTPA scan so unique and advanced.
- Some of them are
 - This scan captures multiple images of the kidneys simultaneously with the use of a Gamma Camera. This, as a result, improves the precision and accuracy of diagnosis and evaluation of the functioning of the kidneys.
- It combines high performance and versatility
- This advanced technology does not expose the patient to a lot of radiation.



DTPA Scan

Detect & Diagnose

- Cysts
- Tumor
- Swelling in Kidney
- Renal arterial blockage
- Kidney failure

 LABSADVISOR

RENAL IMAGING

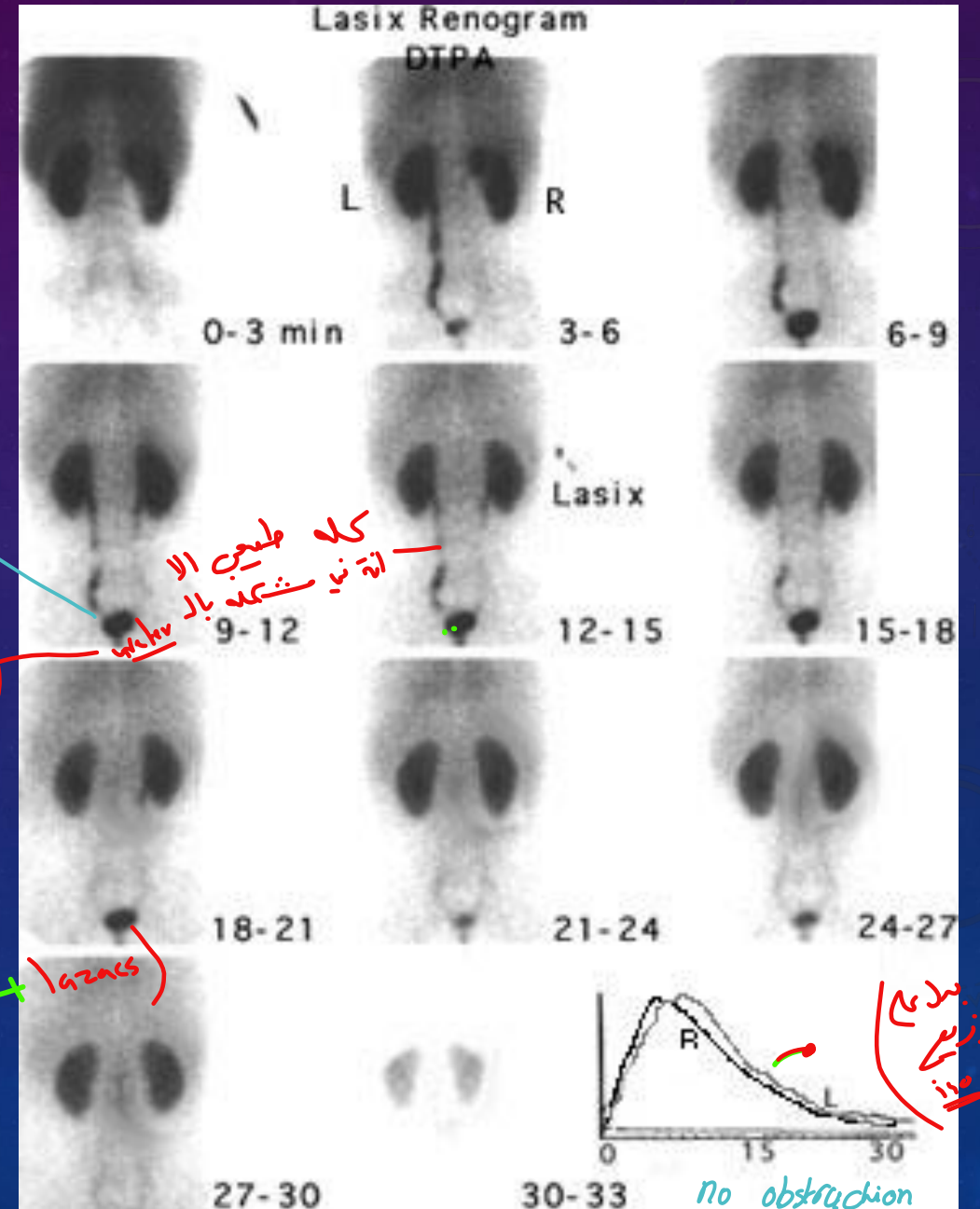
DTPA

كل في دقائق

(الجزء 2-ب)

functional / dynamic

NORMAL LASIX-RENOGRAM



كل ما هو الوقت
كل ما زاد (isotope)
كله موجود 30 min

stenosis

vesicular stone

كله طبيعي الا
انه نيا شئ بال

DTPA + Lasix

partial / complete obstruction

لازم يوخه Lasix

اد برابة لـ 24hrs

بينملا مع
اد سالتيم (technique)

(DTPA + Lasix)

كله طبيعي
اد برابة لـ 24hrs

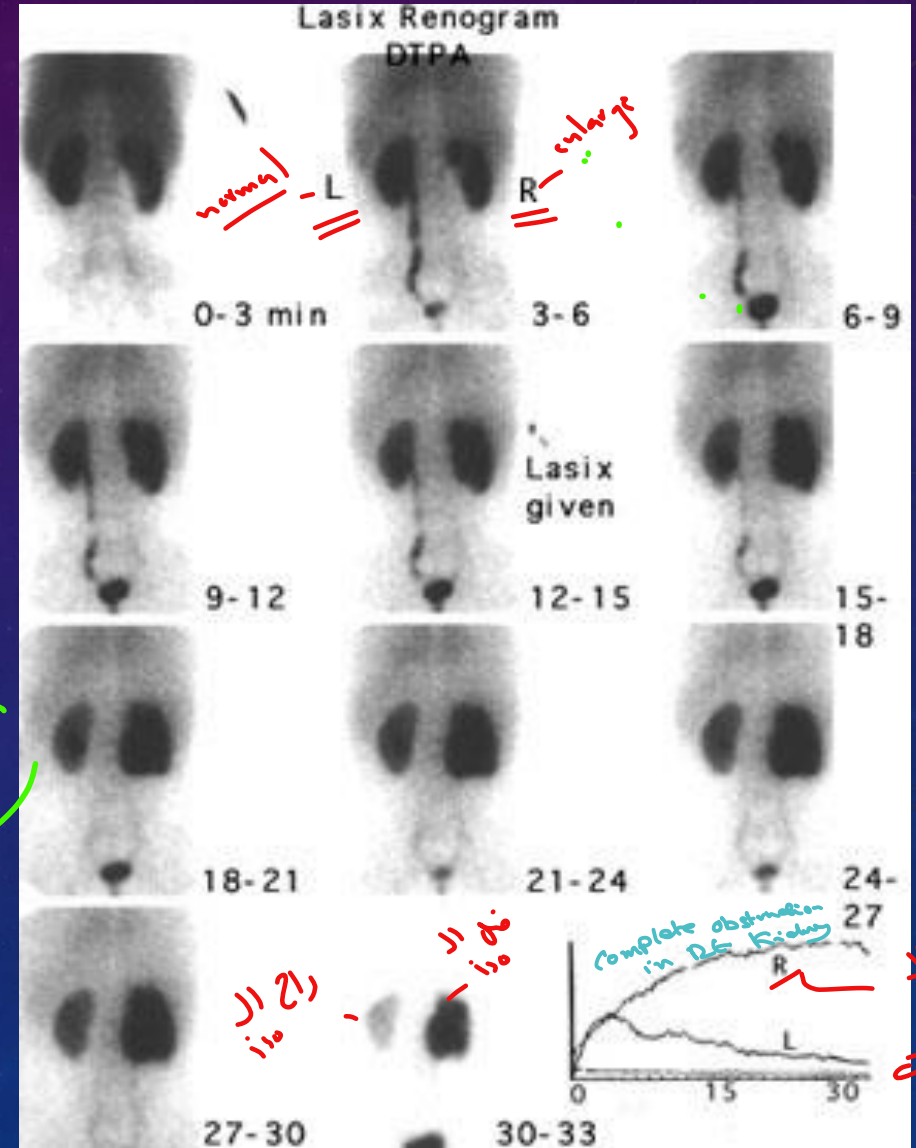
RENAL IMAGING

DTPA

- After the venous injection, both kidney take up the radioisotope, DTPA. Notice that although the kidneys are the same size, the center of the right kidney has areas of decreased radioactivity (photopenia); the hilum of the right kidney is lighter grey. This indicates that the kidney has hydronephrosis; the pelvis is so large that the renal parenchyma is stretched over it.

عنه ر + ل
شكلا با ر
تفهم
اريد ان
كامل

- Notice that the left kidneys show peak concentration (computer generated curve in the lower right-hand corner of the image) at about 5-7 minutes. The left kidney promptly drains (the computer curve drops rapidly). The computer curve of the right kidney shows a much more gradual rise and it continues to rise almost to the end of the study. This shows that the right kidney doesn't drain; it is obstructed. Additional studies demonstrated that the obstruction occurred at the ureteropelvic junction.



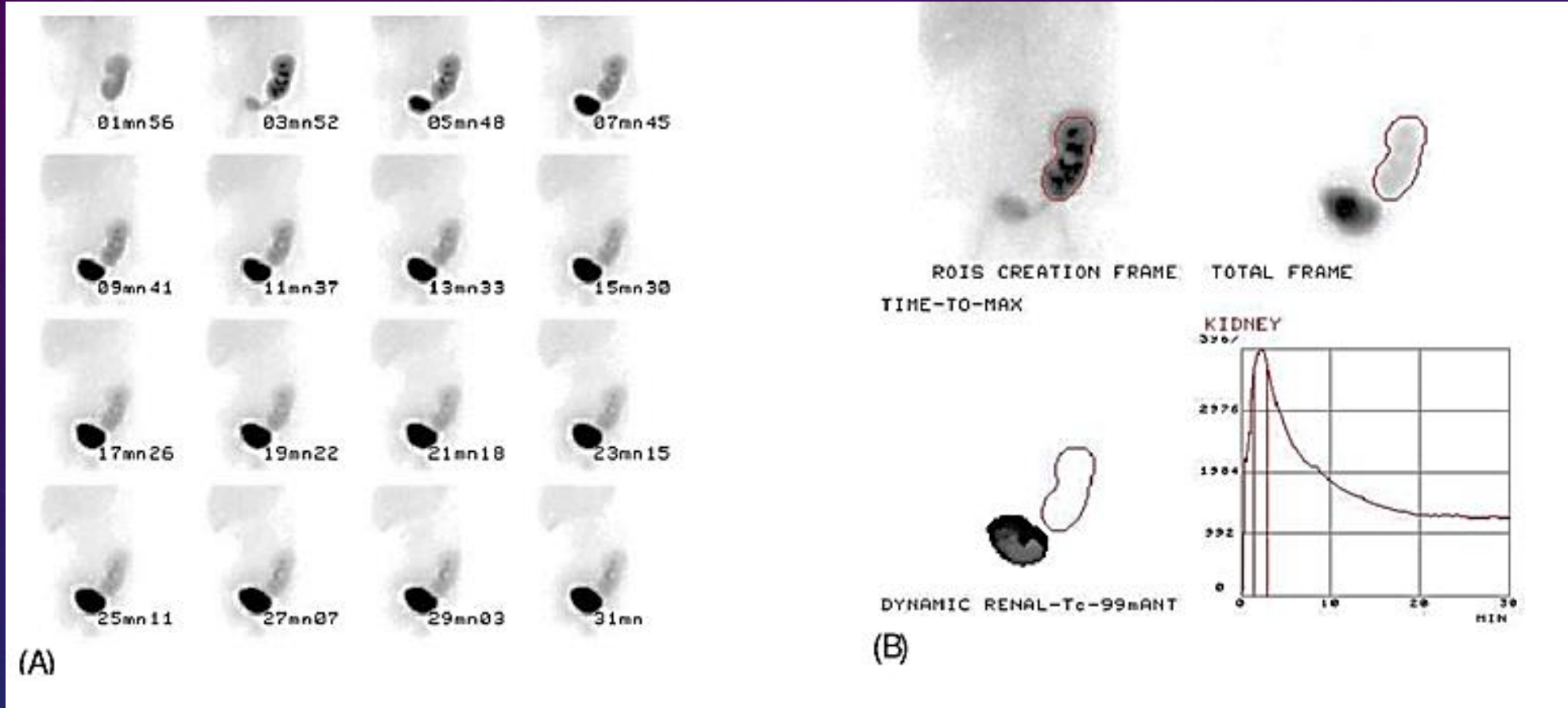
بس لو كان السكتو
يعني بنزل لدم سن لونا اخر
الاول
complete

انواع ال
موا
بما كود الوقت
مبا كود

RENAL IMAGING

DTPA

ناتج
transplanted kidney



- (A) and (B): ^{99m}Tc-DTPA renal scintigraphy. Normal functional phase and renographic curve.

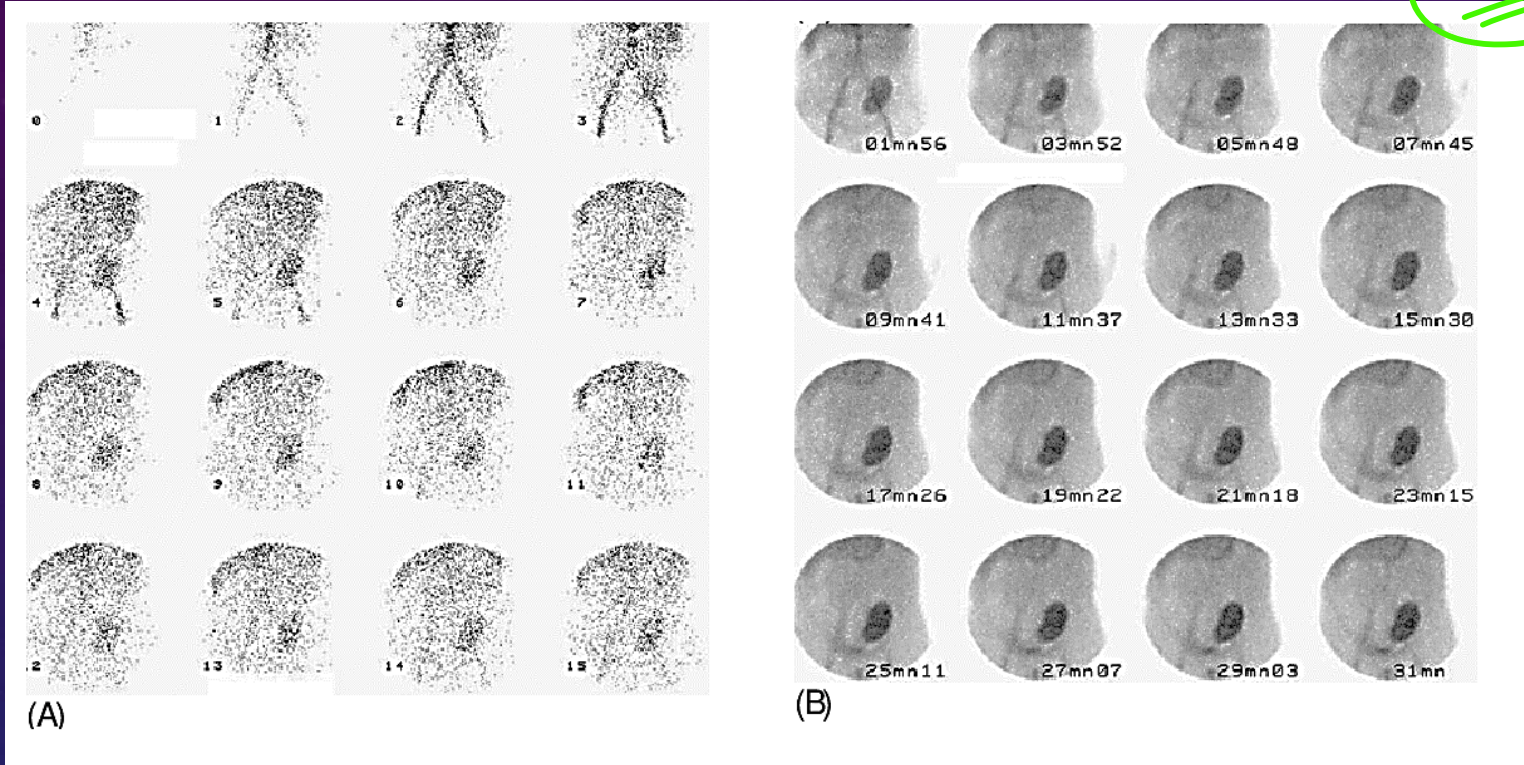
RENAL IMAGING

DTPA

abd. aorta / R, Lt iliac

کله جزوئو

normal



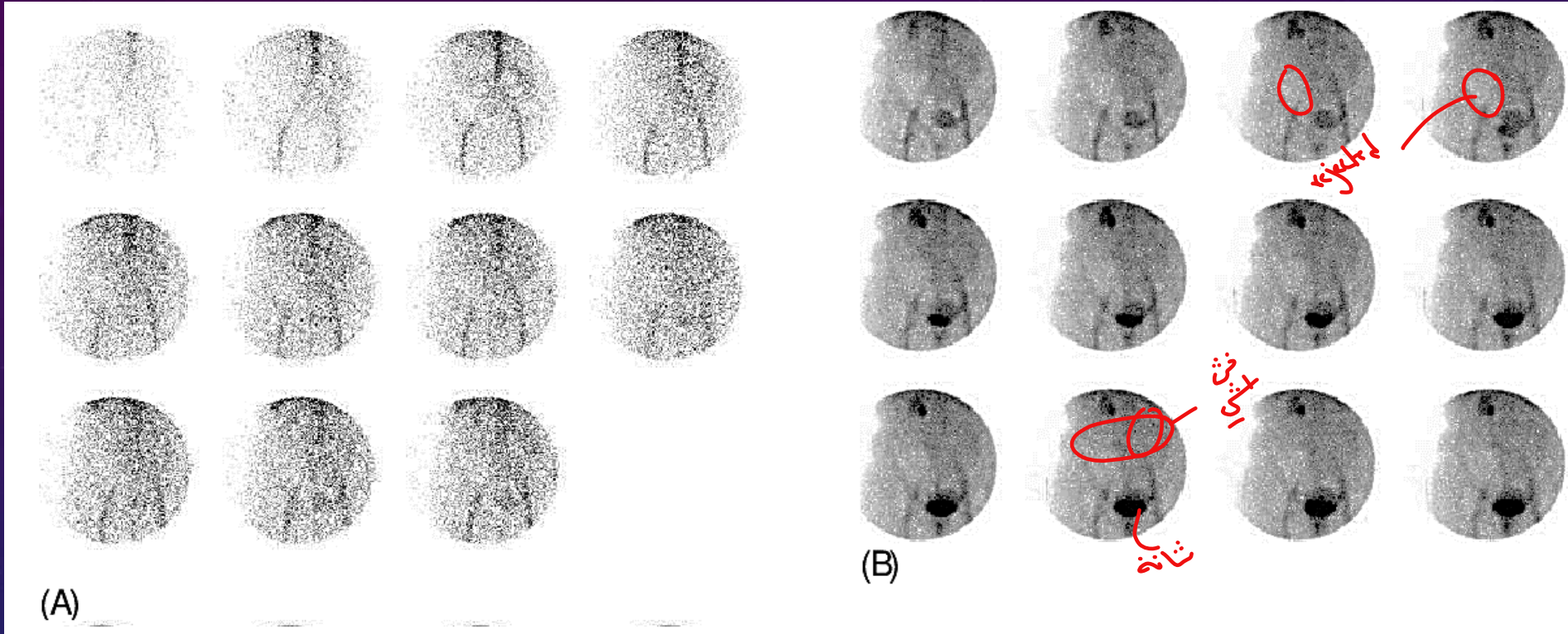
- (A) and (B): ^{99m}Tc -DTPA renal scintigraphy. Postoperative period of 48 hours. Preserved arterial blood flow and glomerular function deficit, with minor urine formation during the study.

rejection ار
بگرنه ماخو انصام ال سو

RENAL IMAGING

DTPA

- infection
- malignancy) \uparrow iso uptake
↓ ~ ~) RAS, الدمار



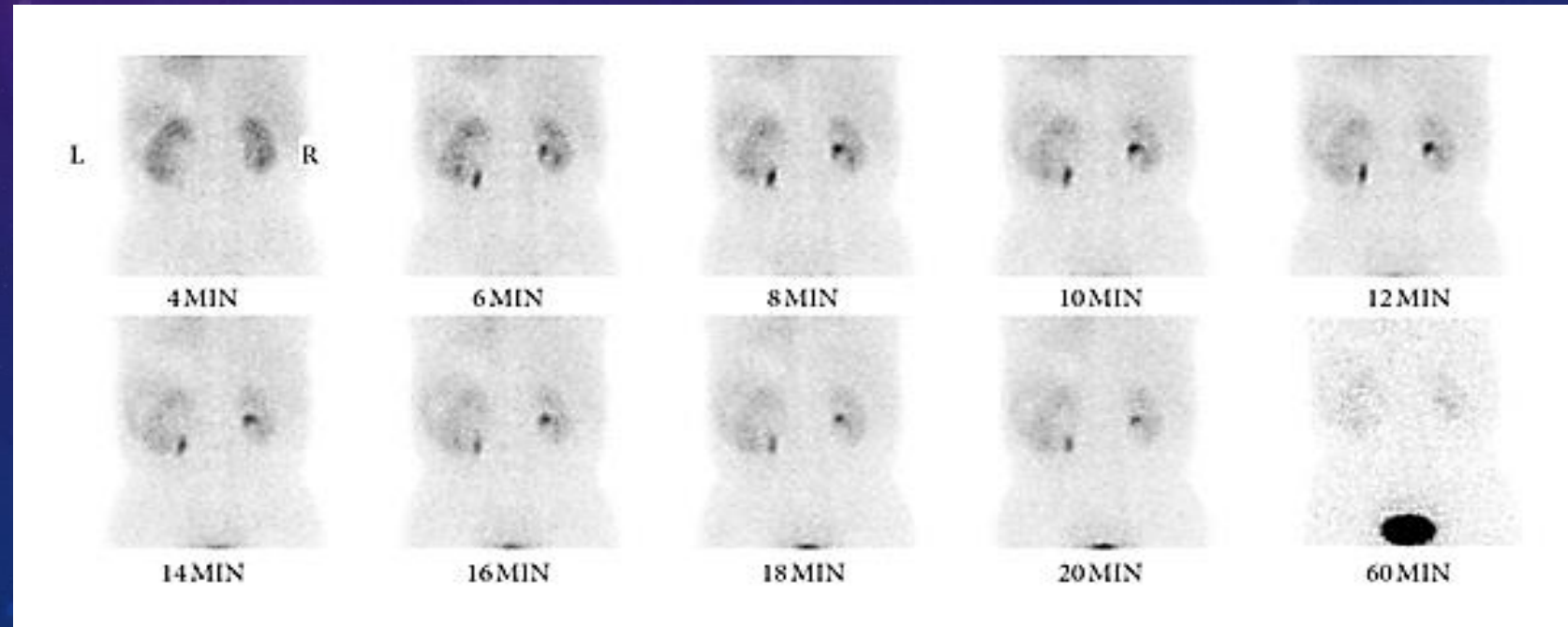
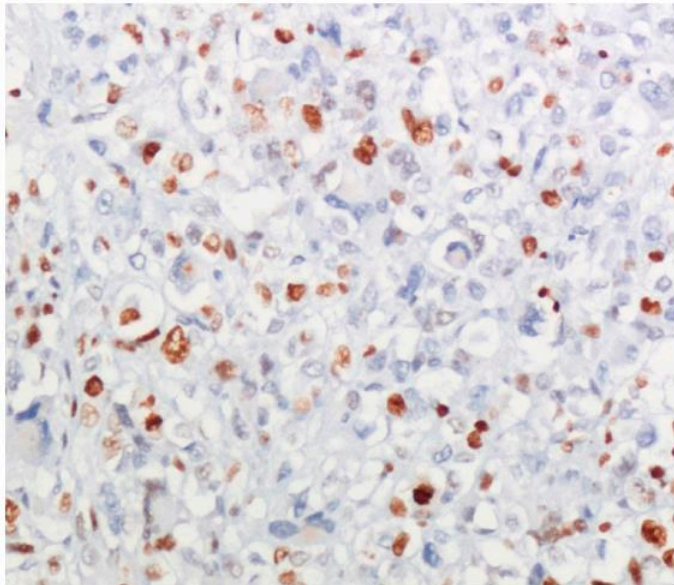
- A and B: ^{99m}Tc -DTPA renal scintigraphy. Photopenic area in the left iliac fossa. Absence of arterial blood flow and of glomerular filtration in the transplanted kidney. Radionuclide angioscintigraphy performed with ^{99m}Tc -DTPA. The photon deficiency and no uptake of radioactivity at the site of the graft indicate non-viability.

RENAL IMAGING

مستی مطلوب

- A 73-year-old man with dedifferentiated liposarcoma in the left retroperitoneum. (a) The renal parenchyma phase showed moderate uptake of Tc-99m DTPA, TGFR = 66.1 ml/min, LGFR = 34.0 ml/min, and RGFR = 32.1 ml/min. Serum renal function was normal. (b) Ki-67 expression is 50% ($\times 200$).

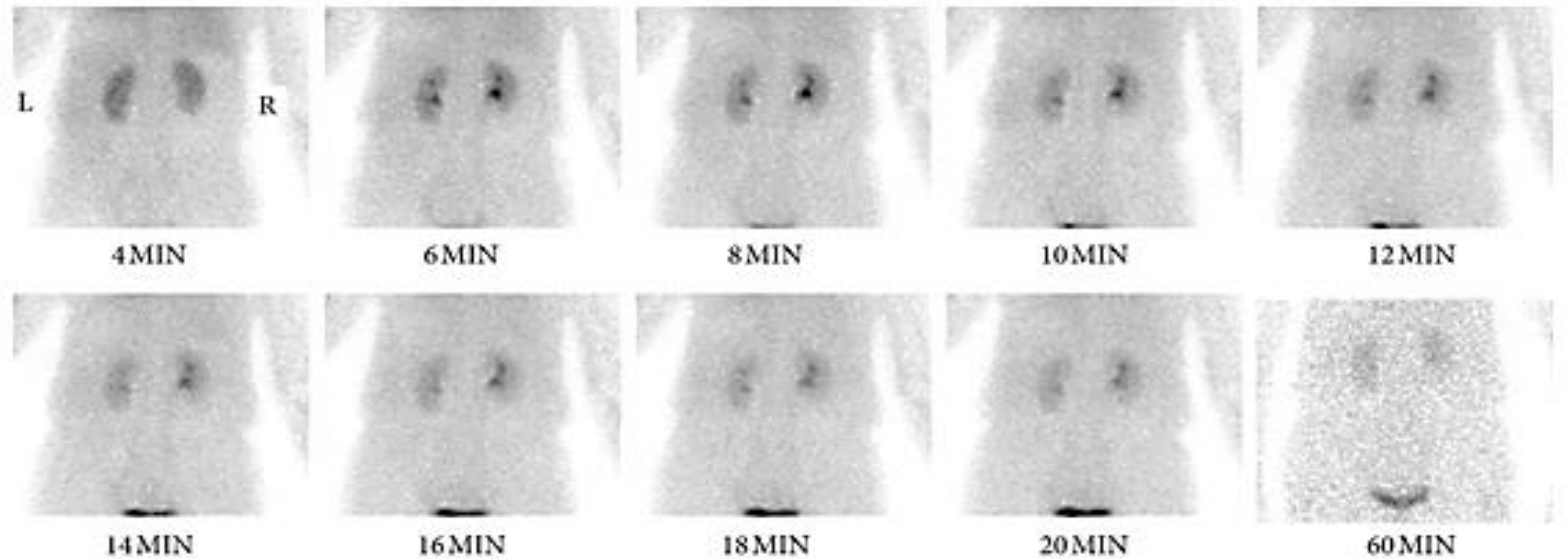
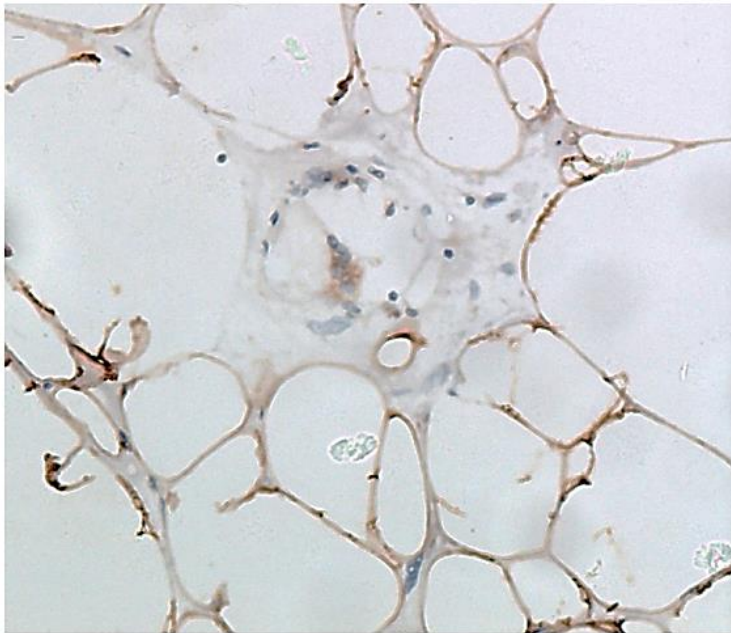
THE ROLE OF TC-99M DTPA RENAL DYNAMIC SCINTIGRAPHY IN RETROPERITONEAL LIPOSARCOMA



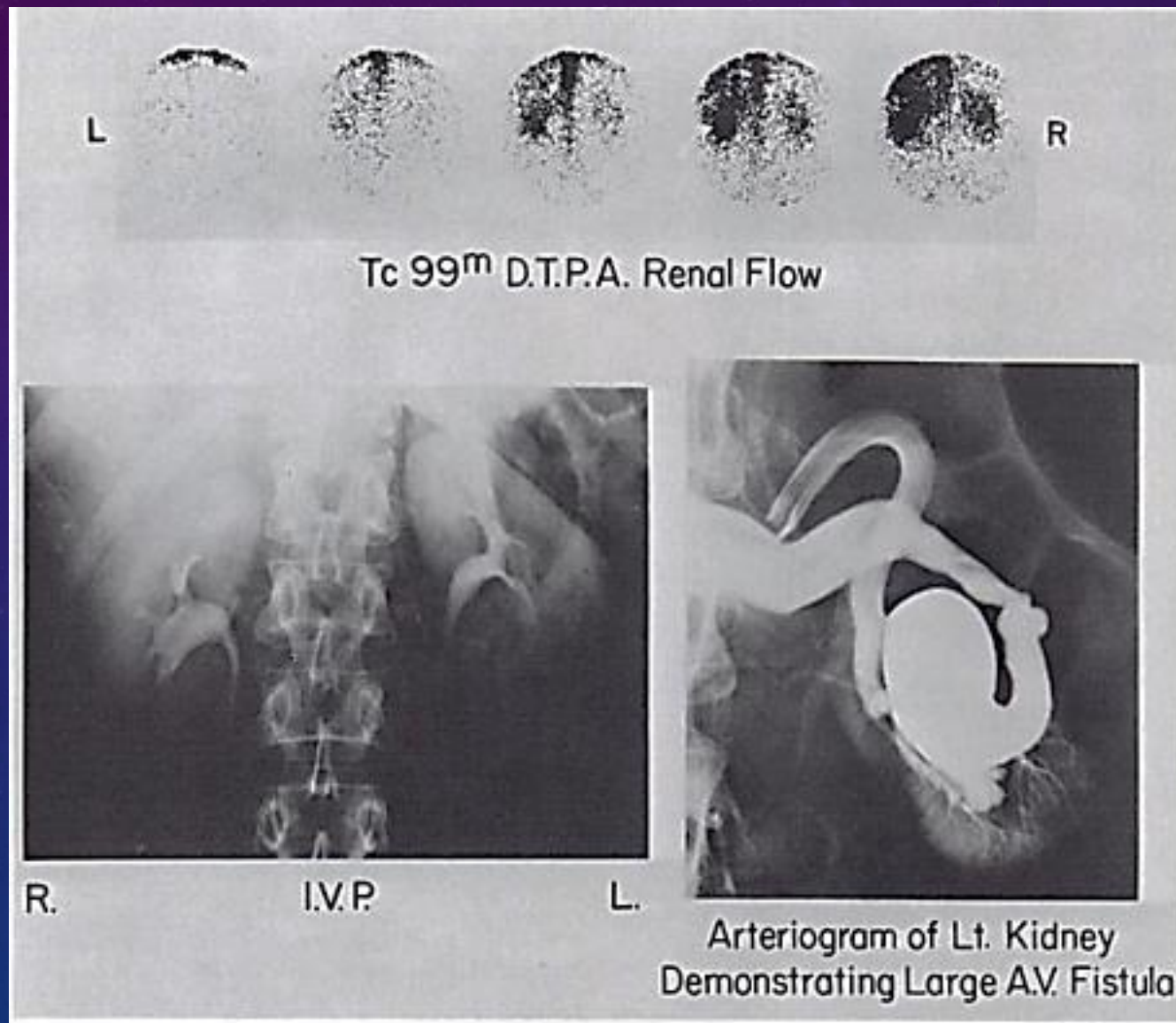
RENAL IMAGING

THE ROLE OF TC-99M DTPA RENAL DYNAMIC SCINTIGRAPHY IN RETROPERITONEAL LIPOSARCOMA

- A 64-year-old woman with well-differentiated liposarcoma in the right retroperitoneum. (a) The renal parenchyma phase shows no uptake of Tc-99m DTPA, TGFR = 67.6 ml/min, LGFR = 34.2 ml/min, and RGFR = 33.4 ml/min. Serum renal function was normal. (b) Ki-67 expression is less than 5% ($\times 200$).



RENAL IMAGING



RENAL IMAGING

99TCM-MAG3 RENAL SCAN

ABNORMAL TRANSPLANT DUE TO ACUTE TUBULAR NECROSIS (ATN).

- A: Normal renal perfusion curve: Time activity curve over 60 seconds. Region of interest (ROI) are on the renal transplant parenchyma (white arrow) and region of iliac artery (blue arrow). Red line - radiotracer activity in the transplant is compared to activity in iliac artery (black line). There is normal transplant upstroke 10 seconds after injection (curved red arrow).
- B: Time activity curve over 30 minutes - ROI over renal parenchyma (white arrow). (Red line in the graph) shows persistent parenchymal activity without downsloping at 30 minutes indicating no radiotracer excretion.

