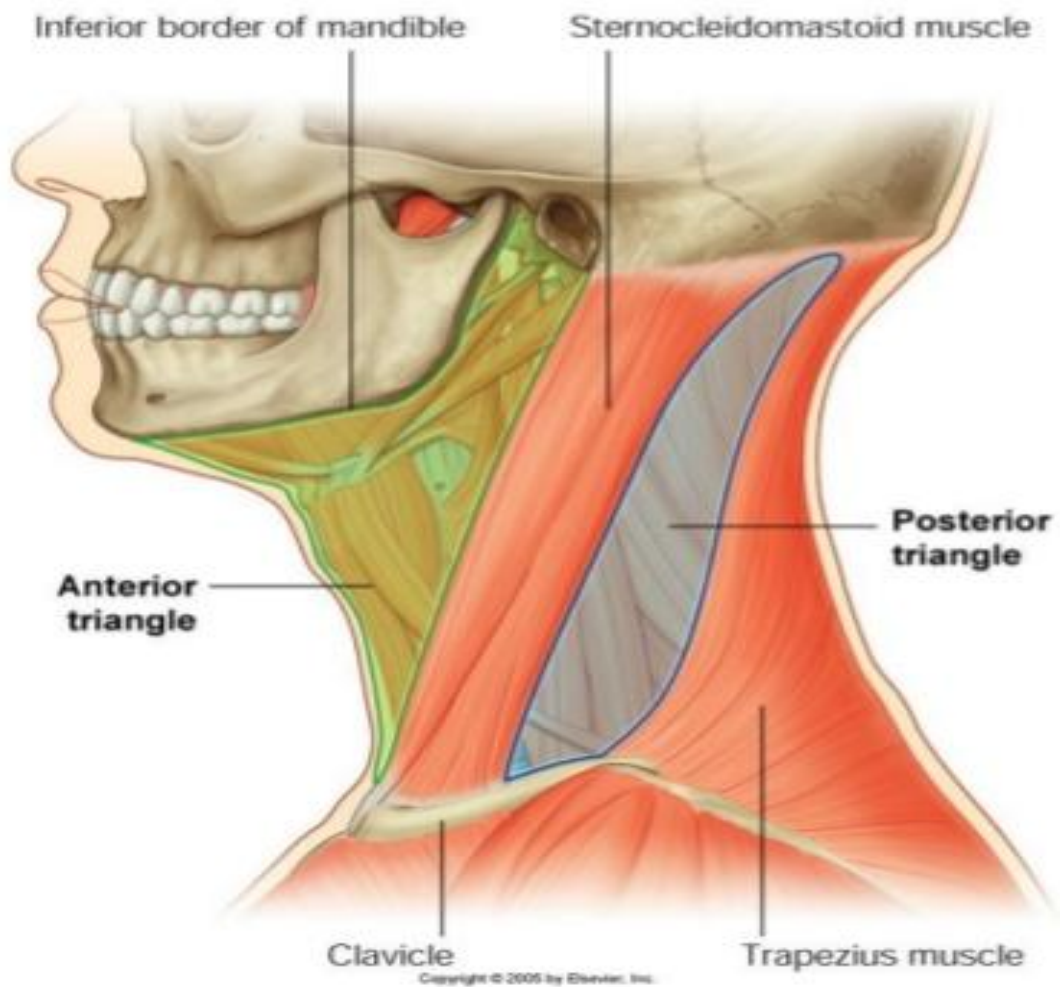


Triangles of The Neck

*The antero-lateral side of neck is divided by sternomastoid muscle into anterior & posterior triangles.



A. posterior. Triangle.

*Boundaries:

1. **Anterior** : Posterior border of sternomastoid.
2. **Posterior** .: anterior border of trapezius.
3. **Apex**: meeting of anterior & posterior borders at the superior nuchal line .
4. **Base**: middle 1/3 of clavicle.
5. **Roof**: Skin, superficial fascia containing platysma , external jugular vein , branches of cervical plexus (lesser occipital nerve , great auricular nerve , supraclavicular nerves , transverse cervical nerve) & deep fascia.
6. **Floor**: from above downwards, splenius capitis , levator scapulae , scalenus medius .

*Contents:

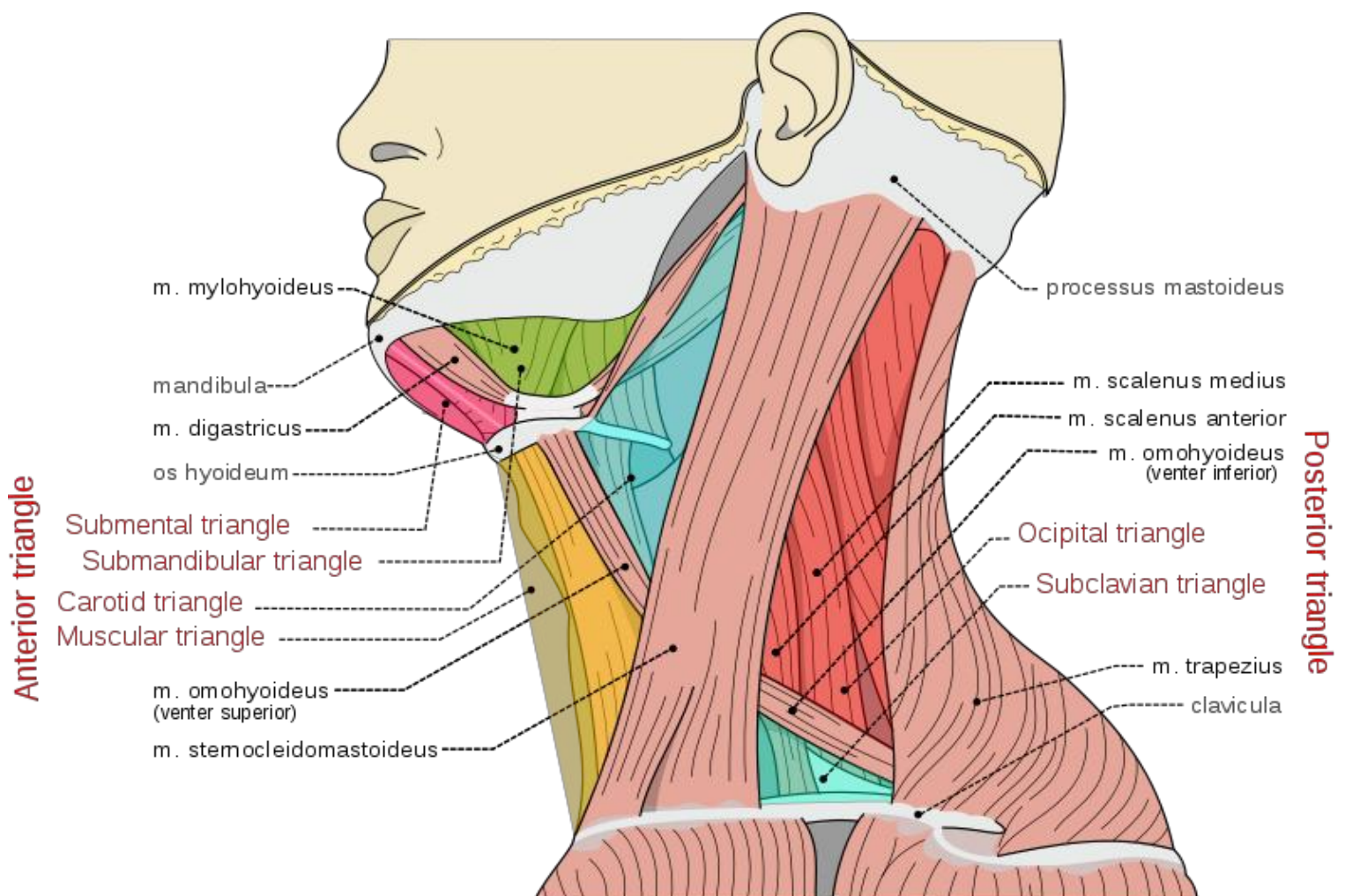
- **Nerves** : spinal accessory nerve , branches of cervical plexus & trunks of brachial plexus.
- **Arteries**: near the **base** of the triangle there are 3rd part of subclavian , suprascapular & transverse cervical & near **the apex** of the triangle there is occipital arteries .
- **Veins** : subclavian , suprascapular & transverse cervical & external jugular veins.
- **Muscles** : Inferior belly of omohyoid.
- Occipital **lymph nodes** & posterior part of deep cervical **lymph nodes** .

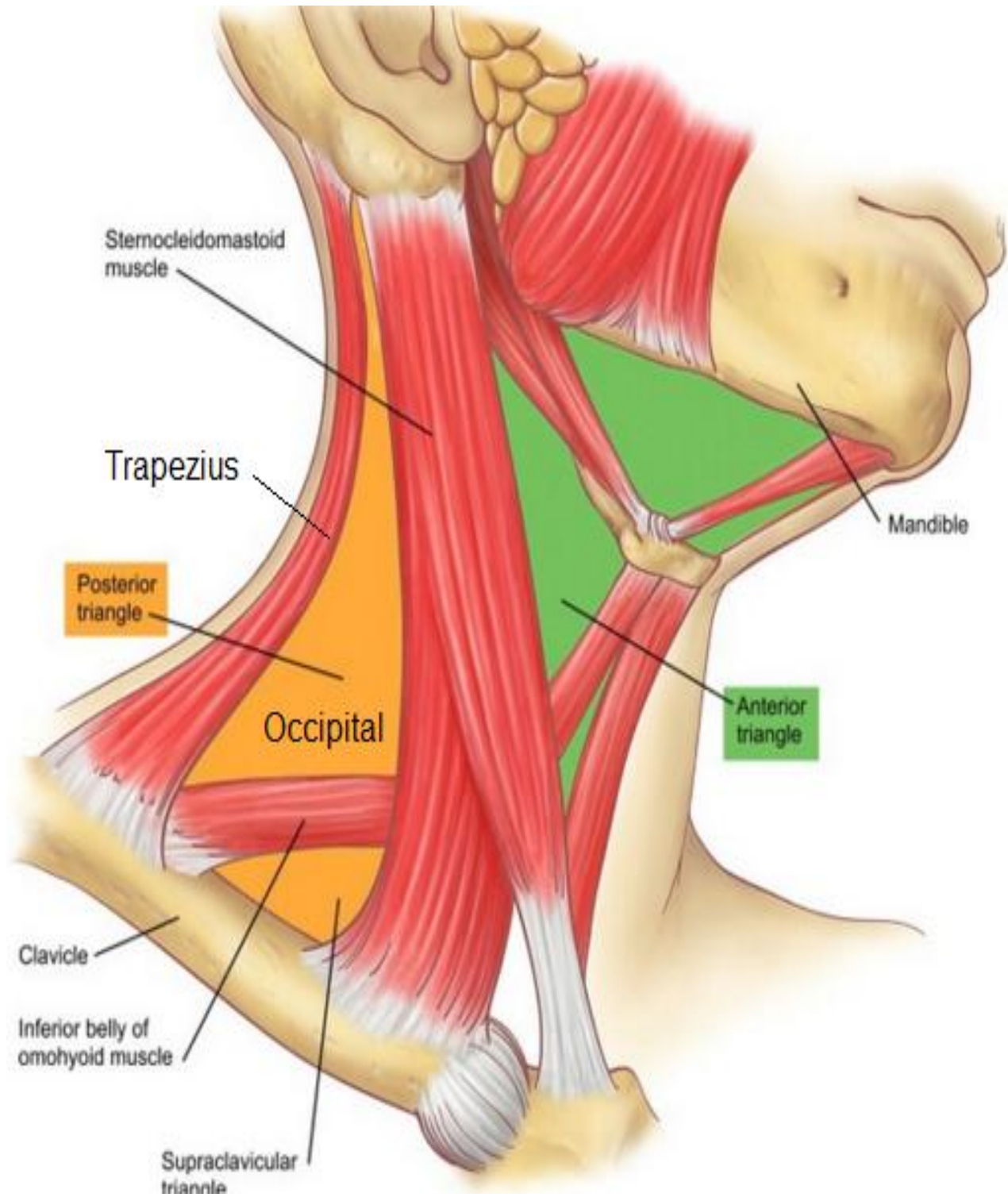
***Subdivisions:**

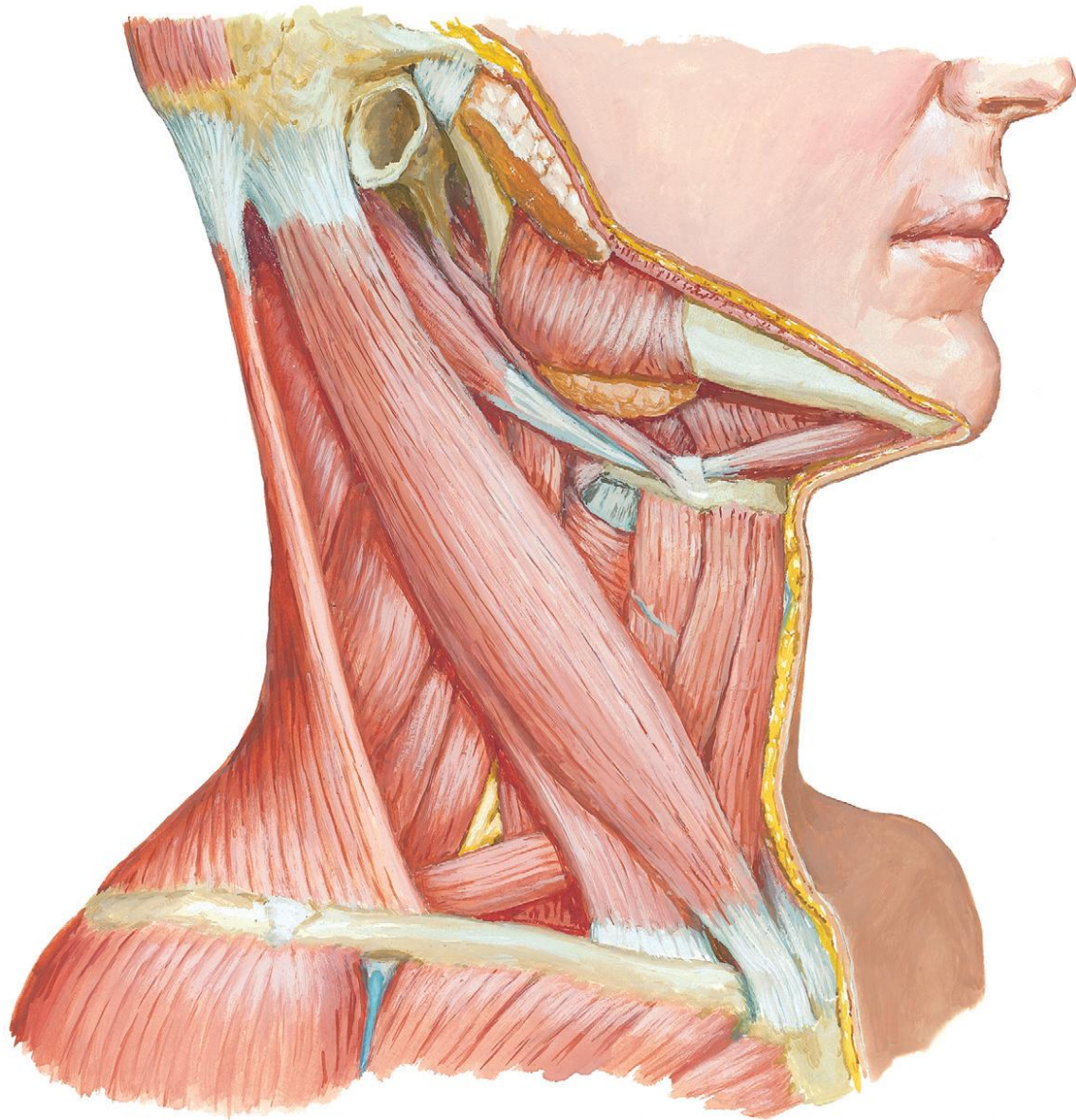
- Inferior belly of omohyoid divides posterior triangle into **occipital** triangle above & **subclavian** (supraclavicular) triangle below

*** N.B :The commonest swelling in the posterior triangle is lymph nodes enlargement .**

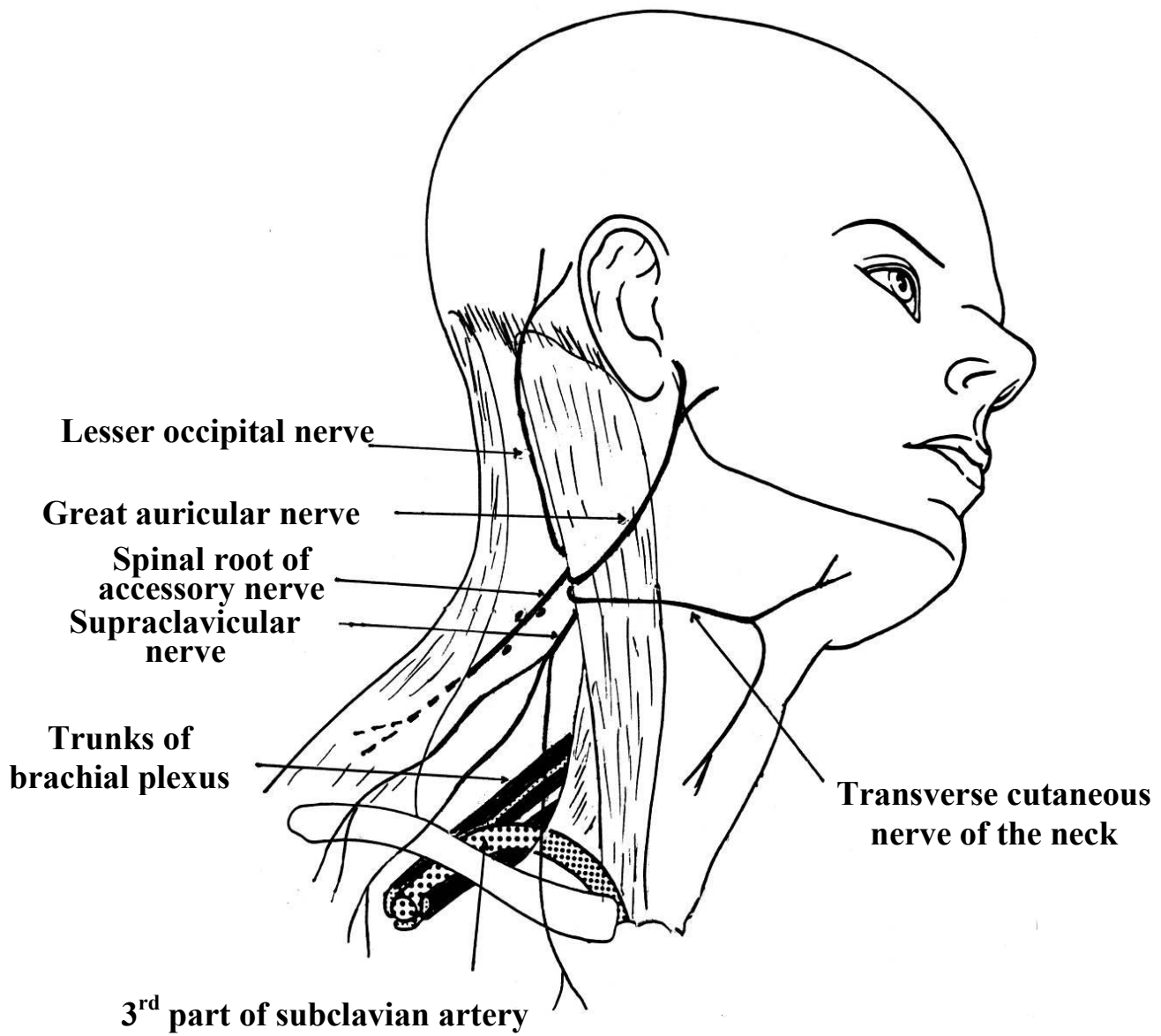
Triangles of the Neck



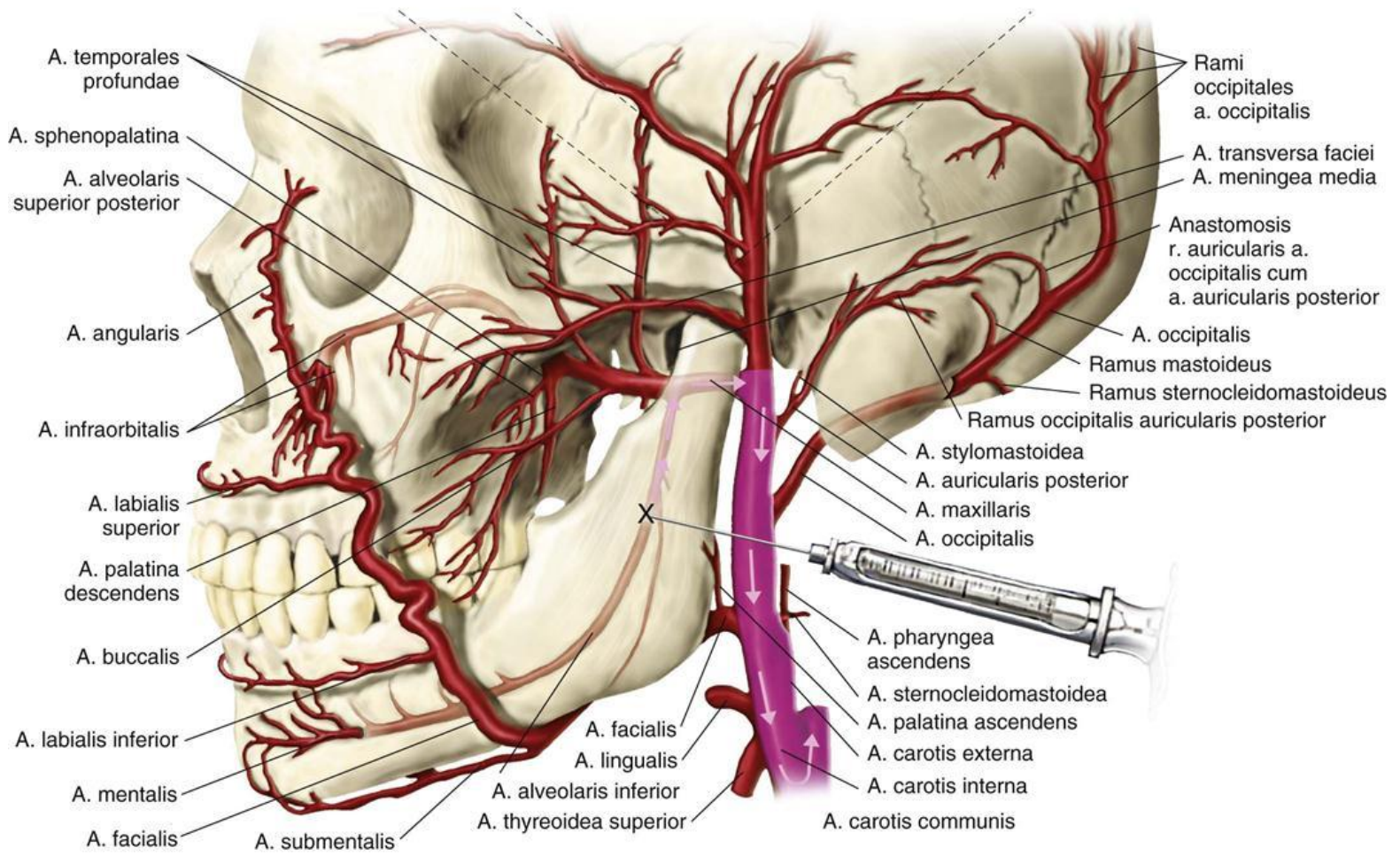




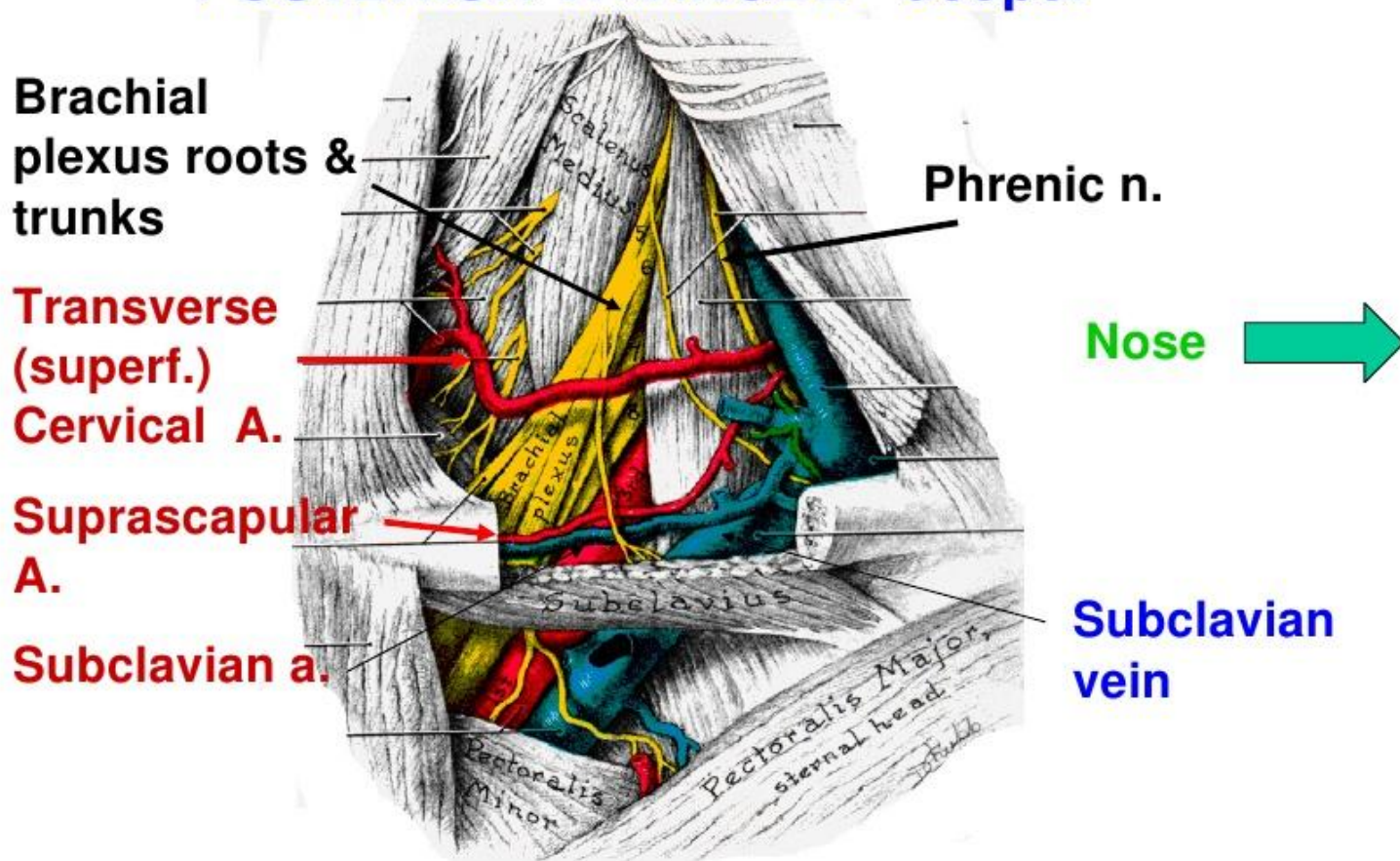
Floor of posterior triangle



Nerves in the Posterior Triangle



POSTERIOR TRIANGLE - deeper



note: Subclavian vein is not in post triangle

ARTERIES OF POSTERIOR TRIANGL