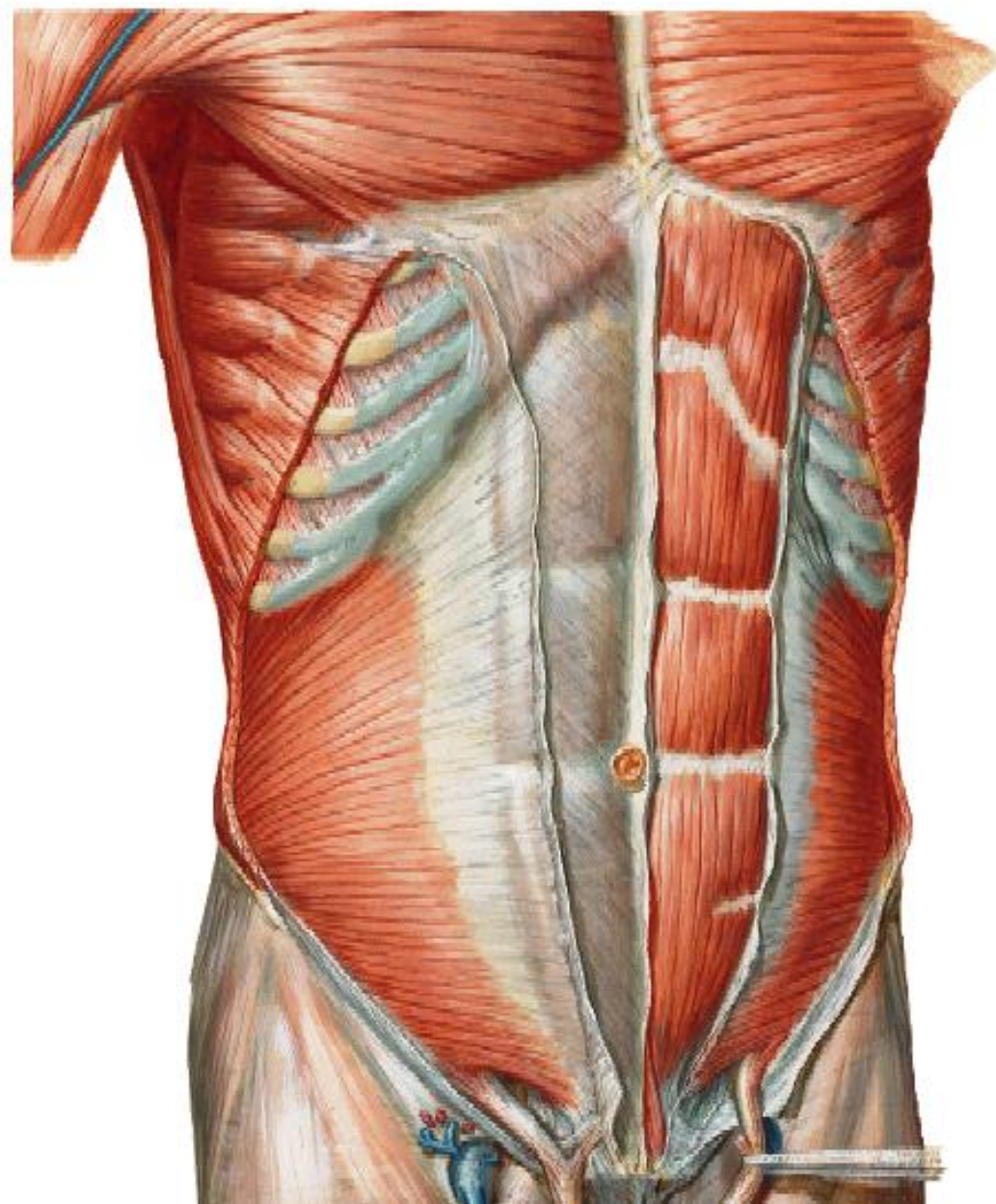


# ANT. ABD. WALL & RECTUS SHEATH



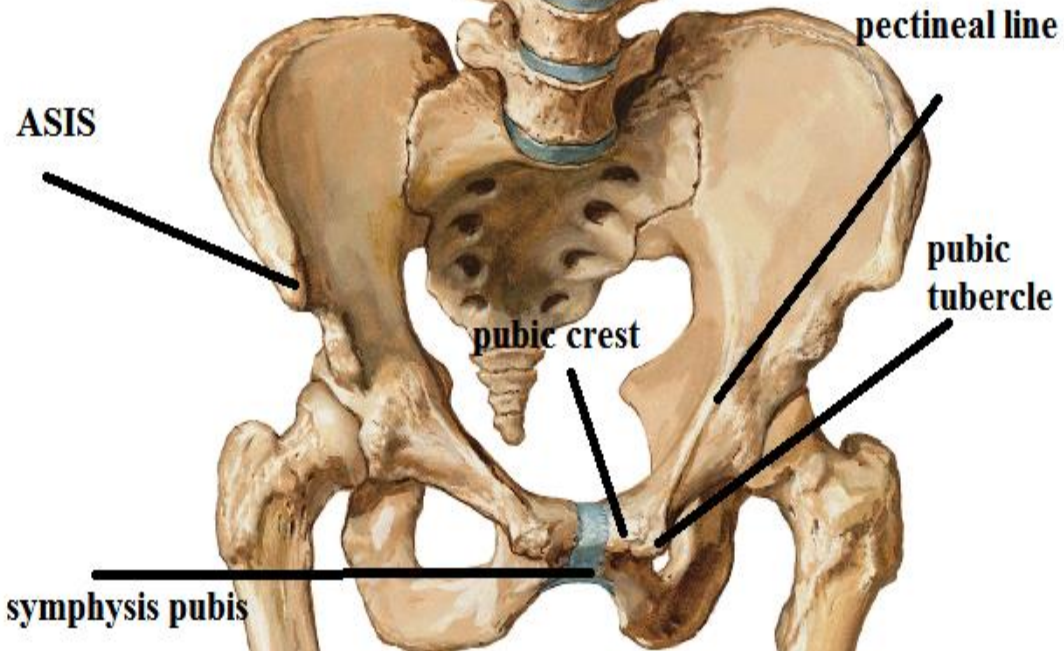
BY

DR ABULMAATY MOHAMED  
ASSISTANT PROFESSOR  
ANATOMY & EMBRYOLOGY  
MUTAH UNIVERSITY

# SKELETON

xiphoid  
process

costal  
margin



# ANTERIOR ABDOMINAL WALL

**layers:-** "from outside inwards"

skin.

superficial fascia: which divides into

Superficial fatty layer

deep membranous layer

N.B.: deep fascia is absent

to allow distension of some organs e.g. uterus.

muscles:

Lateral part:

ext. oblique.

int. oblique

transversus abdominis

Fascia transversalis.

Extra peritoneal fat.

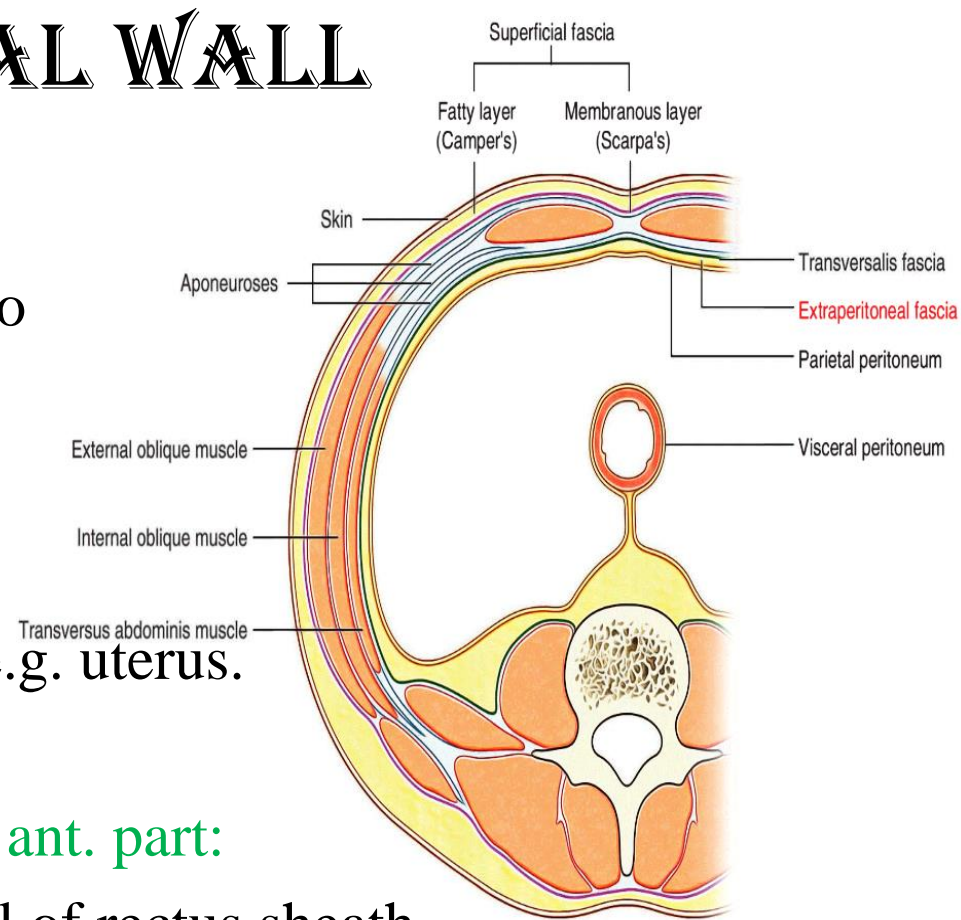
Parietal peritoneum.

ant. part:

ant. Wall of rectus sheath

rectus abdominis & pyramidalis

post. Wall of rectus sheath





# ANTERIOR ABDOMINAL WALL

## MUSCLES

### Vertical muscles

1-Rectus abdominis

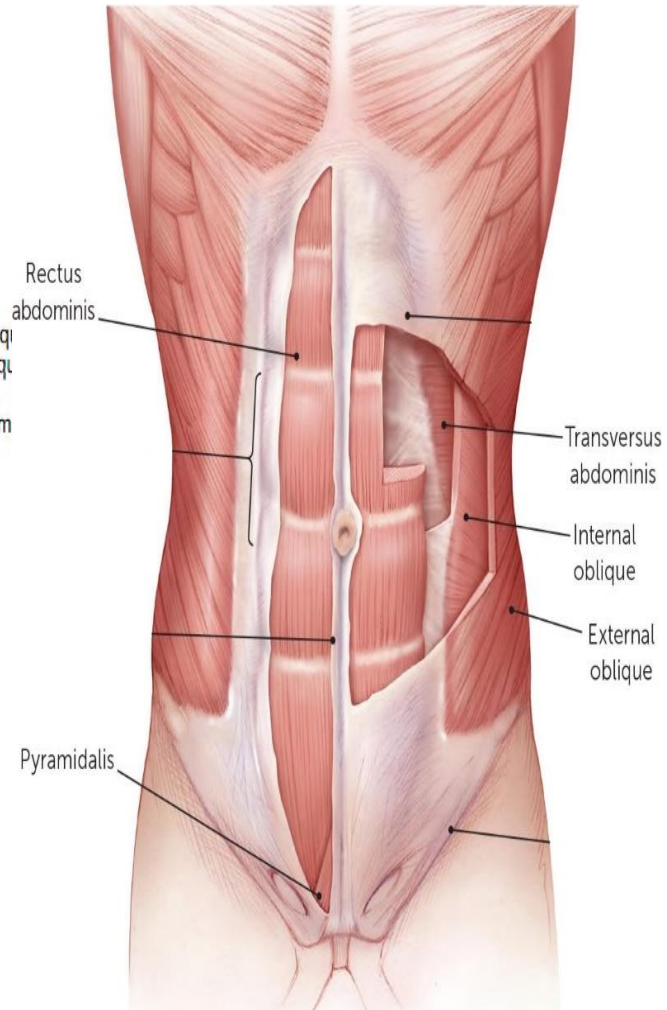
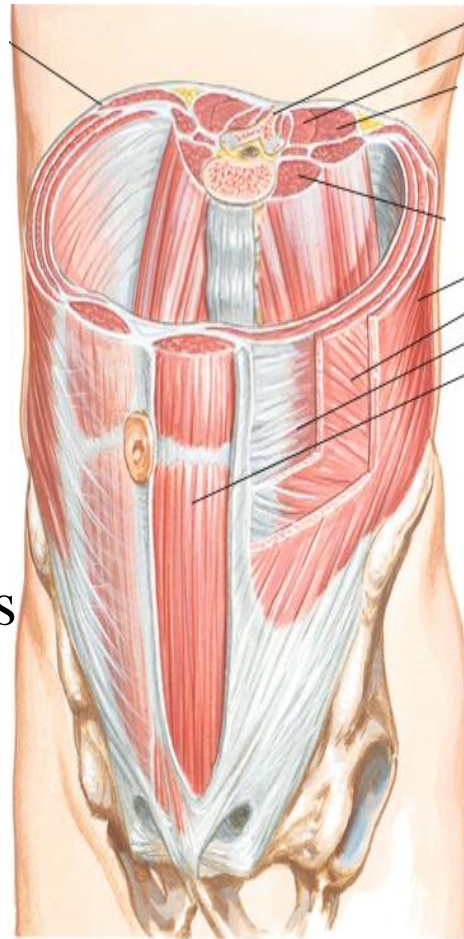
2- Pyramidalis

### Flat muscles

External oblique

Internal oblique

Transversus abdominis



# ANTERIOR ABDOMINAL WALL

## RECTUS ABDOMINIS

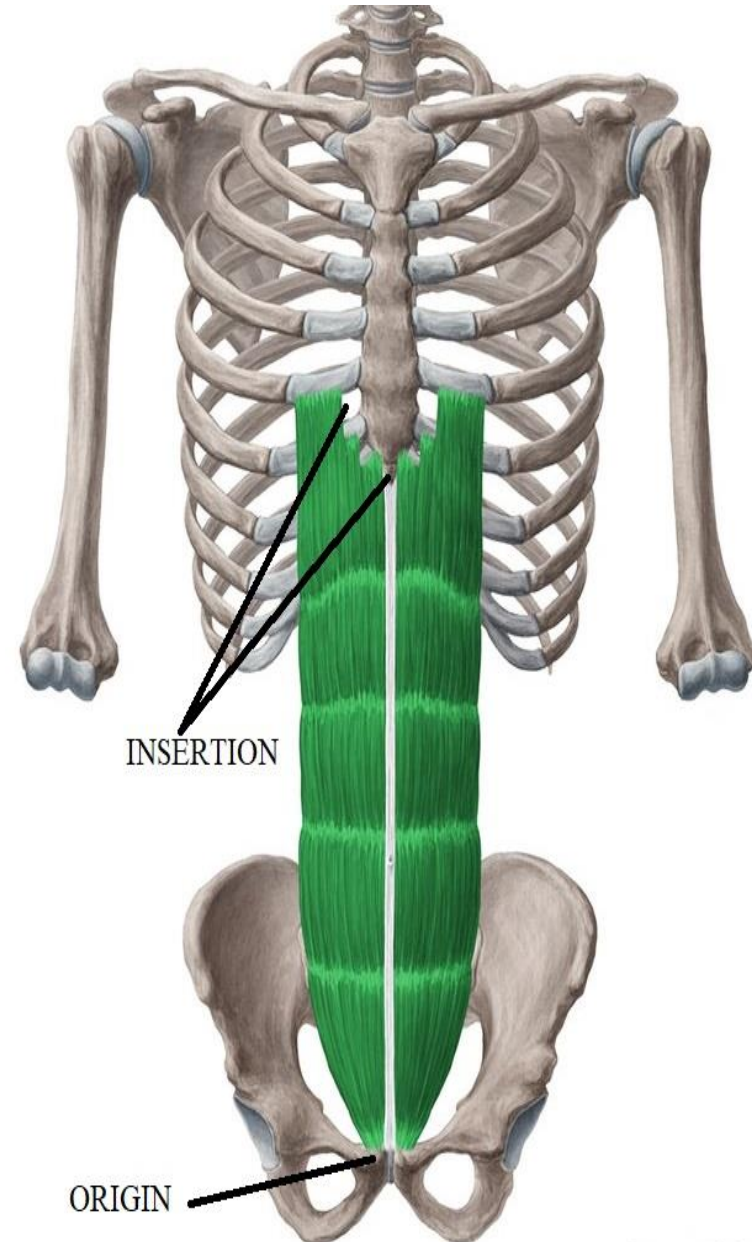
O.:-

1-medial head:- symphysis pubis

2-lateral „ :- pubic crest

I.:-

Front of 5, 6,7 c.c. &  
xiphoid process



# ANTERIOR ABDOMINAL WALL

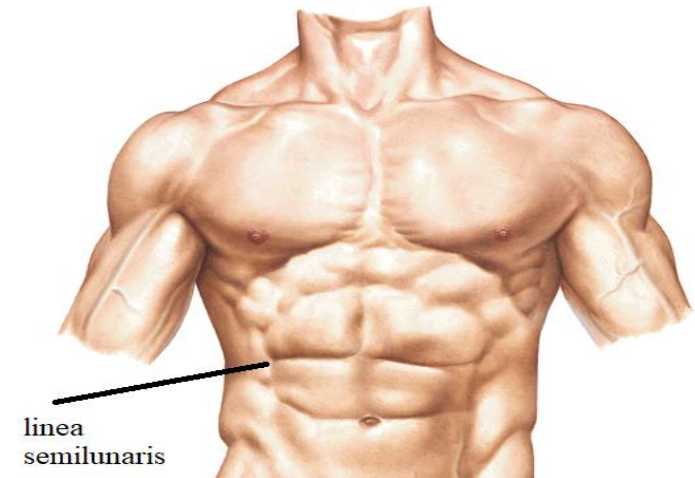
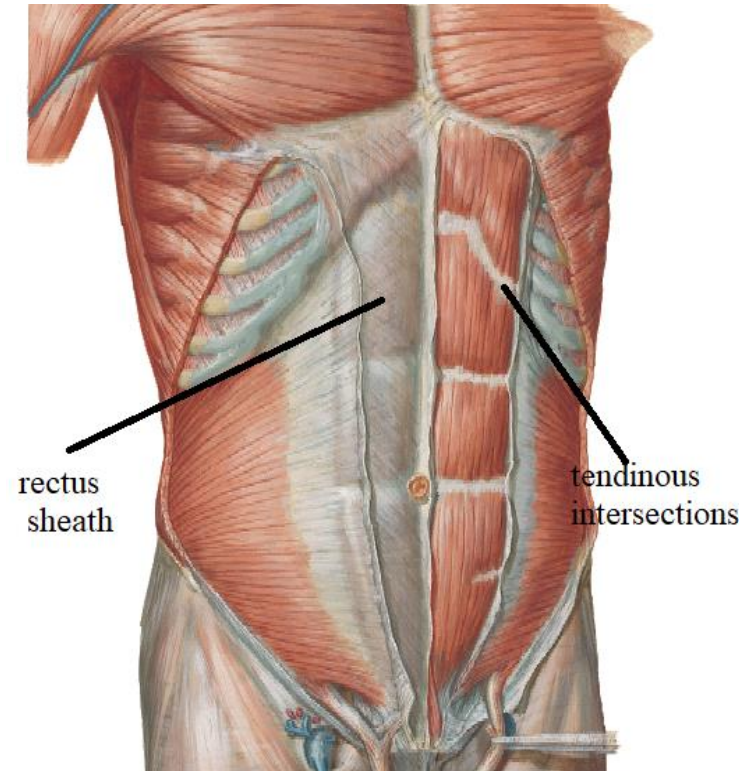
## RECTUS ABDOMINIS

### PARTICULAR FEATURES

- enclosed by rectus sheath
- divided by tendinous intersections:
- site:-
  - 1-at level of xiphoid process.
  - 2-at level of umbilicus.
  - 3-midway ( ) xiphoid process &umbilicus
  - 4-below umbilicus (may be absent).
- These intersections attach to ant. wall of rectus sheath &seen only anteriorly.

### linea semilunaris:

curved groove along lateral border of the muscle





# ANTERIOR ABDOMINAL WALL

## PYRAMIDALIS

O.:-

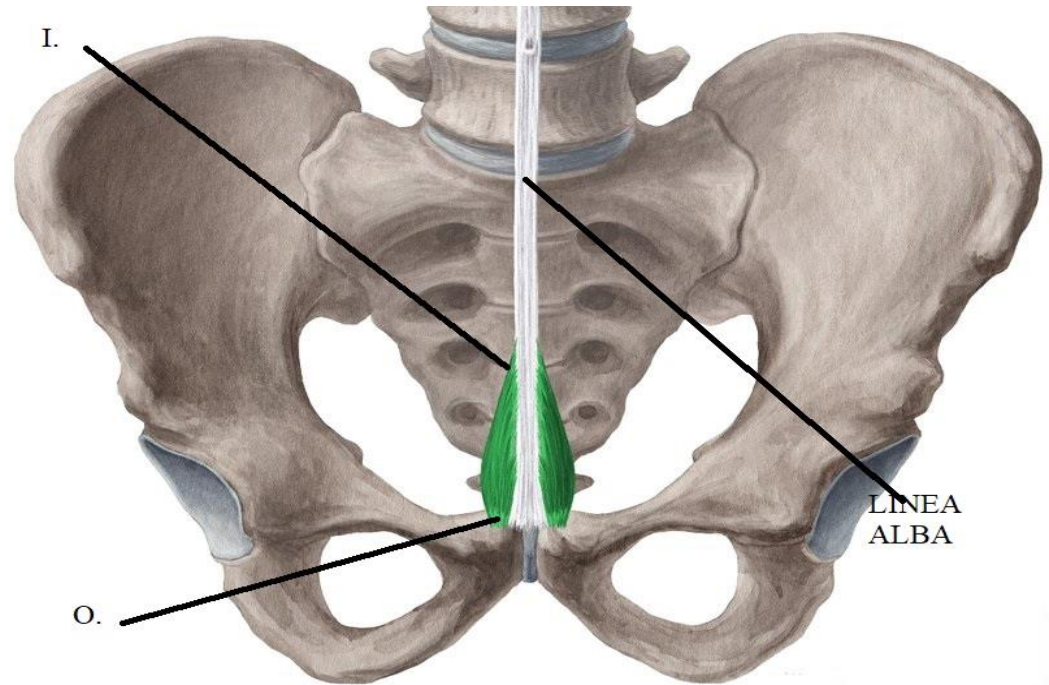
from pubic crest

I.:-

lower part of linea alba  
this insertion marks  
midline

Particular features

May be absent



# ANTERIOR ABDOMINAL WALL

## EXTERNAL OBLIQUE

O.:-Outer surface of lower 8 ribs by digitations

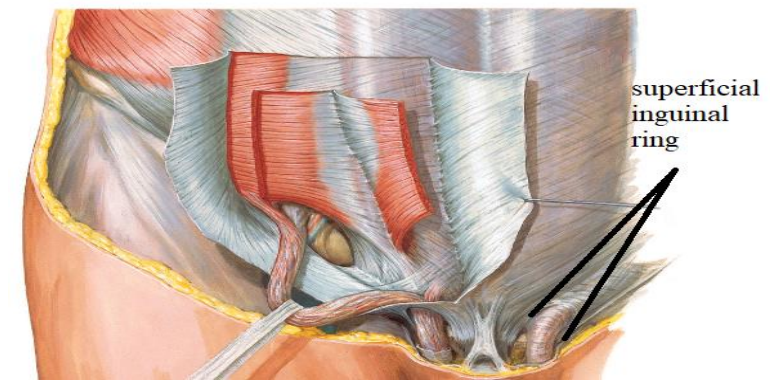
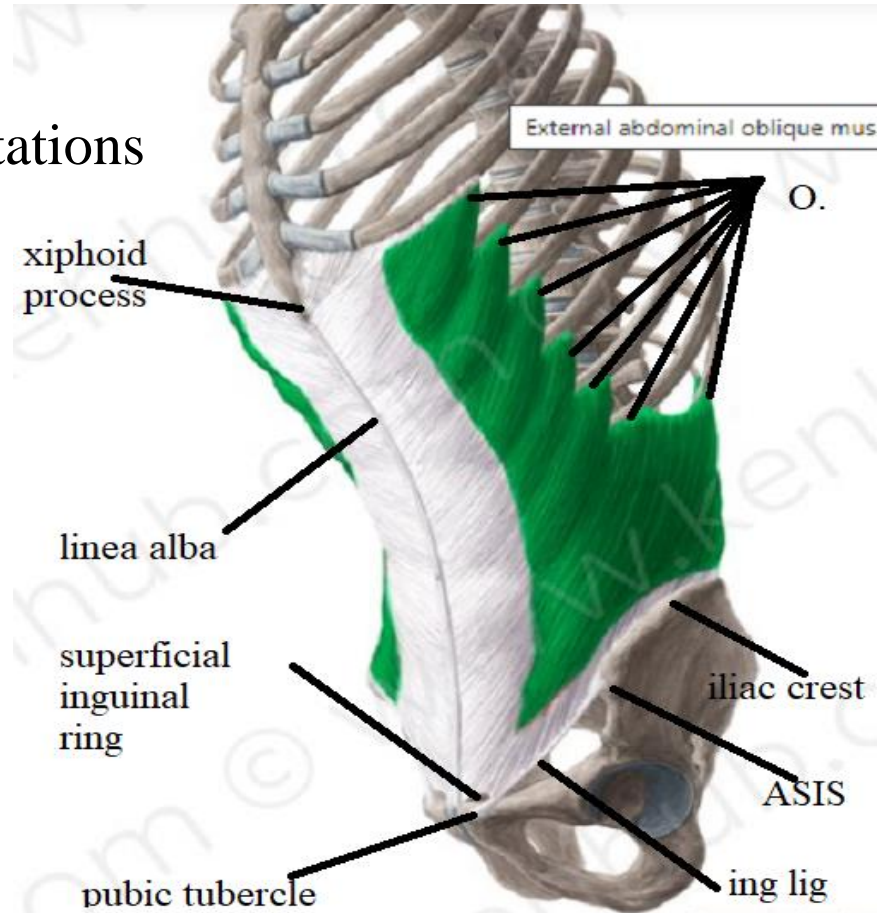
I.:-

Pass downwards, forwards & medially to

- linea alba
- pubic tubercle
- ASIS
- Ant. 1/2 of outer lip of iliac crest

### Particular features

- superficial inguinal ring
- "Lower border is folded upwards & backwards forming inguinal Ligament" that extend from pubic tubercle to ASIS





# ANTERIOR ABDOMINAL WALL

## INTERNAL OBLIQUE

O.:-

- lat. 2/3 of inguinal ligament
- ant. 2/3 intermediate area of iliac crest.
- lumbar fascia.

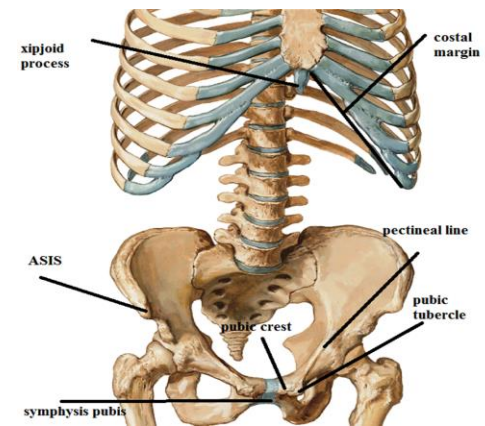
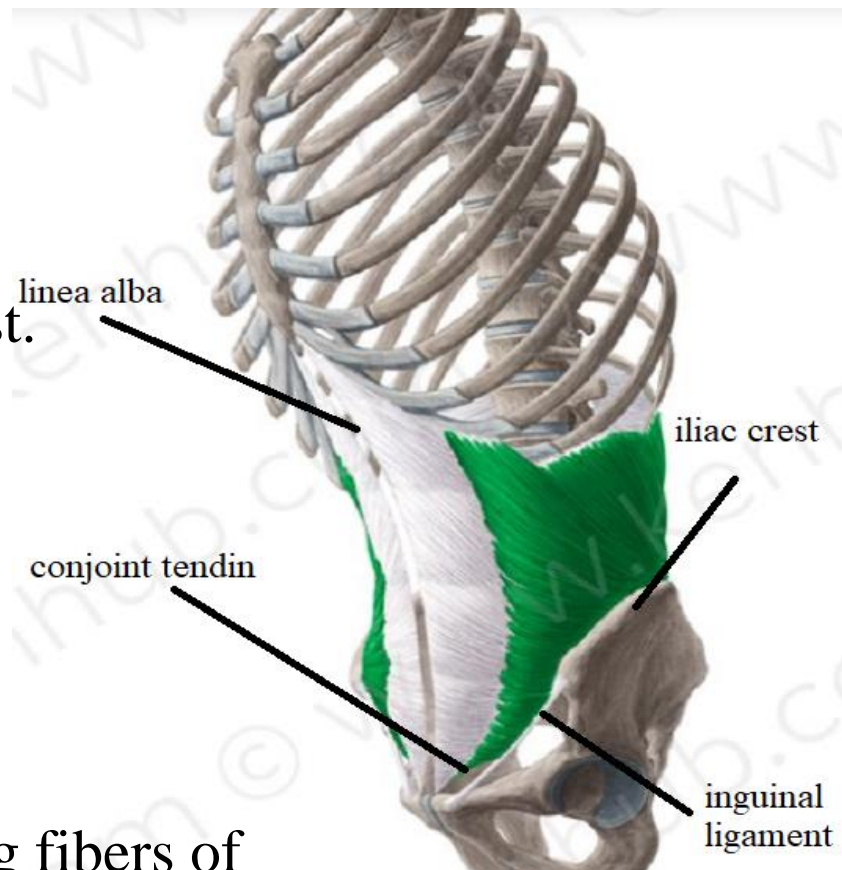
I.:-

pass upwards, forwards & medially to

- Lower 6 ribs.
- Linea alba .
- Lower fibers arch & fuse with arching fibers of transversus abdominis forming conjoint tendon attach to Pubic crest & pectineal line

## PARTICULAR FEATURES

Share in conjoint tendon



# ANTERIOR ABDOMINAL WALL

## Transversus abdominis

O.:-

- Lat. 1/3 of ing. lig.
- ant. 2/3 inner lip of iliac crest.
- lumbar fascia.
- lower 6 ribs & c.c.

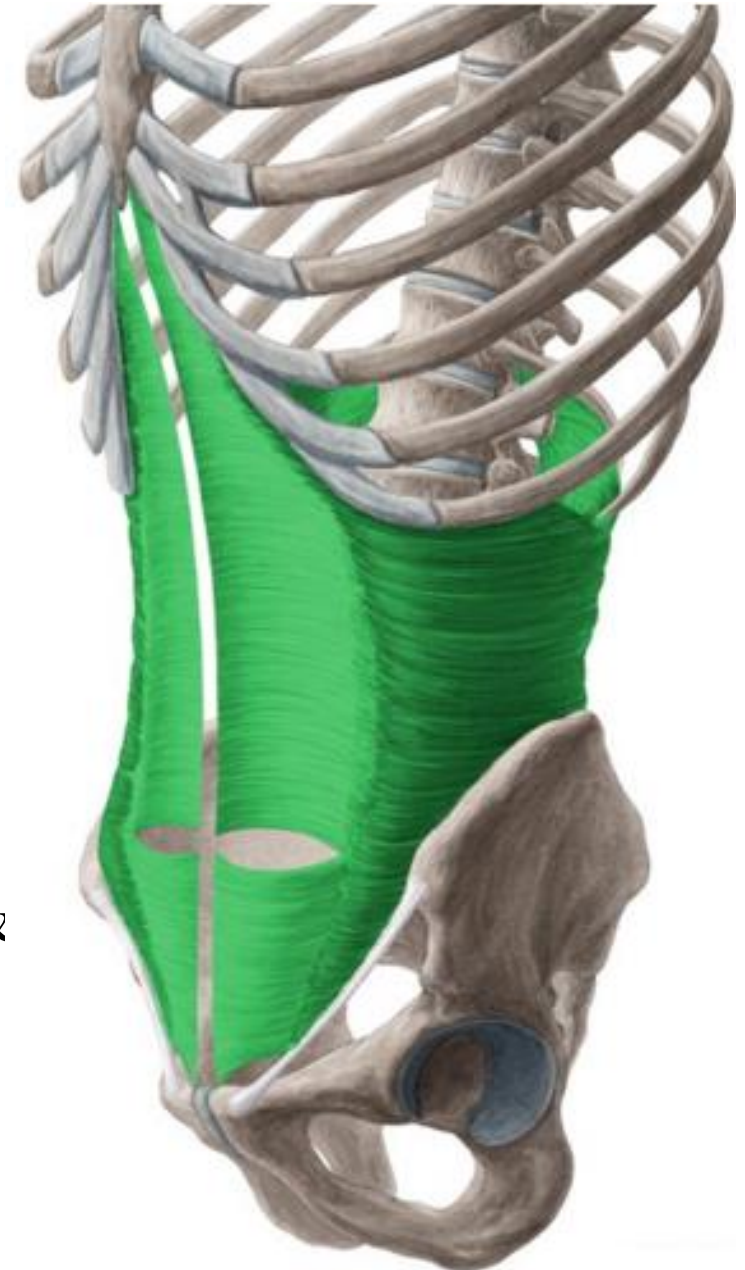
I.:-

Pass horizontally to

- linea alba.
- lower fibers:-arch & fuse with arching fibers of internal oblique forming conjoint tendon attach to pubic crest & pectineal line.

## PARTICULAR FEATURES

Share in conjoint tendon



# ANTERIOR ABDOMINAL WALL

**Nerve Supply :-**

**The 3 flat muscles**

Lower 6 thoracic nerves & L1

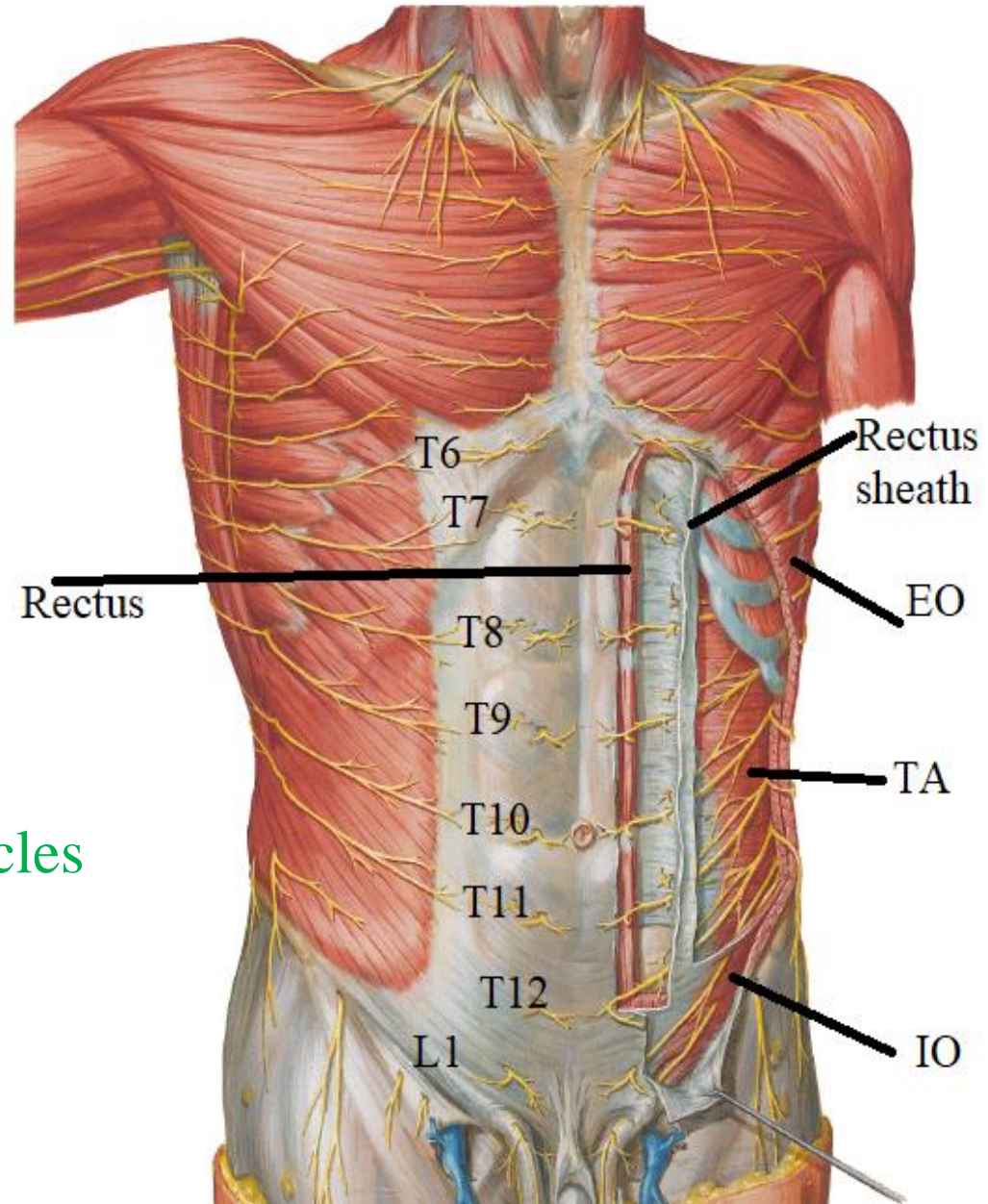
**The rectus abdominis**

Lower 6 thoracic nerves

**The Pyramidalis**

T12

**N.B.:- The nerves run between the internal oblique and the transversus abdominis muscles (neurovascular plane)**





# ANTERIOR ABDOMINAL WALL

## Action of antero-lateral abd. Wall muscles.

### 1-movement of the trunk:-

- Pyramidalis ----tense linea alba.
- Recti-----anterior flexion.
- Flat muscles-----lateral flexion & rotation

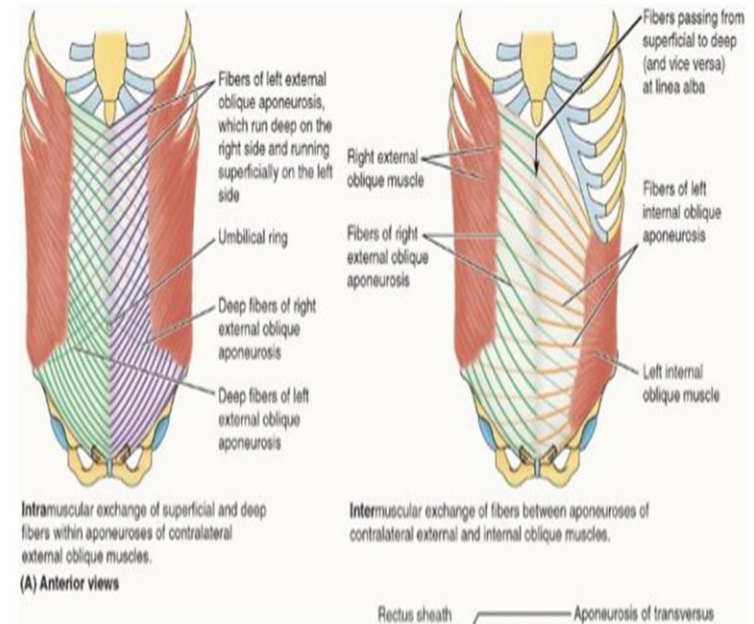
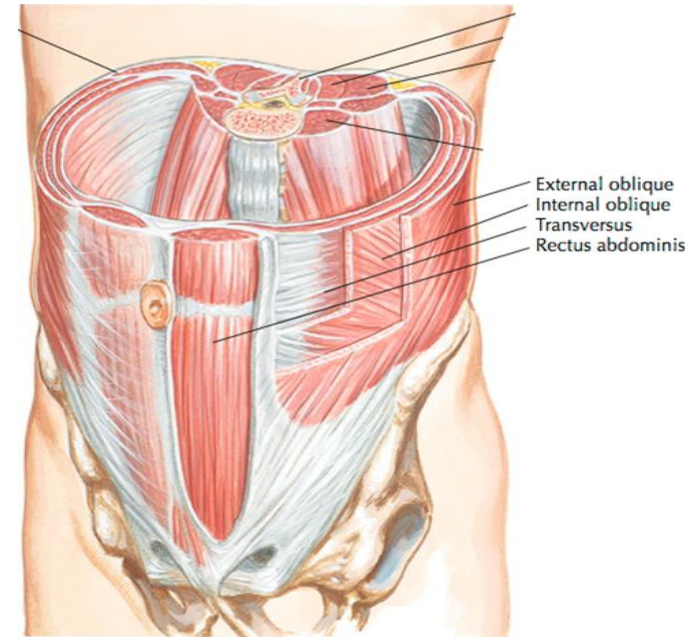
### 2-Respiration:-

- Inspiratory:- relax to accommodate viscera
- Forced expiratory:- contract to pull thoracic cage downwards in cough& sneezing.

### 3-Supportive to viscera by their tone

### 4-Protective to viscera against trauma by reflex contraction

### 5-Expulsive to viscera as in micturition, defecation, vomiting& delivery

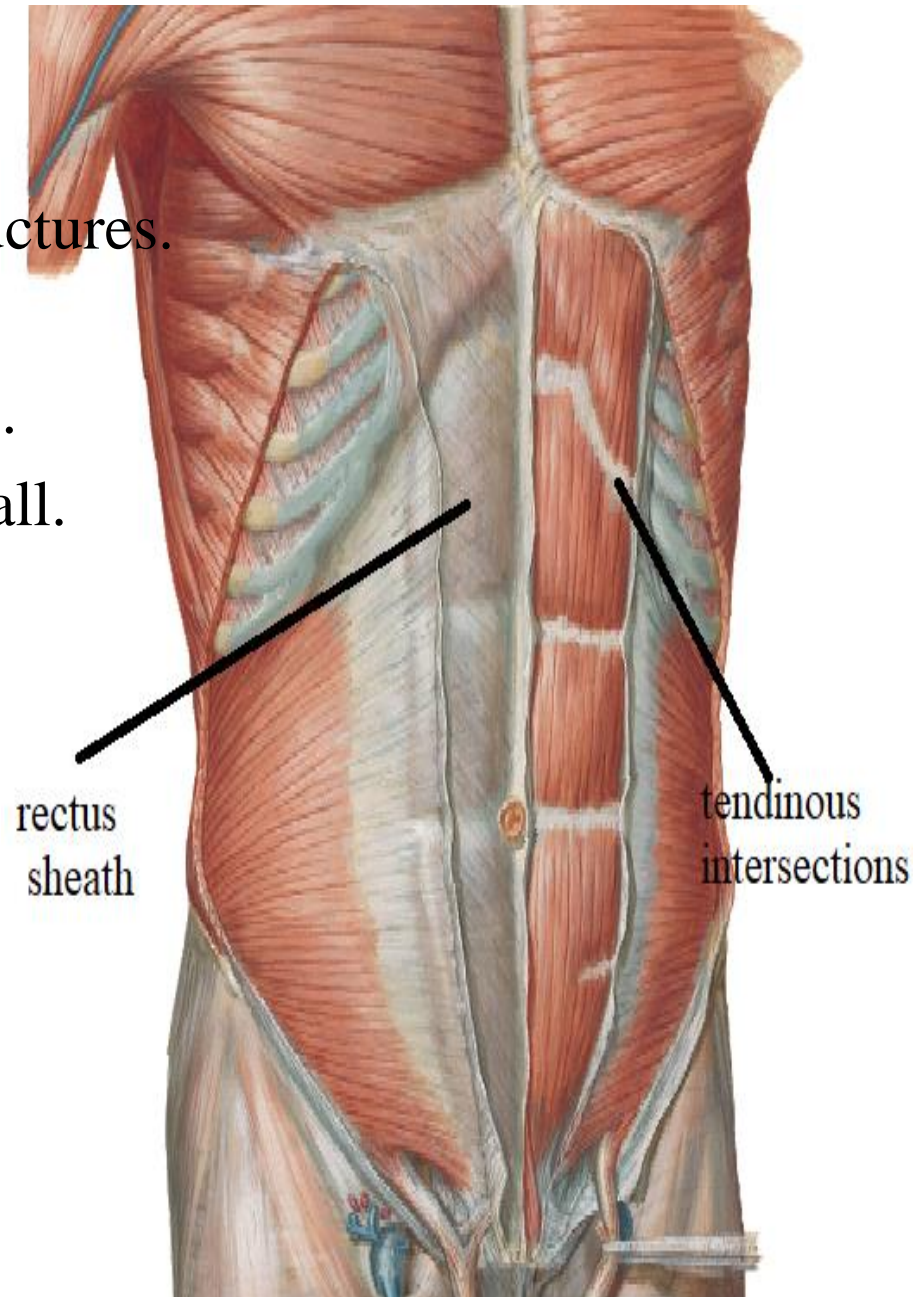


# RECTUS SHEATH

**Def.:-** aponeurotic fibrous sheath  
encloses rectus abdominis & other structures.

## function

- 1-prevent bowing of rectus abdominis .
- 2-maintain the strength of ant. abd. wall.



# RECTUS SHEATH

## Formation:

Upper (1<sup>st</sup> .) part =above costal margin

Ant. Wall:- ext. oblique aponeurosis

Post. Wall:- 5,6 &7 c.c.

middle (2<sup>nd</sup> .) part

=From costal margin to level of ASIS

## Ant. Wall

1.ext. oblique aponeurosis

2.ant. lamina of int. oblique aponeurosis

## Post. Wall

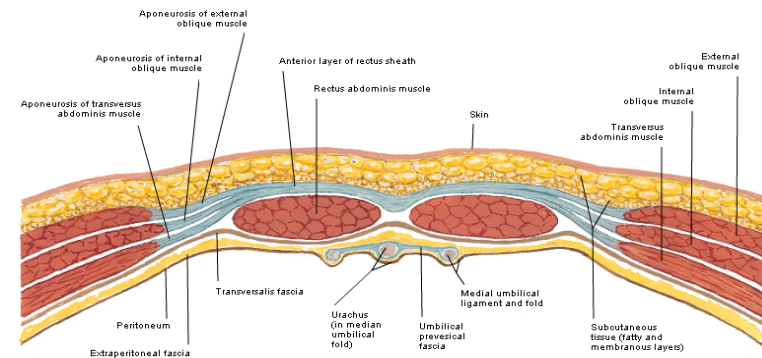
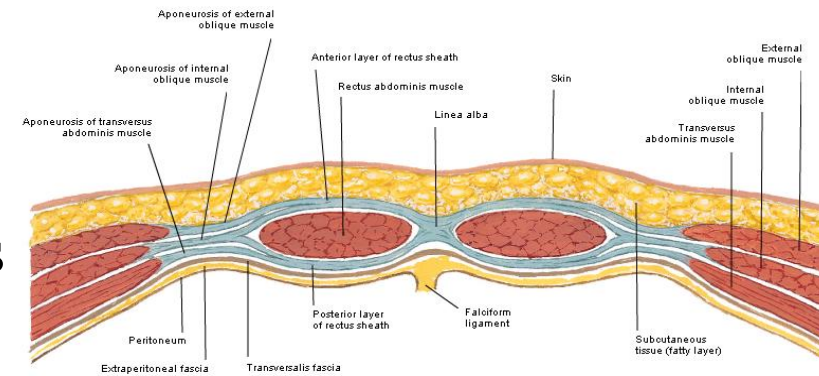
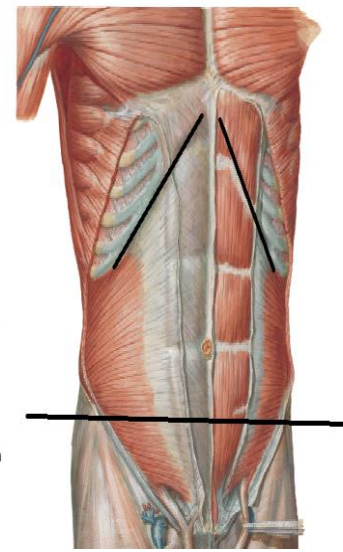
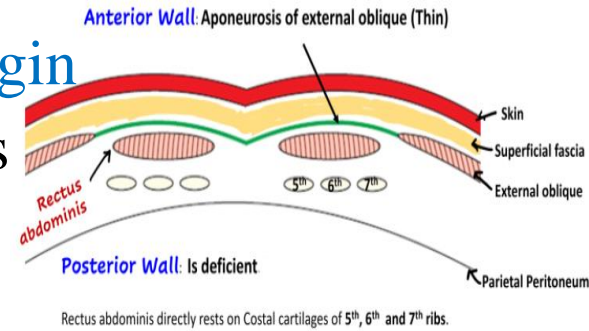
1.Post. lamina of int. oblique aponeurosis

2. Transversus abd. Aponeurosis

lower (3<sup>rd</sup> .) part =below level of ASIS

Ant. Wall:- The 3 muscles aponeuroses

Post. Wall:-fascia transversalis

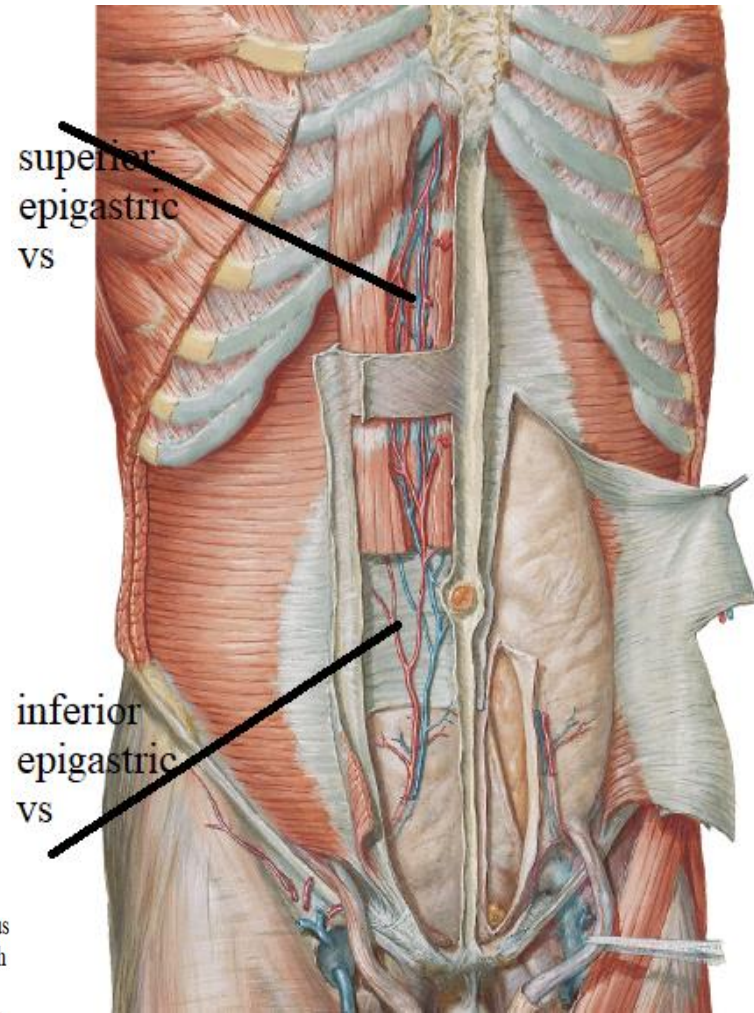
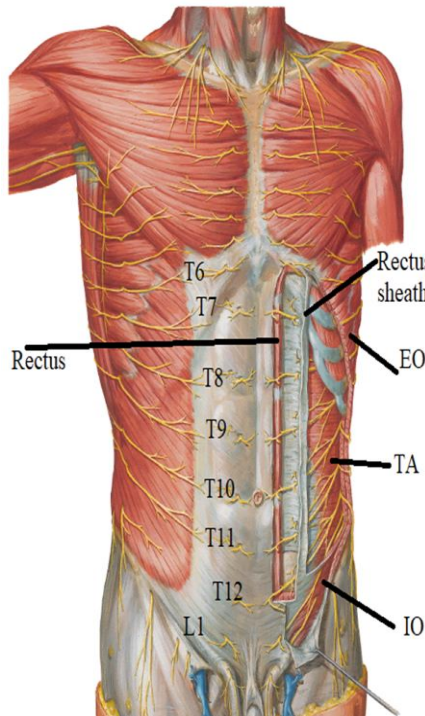




# RECTUS SHEATH

## Contents:

- 1-pyramidalis
- 2-rectus abdominis
- 3-superior epigastric vs
- 4-inferior            „        „
- 5-lower 6 thoracic nerves
- 6-lymphatics



THANQ