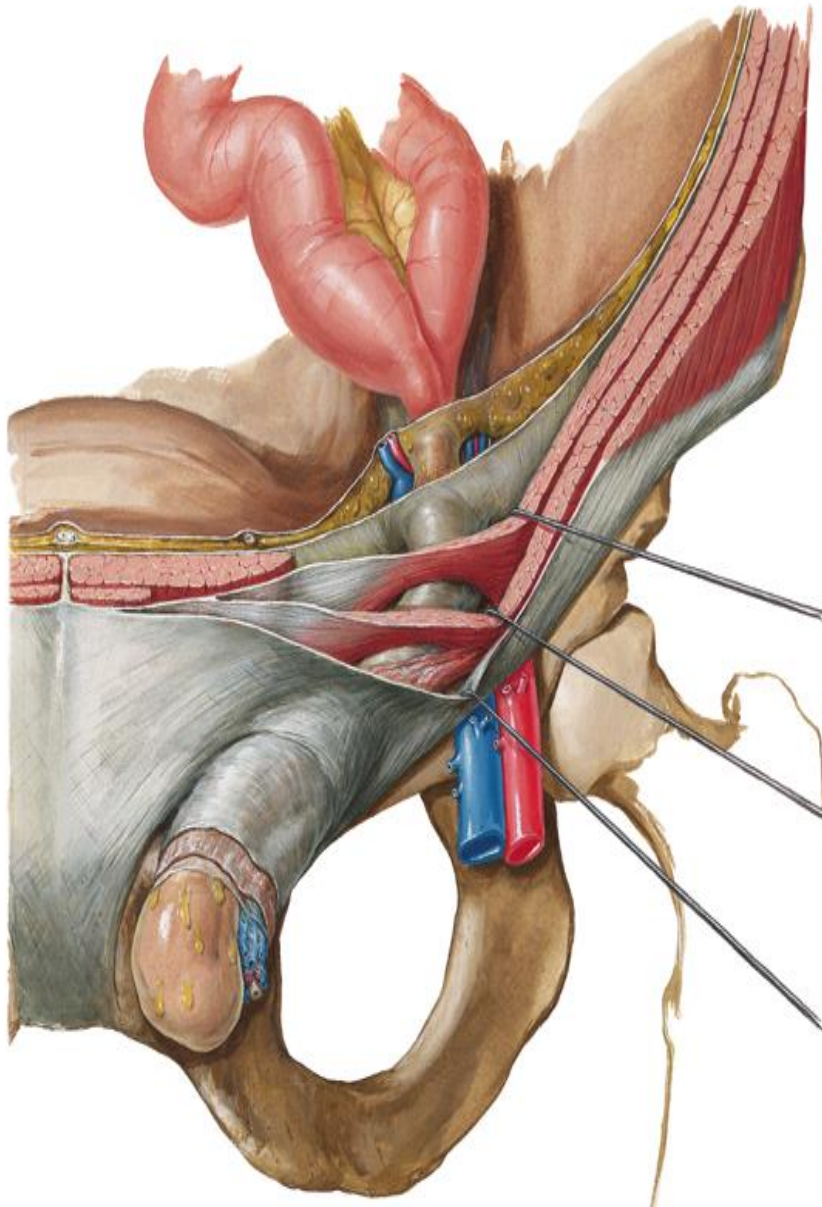


# INGUINAL CANAL AND HERNIA



BY  
DR ABULMAATY MOHAMED  
ASSISTANT PROFESSOR  
ANATOMY & EMBRYOLOGY  
MUTAH UNIVERSITY

# LUMBAR TRIANGLE

## Boundaries:

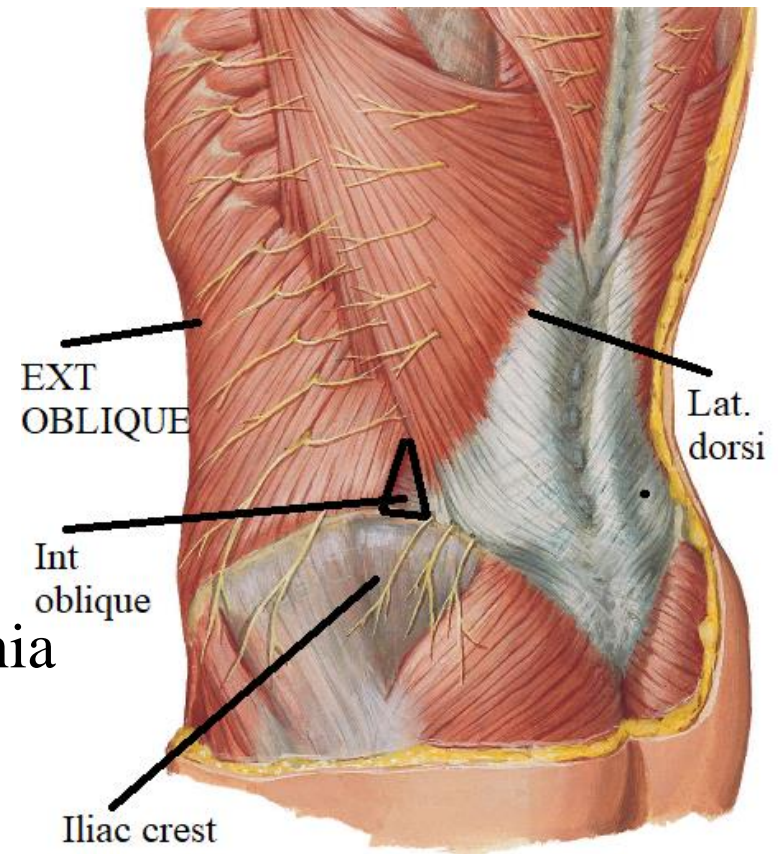
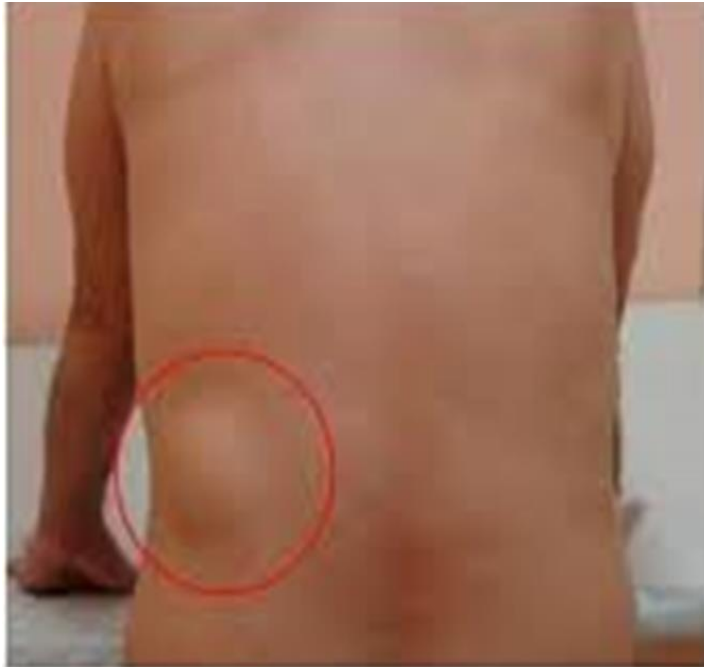ant. : ext. oblique

post. : latissimus dorsi

below: iliac crest

floor : int. oblique.

**significance:** site of very rare lumbar hernia



# INGUINAL LIGAMENT

**DEF.:-** Lower border of external oblique aponeurosis folded upwards & backwards

extend from pubic tubercle to ASIS

**surfaces:**

1-upper concave surface:

2-lower convex surface:

**extensions :** extend from medial part of inguinal lig.

1- **lacunar ligament:-** triangular in shape with

- **apex:** directed medially & attach to pubic tubercle.

- **base:** directed laterally

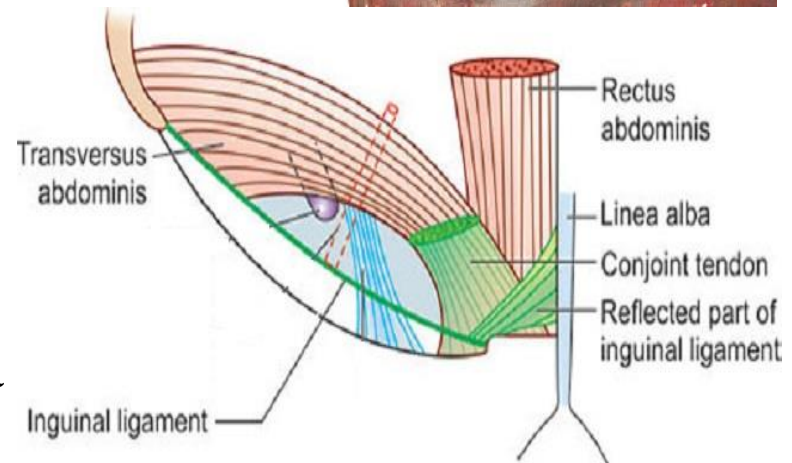
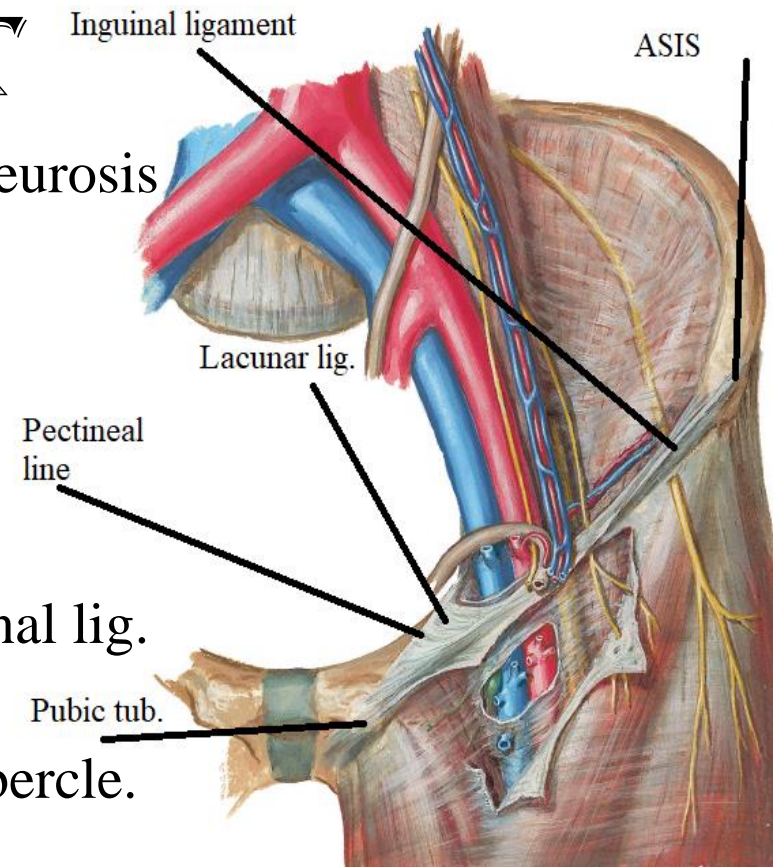
- **ant. border:** attach to inguinal lig.

- **post. border:** attach to pectineal line

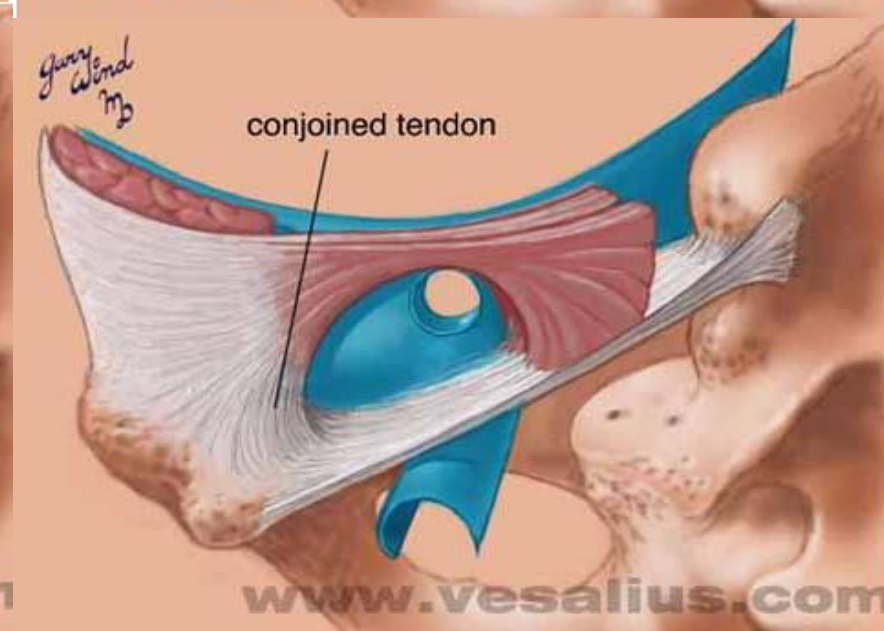
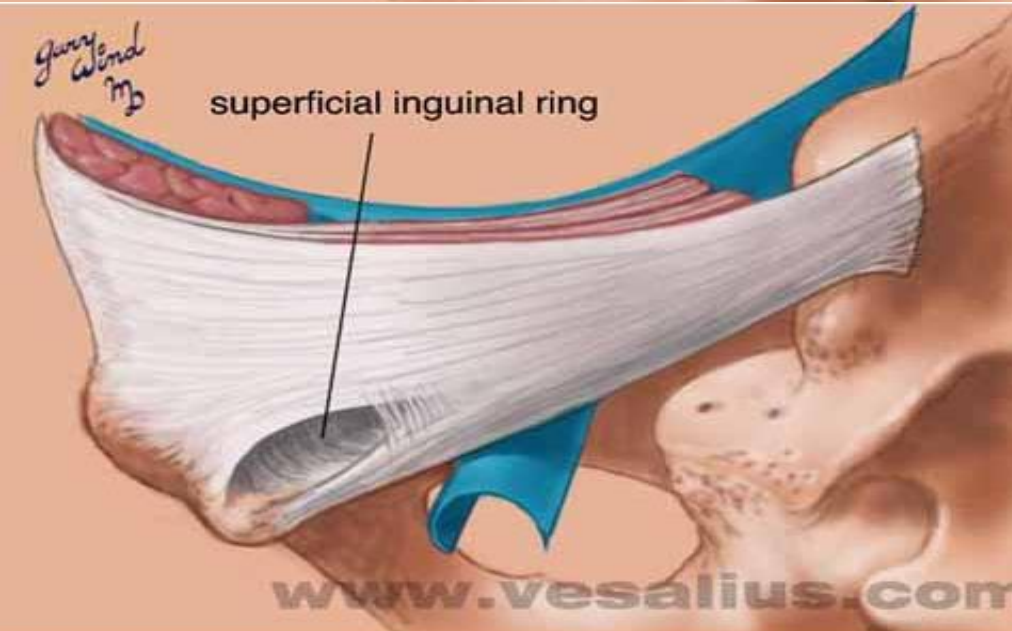
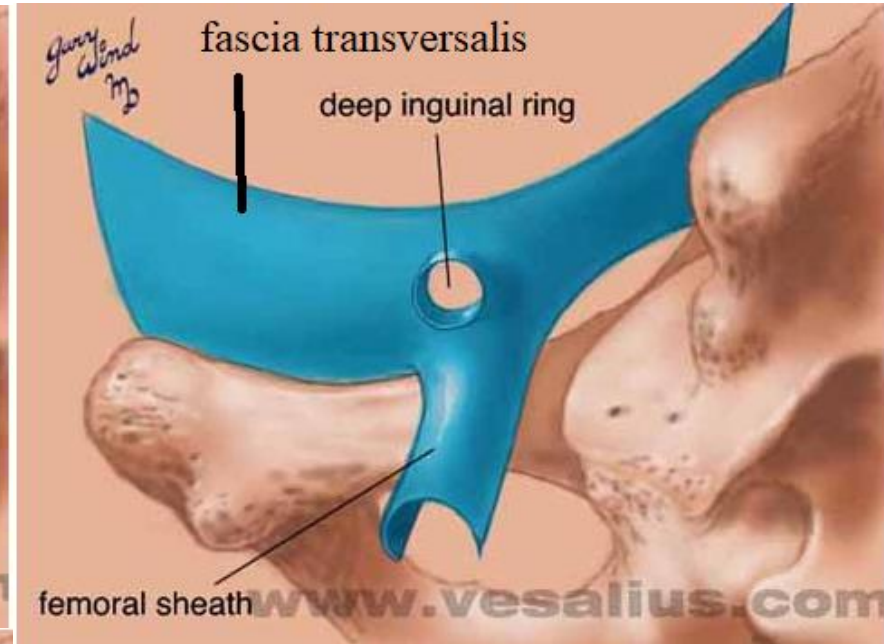
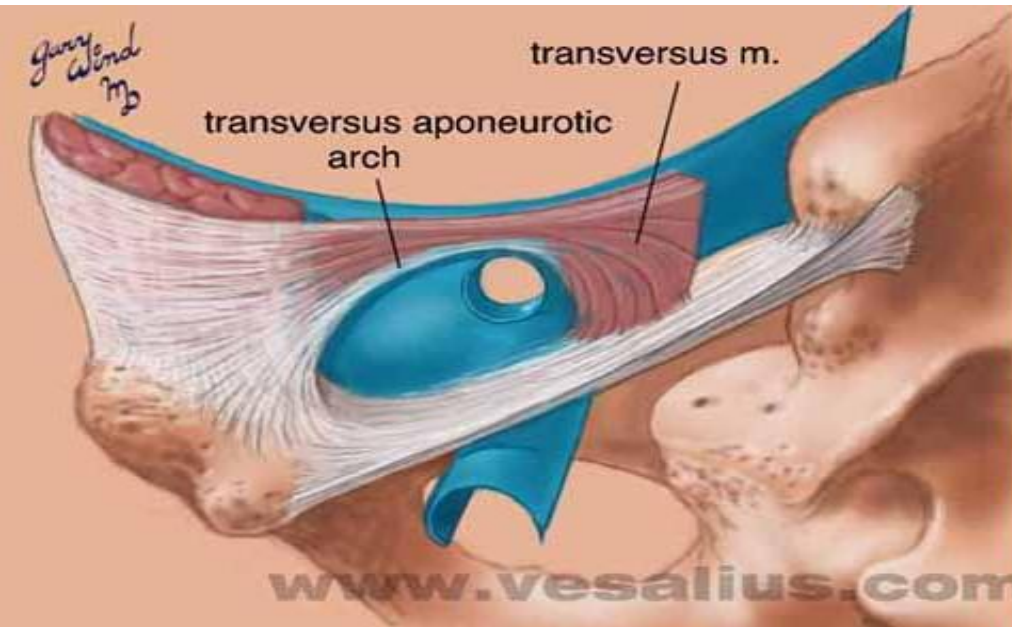
2- **reflected part:**

extends upward & medially

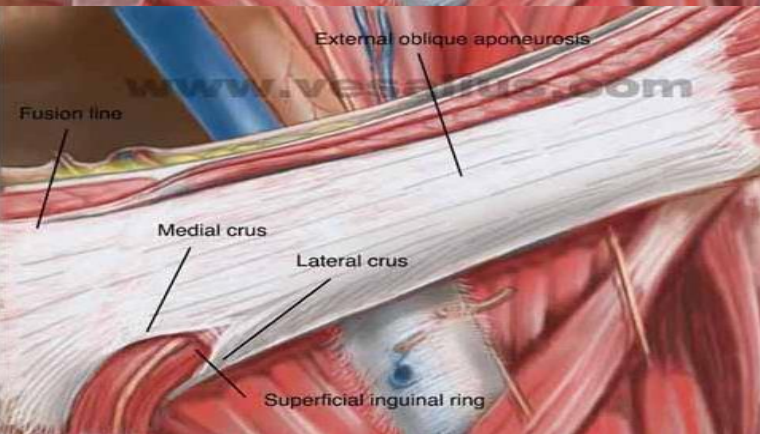
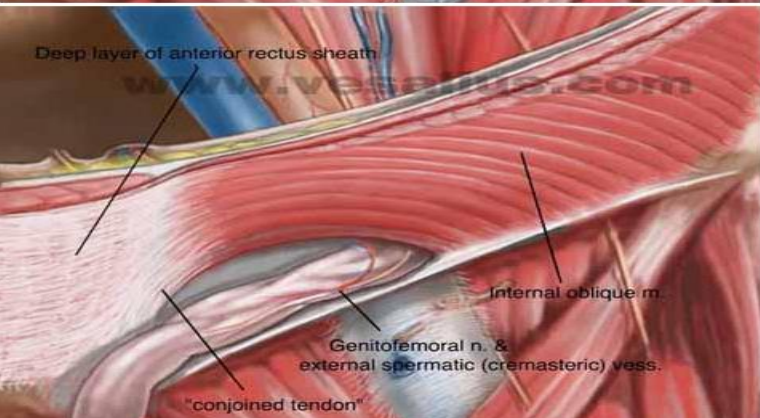
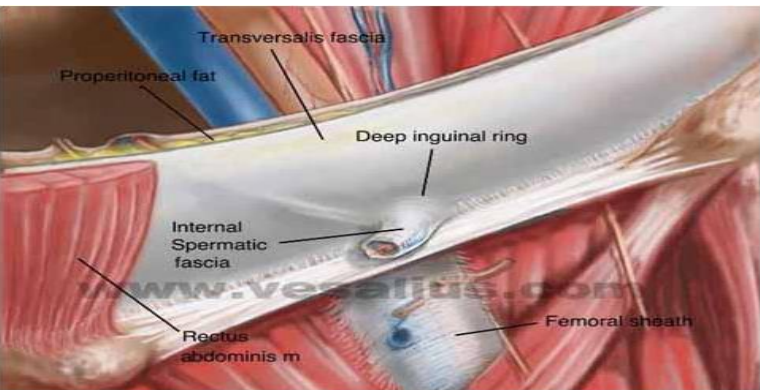
in front conjoint tendon to attach to linea alba



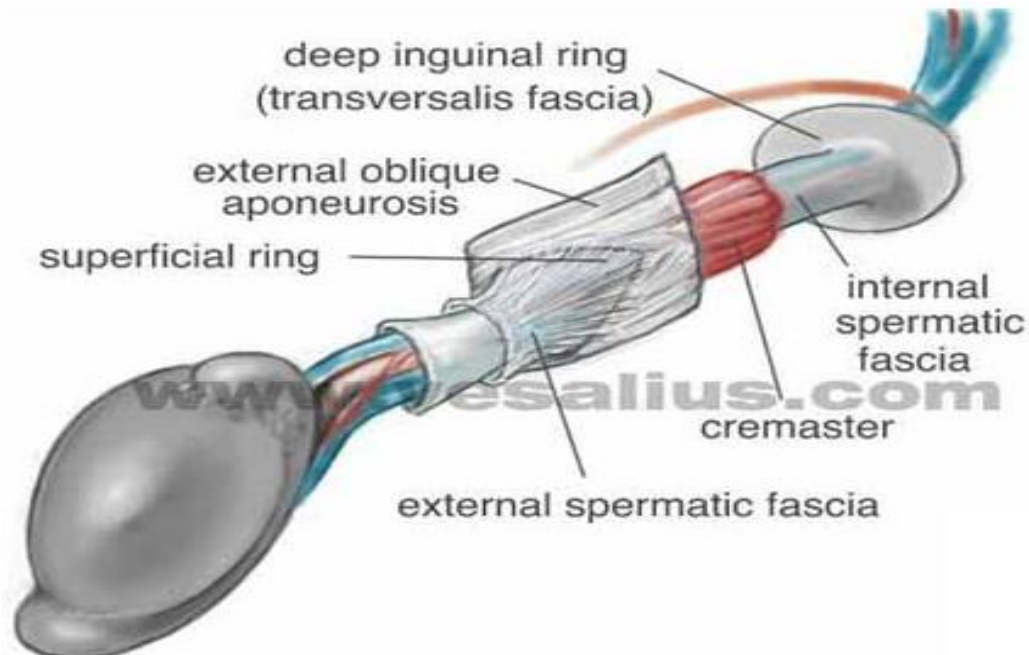
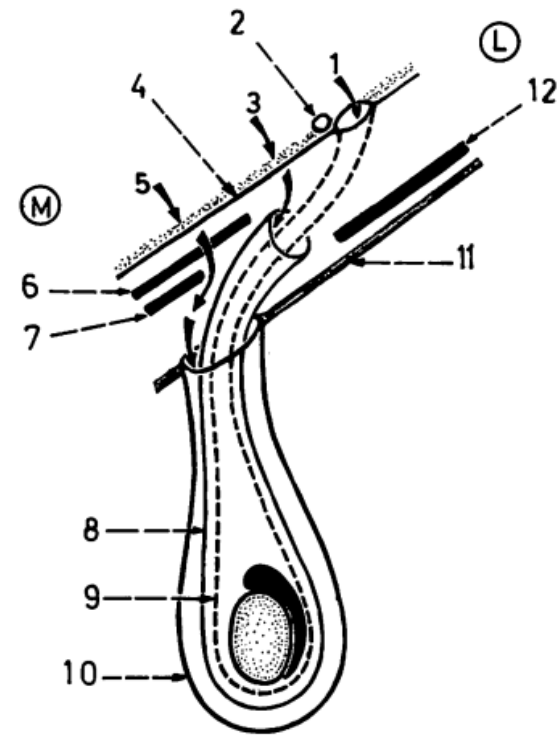
# INGUINAL CANAL



# INGUINAL CANAL



1. deep inguinal ring (site of oblique hernia).
2. inferior epigastric art.
3. site of lateral direct hernia.
4. transversalis fascia.
5. site of medial direct hernia.
6. conjoint tendon.
7. reflected part of inguinal ligament.
8. cremaster muscle and fascia.
9. internal spermatic fascia.
10. external spermatic fascia.
11. anterior wall of inguinal canal.
12. internal oblique muscle.



# INGUINAL CANAL

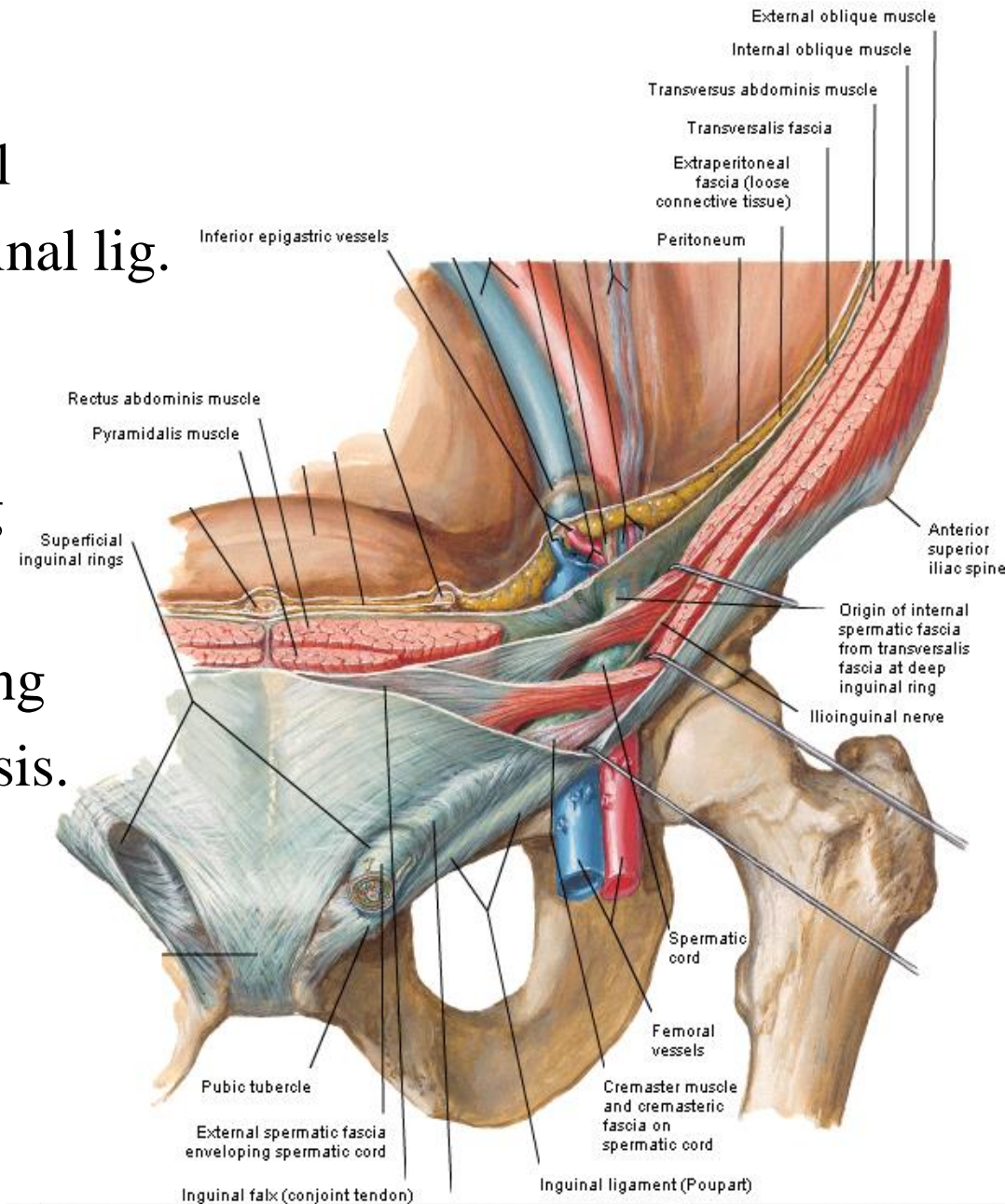
**Def.:** intermuscular passage in lower part of ant. ab. wall

**site:** above medial part of inguinal lig.

**direction:** downward, forward & medially.

**extent:** from deep inguinal ring in fascia transversalis to superficial inguinal ring in ext. oblique aponeurosis.

**length:** 1 1/2 inches (4 cm)



# INGUINAL CANAL

## Boundaries:

Deep inguinal ring

## Site:-

in fascia transversalis

1/2 inches above midinguinal point  
(midway ( ) ASIS & symphysis pubis )

## Shape:- oval

## Transmits:-

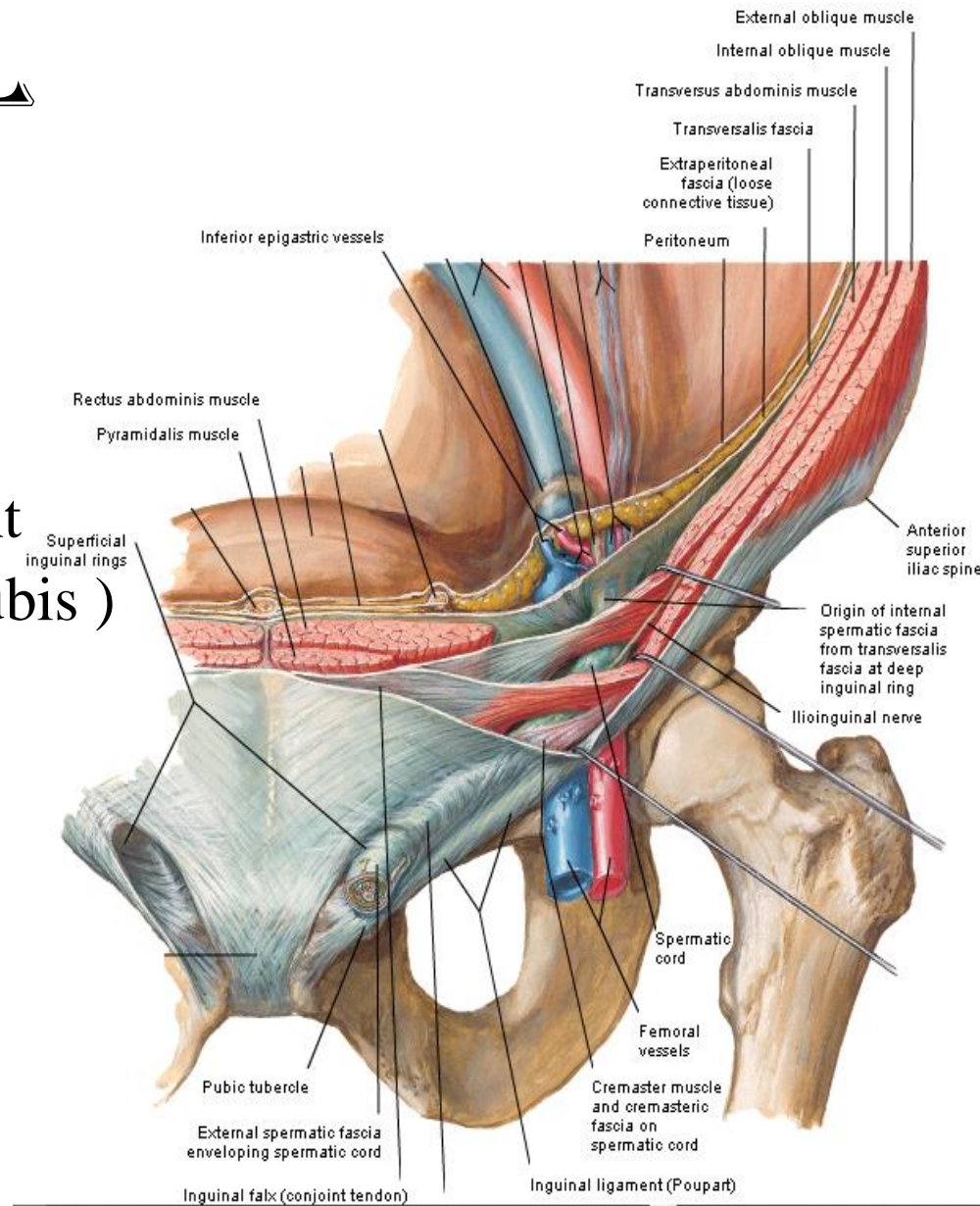
spermatic cord in male

round lig. of uterus in female

## At its margin:-

int. spermatic fascia is formed  
around the spermatic cord

## Relations:- inferior epigastric art. lies medial to the ring



# INGUINAL CANAL

## Boundaries:

### Superficial inguinal ring

**Site:-** in ext. oblique aponeurosis above pubic crest

**Shape:-** triangular with

- base: pubic crest

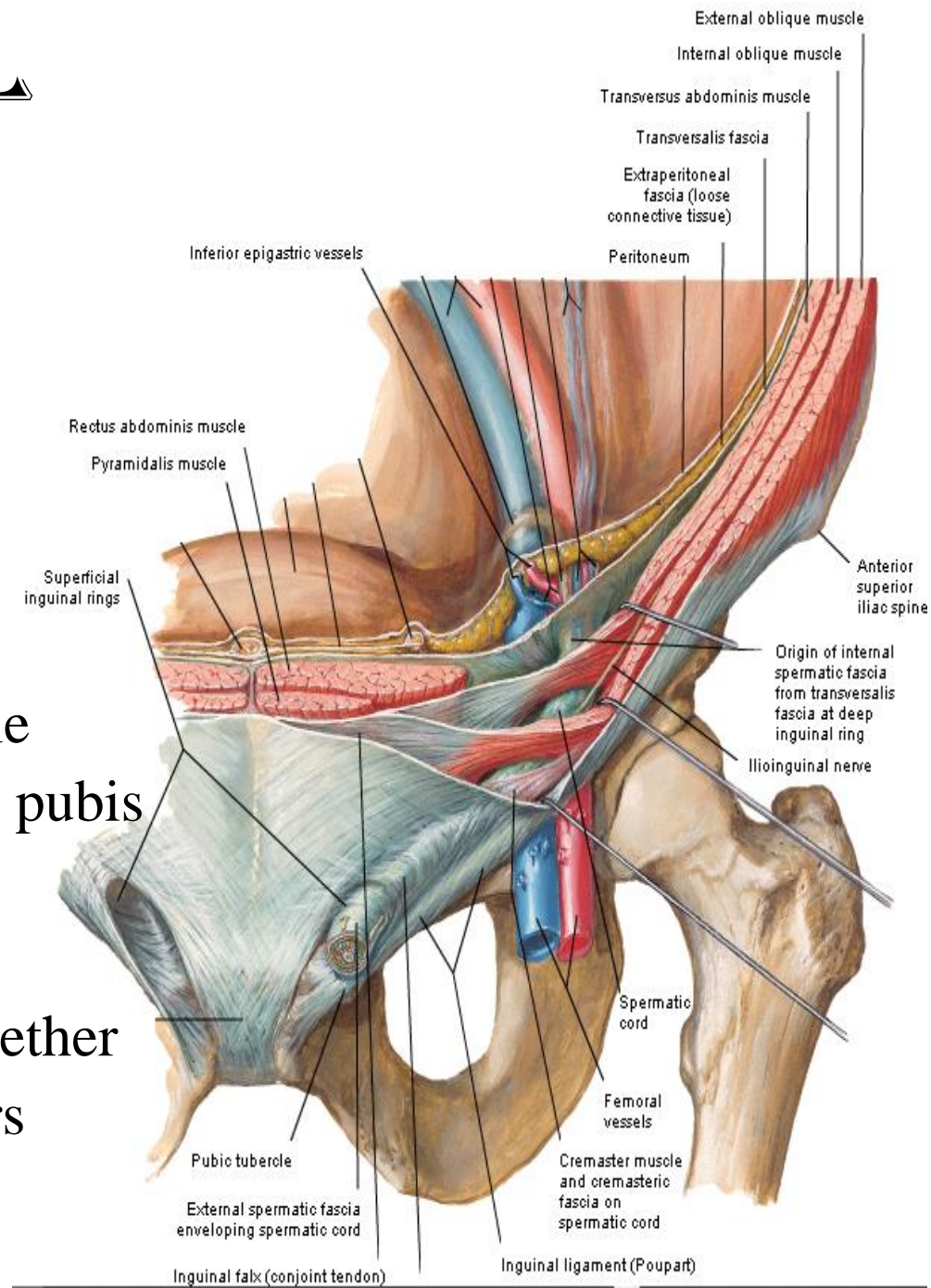
- sides:

lateral crus attach to pubic tubercle

medial crus attach to symphysis pubis

- apex: meeting of 2 crura and is directed upward & laterally

N.B: the 2 crura are connected together above the apex by intercrural fibers that prevent their separation





# INGUINAL CANAL

## Boundaries:

Superficial inguinal ring

## Transmits:-

Ilioinguinal nerve

spermatic cord in male

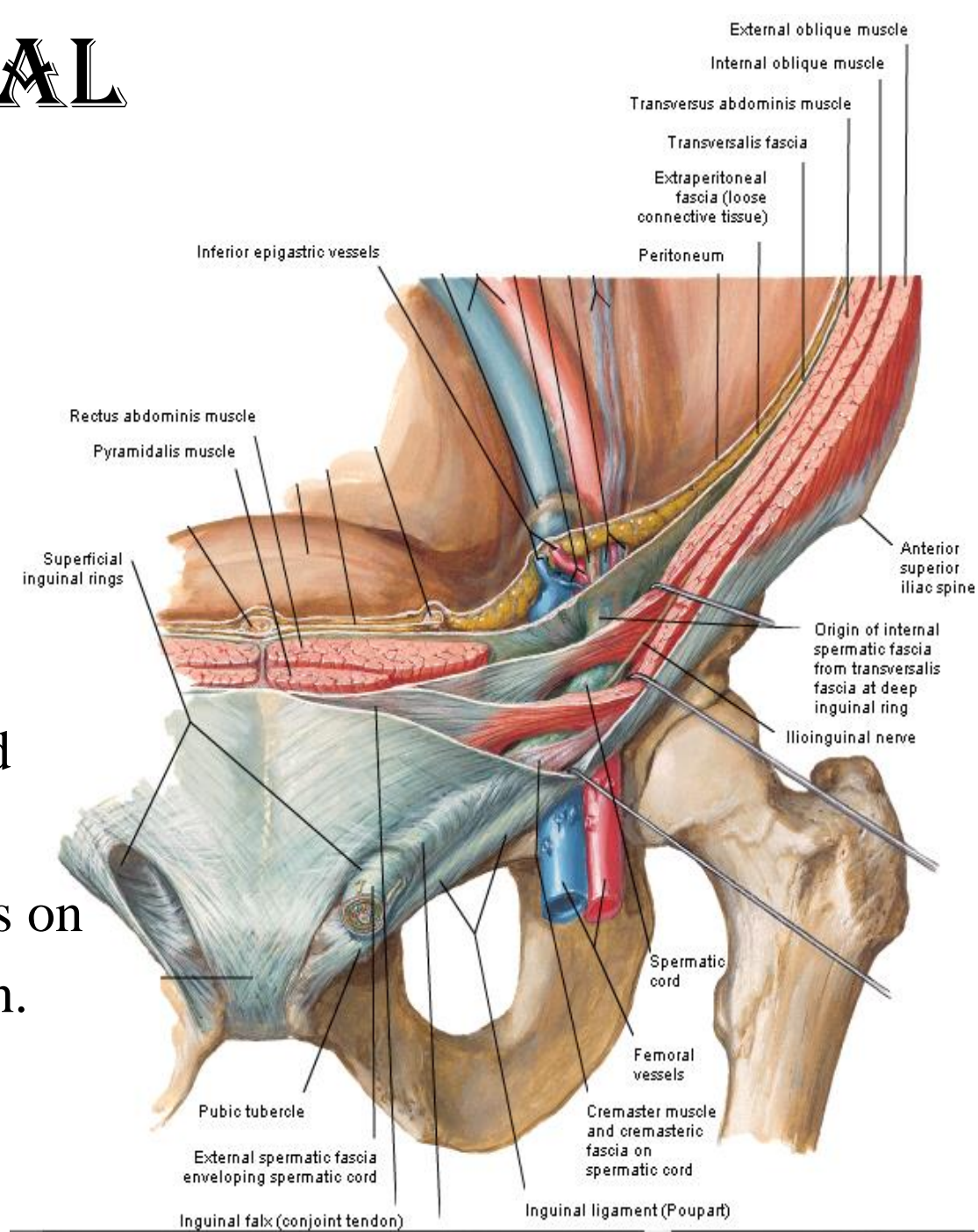
round lig. of uterus in female

## At its margin:-

ext. spermatic fascia is formed  
around the spermatic cord

Relations:- spermatic cord pass on  
lateral crus with ilioinguinal n.

in ( ) it & the crus

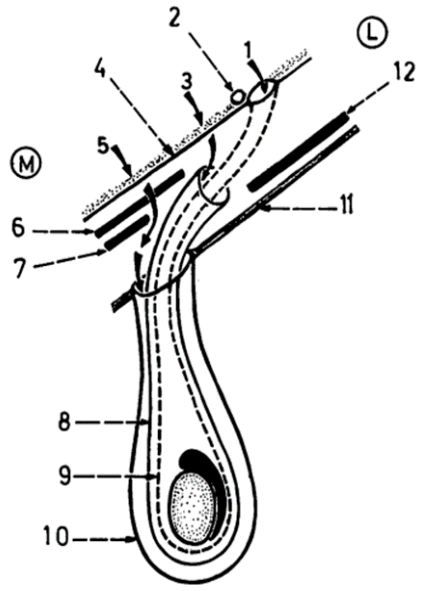


# INGUINAL CANAL

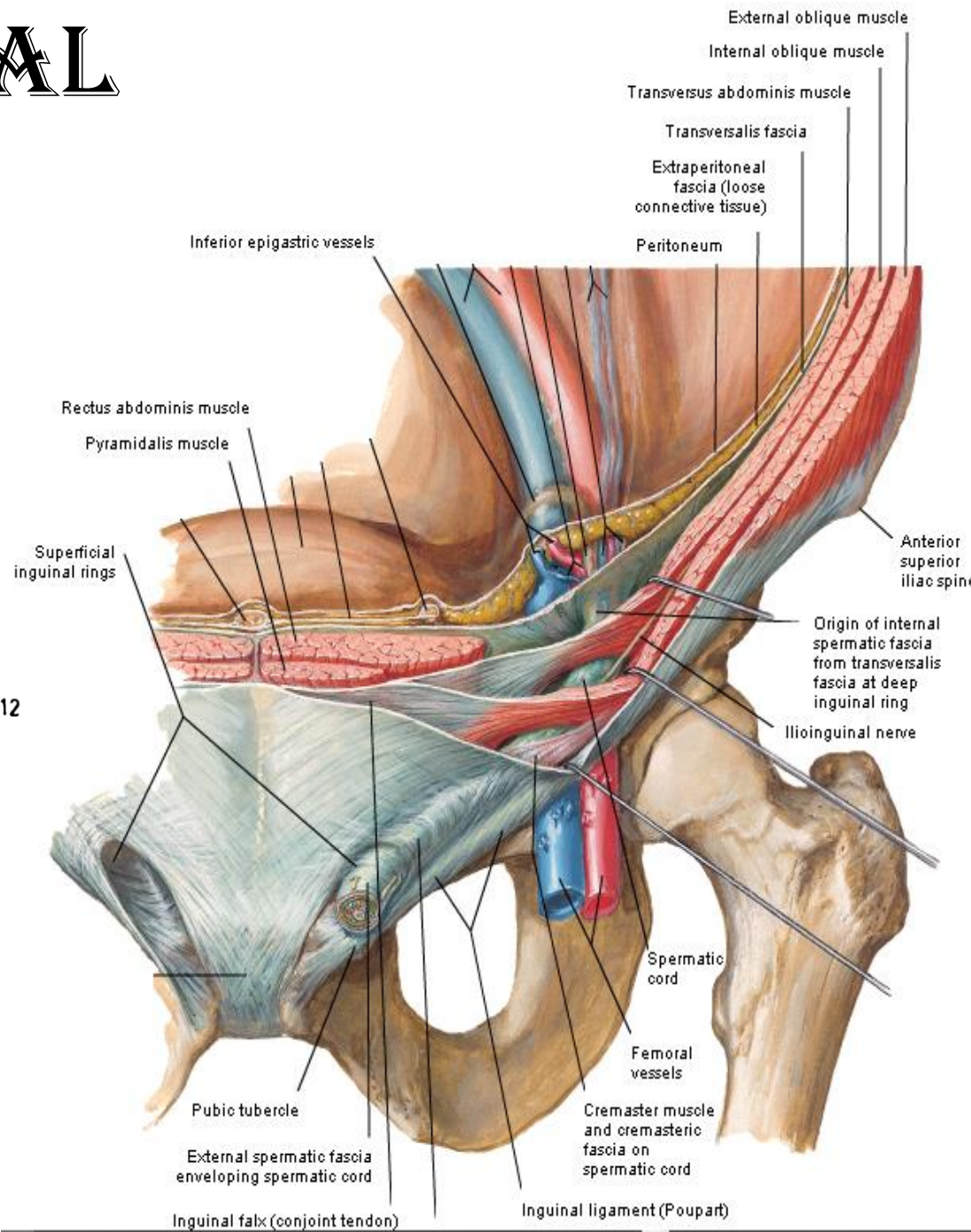
## Boundaries:

### Anterior wall

- ext. oblique aponeurosis
  - int. oblique in front
- deep inguinal ring



1. deep inguinal ring (site of oblique hernia).
2. inferior epigastric art.
3. site of lateral direct hernia.
4. transversalis fascia.
5. site of medial direct hernia.
6. conjoint tendon.
7. reflected part of inguinal ligament.
8. cremaster muscle and fascia.
9. internal spermatic fascia.
10. external spermatic fascia.
11. anterior wall of inguinal canal.
12. internal oblique muscle.



# INGUINAL CANAL

## Boundaries:

### Posterior wall

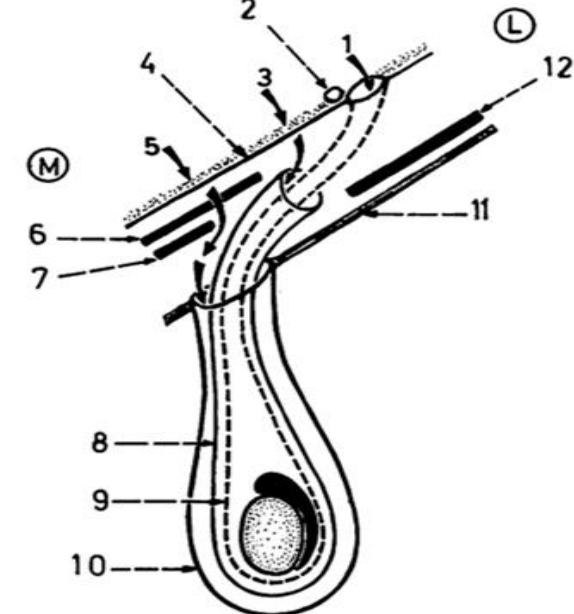
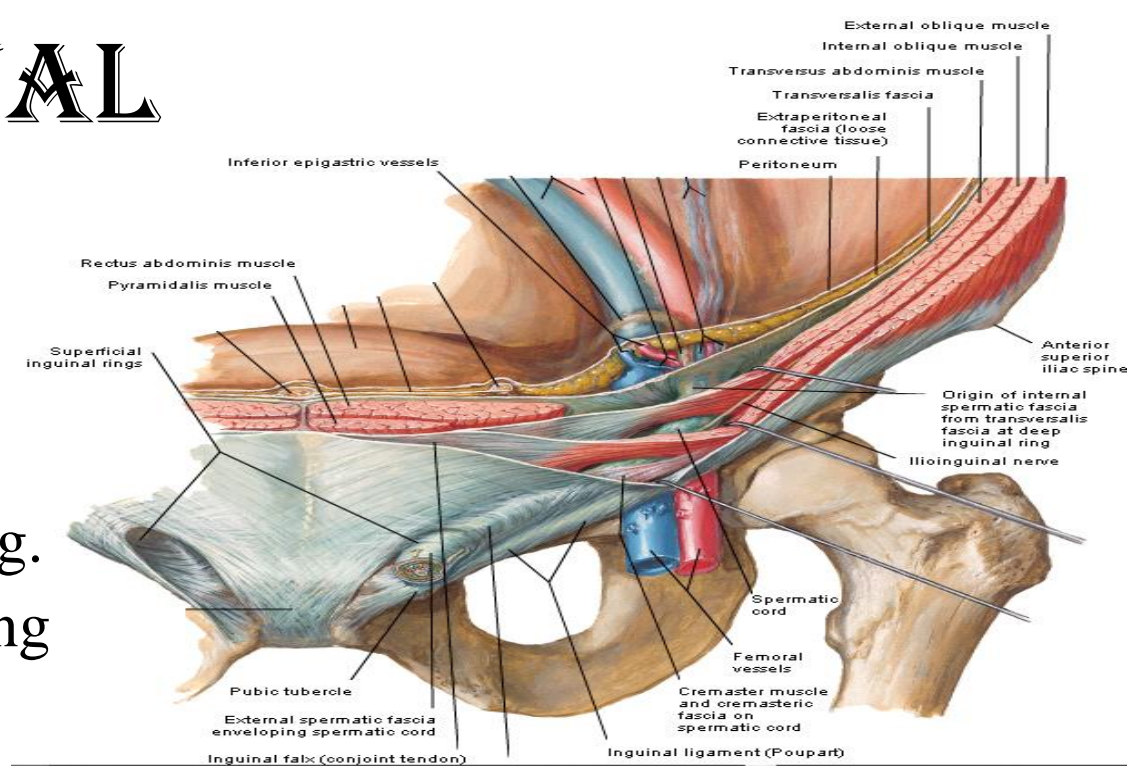
- fascia transversalis
- conjoint tendon & reflected part of inguinal lig. behind superficial inguinal ring

**Roof:** arching fibers of int. oblique & transversus abdo

**Floor:** inguinal lig.  
lacunar lig.

## Contents:

- 1- ilioinguinal n.
- 2- spermatic cord in male  
round lig. of uterus in female



1. deep inguinal ring (site of oblique hernia).
2. inferior epigastric art.
3. site of lateral direct hernia.
4. transversalis fascia.
5. site of medial direct hernia.
6. conjoint tendon.
7. reflected part of inguinal ligament.
8. cremaster muscle and fascia.
9. internal spermatic fascia.
10. external spermatic fascia.
11. anterior wall of inguinal canal.
12. internal oblique muscle.

# INGUINAL CANAL

## Compensatory mechanisms:

compensate weakness in the wall at site of the canal.

### 1-superficial ring

is compensated by conjoint tendon & reflected lig.

### 2-deep ring

is compensated by int. oblique.

### 3-contraction of int. oblique & transversus abdominis

descent of arching fibers & closure of canal.

### 4-contraction of ext. oblique

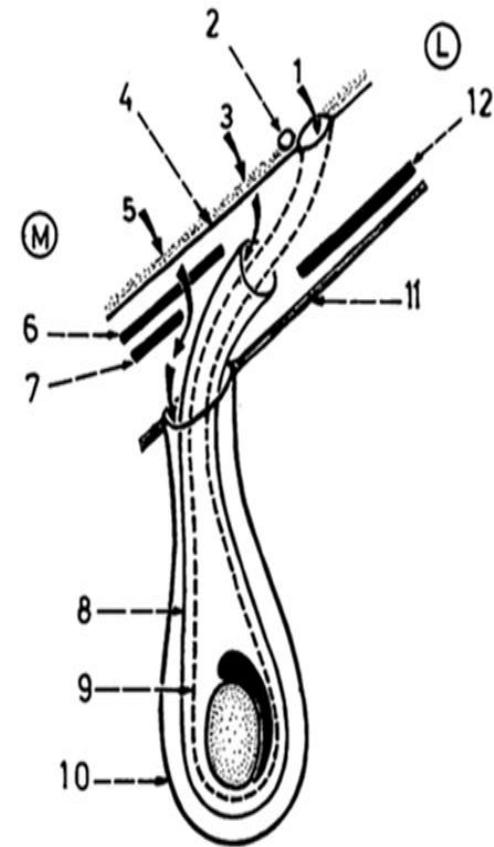
approximate - the 2 crura & closure of superficial ring.

### 5-increased intra abdominal pressure

approximate ant. & post. walls &

closure of canal (because the canal is oblique).

1. deep inguinal ring (site of oblique hernia).
2. inferior epigastric art.
3. site of lateral direct hernia.
4. transversalis fascia.
5. site of medial direct hernia.
6. conjoint tendon.
7. reflected part of inguinal ligament.
8. cremaster muscle and fascia.
9. internal spermatic fascia.
10. external spermatic fascia.
11. anterior wall of inguinal canal.
12. internal oblique muscle.

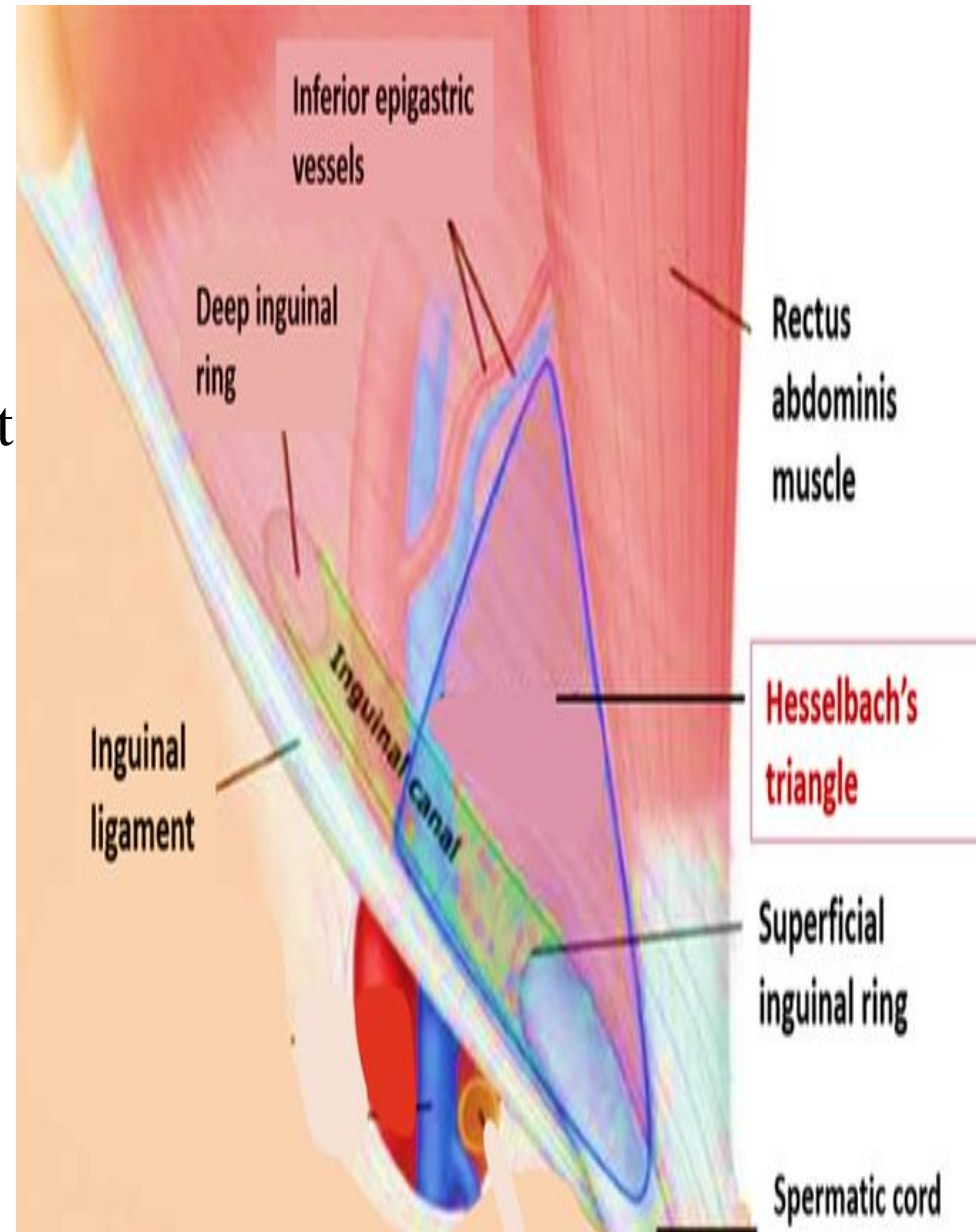


# INGUINAL (HASSELBACH'S) TRIANGLE

## Boundaries:

- medial:** rectus abdominis.
- lateral:** inferior epigastric art.
- base:** inguinal lig.

**surgical importance:** site of direct inguinal hernia.



# INGUINAL HERNIA

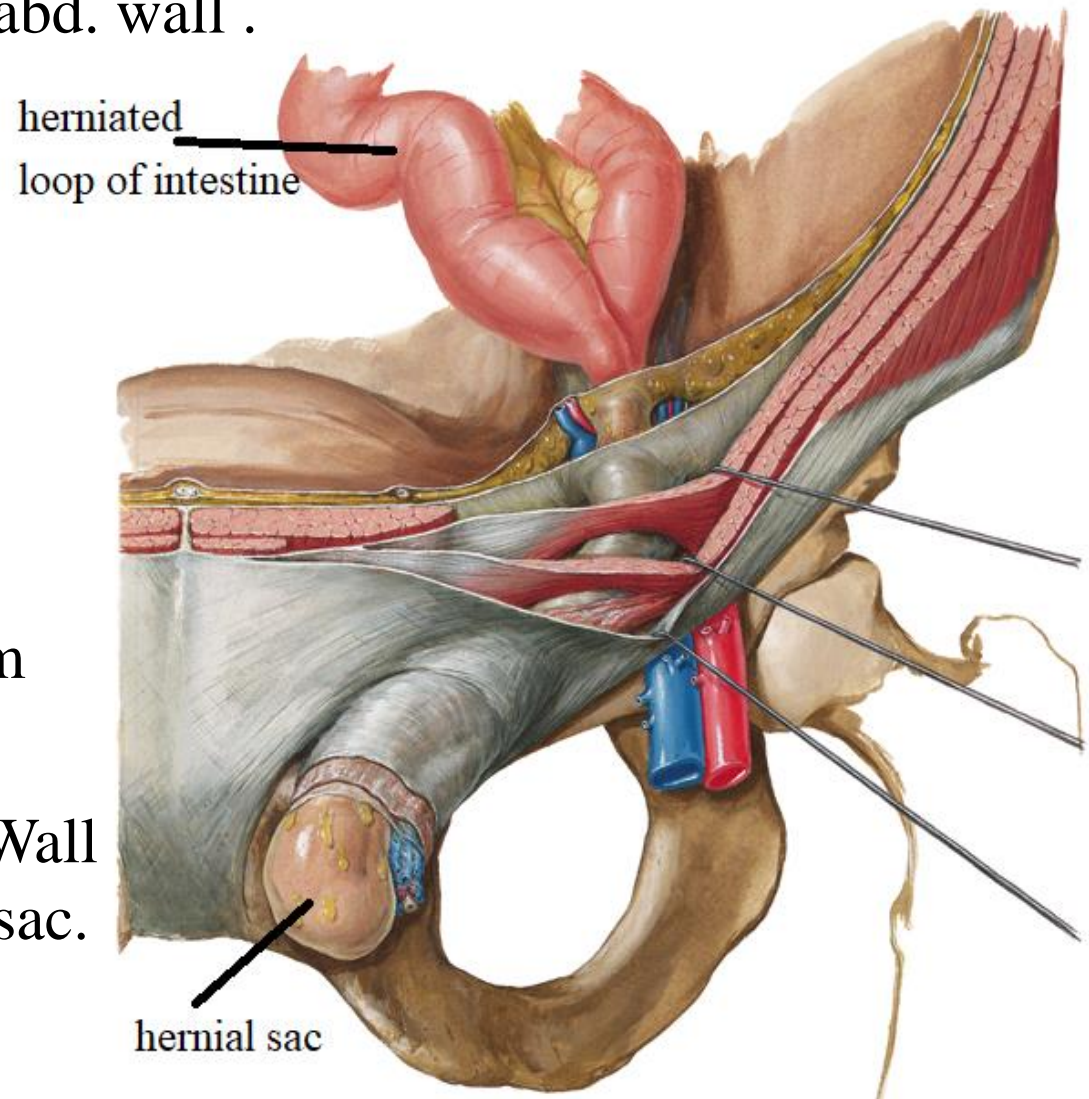
**Def.:** protrusion of an abdominal content through weak point in abd. wall .

## Causes:

- 1-weak abd. muscles
- 2- marked increase in intra-abdominal pressure as raising heavy objects.

## Structure:

- 1-Sac: formed of peritoneum
- 2-Contents: organ.
- 3-Coverings: layers of abd. Wall pushed by the sac.



# INGUINAL HERNIA

## Types:

Oblique(indirect) inguinal hernia

Age:- common in young

## Sac

1-pass through deep inguinal ring lateral to inferior epigastric art.

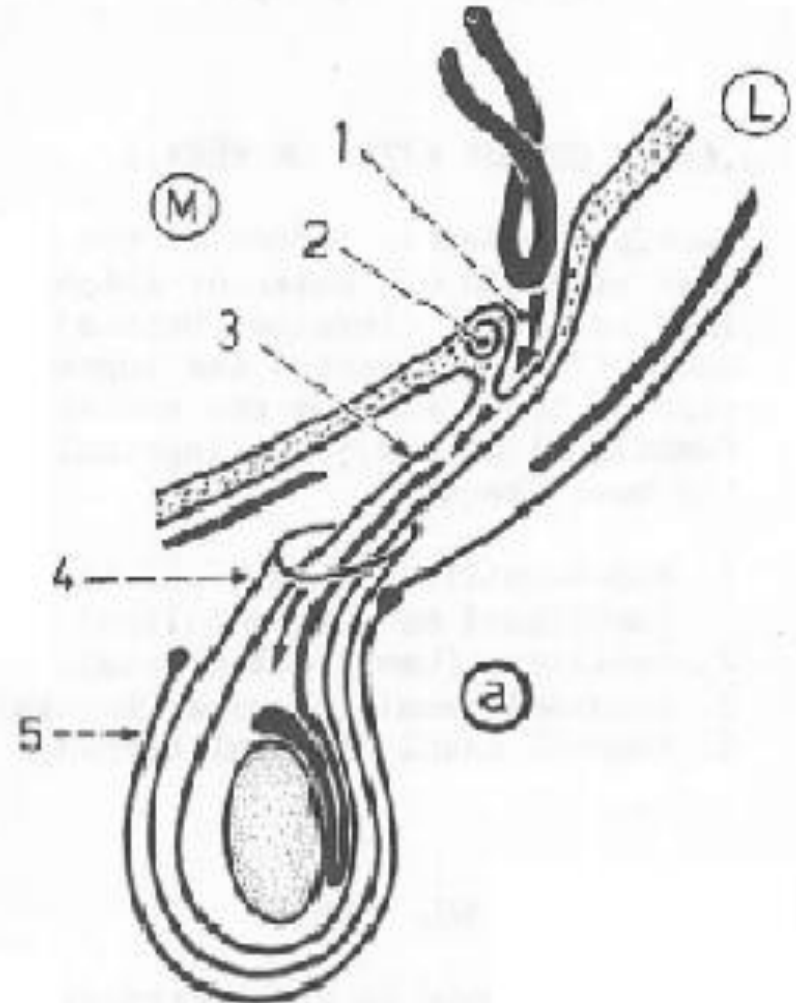
2-ant. to spermatic cord

3-May reach scrotum

## Covering

sac is covered by int. spermatic fascia & cremastic ms and fascia & external spermatic fascia  
not covered by fascia transversalis

1. hernial sac.
2. inferior epigastric artery.
3. internal spermatic fascia.
4. cremaster muscle and fascia.
5. external spermatic fascia.



# INGUINAL HERNIA

## Types:

### Direct inguinal hernia

Age:- common in old age

### Sac

1-pass through inguinal triangle

Medial to inferior epigastric art.

2-posterior to spermatic cord

3-Doesn't reach scrotum

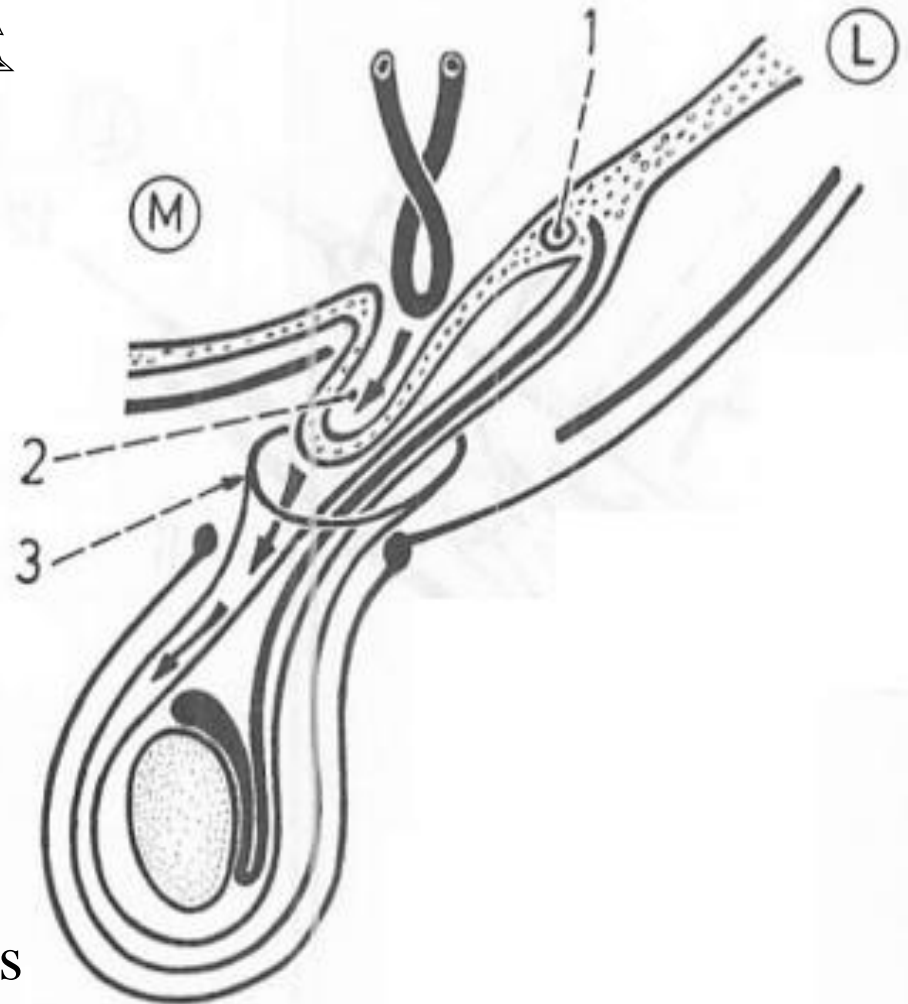
### Covering

sac is covered by fascia transversalis

& cremasteric ms and fascia

& external spermatic fascia

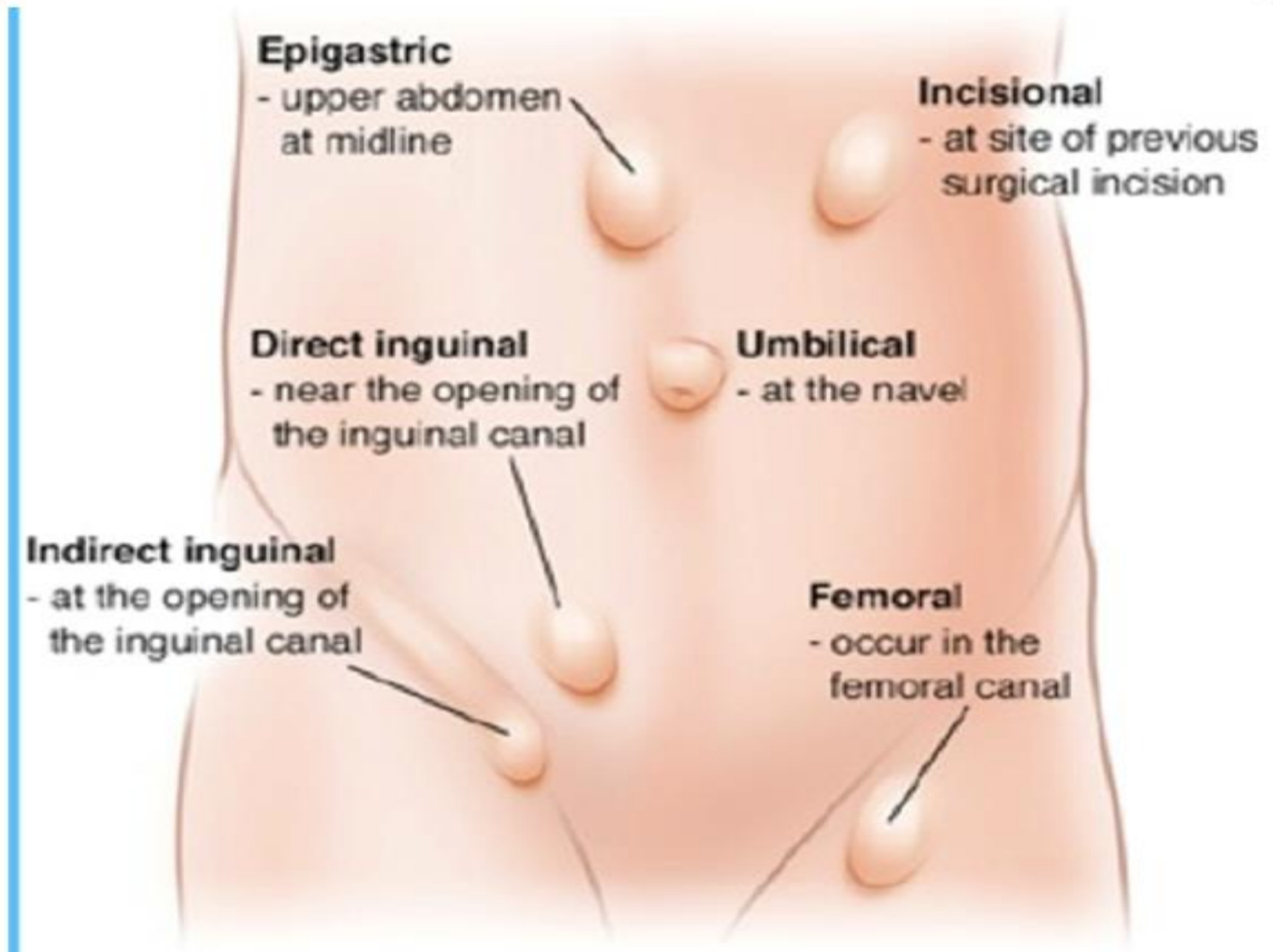
not covered by internal spermatic fascia



1. inferior epigastric artery.
2. hernial sac.
3. cremaster muscle and fascia.



# OTHER TYPES OF HERNIA



THANQ