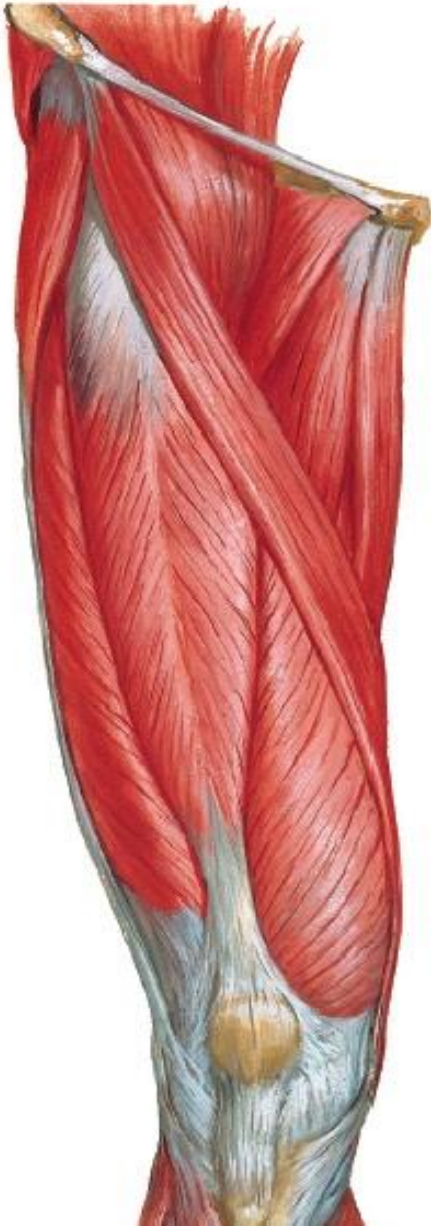


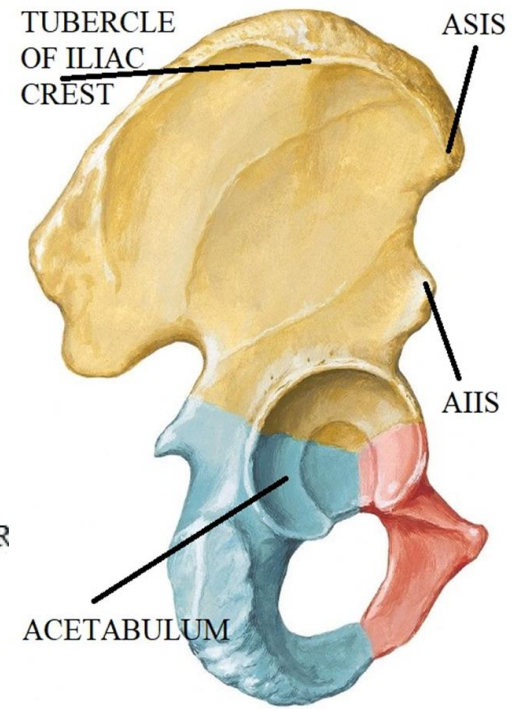
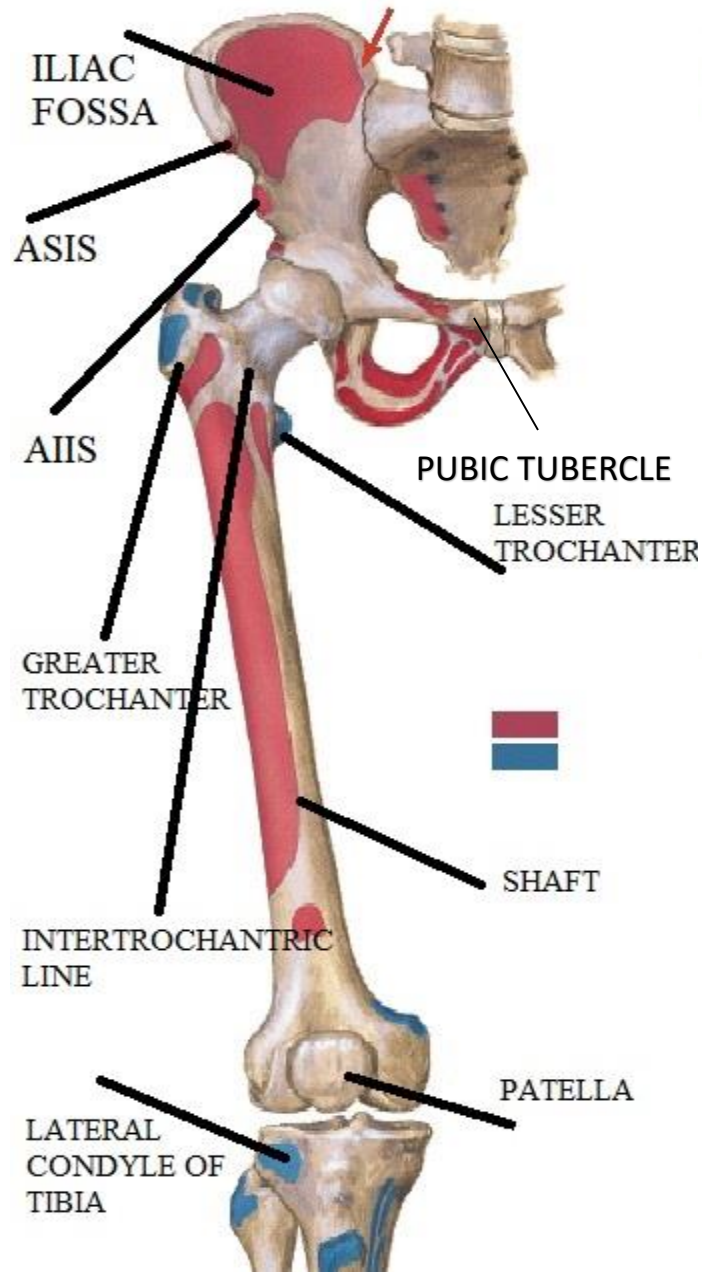
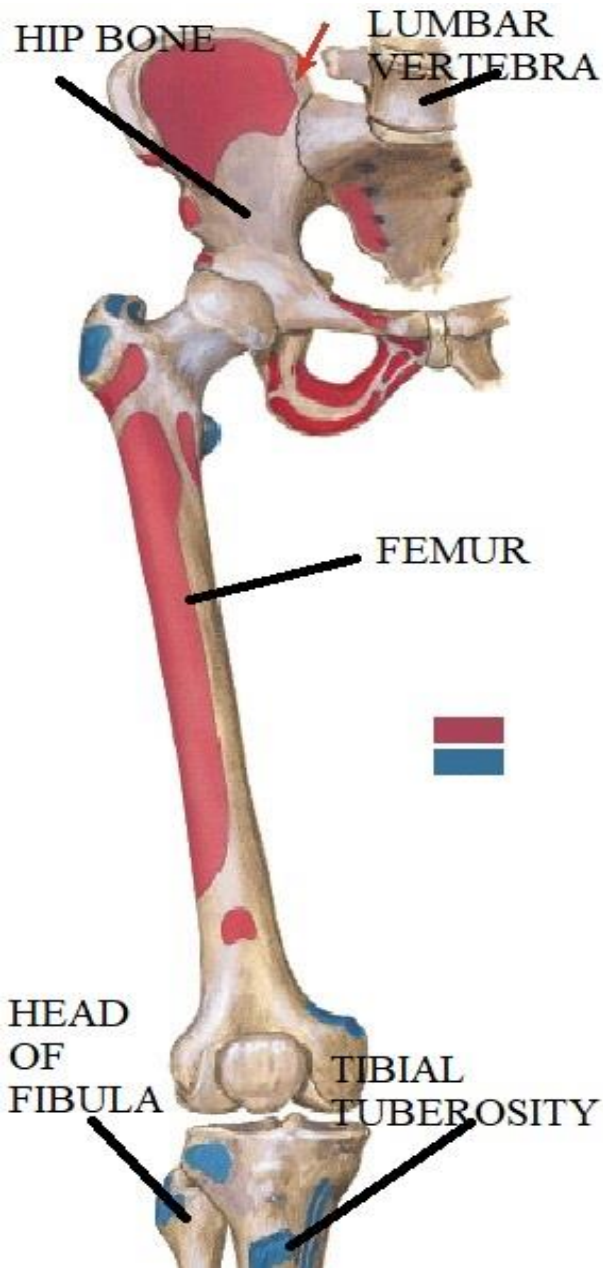
FRONT OF THE THIGH



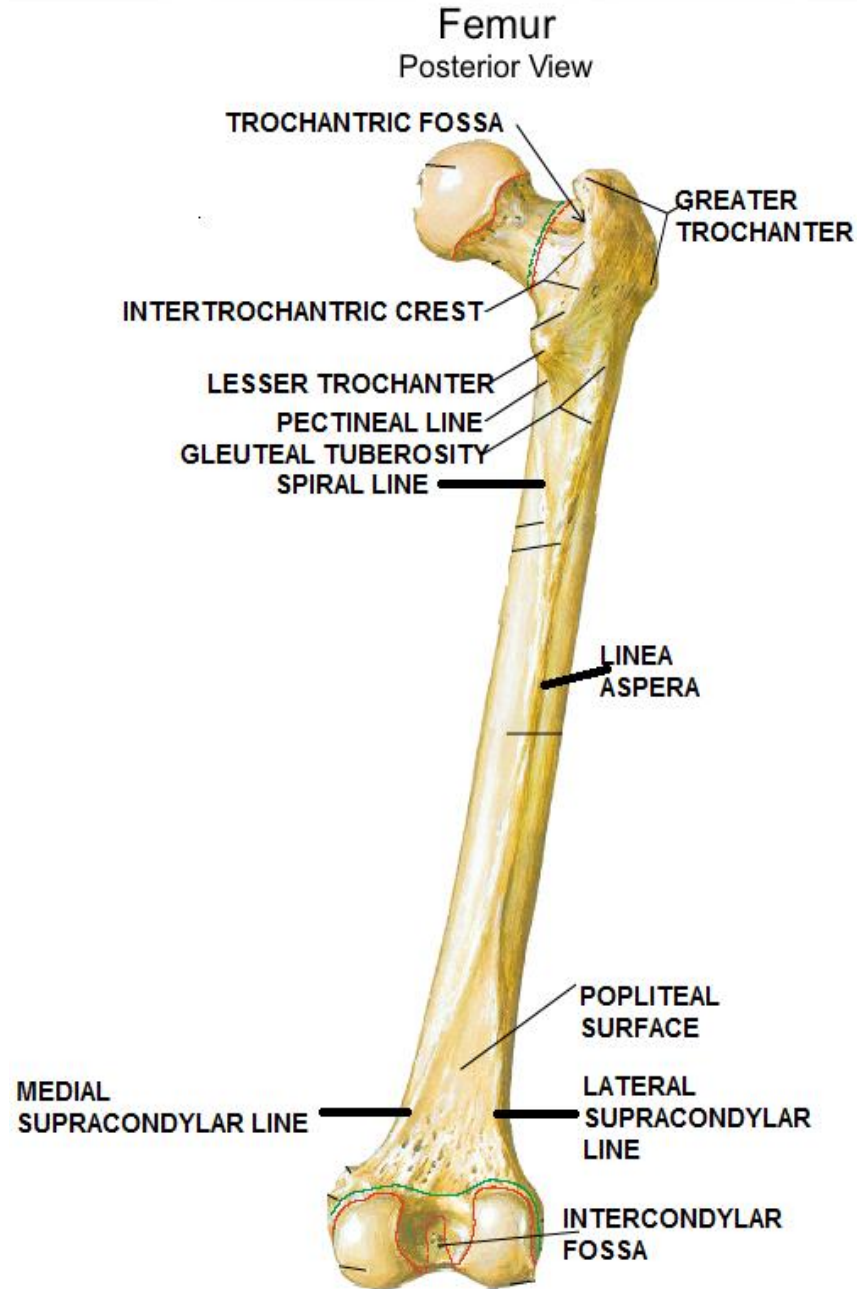
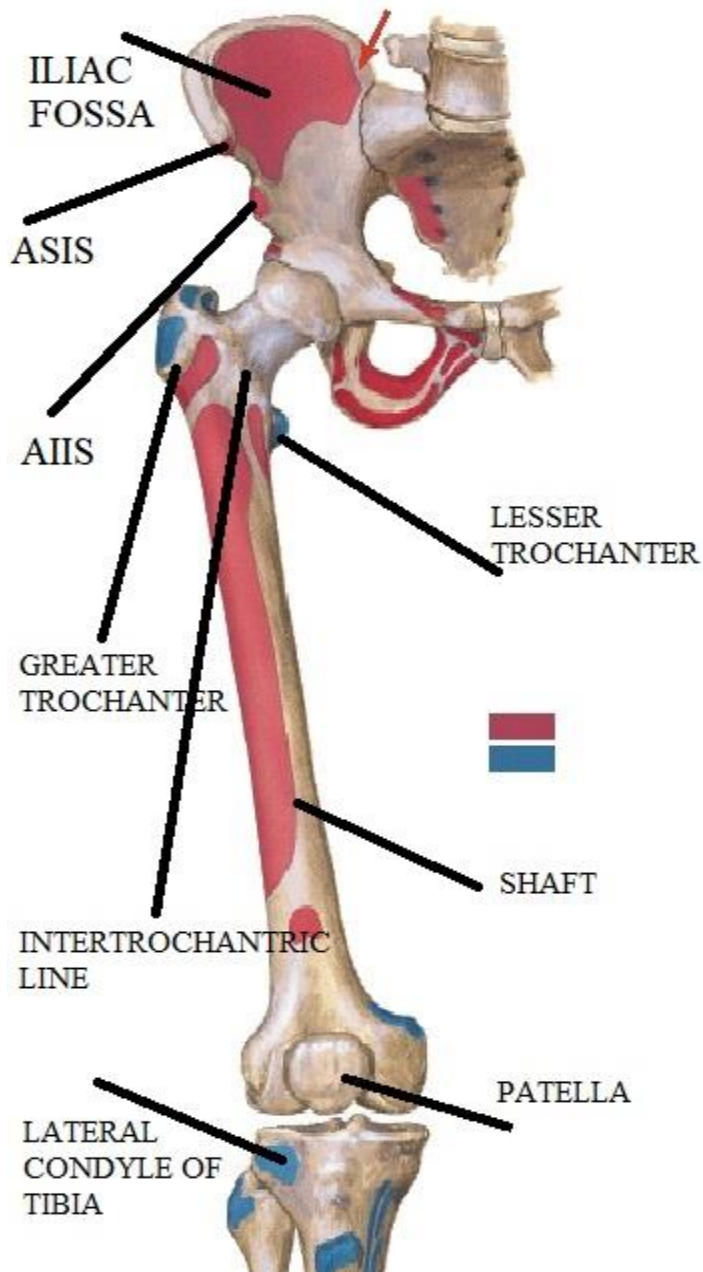
BY

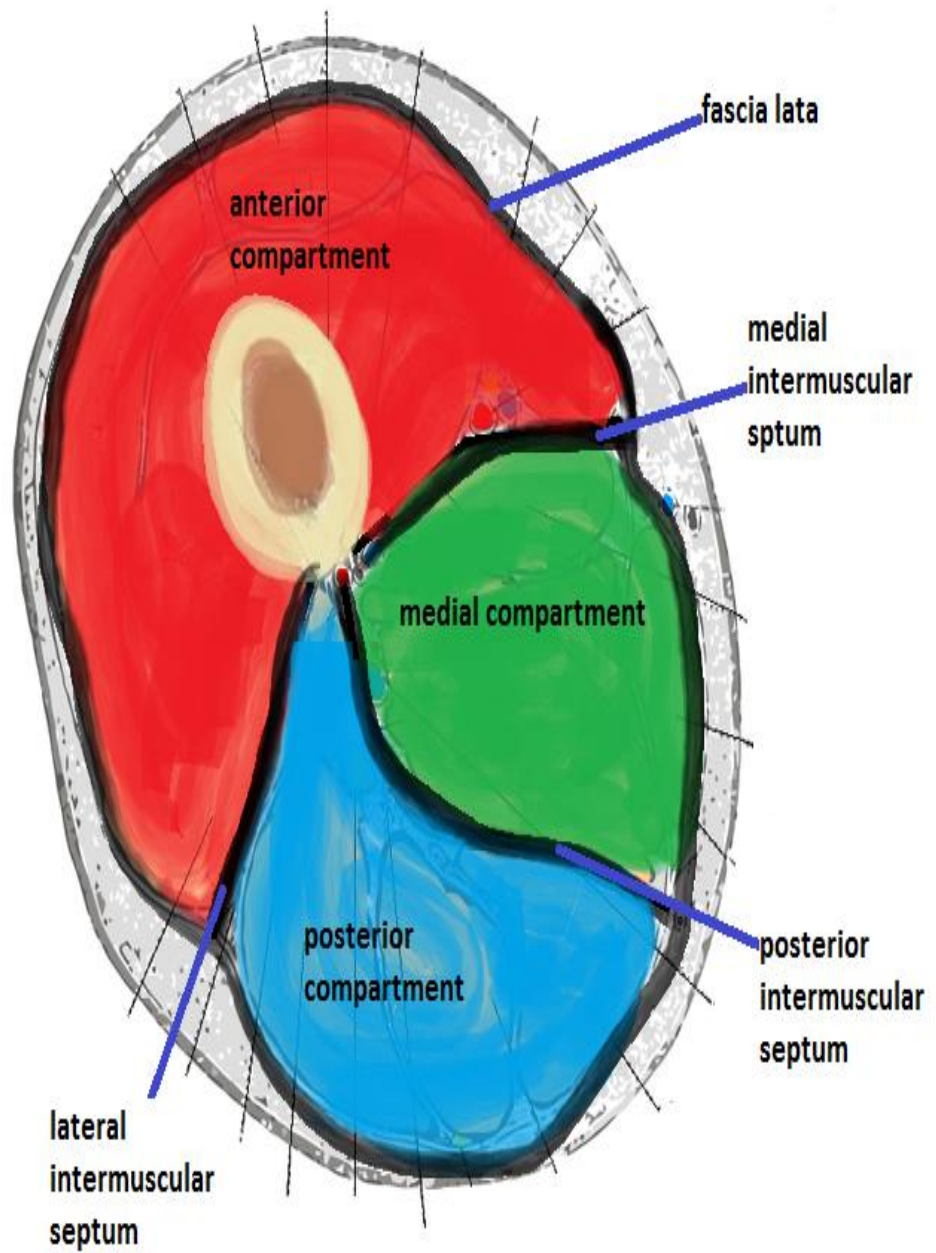
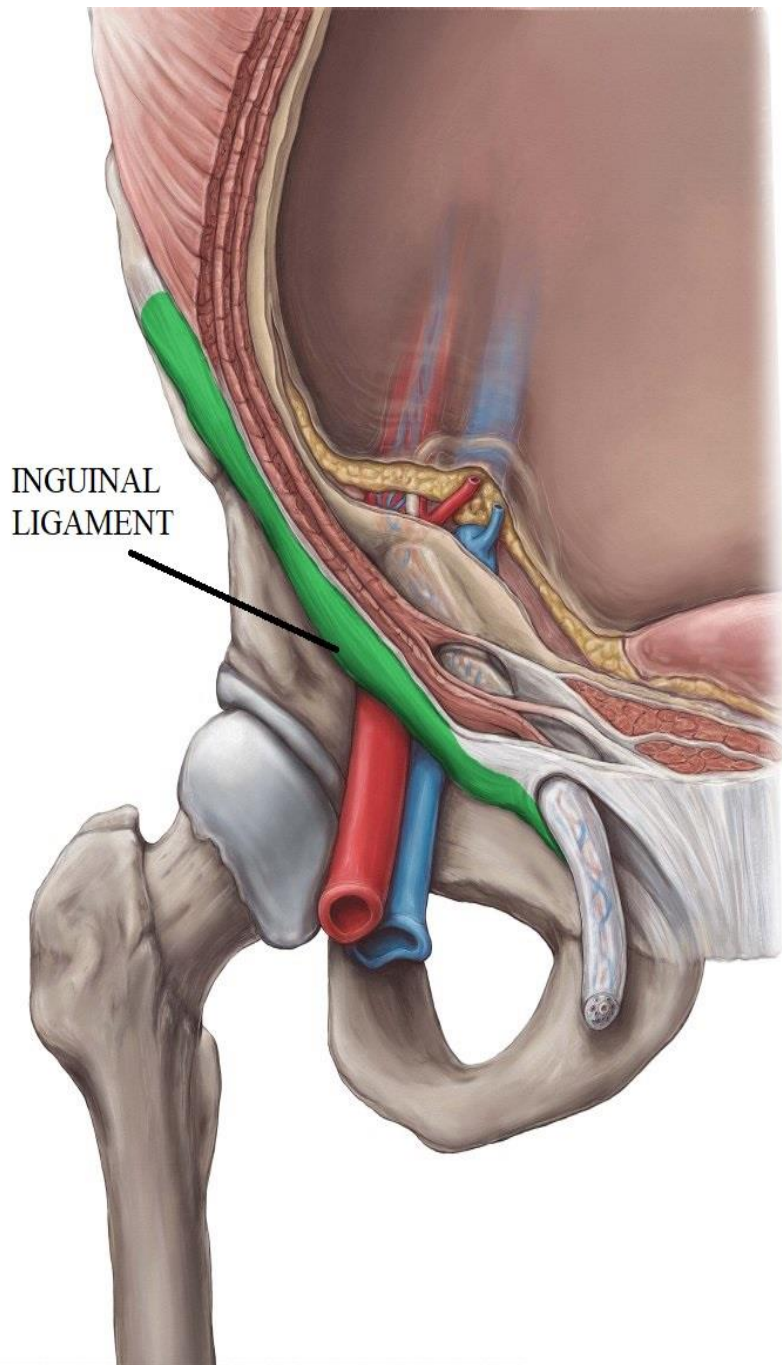
DR ABULMAATY MOHAMED
ASSISTANT PROFESSOR
ANATOMY & EMBRYOLOGY
MUTAH UNIVERSITY

SKELETON



SKELETON





SUPERFICIAL FASCIA OF THE THIGH

Contents:

A-cutaneous nerves:

1-Ilio inguinal n.:-

From the lumbar plexus

Supply the skin below medial part of inguinal ligament

2-Femoral br. of genitofemoral n.:-

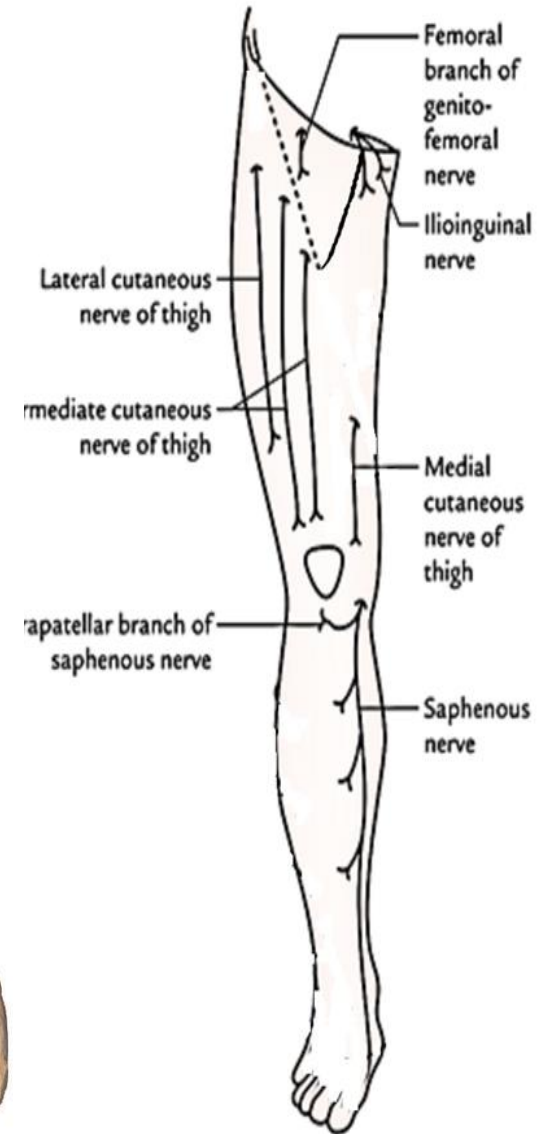
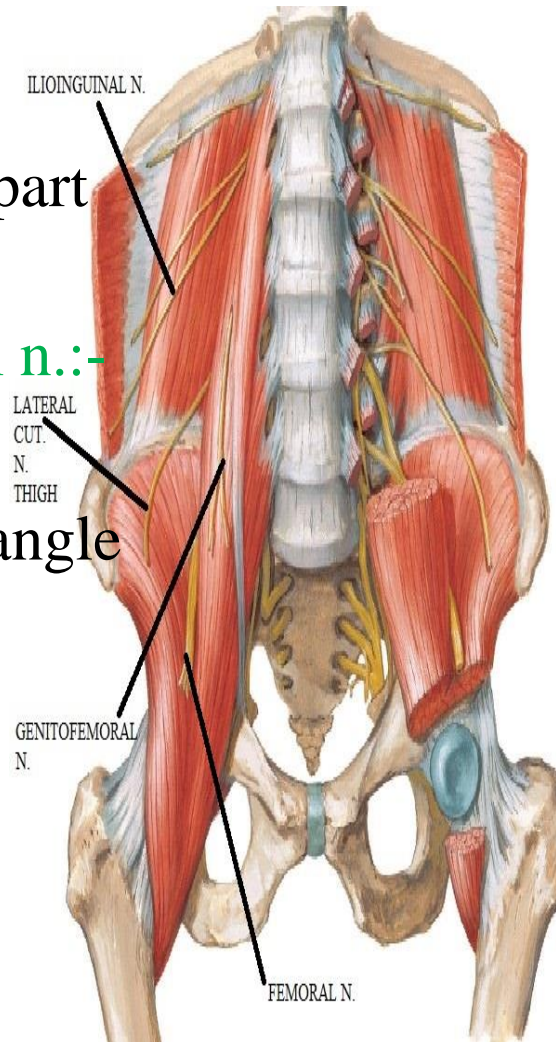
From the lumbar plexus

Supply the skin of femoral triangle

3-Lateral cut. n. of thigh :-

From the lumbar plexus

Supply the skin of lateral side of thigh & knee



SUPERFICIAL FASCIA OF THE THIGH

Contents:

A-cutaneous nerves:

4-Intermediate cut. n. of thigh:-

From the femoral nerve

Divide into 2 branches

Supply the skin of front of thigh

5-Medial cut. n. of thigh :-

From the femoral nerve

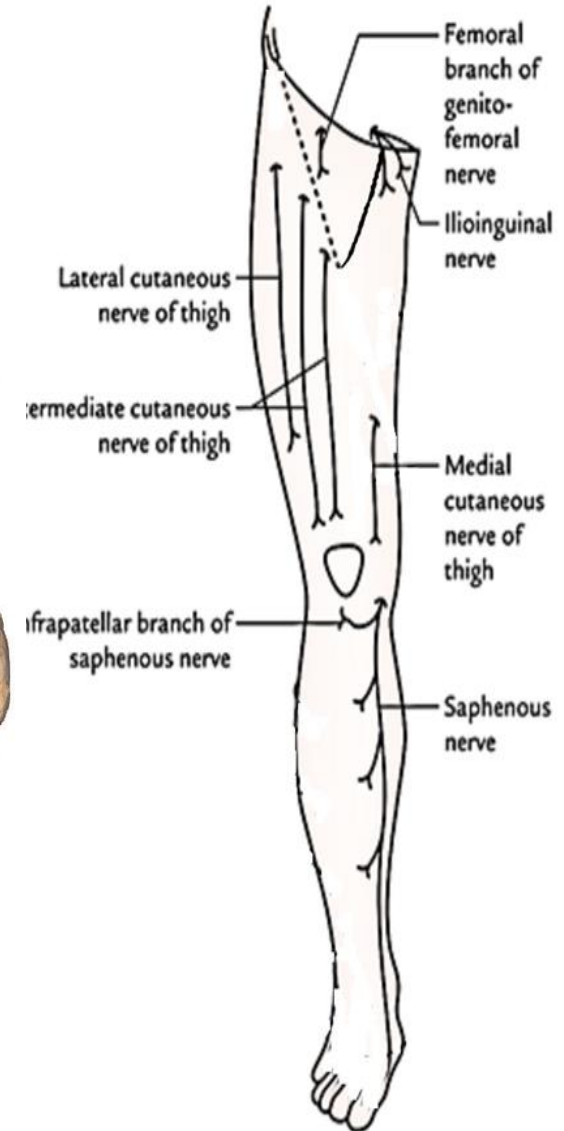
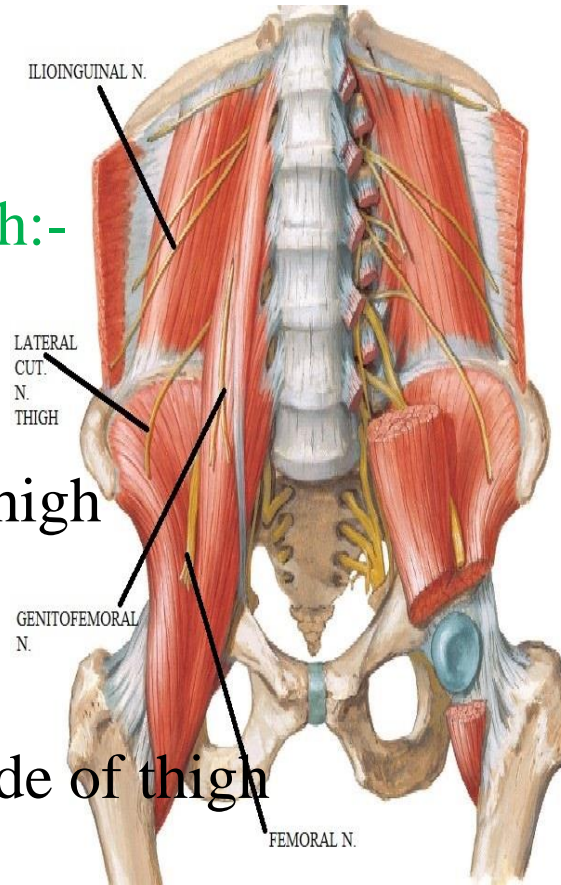
Supply the skin of medial side of thigh

N.B.:- Patellar plexus:

Site: - In front of knee

Formation: - terminal branches of lateral, intermediate, medial cut. Nerves of Thigh

Plus infrapatellar branch of saphenous nerve



SUPERFICIAL FASCIA OF THE THIGH

Contents:

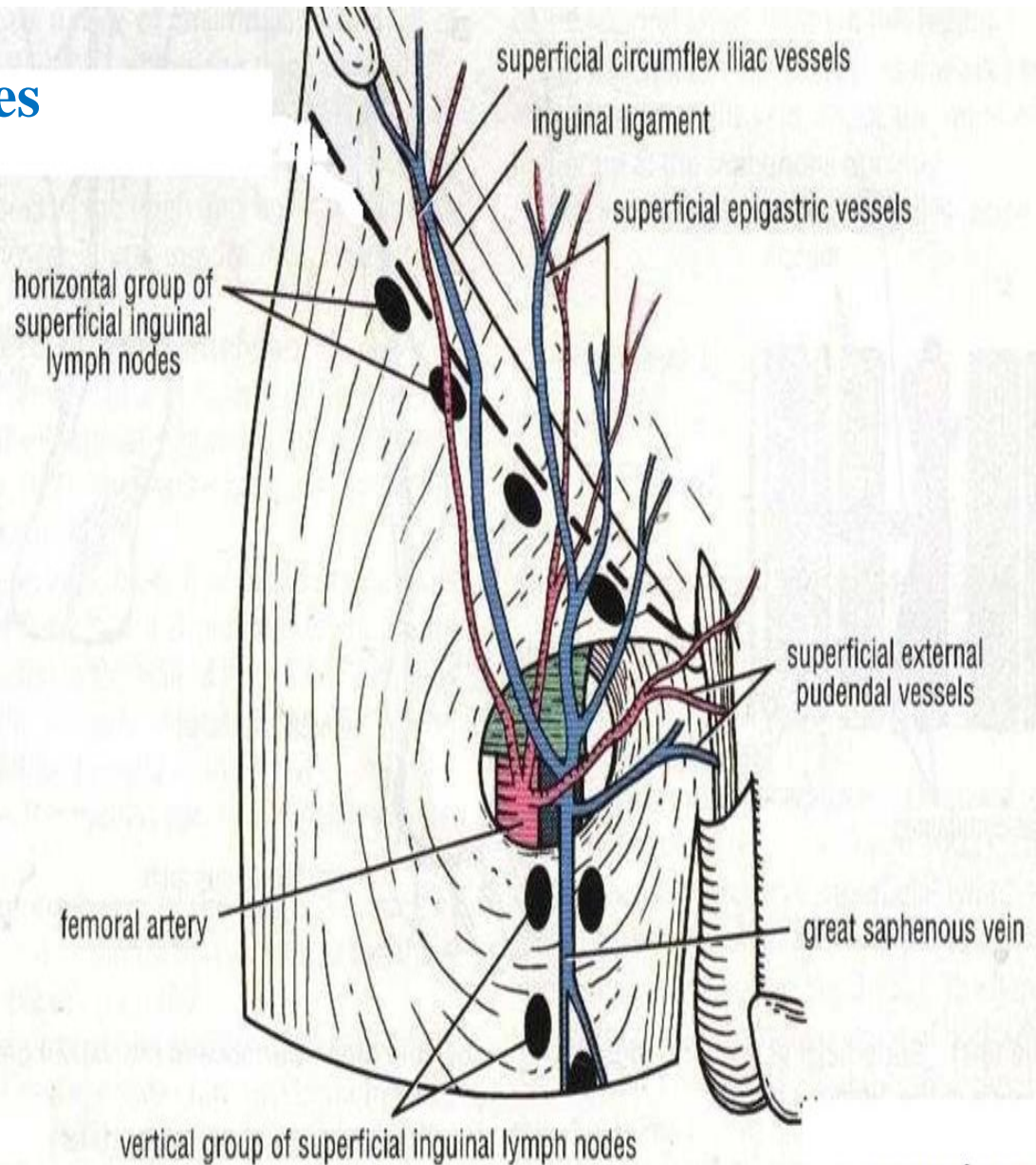
B-superficial inguinal arteries

- 1-Superficial ext. pudendal
- 2-superficial epigastric
- 3-Superficial circumflex iliac

C- Superficial inguinal veins

- 1-Superficial ext. pudendal
- 2-superficial epigastric
- 3-Superficial circumflex iliac
- 4-& great saphenous v

D- superficial inguinal LNs



DEEP FASCIA OF THE THIGH (FASCIA LATA)

Special features :

A-saphenous opening :

Def.: oval opening in deep fascia

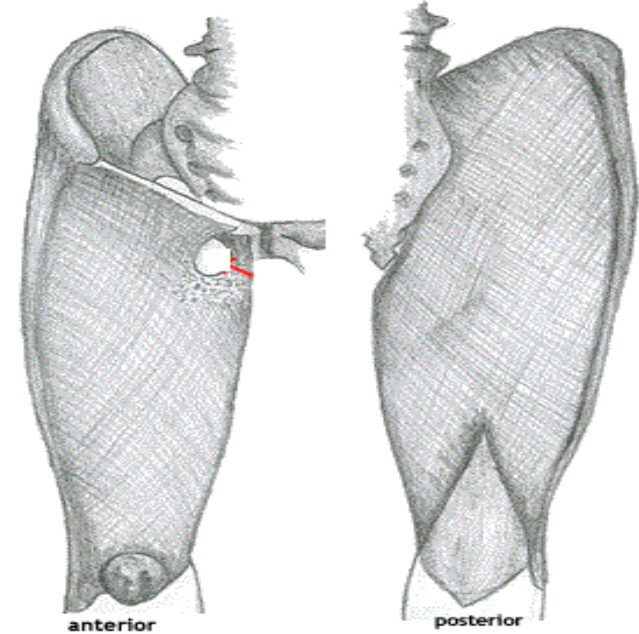
4 cm below & lateral to pubic tubercle.

pierced by:

1- Superficial inguinal arteries??

2- Great saphenous V.

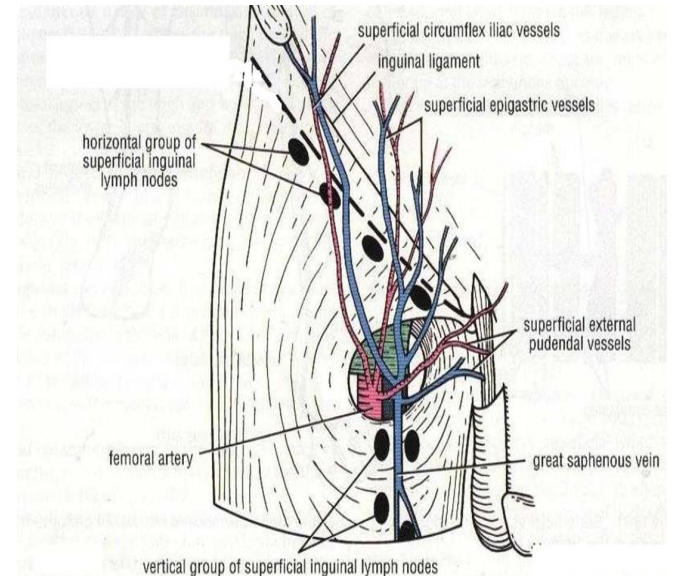
3-lymphatics from superficial to deep inguinal LN.



anterior

posterior

fascia lata



vertical group of superficial inguinal lymph nodes

DEEP FASCIA OF THE THIGH (FASCIA LATA)

Special features :

B-iliotibial tract:

Def.: thickened deep fascia of lateral side of thigh

Attachment:

Above: tubercle of iliac crest

Below: front of lateral tibial condyle

head of fibula

lateral side of patella

capsule of knee joint

Attached structures:

1-tensor fascia lata : ant. border

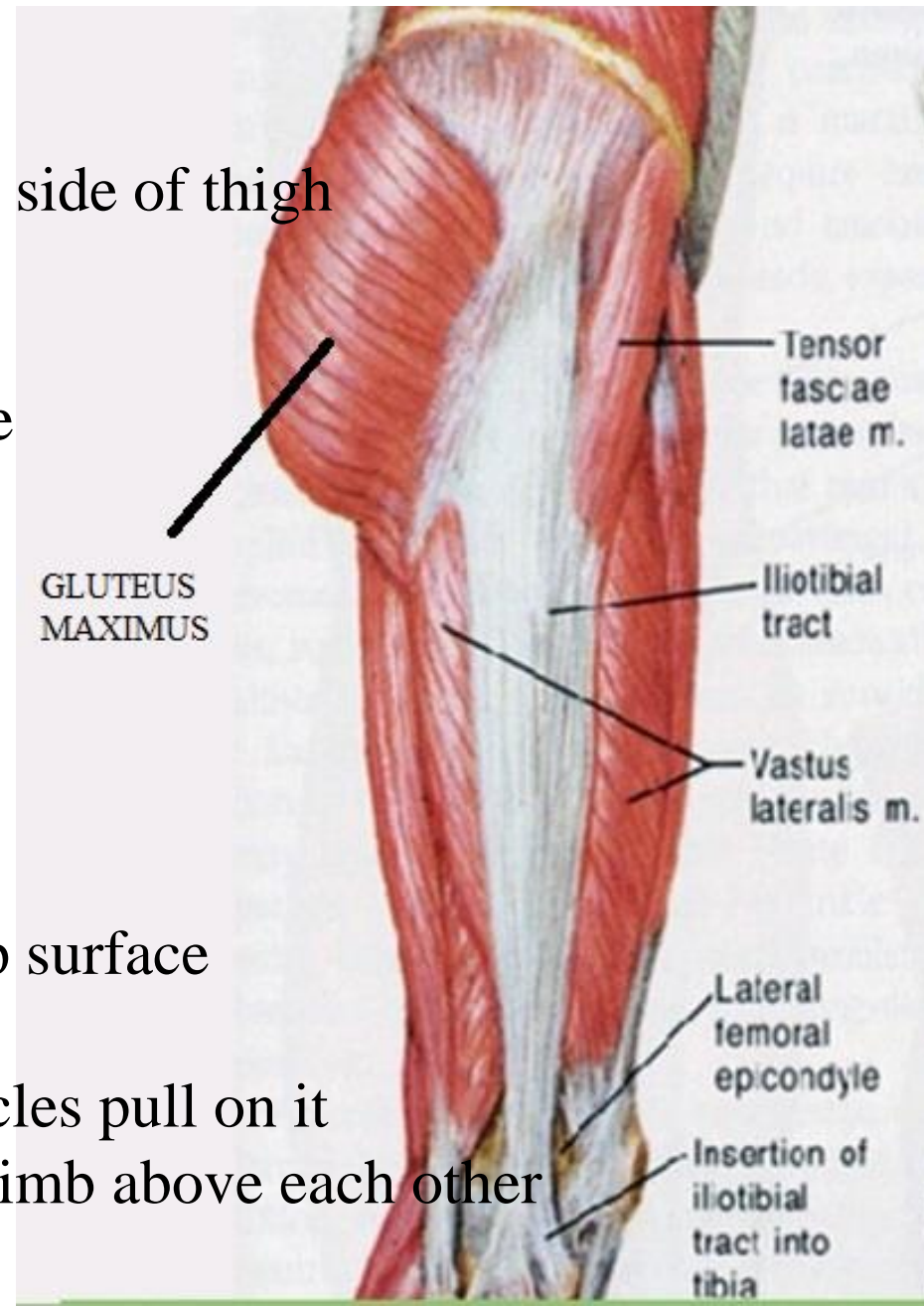
2-gluteus Maximus: post. border

3-lateral intermuscular septum: deep surface

Function:

In standing position the above muscles pull on it

→ Tense → keep bones of lower limb above each other



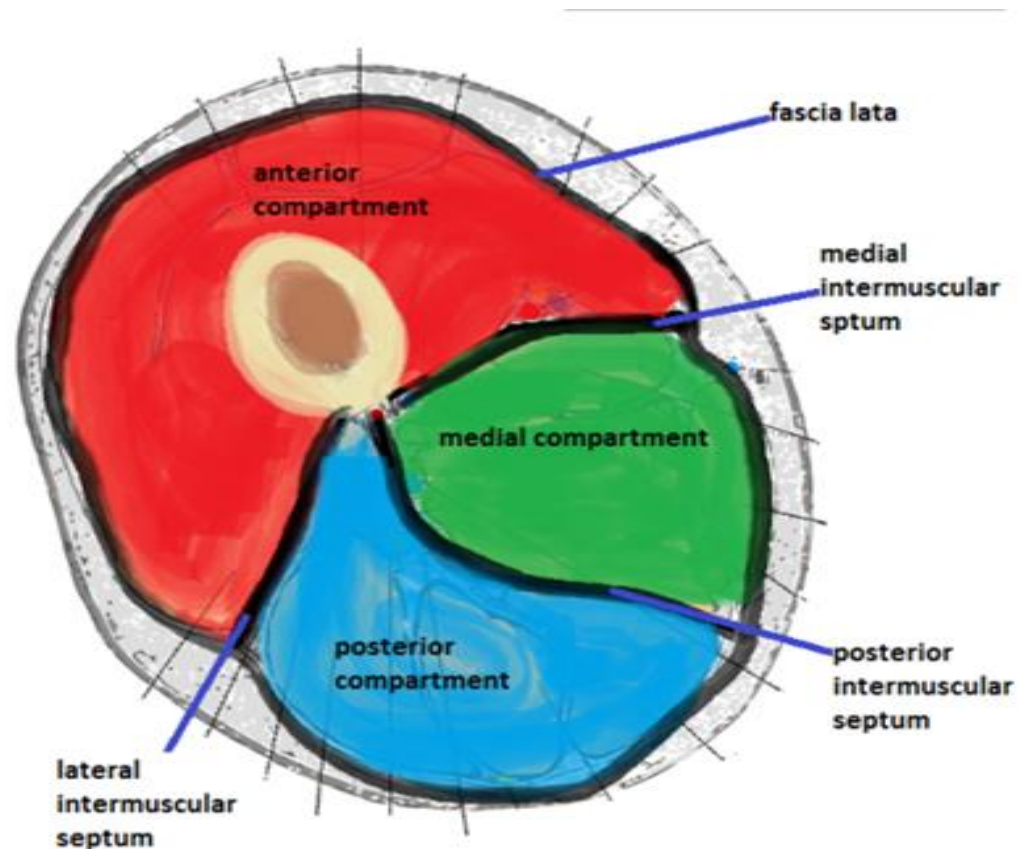
DEEP FASCIA OF THE THIGH (FASCIA LATA)

Special features :

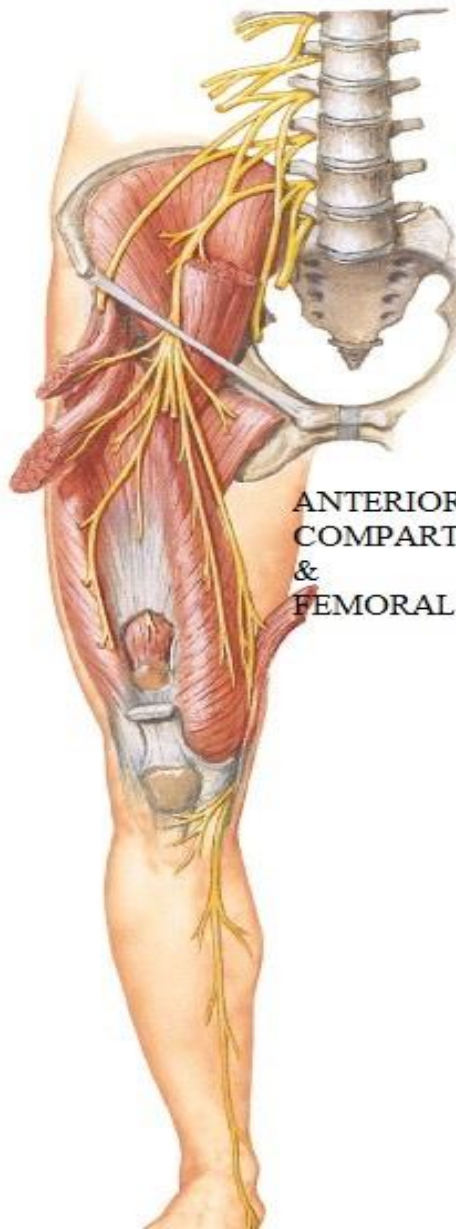
C-inter muscular septa:

-medial, lateral, post. → linea aspera of femur

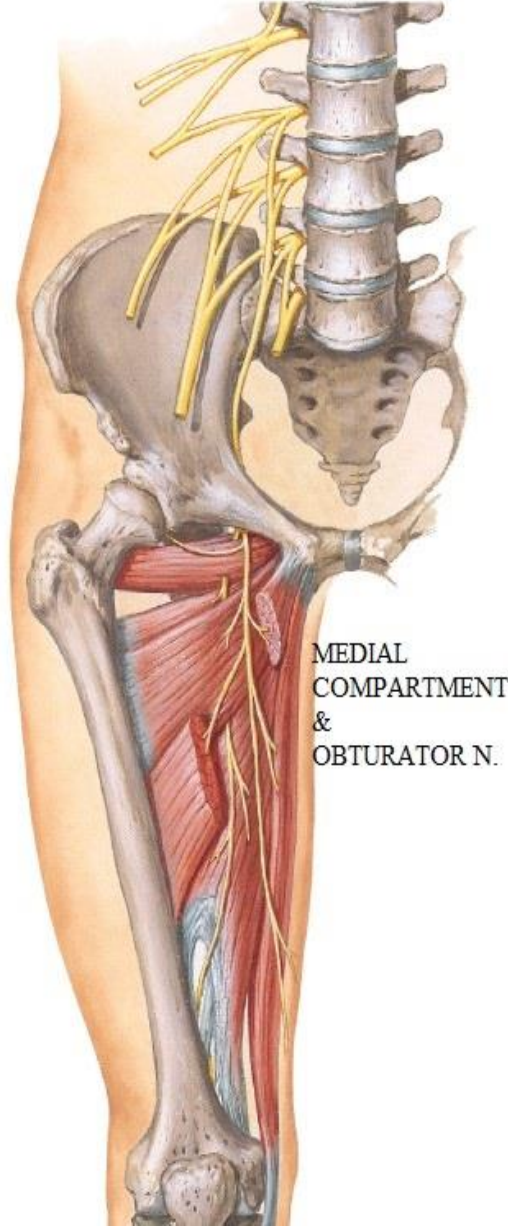
-divide thigh into ant. , medial, post. Compartments



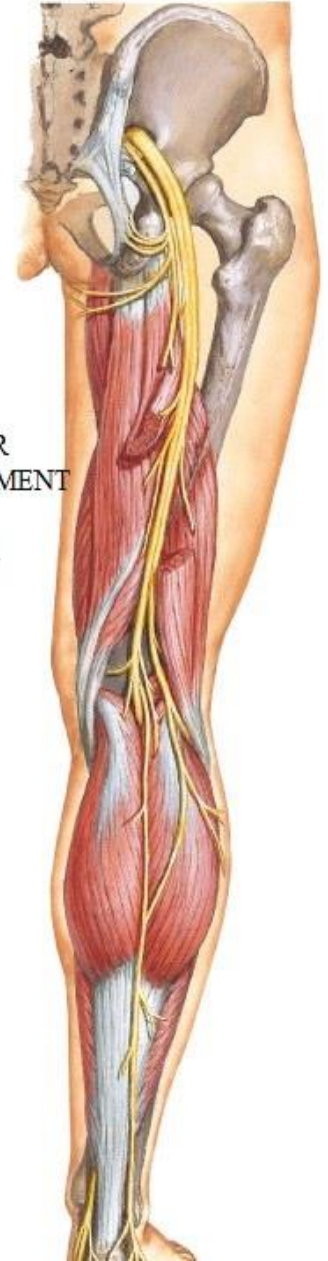MUSCLES OF THE THIGH



ANTERIOR
COMPART
&
FEMORAL



MEDIAL
COMPARTMENT
&
OBTURATOR N.



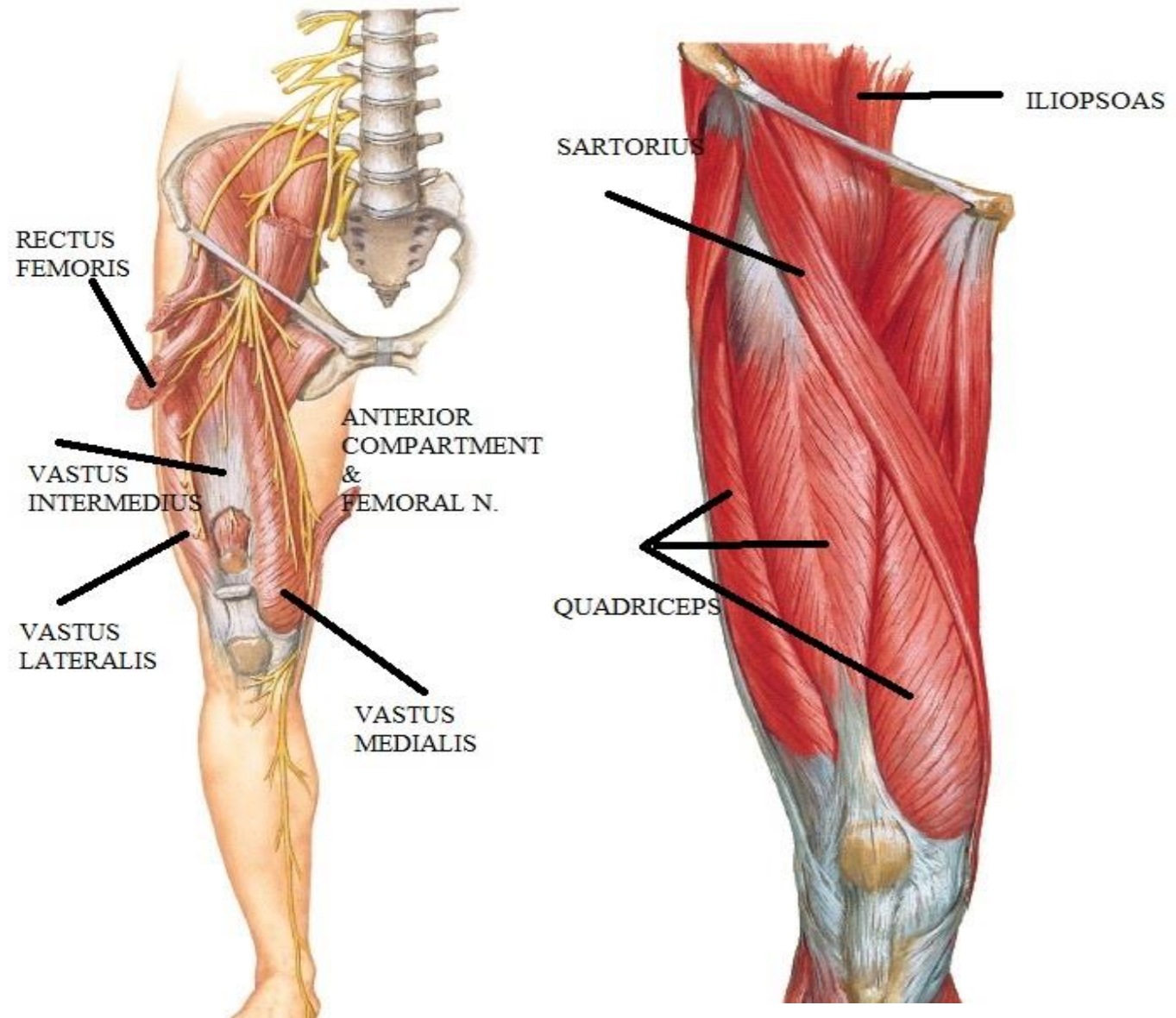
POSTERIOR
COMPARTMENT
&
SCIATIC N.

MUSCLES OF THE ANTERIOR COMPARTMENT

1-QUADRICEPS FEMORIS:- largest muscle in the body

2- ILIOPSOAS

3- SARTORIUS



MUSCLES OF THE ANTERIOR COMPARTMENT

QUADRICEPS FEMORIS

Origin: 4 heads

Vastus intermedius:

upper 2/3 of ant. & lateral surfaces of shaft of femur

Vastus medialis :

lower part of inter trochanteric line

Spiral line

Linea aspera

Medial supracondylar line

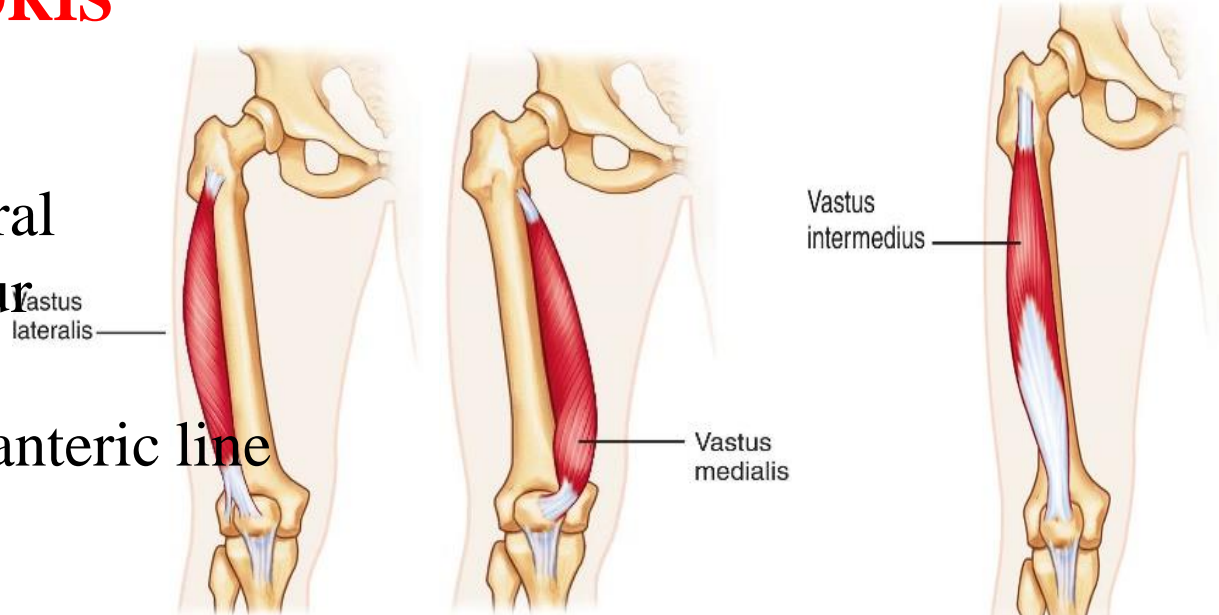
Vastus lateralis :

upper part of inter trochanteric line

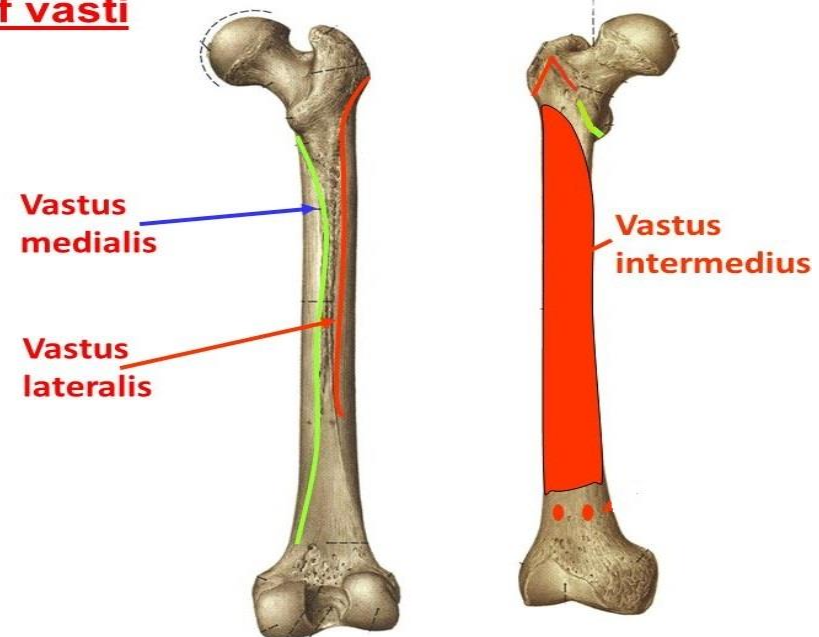
Root of greater trochanter

Gluteal tuberosity

Linea aspera



Origin of vasti



MUSCLES OF THE ANTERIOR COMPARTMENT

QUADRICEPS FEMORIS

Origin: 4 heads

Rectus femoris:

straight head: ant. inf. iliac spine

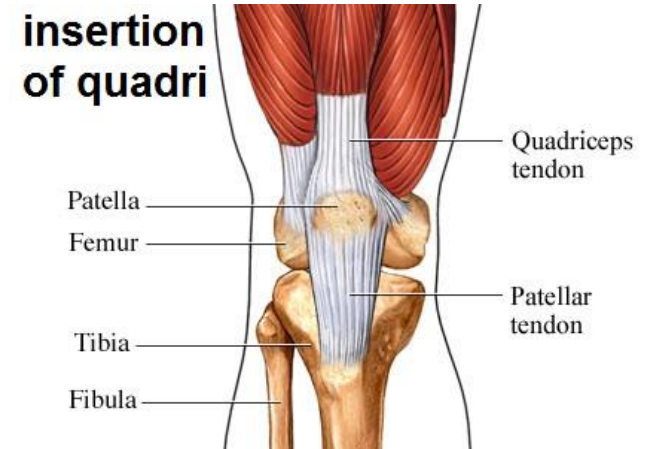
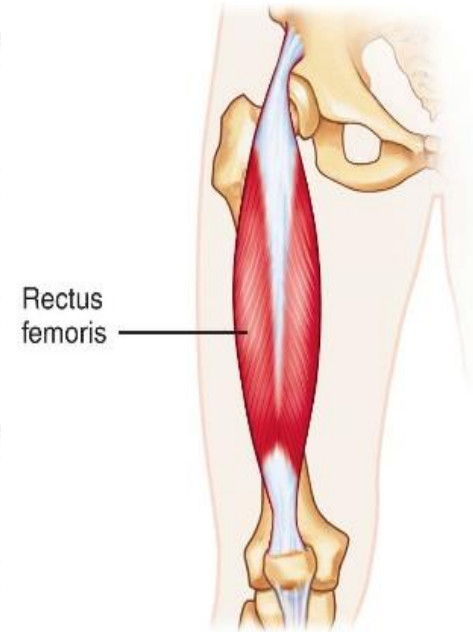
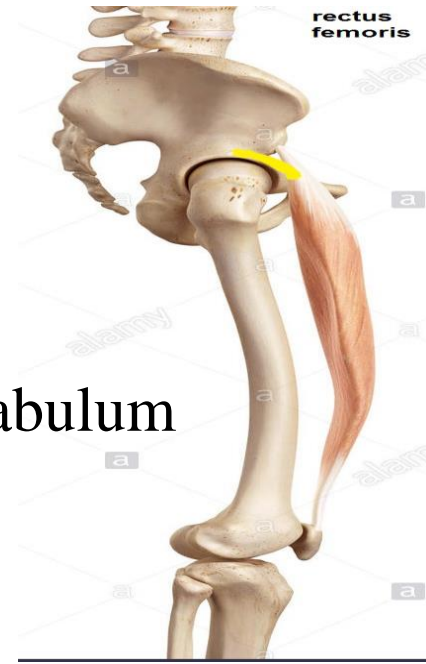Reflected head: groove above acetabulum
(in the ileum)

Insertion:

-base of patella

and lower fibers of vastus medialis & lateralis insert in sides of patella

-ligamentum patellae transmit insertion
from apex of patella to tibial tuberosity.



MUSCLES OF THE ANTERIOR COMPARTMENT

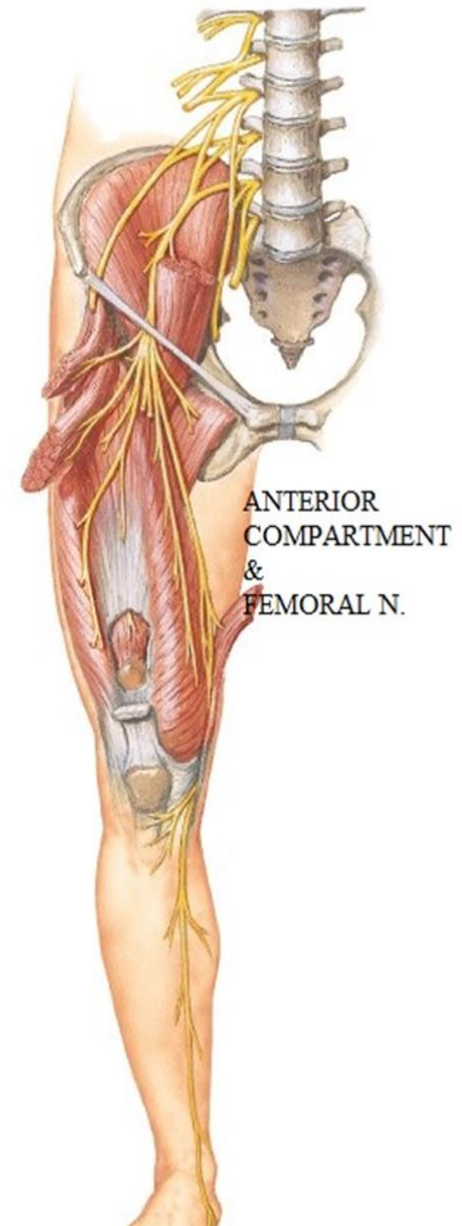
QUADRICEPS FEMORIS

Action

- all the muscle: main extensor of knee
- fibers of medialis & lateralis that attach to sides of patella stabilize it during contraction of quadriceps.
- Rectus femoris: flexion of hip joint

N.S: Femoral n. br. to each head

all heads of quadriceps



MUSCLES OF THE ANTERIOR COMPARTMENT

ILIOPSOAS

Origin:-

Iliacus :- Iliac fossa

psoas major:

T 12 & lumbar vertebrae:
sides of bodies & transverse
processes

I.:-

Lesser trochanter

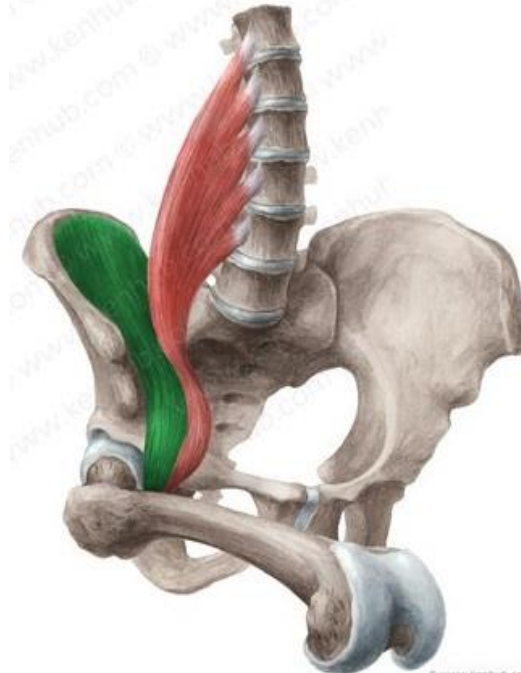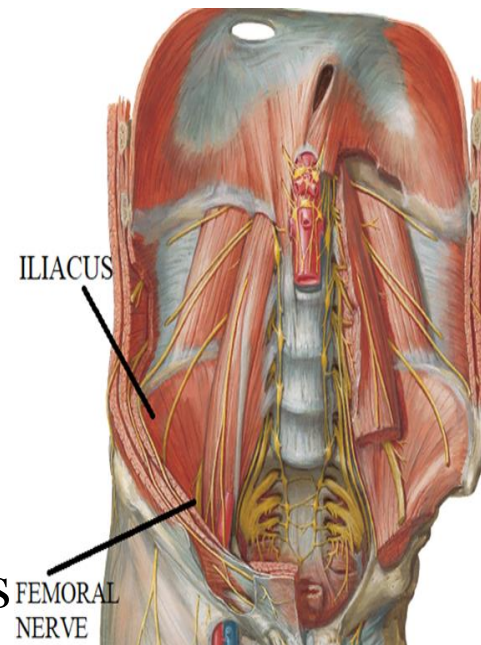
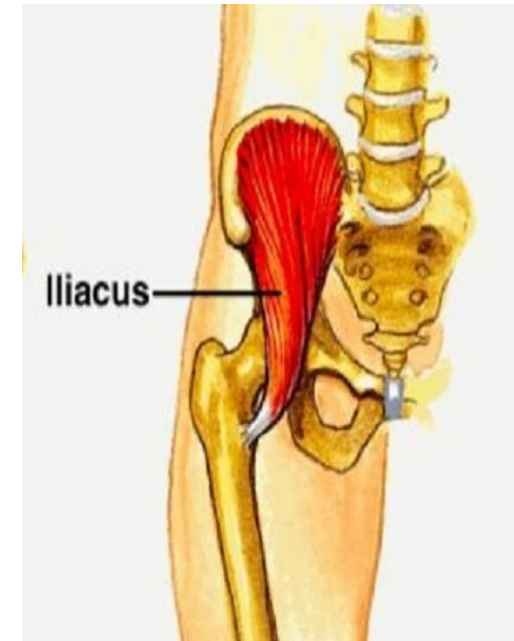
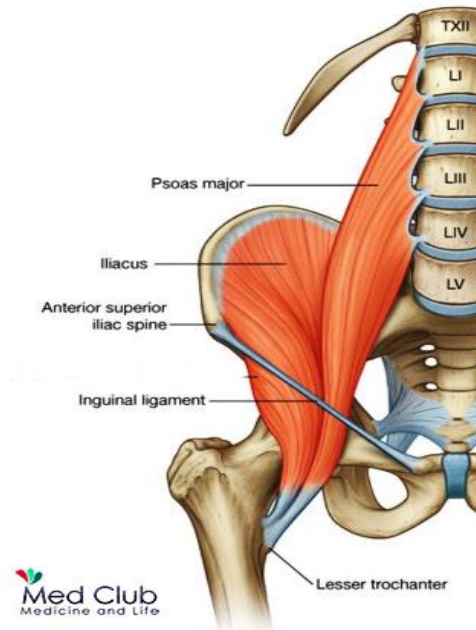
A.:-

Flexion &
lateral rotation of thigh

N.S.:-

Iliacus :- femoral nerve

PSOAS MAJOR Lumbar plexus



MUSCLES OF THE ANTERIOR COMPARTMENT

Sartorius

Origin:-

Ant. superior iliac spine (ASIS)

Insertion:-

upper part of medial surface of tibia

Action:-

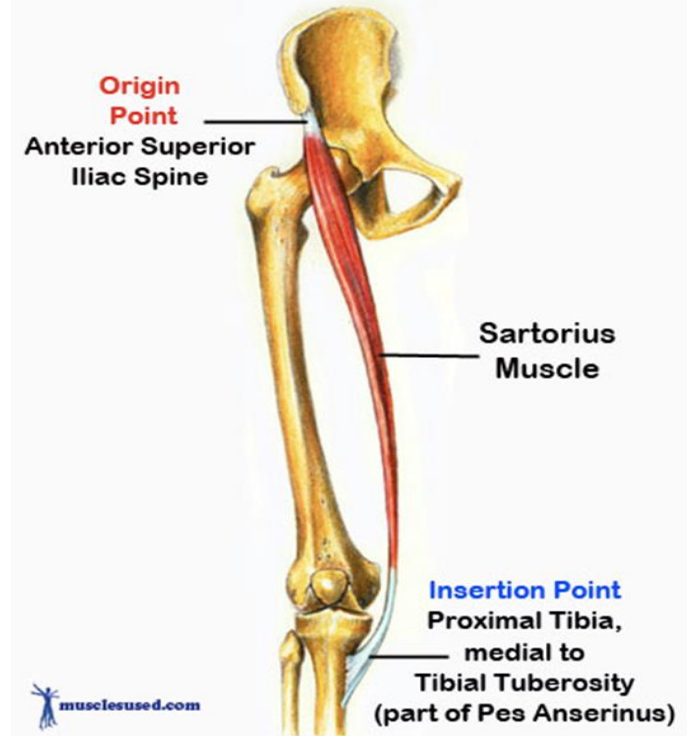
sartor's (cross leg)

- (tailor's) Position :
flexion , medial rotation of knee & flexion & abduction & lateral rotation of hip

- guy rope : support pelvis above femur

N.S.:-

femoral n.



MUSCLES OF THE ANTERIOR COMPARTMENT

Sartorius

The sartorius and the muscles of the pes anserinus

Patrice Thiriet

Realisation : Olivier Rastello



THANQ

