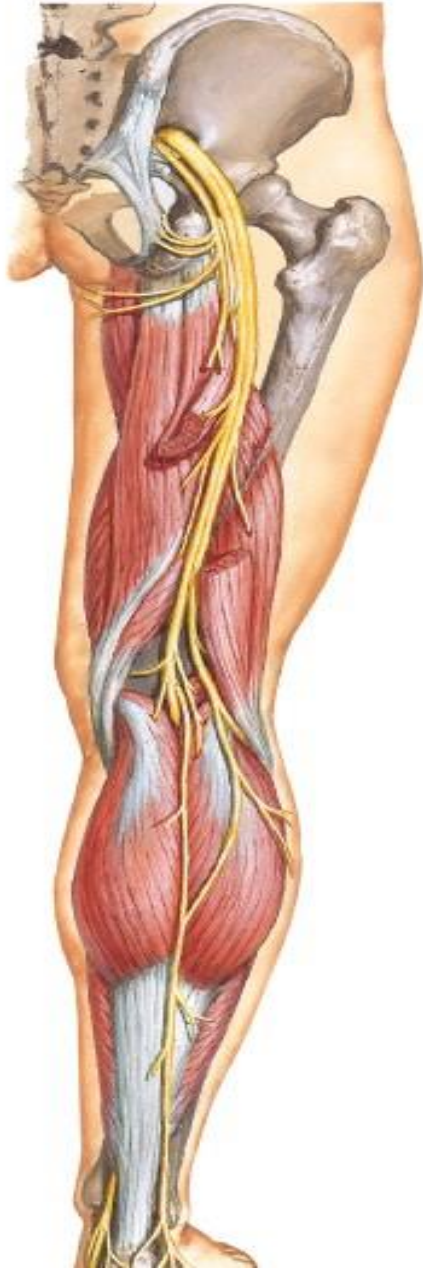

# SACRAL PLEXUS , SCIATIC , PCNT



BY

DR ABULMAATY MOHAMED  
ASSISTANT PROFESSOR  
ANATOMY & EMBRYOLOGY  
MUTAH UNIVERSITY

# SACRAL PLEXUS

**Site:** - in front of piriformis

## **Formation:-**

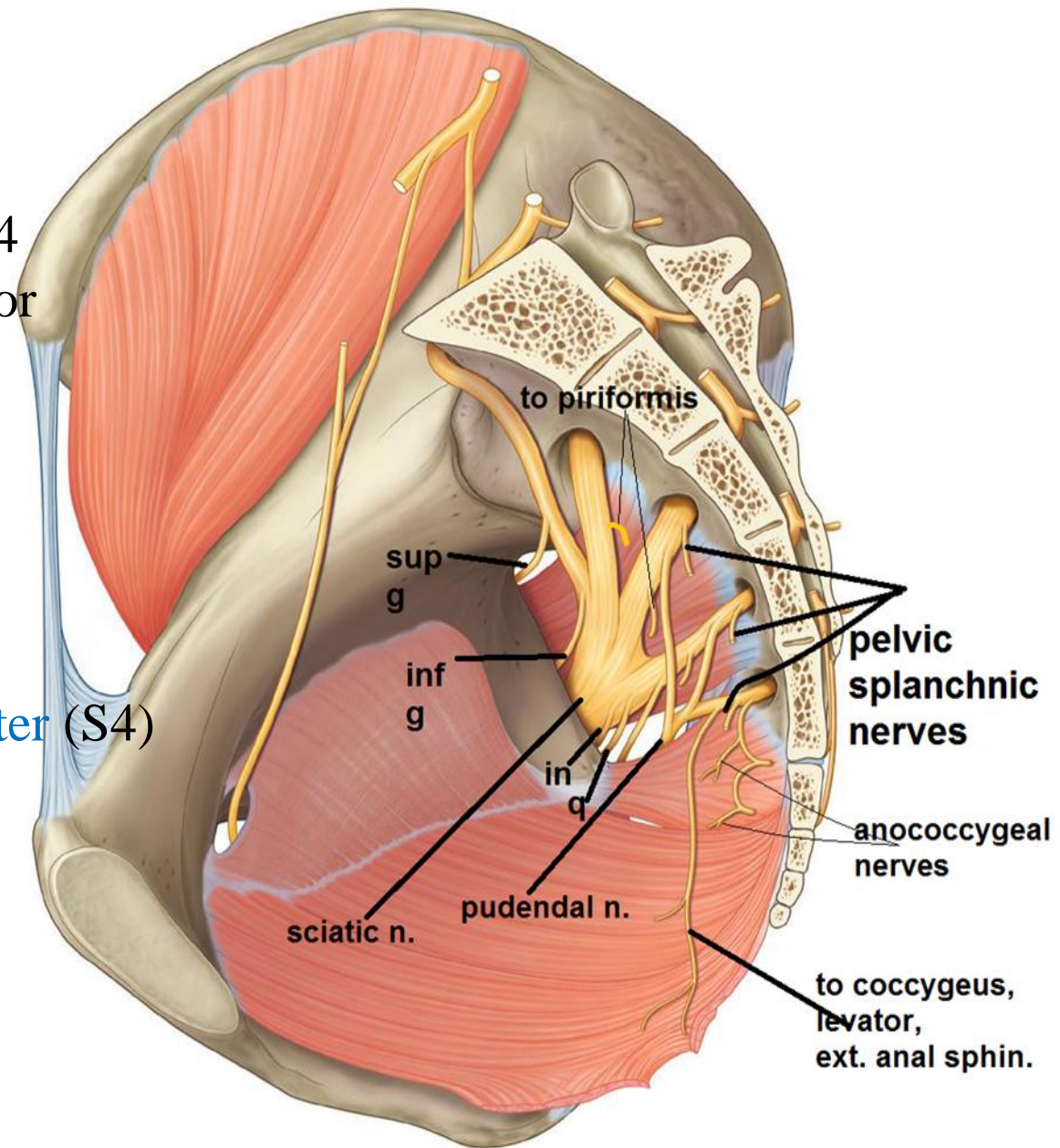
Ventral rami of L.4,5, S.1,2,3,4  
each ramus divides into anterior  
& posterior divisions

## **Branches:-**

Nerve to piriformis (S1,2)

Nerves to Coccygeus,  
levator ani,  
external anal sphincter (S4)

Pelvic splanchnic nerve  
(Parasympathetic):-  
from S2,3,4



# SACRAL PLEXUS

## Branches:-

N. to quadratus femoris (L4,5 S1)

N. to obturator internus (L5 S1,2)

Superior gluteal n. (L4,5 S1)

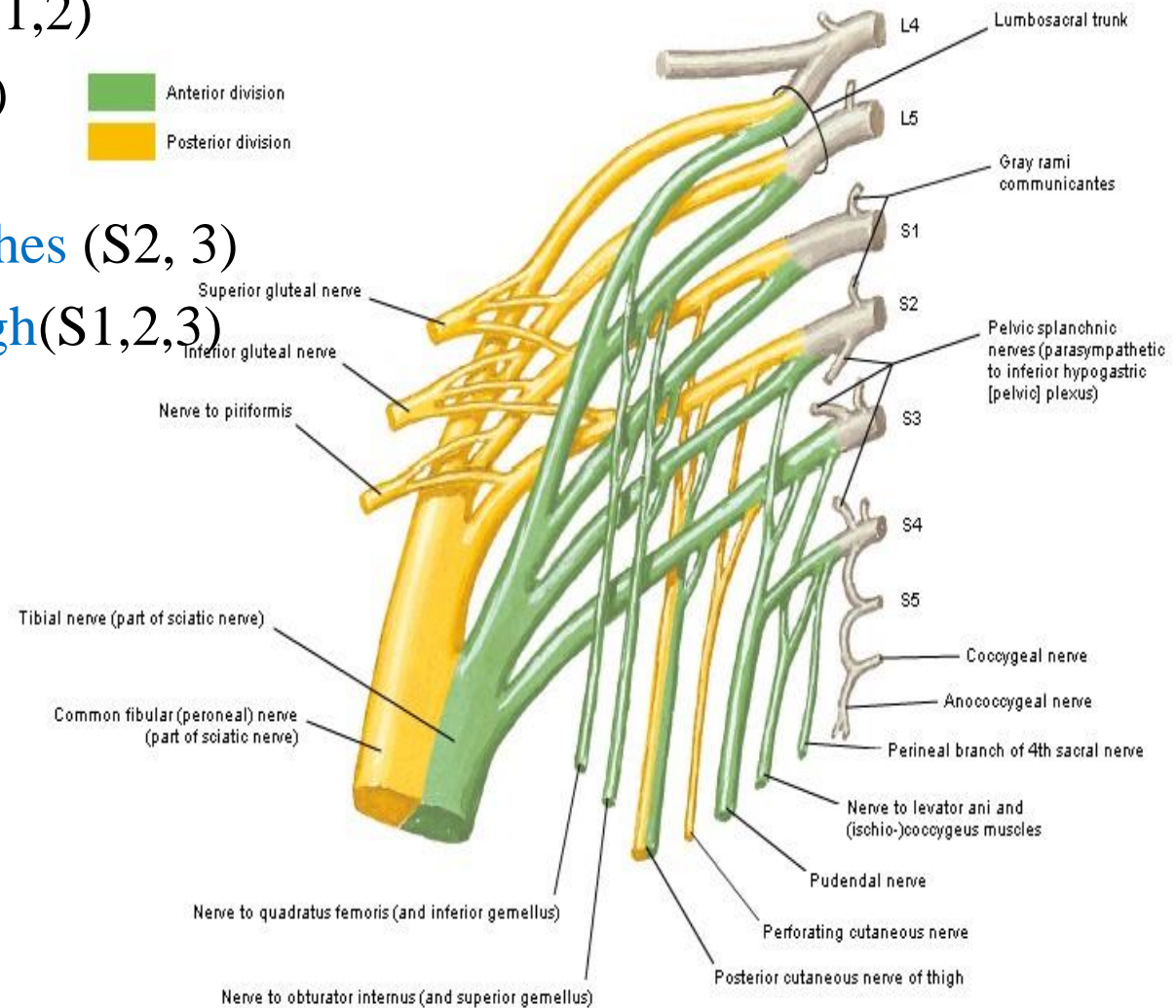
Inferior gluteal n. (L5, S1,2)

Perforating cutaneous branches (S2, 3)

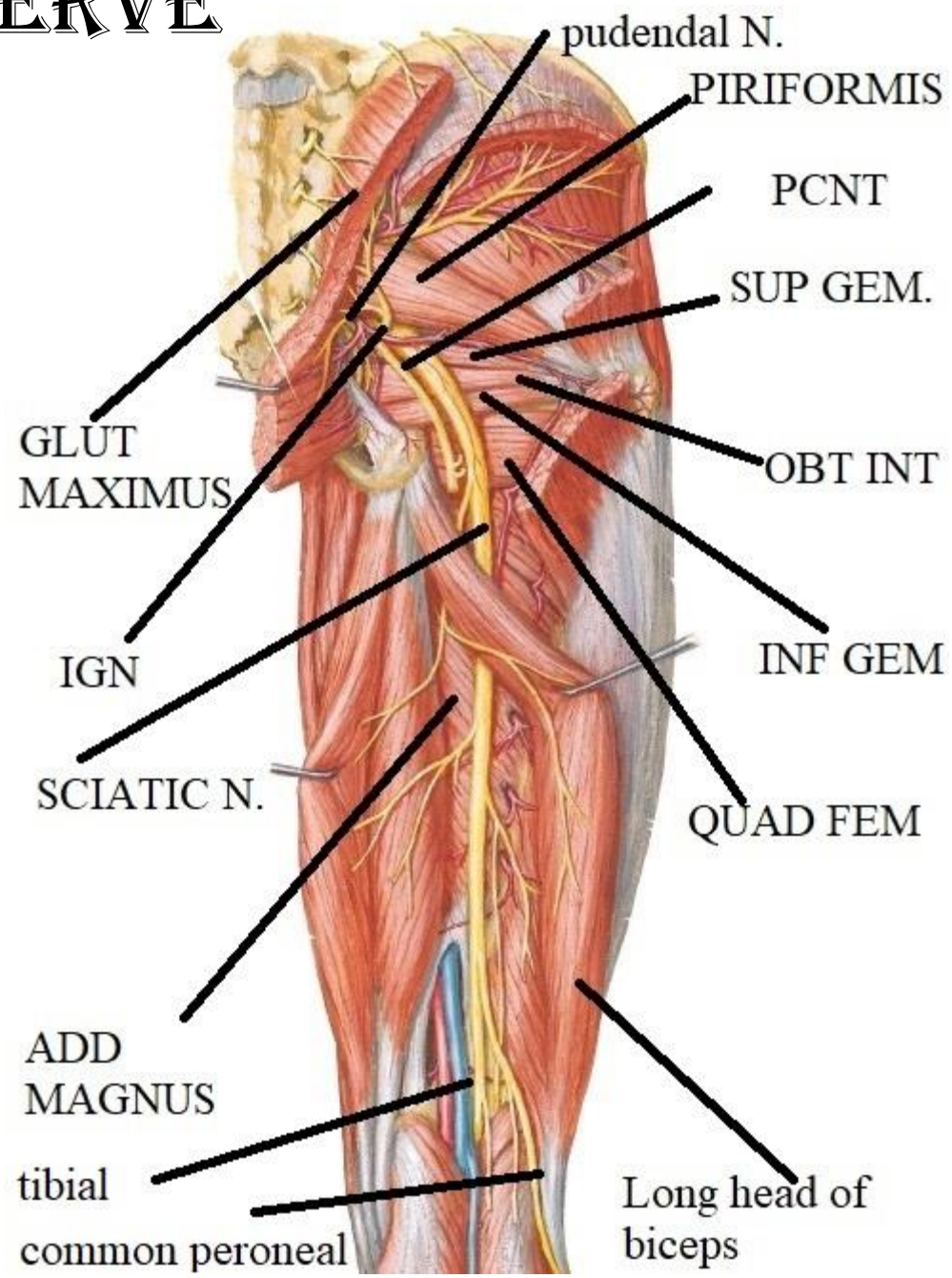
Post. cutaneous nerve of thigh (S1,2,3)

Sciatic n. L4, 5 S1, 2, 3

Pudendal n. S2, 3, 4



# SCIATIC NERVE



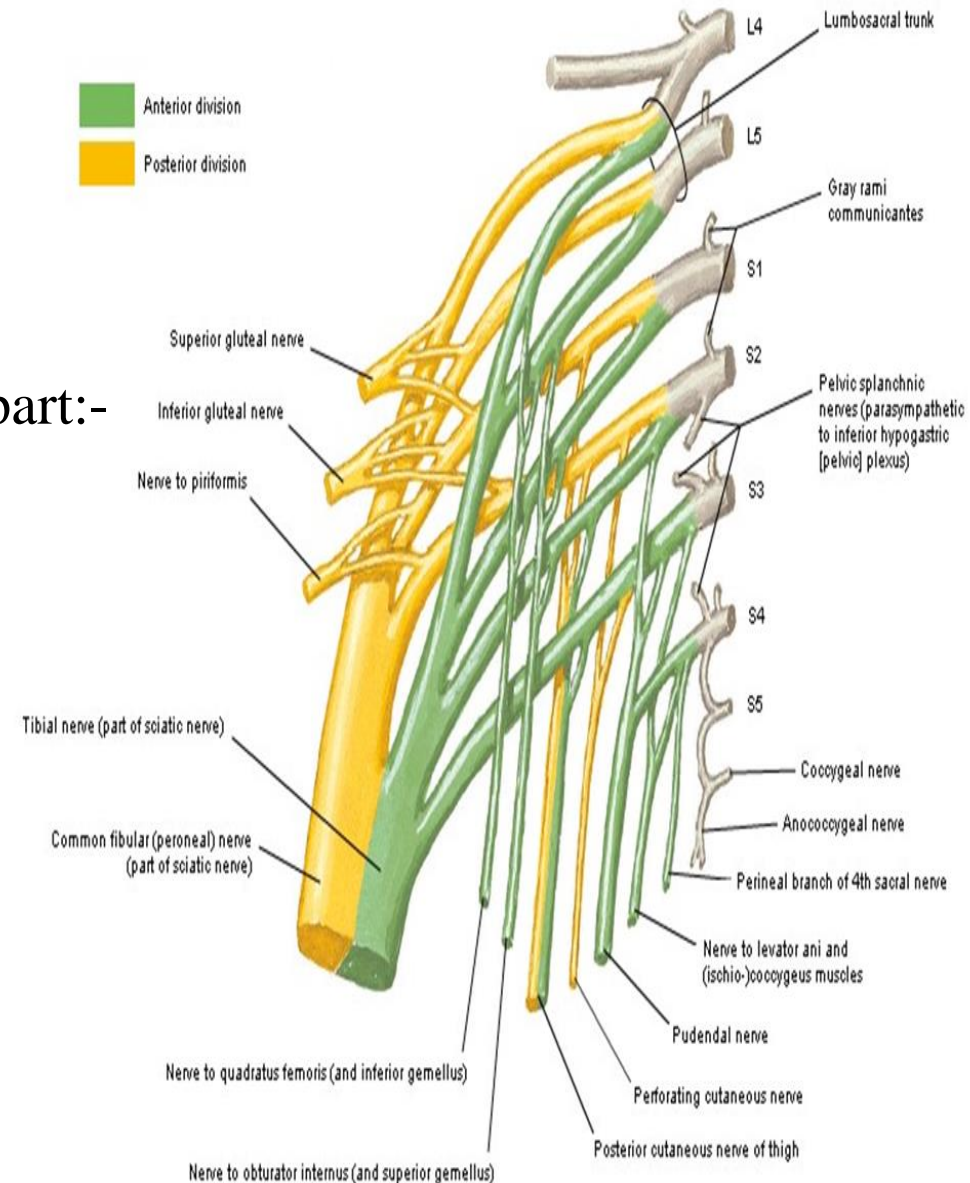
# SCIATIC NERVE

the thickest n. in the body

**O.:** sacral plexus (L4, 5 & S1, 2, 3)

it has 2 parts in a common sheath :

- tibial ( medial popliteal) part:-  
L 4, 5 , S 1 , 2 , 3
- common peroneal (lateral popliteal) part:-  
L4,5 S 1,2



# SCIATIC NERVE

**C.:**  
leaves pelvis through GSF below piriformis  
(lateral to inferior gluteal n. & v. ,  
pudendal nerve , internal pudendal vessels)

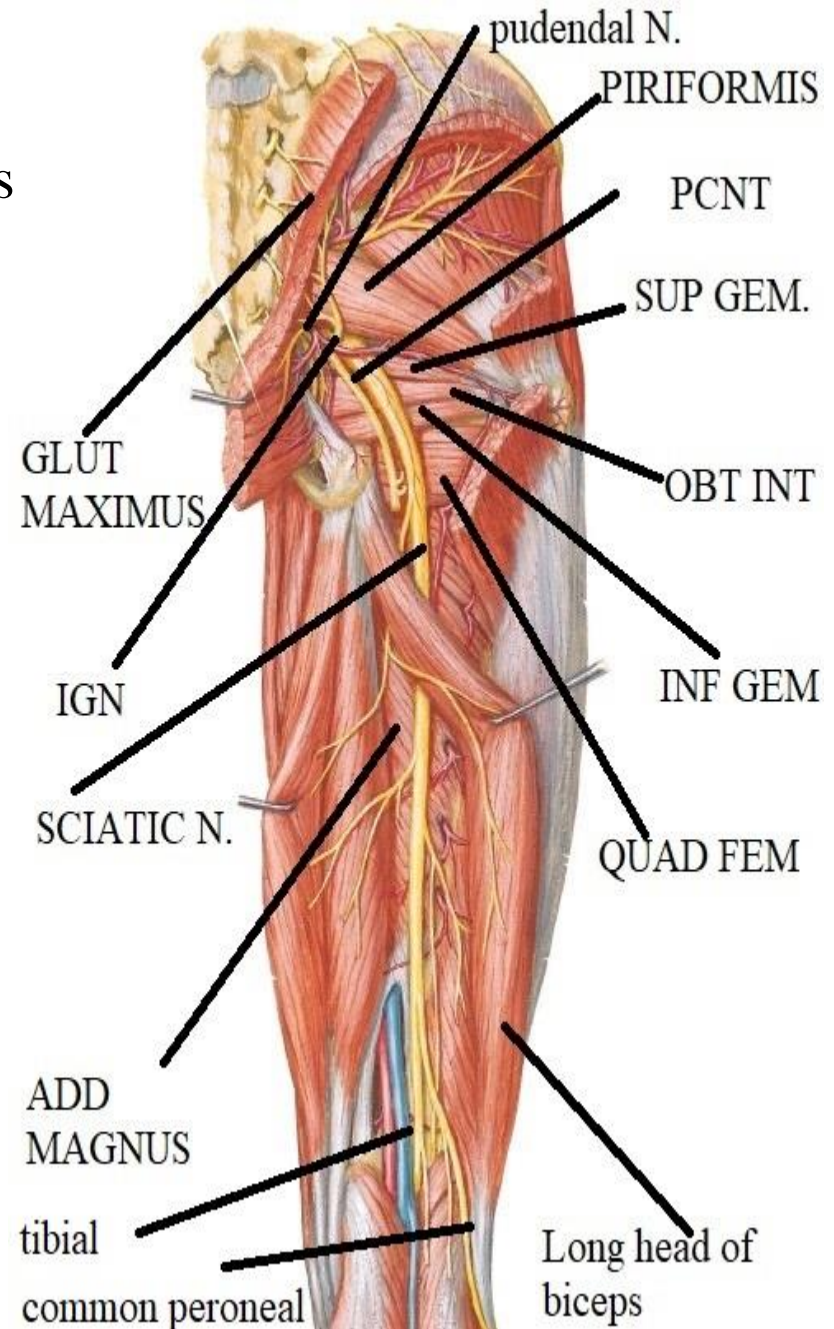
**in gluteal region :-**

it passes downwards & laterally  
to point midway ( ) ischial tuberosity  
& greater trochanter to enter back of thigh

**in back of thigh:-** descend vertically  
in midline of back of thigh.

**ends** proximal to popliteal fossa

divide into tibial & common peroneal



# SCIATIC NERVE

C.:

## Variation of the sciatic nerve:

- The nerve may leave the pelvis as two separate parts:

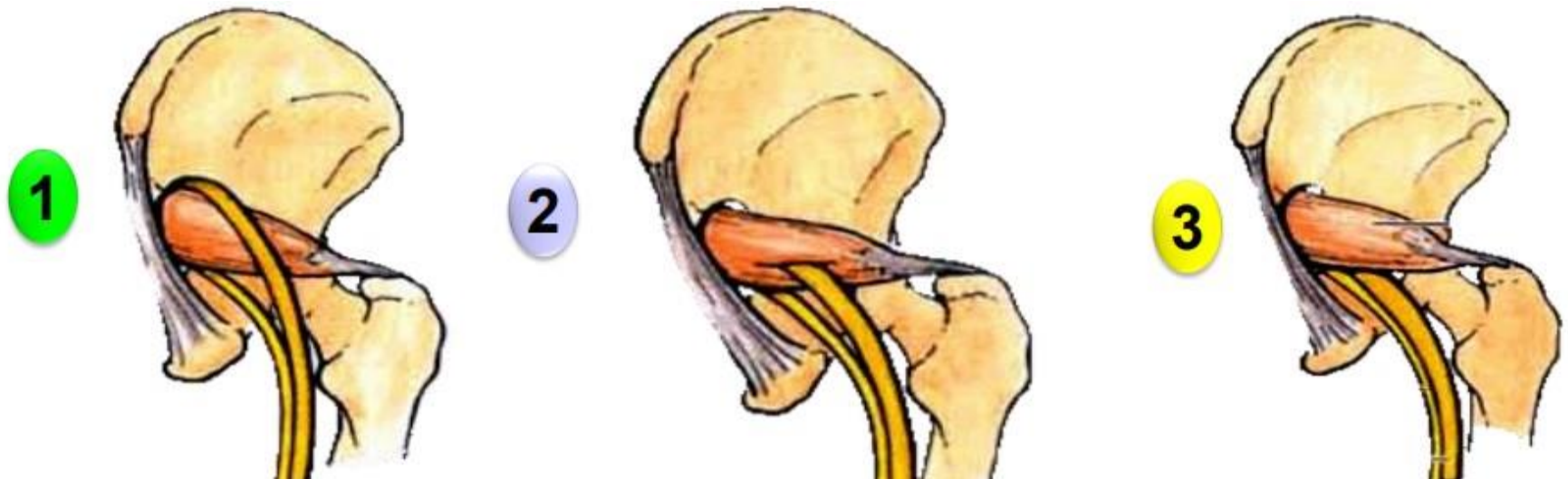
a- **Tibial nerve** passes below the piriformis muscle and takes course of the sciatic nerve.

b- **Common peroneal nerve** passes either

1- Above the piriformis muscle.

2- Through the piriformis muscle.

3- Below the piriformis muscle..



# SCIATIC NERVE

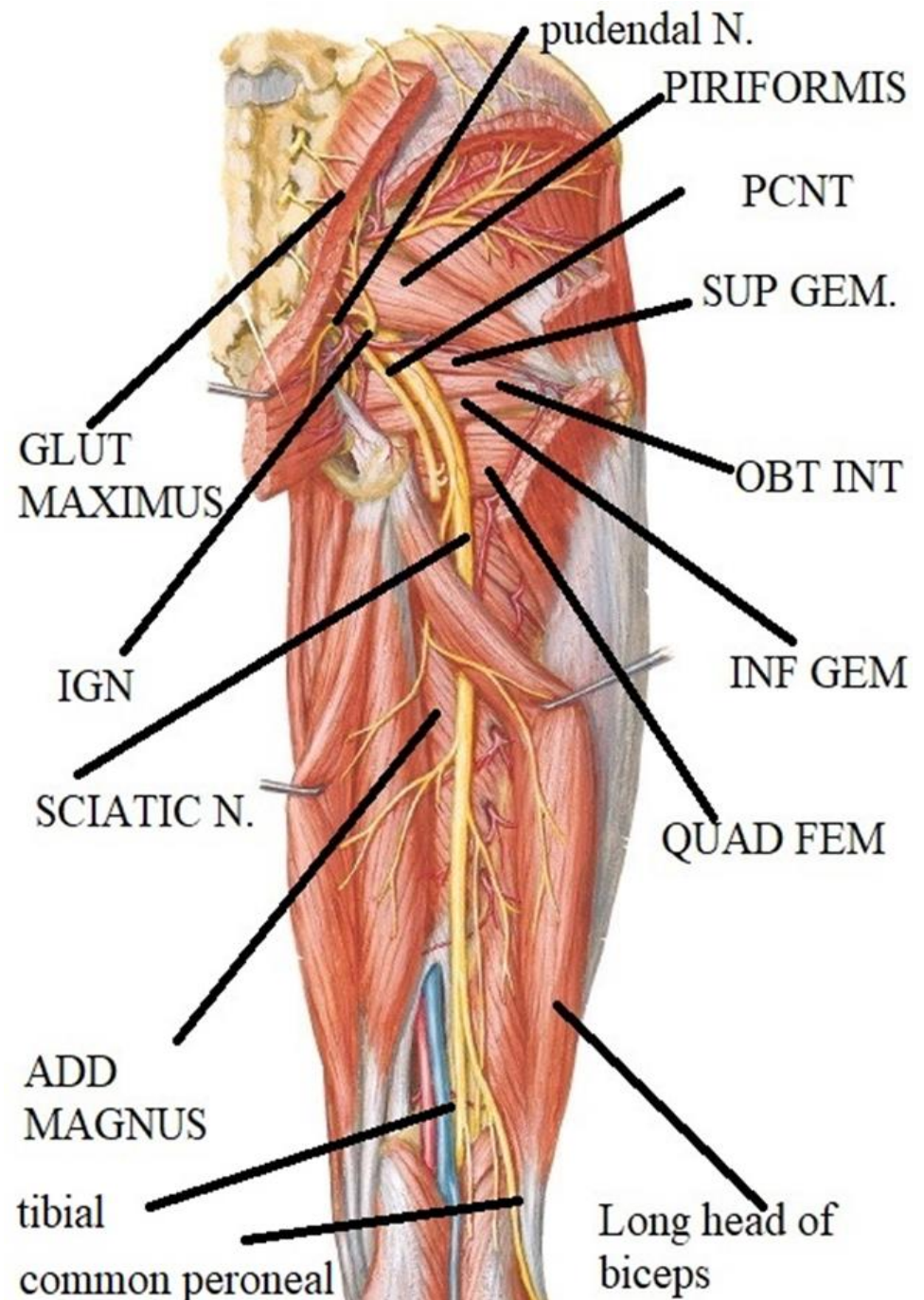
## Relations :

### Superficial (posterior):

- post. cutaneous of thigh
- gluteus maximus
- long head of biceps

### Deep (anterior)

- back of ischium
- superior gemellus
- obturator internus
- inferior gemellus
- quadratus femoris
- n. to quadratus femoris
- adductor magnus





# SCIATIC NERVE

**Branches** : no branches in gluteal region

**Muscular branches**

**From tibial part**

- adductor magnus (ischial head)
- semimembranosus
- semitendinosus
- long head of biceps

**From common peroneal part**

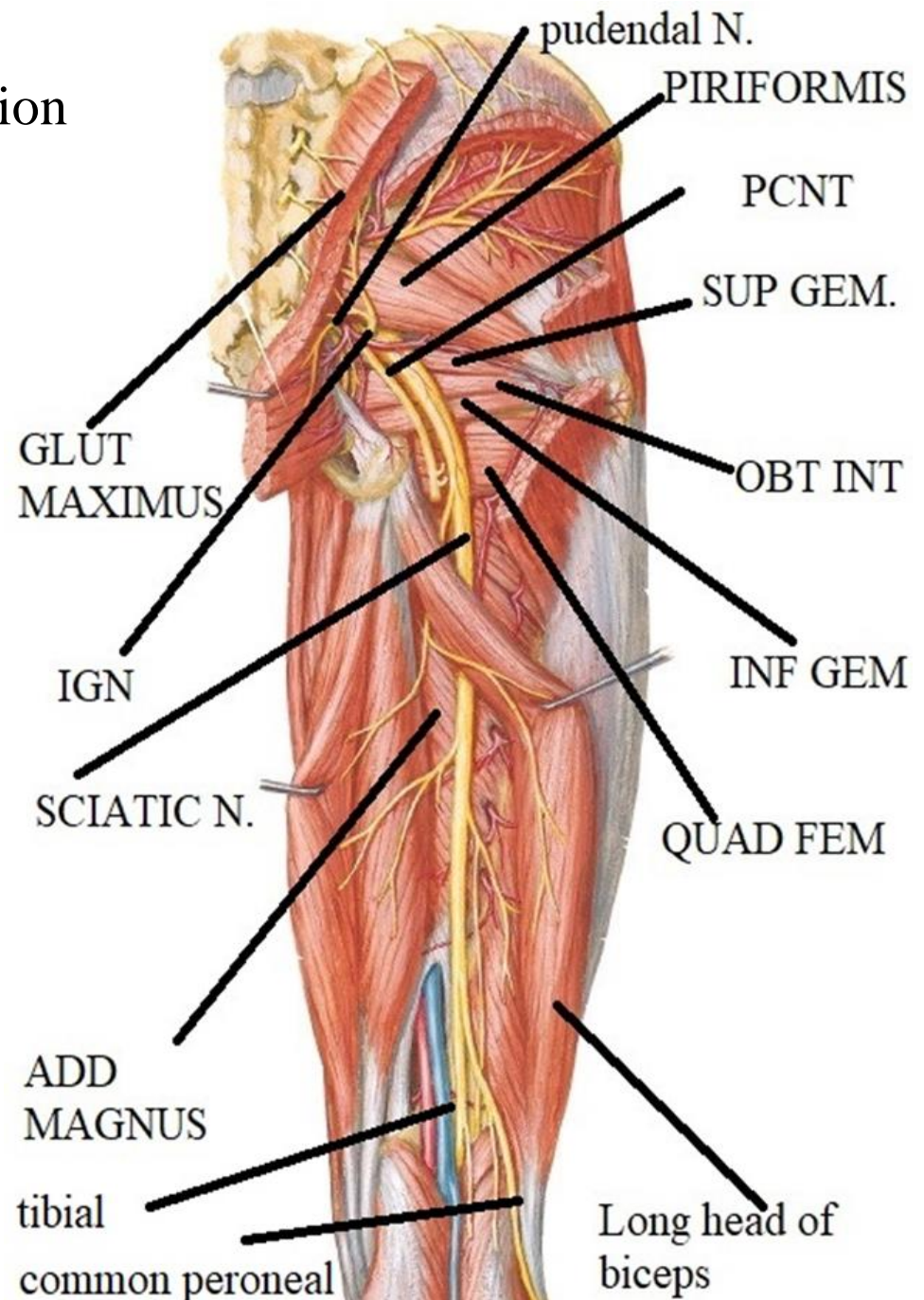
Short head of biceps

**Articular branch**

hip joint

**Terminal branches**

- tibial
- common peroneal

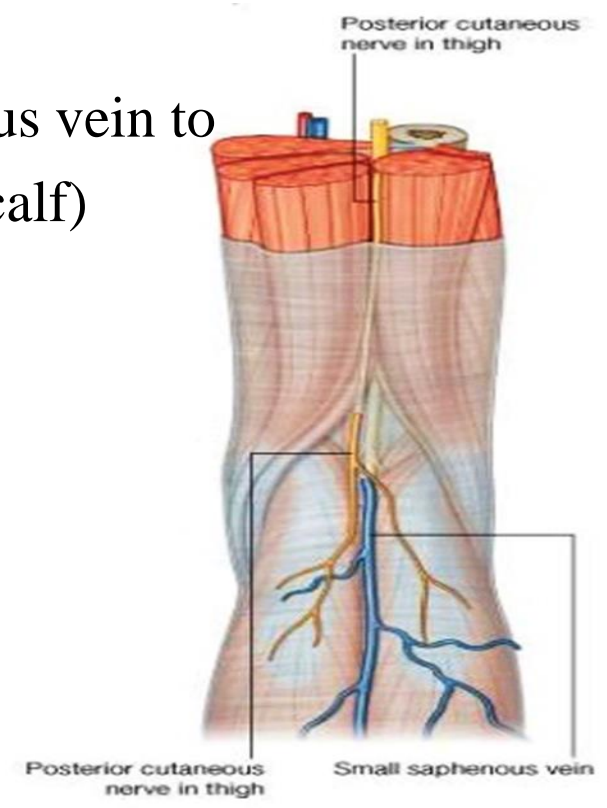
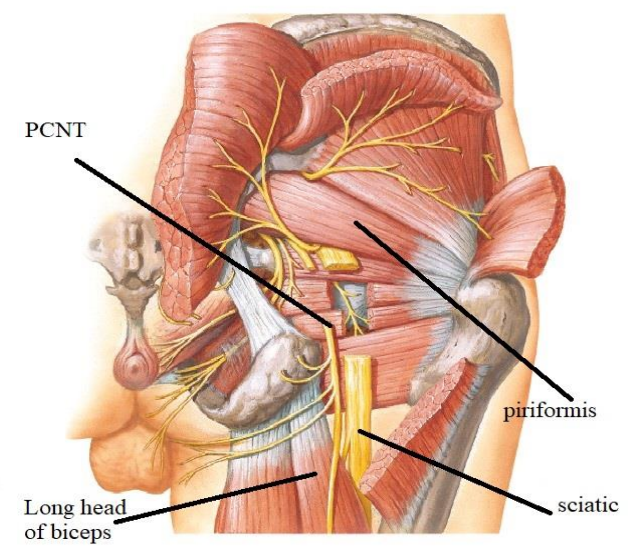


# POSTERIOR CUTANEOUS NERVE OF THIGH

O.: from sacral plexus

C & R :

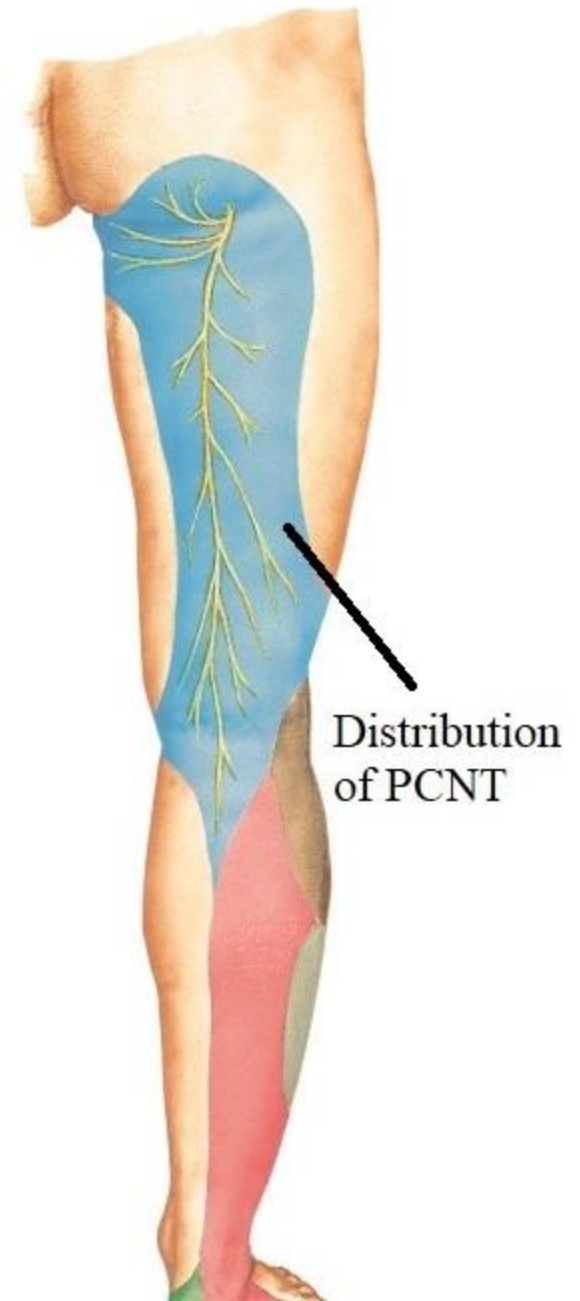
- pass through greater sciatic foramen below piriformis
- descends superficial to sciatic n.
- descend superficial to long head of biceps
- pierce deep fascia & accompany short saphenous vein to upper part of back of leg (calf)



# POSTERIOR CUTANEOUS NERVE OF THIGH

## Distribution

- skin of back of thigh
- skin of lower medial 1/4 of gluteal region
- skin of popliteal fossa & upper part of back of leg.
- skin of back of scrotum or labia majora.



THANQ