



الطبيب والجراحة

لجنتنة

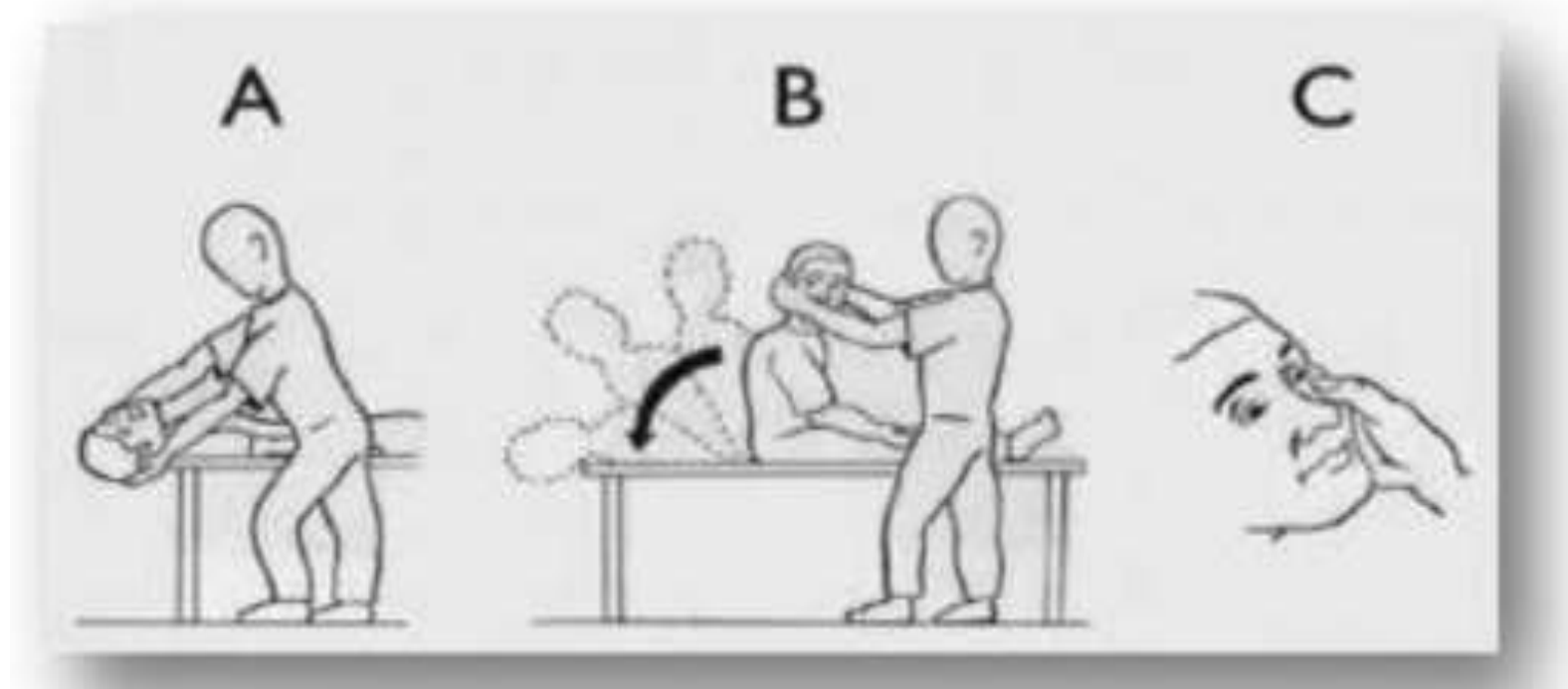

Neuromedicine miniosce 1

Sara saraireh , bara'ah alqudah, rahmah saraireh , shahed saraireh

What is the name of test?

Dix-Hallpike maneuver



➤ 75 years old male came with acute stroke. He has right side weakness. He has spontaneous speech with occasional paraphrasic errors. He cannot understand and follow commands, and repetition is affected.

❖ Which of the following best explains his speech pattern?

- a. Broca aphasia
- b. Transcortical aphasia
- c. Conduction aphasia
- d. Wernicke aphasia**
- e. Global aphasia

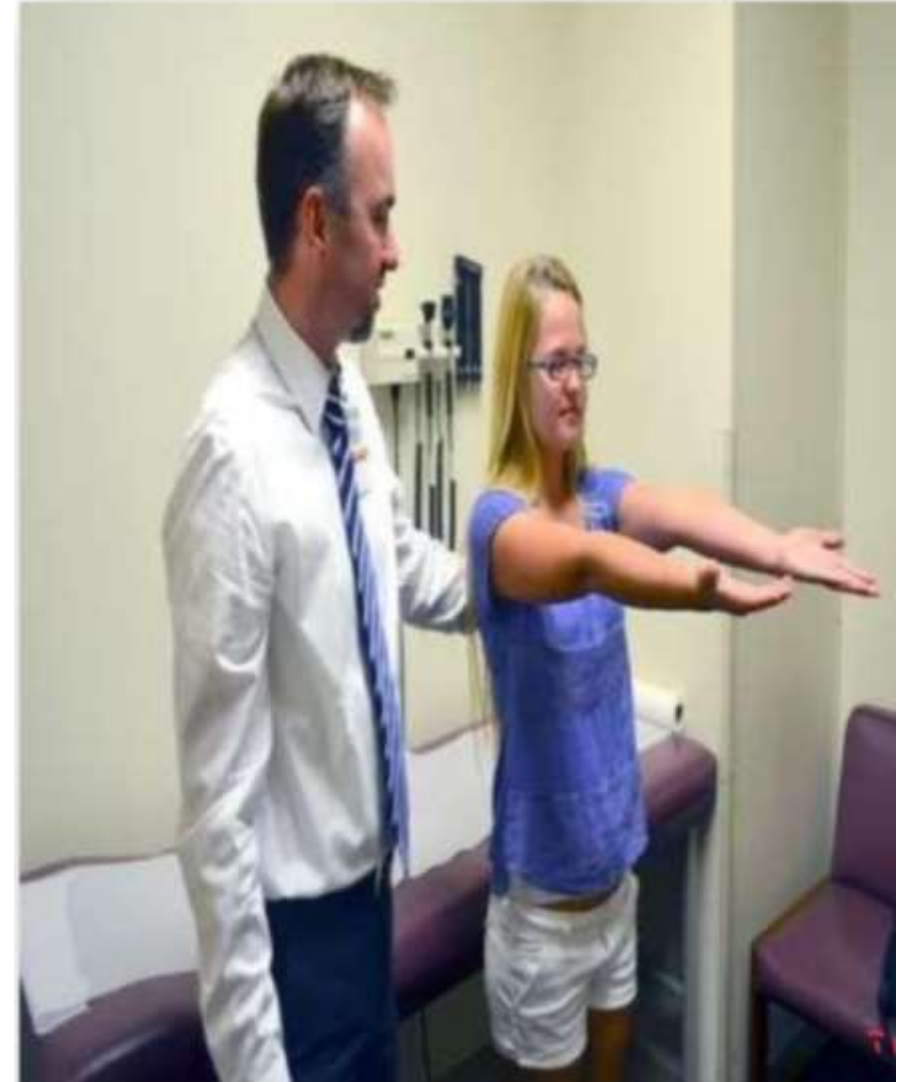
Choose the FALSE combination:

- a. Athetosis is slow writhing movement
- b. Tics are semivoluntary movement
- c. Hemiballismus due to contralateral lesion in subthalamic nucleus
- d. Intention tremors frequency is the same through out the movement
- e. Myoclonus sudden, brief, uncontrolled muscle contraction

- Eye open to verbal command, Incomprehensible sound, and localizes pain.
- Gcs=10
- Gcs 10
- Gcs =5
- Gcs = 12

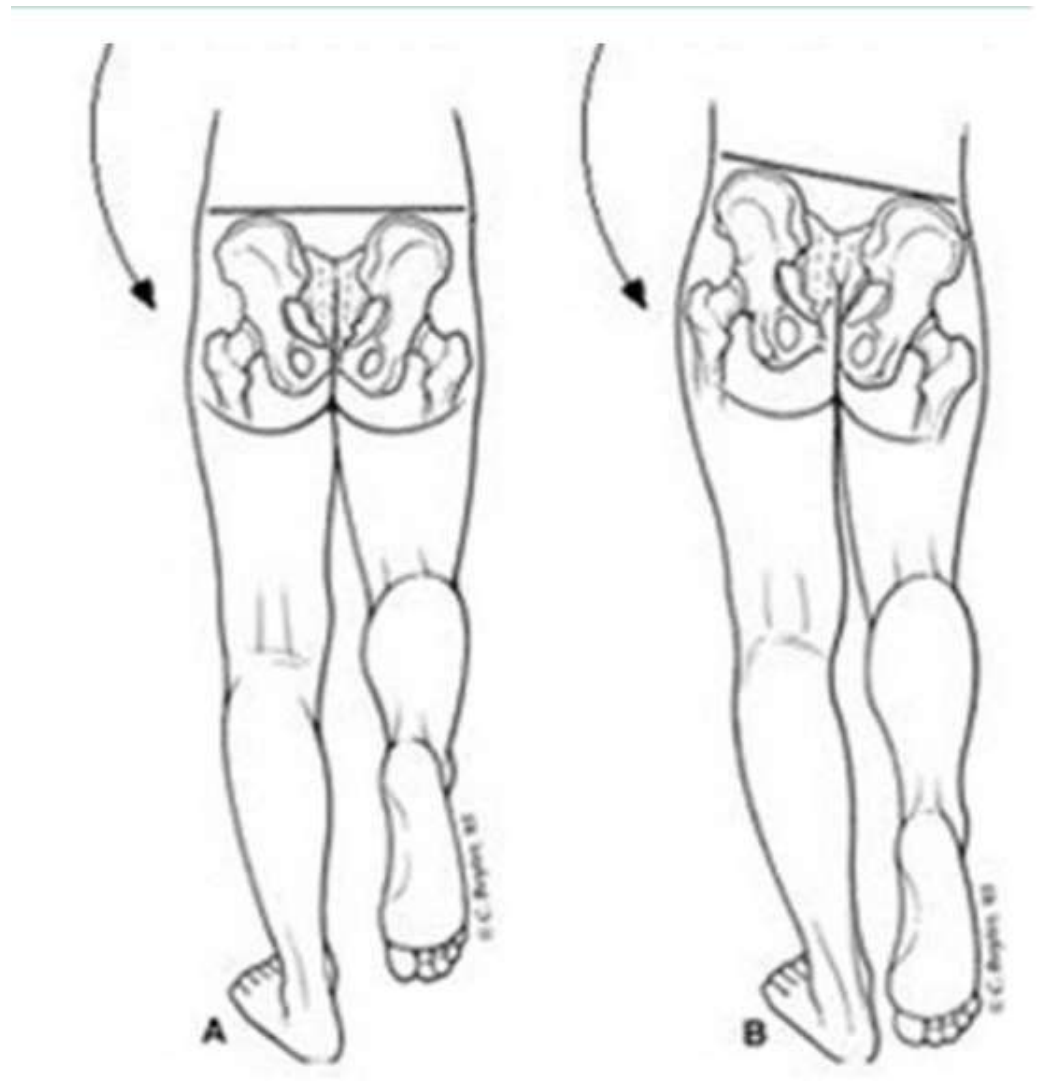
Which of the following is true ?

- the patient lost his balance when closing his eyes after standing ,this is mean positive romberg test



What is the name of test?

Trendelenburg's test



Q5- This test called ?

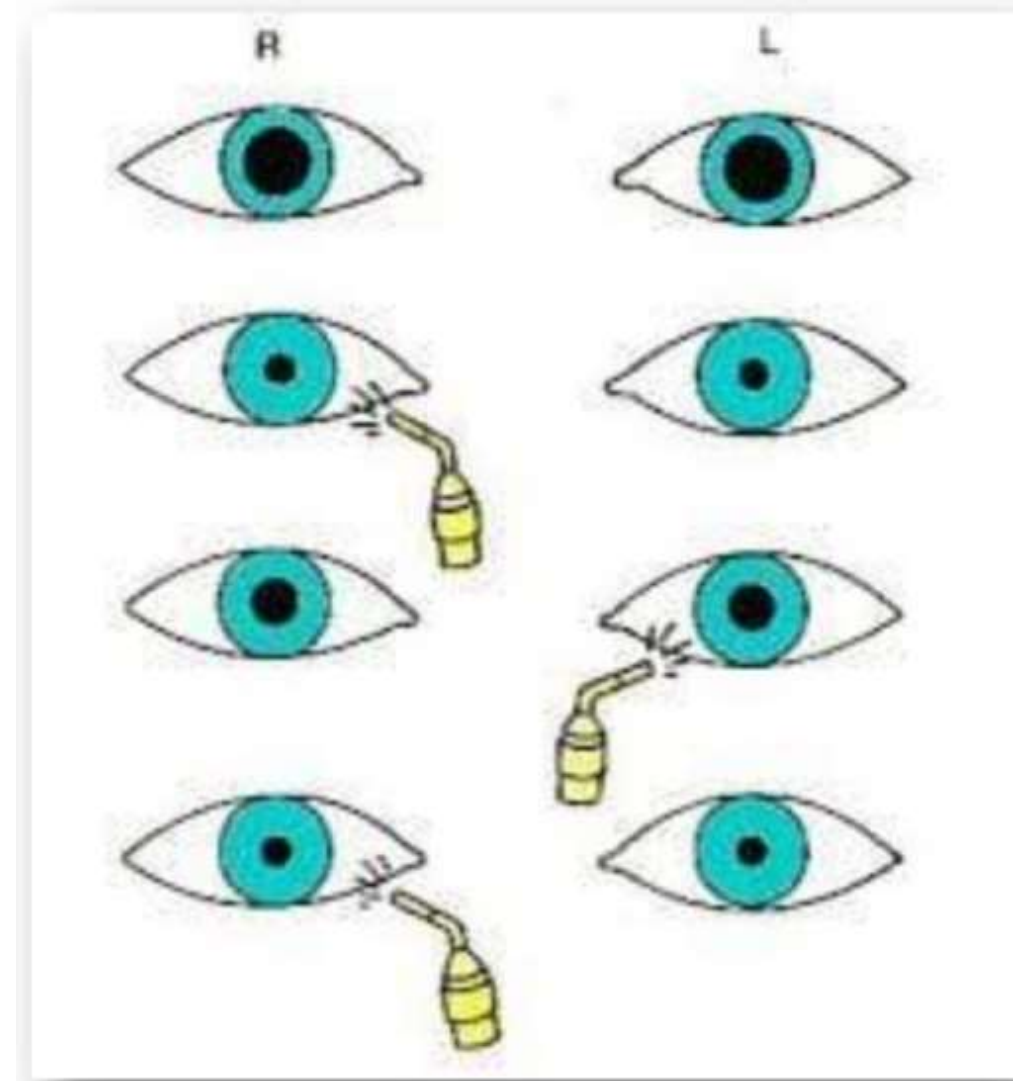
- A. Tandem test
- B. Romberg's test
- C. Trendelenburg's test
- D. Heel-knee-shin test
- E. Babinski's sign



All of the followings are true
except :

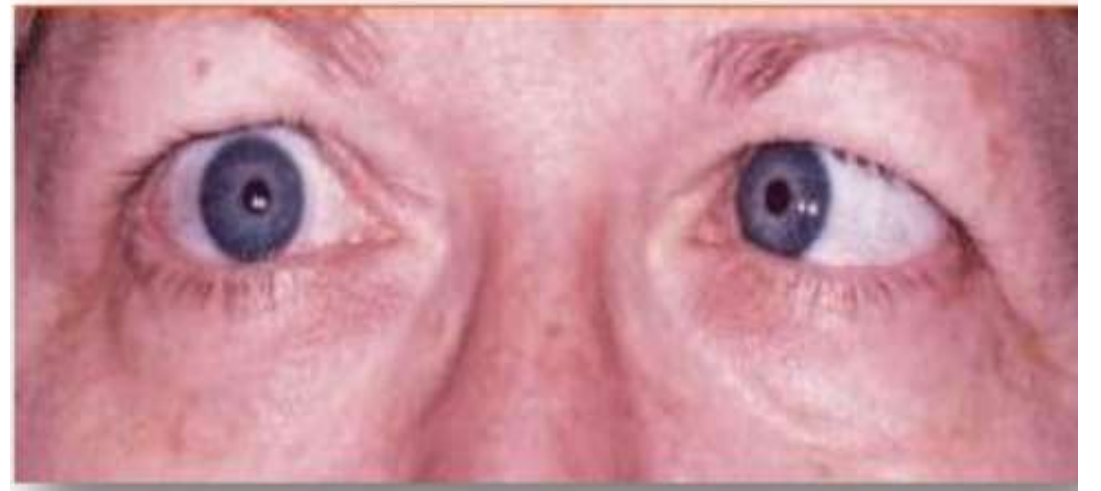- swinging test is more sensitive than direct pupillary reflex
- Occlomotor lesion cause this (مش اكيد , احترنا بين الاجابتين المكتوبات)

Note :afferent pupillary defect best demonstrated using the swinging torch test, in which light is repeatedly shone into the affected eye alternating with the good side



Which nerve is affected?

Abducent nerve

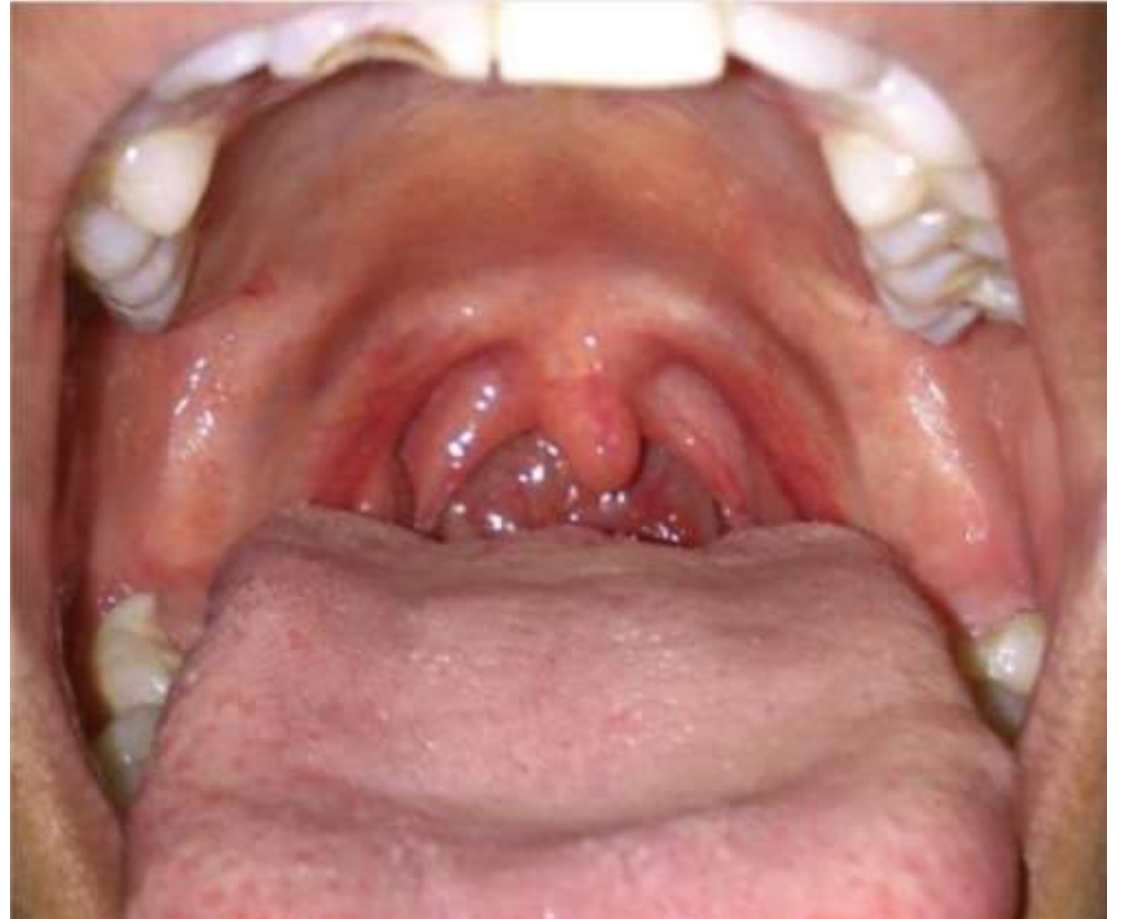

- Vagus nerve and glossopharyngeal nerve are responsible for the followings except :
 - Gag reflex
 - Taste sensation og posterior 1/3 of tongue
 - Swallowing
 - Deviation of tongue

- Patient looks to right, fast phase of nystagmus to left, what is the type of nystagmus ?
- A. Right jerky nystagmus.
- **B. Left jerky nystagmus.**
- C. Right pendular nystagmus.
- D. Left pendular nystagmus.
- E. Multidirectional nystagmus

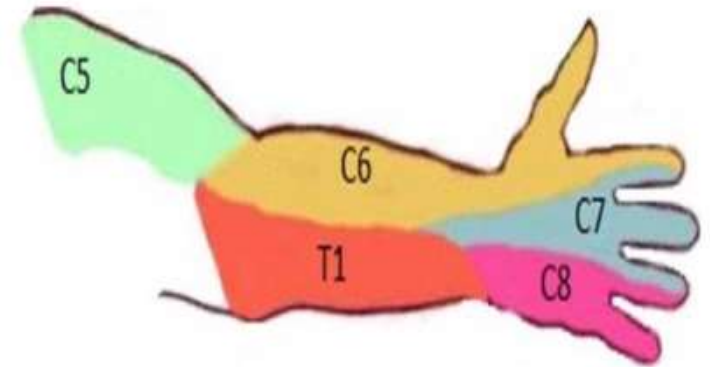
- All of the followings are true regarding to vestibulocochlear nerve except :
 - Fukuda test.
 - Nystagmus testing
 - Weber + Rinne test.
 - Whisper test from behind
 - Gag reflex

Where is the lesion ?
Right vagus

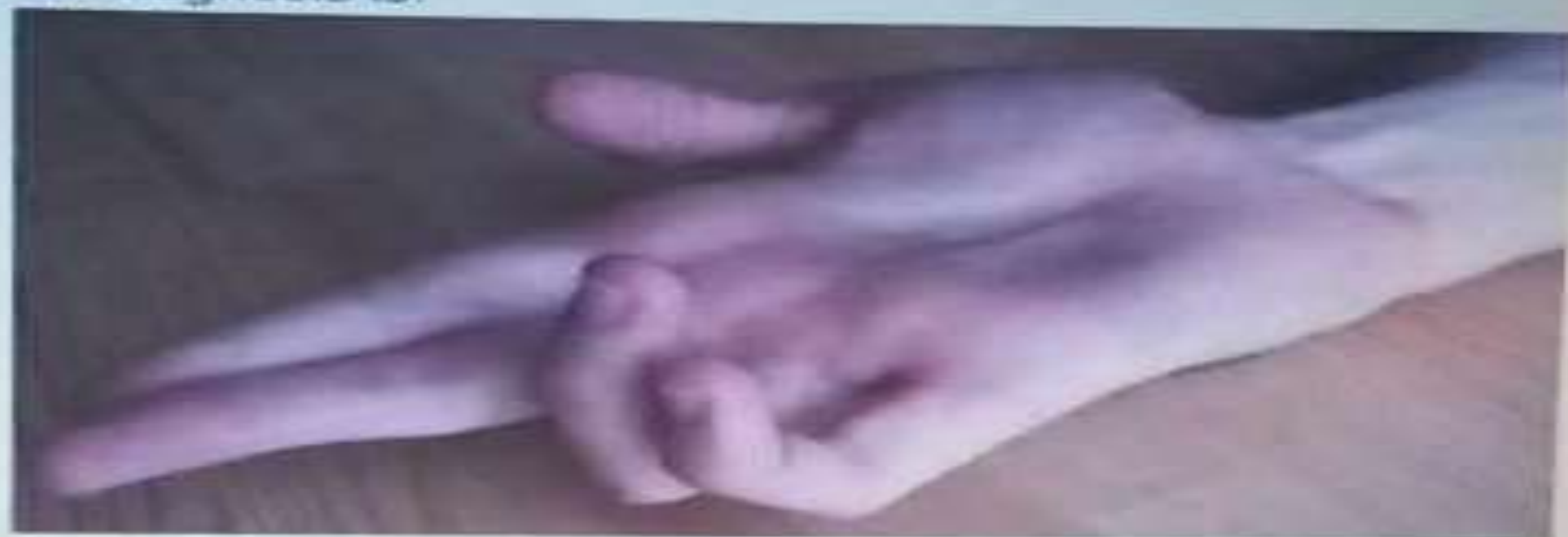

❖ Sensation loss over thumb and lateral part of forearm, where is the lesion ?

- a. C5 radiculopathy
- b. C6 radiculopathy**
- c. C7 radiculopathy
- d. C8 radiculopathy
- e. T1 radiculopathy



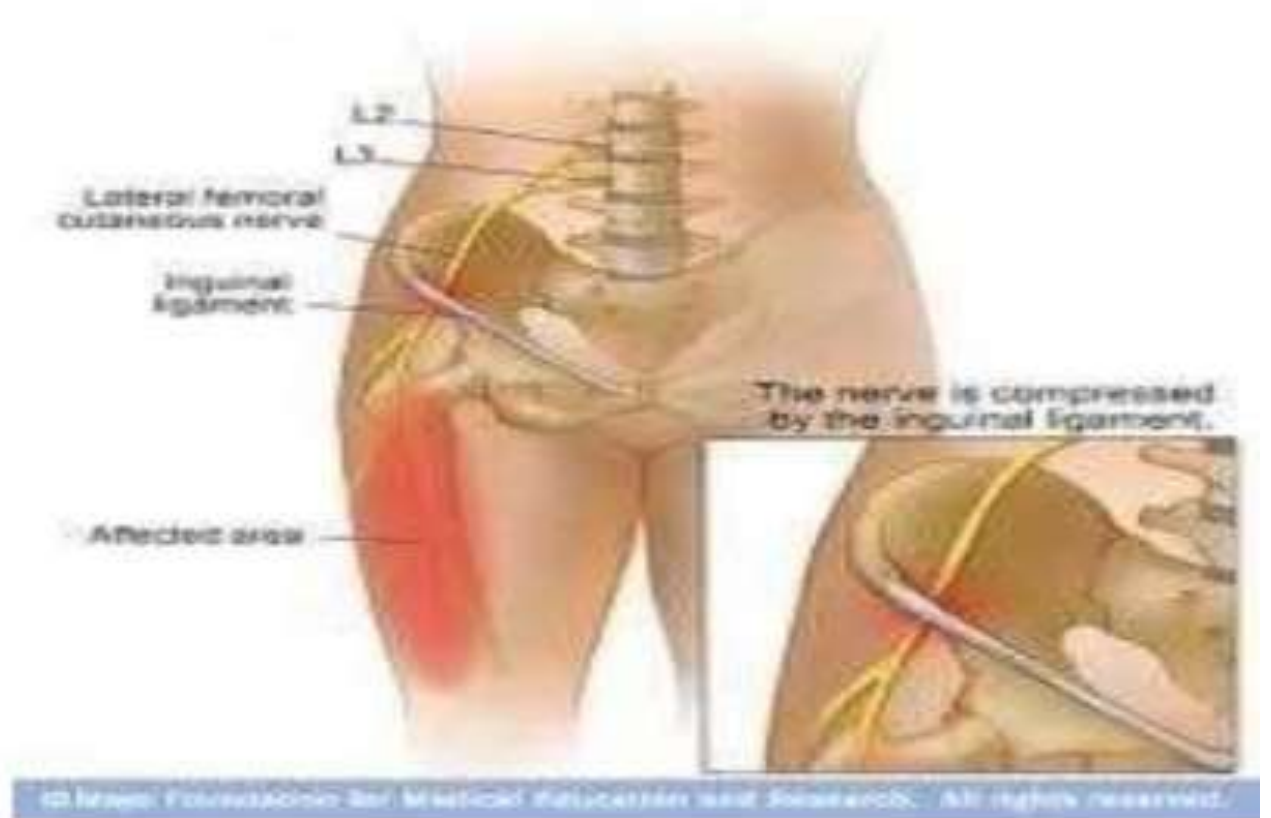
The diagnosis is:



Select one

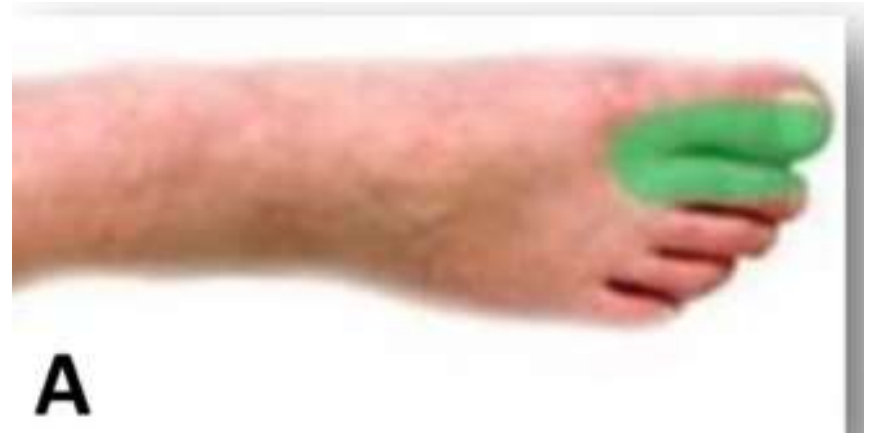- a. radial nerve lesion
- b. musculocutaneous injury
- c. suprascapular nerve
- d. The median nerve
- e. the ulnar nerve

The name of this condition?
Meralgia paresthetica

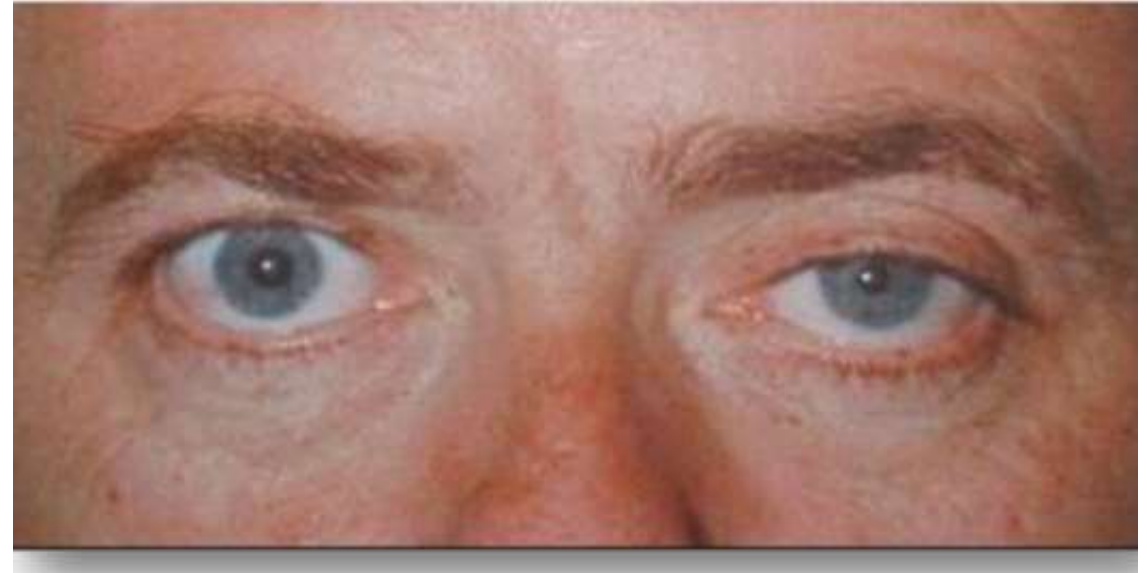

What is the nerve that supplies this area highlighted in (A) ?

Deep peroneal nerve

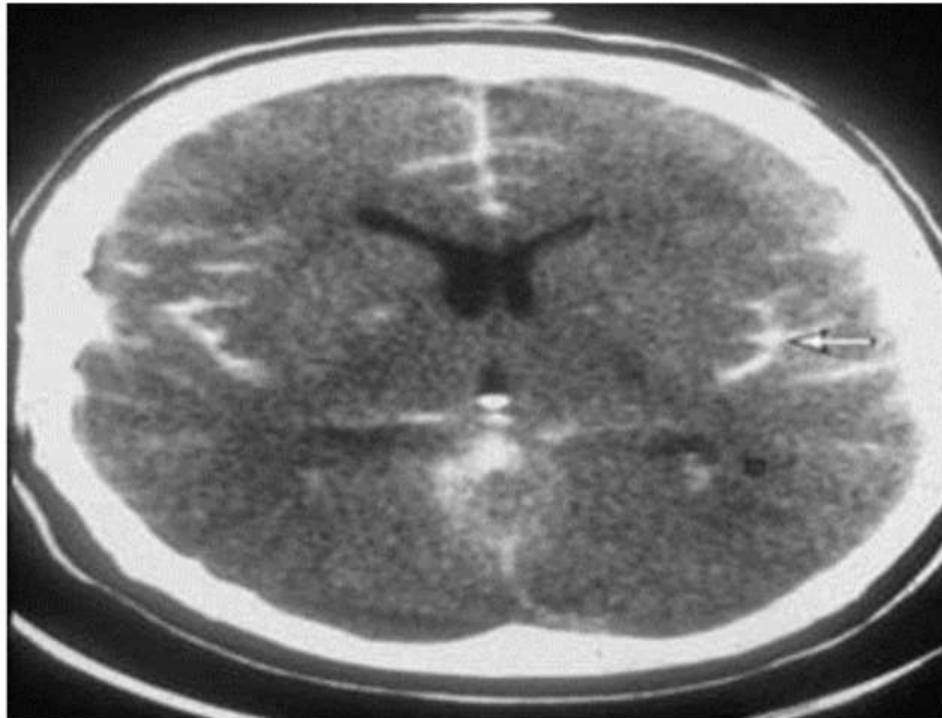


What is the name of this case?
Horner syndrome



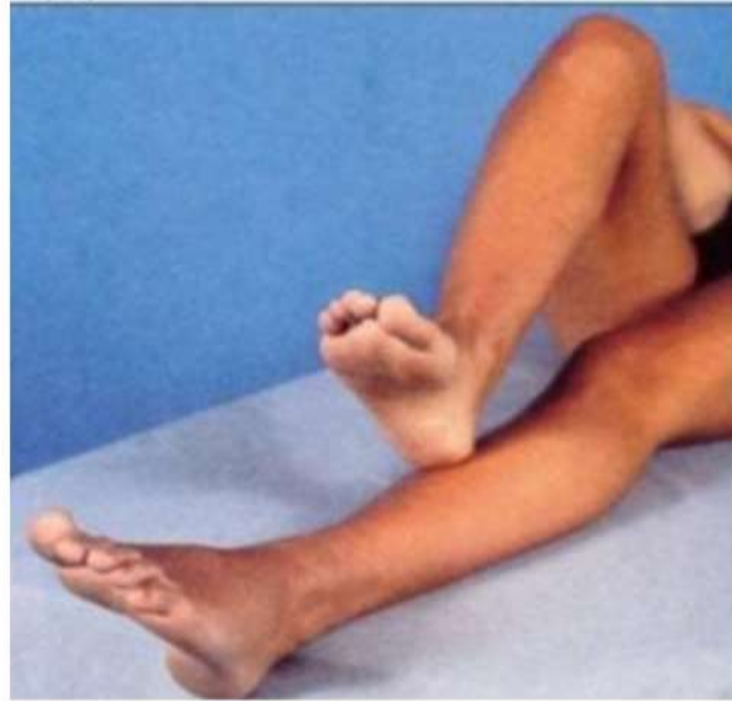
Q6- What is the diagnosis ?

- A. Normal CT scan
- B. Sub-arachenoid hemorrhage
- C. Cerebral infarction
- D. Multiple sclerosis
- E. Watershed infarction



Q3-This test is used for detect the function of:

- A. Right cerebellum
- B. Left cerebellum
- C. Right cerebral
- D. Left cerebral
- E. Dorsal columns



21- a patient presented with status epilepticus, he was given 10mg of diazepam but didn't get better, he was given another 10mgs but it also didn't work. What is the next step ?

- a. 20mg of phenytoin + saline for 2 minutes
- b. 20mg of phenytoin + glucose infusion
- c. 20mg of phenytoin + saline infusion**
- d. 20mg of phenytoin + glucose for 2 minutes
- e. Propofol

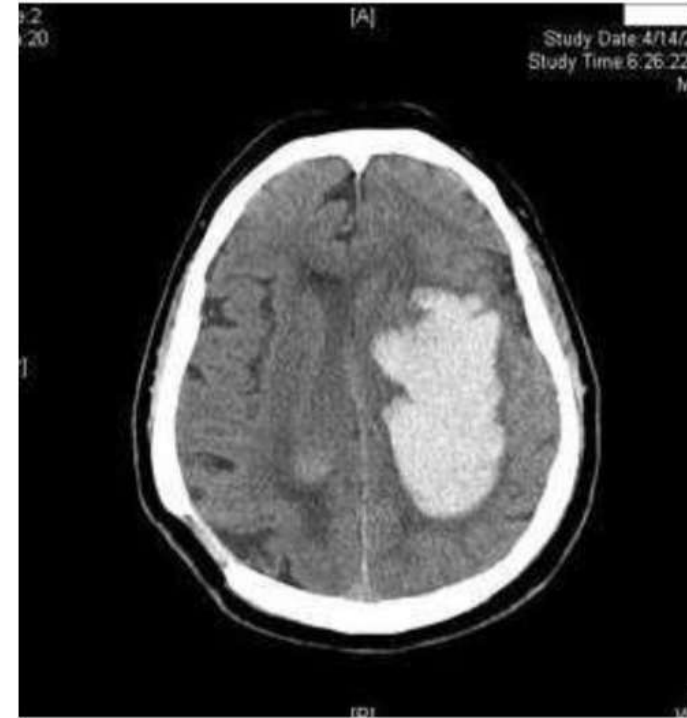Q34- These are CSF results, what do you expect the cause of these findings in A and in B?

1. **A: TB & B: Bacterial**
2. A: Fungal & B: TB
3. A: TB & B: Viral
4. A: Viral & B: Bacterial
5. A: Bacterial & B: TB

	A	B
Opening pressure	elevated	elevated
WBCs	Elevated mainly lymphocytes	Elevated mainly neutrophils
RBCs	none	few
Glucose	Significantly low	low
Protein	high	high
Appearance	turbid	turbid

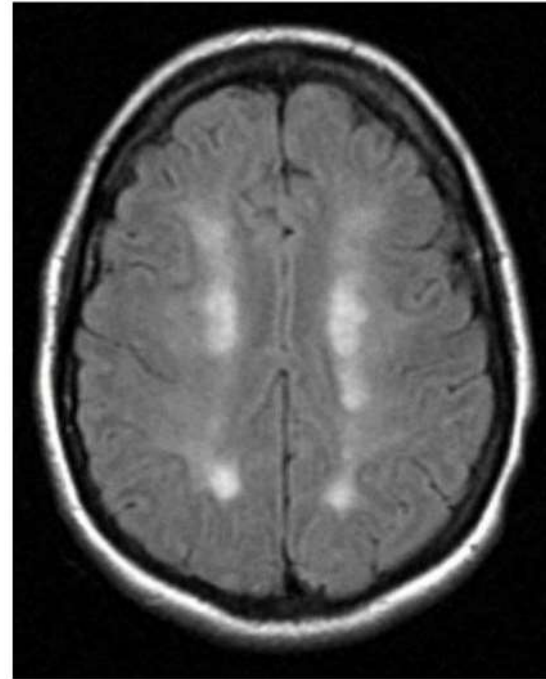
Q19- What is the diagnosis?

- A. Intracranial hemorrhage
- B. Vasogenic edema
- C. Cerebral infarction
- D. Multiple sclerosis
- E. Watershed infarction



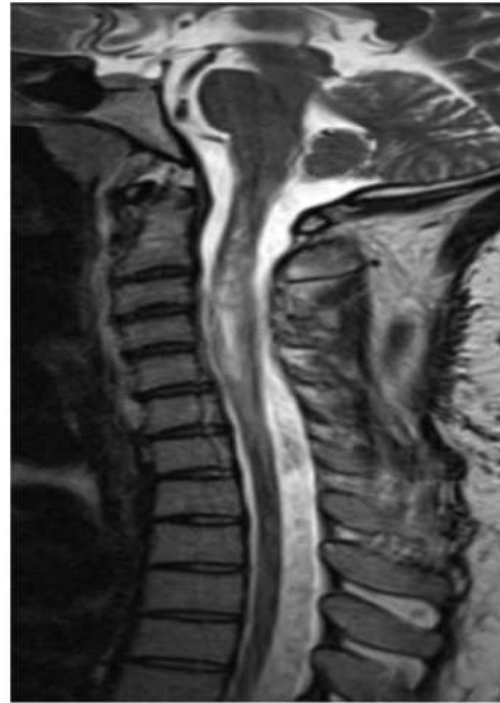
Q18- This condition is caused by ?

- A. Severe hypertension
- B. Severe hypotension**
- C. Encephalitis
- D. Meningitis
- E. Vasculitis



Q8- What is the diagnosis?

- a. T1 Transverse myelitis
 - b. T2 Transverse myelitis**
 - c. T1 syringomyelia
 - d. T2 syringomyelia
 - e. None of the above
-
- Note: T1 and T2 are meant to mean T1-weighted MRI & T2-weighted MRI and not T1 spine

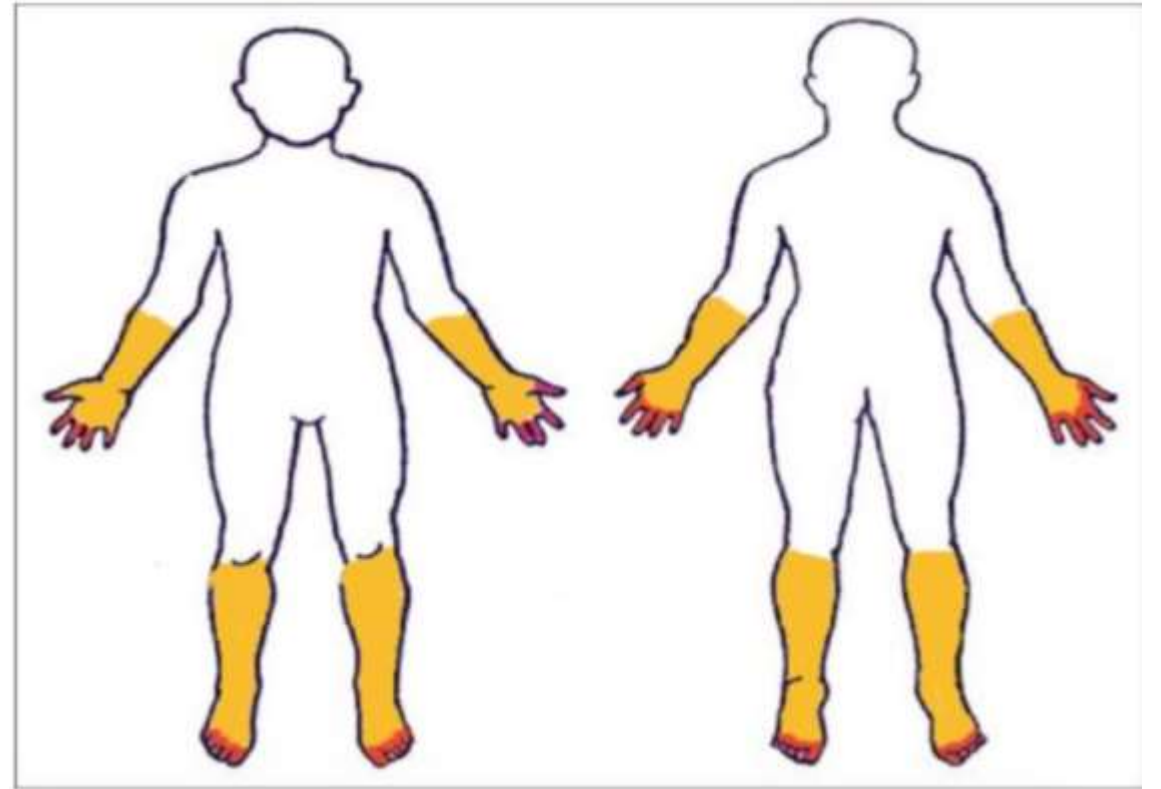


NOT THE SAME PICTURE

- All of these test are for cerebellum except :
 - Finger to nose tes
 - Heel to shin test
 - Rapid alternating movement
 - Rebound test
 - Romberg test

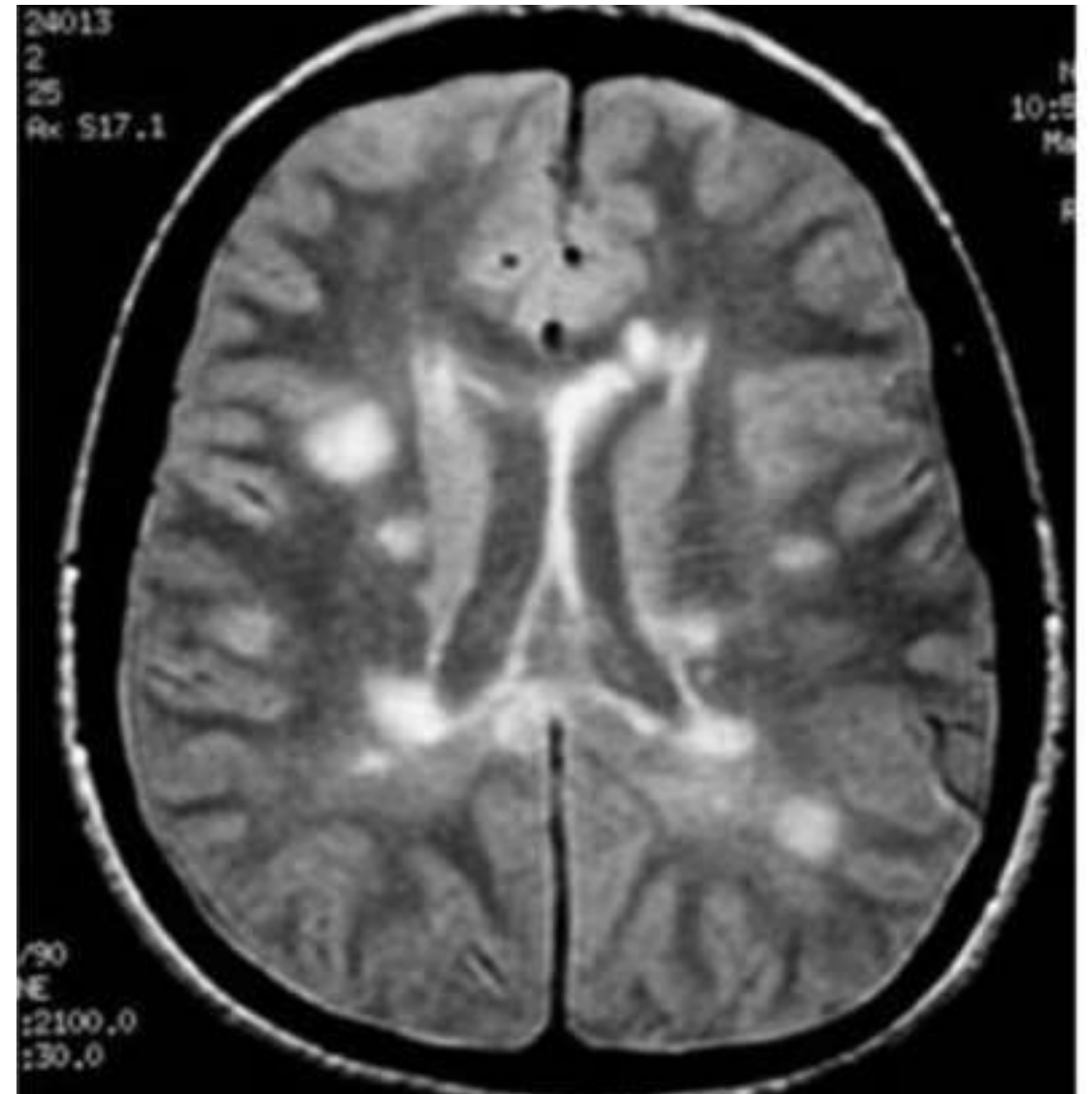
NOTE: THE ROMBERG TEST IS NOT A SIGN OF CEREBELLAR DISEASE.
It is a sign of a disturbance of proprioception

Polyneuropathy

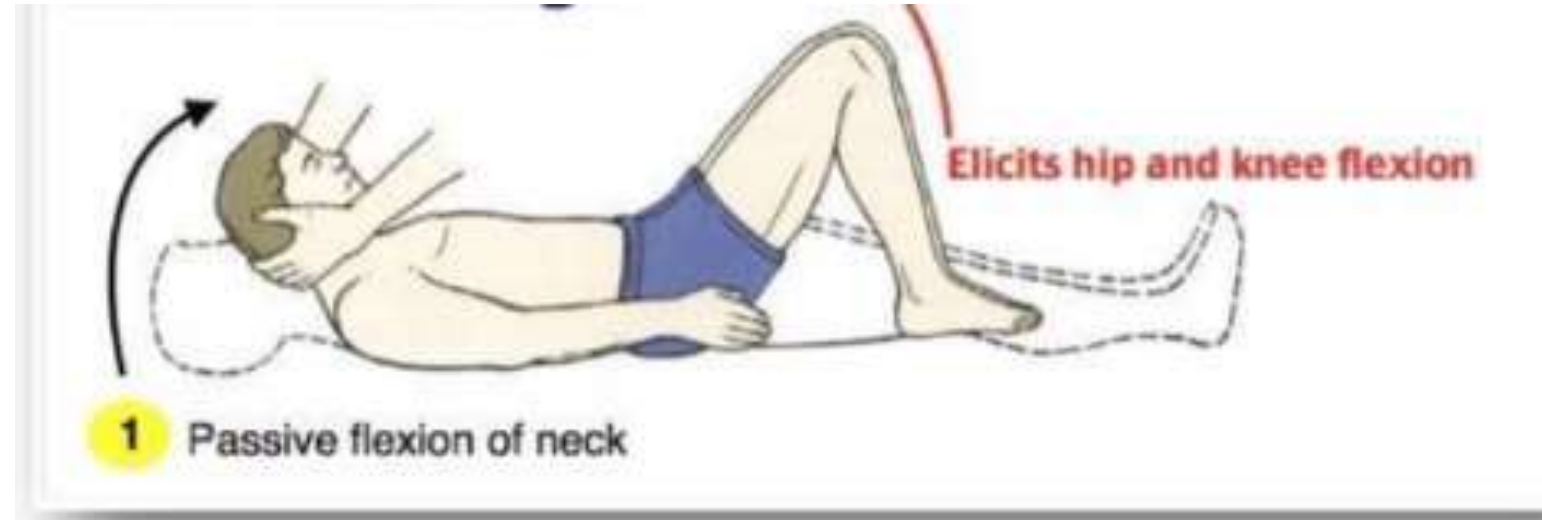


patient suffered from lower limb weakness , last year she was suffered from optic neuritis :

- A. Relapsing remitting
- B. secondary progressive
- C. isolated radiological
- D. isolated clinical

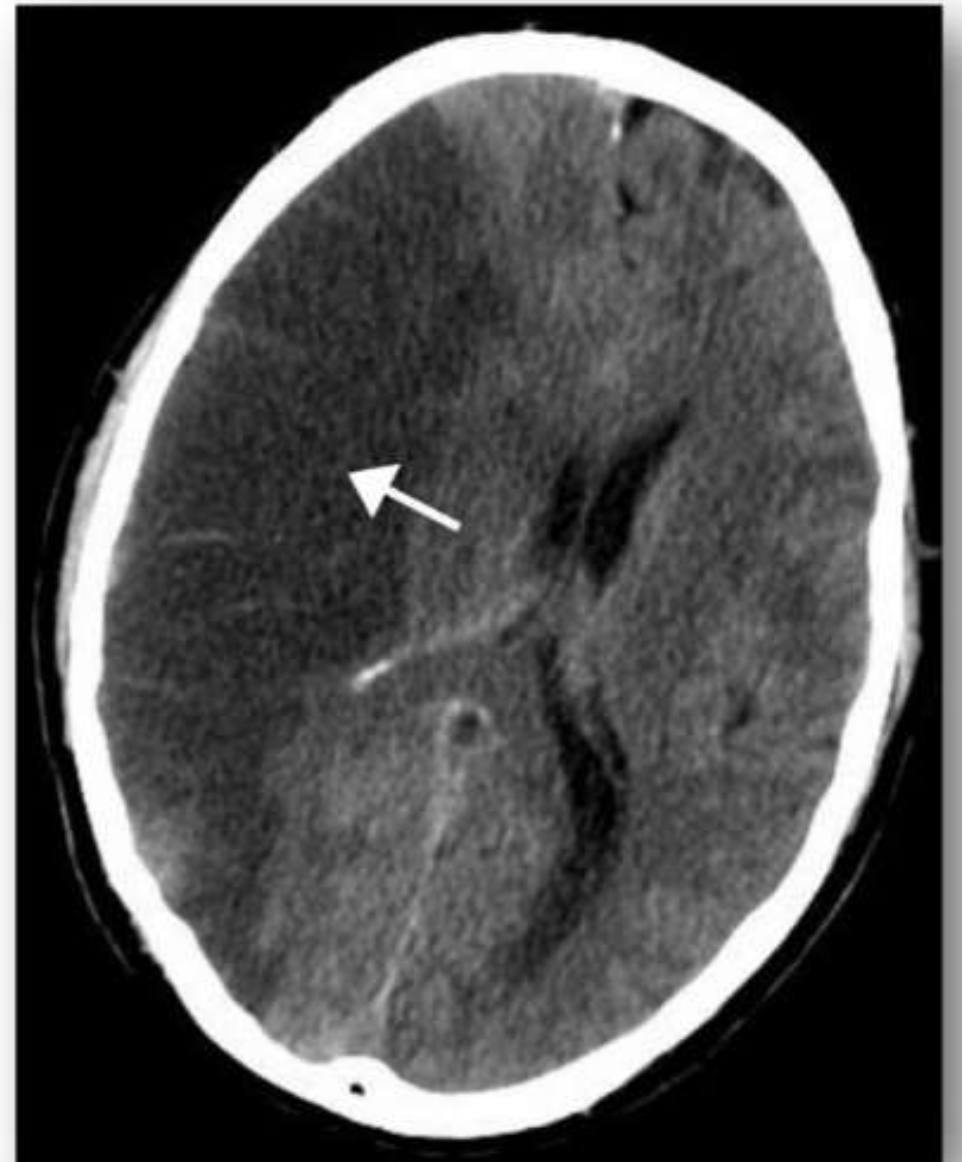

For meningeal irritation



All of these are risk factors for this condition except:

- A. Hypertension.
- B. Patent foramen ovale without DVT**
- C. Valvular heart disease.
- D. Atrial fibrillation.
- E. Left atrial hypertrophy



___ Predictive factors for successful seizure remission except :

- A single type of seizure
- Had no seizures for > 2 years
- A normal neurological exam and IQA
- normalized EEG on antiepileptic treatment
- Has multiple types of seizures

- All true about Paroxysmal hemicrania except :
 - May have up to 100 episodes per day
 - Strictly unilateral
 - Associated w autonomic symptoms
 - Treatment : endomethacin

- Function of oculomotor nerve except :
 - Movement of eye
 - Elevate eyelid
 - Pupillary reflex
 - Corneal reflex

- Which of the following is wrong about pseudobulbar palsy ?
- a. Absent jaw jerk
- b. Spastic tongue
- c. Difficulty in pronunciation

- Which of the following is true regarding sensory examination ?
-if you suspect Syringomyelia,you should test the pain and temperature sensation
- Which of the following is true regarding epilepsy ?
Atonic seizures are usually preceded by myoclonic jerk
- What is true regarding trigeminal nerve ?
- Jaw deviates to abnormal side in trigeminal lesion

- The score or degree of power if the patient can do active movement with gravity eliminated ?

- 2

- 3

- 4

- 1

Nabed
30th of August 2023

إعداد :

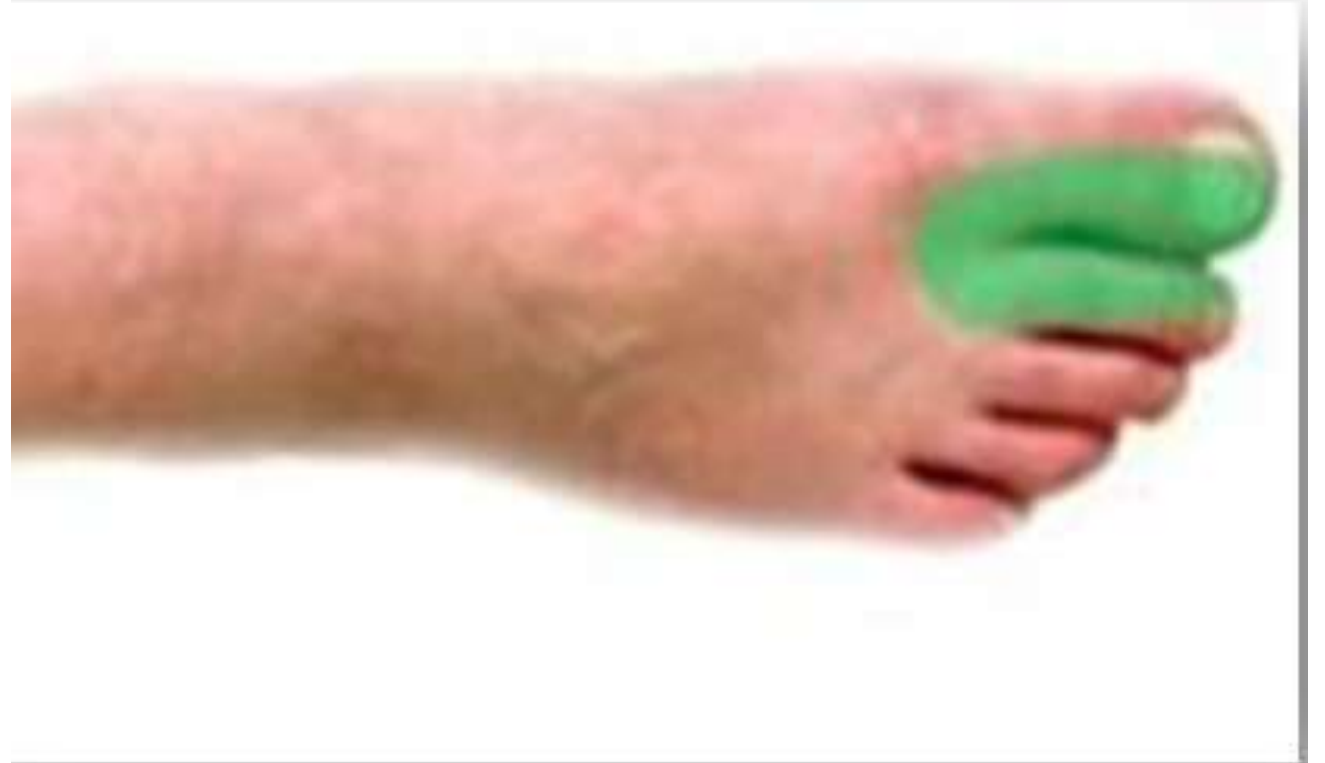خزامى عبد الفتاح سعادة

أميمة أنور البداينة

Q1. patient has sensory loss in the highlighted area , most likely clinical sign found :

- A. Weakness of tibialis anterior
- B. Weak eversion
- C. Plantar flexion upward

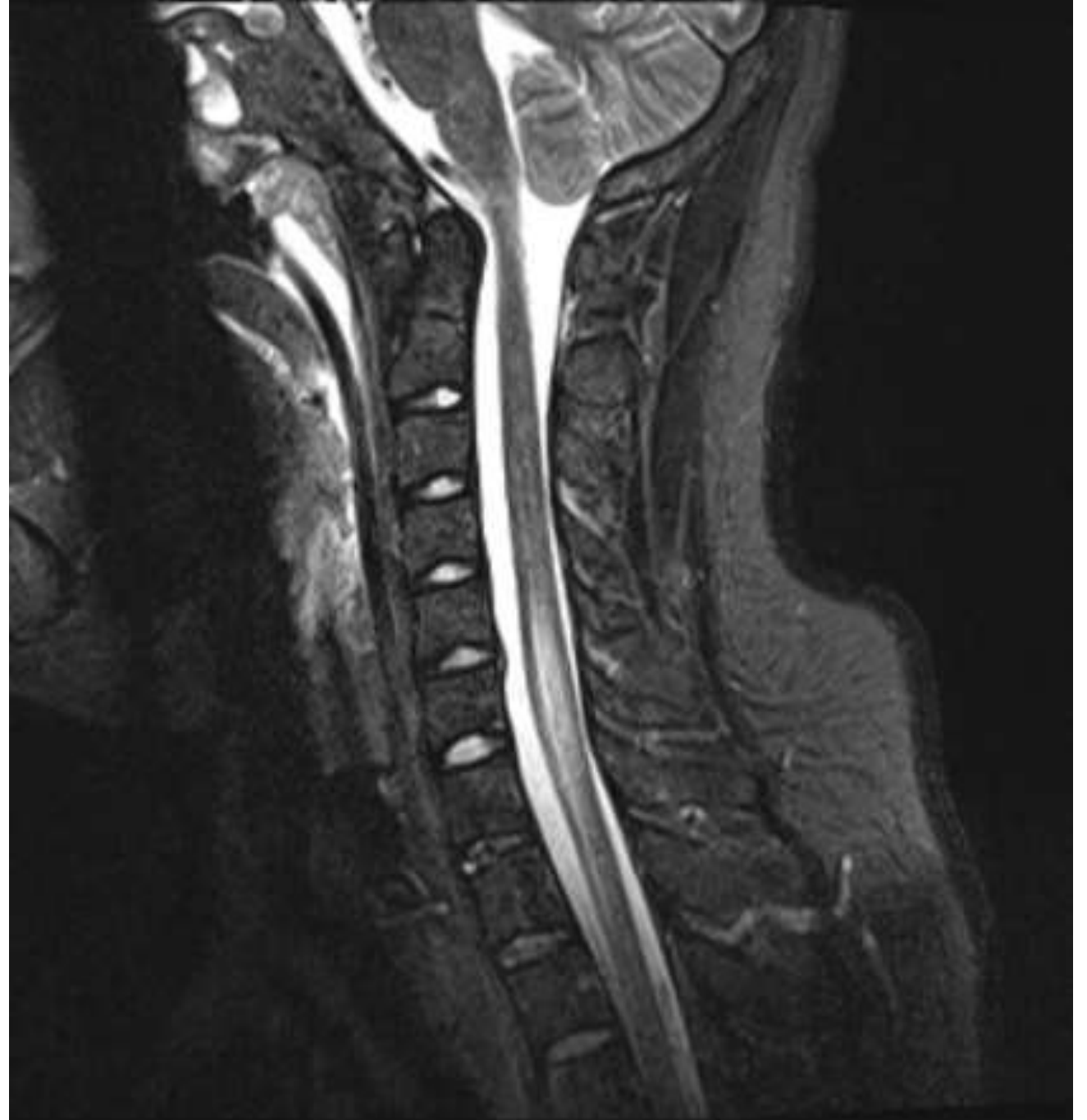ANSWER : A



Q2. Diagnosis

- A. T1 Transverse myelitis
- B. T2 Transverse myelitis
- C. T1 Syringomyelia
- D. T2 Syringomyelia

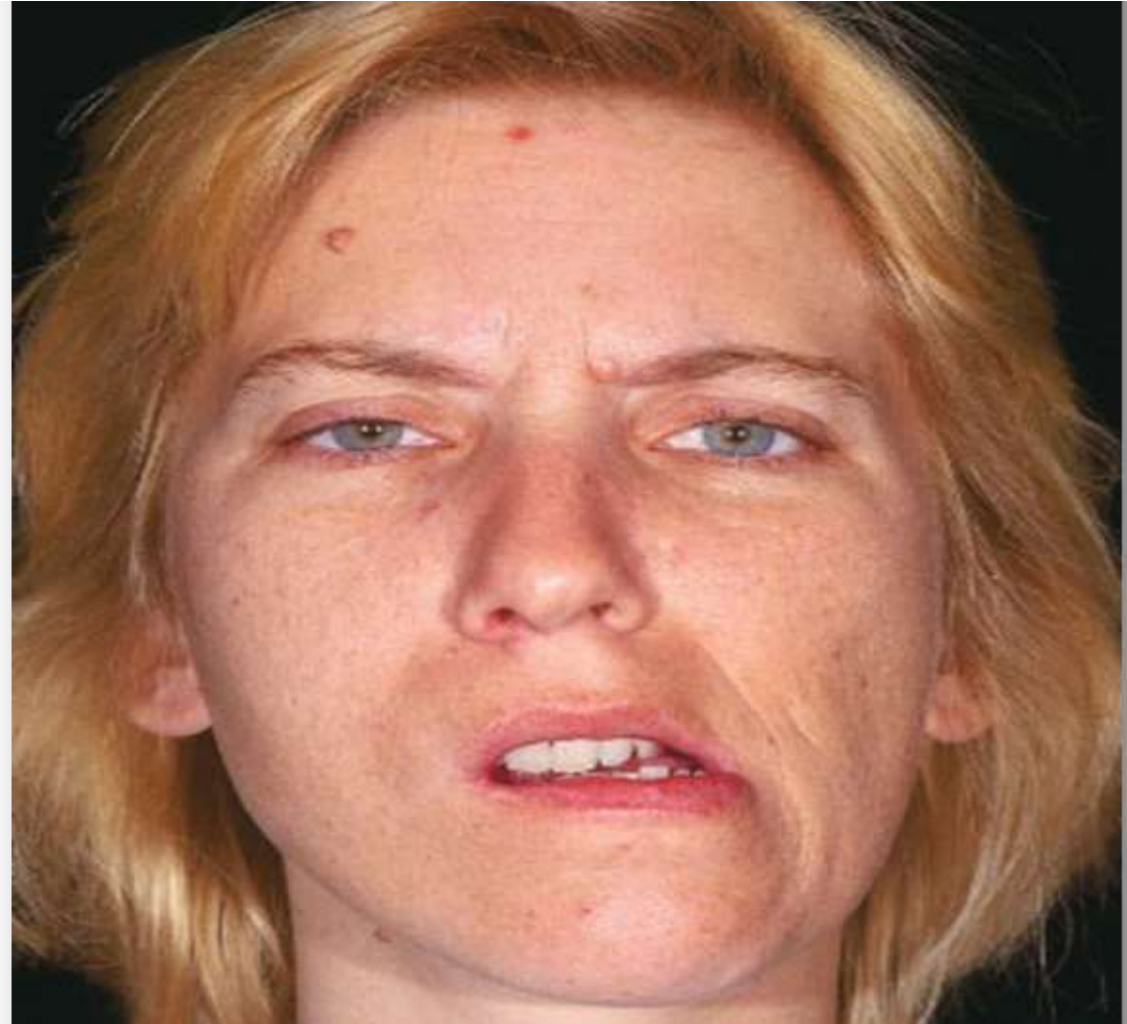ANSWER : B



Q3. Whats the muscle affected :

- A. Right pterygoid muscle
- B. Left pterygoid muscle

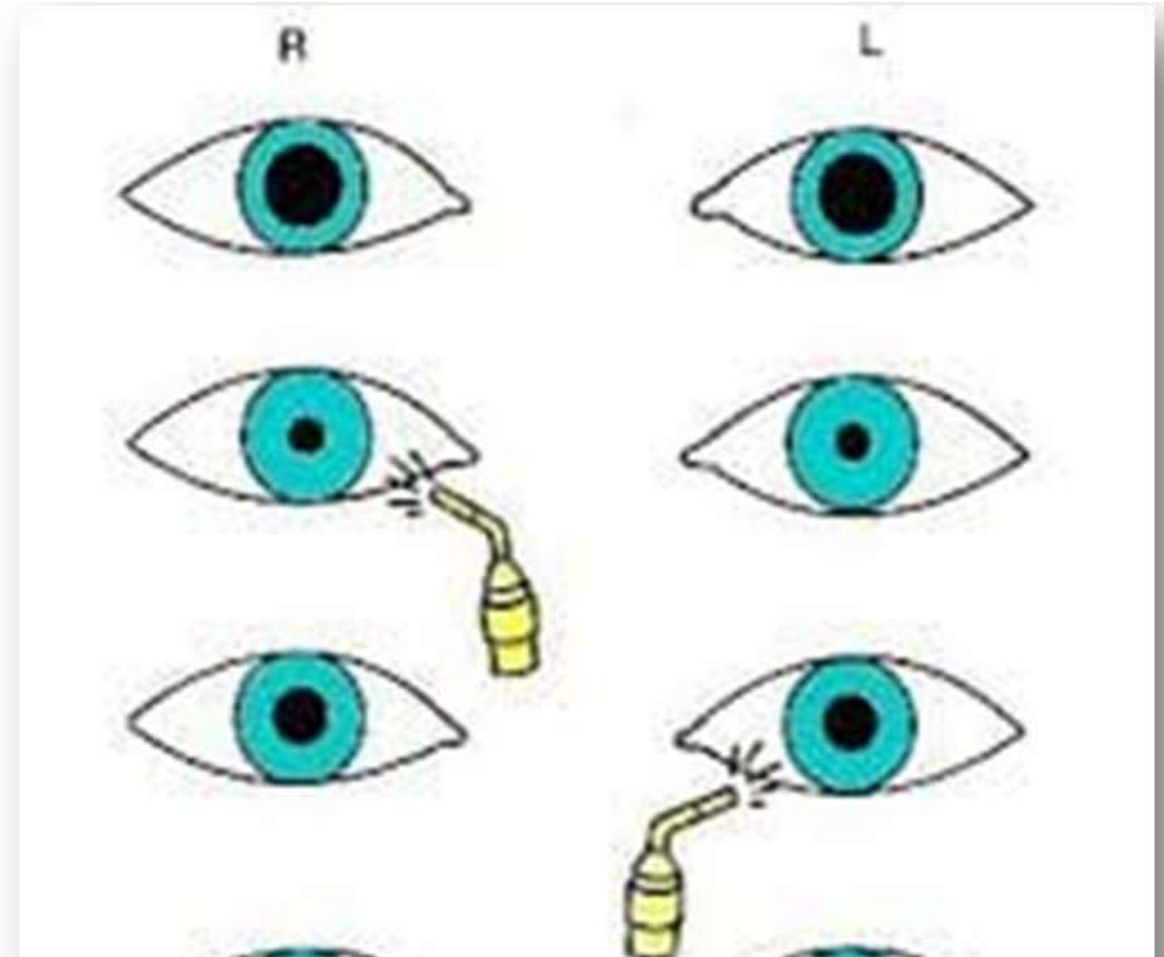
ANSWER : B



Q4. What is a possible cause for this ?

- A. Right optic neuritis
- B. Left optic neuritis
- C. Right oculomotor palsy
- D. Left oculomotor palsy
- E. Horner's syndrome

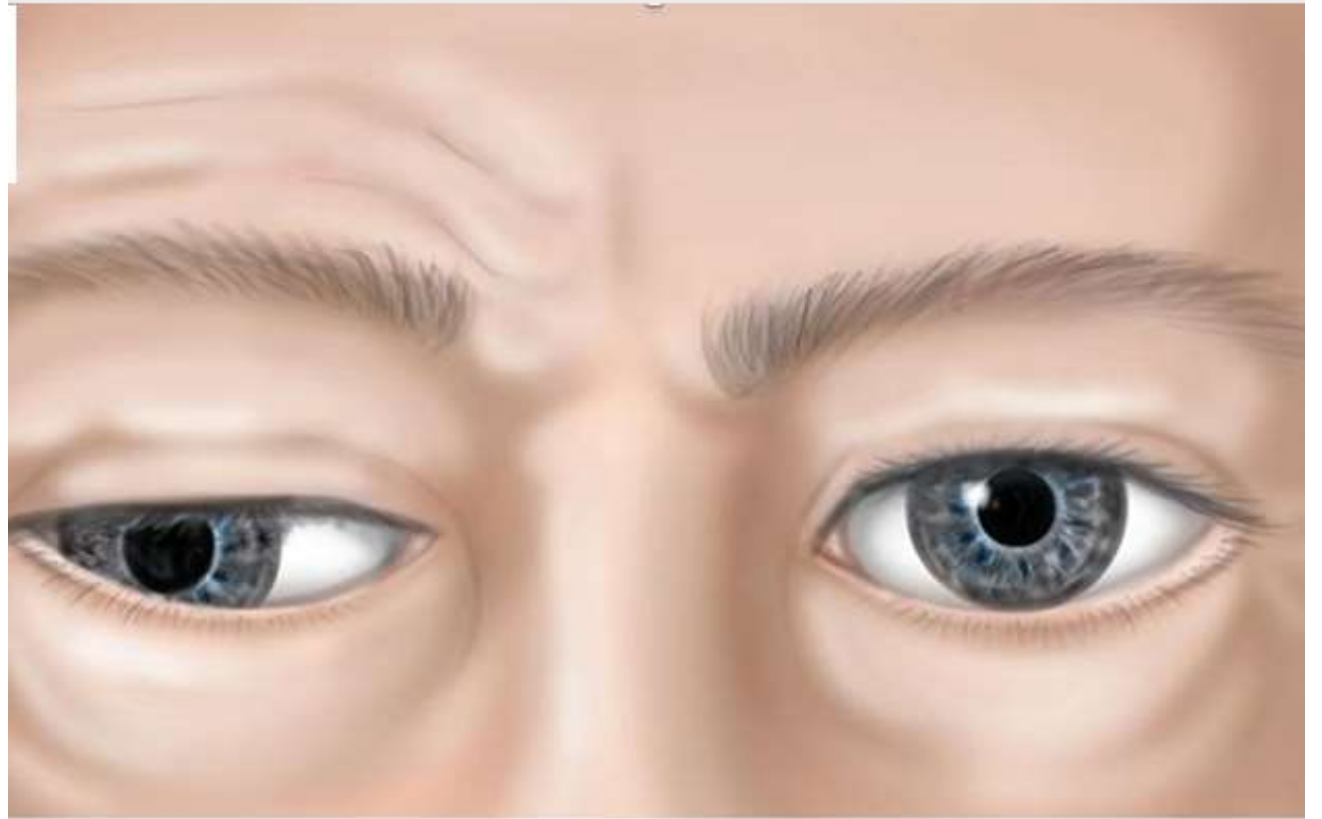
ANSWER : B



Q5. what's the abnormality :

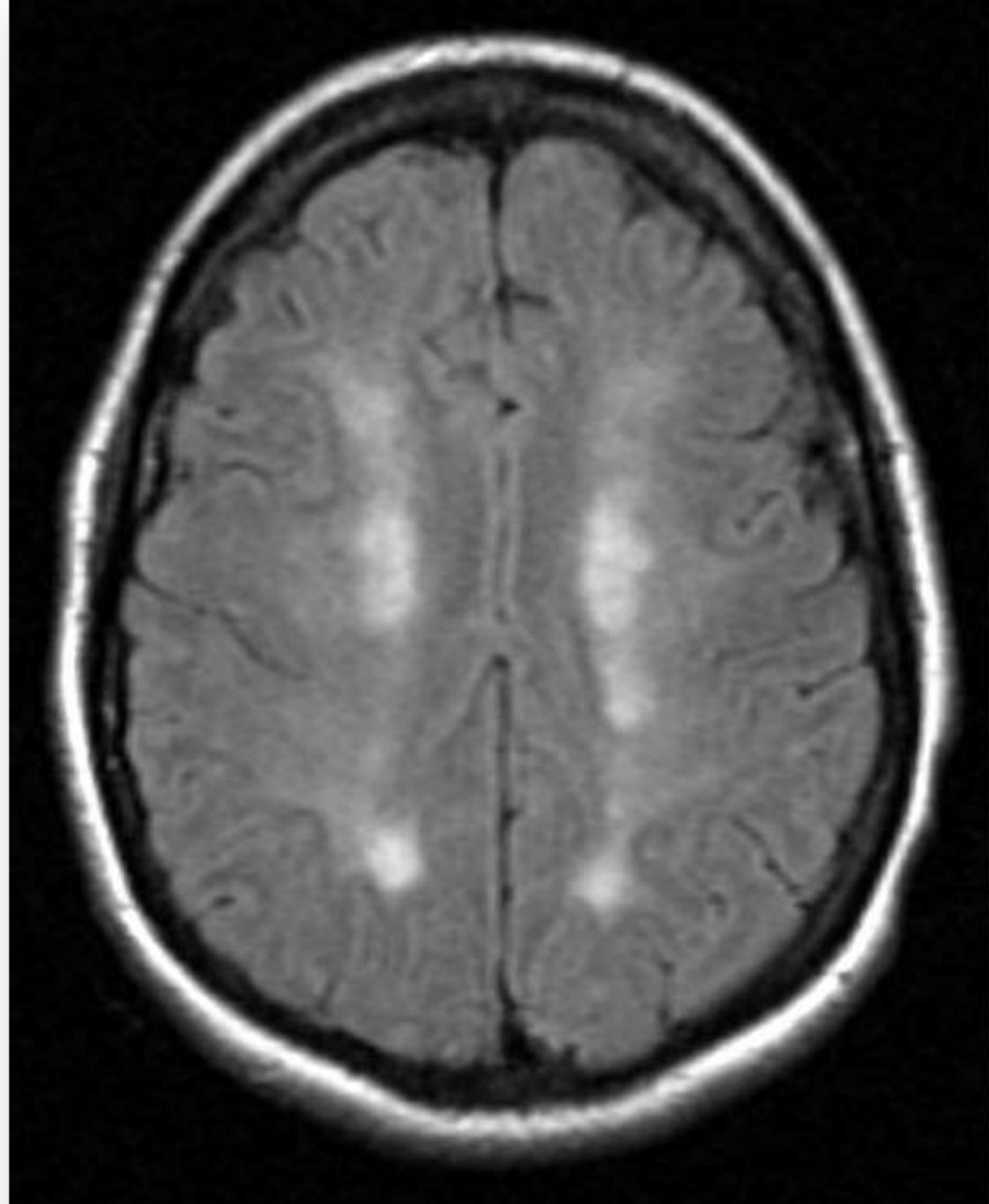
- A. left oculomotor palsy
- B. Right oculomotor palsy
- C. Right abducent
- D. Left trochlear

ANSWER : B



Q6. what's the cause of this lesion :

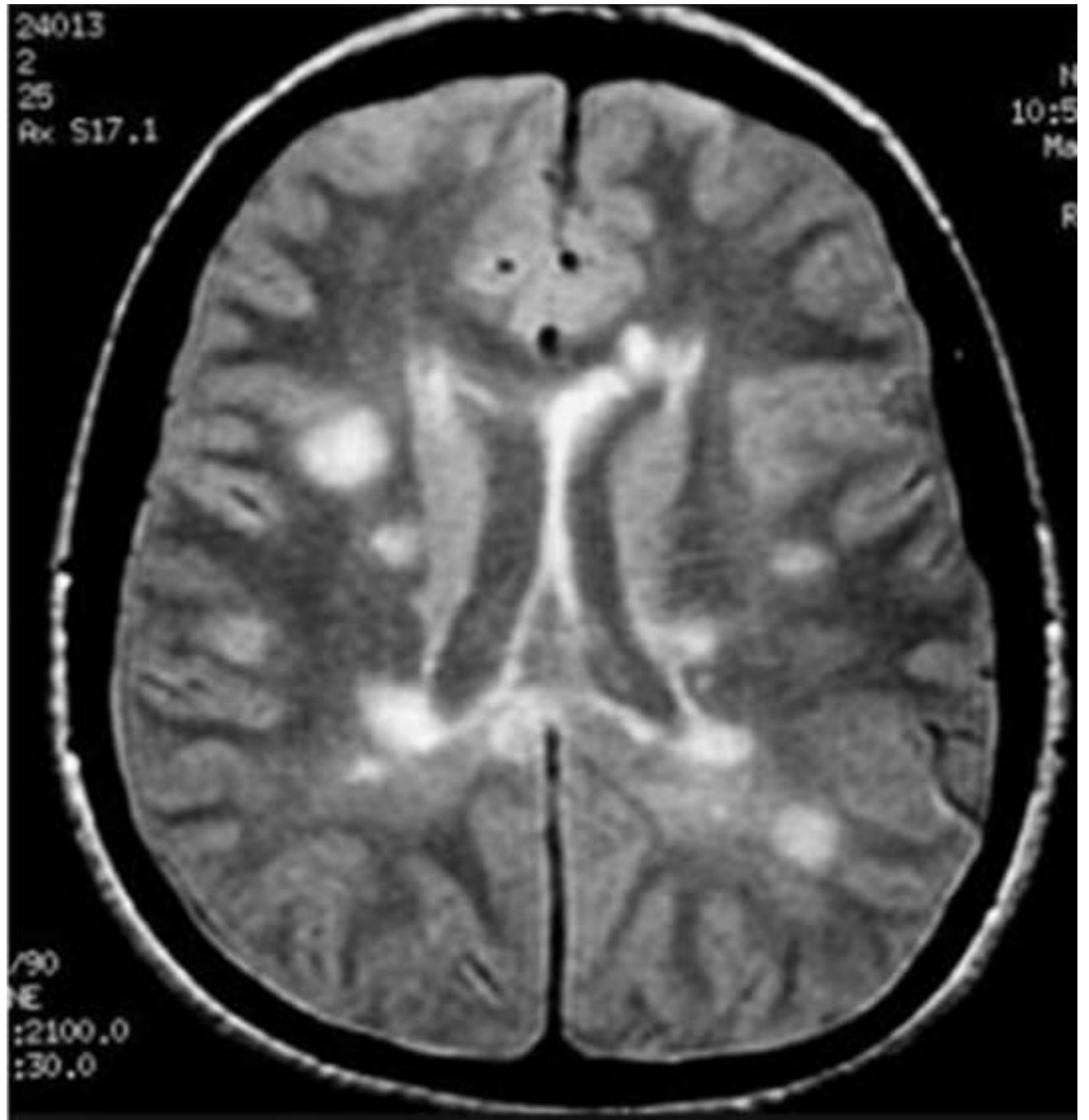
Sever hypotension



Q7. A patient had head trauma, what is the patient diagnosis

- A. Clinically isolated MS
- B. Radiologically isolated MS.
- C. Secondary progressive
- D. Primary progressive
- E. Progressive releasing

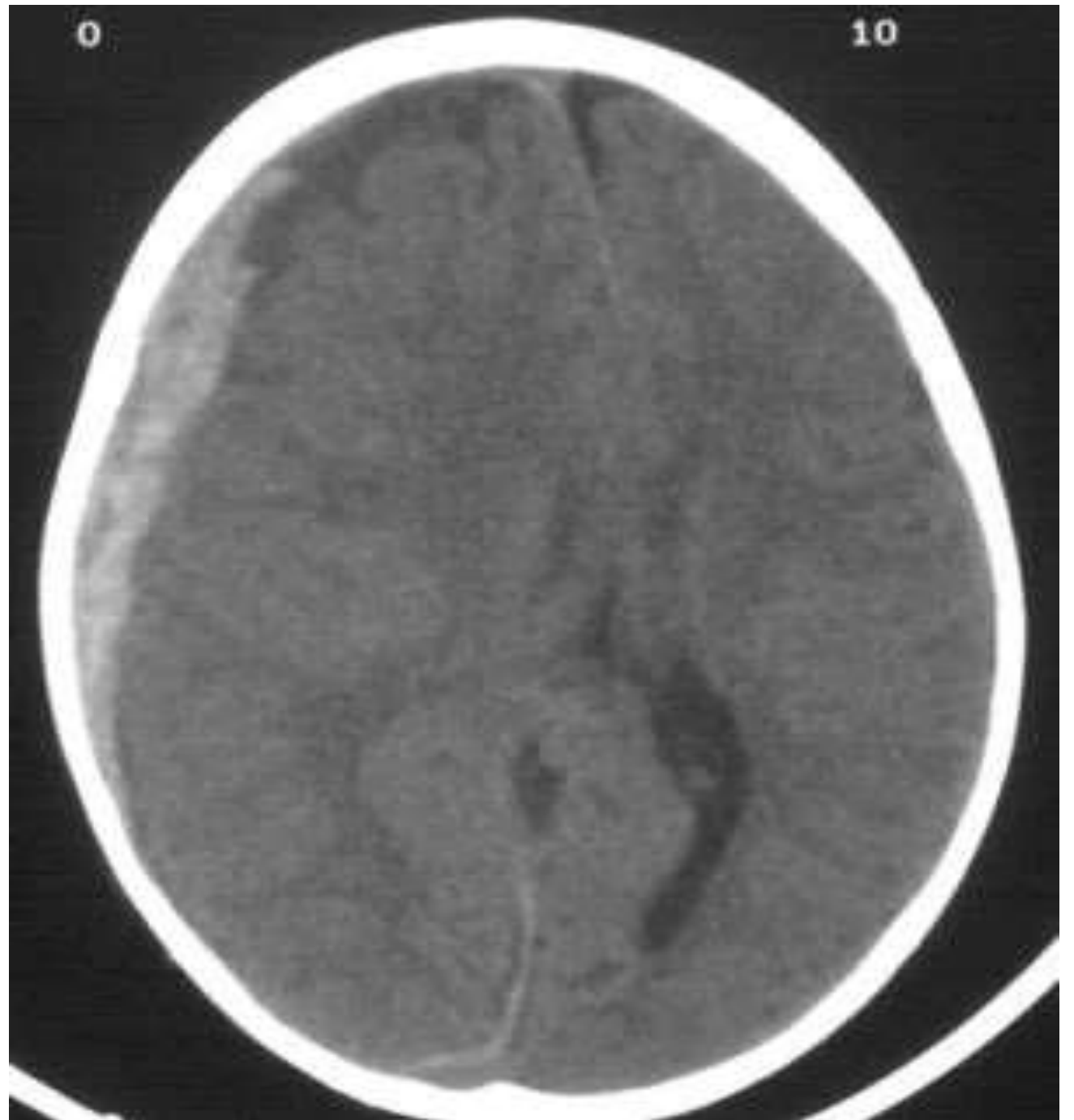
ANSWER : B



Q8. what's the name of the abnormality :

- A. subdural hematoma
- B. Intracranial hemorrhage

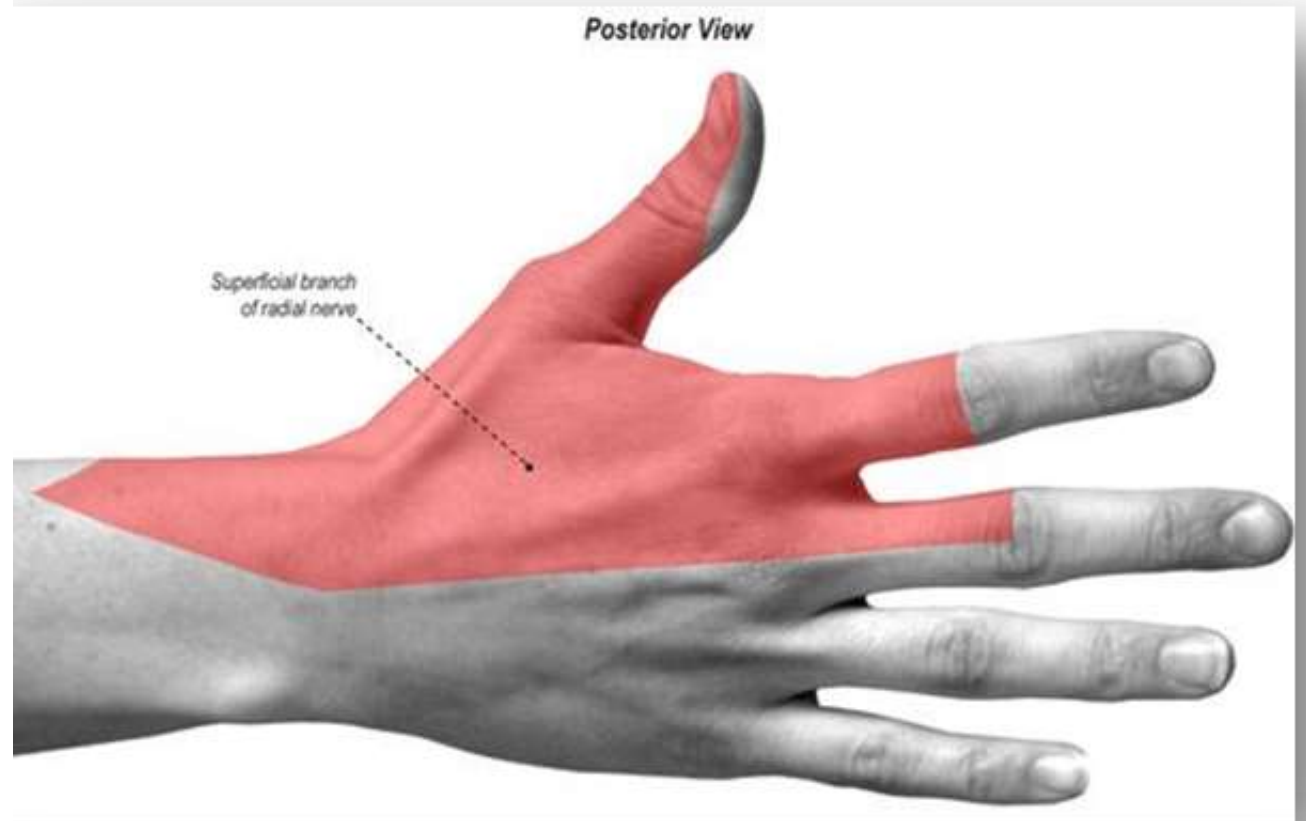
ANSWER : A



Q9. sensory loss in this area , which nerve is affected

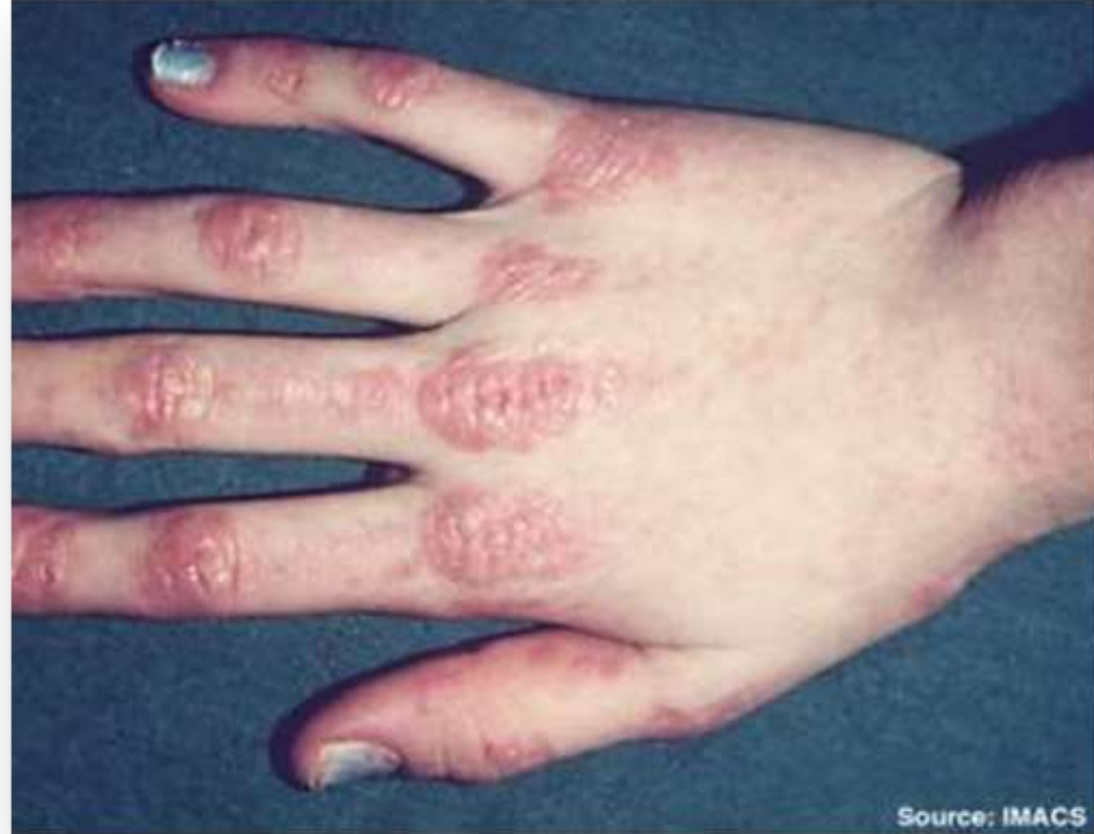- A. Posterior interosseous nerve
- B. Superficial radial nerve
- C. Median nerve
- D. Ulnar nerve

ANSWER : B



Q10. what's the most likely diagnosis :

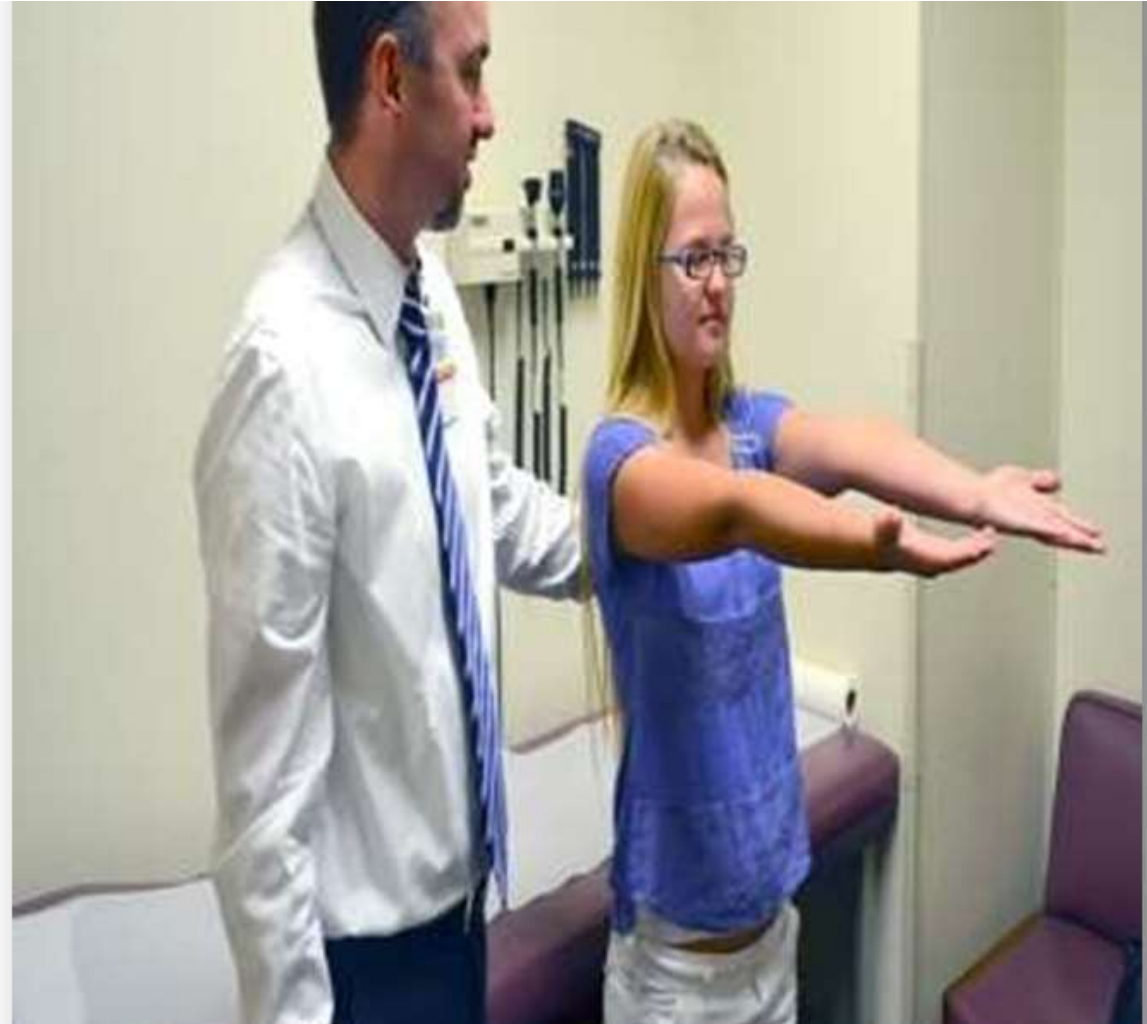Dermatomyositis



Q11. All of the following cause positive rombergs test except :

- A. Dorsal column lesion
- B. Diabetic polyneuropathy
- C. Large fibers polyneuropathy
- D. Impaired proprioception
- E. Small fiber polyneuropathy

ANSWER : E



Q12. A 20 years old patient came with weakness and numbness of lower extremities more than upper extremities, urine retention, & normal reflexes. The most important next step in diagnosis will be:

- A. Nerve conduction study
- B. Perform spinal MRI
- C. Perform lumbar puncture and CSF analysis
- D. Examine for dermatomal sensory loss
- E. Examine for glove and stocking sensory loss

ANSWER : B

Q13. All of the following tests are used in examination of cerebellar function except :

- A. Rebound test
- B. Tandem test
- C. Rapid alternating movement
- D. Trendelenburg's test
- E. Nystagmus

ANSWER : D

Q14. patient can perform active movements when gravity is eliminated , power score :

- A. 1
- B. 2
- C. 3
- D. 4
- E. 5

ANSWER : B

Q15. patient opens his eyes to verbal commands ,
produce incomprehensible sounds and localize pain
, his GCS :

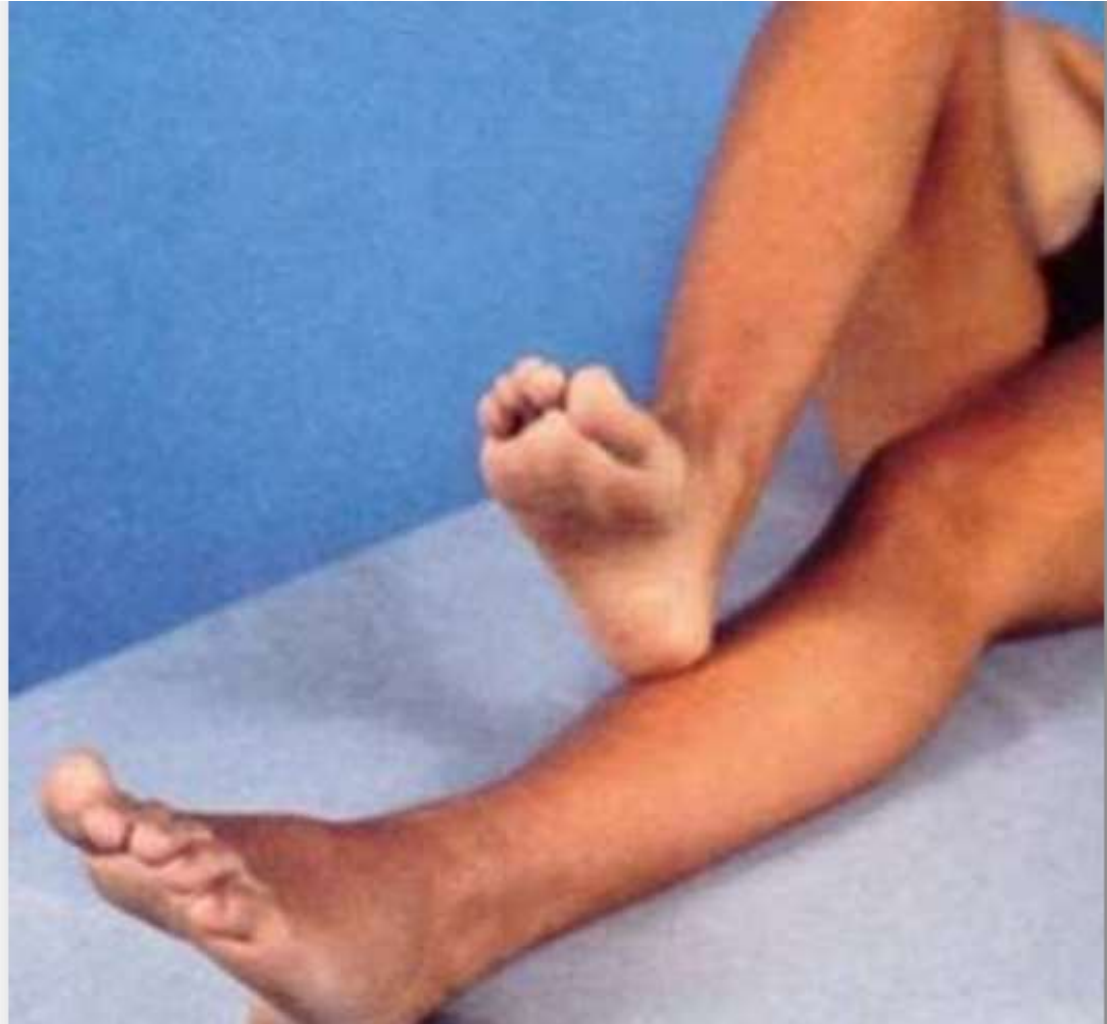
- A. 9
- B. 10
- C. 8
- D. 11
- E. 12

ANSWER : B

Q16. what's is this test examining :

- A. Left cerebellum
- B. Right cerebellum
- C. Right cerebral
- D. Left cerebral
- E. Dorsal columns

ANSWER : B



Q17. All of the following are correctly matched , except :

- A. Resting tremor is characteristic for Parkinson's disease
- B. Intention tremor increase while getting closer to the target
- C. Myoclonus is sudden and regular
- D. Hemiballismus is semivoluntary

ANSWER : C

Q18. all of the following are oculomotor nerve examinations , except :

- A. Accommodation
- B. Visual field
- C. Ptosis
- D. Eye opening
- E. Corneal reflex

ANSWER : E

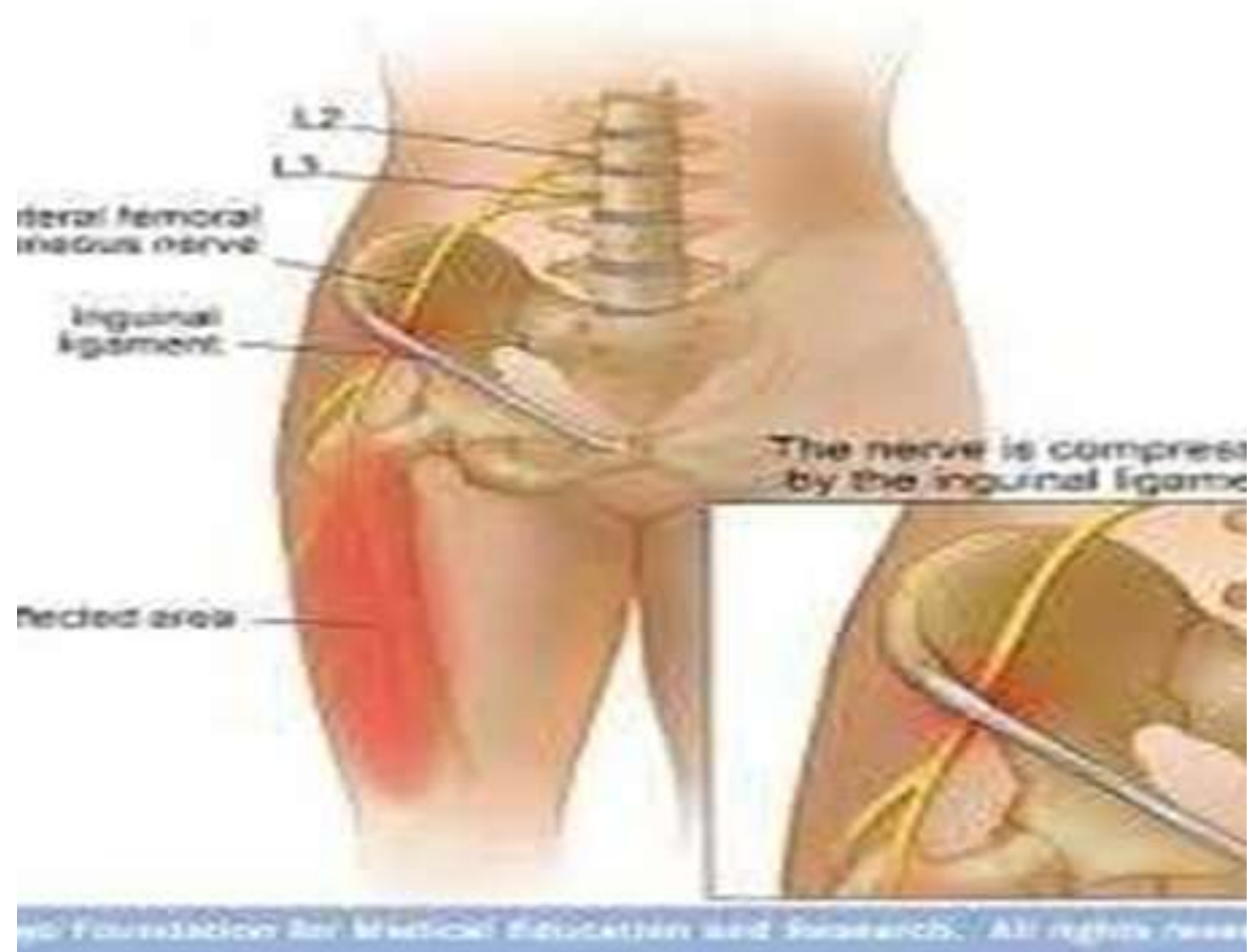
Q19. 75 years old male came with acute stroke. He has right side weakness. He has spontaneous speech with occasional paraphrasic errors. He can understand and follow commands, but repetition is severely affected. Which of the following best explains his speech pattern?

- A. Broca aphasia
- B. Transcortical aphasia
- C. Conduction aphasia
- D. Wernicke aphasia
- E. Global aphasia

ANSWER : C

Q20. 39 patient has sensory loss in the highlighted area, this patient suffers from what ?

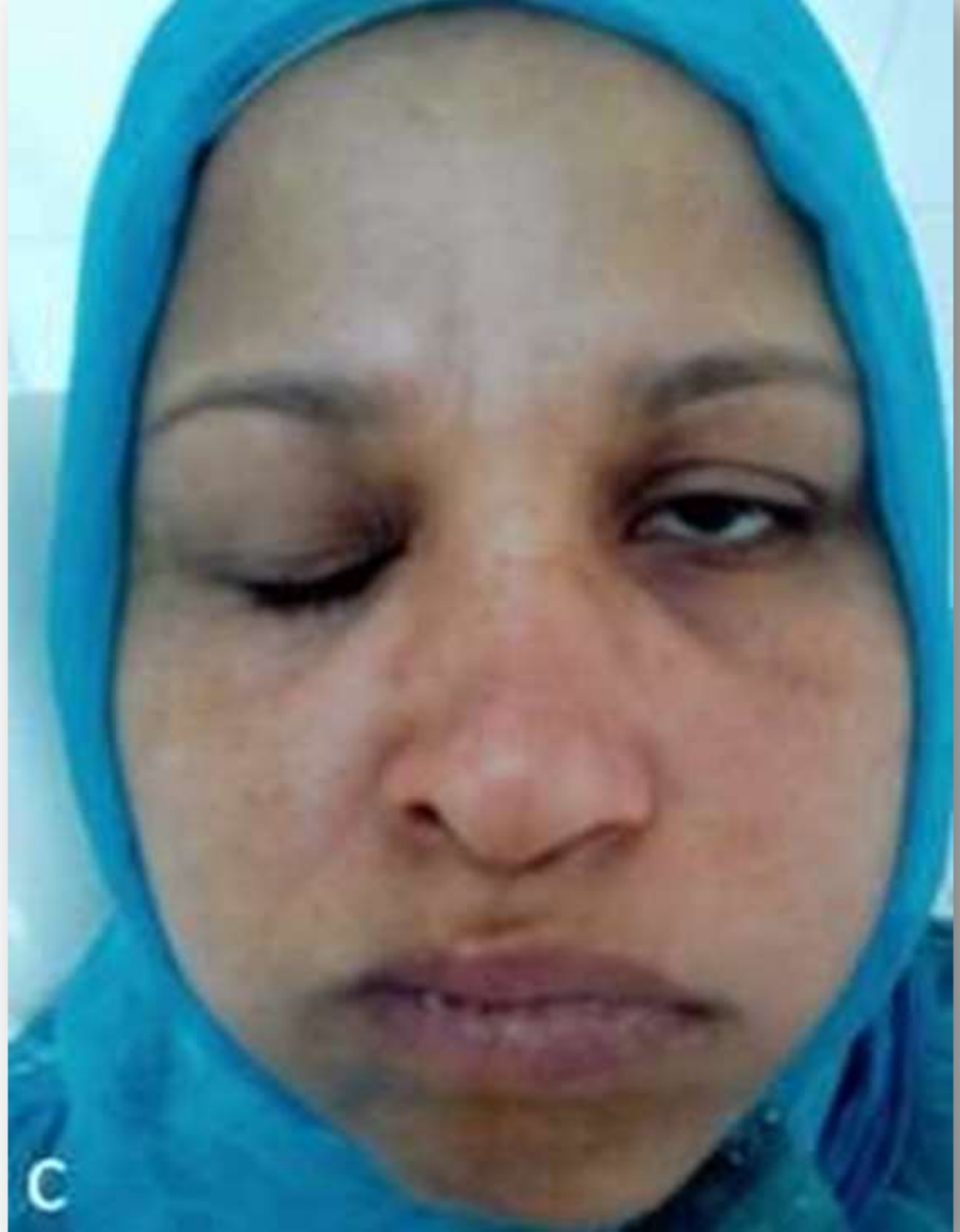Meralgia paresthetica



Q21. The patient may have one of the following :

- A. Tongue deviation
- B. Left ear hearing loss
- C. Left external meatus rash

ANSWER : C



Q22. Which Guillain-Barre variant is associated with ophthalmoplegia, ataxia and areflexia and tends to be associated with GQ1B antibodies?

- A. Acute inflammatory demyelinating polyneuropathy
- B. Chronic inflammatory demyelinating polyneuropathy
- C. Multifocal motor neuropathy
- D. Miller-fisher syndrome
- E. Acute motor axonal neuropathy

ANSWER : D

- .One of the following is main feature of trigeminal nerve injury:
- a) loss of taste sensation of the anterior 2/3 of the tongue
- b) loss of taste sensation of posterior 1/3 of the tongue
- c) jaw hyperreflexia*****
- d) loss of touch sensation of the posterior 1/3 of the tongue

- 50 years old female pt came to ER with progressive severe headache , your initial investigation to do :
- a) esr and crp *****
- b) spinal cord mri
- c) csf analysis
- d) brain CT scan
- e) brain mri

- the name of this test is :
- a) dix hallpike *****
- b) eply maneuver
- c) pure tone audimetry
- d) gallbelar test

- one of the following is the main common manifestations of Meniere's disease :
- a) otoliths in endolymphatic fluid
- b) excessive endolymph *****
- c) bilateral hearing loss
- d) no hearing loss
- e) diagnosed by Dix-Hallpike maneuver

- pt look to the right , fast fase of nystagmus to the left , what's the type of nystagmus?
- a) right gerky nystagmus
- b) left gerky nystagmus *****
- c) multidirectional nystagmus
- d) left pendular nystagmus
- e) right pendular nystagmus

- pt presented with symmetrical loss of position, touch , vibration sensation of both feet up to the ankle joint, all the following can cause this condition except:
 - a) severe DM pt
 - b) spinal cord injury
 - c) large nerve injury
 - d) small nerve injury *****
 - e) chronic polyneuropathy

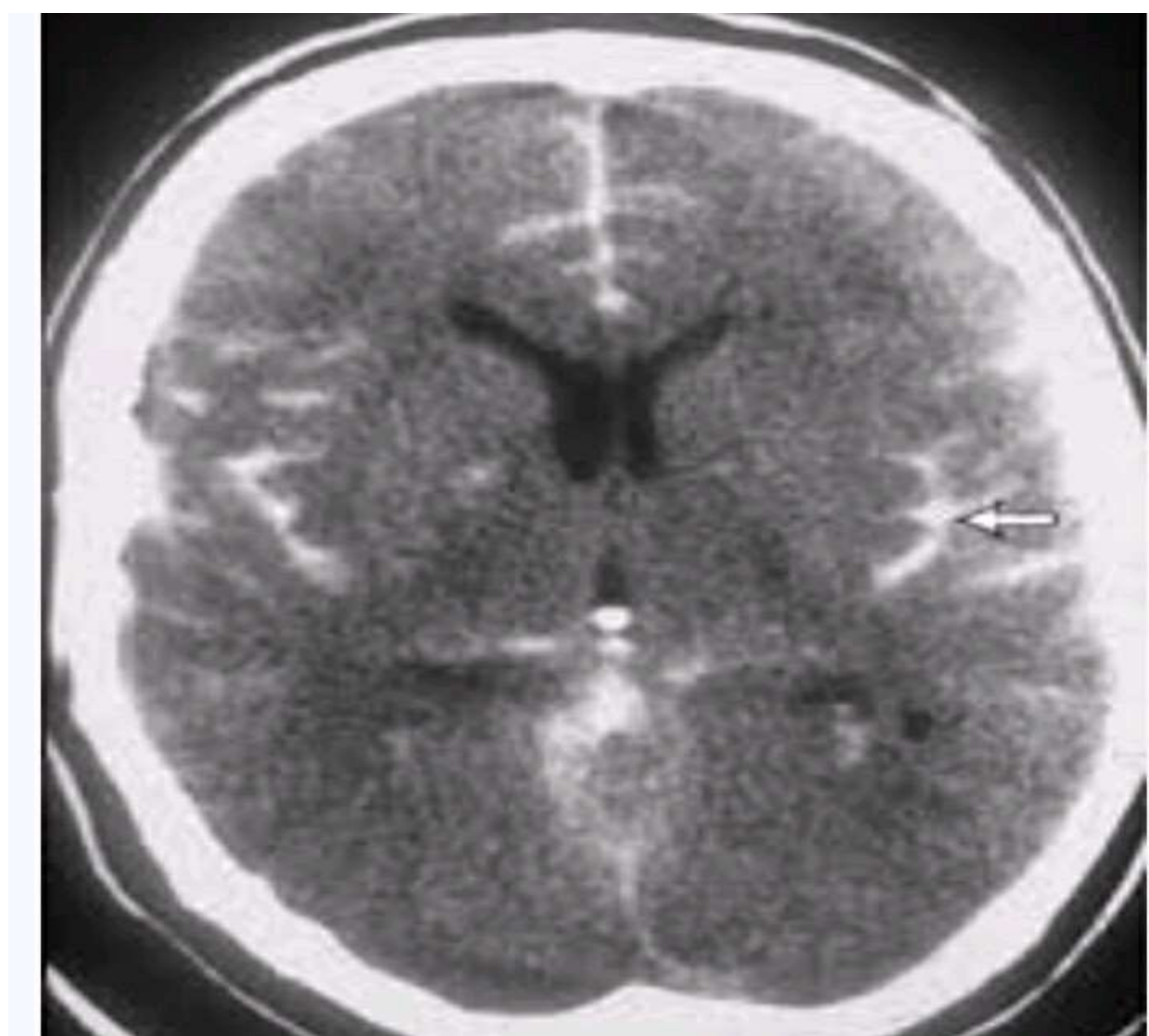
- pt presented with status epilepticus , he was given 10mg of diazepam , but didn't get better he was given another 10mg but doesn't work what is the next step ?
- a) 20 mg phentoin + saline for 2 minutes
- b) 20 mg phentoin + glucose and normal saline
- c) 20 mg phentoin + glucose
- d) 20 mg phentoin + normal saline *****

- one of the following is common manifestations of pseudobulbar palsy except:
- a) absent jaw reflex ****
- b) brisk jaw reflex
- c) spastic tongue
- d) no nasal speech
- e) absence of flaccid tongue

- all the following true about mini mental state examination except:
- a) score of 26 indicates mild cognitive impermanent *****
- b) recall is mention three object test
- c) test indicates attention and calculation
- d) registration part of the test
- e) orientation part of the test

- the name of sign in given picture is :
- a) brudziniski sign
- b) kernig sign*****
- c) trendelperg sign

- dx ??
- a) sub
- arcanoid
- hemorrhage



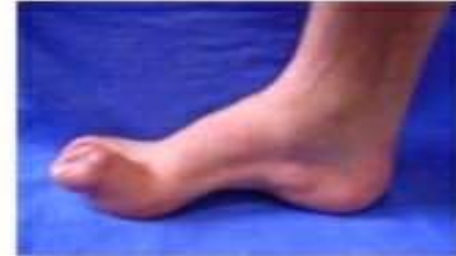- which of the following ass with facial nerve injury:
- a) hyperacoustic stapedius paralysis*****
- b) pterygoid paralysis
- c) intact facial expressions
- d) loss of jaw reflex

- one of the following ass with optic nerve examination:
- a) red glass test
- b) down and out position
- c) corneal reflex *****
- d) efferant pupillary defect

- نفس السؤال والصورة حرفي أرشيف

Charcot–Marie–Tooth disease

- ❖ In NCS (nerve conduction study) the patient showed **demyelination** so what's the diagnosis ?
 - Charcot–Marie–Tooth disease



- b : super marginally low
هون برضو حرفي بي اضااف الدكتور عند

❖ These are CSF results, what do you expect the cause of these findings in A and in B?

- A: TB meningitis
- B: Acute bacterial meningitis

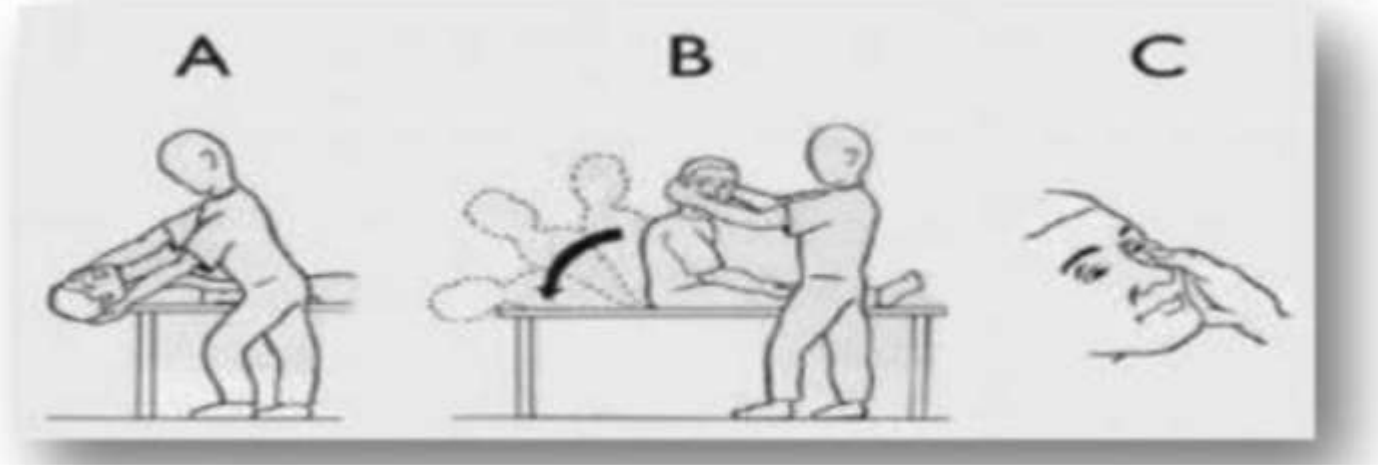	A	B
Opening pressure	elevated	elevated
WBCs	Elevated mainly lymphocytes	Elevated mainly neutrophils
RBCs	none	few
Glucose	Significantly low	low
Protein	high	high
Appearance	turbid	turbid

○ **Neuromedicine 4/10/2023**

- 75 years old male came with acute stroke. He has right side weakness. He has paraphrasic errors. He cannot understand and follow commands, and repetition affected. *Which of the following best explains his speech pattern?
- -wernike aphasia

- Vagus nerve and glossopharyngeal nerve are responsible for the followings except :
 - Gag reflex
 - Taste sensation og posterior 1/3 of tongue
 - Swallowing
 - Deviation of tongue

- What is the name of test? Dix-Hallpike maneuver



- Eye open to verbal command, Incomprehensible sound, and localizes pain.
- **Gcs=10**
- Gcs 10
- Gcs =5
- Gcs = 12

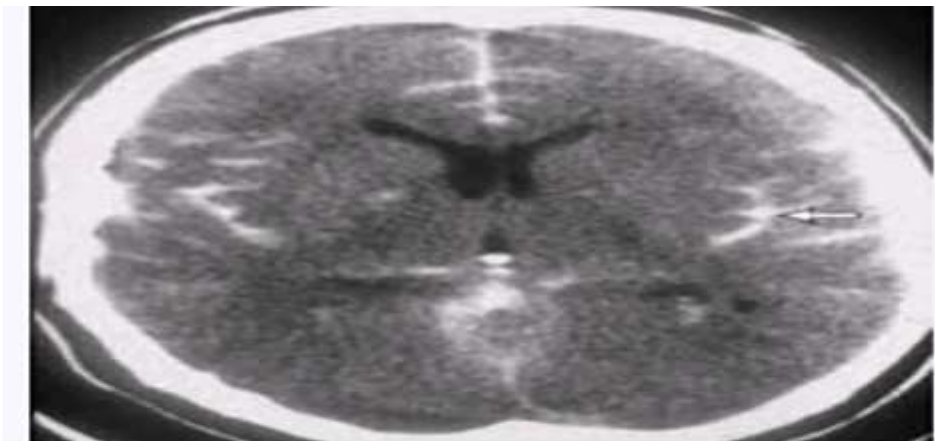- Patient looks to right, fast phase of nystagmus to left, what is the type of nystagmus ?
- A. Right jerky nystagmus.
- **B. Left jerky nystagmus.**
- C. Right pendular nystagmus.
- D. Left pendular nystagmus.
- E. Multidirectional nystagmus

- pt presented with status epilepticus , he was given 10mg of diazepam , but didn't get better he was given another 10mg but doesn't work what is the next step?
- a) 20 mg phentoin + saline for 2 minutes
- b) 20 mg phentoin + glucose and normal saline
- c) 20 mg phentoin + glucose
- d) 20 mg phentoin + normal saline*****

- all the following true about mini mental state examination except:
- a) score of 26 indicates mild cognitive impermanent*****
- b) recall is mention three object test
- c) test indicates attention and calculation
- d) registration part of the test
- e) orientation part of the test

• the name of sign in given picture is: • a) brudziniski sign • b) kernig sign***** • c) trendelberg sign

- dx??
- a) sub
- aracanoid
- hemorrhage



- What is true regarding trigeminal nerve ?
 - **Jaw deviates to abnormal side in trigeminal lesion**
-

- The score or degree of power if the patient can do active movement with gravity eliminated ?

- **2**
- 3
- 4
- 1

- Which of the following is true regarding sensory examination ?

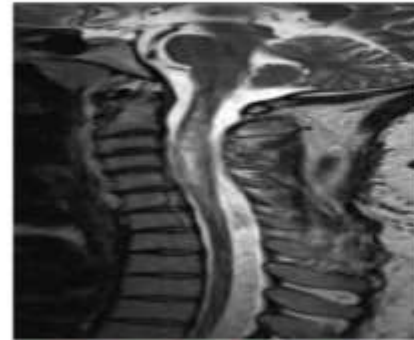
-if you suspect Syringomyelia, you should test the pain and temperature sensation

- Which of the following is wrong about pseudobulbar palsy ?
 - a. Absent jaw jerk
 - b. Spastic tongue
 - c. Difficulty in pronunciation

- All of these test are for cerebellum except :
 - Finger to nose tes
 - Heel to shin test
 - Rapid alternating movement
 - Rebound test
 - Romberg test

Q8- What is the diagnosis?

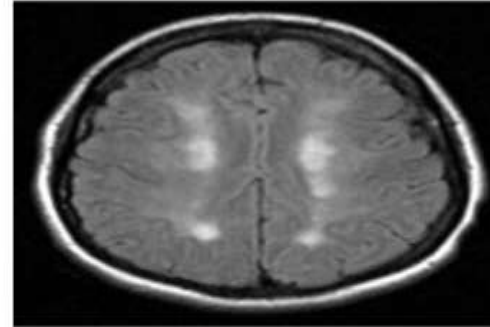
- a. T1 Transverse myelitis
 - b. T2 Transverse myelitis**
 - c. T1 syringomyelia
 - d. T2 syringomyelia
 - e. None of the above
- Note: T1 and T2 are meant to mean T1-weighted MRI & T2-weighted MRI and not T1 spine



NOT THE SAME PICTURE

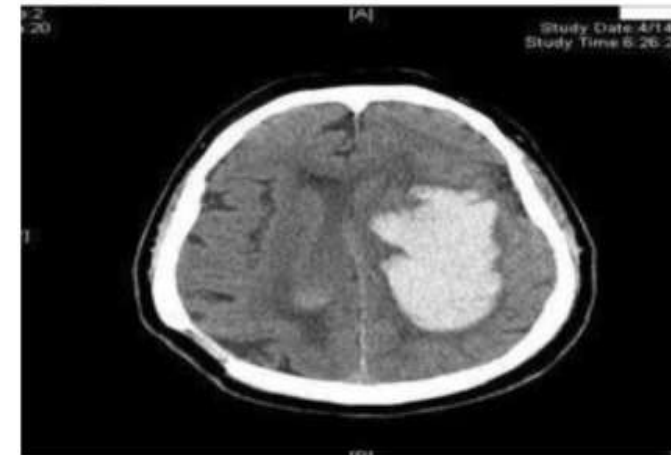Q18- This condition is caused by ?

- A. Severe hypertension
- B. Severe hypotension**
- C. Encephalitis
- D. Meningitis
- E. Vasculitis



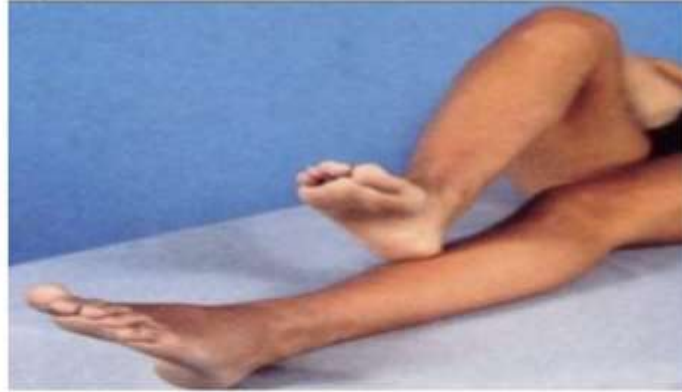Q19- What is the diagnosis?

- A. Intracranial hemorrhage**
- B. Vasogenic edema
- C. Cerebral infarction
- D. Multiple sclerosis
- E. Watershed infarction

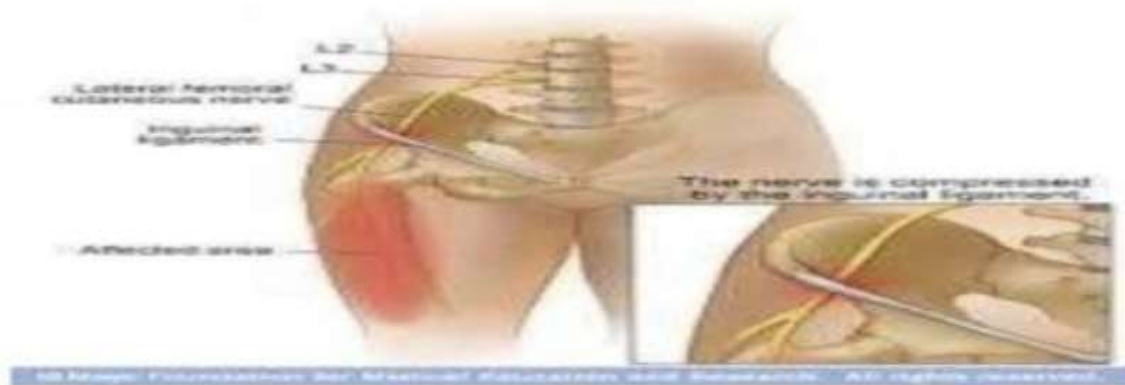


Q3-This test is used for detect the function of:

- A. Right cerebellum
- B. Left cerebellum
- C. Right cerebral
- D. Left cerebral
- E. Dorsal columns



The name of this condition?
Meralgia paresthetica



- b : super marginally low هون برضو حرفي بي اضاف الدكتور عند

❖ These are CSF results, what do you expect the cause of these findings in A and in B?

- A: TB meningitis
- B: Acute bacterial meningitis

	A	B
Opening pressure	elevated	elevated
WBCs	Elevated mainly lymphocytes	Elevated mainly neutrophils
RBCs	none	few
Glucose	Significantly low	low
Protein	high	high
Appearance	turbid	turbid

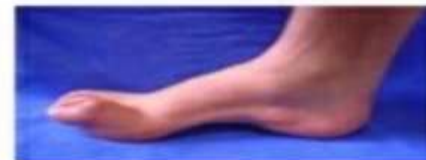الجنة
الجنة

- نفس السؤال والصورة حرفي أرشيف

Charcot–Marie–Tooth disease

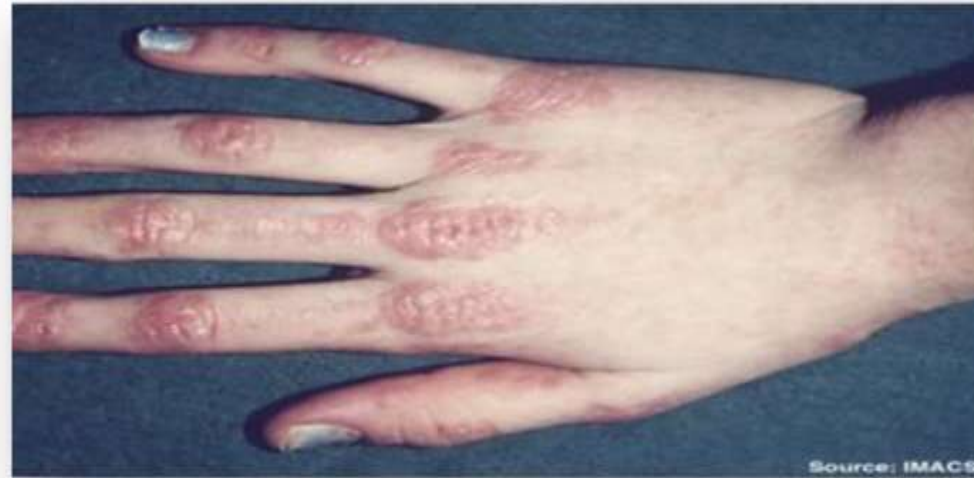❖ In NCS (nerve conduction study) the patient showed **demyelination** so what's the diagnosis ?

- Charcot–Marie–Tooth disease



Q10. what's the most likely diagnosis :

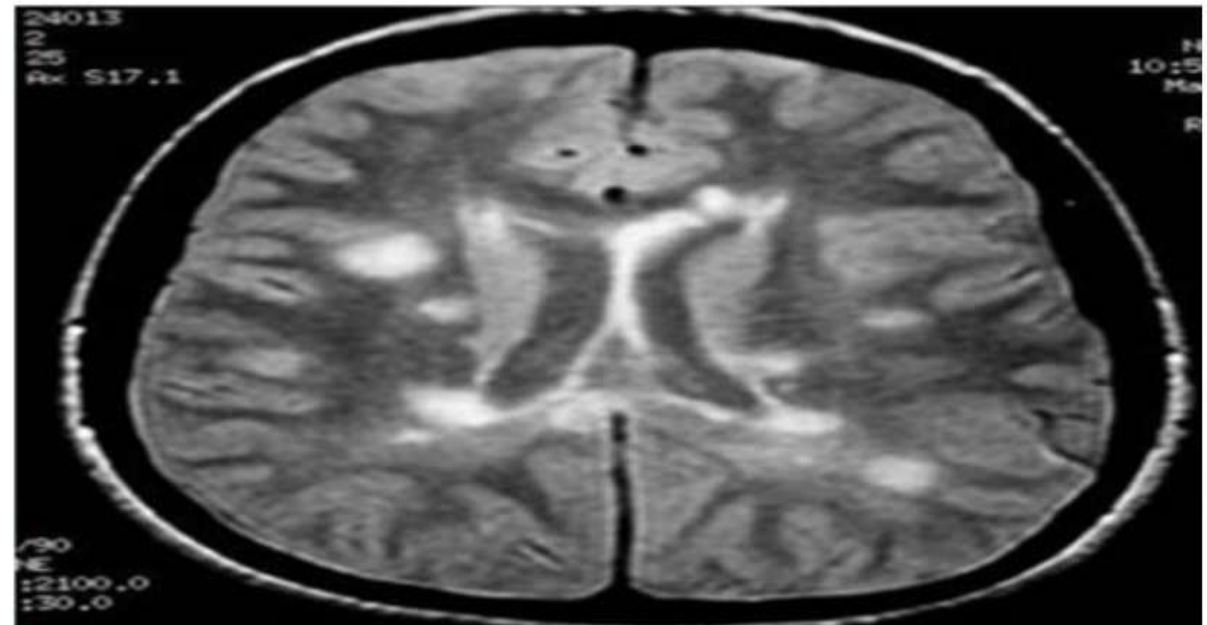
Dermatomyositis



Q7. A patient had head trauma , what is the patient diagnosis

- A. Clinically isolated MS
- B. Radiologically isolated MS.
- C. Secondary progressive
- D. Primary progressive
- E. Progressive releasing

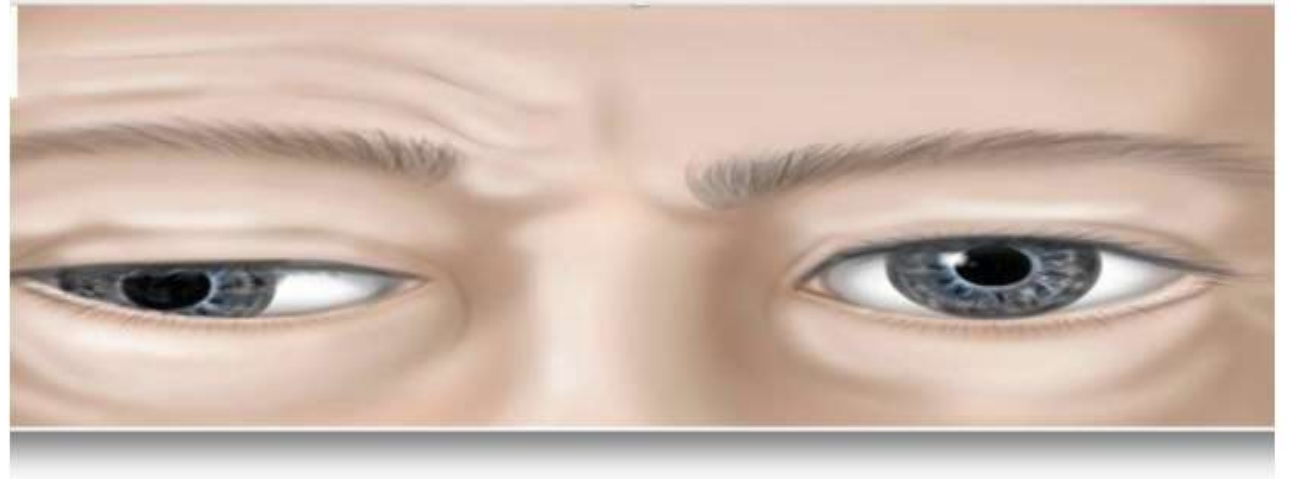
ANSWER : B



Q5. what's the abnormality :

- A. left oculomotor palsy
- B. Right oculomotor palsy
- C. Right abducent
- D. Left trochlear

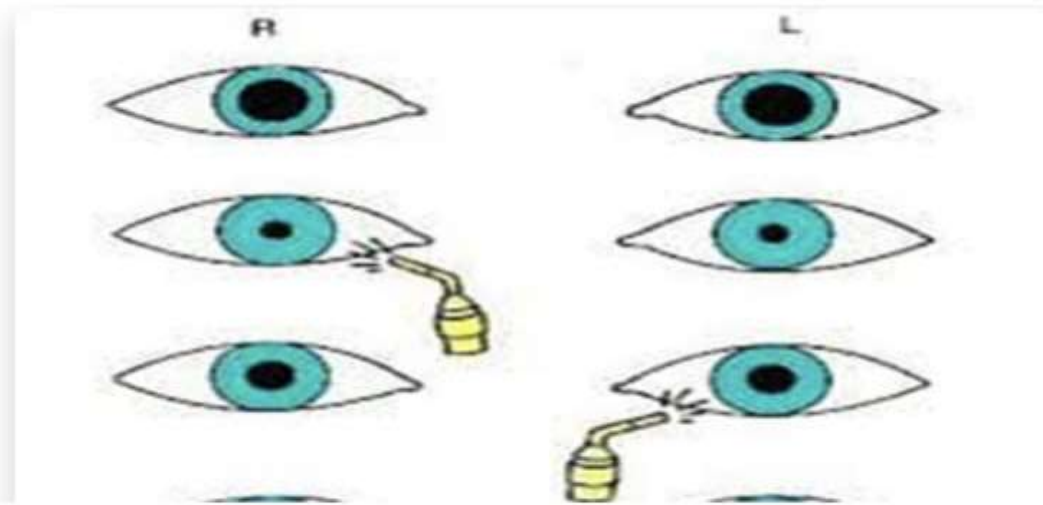
ANSWER : B



Q4. What is a possible cause for this ?

- A. Right optic neuritis
- B. Left optic neuritis
- C. Right oculomotor palsy
- D. Left oculomotor palsy
- E. Horner's syndrome

ANSWER : B



Q3. Whats the muscle affected :

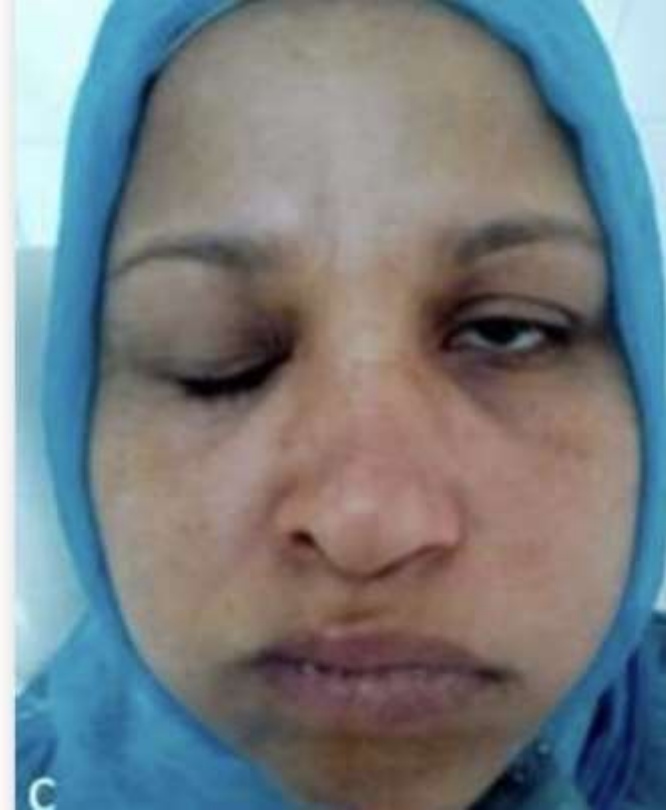- A. Right pterygoid muscle
- B. Left pterygoid muscle

ANSWER : B



Q21. The patient may have one of the following :

- A. Tongue deviation
- B. Left ear hearing loss



Q22. Which Guillain-Barre variant is associated with ophthalmoplegia, ataxia and areflexia and tends to be associated with GQ1B antibodies?

- A. Acute inflammatory demyelinating polyneuropathy
- B. Chronic inflammatory demyelinating polyneuropathy
- C. Multifocal motor neuropathy
- D. Miller-fisher syndrome
- E. Acute motor axonal neuropathy

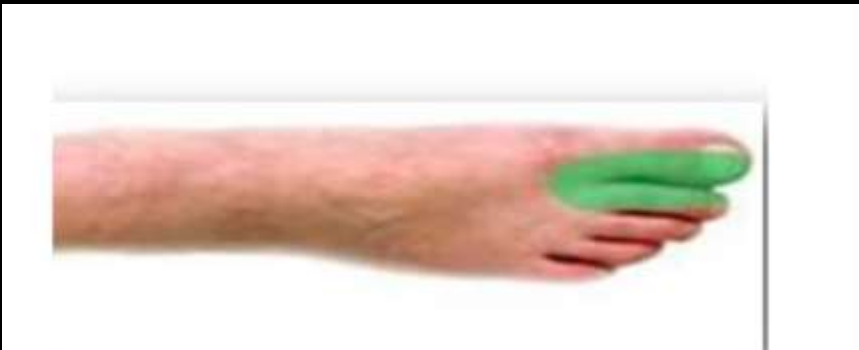ANSWER : D

- 50years old female pt came to ER with progressive sever headache , your initiainvestigation to do :
- a) esr and crp*****
- b) sinal cord mri
- c) csf analysis
- d) brain CT scan
- e) brain mri

All of the following ass with optic nerve examination except

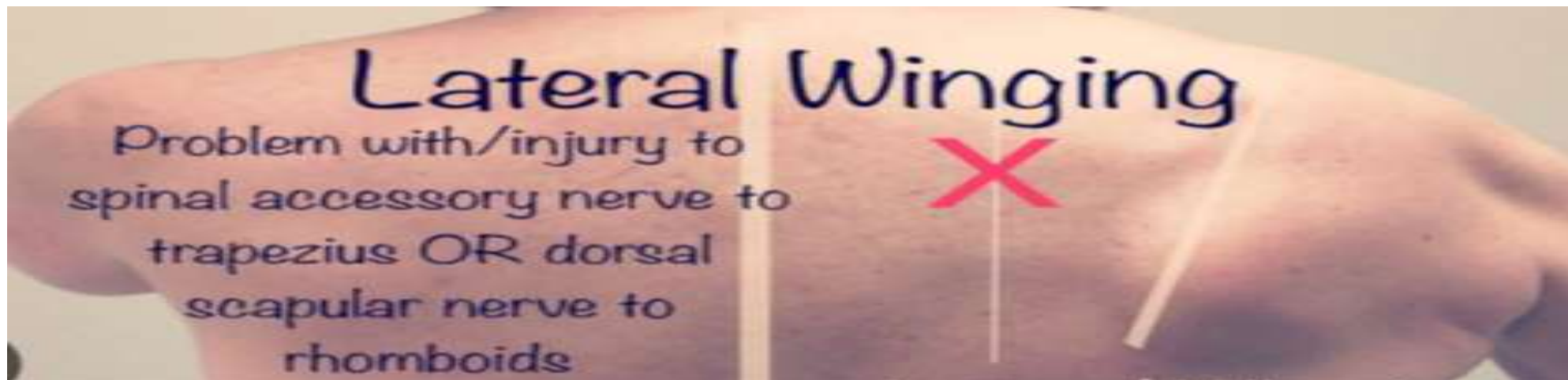
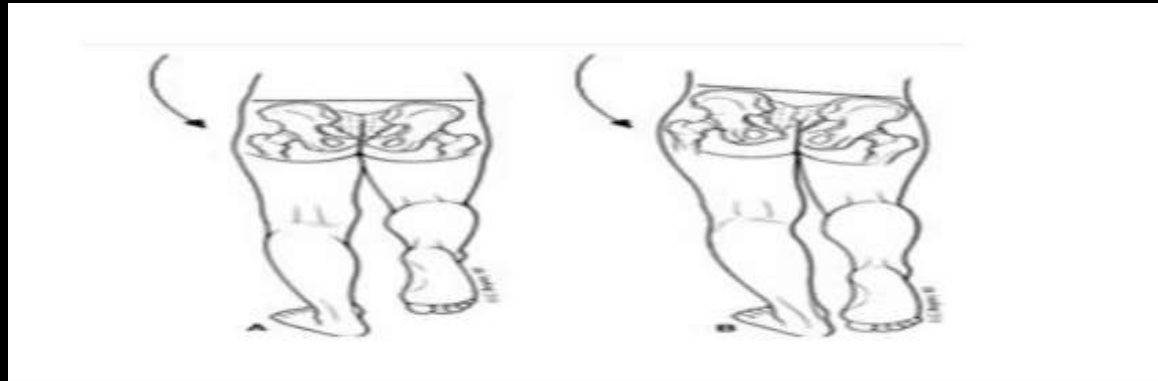
- 1-Visual acuity
- 2-Color vision
- 3.Pupillary reflex
- 4-homonymous hemianopia

patient has sensory
loss in the highlighted area , most likely clinical sign found :



- A. Foot drop
- B. Weak eversion
- C. Plantar flexion upward

Positive test indicate: proximal ms weakness



❖ In what disease do we find otoliths in the endolymphatic fluid ?

- Benign paroxysmal positional vertigo



To assess Vestibulocochlear nerve:

1-Whisper test from behind.

2-Weber + Rinne test

3-Fukuda test.

4-Nystagmus testing.

5-extraocular ms movement

❖ A patient presented with symmetrical loss of position, touch, vibration sensations of both feet up to the ankle joints. He is likely suffering from:

1-tumor in posterior dorsal thoracic spine

2-diffuse L5-s1 prolapse

3-ischemic stroke

Choose the FALSE combination

a. Chorea: Dancing like movement

b. Athetosis : Writhing movement

c. Parkinson: rest tremor

d. Cerebellar Disease: ipsilateral action tremor

E. Myoclonus: slow, regular movement

Old patient came to ER with bilateral lower limb weakness, (&other signs), areflexia

What is the investigation?

1-spinal MRI

2-csf analysis

3-lumber MRI

Neuro-medicine/ Mini- OSCE

Group 4

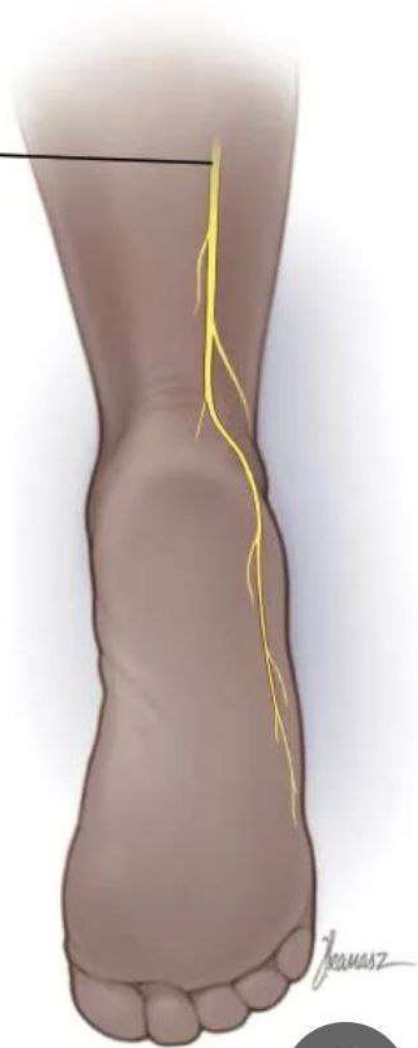Sural nerve

atic nerve

nmon
ilar nerve

al nerve

al nerve



- Vagus nerve and glossopharyngeal nerve are responsible for the followings except :
 - Gag reflex
 - Taste sensation og posterior 1/3 of tongue
 - Swallowing
 - **Deviation of tongue**

- Patient looks to right, fast phase of nystagmus to left, what is the type of nystagmus ?
 - A. Right jerky nystagmus.
 - **B. Left jerky nystagmus.**
 - C. Right pendular nystagmus.
 - D. Left pendular nystagmus.
 - E. Multidirectional nystagmus

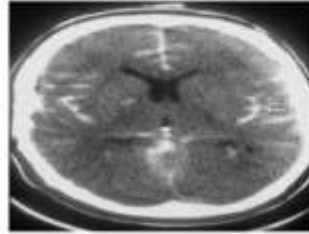
➤ 75 years old male came with acute stroke. He has right side weakness. He has spontaneous speech with occasional paraphrasic errors. He cannot understand and follow commands, and repetition is affected.

❖ Which of the following best explains his speech pattern?

- a. Broca aphasia
- b. Transcortical aphasia
- c. Conduction aphasia
- d. Wernicke aphasia
- e. Global aphasia

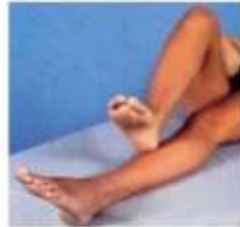Q6- What is the diagnosis ?

- A. Normal CT scan
- B. Sub-arachnoid hemorrhage
- C. Cerebral infarction
- D. Multiple sclerosis
- E. Watershed infarction



Q3-This test is used for detect the function of:

- A. Right cerebellum
- B. Left cerebellum
- C. Right cerebral
- D. Left cerebral
- E. Dorsal columns

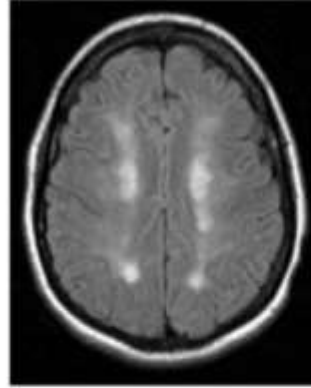


21- a patient presented with status epilepticus, he was given 10mg of diazepam but didn't get better, he was given another 10mgs but it also didn't work. What is the next step ?

- a. 20mg of phenytoin + saline for 2 minutes
- b. 20mg of phenytoin + glucose infusion
- c. 20mg of phenytoin + saline infusion
- d. 20mg of phenytoin + glucose for 2 minutes
- e. Propofol

Q18- This condition is caused by ?

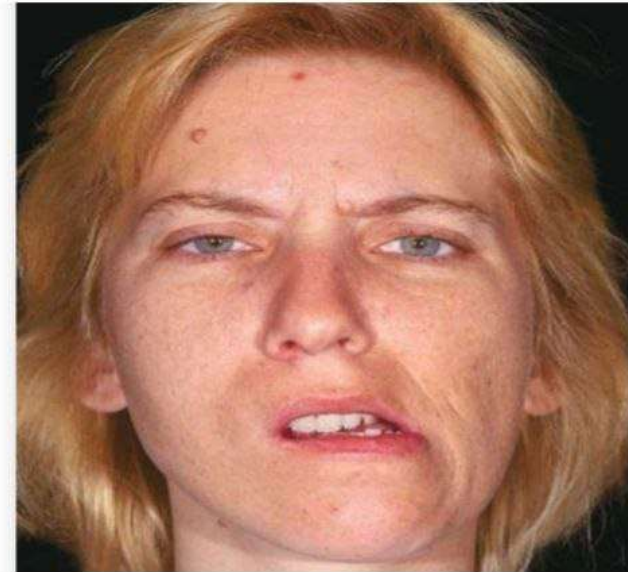- A. Severe hypertension
- B. Severe hypotension
- C. Encephalitis
- D. Meningitis
- E. Vasculitis



Q3. Whats the muscle affected :

- A. Right pterygoid muscle
- B. Left pterygoid muscle

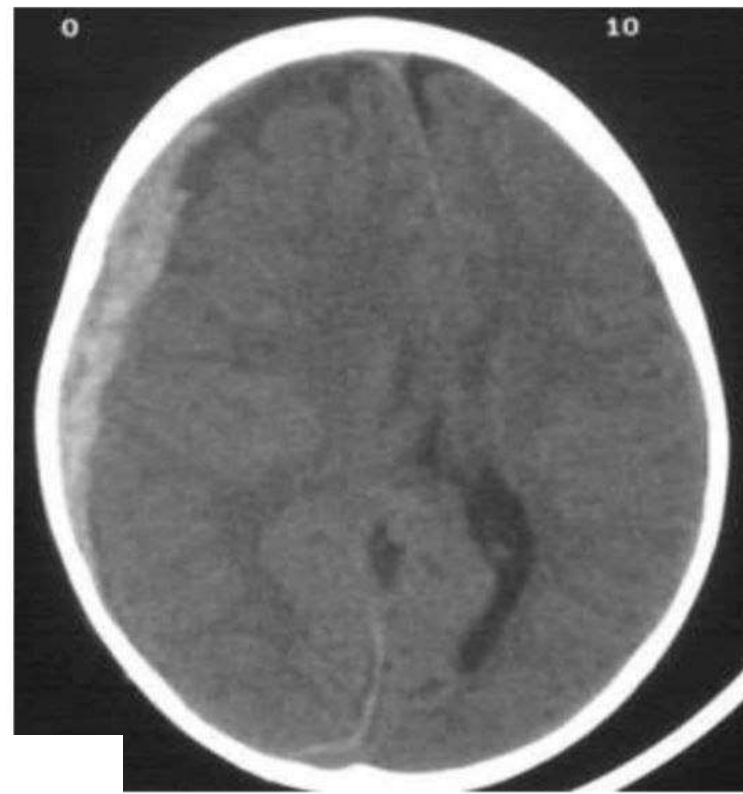ANSWER : B



Q8. what's the name of the abnormality :

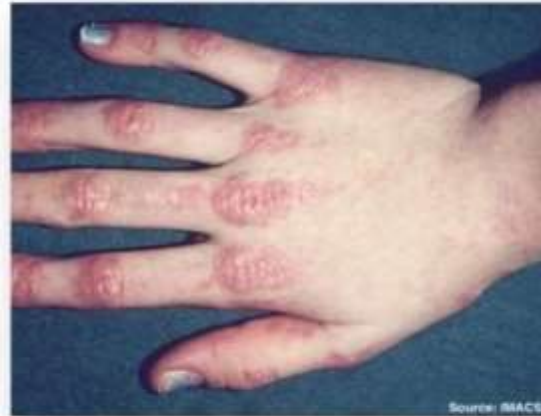- A. subdural hematoma
- B. Intracranial hemorrhage

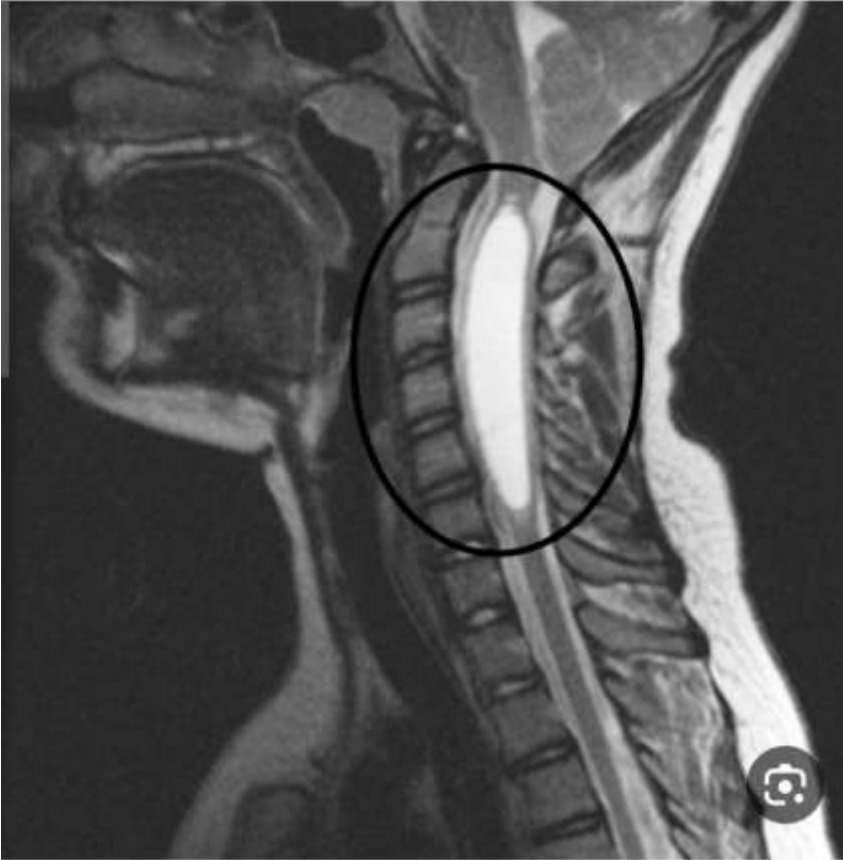ANSWER : A



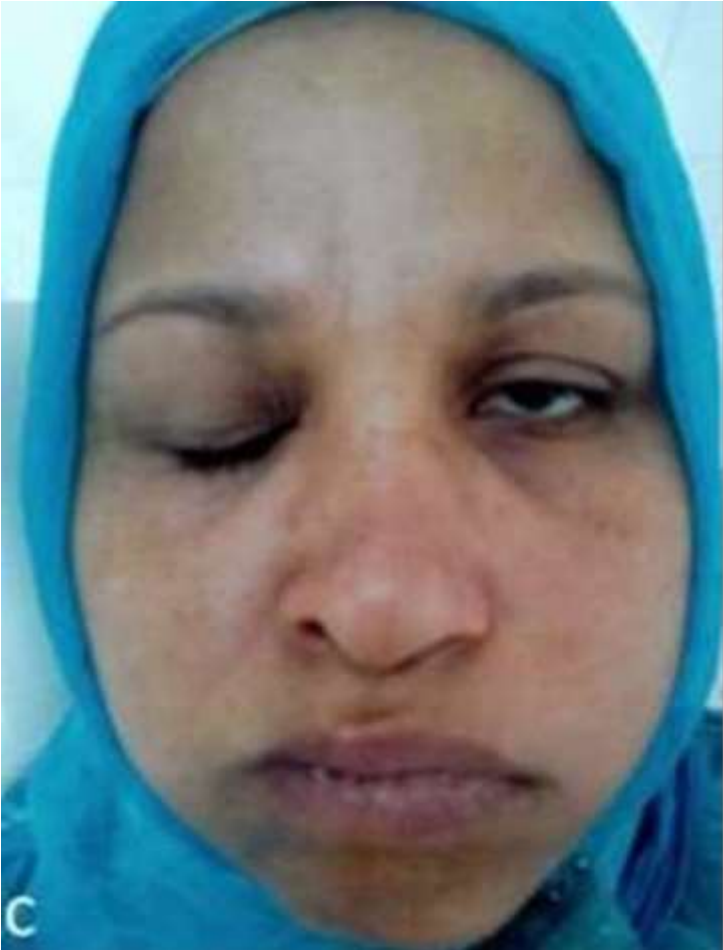Q10. what's the most likely diagnosis :

Dermatomyositis





T2 Syringomyelia



Which of the following is true?

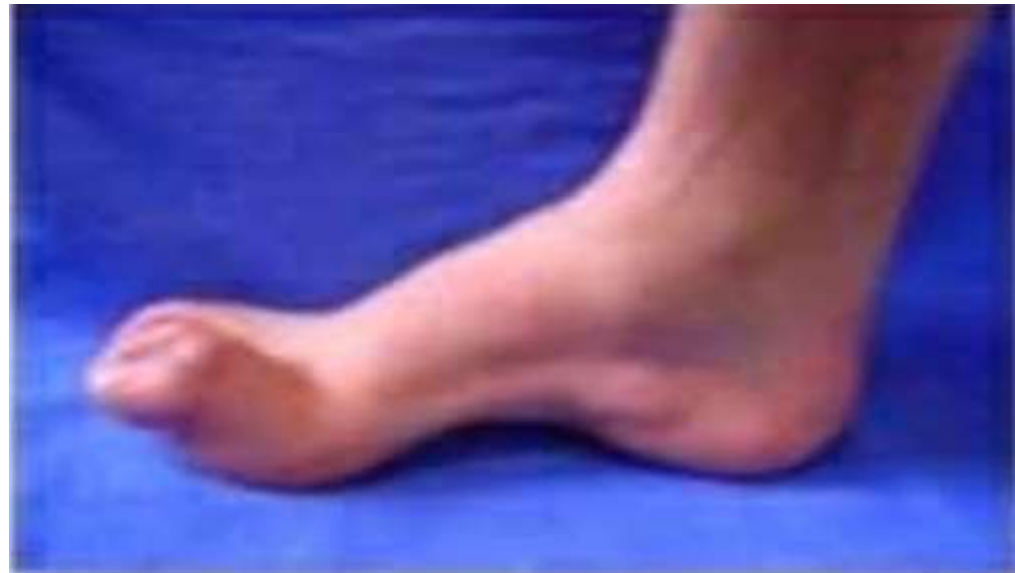- 1- loss of sensation in face
- 2- she had a stroke
- 3- taste sensation is preserved
- 4- MRI is not necessary

- 50 years old female pt came to ER with progressive severe headache , your initial investigation to do :
- a) esr and crp *****
- b) spinal cord mri
- c) csf analysis
- d) brain CT scan
- e) brain mri

- one of the following is the main common manifestations of Meniere's disease :
- a) otoliths in endolymphatic fluid
- b) excessive endolymph *****
- c) bilateral hearing loss
- d) no hearing loss
- e) diagnosed by Dix-Hallpike maneuver

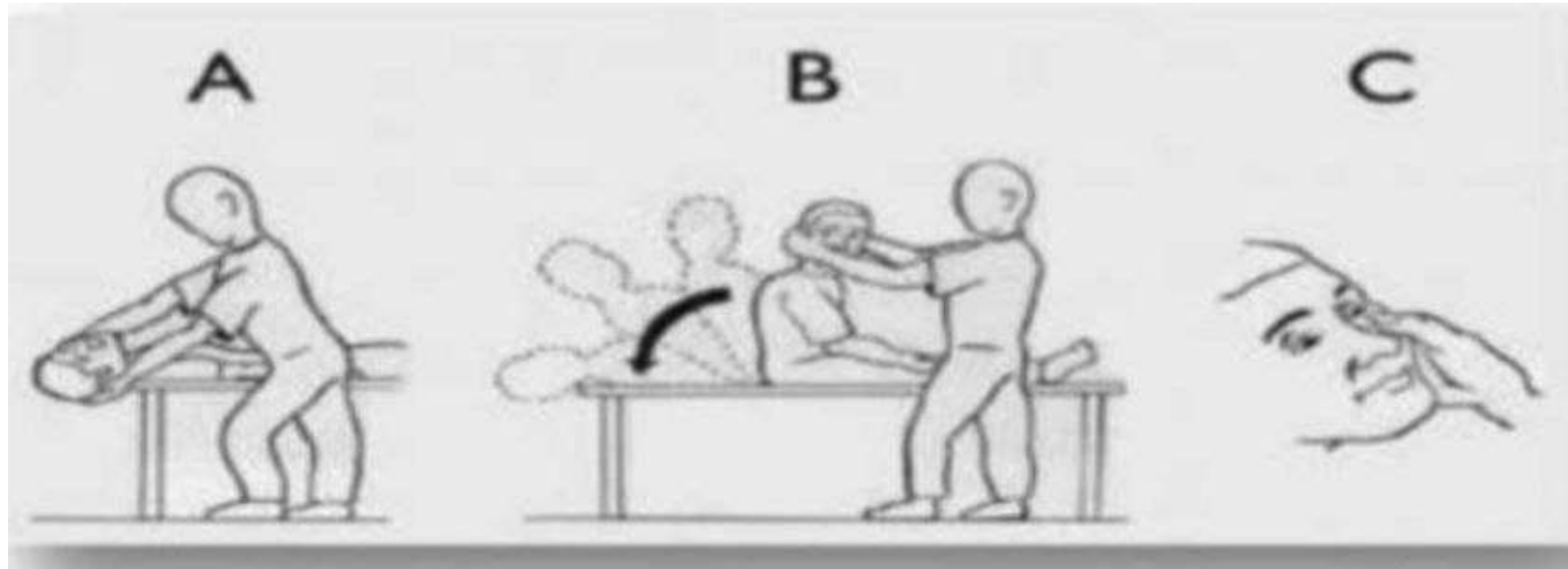
False about this condition?

- Mostly inherited
- bilateral homogenous symmetrical
- ankle reflex preserved



What is this test used for?

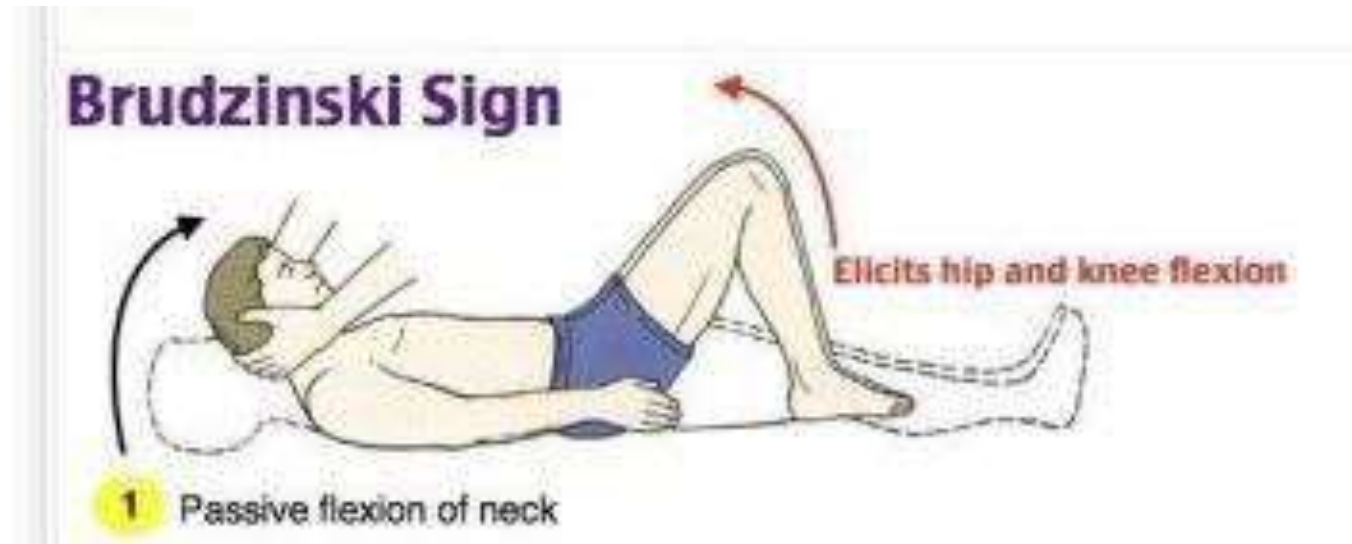
Paroxysmal vertigo due to endoliths in the posterior semicircular canals



Patient presented with fever, neck stiffness and this sign positive, which of the following is false?

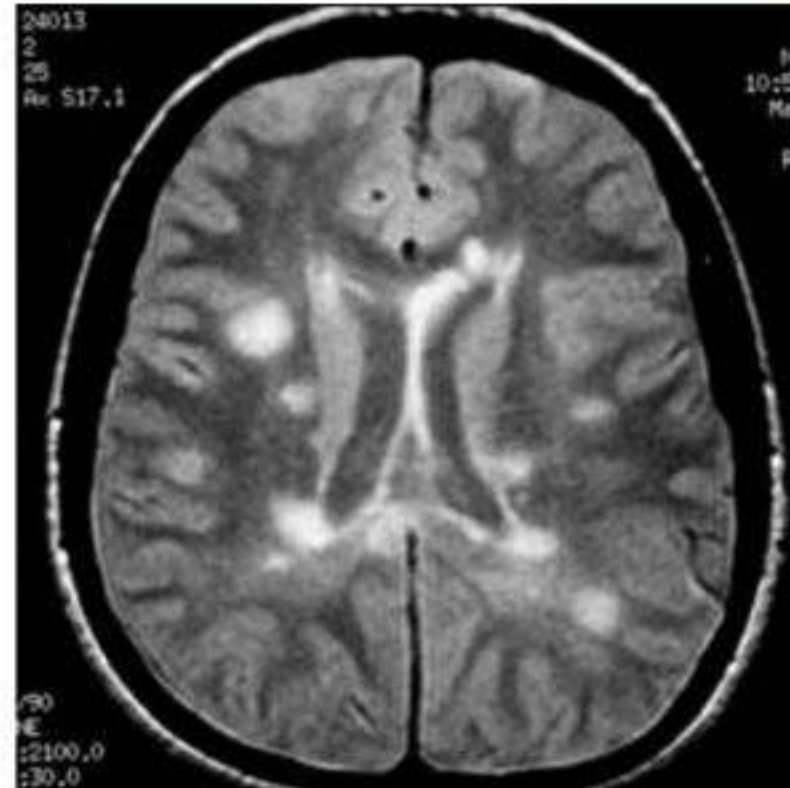
-imaging is used before lumbar puncture if there is focal neurological deficit

-csf analysis can be relied on after days of antibiotics



Pt comes with right lower limb weakness What is the next step to diagnosis?

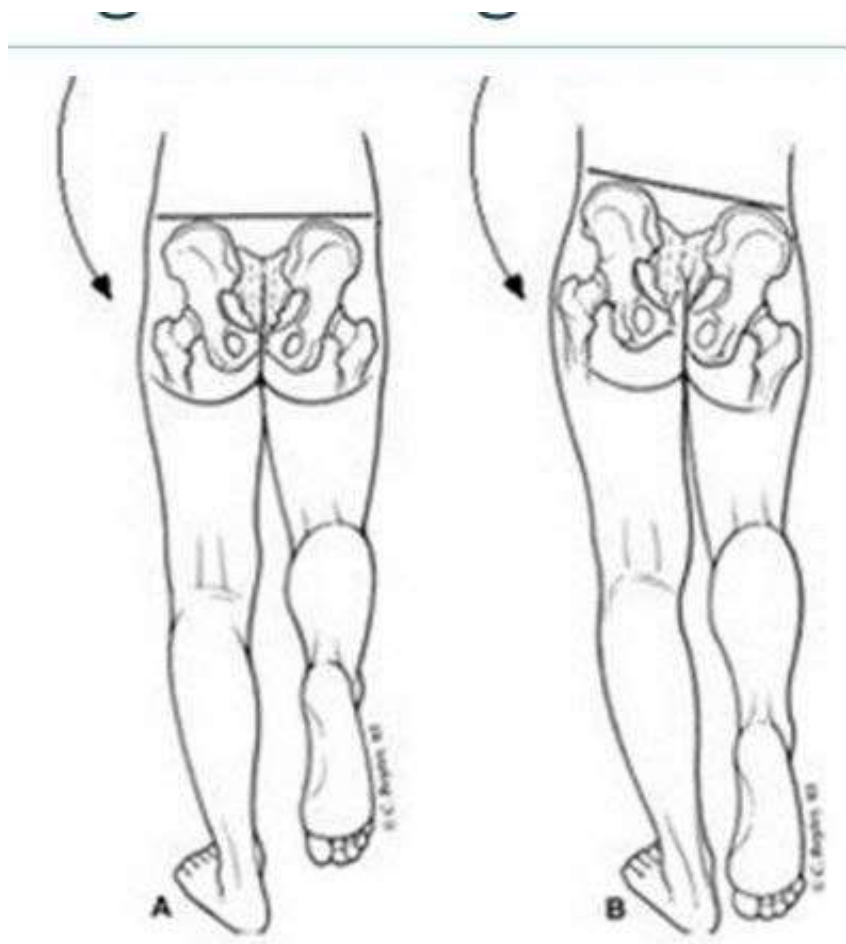
-repeat MRI every 6-12 months



Pt comes with loss of sensation over this area,
what is true?

- Power of lower limb is not affected
- sural nerve injury
- pudendal nerve injury





Positive in superior gluteal nerve lesion

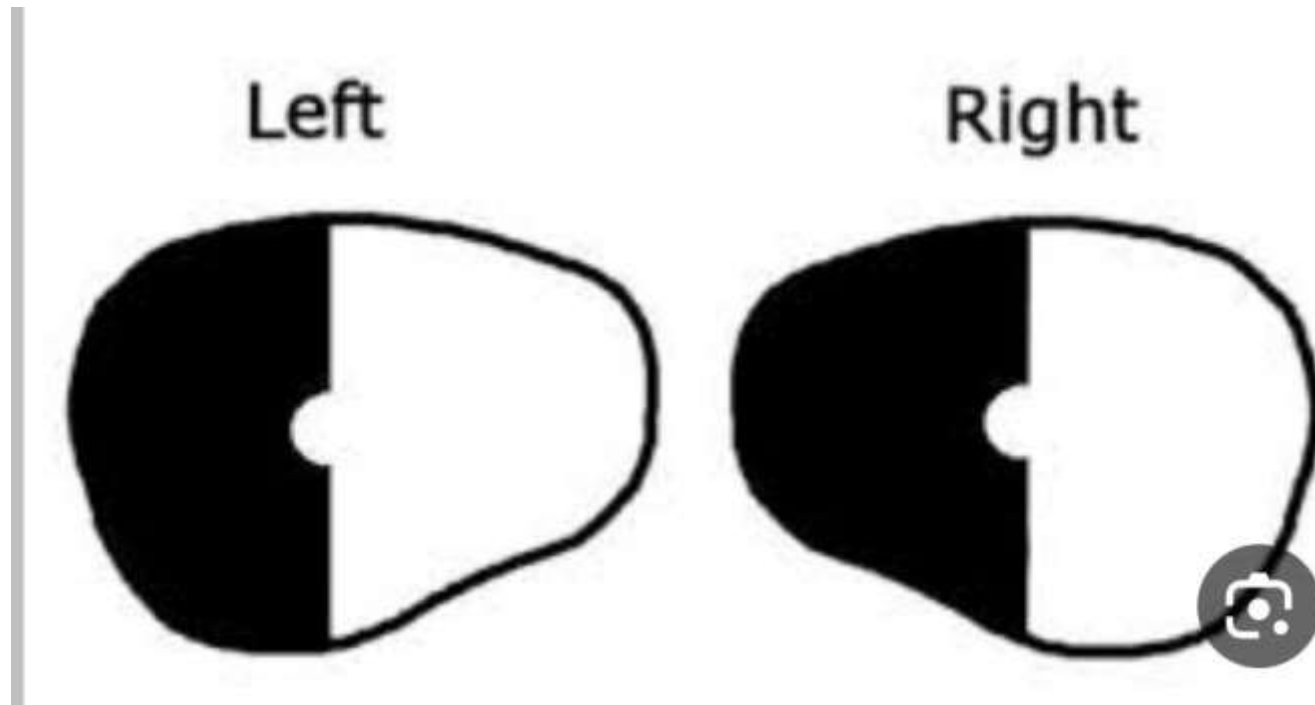
Correctly matched:

A- TB

A- Viral

	A	B
Opening pressure	elevated	elevated
WBCs	Elevated mainly lymphocytes	Elevated mainly neutrophils
RBCs	none	few
Glucose	Marginally significantly low	low
Protein	high	high
Appearance	turbid	turbid

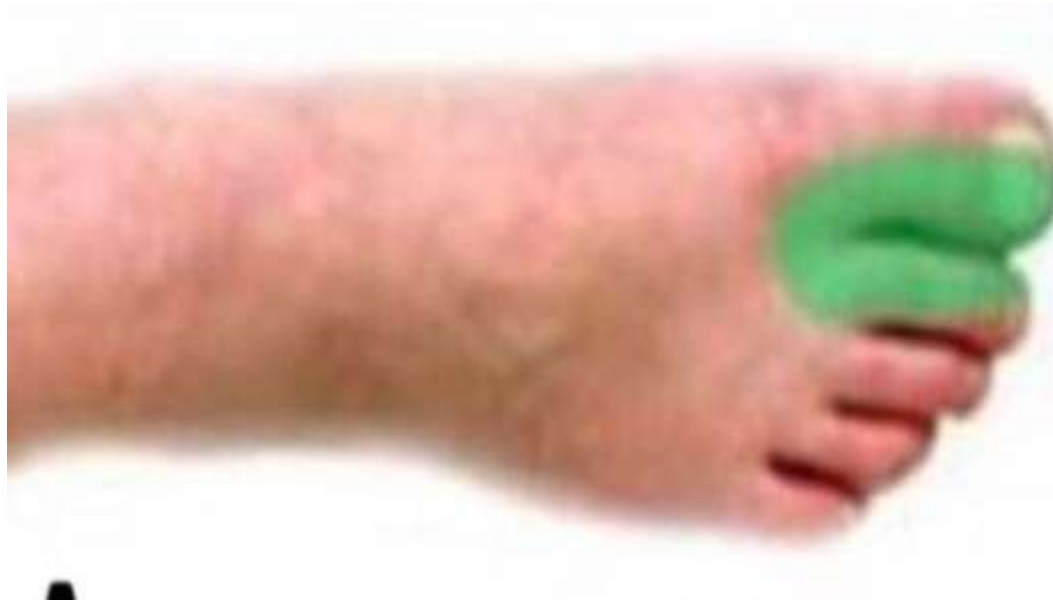Occipital lobe lesion



Patient has loss of sensation in this area, what other findings will she have?

Tibialis anterior weakness

L5-S1 disc prolapsed



True about bells palsy?

-Hyperacusis due to stapedius muscle paralysis

According to the sensory examination. One of the following is False?

-small nerve neuropathy lead to balance problem

Most common form of GBS?

-Acute inflammatory demyelinating polyneuropathy

Glascow coma for patient who opens eyes to pain, localises to pain and is confused? 11

On examination patient can flex arm against gravity but not against resistance what is the power of elbow flexors? 3

Patient came with weakness and numbness of lower extremities more than upper extremities. He was found to have generalized hypoflexia.

❖ The most important next step in diagnosis will be:

Perform brain MRI

Perform lumbar MRI

Perform lumbar puncture and CSF analysis

Examine for dermatomal sensory loss

Examine for glove and stocking sensory loss

With unilateral optic neuritis, all true except?

-homonymous hemianopia

False matching:

Cataplexy: narcolepsy

Akathesia: antipsychotics

Lower motor neuron signs: motor neuron disease

Dystonia: continuous muscle contraction

Not a feature of bulbar palsy? Jaw hyperreflexia

A feature of trigeminal injury? Jaw hyperreflexia

False about mini mental status examination?

Subtraction of 7 from 100 is a test for registration

Which of the following is falsely matched?

Hemiballismus: ipsilateral subthalamic lesion

Which of the following is false about oculomotor nerve?

Accommodation is preserved in oculomotor nerve injury

All are used to test for coordination except?

Romberg

Finger to nose

Rapid alternating

Heel-knee-shin

Nystagmus

Which of the following is true about seizures?

50% of people who have epilepsy have normal EEG

If MRI revealed a temporal lobe pathology, treatment should be started

All of the following are tests for vestibulocochlear nerve except?

Pupillary reflex

Neuromedicine

29/11

Done by:

Tamara almahadeen

Sajedah magableh

Naba jehad

Q.1

- What is the diagnosis ?

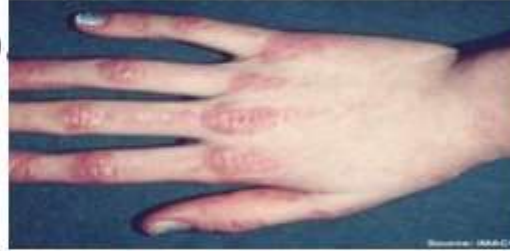Curschmann-Steinert disease

proximal myotonic myop

Polymyositis

Dermatomyositis

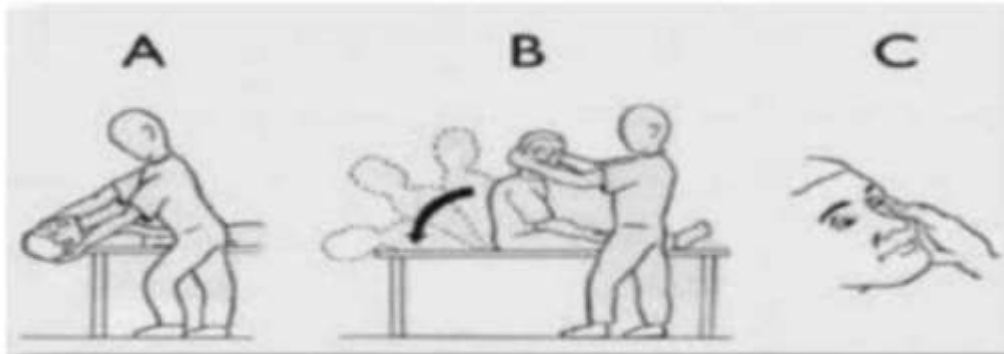
Duchenne muscular dystrophy



Q. 2

What is this test used for?

Paroxysmal vertigo due to endoliths in the posterior semicircular canals



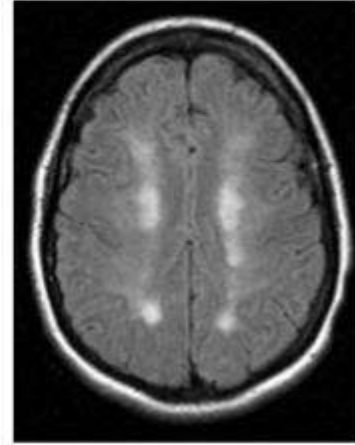
Q. 3

»»»- a patient presented with status epilepticus, he was given 10mg of diazepam but didn't get better, he was given another 10mgs but it also didn't work. What is the next step ?

- a. 20mg of phenytoin + saline for 2 minutes
- b. 20mg of phenytoin + glucose infusion
- c. **20mg of phenytoin + saline infusion**
- d. 20mg of phenytoin + glucose for 2 minutes
- e. Propofol

Q. 4 »»» This condition is caused by ?

Severe hypotension



Q. 5 »»» Patient look to left, fast phase of nystagmus to right, what the type of nystagmus ?

Right jerky nystagmus

Q.6

23 -A 20 years old patient came with weakness and numbness of lower extremities more than upper extremities. He was found to have generalized areflexia. The most important next step in diagnosis will be

- a. Perform brain MRI
- b. Perform lumbar MRI
- c. **CSF analysis**
- d. Examine for dermatomal sensory loss

Q.7 All are used to test for coordination except?

Romberg

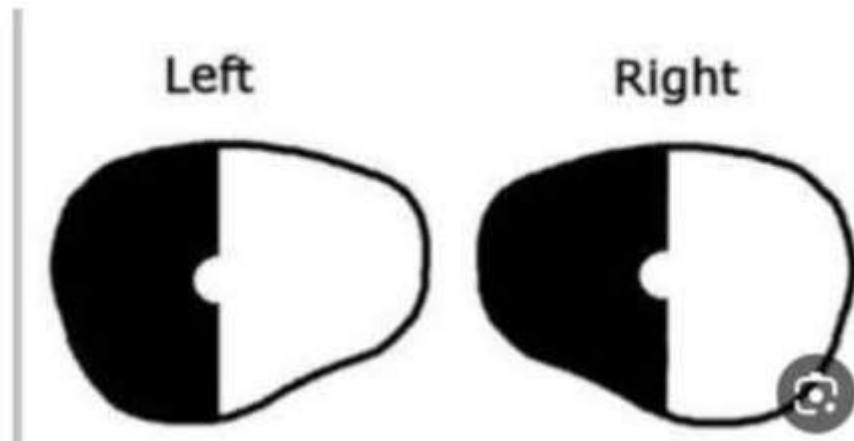
Finger to nose

Rapid alternating

Heel-knee-shin

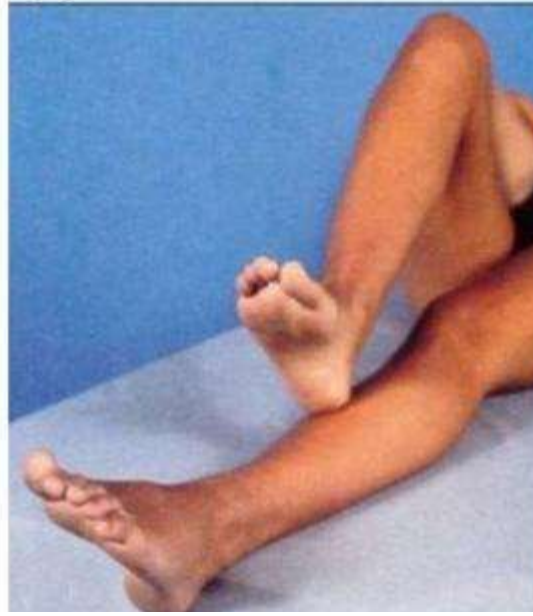Nystagmus

Q.8 Occipital lobe lesion



Q.9 »»»»Q3-This test is used for detect the function of:

- A. **Right cerebellum**
- B. Left cerebellum
- C. Right cerebral
- D. Left cerebral
- E. Dorsal columns



Q. 10 **False matching:**

Cataplexy: narcolepsy

Akathesia: antipsychotics

Lower motor neuron signs: motor neuron disease

Dystonia: continuous muscle contraction

Q.11 Q10- all are true about mini mental status examination except

MMSE is 30 points screening tool used to diagnose dementia

100-7 tests registration

score of 23 risk for mild dementia

It's affected by the patient education

MINI MENTAL STATE EXAMINATION (MMSE)

DOB: _____
Hospital Number: _____

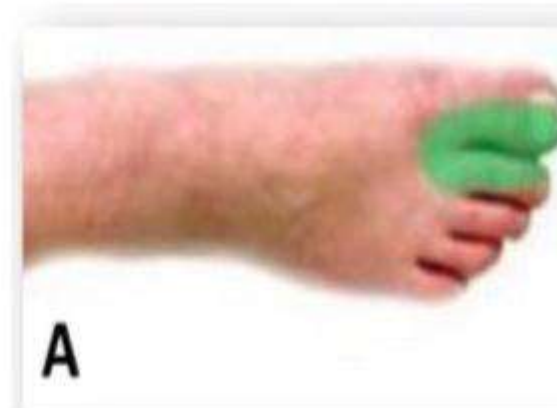One point for each answer

	DATE:			
ORIENTATION				
Year	Season	Month	Date	Time
Country	Town	District	Hospital	Ward/Floor
	—/5	—/5	—/5	—/5
	—/5	—/5	—/5	—/5
REGISTRATION				
Examiner names three objects (e.g. apple, table, penny) and asks the patient to repeat. 0.5 point for each correct. THEN the patient learns the 3 names repeating until correct.				
	—/3	—/3	—/3	—/3
ATTENTION AND CALCULATION				
Subtract 7 from 100, then repeat from result. Continue five times: 100, 93, 86, 79, 72. (Alternative: spell "WORLD" backwards: DROWL)				
	—/5	—/5	—/5	—/5
RECALL				
Ask for the names of the three objects learned earlier.				
	—/3	—/3	—/3	—/3
LANGUAGE				
Name two objects (e.g. pen, watch).				
	—/2	—/2	—/2	—/2
Repeat "No Ns, ands, or subs".				
	—/3	—/3	—/3	—/3
Give a three-stage command. Score 1 for each stage. (e.g. "Place index finger of right hand on your nose and then on your left ear").				
	—/3	—/3	—/3	—/3
Ask the patient to read and obey a written command on a piece of paper. The written instruction is: "Close your eyes".				
	—/1	—/1	—/1	—/1
Ask the patient to write a sentence. Score 1 if it is sensible and has a subject and a verb.				
	—/1	—/1	—/1	—/1
COPYING:				
Ask the patient to copy a pair of intersecting pentagons.				
	—/3	—/3	—/3	—/3



Q. 12 Q36- Clinical sign associated with lesion of the nerve supply the area shown in the picture?

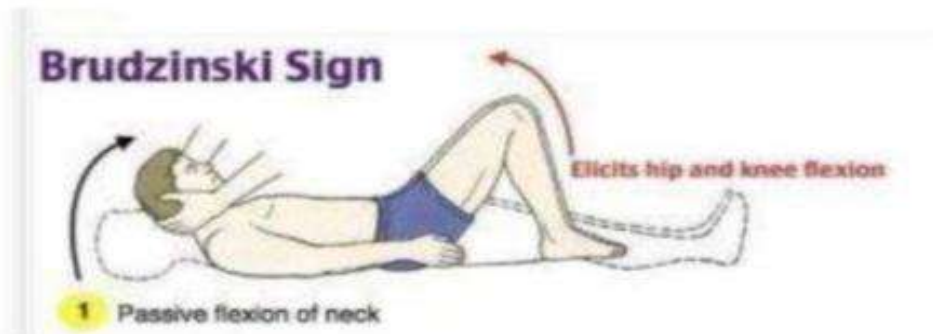- A. **Tibialis anterior weakness**
- B. Weak plantar flexion
- C. Calf muscle atrophy
- D. Absent ankle reflex
- E. Cannot stands on tip of toes



Q.13 »»»- A 75 years old male came with acute stroke. He has right side weakness. He has spontaneous speech with occasional paraphrasic errors. He cannot understand and follow commands, and repetition is affected, which of the following best explains his speech pattern?

- Broca aphasia
 - Transcortical aphasia
 - Conduction aphasia
 - Wernicke aphasia**
 - Global aphasia
-

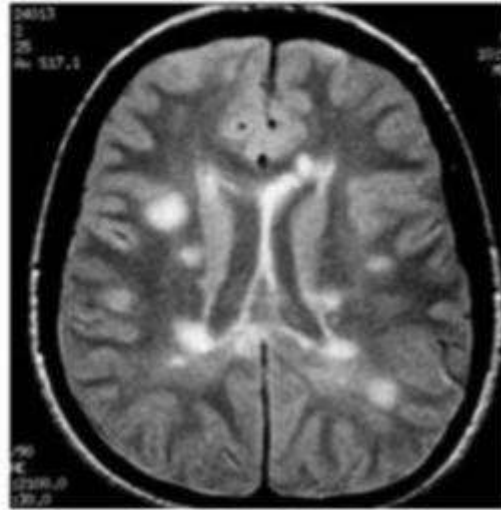
Q.14 Patient presented with fever, neck stiffness and this sign positive, which of the following is false?
-imaging is used before lumbar puncture if there is focal neurological deficit
-csf analysis can be relied on after days of antibiotics



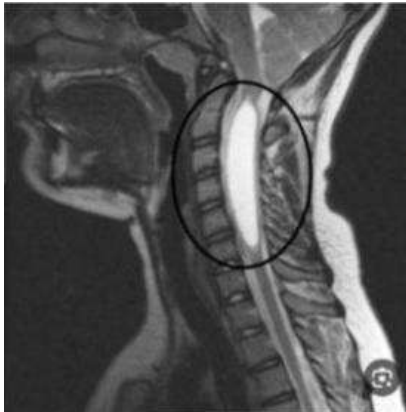Q.15

Pt comes with right lower limb weakness What is the next step to diagnosis?

-repeat MRI every 6-12 months

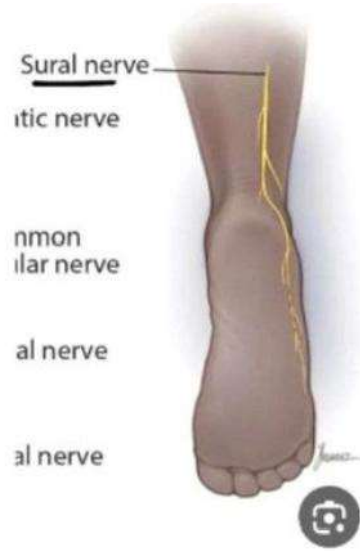


Q. 16



T2 Syringomyelia

Q.17



Q.18

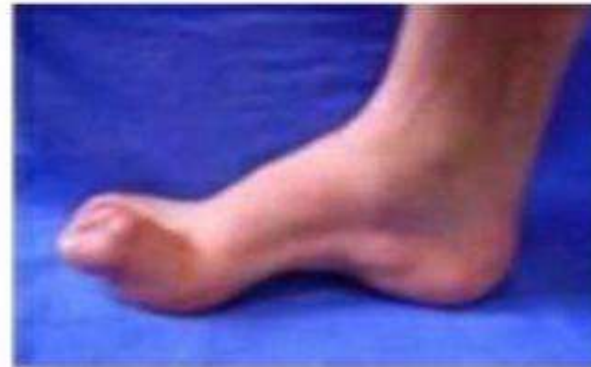Most common form of GBS?

-Acute inflammatory demyelinating polyneuropathy

Q.19

False about this condition?

- Mostly inherited
- bilateral homogenous symmetrical
- ankle reflex preserved

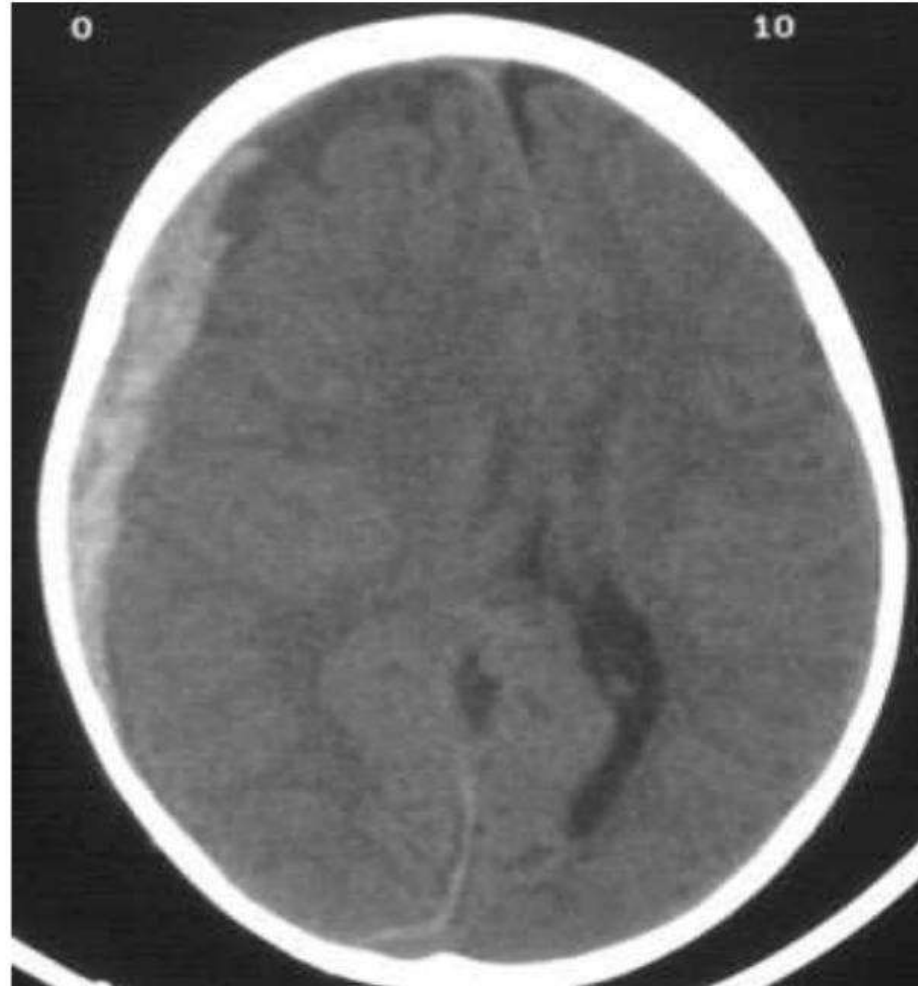


Q.20

Q8. what's the name of the abnormality :

- A. subdural hematoma
- B. Intracranial hemorrhage

ANSWER : A



Q.21

Nerve??

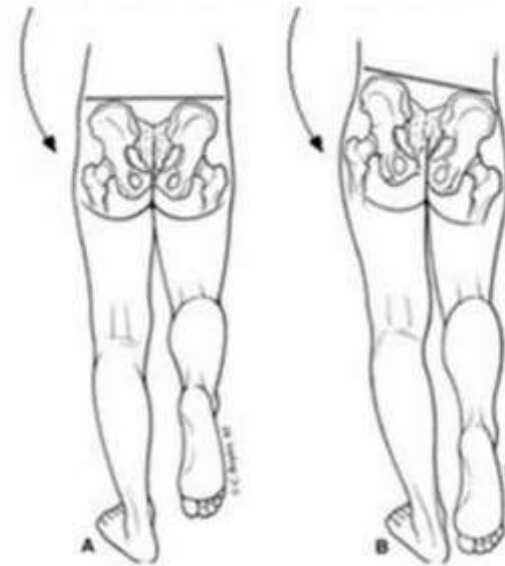
Left mandibular nerve



Q.22

Nerve??

Superior gluteal nerve



Q.23

- Vagus nerve and glossopharyngeal nerve are responsible for the followings except :
 - Gag reflex
 - Taste sensation of posterior 1/3 of tongue
 - Swallowing
 - Deviation of tongue

Q.24

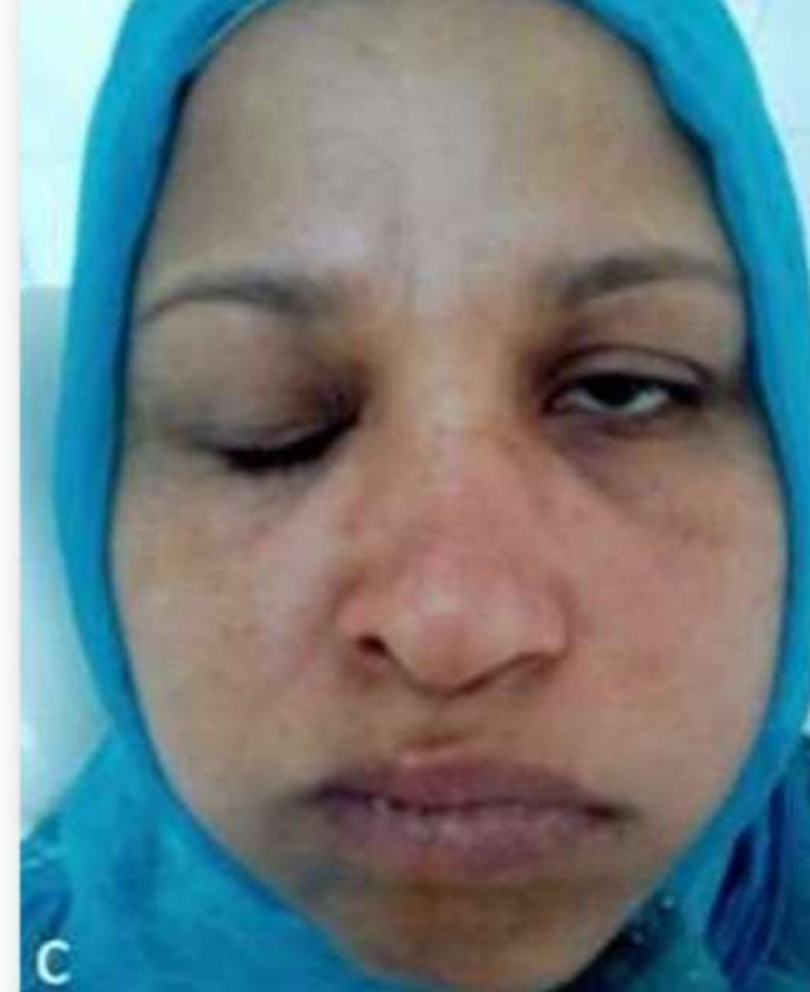
On examination patient can flex arm against gravity but not against resistance what is the power of elbow flexors? 3

Q.25

Q21. The patient may have one of the following :

- A. Tongue deviation
- B. Left ear hearing loss
- C. Left external meatus rash

ANSWER : C



Q.26

Correctly matched:

A- TB

A- Viral

	A	B
Opening pressure	elevated	elevated
WBCs	Elevated mainly lymphocytes	Elevated mainly neutrophils
RBCs	none	few
Glucose	Marginally Significantly low	low
Protein	high	high

Q.27

- one of the following is the main common manifestations of Meniere's disease :
- a) otoliths in endolymphatic fluid
- b) excessive endolymph *****
- c) bilateral hearing loss
- d) no hearing loss
- e) diagnosed by Dix Hallpike maneuver

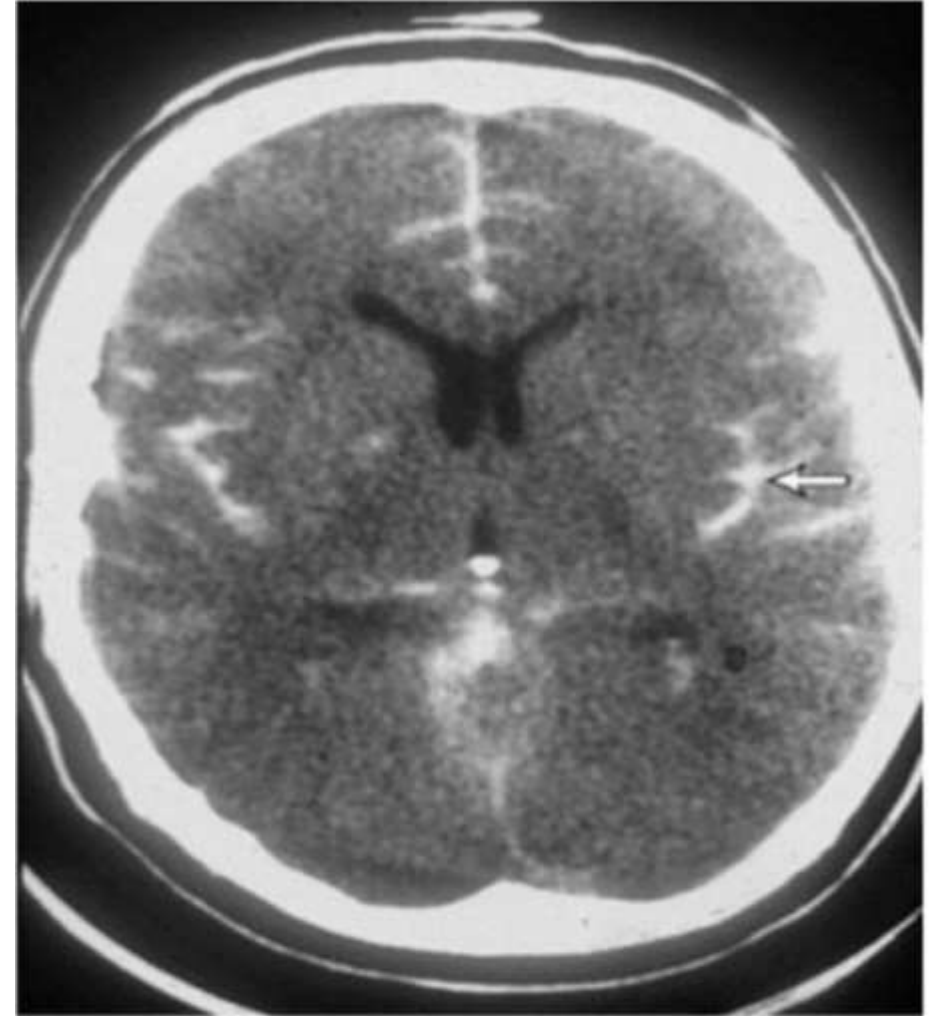
- Q.28** • Femal pt 50 years old , has headache, choose the correct statement:
- **Biopsy should be done in 24 hours✓??**

- Q.29** patient with Optic neuritis, all of the following finding are present in this patient except:
1. Visual acuity defect
 2. Visual field defect
 - 3. Ptosis✓**
 4. Color vision defect
 5. Fundoscopy maybe normal

Q.30

choose the correct statement: ???

1. Severe HTN the most common cause
2. Start Nimodipine in the first day
3. High blood pressure should not be reduced
4. Epileptic drugs should not be used



CT cranial scan of SAH

Q.31

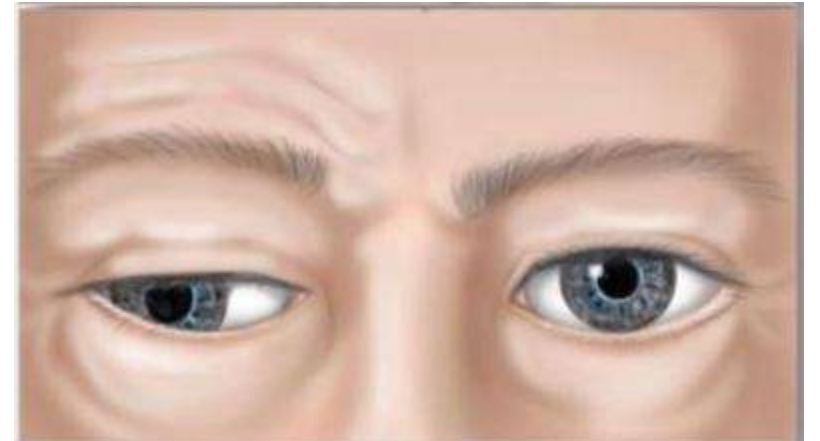
**Glasgow
coma
scale: 12**

Glasgow Coma Scale		
Response	Scale	Score
Eye Opening Response	Eyes open spontaneously	4 Points
	Eyes open to verbal command, speech, or shout	3 Points
	Eyes open to pain (not applied to face)	2 Points
	No eye opening	1 Point
Verbal Response	Oriented	5 Points
	Confused conversation, but able to answer questions	4 Points
	Inappropriate responses, words discernible	3 Points
	Incomprehensible sounds or speech	2 Points
	No verbal response	1 Point
Motor Response	Obeys commands for movement	6 Points
	Purposeful movement to painful stimulus	5 Points
	Withdraws from pain	4 Points
	Abnormal (spastic) flexion, decorticate posture	3 Points
	Extensor (rigid) response, decerebrate posture	2 Points
	No motor response	1 Point
Minor Brain Injury = 13-15 points; Moderate Brain Injury = 9-12 points; Severe Brain Injury = 3-8 points		

Q.32 All the following true about bulbar palsy except: **Brisk jaw**

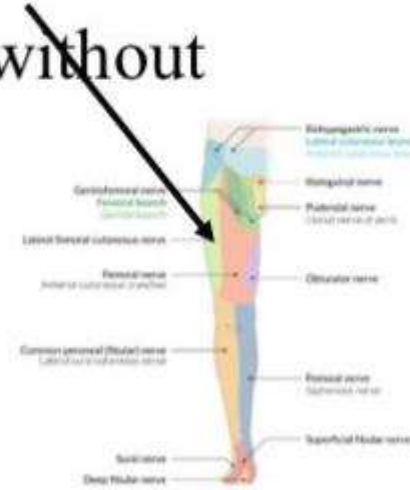Q.33 ❖ Which of the following is wrong about this palsy ?

- a. Eye down due to superior rectus weakness
- b. Eye out due to medial rectus weakness
- c. **Ptosis due to muller weakness**
- d. Mydriasis due to constrictor pupillae weakness
- e. Decreased accommodation due to ciliary body weakness



Q.34

- 39 pt has sensory loss in this area (anteriolateral) , pt suffer from?
- Compression on sensory nerve without weakness
- مش نفس الصورة



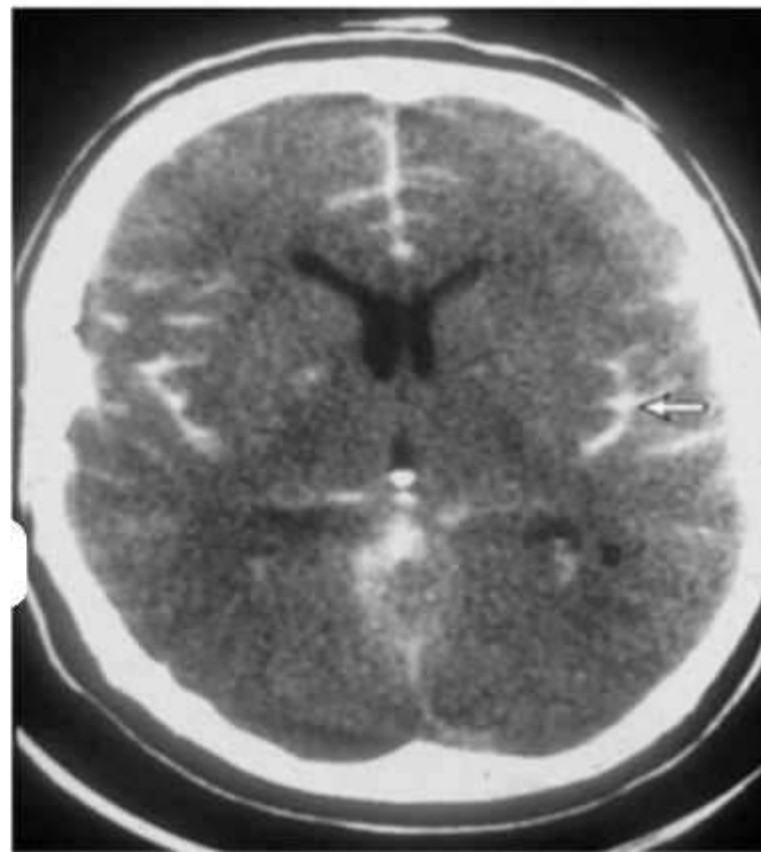
Q.31

Glasgow
coma
scale: 12

Glasgow Coma Scale		
Response	Scale	Score
Eye Opening Response	Eyes open spontaneously	4 Points
	Eyes open to verbal command, speech, or shout	3 Points
	Eyes open to pain (not applied to face)	2 Points
	No eye opening	1 Point
Verbal Response	Oriented	5 Points
	Confused conversation, but able to answer questions	4 Points
	Inappropriate responses, words discernible	3 Points
	Incomprehensible sounds or speech	2 Points
	No verbal response	1 Point
Motor Response	Obeys commands for movement	6 Points
	Purposeful movement to painful stimulus	5 Points
	Withdraws from pain	4 Points
	Abnormal (spastic) flexion, decorticate posture	3 Points
	Extensor (rigid) response, decerebrate posture	2 Points
	No motor response	1 Point
Minor Brain Injury = 13-15 points; Moderate Brain Injury = 9-12 points; Severe Brain Injury = 3-8 points		

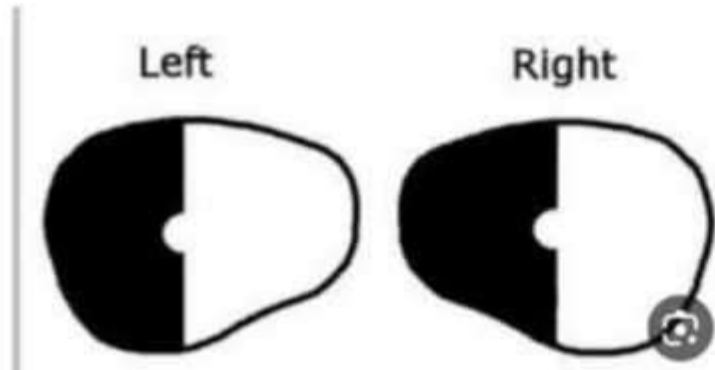
Q.30

choose the correct statment: ???



CT cranial scan of SAH

Q.8 Occipital lobe lesion



- The score or degree of power if the patient can do active movement with gravity eliminated ?

- 2
- 3
- 4
- 1

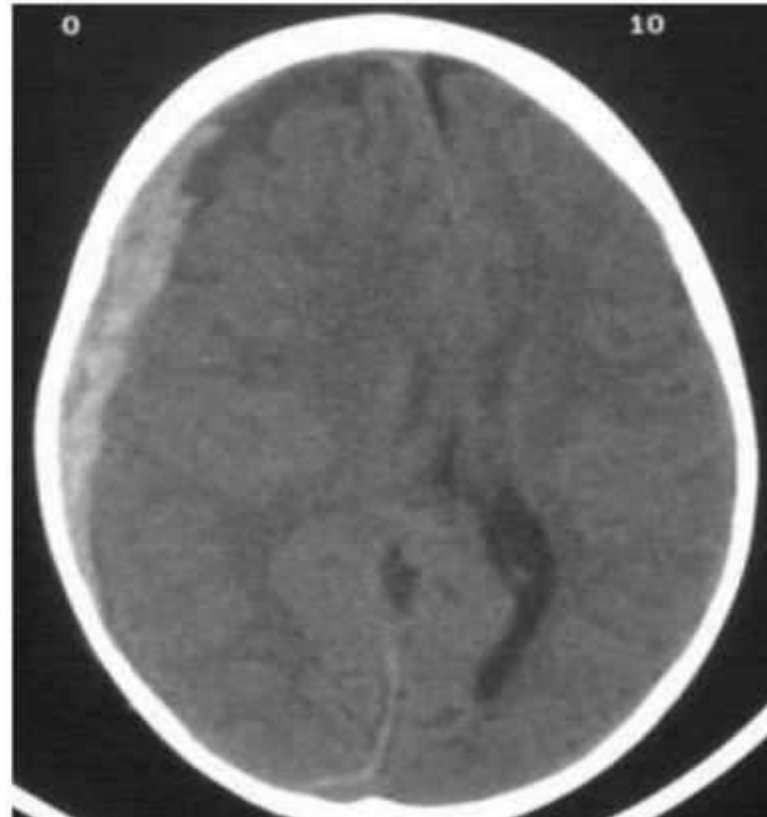


Q.20

Q8. what's the name of the abnormality :

- A. subdural hematoma
- B. Intracranial hemorrhage

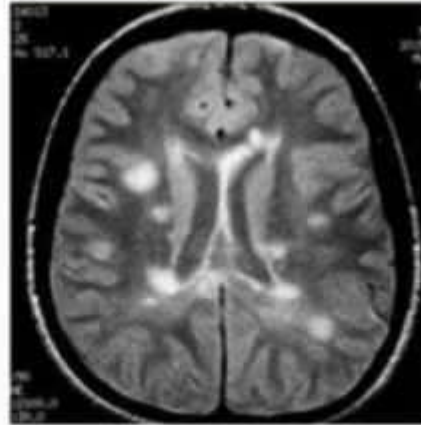
ANSWER : A

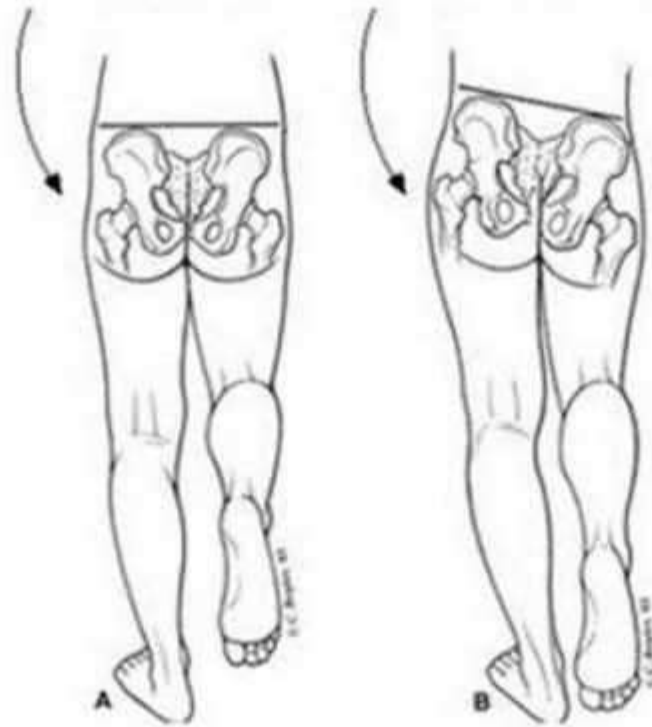


Q.15

Pt comes with right lower limb weakness What is the next step to diagnosis?

-repeat MRI every 6-12 months





Positive in superior gluteal nerve lesion

Q.1

- What is the diagnosis ?

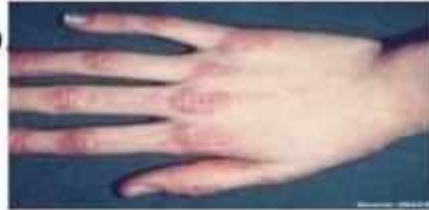Curschmann-Steinert disease

proximal myotonic myop

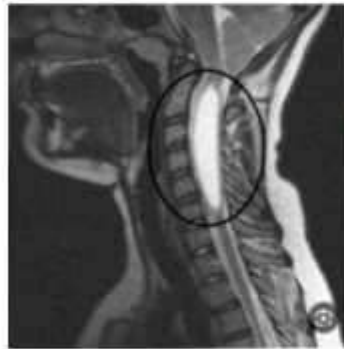Polymyositis

Dermatomyositis

Duchenne muscular dystrophy



Q. 16



T2 Syringomyelia

Correctly matched:

A- TB

A- Viral

	A	B
Opening pressure	elevated	elevated
WBCs	Elevated mainly lymphocytes	Elevated mainly neutrophils
RBCs	none	few
Glucose	Marginally significantly low	low
Protein	high	high
Appearance	turbid	turbid

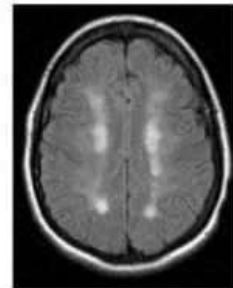
Q. 3

»»- a patient presented with status epilepticus, he was given 10mg of diazepam but didn't get better, he was given another 10mgs but it also didn't work. What is the next step ?

- a. 20mg of phenytoin + saline for 2 minutes
- b. 20mg of phenytoin + glucose infusion
- c. **20mg of phenytoin + saline infusion**
- d. 20mg of phenytoin + glucose for 2 minutes
- e. Propofol

Q. 4 »»» This condition is caused by ?

Severe hypotension



Choose the FALSE combination

- a. Chorea: Dancing like movement
- b. Athetosis : Writhing movement
- c. Parkinson: rest tremor
- d. Cerebellar Disease: ipsilateral action tremor
- E. Myoclonus: slow, regular movement

All are used to test for coordination except?

Romberg

Finger to nose

Rapid alternating

Heel-knee-shin

Nystagmus

Which of the following is true about seizures?

50% of people who have epilepsy have normal EEG

If MRI revealed a temporal lobe pathology, treatment should be started

All of the following are tests for vestibulocochlear nerve except?

Pupillary reflex



To assess Vestibulocochlear nerve:

1-Whisper test from behind.

2-Weber + Rinne test

3-Fukuda test.

4-Nystagmus testing.

5-extraocular ms movement

neuromedicine

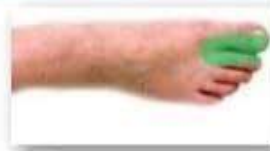shahd Ayoub

Sondos AL-qatawneh

Deep peroneal nerve

❖ Clinical sign associated with lesion of the nerve supply the area shown in the picture ?

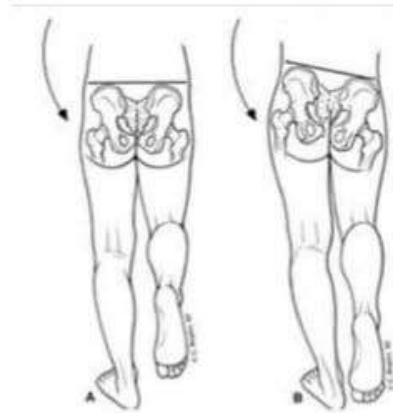
- a. Weak plantar flexion
- b. Calf muscle atrophy
- c. Absent ankle reflex
- d. Cannot stands on tip of toes
- e. **Tibialis anterior weakness**



decrease الجواب كان
power of tibialis anterior

What is the name of test?

Trendelenburg's test



Q5- This test called ?

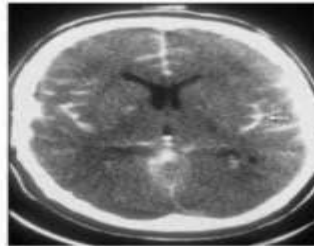
- A. Tandem test
- B. Romberg's test
- C. Trendelenburg's test
- D. Heel-knee-shin test
- E. Babinski's sign



كان بده هون ال

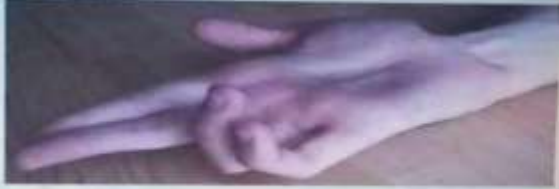treatment

- A. Nimodipine
- B. antihypertensive
- C. Antiepileptic
- D. tpA
- E. V k



الجواب D

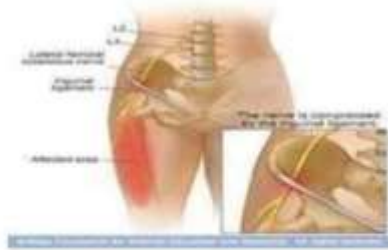The diagnosis is:



Select one:

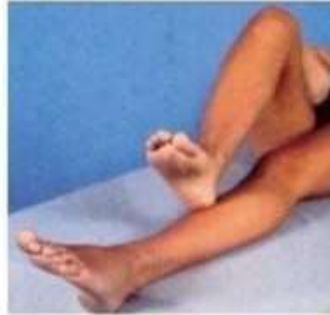- a. radial nerve lesion
- b. musculocutaneous injury
- c. suprapopliteal injury
- d. The median nerve
- e. the ulnar nerve

The name of this condition?
Meralgia paresthetica



Q3-This test is used for detect the function of:

- A. Right cerebellum
- B. Left cerebellum
- C. Right cerebral
- D. Left cerebral
- E. Dorsal columns



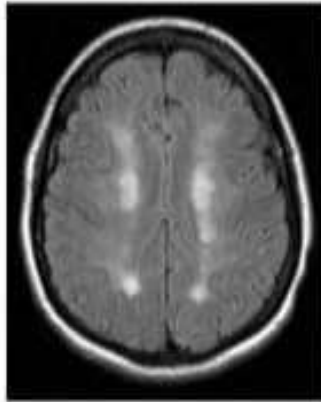
21- a patient presented with status epilepticus, he was given 10mg of diazepam but didn't get better, he was given another 10mgs but it also didn't work. What is the next step ?

- a. 20mg of phenytoin + saline for 2 minutes
- b. 20mg of phenytoin + glucose infusion
- c. 20mg of phenytoin + saline infusion
- d. 20mg of phenytoin + glucose for 2 minutes
- e. Propofol

- All of these test are for cerebellum except :
 - Finger to nose tes
 - Heel to shin test
 - Rapid alternating movement
 - Rebound test
 - **Romberg test**

Q18- This condition is caused by ?

- A. Severe hypertension
- B. Severe hypotension**
- C. Encephalitis
- D. Meningitis
- E. Vasculitis



نفس الخيارات بس بدل

Hypotension

الجواب

Hypovolemia

• Vagus nerve and glossopharyngeal nerve are responsible for the followings except :

- Gag reflex
- Taste sensation og posterior 1/3 of tongue
- Swallowing
- Deviation of tongue

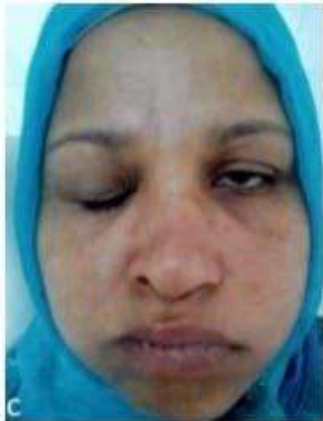نفس الخيارات بس اخر خيار
مغيره الى
Decrease power of
the tongue

-
- Patient looks to right, fast phase of nystagmus to left, what is the type of nystagmus ?
 - A. Right jerky nystagmus.
 - B. Left jerky nystagmus.
 - C. Right pendular nystagmus.
 - D. Left pendular nystagmus.
 - E. Multidirectional nystagmus
-

• All of the followings are true regarding to vestibulocochlear nerve except :

- Fukuda test.
- Nystagmus testing
- Weber + Rinne test.
- Whisper test from behind
- **Gag reflex**

نفس الخيارات بس بدل آخر
Romberg واحد مخطوط
test



Which of the following is true?

- 1- loss of sensation in face
- 2- she had a stroke
- 3- taste sensation is preserved
- 4- **MRI is not necessary**

- which of the following ass with facial nerve injury:
- a) hyperacoustic stapedius paralysis*****
- b) pterygoid paralysis
- c) intact facial expressions
- d) loss of jaw reflex

Q3. Whats the muscle affected :

- A. Right pterygoid muscle
- B. Left pterygoid muscle

ANSWER : B



Q22. Which Guillain-Barre variant is associated with ophthalmoplegia, ataxia and areflexia and tends to be associated with GQ1B antibodies?

- A. Acute inflammatory demyelinating polyneuropathy
- B. Chronic inflammatory demyelinating polyneuropathy
- C. Multifocal motor neuropathy
- D. Miller-fisher syndrome
- E. Acute motor axonal neuropathy

ANSWER : D

Q12. A 20 years old patient came with weakness and numbness of lower extremities more than upper extremities, urine retention, & normal reflexes. The most important next step in diagnosis will be:

- A. Nerve conduction study
- B. Perform spinal MRI
- C. Perform lumbar puncture and CSF analysis
- D. Examine for dermatomal sensory loss
- E. Examine for glove and stocking sensory loss

ANSWER : B

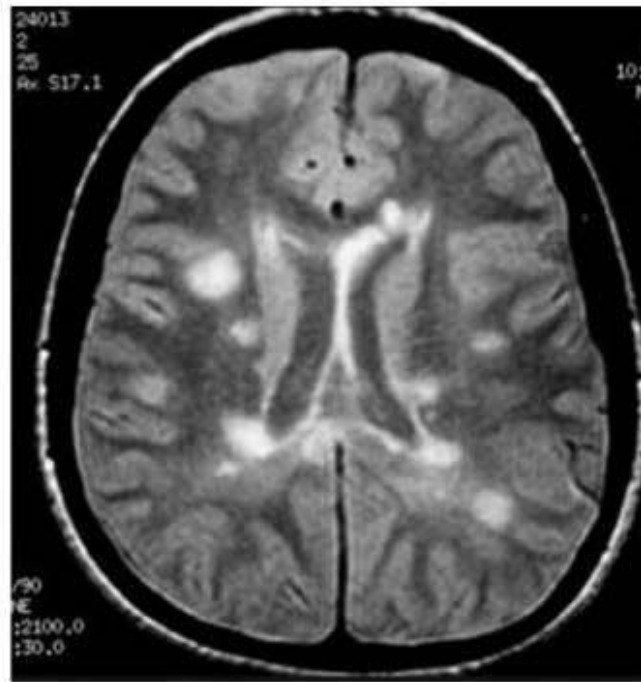
- .One of the following is main feature of trigeminal nerve injury:
- a) loss of taste sensation of the anterior 2/3 of the tongue
- b) loss of taste sensation of posterior 1/3 of the tongue
- c) jaw hyperreflexia*****
- d) loss of touch sensation of the posterior 1/3 of the tongue

- 50 years old female pt came to ER with progressive sever headache , your initiainvestigation to do :
- a) esr and crp *****
- b) sinal cord mri
- c) csf analysis
- d) brain CT scan
- e) brain mri

Q7. A patient had head trauma, what is the patient diagnosis

- A. Clinically isolated MS
- B. Radiologically isolated MS.
- C. Secondary progressive
- D. Primary progressive
- E. Progressive releasing

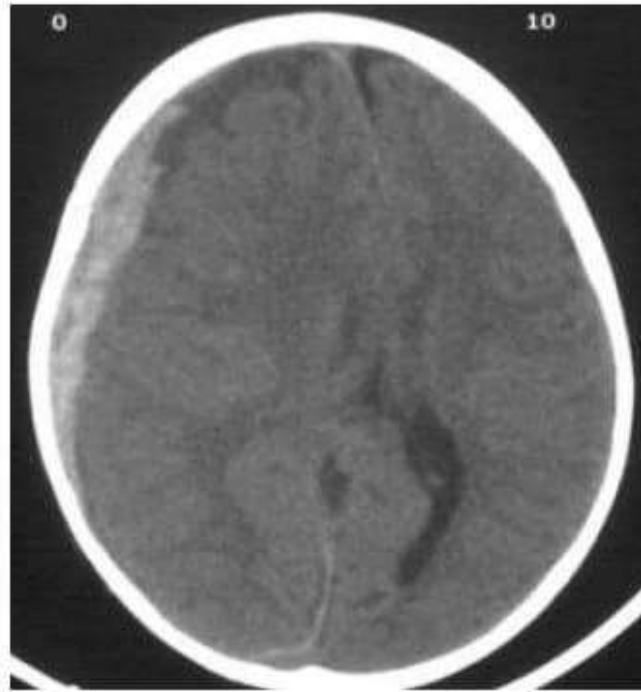
ANSWER : B



Q8. what's the name of the abnormality :

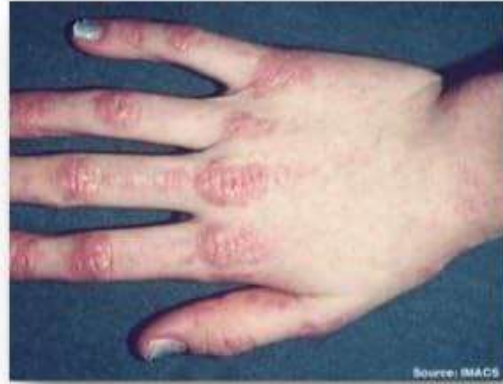- A. subdural hematoma
- B. Intracranial hemorrhage

ANSWER : A

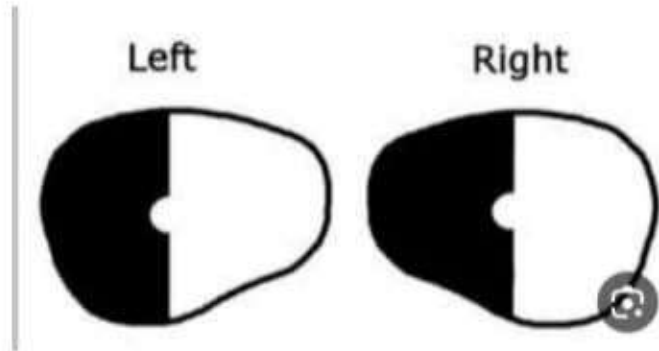


Q10. what's the most likely diagnosis :

Dermatomyositis



Occipital lobe lesion



7

Opening pressure	elevated	elevated
WBCs	Elevated mainly lymphocytes	Elevated mainly neutrophils
RBCs	none	few
Glucose	Marginally low	low
Protein	high	high
	A	B

D: These are CSF results, what do you expect the cause of these findings in A and in B?

A: Viral

B: Acute bacterial meningitis

According to the sensory examination. One of the following is False?

Small nerve neuropathy

Causes areflexia

❖ Which of the following result in a positive Romberg test ?

- a. Dorsal column lesion
 - b. Vit B12 deficiency
 - c. Diabetic neuropathy
 - d. Impaired proprioception
 - e. All of the above
-

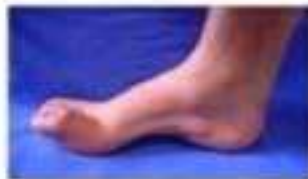Q10- all are true about mini mental status examination except

- MMSE is 30 points screening tool used to diagnose dementia
- 100-7 tests registration
- score of 23 risk for mild dementia
- It's affected by the patient education

On examination patient can flex arm against gravity but not against resistance what is the power of elbow flexors? 3

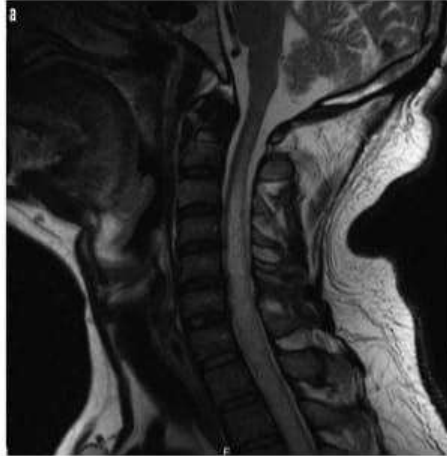Charcot-Marie-Tooth disease

- ❖ In NCS (nerve conduction study) the patient showed **demyelination** so what's the diagnosis ?
 - Charcot-Marie-Tooth disease



What is the diagnosis

T2 syringomyelia



مش نفس الصورة بالزبط

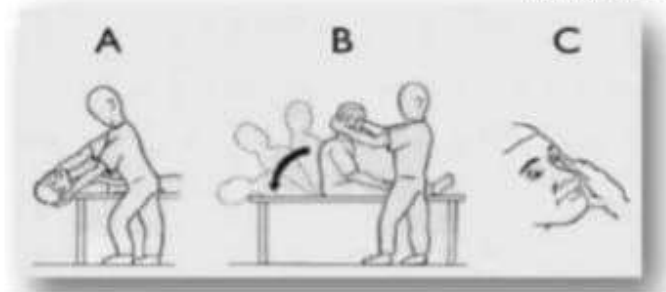out

**Usually accommodations is
normal**

What is the name of test?

Dix-Hallpike maneuver

If Dix-Hallpike maneuver test is positive, what does it mean
Otoliths in posterior semicircular canal



➤ 75 years old male came with acute stroke. He has right side weakness. He has spontaneous speech with occasional paraphrasic errors. He cannot understand and follow commands, and repetition is affected.

❖ Which of the following best explains his speech pattern?

- a. Broca aphasia
- b. Transcortical aphasia
- c. Conduction aphasia
- d. Wernicke aphasia
- e. Global aphasia

نفس نمط هذا السؤال

الجواب E



Choose the FALSE combination:

- a. Athetosis is slow writhing movement
- b. Tics are semivoluntary movement
- c. Hemiballismus due to contralateral lesion in subthalamic nucleus
- d. Intention tremors frequency is the same through out the movement
- e. Myoclonus sudden, brief, uncontrolled muscle contraction

- Eye open to verbal command, Incomprehensible sound, and localizes pain.
- Gcs=10
- Gcs 10
- Gcs =5
- Gcs = 12

الاختلاف هون
Open eye to pain
GCS =9

Patient presented with fever, neck stiffness and this sign positive, which of the following is false?

-imaging is used before lumbar puncture if there is focal neurological deficit

-csf analysis can be relied on after days of antibiotics

- Which of the following is wrong about **-----** bulbar palsy ?

Has hyperreflexia

❖A patient presented with symmetrical loss of position, touch, vibration sensations of both feet up to the ankle joints. He is likely suffering from:

- 1-tumor in posterior dorsal thoracic spine
- 2-diffuse L5-s1 prolapse
- 3-ischemic stroke

الجواب 1

**Which
disease
causes
sensorineur
al hearings
loss?**

- a. Meniere's
disease**

False matching:

Cataplexy: narcolepsy

Akathesia: antipsychotics

Lower motor neuron signs: motor neuron disease

Dystonia: continuous muscle contraction

A feature of trigeminal injury? Jaw hyperreflexia

False about mini mental status examination?

Subtraction of 7 from 100 is a test for registration

Which of the following is falsely matched?

Hemiballismus: ipsilateral subthalamic lesion

Which of the following is false about oculomotor nerve?

Accommodation is preserved in oculomotor nerve injury

hyperacusis due to stapedius muscle paralysis

According to the sensory examination. One of the following is False?

-small nerve neuropathy lead to balance problem

Most common form of GBS?

-Acute inflammatory demyelinating polyneuropathy

Glascow coma for patient who opens eyes to pain, localises to pain and is confused? 11

On examination patient can flex arm against gravity but not against resistance what is the power of elbow flexors? 3

Which of the following is true about seizures?

50% of people who have epilepsy have normal EEG

If MRI revealed a temporal lobe pathology, treatment should be started

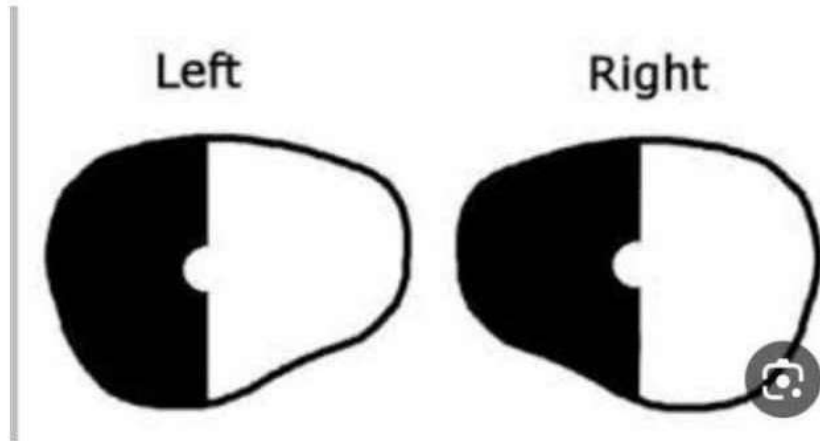
All of the following are tests for vestibulocochlear nerve except?

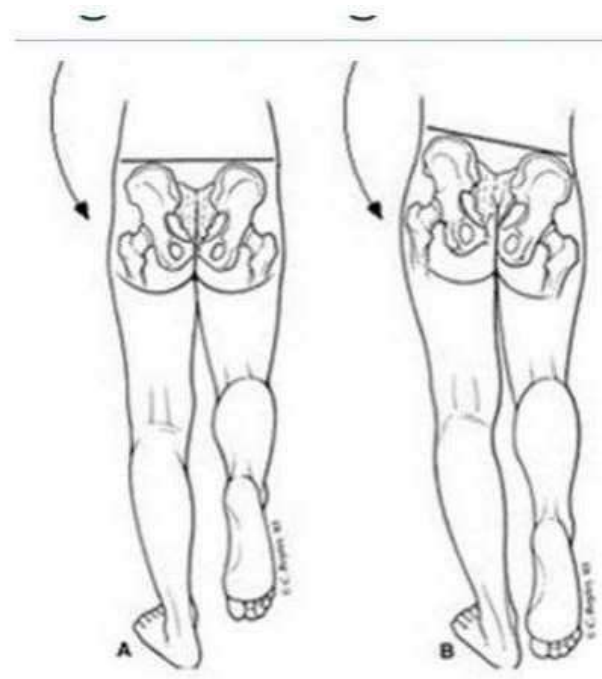
Pupillary reflex

With unilateral optic neuritis, all true except?

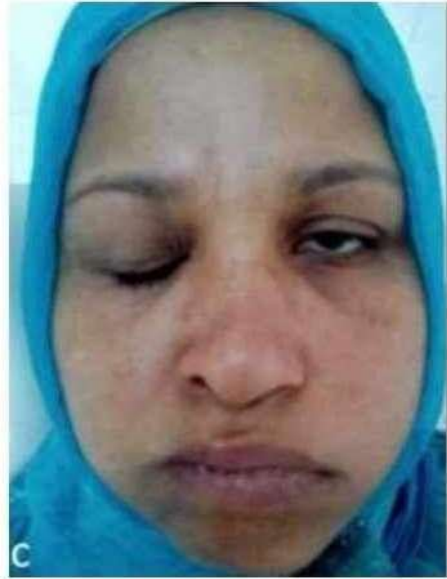-homonymous hemianopia

Occipital lobe lesion





Positive in superior gluteal nerve lesion

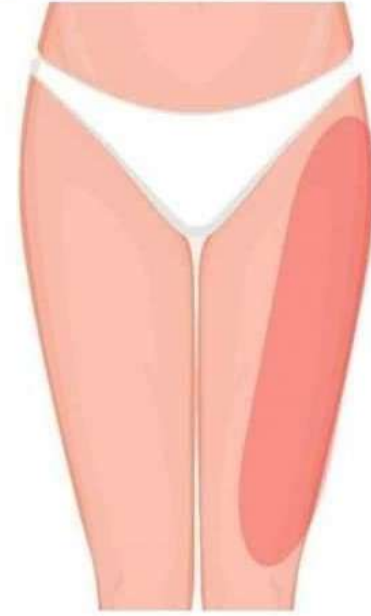


Which of the following is true?

- 1- loss of sensation in face
- 2- she had a stroke
- 3- taste sensation is preserved
- 4- MRI is not necessary

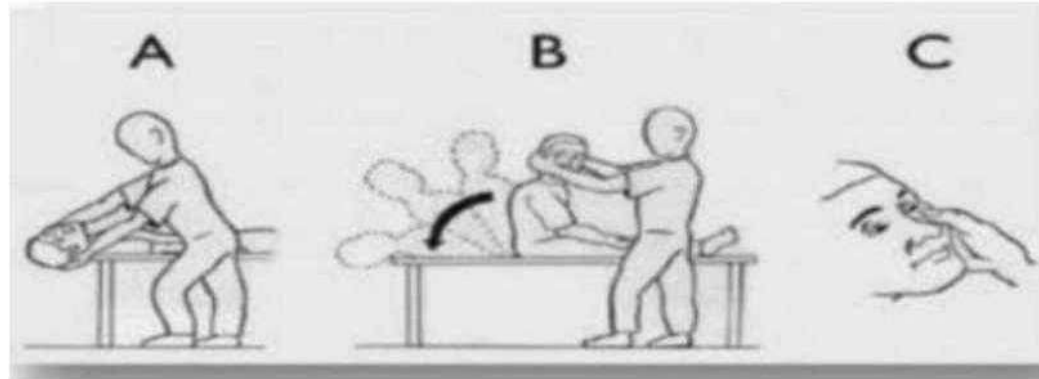
Pt comes with loss of sensation over this area,
what is true?

- Power of lower limb is not affected
- sural nerve injury
- pudendal nerve injury



What is this test used for?

Paroxysmal vertigo due to endoliths in the posterior semicircular canals



- 50 years old female pt came to ER with progressive severe headache , your initial investigation to do :
- a) esr and crp *****
- b) spinal cord mri
- c) csf analysis
- d) brain CT scan
- e) brain mri

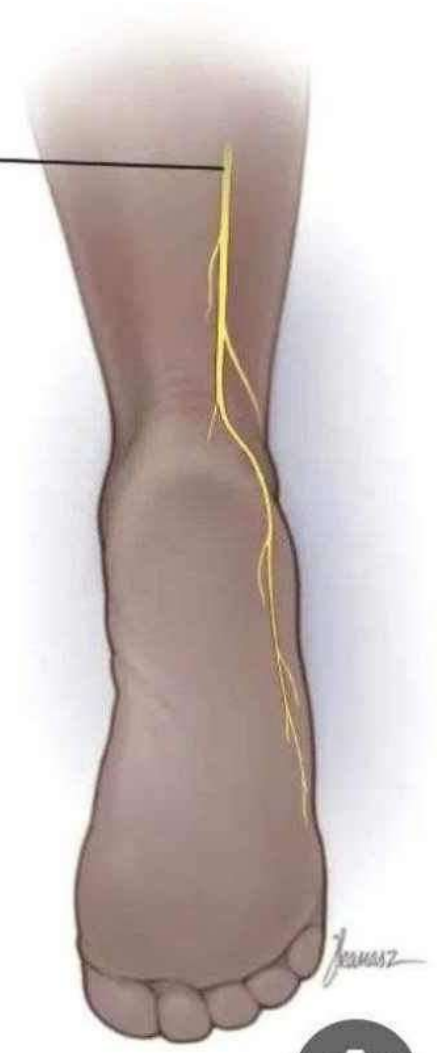Sural nerve

atic nerve

nmon
ilar nerve

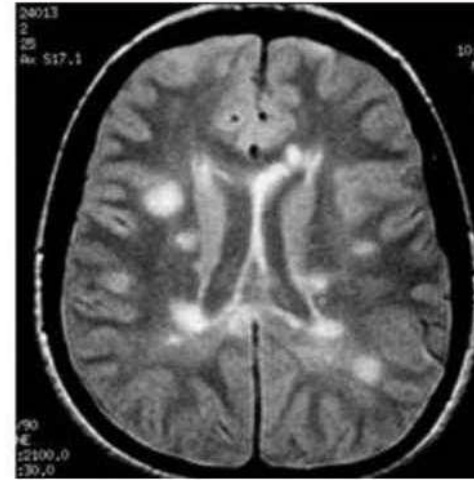
al nerve

al nerve



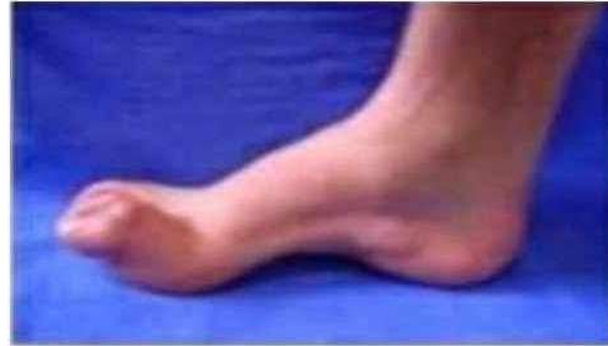Pt comes with right lower limb weakness What is the next step to diagnosis?

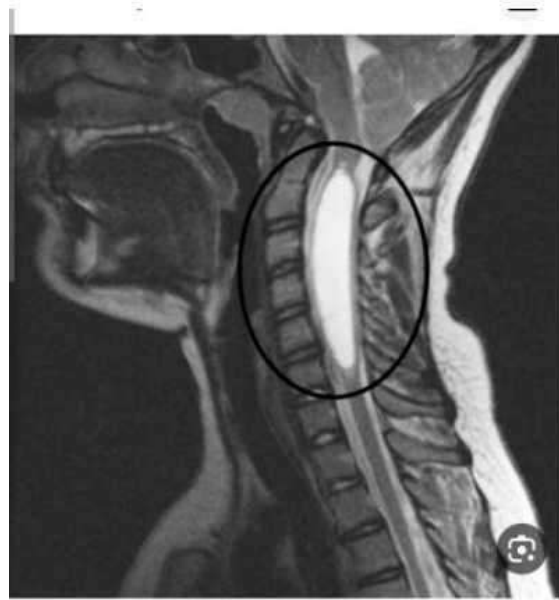-repeat MRI every 6-12 months



False about this condition?

- Mostly inherited
- bilateral homogenous symmetrical
- ankle reflex preserved



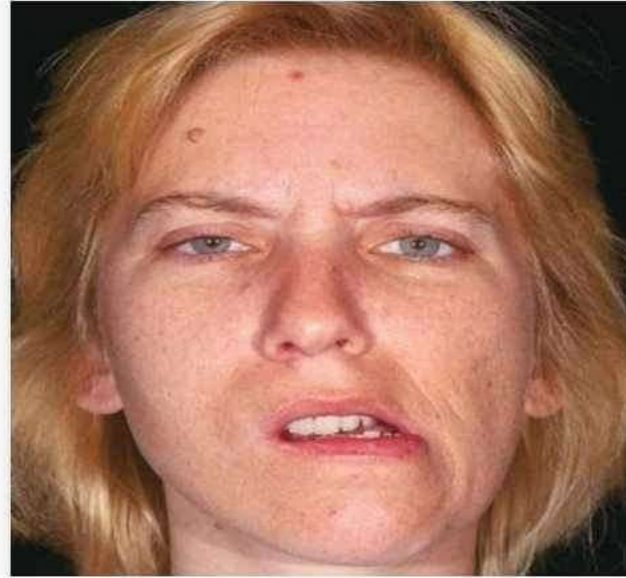

T2 Syringomyelia

Q3. Whats the muscle affected :

- A. Right pterygoid muscle
- B. Left pterygoid muscle

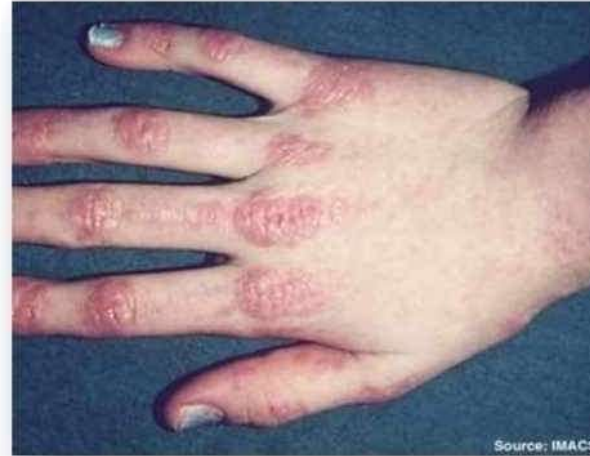ANSWER : B



- which of the following ass with facial nerve injury:
- a) hyperacoustic stapeduis paralysis*****
- b) pterygoid paralysis
- c) intact facial expressions
- d) loss of jaw reflex

Q10. what's the most likely diagnosis :

Dermatomyositis



21- a patient presented with status epilepticus, he was given 10mg of diazepam but didn't get better, he was given another 10mgs but it also didn't work. What is the next step ?

- a. 20mg of phenytoin + saline for 2 minutes
- b. 20mg of phenytoin + glucose infusion
- c. 20mg of phenytoin + saline infusion
- d. 20mg of phenytoin + glucose for 2 minutes
- e. Propofol

Correctly matched:

A- TB

A- Viral

	A	B
Opening pressure	elevated	elevated
WBCs	Elevated mainly lymphocytes	Elevated mainly neutrophils
RBCs	none	few
Glucose	Marginally significantly low	low
Protein	high	high
Appearance	turbid	turbid

- All of these test are for cerebellum except :
 - Finger to nose tes
 - Heel to shin test
 - Rapid alternating movement
 - Rebound test
 - Romberg test

➤ 75 years old male came with acute stroke. He has right side weakness. He has spontaneous speech with occasional paraphrasic errors. He cannot understand and follow commands, and repetition is affected.

❖ Which of the following best explains his speech pattern?

- a. Broca aphasia
- b. Transcortical aphasia
- c. Conduction aphasia
- d. **Wernicke aphasia**
- e. Global aphasia

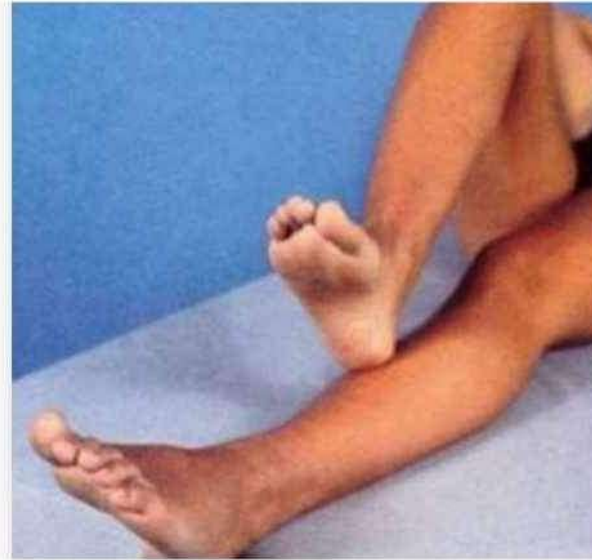


- one of the following is the main common manifestations of Meniere's disease :
- a) otoliths in endolymphatic fluid
- b) excessive endolymph *****
- c) bilateral hearing loss
- d) no hearing loss
- e) diagnosed by Dix-Hallpike maneuver

Q16. what's is this test examining :

- A. Left cerebellum
- B. Right cerebellum
- C. Right cerebral
- D. Left cerebral
- E. Dorsal columns

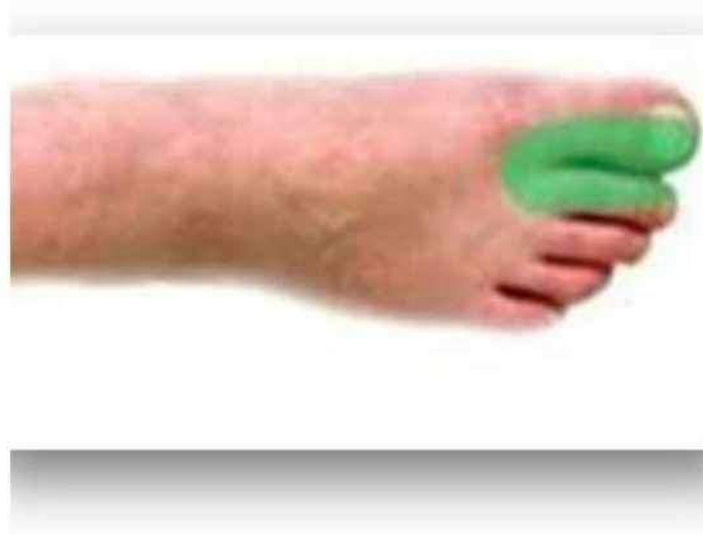ANSWER : B



Q1. patient has sensory loss in the highlighted area , most likely clinical sign found :

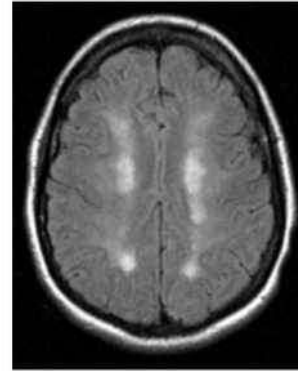
- A. Weakness of tibialis anterior
- B. Weak eversion
- C. Plantar flexion upward

ANSWER : A



Q18- This condition is caused by ?

- A. Severe hypertension
- B. Severe hypotension
- C. Encephalitis
- D. Meningitis
- E. Vasculitis



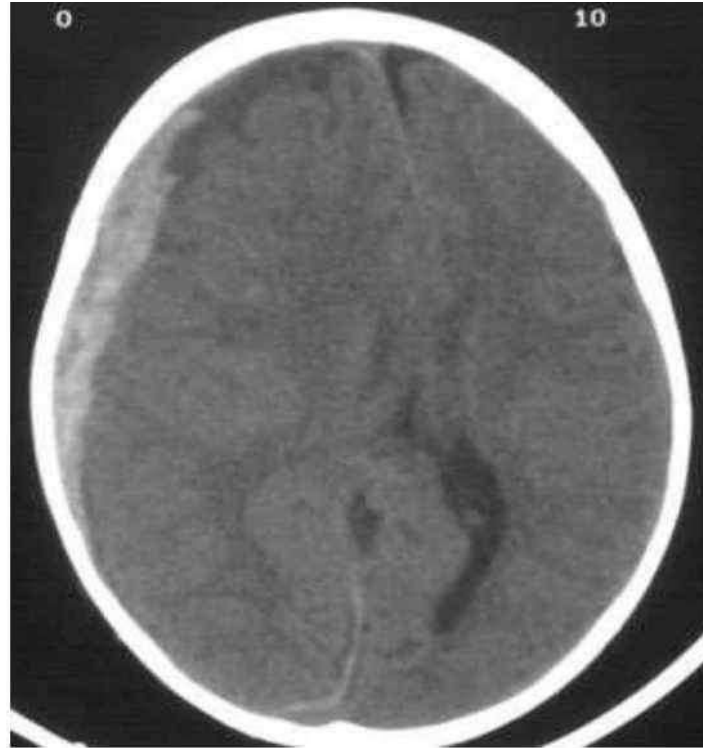
- Vagus nerve and glossopharyngeal nerve are responsible for the followings except :
 - Gag reflex
 - Taste sensation og posterior 1/3 of tongue
 - Swallowing
 - Deviation of tongue

- .One of the following is main feature of trigeminal nerve injury:
- a) loss of taste sensation of the anterior 2/3 of the tongue
- b) loss of taste sensation of posterior 1/3 of the tongue
- c) jaw hyperreflexia*****
- d) loss of touch sensation of the posterior 1/3 of the tongue

Q8. what's the name of the abnormality :

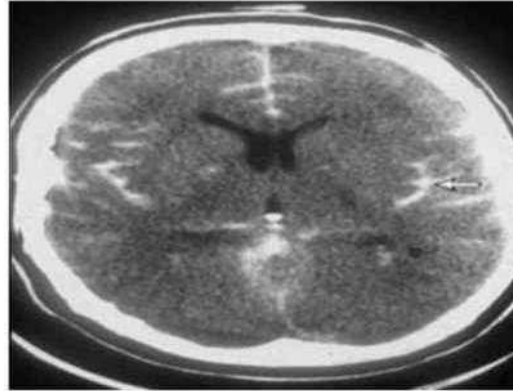
- A. subdural hematoma
- B. Intracranial hemorrhage

ANSWER : A



Q6- What is the diagnosis ?

- A. Normal CT scan
- B. Sub-arachenoid hemorrhage
- C. Cerebral infarction
- D. Multiple sclerosis
- E. Watershed infarction



- Patient looks to right, fast phase of nystagmus to left, what is the type of nystagmus ?
- A. Right jerky nystagmus.
- **B. Left jerky nystagmus.**
- C. Right pendular nystagmus.
- D. Left pendular nystagmus.
- E. Multidirectional nystagmus

Q.6

23 -A 20 years old patient came with weakness and numbness of lower extremities more than upper extremities. He was found to have generalized areflexia. The most important next step in diagnosis will be

- a. Perform brain MRI
 - b. Perform lumbar MRI
 - c. CSF analysis
 - d. Examine for dermatomal sensory loss
-

- Which of the following is wrong about ~~-----~~ bulbar palsy ?

Has hyperreflexia

Neuromedicine archive

Malak hamasha

- 1. What is the Glasgow coma scale for eye open to pain, confused, and pointed to pain:

GCS = 11

- 2. what is the affected nerve?

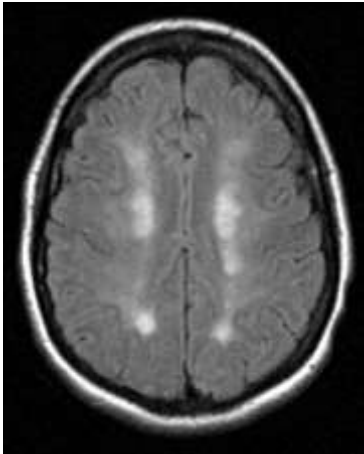
Left trigeminal nerve

- 3. This condition is caused by ?

sever hypotension

- 4. Patient look to left, fast phase to right and left, what the type of nystagmus?

multidirectional nystagmus



5. 50 years female come with persistent severe headache from last week, what is the next step ?

Discharge if ESR and CRP is normal

6. Csf analysis found : lymphocytosis and slight increase in protein and slight decrease in sugar , what is the least diagnosis of this condition ?

A. Lyme disease

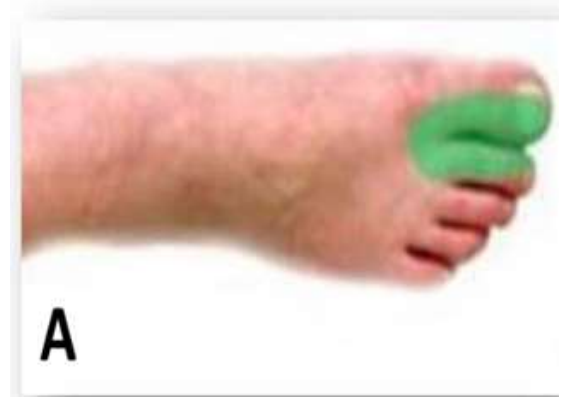B. TB

C. Bacterial meningitis

D. Viral

7. muscle that affect in lesion of the nerve supply the area shown in the picture

Tibialis anterior



8. a patient presented with status epilepticus, he was given 10mg of diazepam but didn't get better, he was given another 10mgs but it also didn't work. What is the next step ?

20mg of phenytoin + saline for 2 minutes

20mg of phenytoin + glucose infusion

20mg of phenytoin + saline infusion

20mg of phenytoin + glucose for 2 minutes

Propofol

9. A 20 years old patient came with weakness and numbness of lower extremities more than upper extremities. He was found to have generalized areflexia. The most important next step in diagnosis will be

Perform brain MRI

Perform lumbar MRI

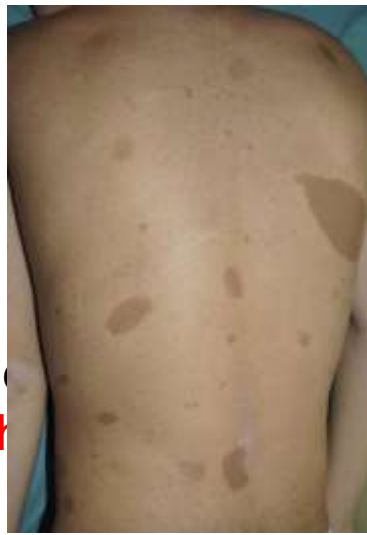CSF analysis

Examine for dermatomal sensory loss

Examine for glove and stocking sensory loss

10. This lesion occur in ?

Neurofibromatosis



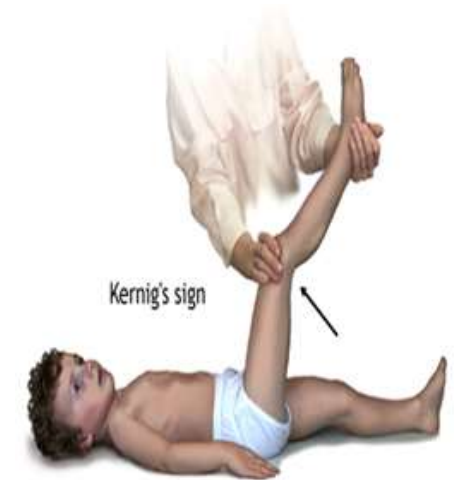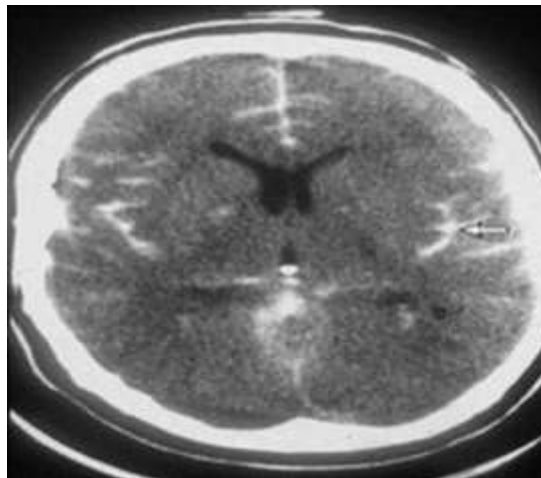
11. The patient has fever and nuchal rigidity

Delay treatment until the CSF result is sh

?

12. Diagnosis ?

Subarachnoid hemorrhage



ADAM

13. What is the diagnosis?

T2 Transverse myelitis

14. all are true about mini mental status examination except
MMSE is 30 points screening tool
used to diagnose dementia

100-7 tests registration

score of 23 risk for mild dementia

It's affected by the patient education

15. This test is used for detect the function of:

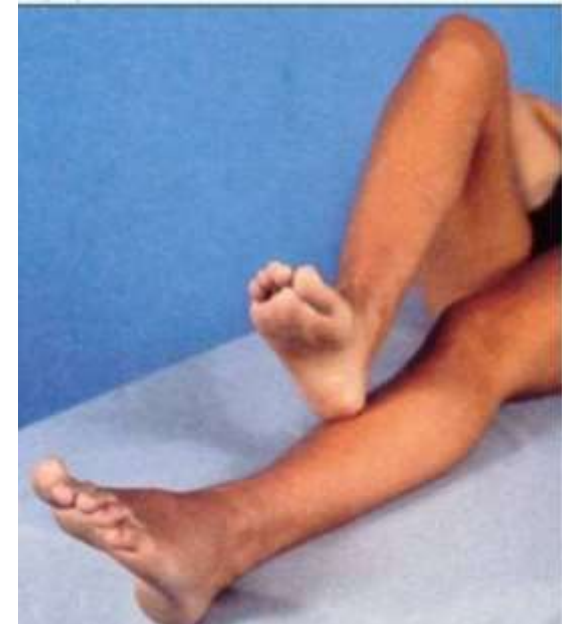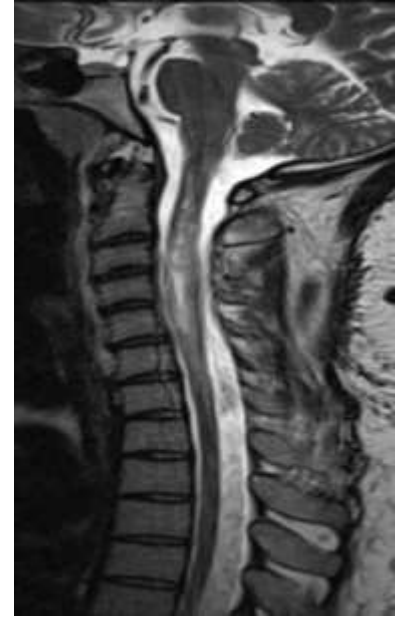A. Right cerebellum

B. Left cerebellum

C. Right cerebral

D. Left cerebral

E. Dorsal columns



16 . What is wrong ?

A. Cataplexy , myasthenia gravis

B. Tics are semivoluntary movement

C. Hemiballismus due to contralateral lesion in sub thalamic nucleus

D. Upper and lower motor sign , motor neuron disease

E. Fatigability , myasthenia gravis

????

17. All of the following found in unilateral optic neuritis except ?

Normal color vision

18. The score or degree of power if the patient can do active movement with gravity eliminated ?

2

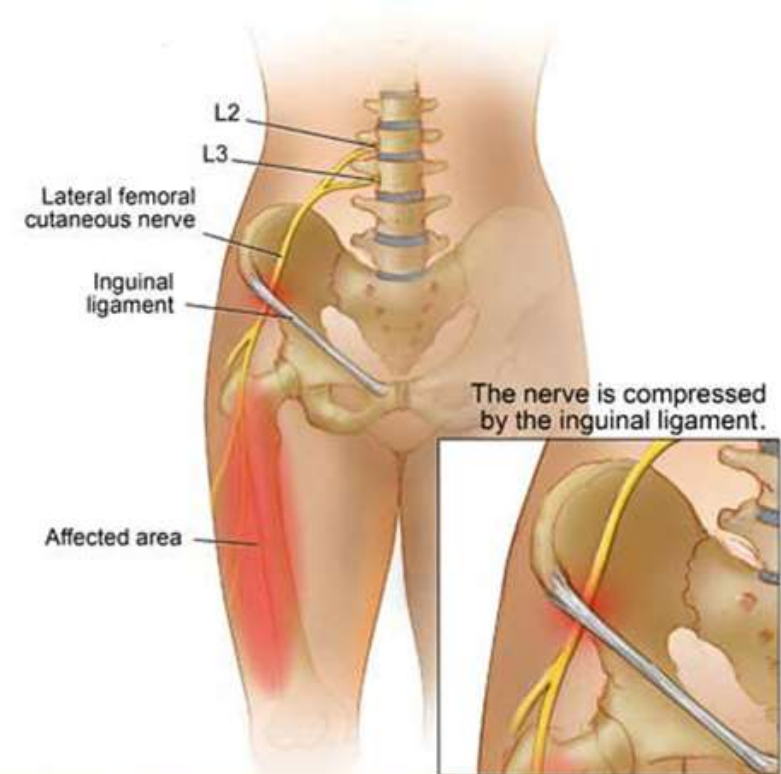
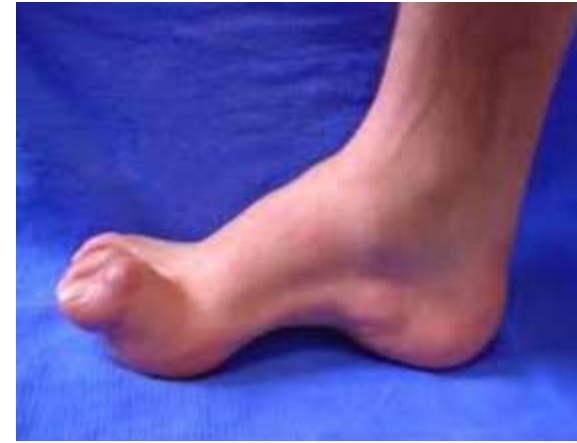19. All are true about this picture except ?

- A. Usually inherited
- B. Ankle reflex is absent
- C. It affect symmetrical
- D. Sensation affected in this area
- E. Give him corticosteroid

??

20. What nerve affected in this picture ?

Lateral femoral cutaneous nerve



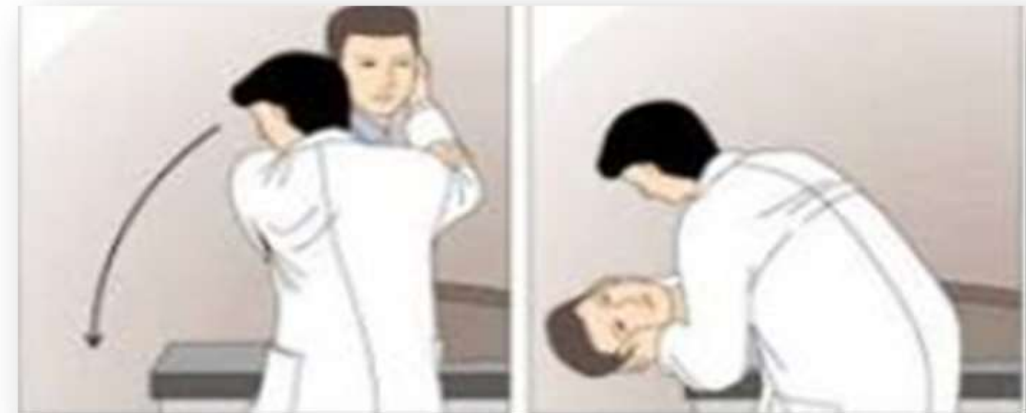21. A 75 years old male came with acute stroke. He has right side weakness. He has minimal affected speech. He cannot understand and follow commands, and repetition is affected, which of the following best explains his speech pattern?

- Broca aphasia
- Transcortical aphasia
- Conduction aphasia
- Wernicke aphasia
- Global aphasia

??

22. this test used to diagnose ?

BPPV



23. One of the following is main feature of trigeminal nerve injury:

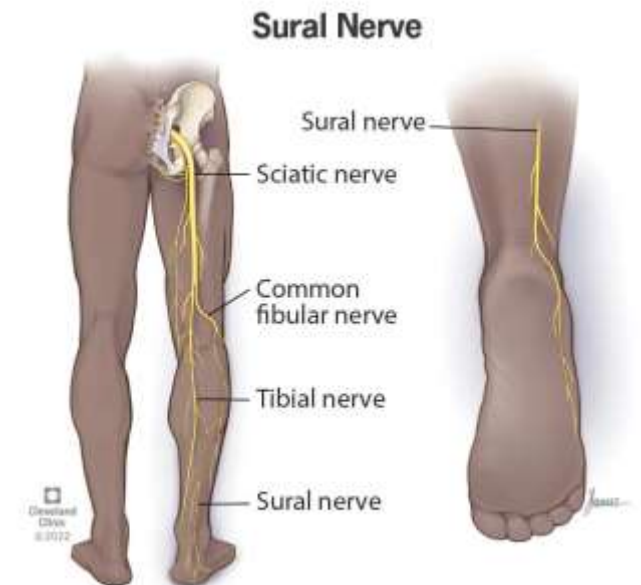
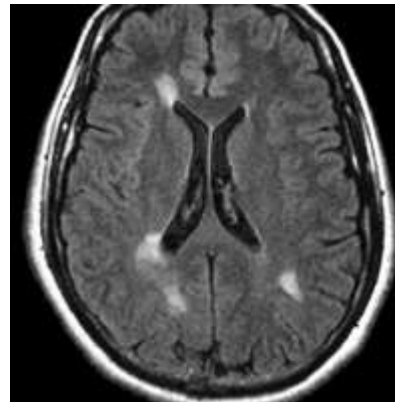
- a) loss of taste sensation of the anterior 2/3 of the tongue
- b) loss of taste sensation of posterior 1/3 of the tongue
- **c) jaw hyperreflexia**
- d) loss of touch sensation of the posterior 1/3 of the tongue

24. Name of the nerve ?

Sural nerve

25. Pt comes with right lower limb weakness What is the next step to diagnosis?

-repeat MRI every 6-12 months



26. True about bells palsy?

-Hyperacusis due to stapedius muscle paralysis

27. According to the sensory examination. One of the following is False?

-small nerve neuropathy lead to balance problem

28. Most common form of GBS?

-Acute inflammatory demyelinating polyneuropathy

29. All are used to test for coordination except?

Romberg

Finger to nose

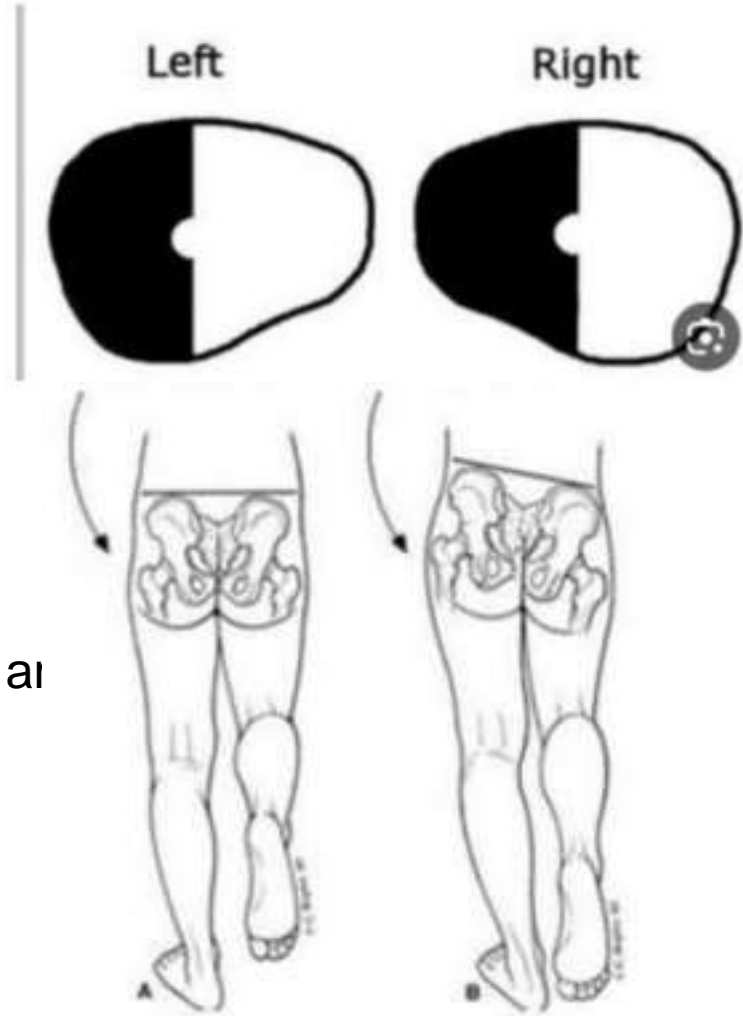
Rapid alternating

Heel-knee-shin

Nystagmus

30. Occipital lobe lesion

31. Nerve affected ?
Superior gluteal nerve

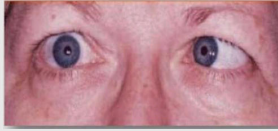


Rest of questions same as previous at

①

Which nerve is affected?

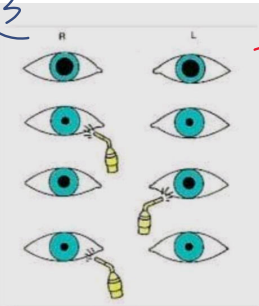
Abducent nerve



②

- Vagus nerve and glossopharyngeal nerve are responsible for the followings except :
- Gag reflex
- Taste sensation og posterior 1/3 of tongue
- Swallowing
- ~~Deviation of tongue~~
- **aphasia**

③



→ test for ?
Optic neuritis

④

> 75 years old male came with acute stroke. He has right side weakness. He has spontaneous speech with occasional paraphrasic errors. He cannot understand and follow commands, and repetition is affected.

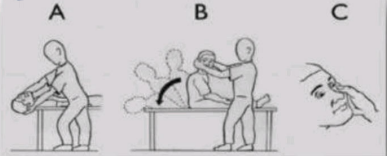- ◆ Which of the following best explains his speech pattern?
- Broca aphasia
 - Transcortical aphasia
 - Conduction aphasia
 - Wernicke aphasia**
 - Global aphasia

⑥

GCS for pt. open his eyes for painful stimulation, localize pain and confused ?

11

⑤



What is this test used for?

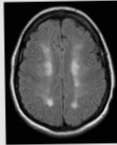
Paroxysmal vertigo due to endoliths in the posterior semicircular canals

- All of these test are for cerebellum except :
- Finger to nose tes
- Heel to shin test
- Rapid alternating movement
- Rebound test
- Romberg test

(7)

(8) This condition is caused by ?

- A. Severe hypertension
- B. Severe hypotension
- C. Encephalitis
- D. Meningitis
- E. Vasculitis

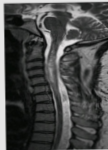

(10) a patient presented with status epilepticus, he was given 10mg of diazepam but didn't get better, he was given another 10mgs but it also didn't work. What is the next step ?

- a. 20mg of phenytoin + saline for 2 minutes
- b. 20mg of phenytoin + glucose infusion
- c. 20mg of phenytoin + saline infusion
- d. 20mg of phenytoin + glucose for 2 minutes
- e. Propofol

(9) What is the diagnosis?

- a. T1 Transverse myelitis
- b. T2 Transverse myelitis
- c. T1 syringomyelia
- d. T2 syringomyelia
- e. None of the above

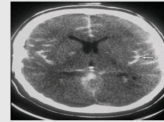


NOT THE SAME PICTURE

- Note: T1 and T2 are meant to mean T1-weighted MRI & T2-weighted MRI and not T1 spine

(11) What is the diagnosis ?

- A. Normal CT scan
- B. Sub-arachnoid hemorrhage
- C. Cerebral infarction
- D. Multiple sclerosis
- E. Watershed infarction

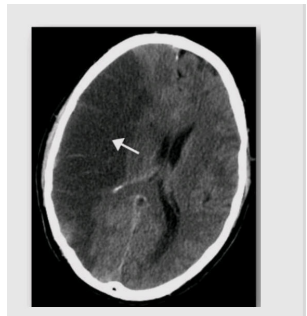

(12)

not a major risk factor for this lesion ?

- 1- DM
- 2- carotid stenosis
- 3- valvular heart disease
- 4- cardiac wall disease
- 5- atrial fibrillation

answer: 1



13. patient has sensory loss in the highlighted area , most likely clinical sign found :

A. Weakness of tibialis anterior
 B. Weak eversion
 C. Plantar flexion upward

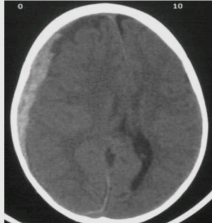
ANSWER : A



14. what's the name of the abnormality :

A. subdural hematoma
 B. Intracranial hemorrhage


ANSWER : A



15. The patient may have one of the following :

A. Tongue deviation
 B. Left ear hearing loss
 C. Left external meatus rash

ANSWER : C



16

- One of the following is main feature of **trigeminal nerve injury**:
- a) loss of taste sensation of the anterior 2/3 of the tongue
- b) loss of taste sensation of posterior 1/3 of the tongue
- c) jaw hyperreflexia*****
- d) loss of touch sensation of the posterior 1/3 of the tongue

17

- which of the following ass with facial nerve injury:
- a) hyperacoustic stapedius paralysis*****
- b) pterygoid paralysis
- c) intact facial expressions
- d) loss of jaw reflex

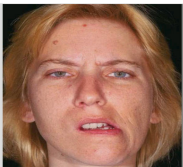
18

What's the muscle affected :

A. Right pterygoid muscle
 B. Left pterygoid muscle

ANSWER : B

العكس ع اليمين




18

Which of the following is wrong about --- bulbar palsy ?

Has hyperreflexia

20



Sural nerve
 Iliac nerve
 Tibial nerve
 Peroneal nerve

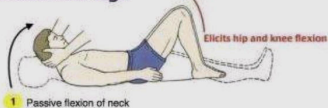Patient presented with fever, neck stiffness and this sign positive, which of the following is false?

-imaging is used before lumbar puncture if there is focal neurological deficit

-csf analysis can be relied on after days of antibiotics

(21)

Brudzinski Sign



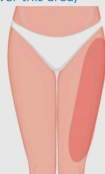(23)

Pt comes with loss of sensation over this area, what is true?

-Power of lower limb is affected

- sural nerve injury

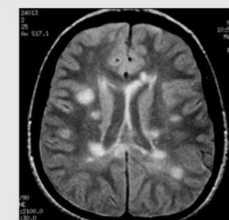
- pudendal nerve injury



(22)

Pt comes with right lower limb weakness What is the next step to diagnosis?

-repeat MRI every 6-12 months



Occipital lobe lesion

(25)

Left

Right



(24)

Correctly matched:

A- TB

A- Viral

	A	B
Opening pressure	elevated	elevated
WBCs	Elevated mainly lymphocytes	Elevated mainly neutrophils
RBCs	absent	few
Glucose	Marginally low	low
Protein	high	high
Appearance	turbid	turbid

26

According to the sensory examination. One of the following is False?

-small nerve neuropathy lead to balance problem

27

Most common form of GBS?

-Acute inflammatory demyelinating polyneuropathy

28

On examination patient can flex arm against gravity but not against resistance what is the power of elbow flexors? 3

29

False about mini mental status examination?

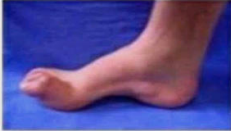Subtraction of 7 from 100 is a test for registration

30

False about this condition?

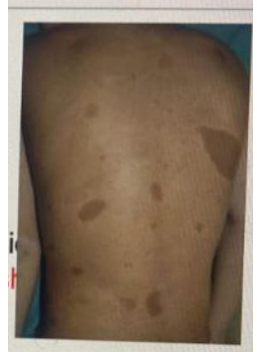- Mostly inherited
- bilateral homogenous symmetrical
- ankle reflex preserved

asymmetric



33

diagnosis: neurofibromatosis



31

first attack of epilepsy, which is true ?

- 1- MRI not necessary
 - 2- low IQ of pt. affect the prognosis
 - 3- we give antiepileptics in first attack
 - 4- EEG always abnormal
- (2)

سنوات (1)

Golden rule for these questions

- A 20 years old patient came with weakness and numbness of lower extremities more than upper extremities.
- ❖ When you see this presentation (weakness & numbness more in the lower limbs) there are 3 differential diagnoses:
 1. If there is normal reflexes, it's transverse myelitis:
 - Next step: perform spinal MRI (must contain thoracic spines)
 2. If there is hyperreflexia, it's Conus medullaris syndrome:
 - Next step: perform lumbar MRI
 3. If there is hyporeflexia, it's Gillian-Barre syndrome:
 - Next step: perform lumbar puncture + CSF analysis

32

answer: spinal MRI

33

pt. complain of headache, which one is false ?

- 1- ESR is sensitive test
- 2- biopsy can confirm the diagnosis
- 3- the pt may suffer from amaurosis fugax
- 4- we can't give steroids until the result of culture appears.

4

34 which of the following is wrong matched :

- 1- akathisia usually caused by drugs
- 2- tardive dyskinesia usually caused by infection
- 3- dystonia is sustained muscular contractions
- 4- intentional tremor increase in intensity while directing to the object

2

35

patient with Optic neuritis, all of the following finding are present in this patient except:

1. Visual acuity defect
2. Visual field defect
- 3- ophthalmoplegia
4. Color vision defect
5. Fundoscopy maybe normal

136

36

all are tests for vestibulocochlear nerve except:
pupillary reflex

37

which is false ?
oculomotor nerve for corneal reflex

