



Wateen archive group A

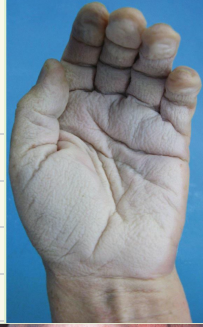**Done by: Mhmad Shehadeh
Batool Frehat**

One of the following prescribe the Picture:

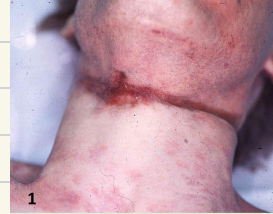- a) A is drowning B is throttling
- b) A is drowning a B is strangulation
- c) A is unknown B is strangulation

Answer: C

A:



B:



Q:2



- A) visual identification is most important method
- b) close disaster
- c) open disaster

Answer: C

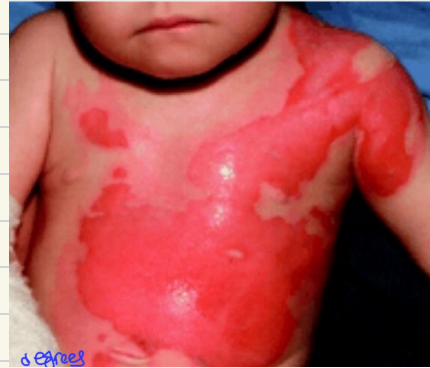Q3) one of the following is true:

A) Dry burn

b) scalds, and it is mostly non-Accidental

c) scalds, and it is mostly Accidental

d) chemical burn.



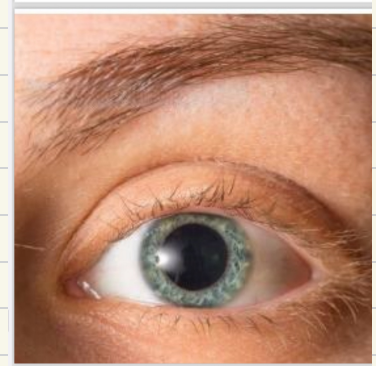Answer: b

Q4) pupil reactively dilated to light

A) amphetamine, cocaine

b) opiate, phenothiazine, OPI

C) anticholinergic



Answer: A

Q5) Ethanol found in body after death due to:

a) Antemortem ingestion.

b) only in diabetic patient

c) Postmortem fermentation.

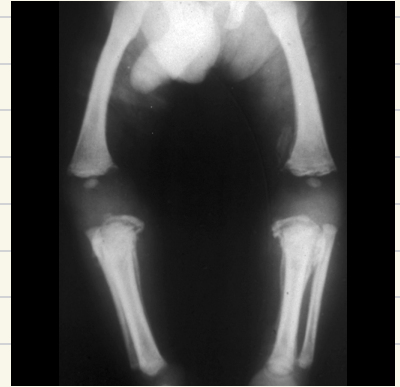
Answer: C

Q6: upper end of Tibia indicate

a) Bucket-handle fracture.

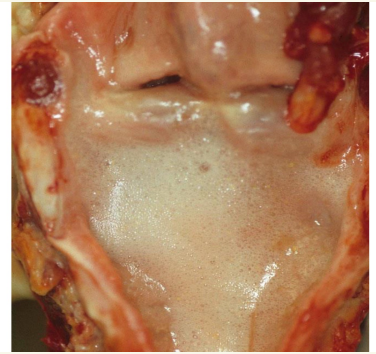
b) primary ossific center.

Answer: A



Q7:

Answer: sure drowning



Q8: this method of identification called:

A) dental print

Answer: B

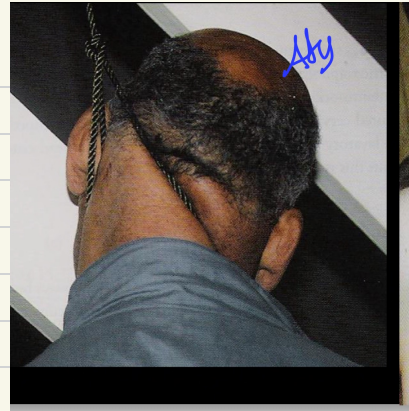b) facial reconstruction



Q9) this image indicate:

- A) incomplete Atypical Hanging**
- b) Atypical Hanging**
- c) complete typical Hanging**
- d) complete Atypical**

Answer: b



Q1 0) Traumatic Abortion:

- A) longitudinal in lower segment**
- b) Transverse**
- c) longitudinal in the fundus**

Answer: C

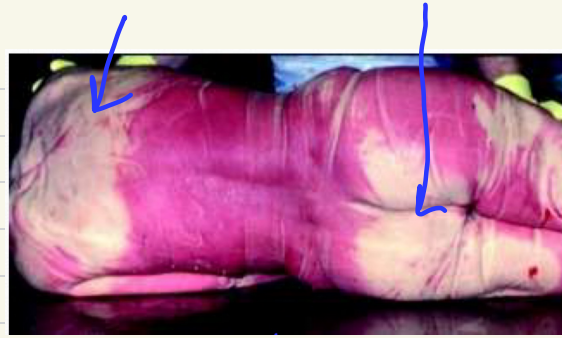Q1 1) - 3 people were in this building, one died, the 2nd had myocardial ischaemia and the 3rd only suffered from severe headache, what is the management?

Answer: hyperbaric oxygen for the 2nd patient

Q12: the arrows indicate:

- A) area of vasodilation**
- b) Hypostasis**
- c) flattened area with contact**
- d) Area of vasoconstriction**

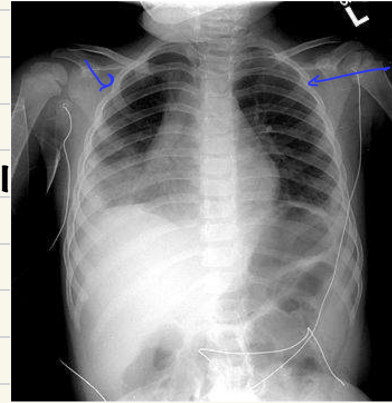
Answer: C



Q 13

- A) admission with antibiotic a oxygen**
- b) Admission only when symptomatic with antibiotic a oxygen without Activated charcoal**

Answer: b.



Q14) the age of female:

- A) below 16**
- b) above 18**
- c) between 16 and 18**
- d) above 20**

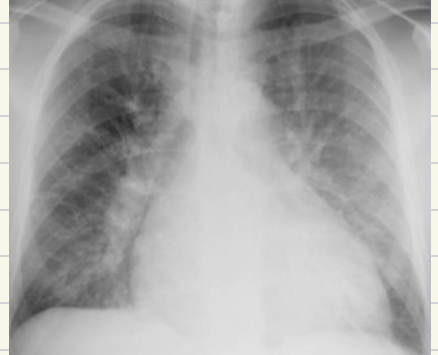Answer: C

* كانت ال Epipheseed plate مبينة بنهاية ال radius. و مش مبينة غي نهاية ال Metacarpals

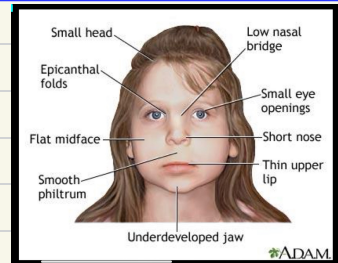
15) Patient come with this CXR with normal pupil size what are the possible toxins??

Opiate Organophosphorus Salicylate

- A) opiate,OPI**
- b) Opiate , Salicylate**
- C)all of them**
- d)Salicylate**



Q1 6: these symptoms indicate
Answer: Fetal Alcohol syndrome



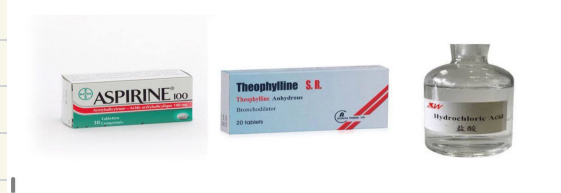Q1 7) All of the following characteristic Except:

- A)it is vasculotoxic**
- b)mild to moderate local manifestation**
- c)Ptosis is common**

Answer: C



Q18) Urine alkalization indicated in which of these toxins



Answer: salicylate only

Q19) Which of the following incorrect about naloxone

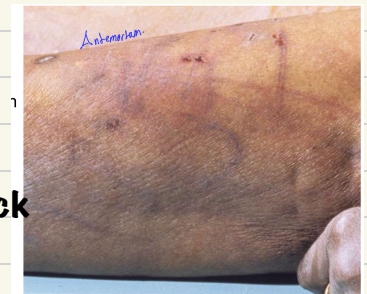- part of cocktail for coma
- diagnostic and therapeutic for coma cause
- may exacerbate opiate withdrawal manifestation
- pharmacological antagonist of opioids

- long acting opioid antidote

Answer

Q20) Picture indicate:

- a) Pattern wound due to flexible whip
- b) Pattern wound due to fixed instrument like stick
- c) Bruises due to flexi bc ble whip
- d) Bruises due to lived instrument like stick



Answer: A

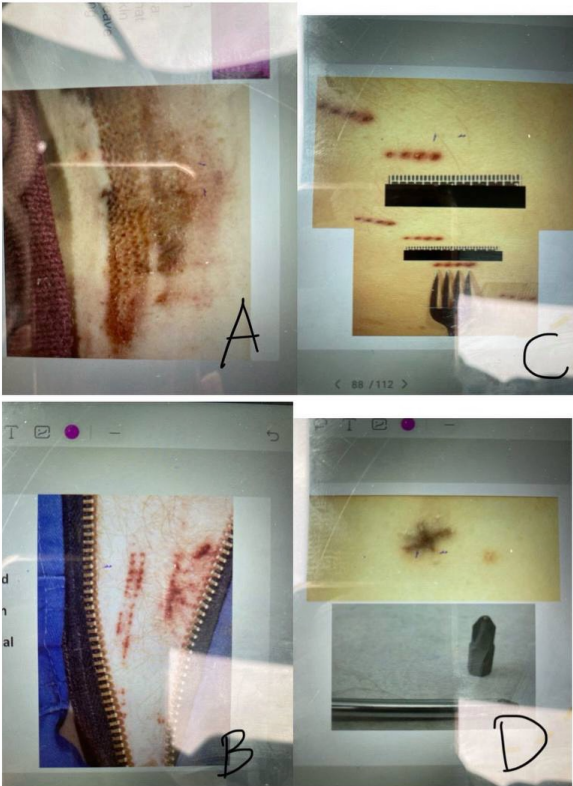
Q21) one of the following is true about picture.

- As Patent print**
- b) latent print**
- C) 3d print**
- d) plastic print**



Answer: b

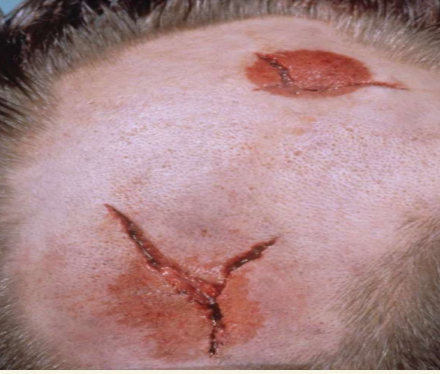Q22)



All are patterned caused by blunt object
AB are patterned caused by blunt object ,CD are patterned caused by force sharp objects

Written Questions

1
Write wound report.



كانت الصورة قريبة من هاي

2
A female patient come to ER with sudden onset of dyspnea and history of previous DVT ,treatment started put the patient die

...Write Death Certificate

3

ال toxin

كانت بنت ٢٠ سنه اخذت ٥٠ تايلت من البنادول

The historical information!!!

The most important decontamination??

Only 2 investigations should obtained in this case!!!!

4

صورتين firearm wounds

وحده reflied مثل النجمه كانت

و الثانيه nonreflied

طلب الدكتور وصف للصورتين؟؟

و طلب مسافة الإطلاق مع التوضيح!!

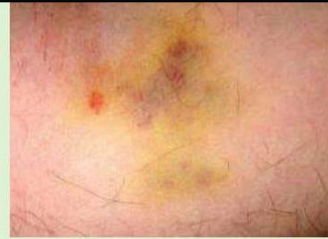Forensic

Group B

• 21) which of the following is true?

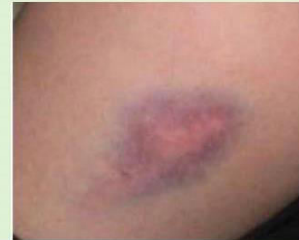
- a. A is older than B
- b. B is older than A

Answer: A

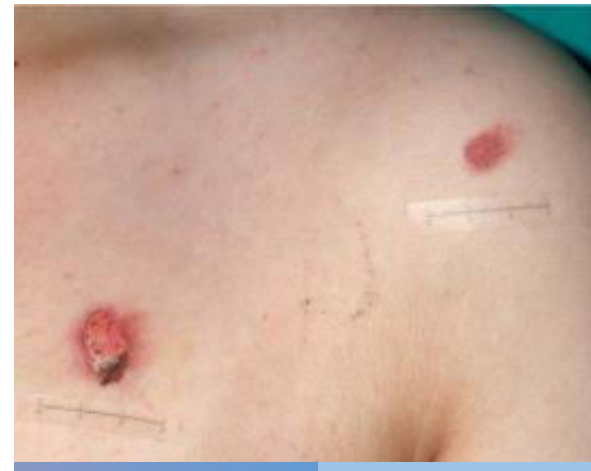

A

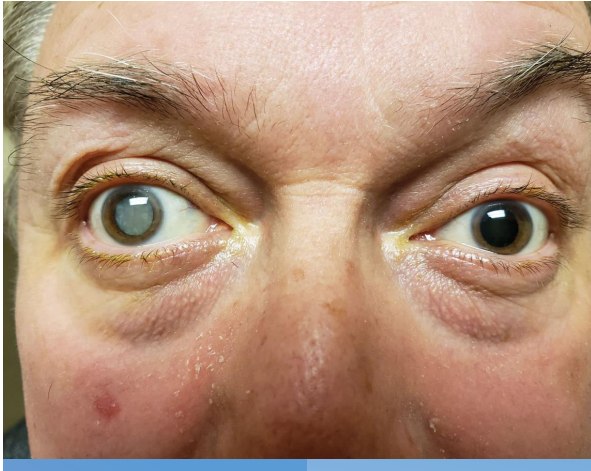B



- 100% oxygen with pressure



- Child abuse because multi injury from single Cause



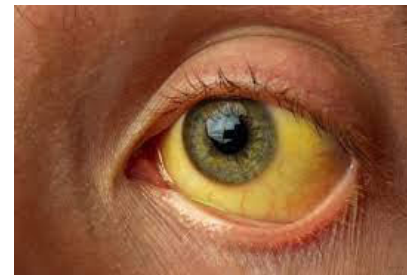Permanent infirmity



Mugging

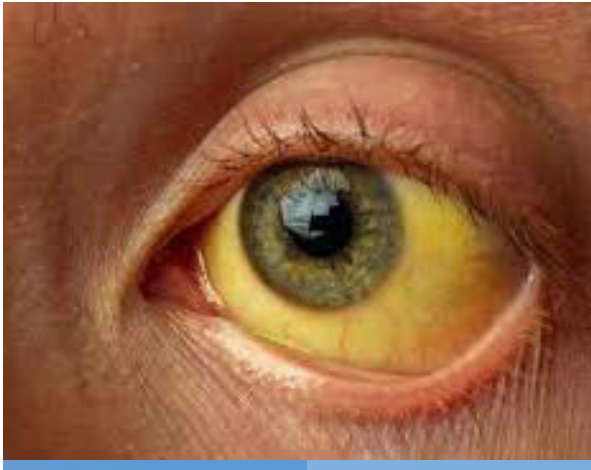

Live reffiling



which of the following cause this condition?

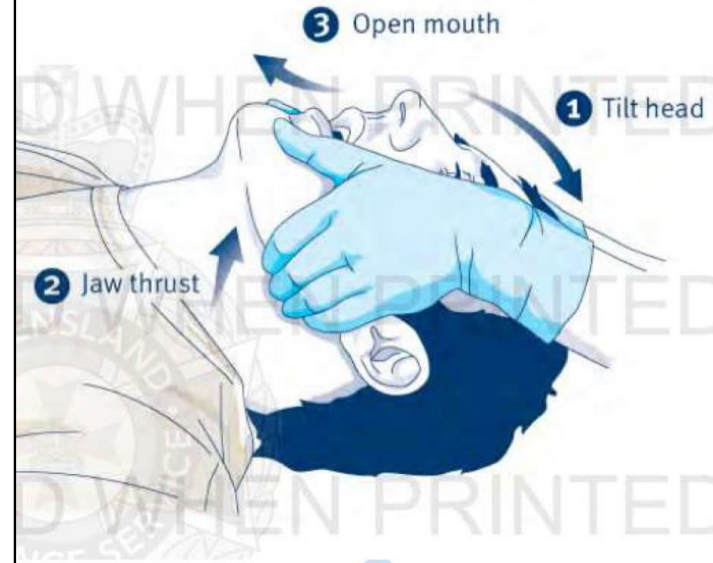
Answer:
Iron ,Paracetamol ,Alcohol ,Phosphorus



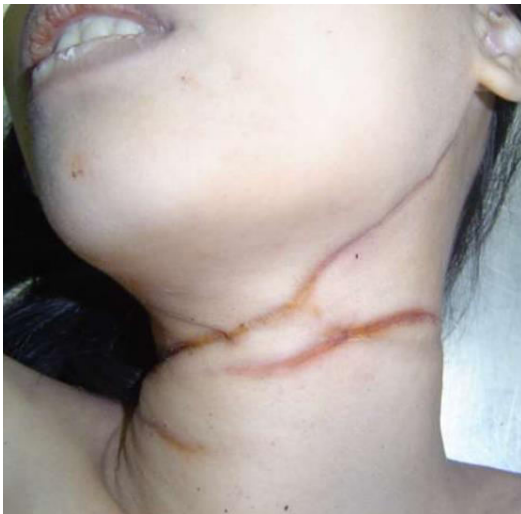All of this can use to treat this case ,except:

- A. oral N-Acetylcysteine
- B. IV N-Acetylcysteine
- C. decontamination
- D. life support

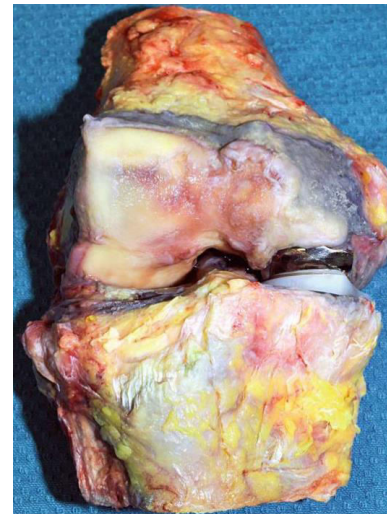• Answer: C



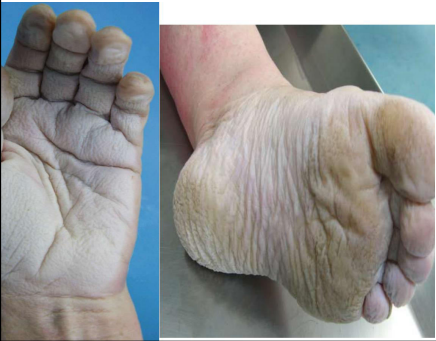- Triple airway manoeuvre for Airway opening



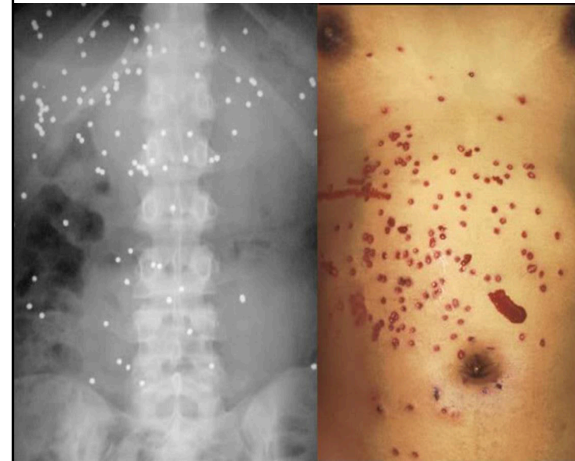hangging



medical record

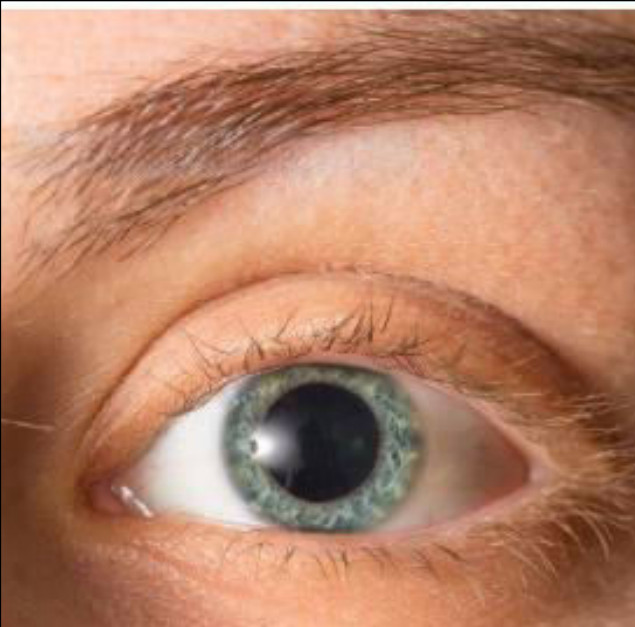

- Sure signs of drawing
- **May be drawing**

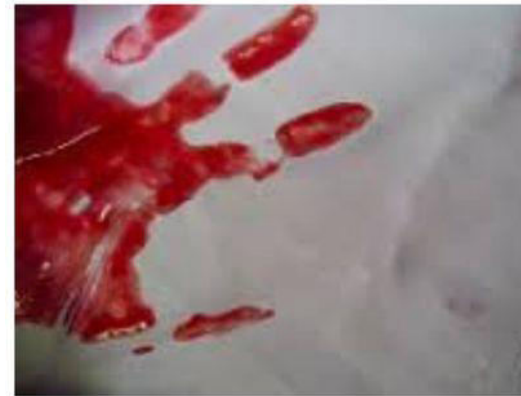

Not the same

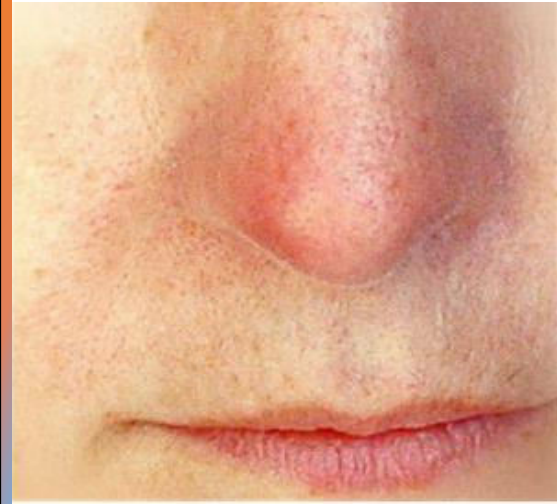Non rifle, less than 4m



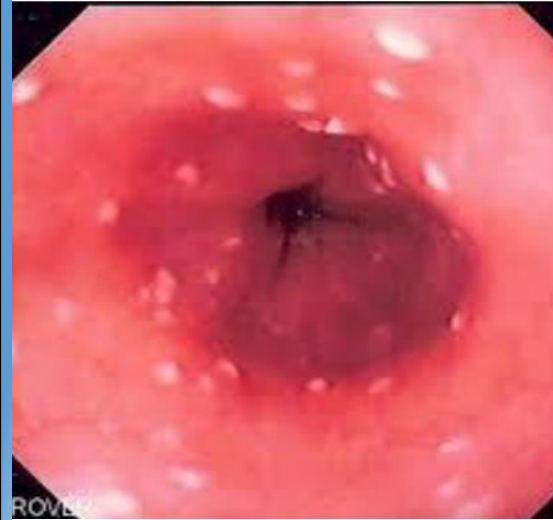- Non reactive dilated :
which of the following
cause this condition?
- Anticholinergic



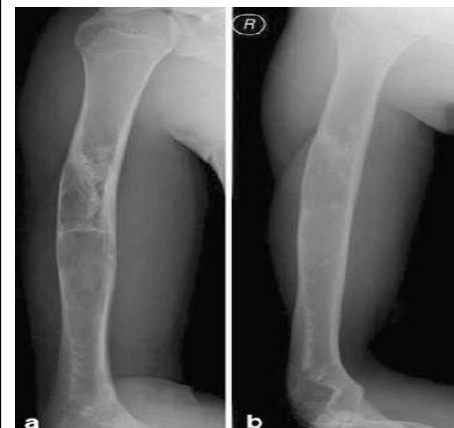- Patent prints



- Rhinophyma



- Hot endoscopy in 1st 24 hr

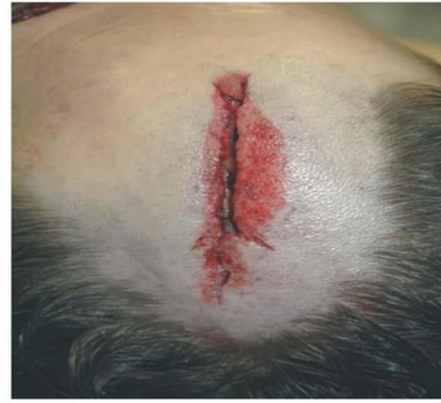

- Less than 16

صورة تقريرية للكتف والكوع

- A patient came with and decreased visual acuity and Hyperemia of optic disc . What is the cause ? Methanol
- Red hypostasis ?? Co , cyanide, hypothermia

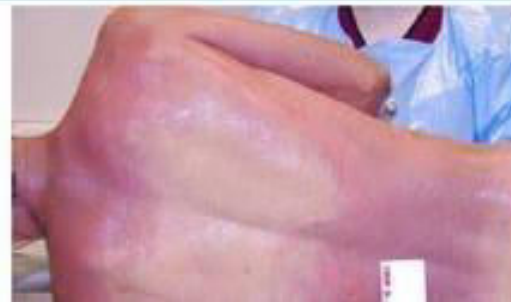اسئلة الكتابي



Write a wound report
بالعربي ,

- 10 y male with high fever , he dignosia as viral encephalitis ,later spread to mid brain , coma, ventilator for 3 day and die

- death certification?



what is PM change??
what is the interval of cadaveric warmth??

hypostasis
(3-8)h

- 33 y male who bite by snake (frank bite)and not notified it , his family membrane apply ice on site of bite then take him to ER,the doctor say that he is completely free , give him single dose of antivenom and discharge him.
- mention 2 wrong behaviour
- what is the antivenom that use in jordan??
- Why did he not show any symptoms even though the snake bit him?

- 1) give him single dose of antivenom(no symptom)/ apply ice on site of bite (cryotherapy)
- 2) polyvalent
- 3) Non-venomous viper/dry bite

بِسْمِ اللّٰهِ الرَّحْمٰنِ الرَّحِیْمِ

ارشیف الشریعی

Done by : Eiman Alrfou & Afnan bassam

Mcq questions

Q1. uncontrolled hyper emises gravidum indicate :

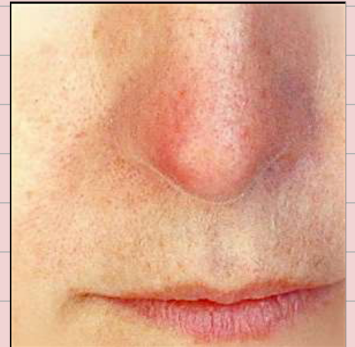- A. Spontanoues abortion
- B. Theraputic abortion
- C. Illegal abortion
- D. Criminal abortion

Answer : B

Q2. Which one of the follwing is true about this picture:

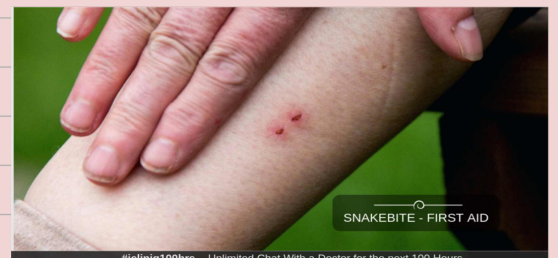- A. Acute alchol intoxication
- B. Rinorrhea
- C. Rhinophyma

Answer: C



Q3. The patient in this picture has a "snake bite" all of the follwing measure can do except :

- A. apply ice on the site of bite
- B. Immobilize the injured part of the body



C. Fashion a splint out of any rigid object

D. avoid walking at the site of injury

Answer : A

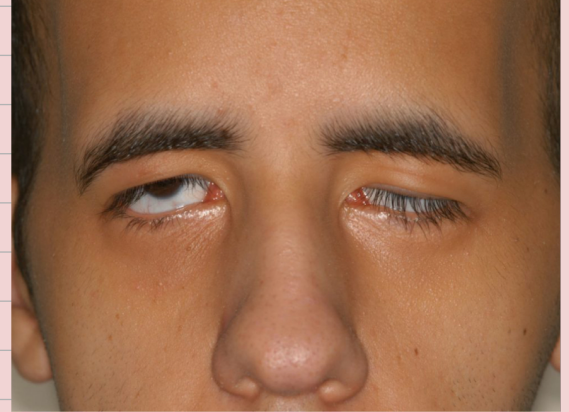Q4. The following manifestaion caused by :

A. Bite from copra

B. Bite by palestinian snake

C. Bite frome the viperidae familiy

D. Caused vasculotoxic effect mostly



Answer : A

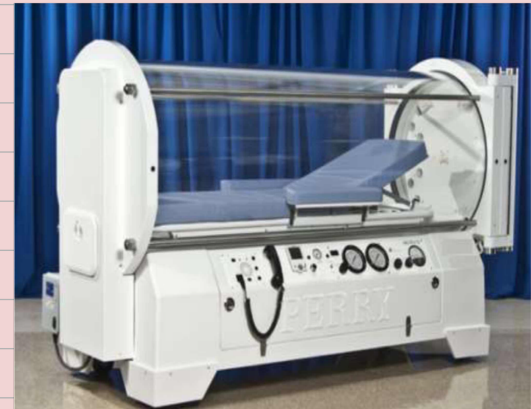Q5. Which of the follwing about this device true:

A. Used in paient with CO_2 toxicity

B. Used when level of oxygen below 10%

C. Used 100% oxygen at normal atmospheric pressur

D. 100% oxygen indicated in pregnancy ,coma and myocardial ischemia



Answer : D

Q6. Case study about methanol which of the follwing drug not indicated

In methanol toxiety:

A. Hemodialysis

B. 4 metyl pyrazole

C. Ethanol

D. Sodium bicarbonate

E. calcium gluconate

Answer : E

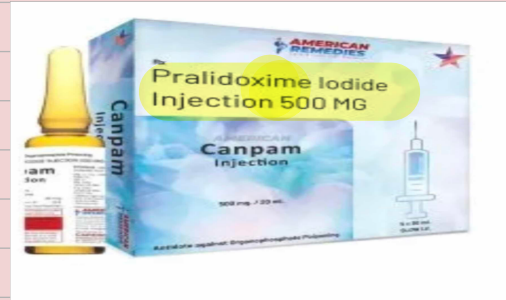Q7. One of following is mostly true :

A. Used in malathion before 48 hour

B. Used in malathaion and carbamate

C. Used in malathion after 48 hour

D. Used in carbamate before 48 hour



Answer : A

Q8. One of the following is true about picture :

A. Patent print

B. Latent print

C. 3d print

D. Plastic print



Answer : B

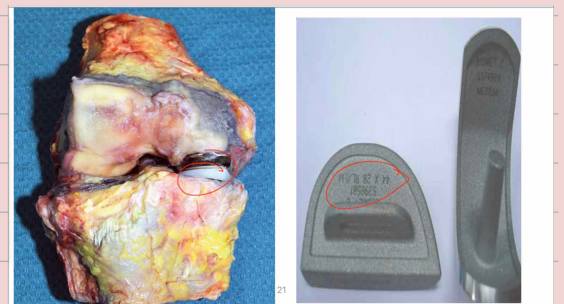Q9. The method of identification used in this picture :

A. Dental identification

B. age estimation

C. X ray

D. Medical record

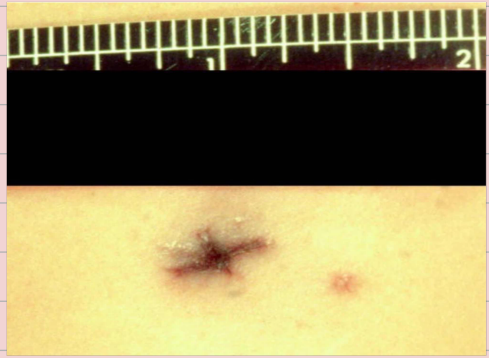


Answer : D

Q 10. This injury most likely considered :

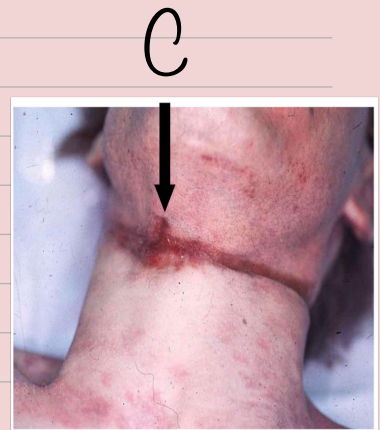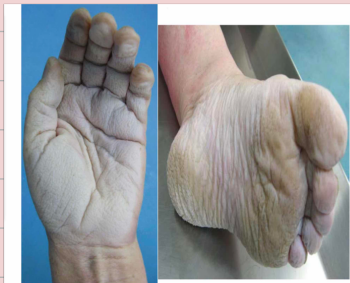- A. Penetrating wound
- B. Transfixing wound
- C. Perforating wound
- D. Pattern wound

Answer : D

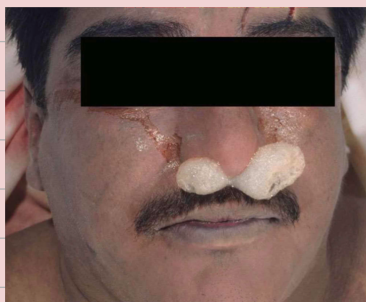

Q 11. Chose the correct answer :

- A. immersion, froth, strangulation
- B. Drowning, froth, strangulation
- C. Immersion, froth, hanging
- D. Drowning, froth, hanging



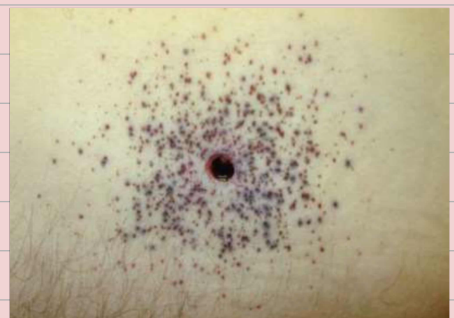Answer : A



Q 12. The distance of this firearm injury :

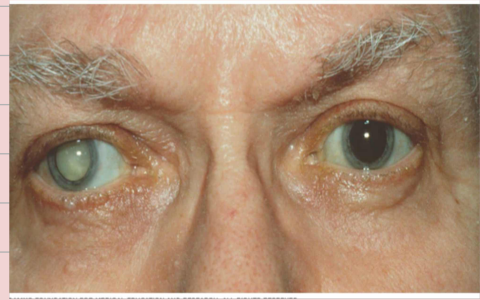- A. Less than 6 m
- B. Less than 1 m
- C. Less than 6 Km
- D. More than 3 m

Answer : B



Q 13. This effect mostly due to :

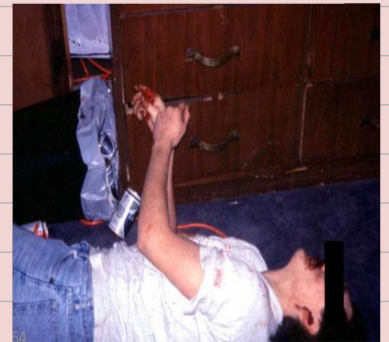
- A. Simple blunt object
- B. Simple sharp object
- C. Dangerous blunt object
- D. fatal blunt object



Answer : C

Q 14. This picture show "cadaveric sign" the estimated time of death :

- A. More than 8 hour
- B. Less than 6 hour
- C. More than 36 hour
- D. Less than 3 hour early

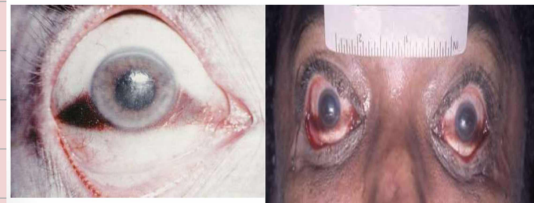


Answer: D

Q 15. Chose the correct answer :

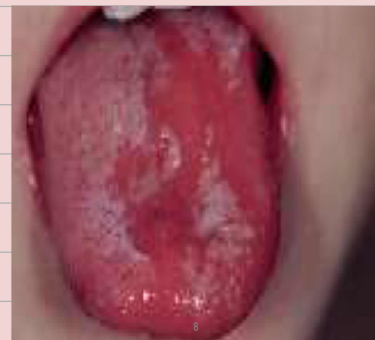
Early change on eyes postmortem

Tache noire: where the sclera remains exposed to air, two black triangular spots appear at each side of the cornea (due to drying).



Q 16. Choose the most correct answer

Steroid can be used



Essay questions

Arabic questions

كتابة تقرير اصابة أولي :

One cut wound in face by sharp object

السؤال الأول

كتابة شهادة وفاة :

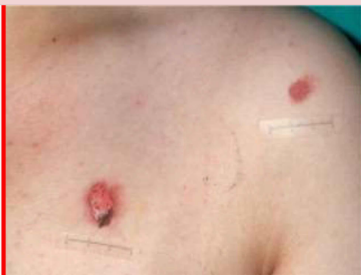السؤال الثاني

44 old female come to hospital suffer from dyspepsia and heart burn was diagnosed Peptic Dodenal ulcer after adimtion she developed pertonitis and septicemia after this she died

English questions

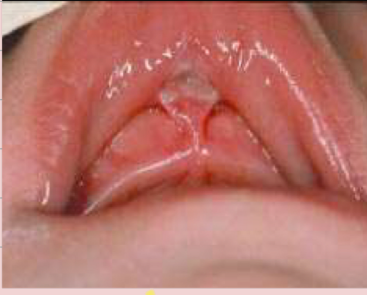
The first question

Identification the type of injury into accedental and non accedental , justify your answar



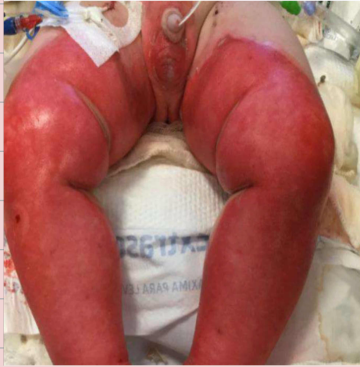Non accedntal , multipel ciggrate burn injury from singel cause

A



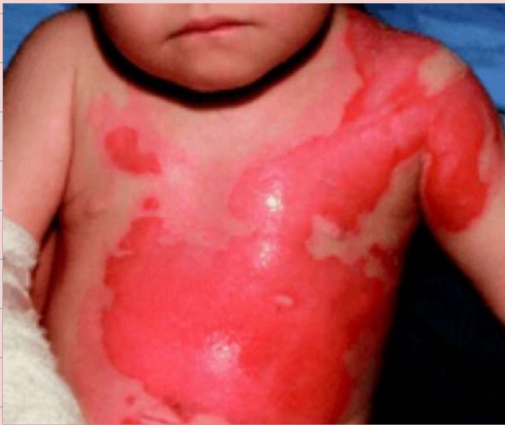Non accidental , avulsion of frenulum due to direct blow to child's mouth

B



Non accidental , no splash mark sharply demarcated burn margin

C



ملاحظة : ما اجت هاي الصورة حر في بيت قريبة منها و بنفس المبدأ

Accidental, splash mark , atypical margin

D

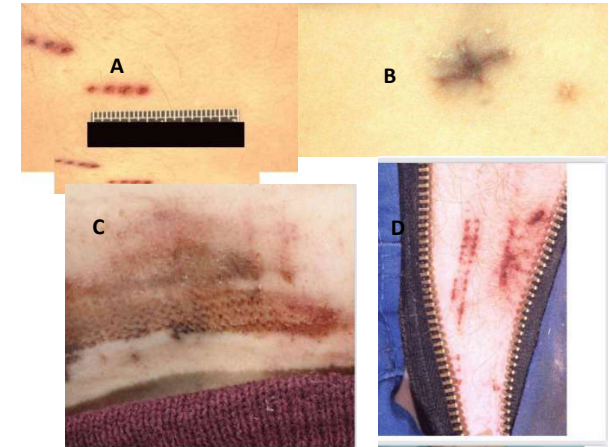
The second question

Case study about patient come to hospital with paracetamol toxicity after three hour

Write: Most effective method of decontamination
Signs and symptoms
Antidote used and route of administration

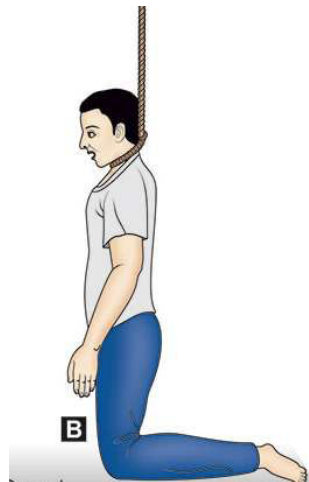
Forensic

- a) All blunt
- b) All blunt except d
- c) **All patterned**
- d) All patterned except a



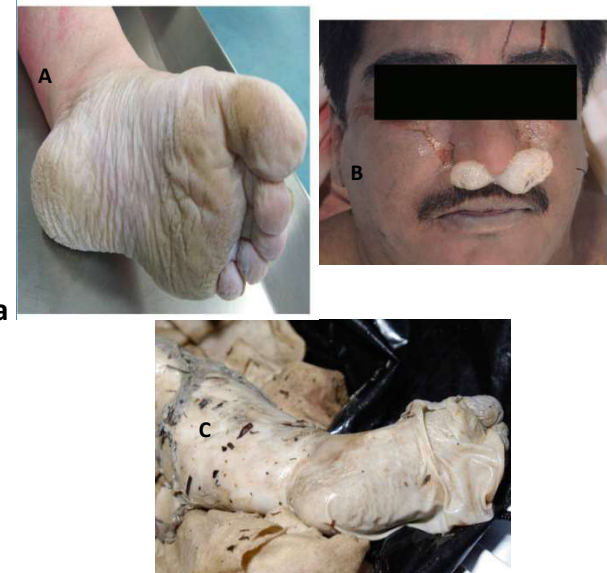صورة تقريبية بس ما كانوا
كل رجليه عالارض كانوا يا
دوب الاصابع

Typical incomplete hanging

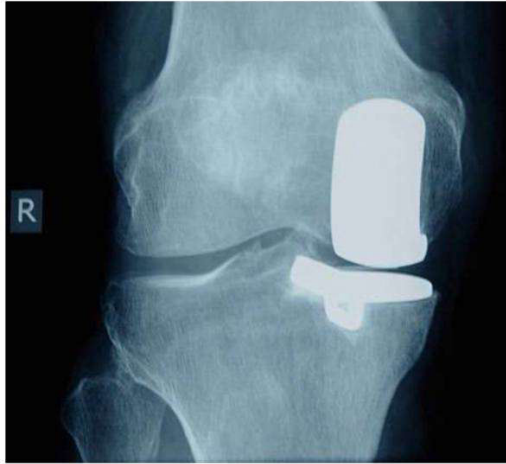

All these pic represent to:
السؤال عليه خلاف باعتبار انه
A not sure sign

- a) **All Sure signs of drowning**
- b) Sure signs of drowning except a



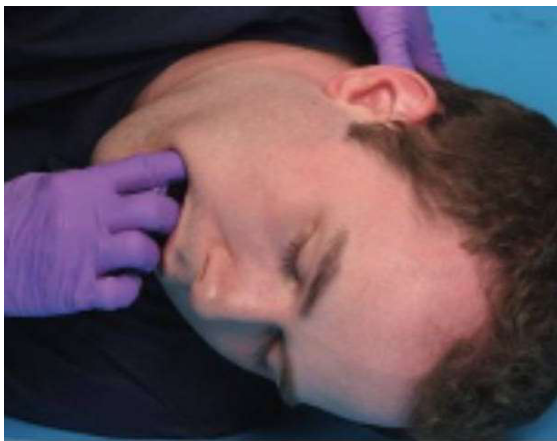- a) **Medical record**
- b) Visual ID
- c) Social status
- d) dental ID
- e) Congenital anomalies



- Patent prints**
- Latent prints
- Plastic prints

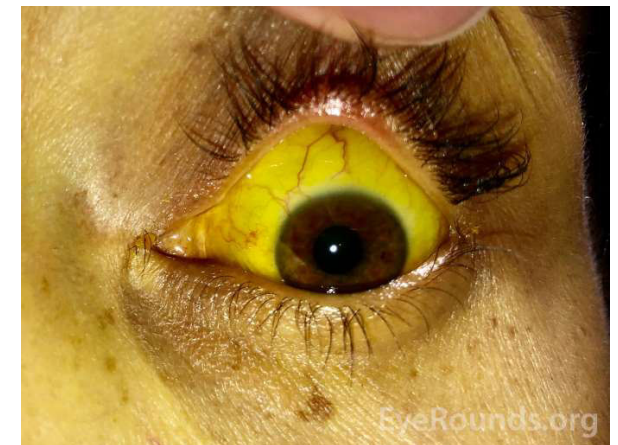

**We do this to
open airway**



- a) **Need LFT + NAC**
- b) LFT is enough
- c) NAC is enough

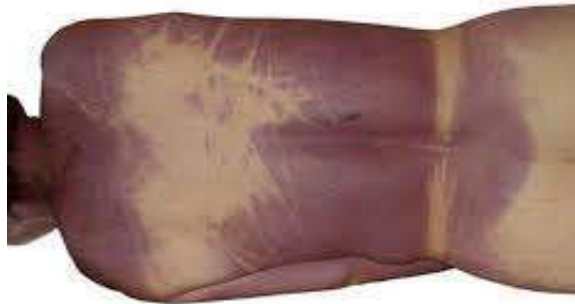الدكتور مرة حكي انه
NAC
شو ما تأخرنا ممكن انه نعطييه



EyeRounds.org

**He died when
he was on back**

Supine position



Pt came to ER with snake bite with **no local or systemic manifestation** what you will do:

- **Nothing**
- 3-5 vials
- 5-10 vials
- 10-150vials

Fetal causes which indicate abortion consider as:

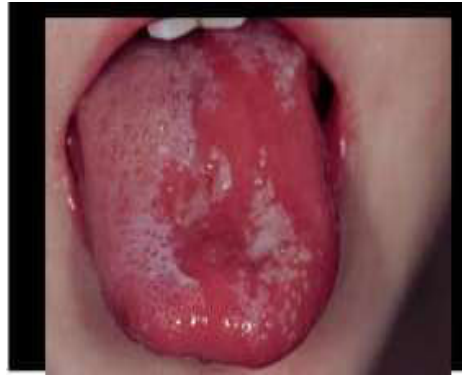- **Spontaneous abortion**
- Induced abortion
- Therapeutic abortion
- Criminal abortion

Percent of alcohol in Jordan

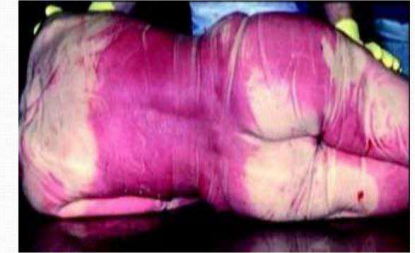- **0.08%**
- 0.05%
- 0.02%
- 0.01%

What you can do:

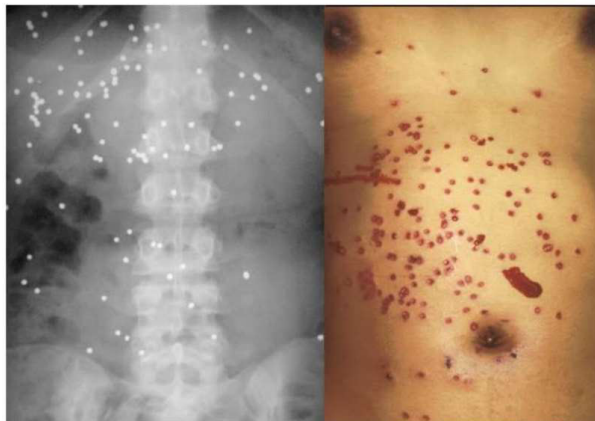- a) Analgesia
- b) Emesis
- c) Gastric lavage
- d) AC



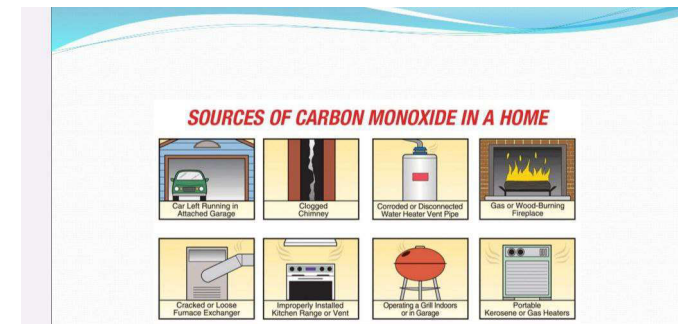
Hypostasis due to death at cold or cyanide toxicity



- a) Smooth weapon , more than 4m
- b) Smooth weapon , Less than 4m



First line of treatment
100%o2

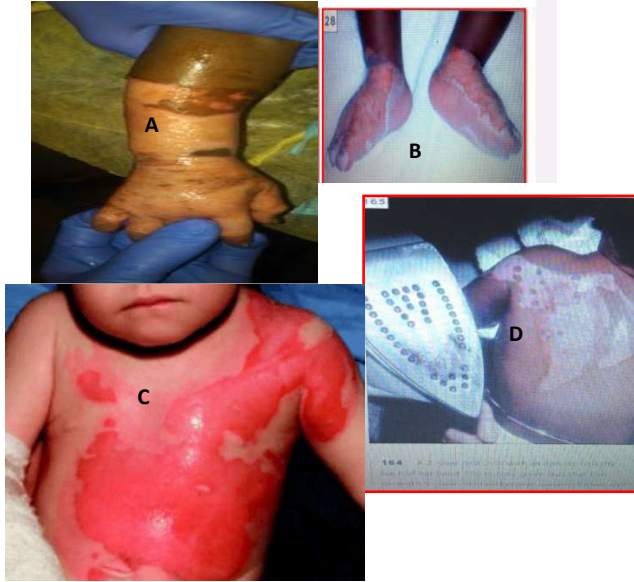


All of them are related to child abuse except:

- A
- B
- C
- D

مش بالزبط كانت الصور هاي كلها بس الاجابة كانت قريبة من الصورة

C

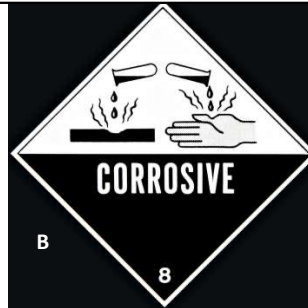


SHAKEN BABY SYNDROME

- a) characterized by retinal, subdural just
- b) characterized by retinal, subdural ± subarachnoid hemorrhages
- c) characterized by retinal, subdural ± subarachnoid hemorrhages and fracture

كانت الصور اوضح

- a) Emesis is contraindicated in all cases except D : organophosphorus
- b) Emesis is contraindicated in all cases
- c) Emesis is contraindicated in all cases except A
- d) Emesis is contraindicated in all cases except B
- e) Emesis is contraindicated in all cases except C

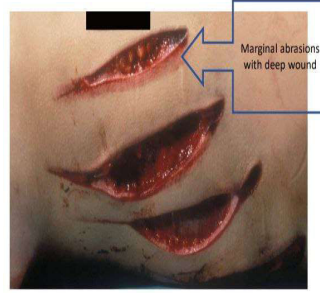


- a) Active ,Rifled weapons
- b) empty Rifled weapons
- c) Active ,non Rifled weapons
- d) empty non Rifled weapons



كان في زي هذا الجرح بالوجة

Cut
laceration



Case: Flush , non
reactive dilated pupil :

- a) Organophosphorus
- b) alcohol
- c) atropine

One is false
:MISMATCHING

**COBRA: central
respiratory failure**

كانه هيك كان الخيار بس
باقي الخيارات الصحيحة
كانت واضحة ف بالاستثناء
ممکن

اسئلة الكتابي

1-Injury report: Multiple bruising at the left side chest above nipple

2-Identification: boy age more than 18 less than 20 based on the distal part of metacarpal and distal end of radius and ulna

جانب صورة كان بدها تدقيق وكان في فرعين
*كم العمر المتوقع مع التبرير
*في اي محكمه سيحاكم المتهم

Case presented with clinical pic of OP :
Toxicology: organophosphorus
poisonous

ما كان معطينا نوع السم بس معطينا الاعراض

1. Toxidrom ans: organophosphorus poisonous
2. decontamination
3. antidote

death certificate
DM & obesity presented with
chest pain
MI and death

FORENCIC


GROUP B

1

سؤال من محاضرة ال firearms
Which of the following is correct ?

1. A can be used with this type of this weapon ✓
2. B can be used with this type of this weapon

pistol with rifels



A

B



ما كان هيك حرفي بس هيك فكرته

2

What signs of this drug after 36 hours?

- a. Anorexia , nausea , vomiting , malaise
- b. Fulminant hepatic failure
- c. Kidney failure ?
- d. ECG changes
- e. Free of symptoms

احترت فيه و ما عرفت الصح



3

Which of the following false about organophosphorus and carbamate ?

- a. Both treated with oximes ✓
- b. Both treated with atropine
- c. Can't give atropine as antidote for both

4

which can't be determined in ID from this x ray :

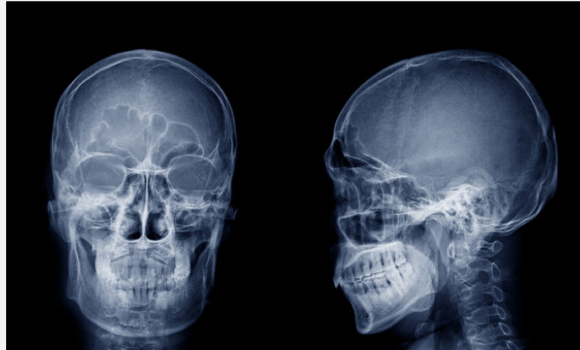Ear print

Frontal sinus.

Sella tursica.

Skull suture pattern

vascular grooves.



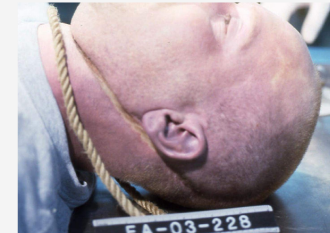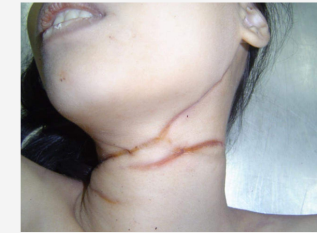5

Which of the following is true ?

1. A is atypical hanging and b is typical hanging
2. B is atypical hanging and A is typical hanging
3. Both typical

A

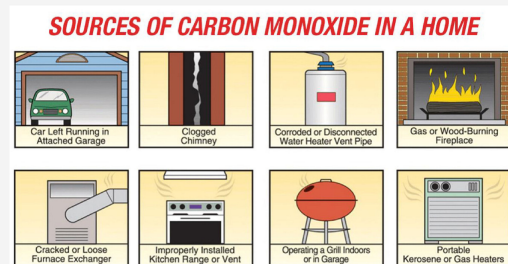
B



6

About poisoning from these sources what is true ?

treated by hyperbaric O2



7

Disulfiram used for ?

- a. acute alcoholic
- b. Chronic alcoholism
- c. Alcohol dependence

??

8

Castor oil?
Prostaglandin
Poison
Ecboic
Drastic purgative ✓
Contraceptive

9

Alcometer used to measure ?
a. ethanol in breath
b. ethanol metabolites in breath
c. Methanol in breath
b. Methyl metabolites in breath
e. Ethanol in saliva



10

Which is true?

1. Bucket handle fracture happens only in non-accidental injury
2. Bucket handle fracture happens only in accidental injury
3. Bucket handle fracture happens in both accidental & non-accidental injury

11

Molecular death?

- a. Period of time between clinical death and brainstem death
- b. Period of time between molecular death and brainstem death ?
- c. Period of time between intrauterine life until death

12

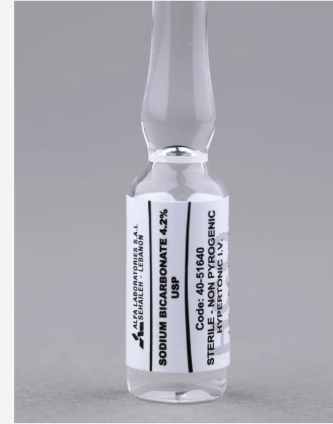Which Of the following true ?

a. Most common in Jordan is viper ✓

13

This used for ?

- a. Salicylate , anti-depressant , barbiturates
- b. Acidification
- c. Alkalines
- d. Forced diuretics



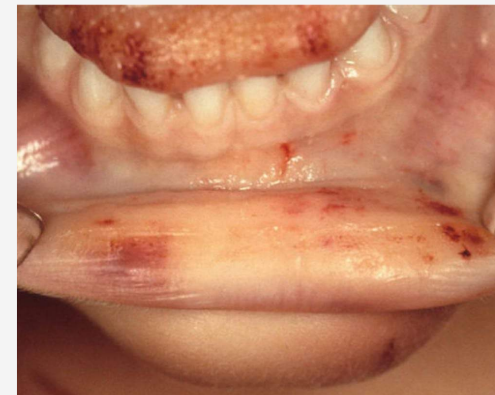14

Child drink corrosive **و كان حاط صورته** . Which of the following is true as investigation early at first 6 hours ..

- a. Endoscopy
- b. emesis is contraindicated due to duration
- c. emesis is contraindicated due to perforation
- d. Gastric lavage contraindicated due to perforation
- e. Gastric lavage contraindicated due to aspiration

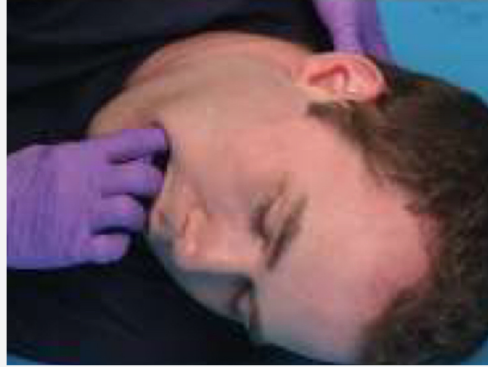15

Smothering



16

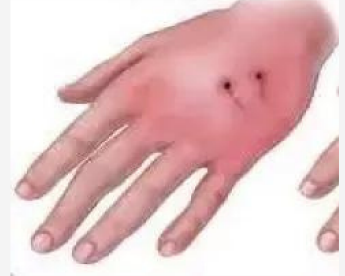Finger sweep



17

For this case:

- A. Antivenom indication
- B. No investigations needed
- C. Antivenom for systemic manifestations
- D. Antivenom for systemic and local manifestations



مثش نفس الصورة بتشبهها بس بالرجل كانت

الأسئلة الكتابية

1-name of sign & if the position fixed what is the time interval ?

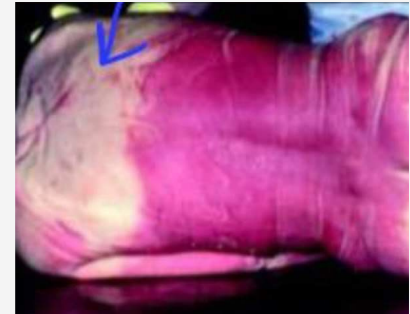hypostasis , 2-8 hours ?

2-name of toxic that cause it :

1-co poisoning

2-cyanide poisoning

3-hypothermia



كيس وكان معه tachycardia وانه كان برش حوالين الدار اشبي زي هيك
كان طالب ال toxidrome؟؟
واشرح سبب ال tachy؟؟
وشو ال antidote الي بزبط على
?? nicotinic receptor

a. Cholinergic toxidrome

b. preganglionic sympathetic انه يشغل على ال

c. Oximes

Death certificate

patient with prostatic cancer , has liver cancer which
enlarge and make pressure
on hepatic veins the esophageal veins , with high pressure
it perforate and bleeding , the patient dead...

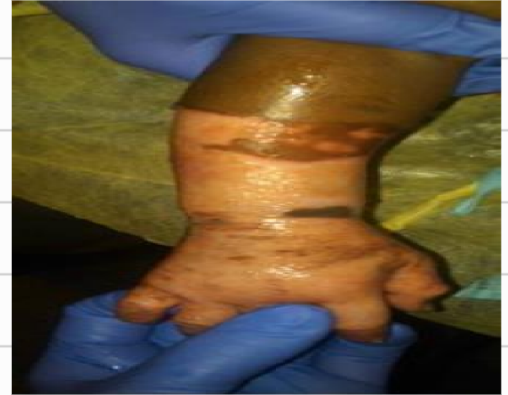Wound report

الصورة كانت لشخص كل وجهه كدمات و نكتب report 🙄



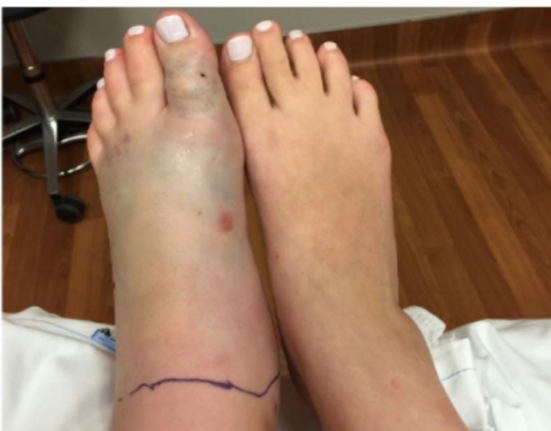1. Picture about a burned child

The answer is intentional scald burn

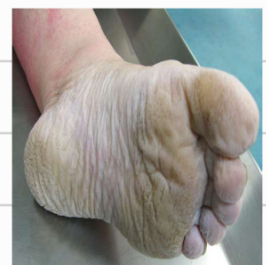

2.a picture about viper snake bite

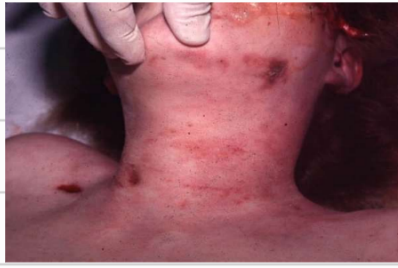وكان بده الخطأ كلهم كانوا تقريبا صح بس العضه ما كانت منتشره كثير لهيك
حطيناها coagulation profile is mandatory



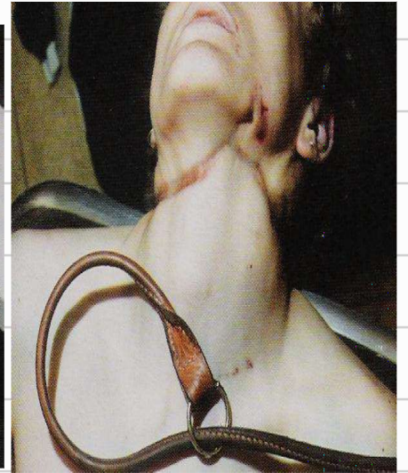
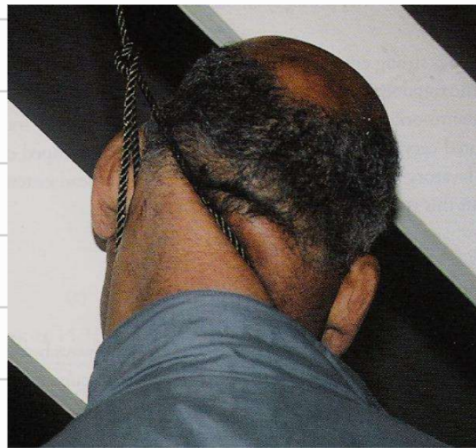3.pictures about signs of immersion



4. Throttling



5. fixed knot, running noose



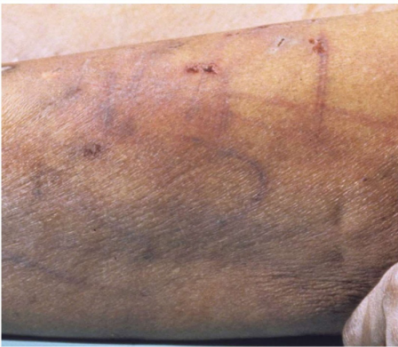6. methanol overdos اعراض

7. جاب سؤال عن وحده دخلت er وكان عندها اعراض زي ال
vomiting, gagging, coughing, tachypnia
شو الماده اللي شربتها (kerosene)

8. جاب عن هاد الجدول تاع ال abortion

Traumatic rupture of uterus (in criminal abortion)	Rupture of uterus due to obstructed labour	Pathologic rupture of uterus
-The site of rupture is usually in the <u>fundus</u> .	-The site of rupture is in the <u>lower segment</u> .	-The site of rupture is <u>anywhere</u> .
-It is <u>longitudinal</u> and taking the shape of <u>instrument</u> .	-It is <u>transverse</u>	-There are degenerative changes in <u>uterine muscles</u> .

9.

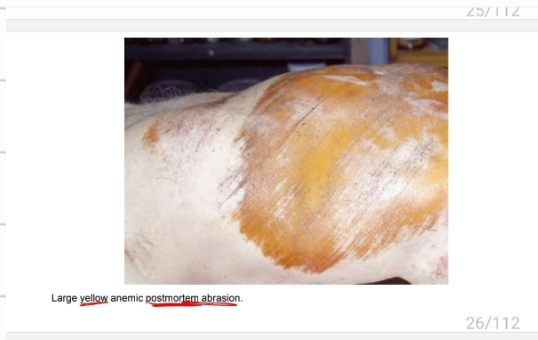

Numerous patterned injuries produced by an electrical cord "loop" that was used as a "whip." Notice that some of the marks have a "tram-track" appearance

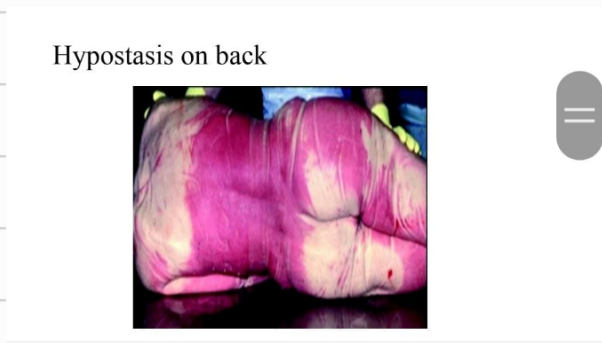10. كان بحكي شو الاشئ الصح بالخيارات التالیه
الجواب:

Priapism is sustained erection of the penis after a scorpion sting

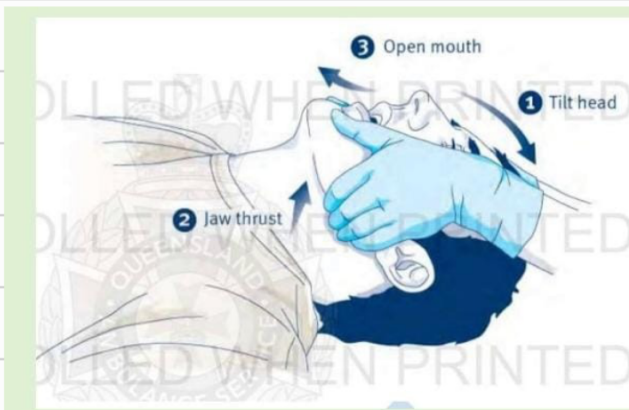
11.



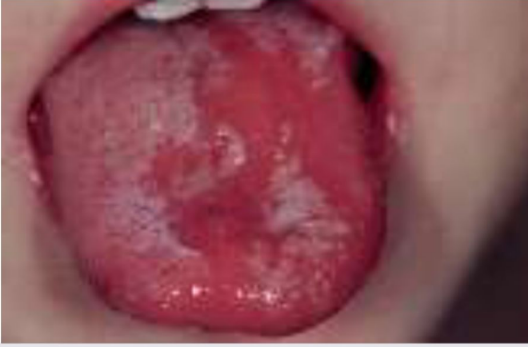12. the causes of this picture
(Co, CN, cold exposure)



13. To open the airway



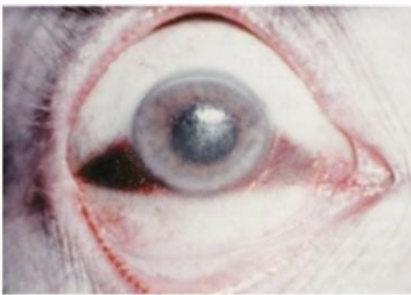14. طفل صغير اجا بعد تقريبا 4 ايام وكان يعاني من الم حاد بعد شربه ماده
حارقه شو بعمله
بس بعطيه steroids



15. Closed disaster

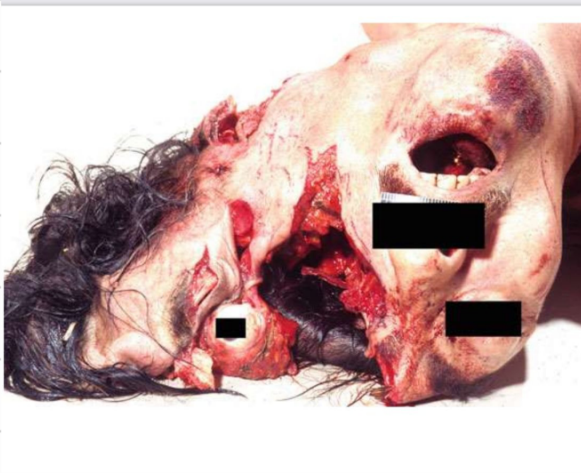

16. tache noir

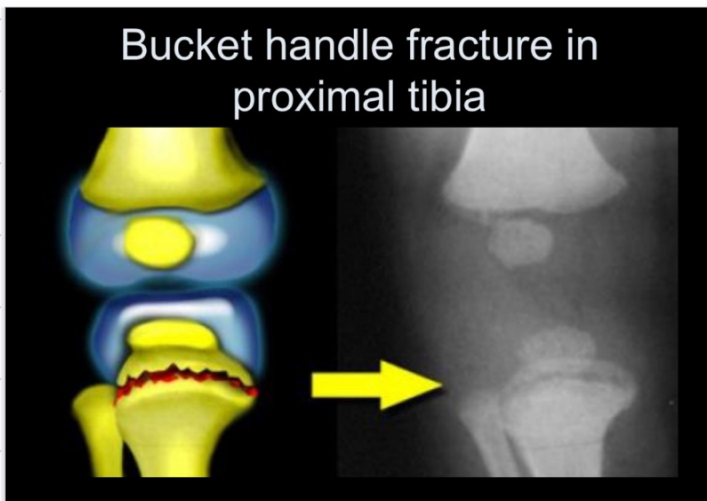


17. ان السؤال انه شو الاشي اللي مارح ويكون واضح ب identification

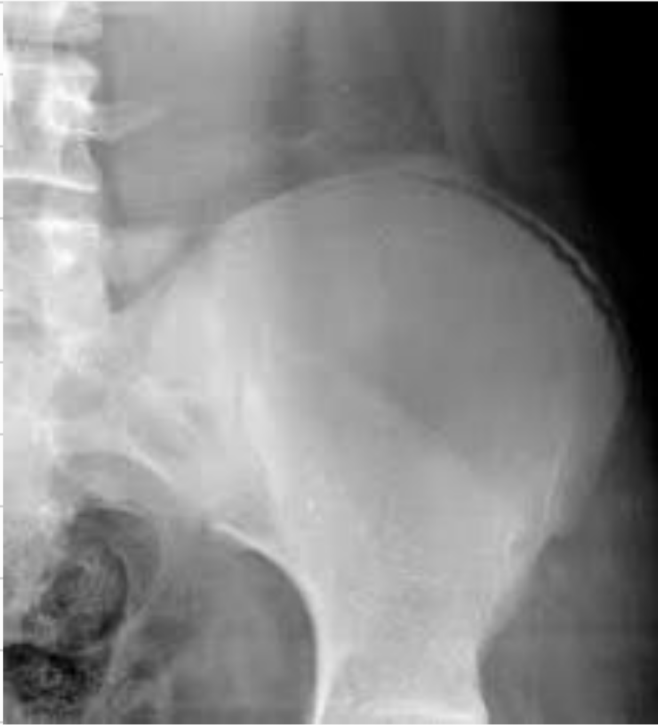(Visual identification)



18.



19. Below 23y.o



20. كان جايب اكثر من صوره ومن ضمنهم هاي الصوره وحكا شو اللي ممكن اعمله **emesis** ، كلهم ما بقدر اعمالهم (كان، وكلور، اداه حادة)
الا **organophosphorus**



22. جاب شو اللي ممكن يعمل **pin-pointed pupils**

1. Pin-pointed: with **opiates**, **OPI**, **phenothiazines** and pontine lesions.
2. Reactive dilated: with **sympathomimetics** (**amphetamine**, **cocaine**).
3. Non reactive dilated: occurs with **anticholinergics**.

Paralytic (non reactive) Dilution

Al-mphe
قنانه الحبوب



5. Respiratory system:

23. جاب سؤال شو الغلط بالخيارات وكان الخطأ انه

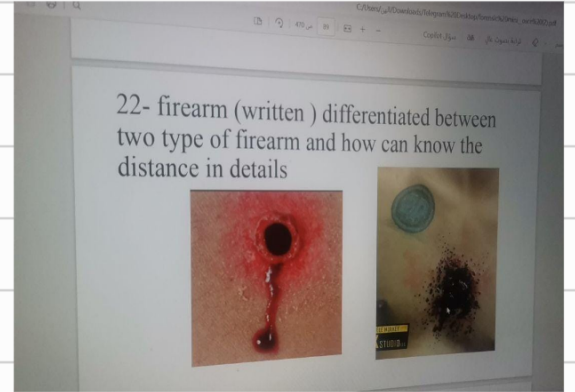
We use oximes with carbamate

written Questions

سؤال عن firearm صورتين كالتالي والأسئلة عليهم

1. فرق بينهم واكتب خصائص الصورتين

2. المسافة المحتملة عند كل صورة



Range of firing of non-rifled weapons:

1. Less than 2 meters :

- Single circular entrance wound
- Associates
- Pink coloration of wound due to CO
- Wads or plastic cups in the wound

2. 2-4 meters :

- Central hole surrounded by dispersion .

3. more than 4 meters :

- Only individual pellet holes are seen (full dispersion)
- Central hole absent

سؤال عن wond report وكان عبارته عن cut wond بالوجه

سؤال toxicology عن ال paracetamol

و الاسئلة كالاتي : شو اهم سؤال ممكن اسئله للمريضه؟ اكيد وقت اخذ الدواء

شو اهم فحصين بعملهم؟ IFT, KFT

antidotes and type of administration واكتب ال

death certificate سؤال عن

Mini osce forensic wateen 2024

Group 3

Written questions

• Arabic questions

سؤال عن كتابه تقرير لجرح رضي متهتك فوق العين منطقة الحاجب و مع نزيف في الجفن العلوي للعين اليمنى

تقرير الوفاة

• Patient complained of epigastric pain, had peritonitis then developed septicemia and died.

سبب الوفاه هبوط حاد في الدورة الدمويه ناتج عن تسمم الدم البكتيري الناتج عن التهاب الغشاء البريتوني

• English questions

□ About paracetamol toxicity,


1- gastric decontamination methods from most effective to least


2- the name of the nomogram used to assess the treatment


3- what are the patient symptoms the next day


Written question about child abuse

Identification the type of injury into accedental and non accedental ,justify your answer

A  Non accedntal , multipel ciggrate burn injury from singel cause

B  Non accedntal , avulsion of frenulum due to direct blow to childs mouth

C  Non accedntal , no splash mark sharply demarcated burn margin

D  ملاحظة : ما احدثها الصورة حرق بع قربة منعا وبقت اطريا
Accedental, splash mark , atypical margin



سؤال عن الجهاز كان عدة خيارات والجواب كان 100% oxygen with pressure three times the atmospheric pressure

Q8. One of the following is true about picture :

- A. Patent print
- B. Latent print
- C. 3d print
- D. Plastic print

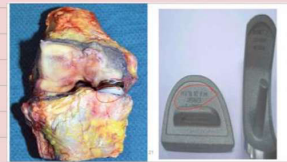
Answer : B



Q9. The method of identification used in this picture :

- A. Dental identification
- B. age estimation
- C. X ray
- D. Medical record

Answer : D



Q14. This picture show "cadaveric sign" the estimated time of death :

- A. More than 8 hour
- B. Less than 6 hour
- C. More than 36 hour
- D. Less than 3 hour early

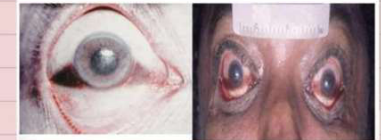Answer: D



Q15. Chose the correct answer :

Early change on eyes postmortem

Tache noire: where the sclera remains exposed to air, two black triangular spots appear at each side of the cornea (due to drying).



MCQs

- Animal poisoning

سؤال كان عدة معلومات عامه عن الافاعي اللي فالاردن و كانت الاجابة أغلب الافاعي في الاردن غير سامة

- distance of firearm

m كان الجواب الصح 2-4

- diminished visual acuity & blindness معها anti-freaz شربت

الجواب Methanol

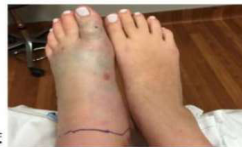- Abortion

سؤال في اول 3 شهور ايش ممكن يكون دواعي الاجهاض

الجواب ممكن يكون Therapeutic or spontaneous or criminal

- في صورتين و مين فيهم

Rifled and non rifled



- naloxon كان في سؤال عن ال

- Light reflex في سؤال جابوا صورة للعين و كانت متوسعة و بالسؤال حاكيين لو حطينا ضوءا و لقينا

فأي الأدوية بتسوي هيك و من الخيارات

Amphetamine and atropine

Cocaine amphetamine atropine

الجواب كان Cocaine amphetamine

- Alcohol

سؤال عن اسم الجهاز الي بقيس النسبة عن طريق التنفس

الخيارات كانت انها بتقيس

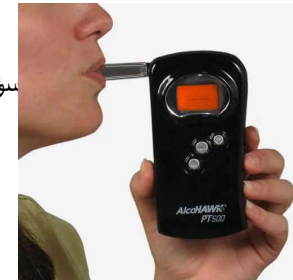
Ethanol through saliva

Ethanol through breath

Ethanol metabolite through breath

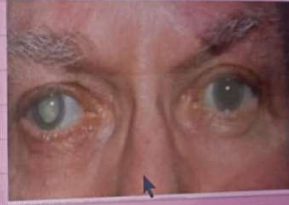Methanol through breath

Methanol through saliva



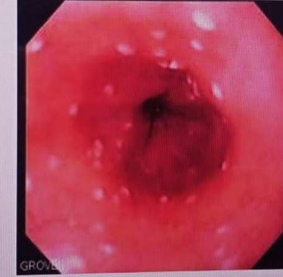Q13. This effect mostly due to :

- A. Simple blunt object
- B. Simple sharp object
- C. Dangerous blunt object
- D. fatal blunt object



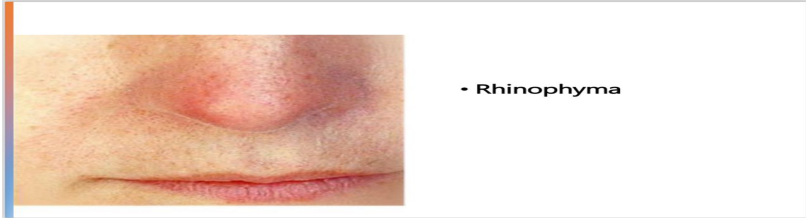
Answer : C

Hot endoscopy in 1st 24 hr, can be done to assess the severity of esophago-gastric injury. It's contraindicated if respiratory distress is present.



كان السؤال بسأل عن اسم الطريفة و كم المدة

أرشيف المجموعة الأخيرة وتين ٢٠٢٤

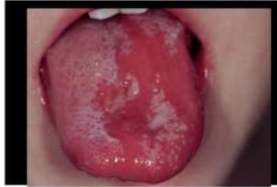

• Rhinophyma

English questions

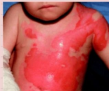The first question

Identification the type of injury into acedental and non acedental ,justify your answer



Non acedntal , no splash mark sharply demarcated burn margin

C



Accedental, splash mark , atypical margin

D

Q5. Which of the following about this device true:

- A. Used in paient with co2 toxicity
- B. Used when level of oxygen below 10%
- C. Used 100% oxygen at normal atmospherie pressur
- D. 100% oxygen indicated in pregnancy ,coma and myocardial ischemia

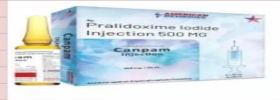

Answer : D

..... which of the follwing drug not indicated

Answer : E

our
nate
ur
hour



Answer : A

Q8: this method of identification called:

- A) dental print**
- b) facial reconstruction**

Answer: B

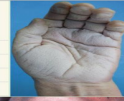

One of the following prescribe the Picture:

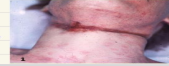- a) A is drowning B is throttling**
- b) A is drowning a B is strangulation**
- c) A is unknown B is strangulation**

Answer: C

A:



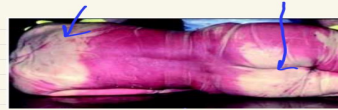B:



Q12: the arrows indicate:

- A) area of vasodilation**
- b) Hypostasis**
- c) flattened area with contact**
- d) Area of vasoconstriction**

Answer: C



#we can identify it by :

- dental
- medical
- visual
- frontal sinuses

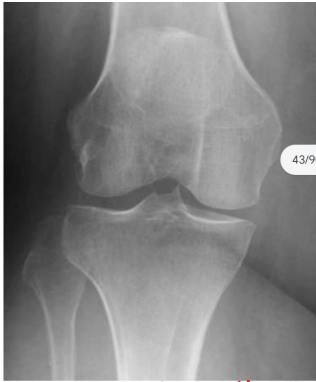- all true
- all false
- all true except 3
- all true except 1
- all false except 1



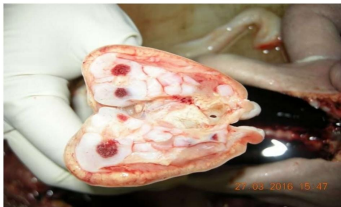knee joint fused

a 15 year old female got raped by an assailant. انه هاي ركبته
he's below 18 no execution

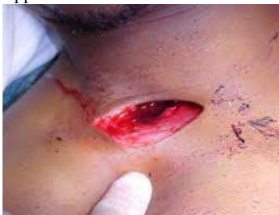he's below 16 no execution
he's above 21 with execution
he's above 19 with execution



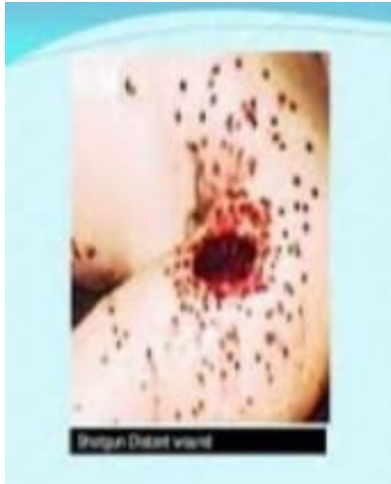#ossific centers can be seen in autopsy and radio



#according to air embolism:
-this injury cannot cause venous embolism
-The minimum amount
of air to cause air
embolism is 60 ml.
-can't happen at this site




#بتشبهه هاي
Distance of firing ?
2-4m



#Abortifacient pills: mifepristone+misoprostol
پيلس مش drugs باقي الخيارات كانت

cadavric contraction
cadavric spasm
rigor mortis



#cold cadaver time?
8-24h

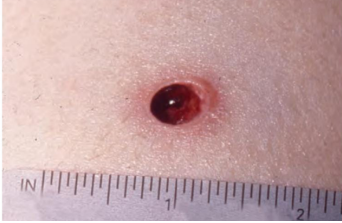#farmer spilled insecticide on ungloved hand after 3 hours came to the hospital

symptoms وكان عنده كثير

(الجواب من د ميلاد) wash his hand

oxime before atropine

#هاي شو سببها من ضمن الصور هاي الطلقه و سكينه و حديدته غير مديبه



#patterned

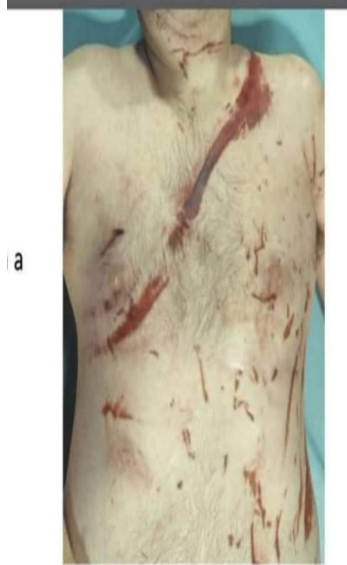
new injury

blunt

a.m

الجواب

all true



من

صور وشو سبب كل وحده

throttling, hanging, choking, unknown (peeling كانت صوره)

sure sign peel مش غلط بتكون لانه ال drowning كان في خيارات فيها

اجت الصورة هاي وكان بده بعد اربع ايام شو بعمل والجواب#

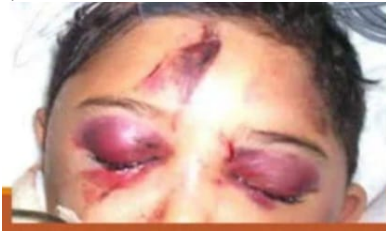antibiotic

الاسئلة الكتابية

1)death certificate

a 56 year old female was complaining from abdominal pain she was diagnosed with peritonitis,after admission she had septicaemia and died

2) wound



3)toxicology case

female took paracetamol overdose 3 hours prior coming to hospital +had multiple episodes of emsis in

30 min

what is the effective way of decontamination?
after 24 hours what symptoms will she develop?
when is the best time to give her the antidote?



الطبيب والجراحة
للجراحة