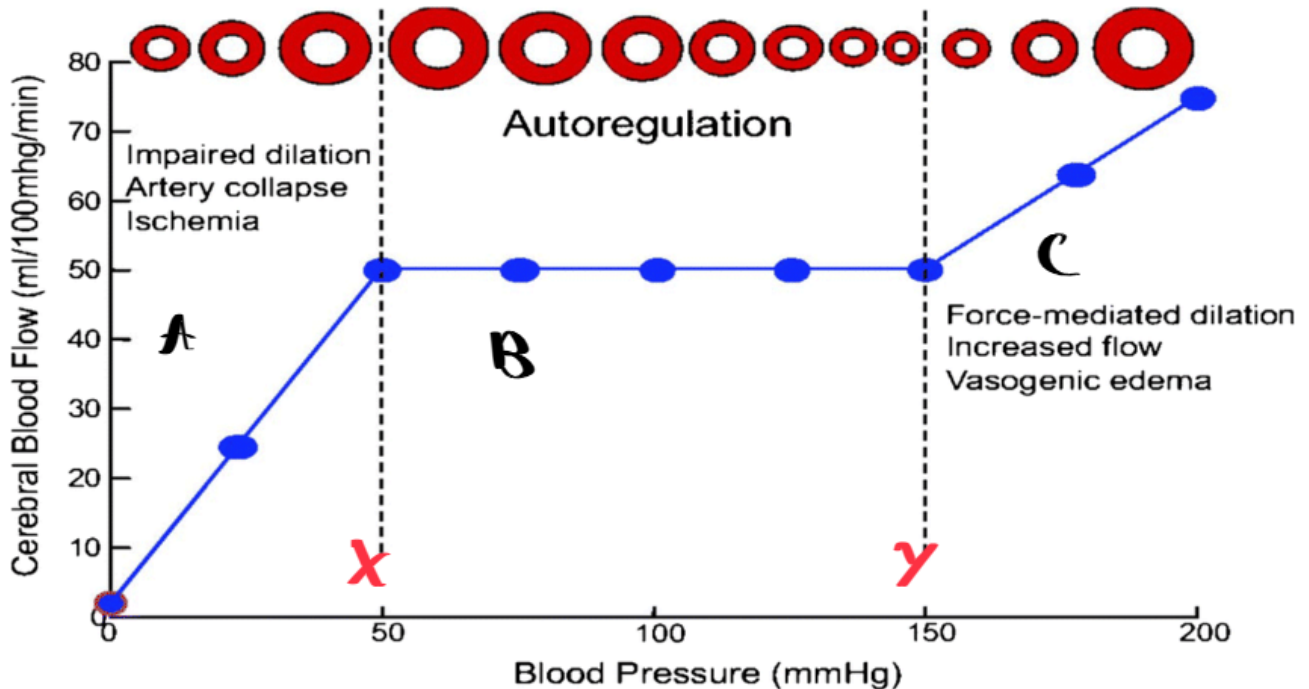


Neurosurgery wateen group 2 :

Done by Tala , Hala



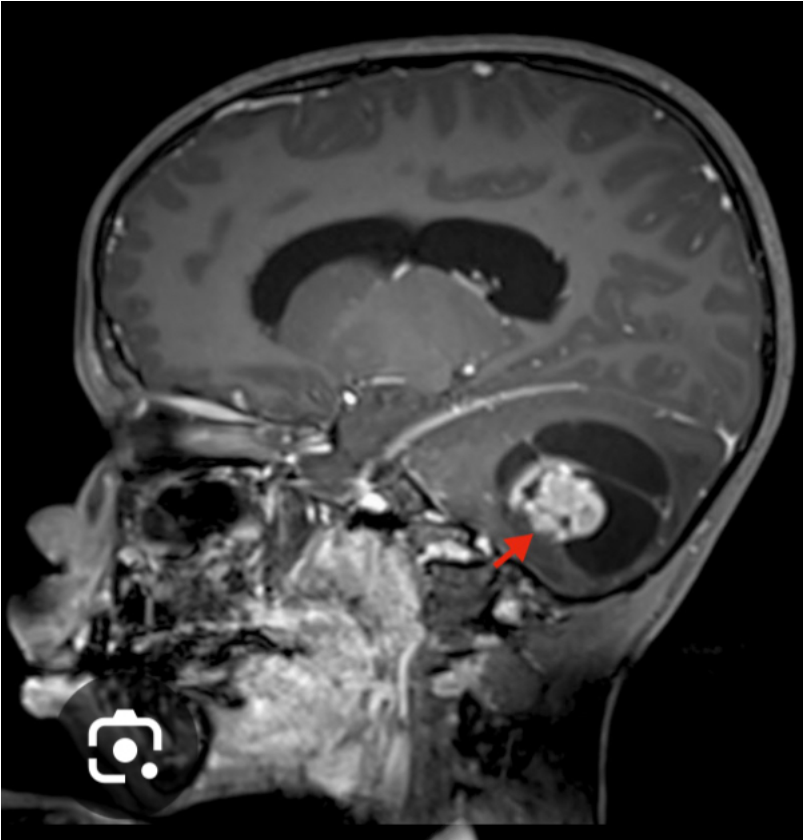1. According to cerebral blood flow - pressure curve :

A) what is the type of edema in zone C : **vasogenic**

B) what is the range of MAP in case of head trauma in X and Y : **x=50 , y=70**

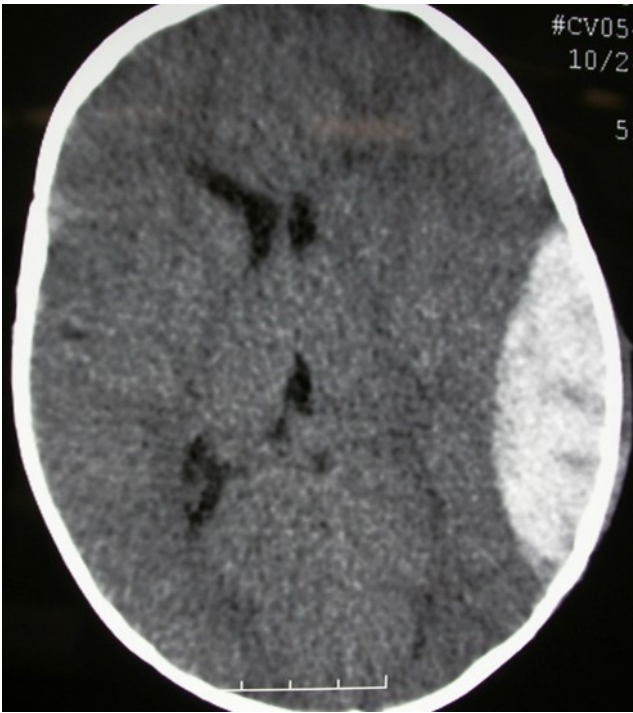
C) what is the mechanism to maintain zone B : **vasodilation and vasoconstriction**

D) what does zone A represent: **ischemia**



2. a case of child with astrocytoma :

- A) what is the most common site of astrocytoma : **cerebellum**
- B) what is the Histo pathological finding: **Rosenthal fibres**
- C) what is the MRI FINDING : **solid and cystic component (mural nodule)**
- D) what is the management : **surgery**



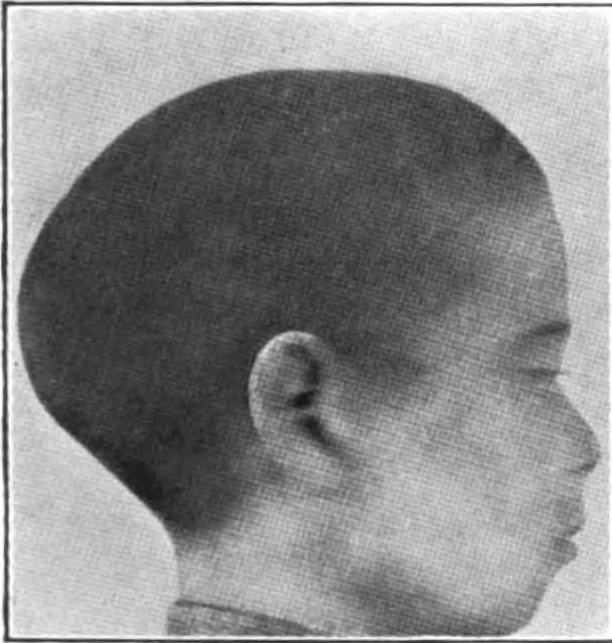
3. a case of epidural hematoma :

A) what is the shape: **lens shaped**

B) what is the affected vessel: **middle meningeal artery**

C) what's the management: **craniotomy and evacuation**

D) when to use intubation for epidural hematoma : **عليه اختلاف**



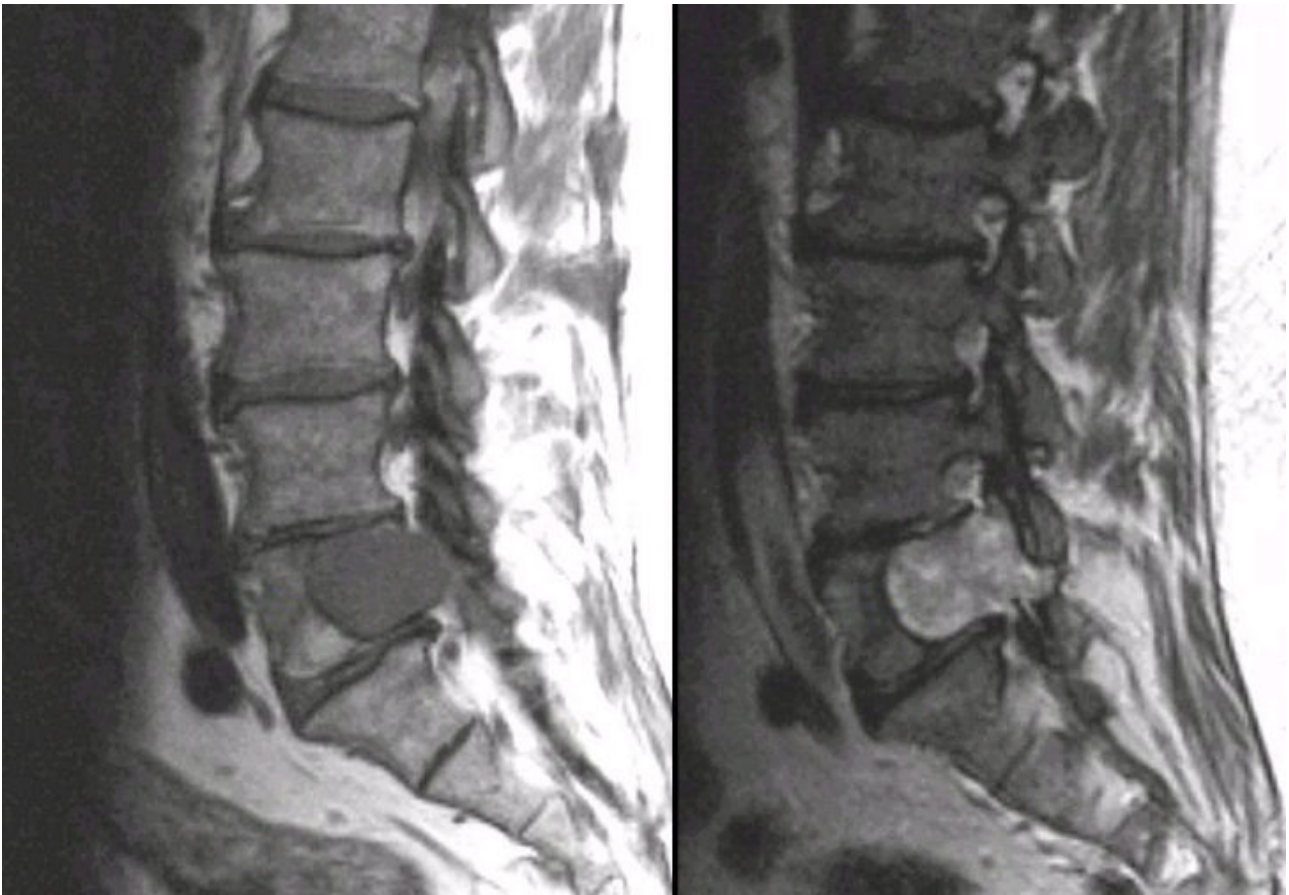
4. case about brain congenital anomaly:

A) what the name of the anomaly : **scaphocephaly**

B) which CSO most associated with multiple congenital anomaly:
brachycephaly

C) about the management of CSO all true except: **the cut is less than 1 Cm**

D) what is the preferred age for surgery: **6 month**



5. patient low back pain and move his foot from side to side in supine position:

A) according to MRI the diagnosis is : **met**s

B) muscle strength scale for the patient: **2**

C) level of the spinal vertebrae lesion : **T6 or T 10** عليها ختلاف

D) all of the following are part of the management except : **lower limb X-ray**