

Assisted Vaginal Delivery

Topic- based Uworld Questions

Block 1, 2, 7, 8



A 28-year-old primigravida was admitted to the hospital in active labor. On admission, her cervix was 7 cm dilated and 100% effaced. She received epidural anesthesia and proceeded to complete cervical dilation with the fetal head at +3 station within a few hours. The patient has been pushing for 4 hours and is exhausted. She cannot feel her contractions and does not know when to push because of her epidural anesthesia. The patient has had no complications during the pregnancy and has no chronic medical conditions. The estimated fetal weight by Leopold maneuvers is 3.4 kg (7.5 lb). Vital signs are normal. Fetal heart rate tracing is category 1. Tocodynamometer indicates contractions every 2-3 minutes. A repeat cervical examination shows complete cervical dilation with the fetal head at +3 station and in the left occiput anterior position with no molding or caput. Which of the following is the best next step in management of this patient?

- A. Apply uterine fundal pressure
- B. Decrease epidural infusion rate
- C. Perform vacuum-assisted vaginal delivery
- D. Recommend internal podalic version
- E. Rotate fetal head to occiput posterior position

Submit

A 28-year-old primigravida was admitted to the hospital in active labor. On admission, her cervix was 7 cm dilated and 100% effaced. She received epidural anesthesia and proceeded to complete cervical dilation with the fetal head at +3 station within a few hours. The patient has been pushing for 4 hours and is exhausted. She cannot feel her contractions and does not know when to push because of her epidural anesthesia. The patient has had no complications during the pregnancy and has no chronic medical conditions. The estimated fetal weight by Leopold maneuvers is 3.4 kg (7.5 lb). Vital signs are normal. Fetal heart rate tracing is category 1. Tocodynamometer indicates contractions every 2-3 minutes. A repeat cervical examination shows complete cervical dilation with the fetal head at +3 station and in the left occiput anterior position with no molding or caput. Which of the following is the best next step in management of this patient?

- A. Apply uterine fundal pressure (17%)
- B. Decrease epidural infusion rate (16%)
- C. Perform vacuum-assisted vaginal delivery (55%)
- D. Recommend internal podalic version (1%)
- E. Rotate fetal head to occiput posterior position (8%)

Omitted

Correct answer

C



55%

Answered correctly



01 sec

Time Spent



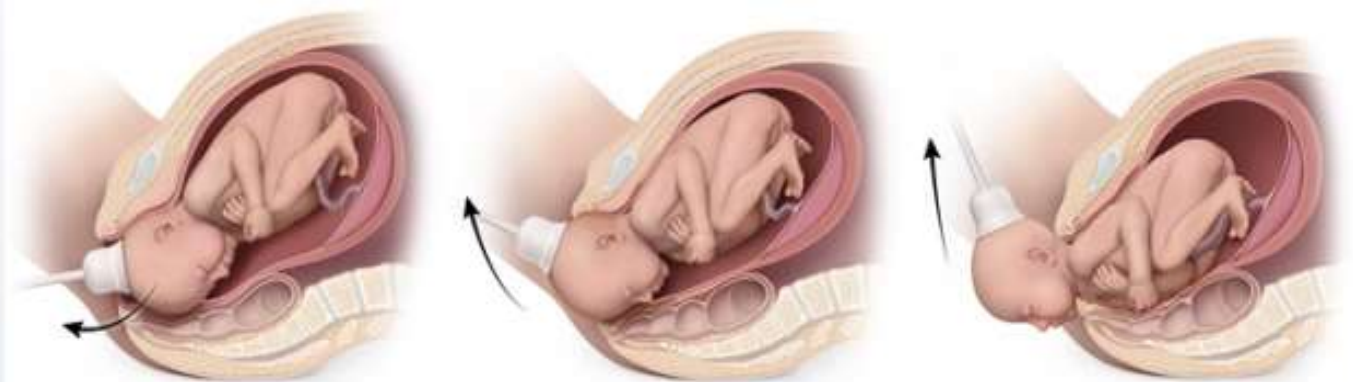03/28/2020

Last Updated

Explanation

Vacuum-assisted vaginal delivery

Vacuum-assisted vaginal delivery



©UWorld

The **second stage of labor** is the period from complete cervical dilation (**10 cm**) to **fetal delivery**. This patient achieved excellent fetal descent to +3 due to her average-sized infant (eg, 3.4 kg), suitable pelvis (no fetal molding or caput, suggesting no resistance against the bony maternal pelvis), and favorable fetal position (left occiput anterior). However, she meets criteria for **second-stage arrest** (ie, no further fetal descent), which are:

- ≥ 3 hours of pushing in a **primigravida** without an epidural; some providers allow additional time with an epidural (ie, **≥ 4 hours pushing** with an epidural, as in this patient)

OR

- ≥ 2 hours of pushing in a multigravida without an epidural (≥ 3 hours pushing with an epidural)

Continued pushing **increases delivery complications** (eg, postpartum hemorrhage) with limited chance of spontaneous vaginal delivery.

Therefore, the best next step in management is **operative vaginal delivery** (eg, vacuum-assisted) to expedite delivery. Other indications for operative vaginal delivery include **maternal exhaustion**, fetal distress, and maternal conditions in which the Valsalva maneuver is not recommended (eg, hypertrophic cardiomyopathy).

(Choice A) Fundal pressure is external pressure applied to the most cephalad portion of the uterus, with force directed toward the maternal

OR

- ≥ 2 hours of pushing in a multigravida without an epidural (≥ 3 hours pushing with an epidural)

Continued pushing **increases delivery complications** (eg, postpartum hemorrhage) with limited chance of spontaneous vaginal delivery.

Therefore, the best next step in management is **operative vaginal delivery** (eg, vacuum-assisted) to expedite delivery. Other indications for operative vaginal delivery include **maternal exhaustion**, fetal distress, and maternal conditions in which the Valsalva maneuver is not recommended (eg, hypertrophic cardiomyopathy).

(Choice A) Fundal pressure is external pressure applied to the most cephalad portion of the uterus, with force directed toward the maternal pelvis. This maneuver does not improve spontaneous vaginal delivery rates.

(Choice B) Epidurals can lengthen the second stage, but they do not cause arrest or affect spontaneous vaginal delivery rates. In addition, appropriate analgesia is a prerequisite for operative vaginal delivery.

(Choice D) Internal podalic version is manual rotation of an infant to a breech presentation for breech vaginal delivery. Internal podalic version of a singleton fetus is contraindicated because breech vaginal delivery has a high risk of neonatal mortality and morbidity.

(Choice E) The ideal fetal head position is occiput anterior (OA) because the flexed head presents a smaller diameter and facilitates the cardinal movements of labor. In contrast, the **occiput posterior (OP) position** presents a larger-diameter head in a deflexed position. Rotating the fetal head to OP decreases the chance for spontaneous vaginal delivery.

Educational objective:

Second stage arrest of labor is lack of fetal descent after ≥ 4 hours of pushing in a primigravida with an epidural (≥ 3 hours without) or ≥ 3 hours in a multigravida with an epidural (≥ 2 hours without). Second-stage arrest is managed with operative vaginal delivery (eg, vacuum-assisted). Other indications for operative vaginal delivery include maternal exhaustion, fetal distress, and maternal conditions in which the Valsalva maneuver is not recommended.

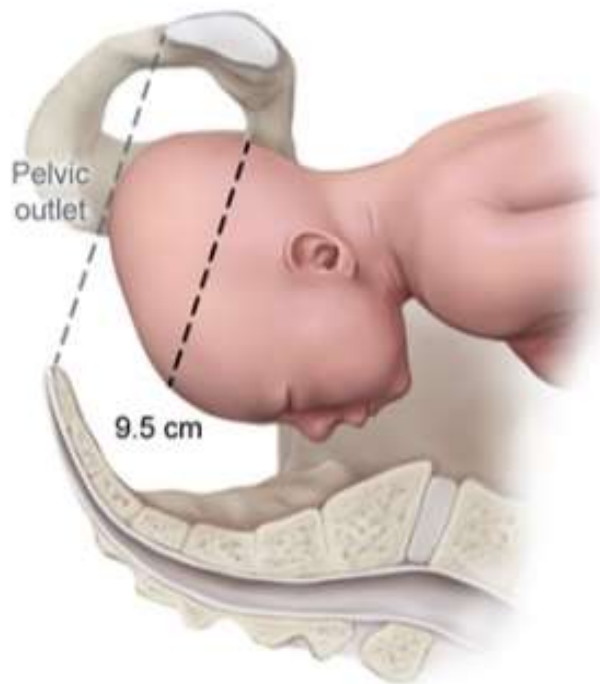References

- [Contemporary patterns of spontaneous labor with normal neonatal outcomes.](#)
- [Epidural versus non-epidural or no analgesia for pain management in labor.](#)

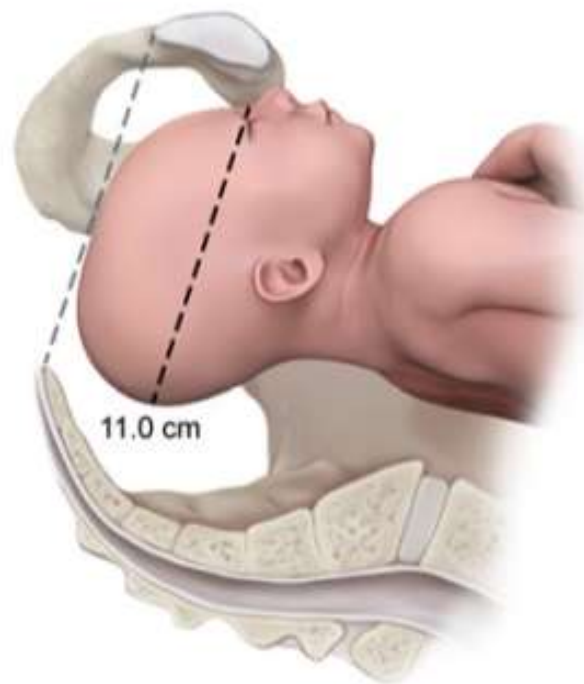
recommended (eg, hypertrophic cardiomyopathy).

Exhibit Display

Occiput anterior position



Occiput posterior position



©UWorld

Zoom In

Zoom Out

Reset

Add To New Card | Existing Card