

Pelvic Inflammatory Disease

Topic- based Uworld Questions

Block 1, 2, 7, 8



A 24-year-old woman comes to the office for evaluation of abnormal vaginal bleeding. The patient has a history of heavy, regular menstrual periods for which she had a progestin-releasing intrauterine device (IUD) placed 2 years ago. After IUD insertion, the patient became amenorrheic. However, for the last month, she has had light vaginal spotting with wiping. The patient also recently developed intermittent pelvic pain that has now become constant and unrelieved with ibuprofen. She has no chronic medical conditions and has had no prior surgeries. She has had 3 sexual partners in the last year and does not use tobacco, alcohol, or illicit drugs. Family history is unremarkable. Urine pregnancy test is negative. Which of the following is the most likely cause of this patient's symptoms?

- A. Adenomyosis
- B. Endocervical polyp
- C. Endometriosis
- D. Ovarian torsion
- E. Pelvic inflammatory disease
- F. Progestin-induced endometrial atrophy

Submit



A 24-year-old woman comes to the office for evaluation of abnormal vaginal bleeding. The patient has a history of heavy, regular menstrual periods for which she had a progestin-releasing intrauterine device (IUD) placed 2 years ago. After IUD insertion, the patient became amenorrheic. However, for the last month, she has had light vaginal spotting with wiping. The patient also recently developed intermittent pelvic pain that has now become constant and unrelieved with ibuprofen. She has no chronic medical conditions and has had no prior surgeries. She has had 3 sexual partners in the last year and does not use tobacco, alcohol, or illicit drugs. Family history is unremarkable. Urine pregnancy test is negative. Which of the following is the most likely cause of this patient's symptoms?

- A. Adenomyosis (6%)
- B. Endocervical polyp (12%)
- C. Endometriosis (13%)
- D. Ovarian torsion (1%)
- E. Pelvic inflammatory disease (49%)
- F. Progestin-induced endometrial atrophy (16%)

Omitted

Correct answer

E

49%
Answered correctly02 secs
Time Spent02/24/2020
Last Updated

Explanation

Pelvic inflammatory disease

Pelvic inflammatory disease	
Symptoms	<ul style="list-style-type: none"> • Lower abdominal pain • Abnormal bleeding
Risk factors	<ul style="list-style-type: none"> • Multiple sexual partners • Age 15-25 • Previous pelvic inflammatory disease • Inconsistent barrier contraception use • Partner with sexually transmitted infection
Physical examination	<ul style="list-style-type: none"> • Fever >38.3 C (>100.9 F) • Cervical motion tenderness • Mucopurulent cervical discharge
Treatment	<ul style="list-style-type: none"> • Outpatient: Ceftriaxone plus doxycycline • Inpatient: Cefoxitin plus doxycycline
Complications	<ul style="list-style-type: none"> • Tuboovarian abscess • Infertility • Ectopic pregnancy • Perihepatitis

After insertion of a progestin-releasing intrauterine device (IUD), patients may experience 3-6 months of irregular bleeding due to gradual endometrial thinning (ie, progestin-induced atrophy), often followed by amenorrhea (**Choice F**). Patients with stable amenorrhea who develop new-onset abnormal vaginal bleeding, such as this patient, require further evaluation.

In this patient with a change in bleeding pattern and new-onset pelvic pain, the most likely diagnosis is **pelvic inflammatory disease (PID)**, a



After insertion of a progestin-releasing intrauterine device (IUD), patients may experience 3-6 months of irregular bleeding due to gradual endometrial thinning (ie, progestin-induced atrophy), often followed by amenorrhea (**Choice F**). Patients with stable amenorrhea who develop new-onset abnormal vaginal bleeding, such as this patient, require further evaluation.

In this patient with a change in bleeding pattern and new-onset pelvic pain, the most likely diagnosis is **pelvic inflammatory disease (PID)**, a polymicrobial infection of the upper genital tract. Risk factors include age 15-25, multiple sexual partners, and inconsistent barrier protection use. PID is typically a complication of *Neisseria gonorrhoeae* or *Chlamydia trachomatis* **cervicitis**; symptomatic patients initially have **abnormal vaginal bleeding** (eg, with wiping, postcoital) due to an inflamed, **friable cervix**. Cervical inflammation can eventually compromise the endocervical barrier, thereby allowing polymicrobial vaginal flora (eg, anaerobes) to ascend and infect the **upper genital tract** (eg, uterus, fallopian tubes). Patients may initially have intermittent pain; however, as infection and inflammation spread throughout the peritoneal cavity, **constant pelvic pain** develops.

PID is **diagnosed clinically**; patients are prescribed empiric **broad-spectrum antibiotic therapy** (ie, second-generation cephalosporin plus doxycycline) to prevent complications (eg, infertility, chronic pain). In patients with an IUD in situ, IUD removal is not required; removal increases the risk of unintended pregnancy and does not affect treatment outcomes.

(Choice A) **Adenomyosis**, endometrial glands within the myometrium, typically presents with heavy vaginal bleeding and severe dysmenorrhea rather than light vaginal spotting and constant pelvic pain.

(Choice B) **Endocervical polyps** are benign, vascular, hyperplastic growths that can cause vaginal spotting (eg, postcoital bleeding); however, they do not cause pelvic pain.

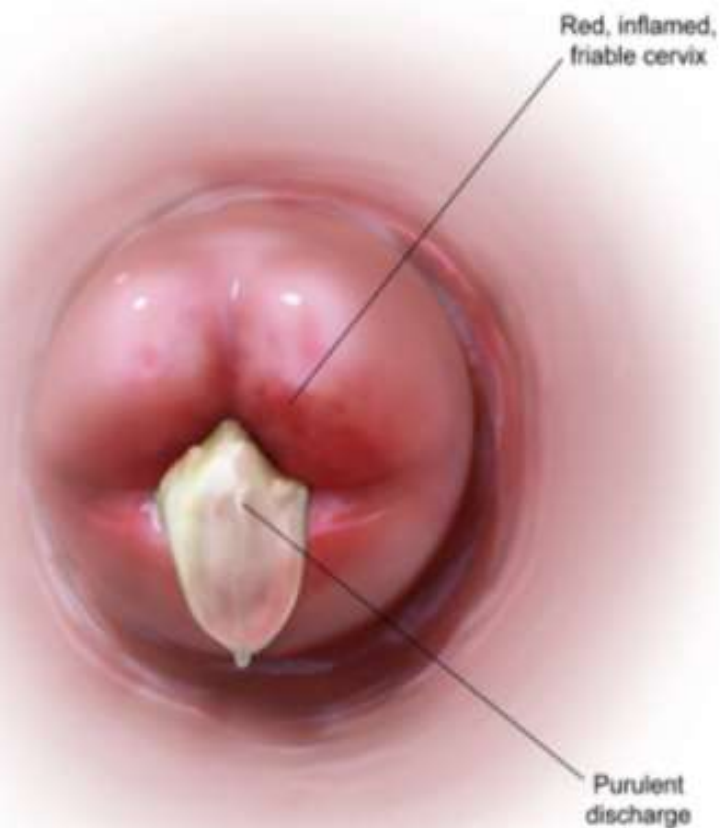(Choice C) **Endometriosis** is a common cause of pelvic pain in women of reproductive age due to the abnormal implantation of endometrial glands and stroma outside the uterus; because it is an extrauterine disease, abnormal vaginal bleeding is not present.

(Choice D) **Ovarian torsion** can present with pelvic pain due to ovarian vessel occlusion; however, patients typically have acute, severe unilateral pelvic pain. There is no associated abnormal vaginal bleeding.

Educational objective:

Exhibit Display

Cervicitis



©UWorld

Zoom In

Zoom Out

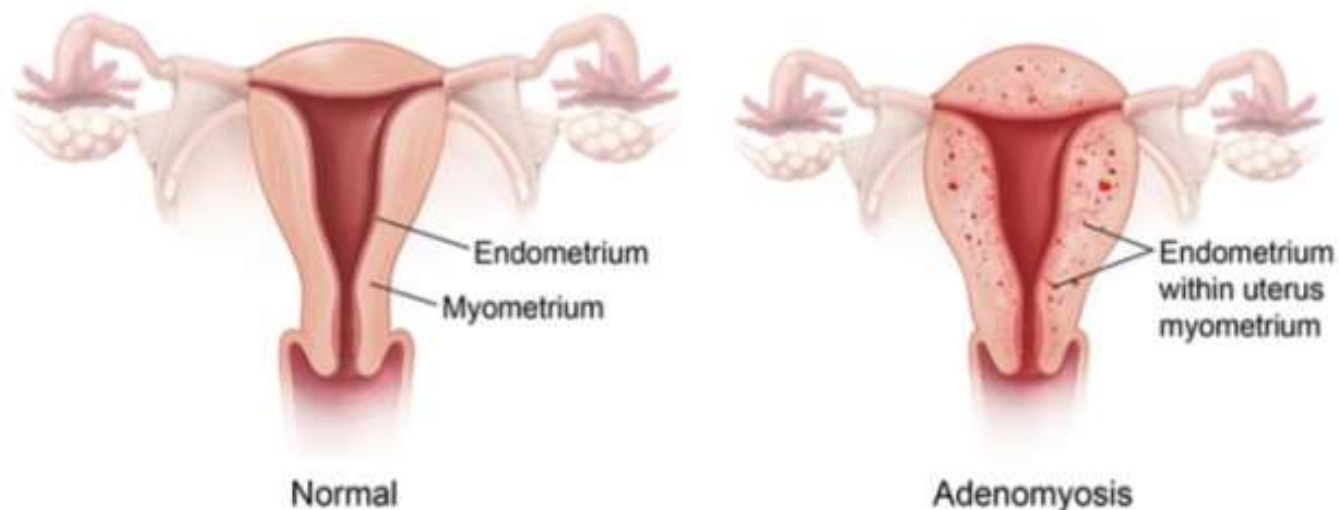
Reset

Add To New Card | Existing Card

endocervical barrier, thereby allowing polymicrobial vaginal flora (eg, anaerobes) to ascend and infect the **upper genital tract** (eg, uterus).

Exhibit Display

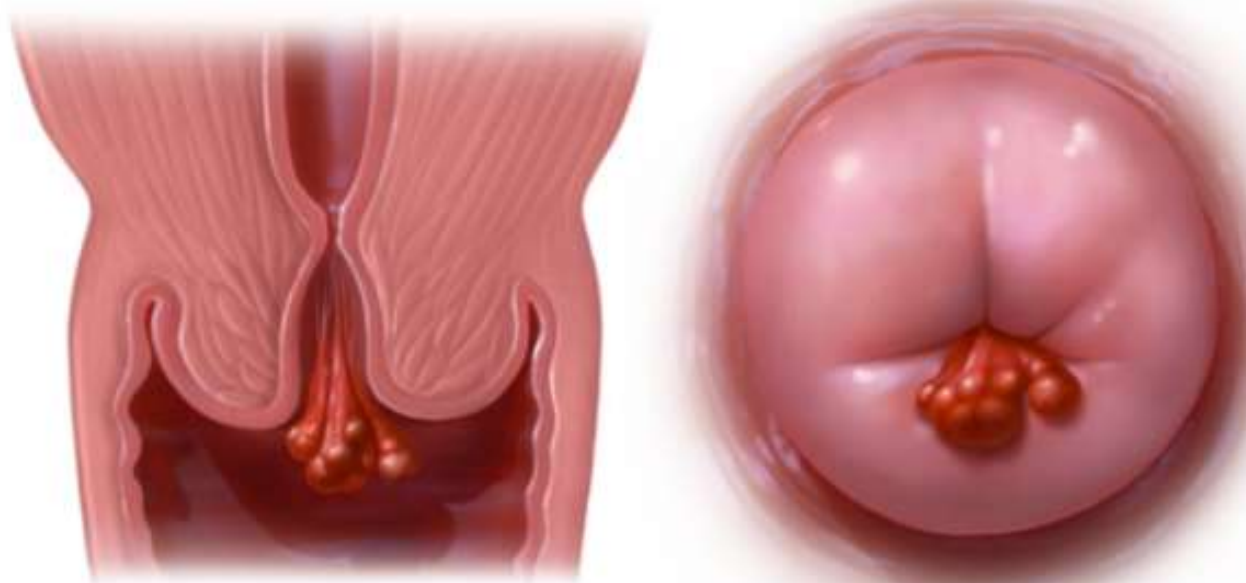
Normal uterus vs. adenomyosis



© USMLEWorld, LLC

endocervical barrier, thereby allowing polymicrobial vaginal flora (eg, anaerobes) to ascend and infect the **upper genital tract** (eg, uterus).

Exhibit Display



©UWorld

Zoom In

Zoom Out

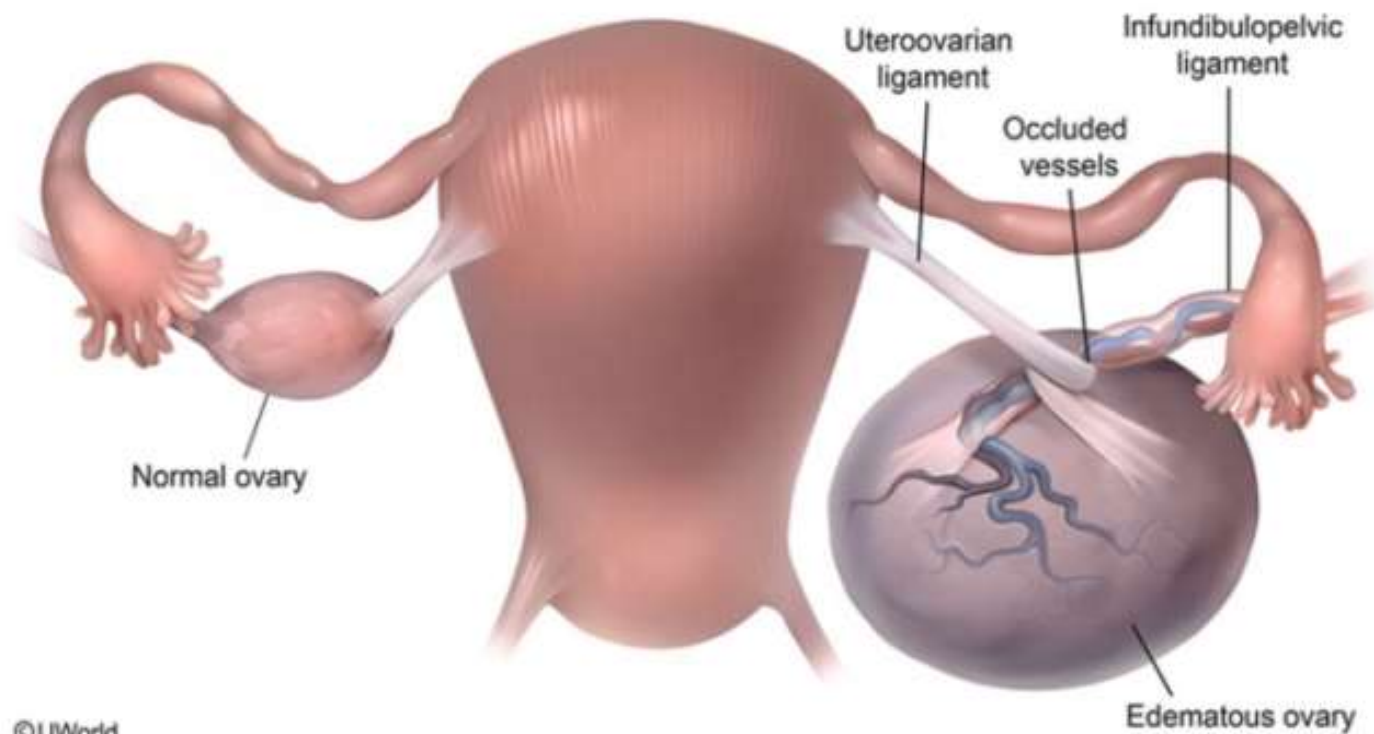
Reset

Add To New Card | Existing Card

endocervical barrier, thereby allowing polymicrobial vaginal flora (eg, anaerobes) to ascend and infect the **upper genital tract** (eg, uterus

Exhibit Display

Ovarian torsion



©UWorld

Zoom In

Zoom Out

Reset

Add To New Card | Existing Card

A 40-year-old woman comes to the emergency department due to abdominal pain for the past 2 weeks. The pain has become worse over the past day and is not relieved by ibuprofen. The patient has a fever but no nausea, vomiting, diarrhea, or dysuria. She has no chronic medical conditions or previous surgery. Her last menstrual period was 2 weeks ago; menses are regular and last 5 days, with painful cramping and heavy bleeding on the first day. The patient is currently sexually active with a male partner and uses condoms for contraception. She does not use tobacco, alcohol, or illicit drugs. Temperature is 38.8 C (102 F), blood pressure is 100/60 mm Hg, and pulse is 92/min. The abdomen has diffuse tenderness to deep palpation that is worst in the right lower quadrant. There is no rebound or guarding. Pelvic examination reveals a small, mobile, tender uterus and an enlarged, tender right adnexal mass. Leukocyte count is 22,000/mm³. C-reactive protein and CA-125 are elevated. Urine pregnancy test is negative. Pelvic ultrasonography reveals a large, thick-walled multiloculated mass filled with debris obliterating the right adnexa. Which of the following is the most likely diagnosis in this patient?

- A. Appendiceal abscess (1%)
- B. Degenerating subserosal uterine leiomyoma (0%)
- C. Endometriosis (1%)
- D. Infected ectopic pregnancy (0%)
- E. Mature cystic teratoma (14%)
- F. Ovarian serous cystadenocarcinoma (32%)
- G. Ovarian torsion (2%)
- H. Tubo-ovarian abscess (45%)

Omitted

Correct answer

H



45%

Answered correctly



05 secs

Time Spent



02/15/2020

Last Updated

Chlamydia & gonorrhea in women	
Risk factors	<ul style="list-style-type: none"> • Age <25 • High-risk sexual behavior
Manifestations	<ul style="list-style-type: none"> • Asymptomatic (most common) • Cervicitis • Urethritis • Perihepatitis (Fitz-Hugh and Curtis syndrome)
Diagnosis	<ul style="list-style-type: none"> • Nucleic acid amplification testing
Treatment	<ul style="list-style-type: none"> • Empiric: azithromycin + ceftriaxone • Confirmed chlamydia: azithromycin • Confirmed gonorrhea: azithromycin + ceftriaxone
Complications	<ul style="list-style-type: none"> • Pelvic inflammatory disease • Ectopic pregnancy • Infertility • Pharyngitis

Tubo-ovarian abscess (TOA), a complication of pelvic inflammatory disease, presents with fever, abdominal pain, and a **complex multiloculated adnexal mass** with thick walls and internal debris. TOA typically occurs in reproductive-age women due to a **polymicrobial infection** of the upper genital tract, a normally sterile environment. Infection extends to the fallopian tubes and creates an inflammatory exudate, purulent fluid, and wall thickening, which conglomerate into a complex mass to create pyosalpinx (eg, infected fallopian tube) and TOA.

Laboratory findings include increases in nonspecific indices (eg, leukocytosis, C-reactive protein, CA-125), which along with fever, suggest infection rather than malignancy (eg, ovarian serous cystadenocarcinoma) (**Choice F**). TOA is diagnosed by imaging (eg, pelvic ultrasound, CT

Tubo-ovarian abscess (TOA), a complication of pelvic inflammatory disease, presents with fever, abdominal pain, and a **complex multiloculated adnexal mass** with thick walls and internal debris. TOA typically occurs in reproductive-age women due to a **polymicrobial infection** of the upper genital tract, a normally sterile environment. Infection extends to the fallopian tubes and creates an inflammatory exudate, purulent fluid, and wall thickening, which conglomerate into a complex mass to create pyosalpinx (eg, infected fallopian tube) and TOA.

Laboratory findings include increases in nonspecific indices (eg, leukocytosis, C-reactive protein, CA-125), which along with fever, suggest infection rather than malignancy (eg, ovarian serous cystadenocarcinoma) (**Choice F**). TOA is diagnosed by imaging (eg, pelvic ultrasound, CT scan) and treated with broad-spectrum parenteral antibiotics.

(Choice A) An appendiceal abscess can cause a right lower quadrant abscess. However, typical presentation is periumbilical pain that migrates to the right lower quadrant with associated nausea, vomiting, and anorexia.

(Choice B) Degenerating subserosal uterine leiomyoma can present with abdominal pain, fever, and an irregularly enlarged, focally tender uterus. Ultrasound findings would reveal a leiomyoma rather than an adnexal mass.

(Choice C) Endometriosis can present with pelvic pain and an adnexal mass (eg, endometrioma) that is typically described as having a "ground glass" appearance on ultrasound. Physical examination reveals an adherent, immobile uterus, which is not seen in this patient.

(Choice D) An infected ectopic pregnancy is a rare cause of adnexal abscess. This diagnosis is excluded by a negative pregnancy test.

(Choice E) A mature cystic teratoma may present with abdominal pain or symptoms of torsion but does not cause fever and leukocytosis. Ultrasound reveals an ovarian cyst with solid components, hyperechoic nodules, and calcifications.

(Choice G) Ovarian torsion presents with sudden onset of unilateral pelvic pain without fever or leukocytosis. Ultrasound findings include an adnexal mass with absent Doppler flow to the ovary.

Educational objective:

Tubo-ovarian abscess is a complication of pelvic inflammatory disease; it presents with fever, abdominal pain, and a complex multiloculated adnexal mass with thick walls and internal debris on ultrasound.

References