

# Puberty, PCOS, Intersex, Hirsutism

Topic- based Uworld Questions

Block 1, 2, 7, 8



A 14-year-old girl is brought to the office by her mother for evaluation of lack of menstruation. The patient has no headaches, nipple discharge, or abdominal or pelvic pain. She takes a topical retinoid and an oral antibiotic for acne and was recently prescribed glasses for myopia. Her last office visit was 3 months ago for evaluation of gastroenteritis. Vaccinations are up to date, including human papillomavirus. Her mother has hypothyroidism; family history is otherwise unremarkable. The patient has 2 older sisters, both of whom underwent menarche at age 13. The patient is not sexually active and does not use tobacco, alcohol, or illicit drugs. Since her last appointment, height has increased from 152 cm (5 ft) to 155 cm (5 ft 1 in, 10th percentile) and weight is unchanged at 45.4 kg (100 lb, 15th percentile). Blood pressure is 118/72 mm Hg and pulse is 68/min. Physical examination shows nodulocystic acne on the face; the skin on the chest and back is clear. The thyroid is soft with no palpable nodules. Breast development is Tanner stage 4 and pubic hair is Tanner stage 3. Which of the following is the best next step in management of this patient?

- A. CT scan of the abdomen
- B. Karyotype analysis
- C. MRI of the brain
- D. Pelvic ultrasound
- E. Reassurance and reevaluation
- F. Thyroid-stimulating hormone level

Submit

A 14-year-old girl is brought to the office by her mother for evaluation of lack of menstruation. The patient has no headaches, nipple discharge, or abdominal or pelvic pain. She takes a topical retinoid and an oral antibiotic for acne and was recently prescribed glasses for myopia. Her last office visit was 3 months ago for evaluation of gastroenteritis. Vaccinations are up to date, including human papillomavirus. Her mother has hypothyroidism; family history is otherwise unremarkable. The patient has 2 older sisters, both of whom underwent menarche at age 13. The patient is not sexually active and does not use tobacco, alcohol, or illicit drugs. Since her last appointment, height has increased from 152 cm (5 ft) to 155 cm (5 ft 1 in, 10th percentile) and weight is unchanged at 45.4 kg (100 lb, 15th percentile). Blood pressure is 118/72 mm Hg and pulse is 68/min. Physical examination shows nodulocystic acne on the face; the skin on the chest and back is clear. The thyroid is soft with no palpable nodules. Breast development is Tanner stage 4 and pubic hair is Tanner stage 3. Which of the following is the best next step in management of this patient?

- A. CT scan of the abdomen (0%)
- B. Karyotype analysis (5%)
- C. MRI of the brain (0%)
- D. Pelvic ultrasound (18%)
- E. Reassurance and reevaluation (67%)
- F. Thyroid-stimulating hormone level (6%)

Omitted

Correct answer

E



67%

Answered correctly



01 sec

Time Spent



02/22/2020

Last Updated

Explanation

## Explanation

**Normal pubertal development** begins with the activation of the [hypothalamic-pituitary-ovarian axis](#). Pulsatile secretion of gonadotropin-releasing hormone from the hypothalamus stimulates the release of FSH and LH from the anterior pituitary, activating the gonads to produce estrogen.

**Breast development** (thelarche) is typically the **first sign of puberty in girls** and occurs at age 8-12 in response to rising estrogen levels. **Pubic hair** development (pubarche) usually follows thelarche but can occur first. The onset of menses (**menarche**) is expected around [Tanner stage 4](#), approximately 2-2.5 years after initial breast bud development. The average age for menarche is 12.5; however, lack of menses is considered normal at age <15 if development of secondary sex characteristics has been appropriate. In the 6 months preceding menarche, girls experience a **growth spurt**, a peak in growth velocity.

This patient is age 14 with normal breast and pubic hair development. Given that she has grown 3 cm in the past 3 months, she is likely undergoing a pubertal growth spurt, and menarche is anticipated within the next 6 months. Appropriate management is to provide **reassurance** regarding her normal development and **reevaluate** if menarche does not occur by age 15.

**(Choice A)** CT scan of the abdomen can evaluate for an androgen-secreting adrenal mass in patients with virilization (eg, clitoromegaly, premature pubarche). This patient has facial acne and pubic hair typical of normal adrenarche.

**(Choice B)** Karyotype analysis is performed for amenorrhea in the setting of little or no breast development, a presentation concerning for Turner syndrome. Patients have primary ovarian insufficiency, resulting in a lack of estrogen and abnormal pubertal development.

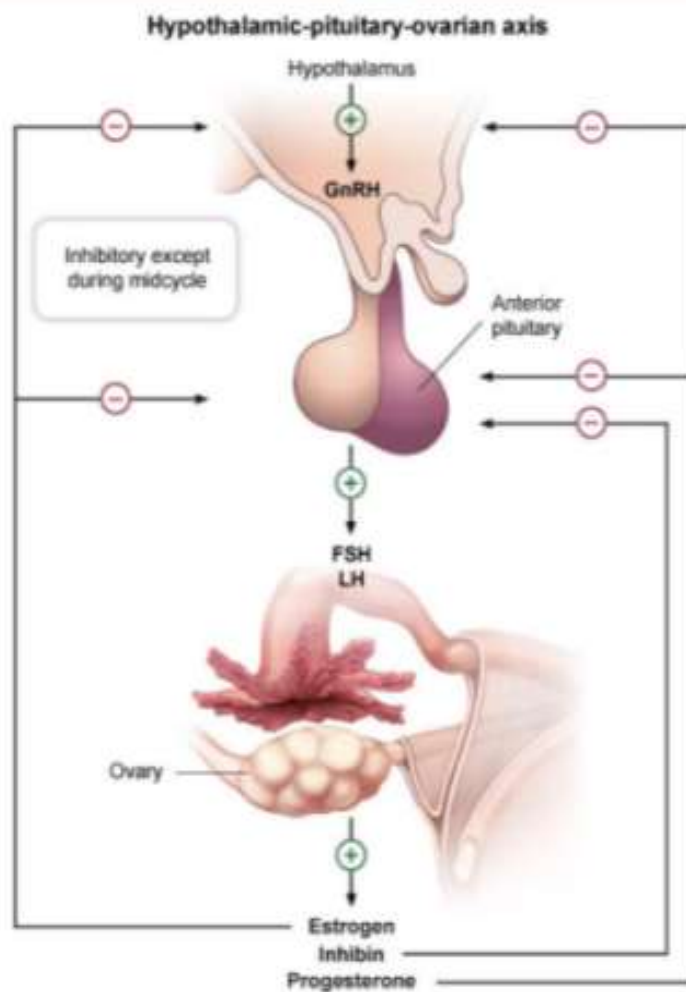
**(Choices C, D, and F)** Primary amenorrhea is the lack of menses without secondary sex characteristics at age  $\geq 13$  or with secondary sex characteristics at age  $\geq 15$ . Evaluation includes a thyroid-stimulating hormone level to evaluate for hypothyroidism and a pelvic ultrasound to confirm the presence of a uterus and ovaries. MRI of the brain may be indicated in a patient who also has galactorrhea and an elevated prolactin level, a presentation suggestive of a prolactinoma. This patient does not have primary amenorrhea as she is age 14 with normal pubertal development.

**Educational objective:**

Breast development is typically the first manifestation of puberty and is followed by menarche within 2-2.5 years. Premenarchal patients age <15 with normal breast and pubic hair development require no further evaluation.

Explanation

## Exhibit Display

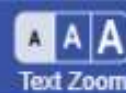


Zoom In

Zoom Out

Reset

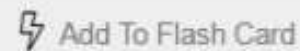
Add To Flash Card



Explanation

## Exhibit Display

Normal pubertal growth in girls

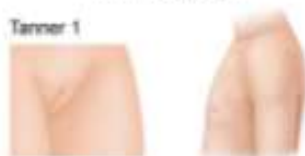

Explanation

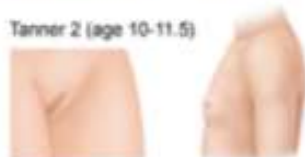## Exhibit Display

## Tanner stages

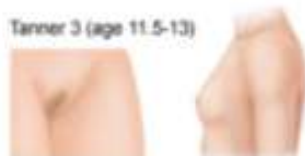Tanner 1



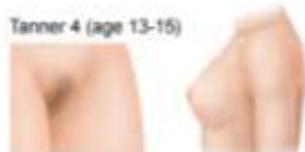Tanner 2 (age 10-11.5)



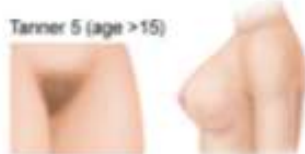Tanner 3 (age 11.5-13)



Tanner 4 (age 13-15)



Tanner 5 (age &gt;15)



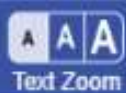
Note: ages represent mean ages of development.  
© 2010

Zoom In

Zoom Out

Reset

Add To Flash Card



A 16-year-old girl comes to the office for evaluation of acne. Around the time of her first menstrual period at age 10, the acne appeared only on her face, but over the past 6 years, it has spread to her chest and back. Topical preparations are not effective, and the patient feels anxious regarding social situations at school. She quit the soccer team and has since gained 9.1 kg (20 lb). The patient has never been sexually active. Menses are irregular and her last menstrual period was 3 months ago. She has not had a Pap test but has completed the human papillomavirus vaccination series. The patient takes no medications and does not use tobacco. Family history is noncontributory. Physical examination shows cystic and nodular acne over the face, back, and upper chest. There is no goiter or thyroid masses. Terminal hairs are notable on the upper lip and around the nipples. Development is Tanner stage V. The abdomen is obese and nontender, with no masses and normal bowel sounds. Serum total testosterone and dehydroepiandrosterone sulfate levels are normal. This patient is at greatest risk for developing malignancy of which of the following?

- A. Adrenal gland
- B. Cervix
- C. Endometrium
- D. Thyroid
- E. Vagina
- F. Vulva

Submit



A 16-year-old girl comes to the office for evaluation of acne. Around the time of her first menstrual period at age 10, the acne appeared only on her face, but over the past 6 years, it has spread to her chest and back. Topical preparations are not effective, and the patient feels anxious regarding social situations at school. She quit the soccer team and has since gained 9.1 kg (20 lb). The patient has never been sexually active. Menses are irregular and her last menstrual period was 3 months ago. She has not had a Pap test but has completed the human papillomavirus vaccination series. The patient takes no medications and does not use tobacco. Family history is noncontributory. Physical examination shows cystic and nodular acne over the face, back, and upper chest. There is no goiter or thyroid masses. Terminal hairs are notable on the upper lip and around the nipples. Development is Tanner stage V. The abdomen is obese and nontender, with no masses and normal bowel sounds. Serum total testosterone and dehydroepiandrosterone sulfate levels are normal. This patient is at greatest risk for developing malignancy of which of the following?

- A. Adrenal gland (5%)
- B. Cervix (1%)
- C. Endometrium (91%)
- D. Thyroid (0%)
- E. Vagina (0%)
- F. Vulva (0%)

Omitted

Correct answer

C



91%

Answered correctly



02 secs

Time Spent



02/27/2020

Last Updated

Explanation

Polycystic ovary syndrome	
<b>Clinical features</b>	<ul style="list-style-type: none"> <li>• <b>Androgen excess</b> (eg, acne, male pattern baldness, hirsutism)</li> <li>• Oligoovulation or anovulation (eg, <b>menstrual irregularities</b>)</li> <li>• Obesity</li> <li>• <b>Polycystic ovaries</b> on ultrasound</li> </ul>
<b>Pathophysiology</b>	<ul style="list-style-type: none"> <li>• ↑ Testosterone levels</li> <li>• ↑ Estrogen levels</li> <li>• LH/FSH imbalance</li> </ul>
<b>Comorbidities</b>	<ul style="list-style-type: none"> <li>• Metabolic syndrome (eg, diabetes, hypertension)</li> <li>• Obstructive sleep apnea</li> <li>• Nonalcoholic steatohepatitis</li> <li>• Endometrial hyperplasia/cancer</li> </ul>
<b>Treatment options</b>	<ul style="list-style-type: none"> <li>• Weight loss (first-line)</li> <li>• Oral contraceptives for menstrual regulation</li> <li>• Letrozole for ovulation induction</li> </ul>

**Polycystic ovary syndrome (PCOS)** is a common condition diagnosed in adolescents due to signs of **hyperandrogenism** and irregular menses. Clinical evidence of hyperandrogenism includes **severe nodulocystic acne**, male pattern baldness, and **hirsutism**. Although many patients with PCOS have biochemical evidence of hyperandrogenism with elevated serum levels of total testosterone, these laboratory values may be normal in some due to decreased levels of sex hormone-binding globulin, with elevated free testosterone levels instead. Therefore, the diagnosis requires either clinical or biochemical evidence of hyperandrogenism.

Women with PCOS typically have decreased progesterone secretion due to chronic anovulatory cycles. Therefore, these patients usually have a constant and unbalanced **proliferation of the endometrium by estrogens**. This unopposed estrogen stimulation places patients at increased risk for **endometrial hyperplasia and cancer**. Treatment with cyclic progesterone, estrogen/progestin oral contraceptives, or progesterone-releasing

**Polycystic ovary syndrome (PCOS)** is a common condition diagnosed in adolescents due to signs of **hyperandrogenism** and irregular menses. Clinical evidence of hyperandrogenism includes **severe nodulocystic acne**, male pattern baldness, and **hirsutism**. Although many patients with PCOS have biochemical evidence of hyperandrogenism with elevated serum levels of total testosterone, these laboratory values may be normal in some due to decreased levels of sex hormone-binding globulin, with elevated free testosterone levels instead. Therefore, the diagnosis requires either clinical or biochemical evidence of hyperandrogenism.

Women with PCOS typically have decreased progesterone secretion due to chronic anovulatory cycles. Therefore, these patients usually have a constant and unbalanced **proliferation of the endometrium by estrogens**. This unopposed estrogen stimulation places patients at increased risk for **endometrial hyperplasia and cancer**. Treatment with cyclic progesterone, estrogen/progestin oral contraceptives, or progesterone-releasing intrauterine devices protects the endometrium from hyperplasia and reduces cancer risk.

**(Choice A)** Adrenocortical malignancies typically occur with an associated syndrome (eg, Li-Fraumeni syndrome). An adrenocortical tumor may cause hyperandrogenism but is unlikely in a patient with a negative family history and normal dehydroepiandrosterone sulfate.

**(Choices B and F)** The main risk factor for squamous cell vulvar and cervical cancer is persistent human papillomavirus (HPV) infection. The HPV vaccination series reduces the risk of these cancers by preventing infection with high-risk HPV types 16 and 18.

**(Choice D)** Family history and radiation exposure are the major risk factors for thyroid cancer. Typical presentation is a thyroid nodule and no menstrual irregularities.

**(Choice E)** Clear cell vaginal cancer is linked to in utero exposure to diethylstilbestrol, not PCOS. Vaginal squamous cell carcinoma is linked to HPV infection.

#### Educational objective:

Polycystic ovary syndrome (PCOS) presents with hyperandrogenism (eg, severe acne, hirsutism, androgenic alopecia) and irregular menses. Patients with PCOS are at increased risk for endometrial hyperplasia and cancer due to unregulated endometrial proliferation from unopposed estrogen stimulation.

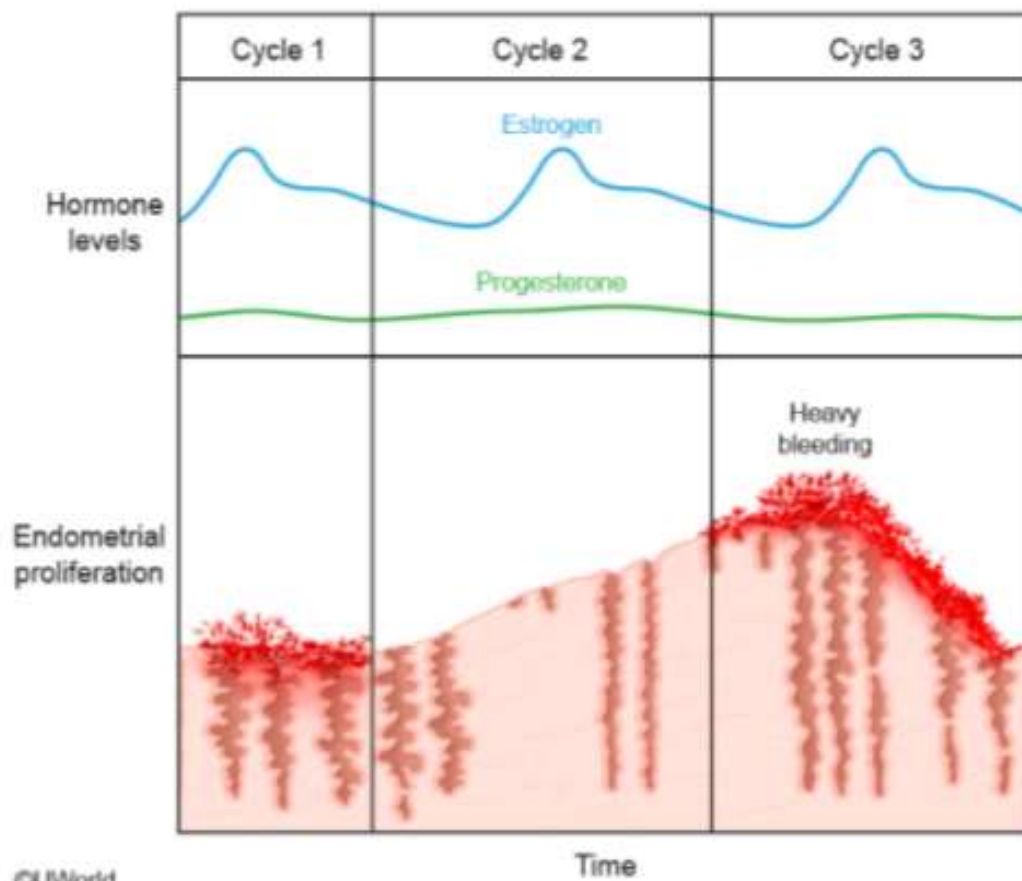
#### References

- [ACOG Practice Bulletin No. 108: polycystic ovary syndrome.](#)

- LH/FSH imbalance

## Exhibit Display

## Effect of anovulatory cycles on the endometrium



GUWorld

Time

Zoom In

Zoom Out

Reset

Add To New Card | Existing Card

A 13-year-old girl is brought to the office for evaluation of acne. She began to develop acne over her forehead and chin 4 months ago. She used over-the-counter topical salicylic acid, but the acne did not improve. Now, the patient has painful acne over her face and upper chest. She participates in a soccer league after school, and her mother feels that her exercise regimen is too strenuous and stressful and contributes to her acne. The patient has no medical conditions and has had no surgeries. She has not had a menstrual period. The girl has grown 10.1 cm (4 in) in the last year; her height and weight are at the 70th percentile for age. Vital signs are normal. Nodulocystic acne is present across the face and upper chest. There is no breast bud development. The abdomen is nontender and has no palpable masses. External pelvic examination shows the clitoris protruding from the clitoral hood and bilateral masses in the labia majora. Which of the following is the most likely diagnosis in this patient?

- A. 5-alpha-reductase deficiency
- B. Androgen insensitivity syndrome
- C. Nonclassic congenital adrenal hyperplasia
- D. Ovarian hyperthecosis
- E. Polycystic ovary syndrome
- F. Sertoli-Leydig cell tumor

Submit



Previous



Next



Full Screen




Tutorial



Lab Values




Notes



Calculator



Reverse Color



Text Zoom

A 13-year-old girl is brought to the office for evaluation of acne. She began to develop acne over her forehead and chin 4 months ago. She used over-the-counter topical salicylic acid, but the acne did not improve. Now, the patient has painful acne over her face and upper chest. She participates in a soccer league after school, and her mother feels that her exercise regimen is too strenuous and stressful and contributes to her acne. The patient has no medical conditions and has had no surgeries. She has not had a menstrual period. The girl has grown 10.1 cm (4 in) in the last year; her height and weight are at the 70th percentile for age. Vital signs are normal. Nodulocystic acne is present across the face and upper chest. There is no breast bud development. The abdomen is nontender and has no palpable masses. External pelvic examination shows the clitoris protruding from the clitoral hood and bilateral masses in the labia majora. Which of the following is the most likely diagnosis in this patient?

- A. 5-alpha-reductase deficiency (34%)
- B. Androgen insensitivity syndrome (36%)
- C. Nonclassic congenital adrenal hyperplasia (18%)
- D. Ovarian hyperthecosis (1%)
- E. Polycystic ovary syndrome (1%)
- F. Sertoli-Leydig cell tumor (7%)

Omitted

Correct answer

A



34%

Answered correctly



02 secs

Time Spent



01/15/2020

Last Updated

Explanation

5-alpha-reductase deficiency	
<b>Pathogenesis</b>	<ul style="list-style-type: none"> <li>• 46,XY genotype</li> <li>• Impaired testosterone to DHT conversion</li> <li>• Impaired virilization during embryogenesis</li> <li>• Normal male testosterone &amp; estrogen levels</li> </ul>
<b>Clinical features</b>	<ul style="list-style-type: none"> <li>• Male internal genitalia (eg, testes, vas deferens)</li> <li>• Female external genitalia (eg, blind-ending vagina)</li> <li>• Phenotypically female at birth</li> <li>• Virilization at puberty (↑ testosterone)               <ul style="list-style-type: none"> <li>◦ Clitoromegaly</li> <li>◦ Increased muscle mass</li> <li>◦ Male-pattern hair development</li> <li>◦ Nodulocystic acne</li> </ul> </li> </ul>

DHT = dihydrotestosterone.

During embryogenesis, sexual development in genotypically male fetuses (46,XY) occurs due to testicular hormone production. The testes produce testosterone, which promotes development of the male internal genitalia (eg, vas deferens, epididymis). Testosterone is also converted to dihydrotestosterone (DHT) via 5-alpha-reductase; DHT promotes development of the male external genitalia (eg, penis) and prostate. Patients with **5-alpha-reductase deficiency** are unable to convert testosterone into DHT; therefore, they have **no male external genitalia** development, have **undescended testes** (eg, bilateral labial masses), and appear **phenotypically female** at birth.

At puberty, **increased testosterone** levels cause **virilization**, such as nodulocystic acne and clitoromegaly (ie, clitoris protruding from the clitoral hood), of phenotypically female patients. Additional features of virilization may include voice deepening and increased muscle mass. The testosterone levels at puberty are at the normal male range; therefore, patients develop additional normal secondary sexual characteristics (eg, axillary and pubic hair). Patients have **no breast development** because testosterone binds to the breast androgen receptor and inhibits breast

hood), of phenotypically female patients. Additional features of virilization may include voice deepening and increased muscle mass. The testosterone levels at puberty are at the normal male range; therefore, patients develop additional normal secondary sexual characteristics (eg, axillary and pubic hair). Patients have **no breast development** because testosterone binds to the breast androgen receptor and inhibits breast tissue proliferation. Diagnosis in adolescents and adults is based on an elevated testosterone/DHT ratio. Management is dependent on age and gender identity.

**(Choice B)** Patients with androgen insensitivity syndrome (AIS) have a defective androgen receptor, which prevents virilization during embryogenesis. Fetuses have male internal genitalia (ie, testes) that produce testosterone but, due to peripheral testosterone resistance, do not develop male external genitalia. Therefore, patients with AIS appear phenotypically female at birth. However, in contrast to patients with 5-alpha-reductase deficiency, those with AIS have breast development at puberty as the defective androgen receptor is unable to inhibit breast tissue proliferation.

**(Choice C)** Patients with nonclassic congenital adrenal hyperplasia (21-hydroxylase deficiency) can have virilization; however, they are genotypically female (46,XX) and therefore do not have undescended testes (eg, bilateral labial masses).

**(Choice D)** Ovarian hyperthecosis can present in women with virilization; however, patients are typically postmenopausal and have bilaterally enlarged ovaries (not testes).

**(Choice E)** Patients with polycystic ovary syndrome have hyperandrogenism (eg, acne, hirsutism) but not virilization (eg, clitoromegaly).

**(Choice F)** Sertoli-Leydig cell tumors are testosterone-producing ovarian tumors that can result in virilization. However, patients have a unilateral solid adnexal mass rather than bilateral undescended testes.

#### Educational objective:

5-alpha-reductase deficiency causes impaired conversion of testosterone to dihydrotestosterone. In male fetuses, this impaired conversion during embryogenesis causes male internal genitalia and female external genitalia development, resulting in a phenotypically female infant. During puberty, increased testosterone levels result in virilization (eg, clitoromegaly) in these patients.

#### References

- [Steroid 5a-reductase 2 deficiency.](#)
- [5-Alpha reductase deficiency: a 40-year retrospective review](#)



A 16-year-old girl comes to the office for evaluation of excessive facial hair. The patient has used multiple creams and makeup over the last year but is still embarrassed by the facial hair. She also has had irregular menstrual cycles since menarche at age 12; her last menstrual period was 6 weeks ago. She is an avid runner. Blood pressure is 122/70 mm Hg and pulse is 87/min. BMI is 20 kg/m<sup>2</sup>. Physical examination shows hirsutism. The patient has normal external female genitalia, the rest of the examination is unremarkable. Urine pregnancy test is negative. Laboratory results are as follows:

17-hydroxyprogesterone	350 ng/mL (normal: <15)
Serum testosterone	80 ng/mL (normal: 20-75)
Serum dehydroepiandrosterone sulfate	390 µg/dL (normal: 37-307)

Serum glucose and electrolytes are normal. Which of the following is the most likely diagnosis in this patient?

- A. Adrenal carcinoma
- B. Cushing syndrome
- C. Germ cell tumor
- D. Idiopathic hirsutism
- E. Nonclassic congenital adrenal hyperplasia
- F. Polycystic ovary syndrome
- G. Use of performance-enhancing agents



A 16-year-old girl comes to the office for evaluation of excessive facial hair. The patient has used multiple creams and makeup over the last year but is still embarrassed by the facial hair. She also has had irregular menstrual cycles since menarche at age 12; her last menstrual period was 6 weeks ago. She is an avid runner. Blood pressure is 122/70 mm Hg and pulse is 87/min. BMI is 20 kg/m<sup>2</sup>. Physical examination shows hirsutism. The patient has normal external female genitalia; the rest of the examination is unremarkable. Urine pregnancy test is negative. Laboratory results are as follows:

17-hydroxyprogesterone	350 ng/mL (normal: <15)
Serum testosterone	80 ng/mL (normal: 20-75)
Serum dehydroepiandrosterone sulfate	390 µg/dL (normal: 37-307)

Serum glucose and electrolytes are normal. Which of the following is the most likely diagnosis in this patient?

- A. Adrenal carcinoma (3%)
- B. Cushing syndrome (0%)
- C. Germ cell tumor (3%)
- D. Idiopathic hirsutism (0%)
- E. Nonclassic congenital adrenal hyperplasia (74%)
- F. Polycystic ovary syndrome (11%)
- G. Use of performance-enhancing agents (6%)


Nonclassic congenital adrenal hyperplasia	
<b>Pathophysiology</b>	<ul style="list-style-type: none"><li>• Autosomal recessive</li><li>• ↓ 21-Hydroxylase activity</li><li>• Normal glucocorticoids &amp; mineralocorticoids</li><li>• ↑ Androgens</li></ul>
<b>Clinical features</b>	<ul style="list-style-type: none"><li>• Early pubic/axillary hair growth</li><li>• Severe acne</li><li>• Hirsutism &amp; oligomenorrhea in girls</li><li>• ↑ Growth velocity &amp; bone age</li><li>• ↑ 17-Hydroxyprogesterone level</li></ul>
<b>Treatment</b>	<ul style="list-style-type: none"><li>• Hydrocortisone</li></ul>

This patient has **nonclassic** (late-onset) **congenital adrenal hyperplasia** (CAH) based on hyperandrogenism and an **elevated 17-hydroxyprogesterone** (17-OHP) level. The majority of nonclassic CAH is due to a partial deficiency in **21-hydroxylase**, which results in impaired conversion of 17-OHP to 11-deoxycortisol. Buildup of 17-OHP is then diverted toward adrenal androgen synthesis, resulting in **hyperandrogenism**.

Girls with nonclassic CAH typically present in **adolescence** or early adulthood with **irregular menses**, severe acne, and **hirsutism**; virilization (eg, clitoromegaly, deepening of the voice) is rare. Since the enzyme deficiency in nonclassic CAH is relatively mild, sufficient glucocorticoids and mineralocorticoids are produced; therefore, patients do not have the salt-wasting seen in classic CAH, and electrolytes and blood pressure remain normal. Diagnosis is confirmed by an exaggerated 17-OHP response on ACTH stimulation test.

**(Choice A)** Androgen-producing adrenal tumors typically present in adulthood with rapidly progressive hirsutism and virilization. Serum DHEAS is markedly elevated with concentrations >700 µg/dL.

**(Choice B)** Cushing syndrome can cause hirsutism due to elevated adrenal androgens. However, this patient has no Cushingoid features such as moon facies, buffalo hump, central obesity, hypertension, or electrolyte abnormalities. 17-OHP levels are usually normal in Cushing syndrome.



This patient has **nonclassic** (late-onset) **congenital adrenal hyperplasia** (CAH) based on hyperandrogenism and an **elevated 17-hydroxyprogesterone** (17-OHP) level. The majority of nonclassic CAH is due to a partial deficiency in **21-hydroxylase**, which results in impaired conversion of 17-OHP to 11-deoxycortisol. Buildup of 17-OHP is then diverted toward adrenal androgen synthesis, resulting in **hyperandrogenism**.

Girls with nonclassic CAH typically present in **adolescence** or early adulthood with **irregular menses**, severe acne, and **hirsutism**; virilization (eg, clitoromegaly, deepening of the voice) is rare. Since the enzyme deficiency in nonclassic CAH is relatively mild, sufficient glucocorticoids and mineralocorticoids are produced; therefore, patients do not have the salt-wasting seen in classic CAH, and electrolytes and blood pressure remain normal. Diagnosis is confirmed by an exaggerated 17-OHP response on ACTH stimulation test.

**(Choice A)** Androgen-producing adrenal tumors typically present in adulthood with rapidly progressive hirsutism and virilization. Serum DHEAS is markedly elevated with concentrations  $>700 \mu\text{g/dL}$ .

**(Choice B)** Cushing syndrome can cause hirsutism due to elevated adrenal androgens. However, this patient has no Cushingoid features such as moon facies, buffalo hump, central obesity, hypertension, or electrolyte abnormalities. 17-OHP levels are usually normal in Cushing syndrome.

**(Choice C)** Ovarian germ cell tumors (eg, embryonal carcinoma, choriocarcinoma) typically present with abdominal ascites, pelvic mass, and pregnancy symptoms (eg, breast tenderness). However, they do not usually cause hirsutism. In addition, these tumors often secrete  $\beta$ -hCG, creating a false-positive pregnancy test.

**(Choice D)** Idiopathic hirsutism is due to excessive conversion of testosterone to dihydrotestosterone in the hair follicles. There is usually a positive family history and normal 17-OHP and androgen levels.

**(Choice F)** Patients with polycystic ovary syndrome have menstrual irregularities and hyperandrogenism; however, 17-OHP is not elevated.

**(Choice G)** Anabolic steroid use for performance enhancement presents with hirsutism, voice deepening, increased muscle bulk, and virilization. However, exogenous androgens would not cause elevated 17-OHP.

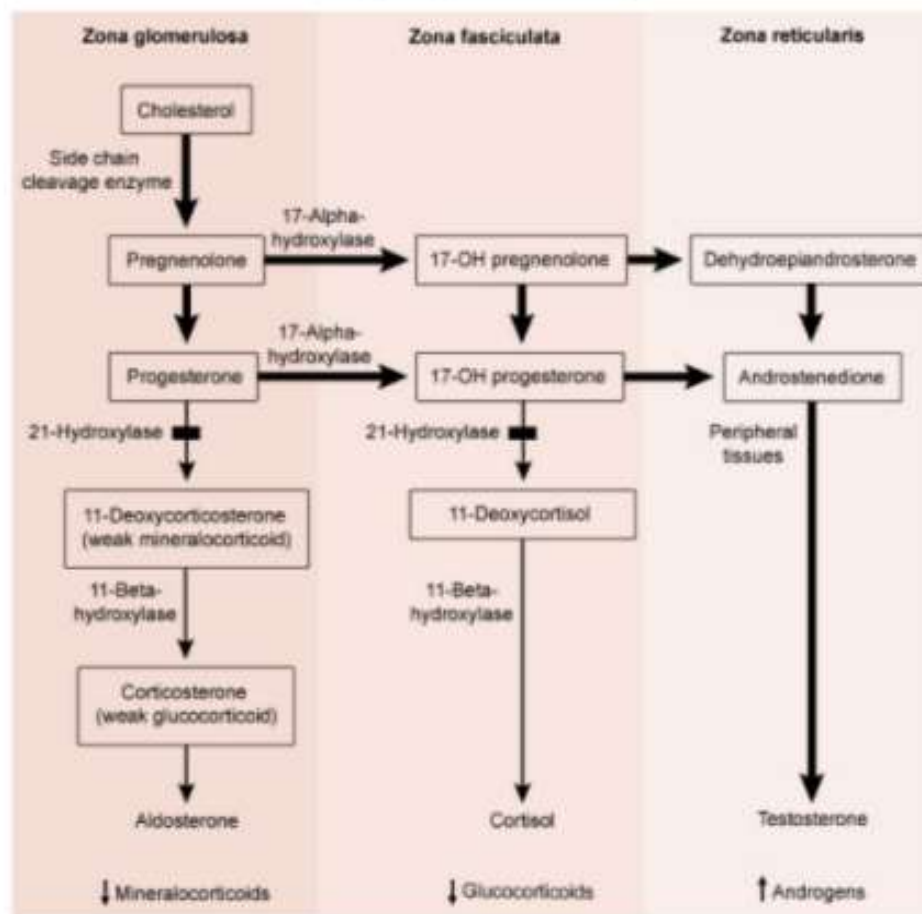
**Educational objective:**

Nonclassic congenital adrenal hyperplasia is caused by a partial deficiency of 21-hydroxylase and typically presents with hyperandrogenism (eg, irregular menses, hirsutism) and elevated 17-hydroxyprogesterone level.

This patient has **nonclassic (late-onset) congenital adrenal hyperplasia (CAH)** based on hyperandrogenism and an **elevated 17-**

### Exhibit Display

#### 21-Hydroxylase deficiency



©UWorld

menstrual menses, hirsutism) and elevated 17-hydroxyprogesterone level.