

Respiratory System Module

1st Semester 2024-2025

**Thoracic Cage
Intercostal muscles**

**Dr. Aiman Qais Afar
Surgical Anatomist**

College of Medicine / University of Mutah

2024-2025

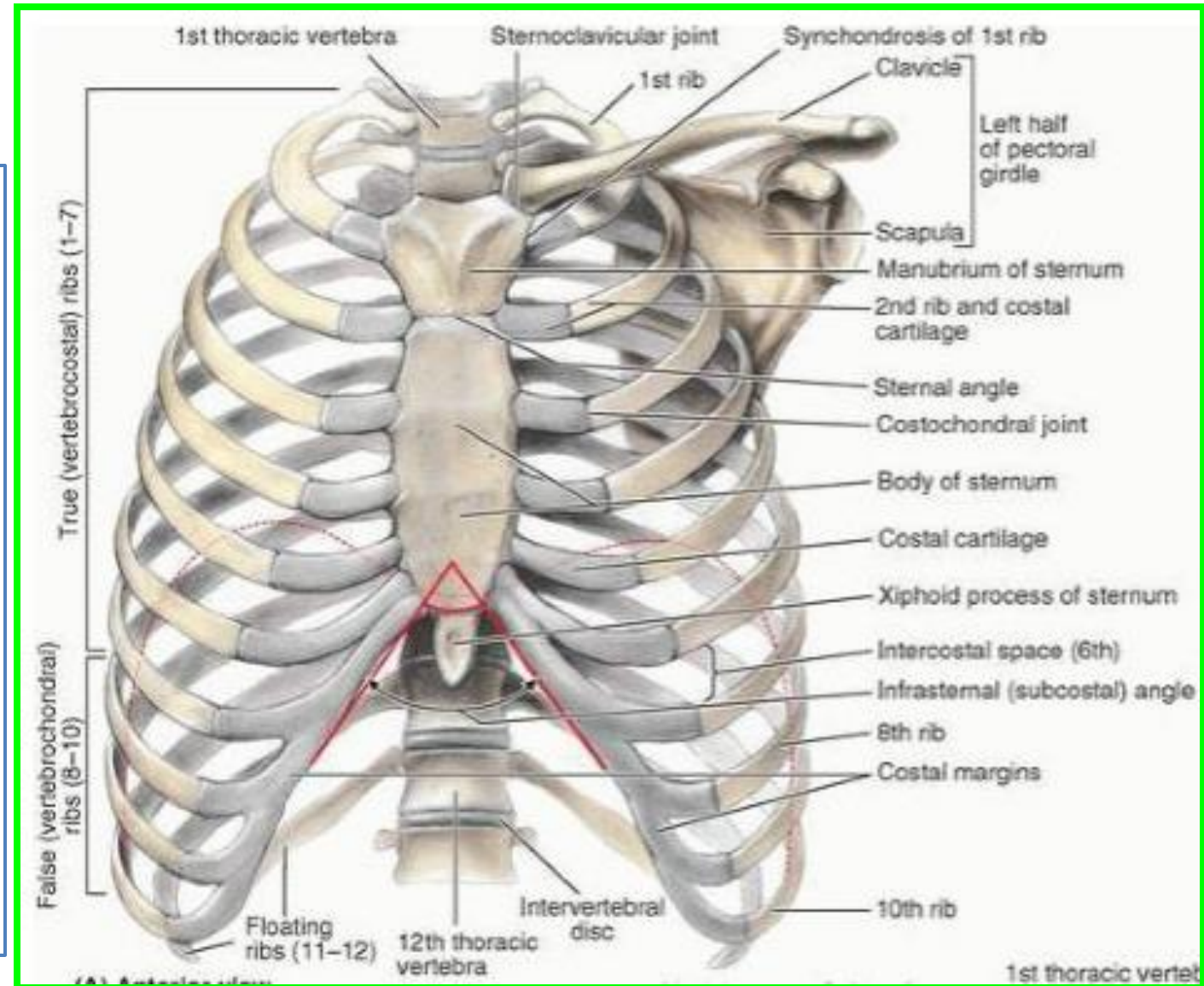
Sunday 6 October 2024

The Thoracic Wall

The thorax (or chest) is the region of the body between the neck and the abdomen.

It is flattened in front and behind but rounded at the sides.

The framework of the walls of the thorax, which is referred to as the **thoracic cage**



Thoracic Cage

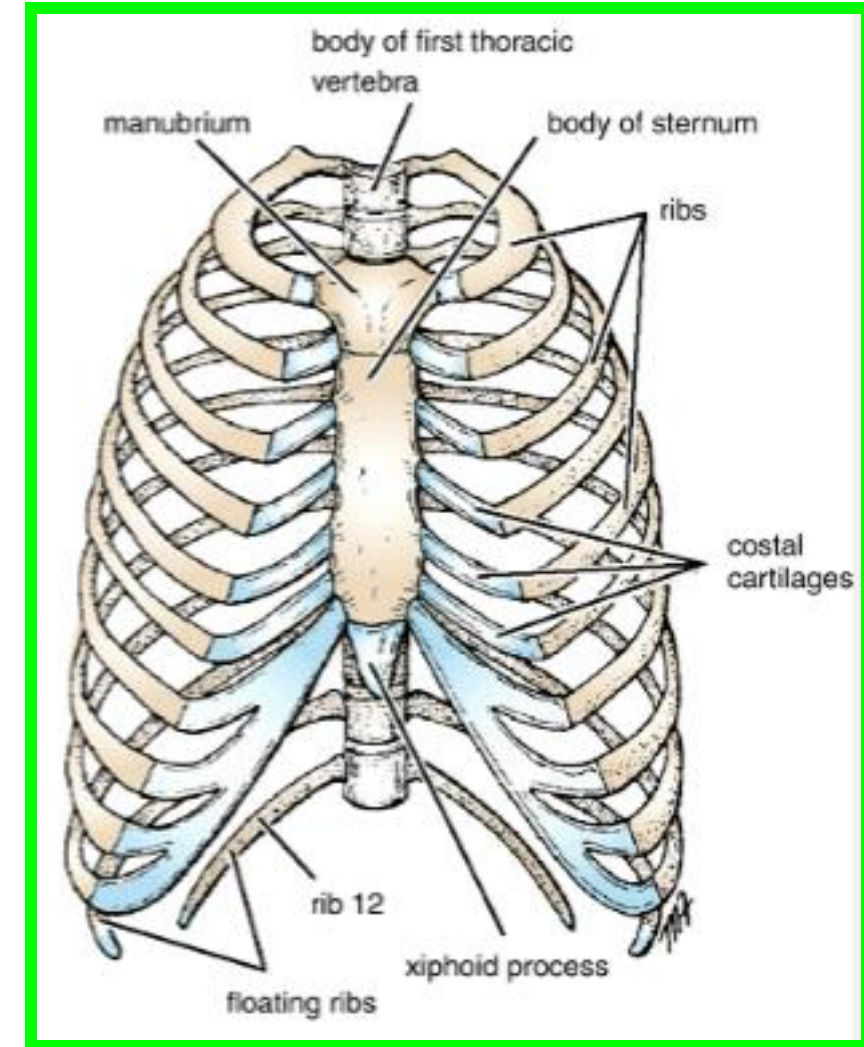
The thoracic wall is formed **posteriorly** by the **thoracic part of the vertebral column**;

anteriorly by the **sternum and costal cartilages**.

laterally by the **ribs and intercostal spaces**;

superiorly by the **suprapleural membrane**; and

inferiorly by the **diaphragm**, which separates the **thoracic cavity** from the **abdominal cavity**.

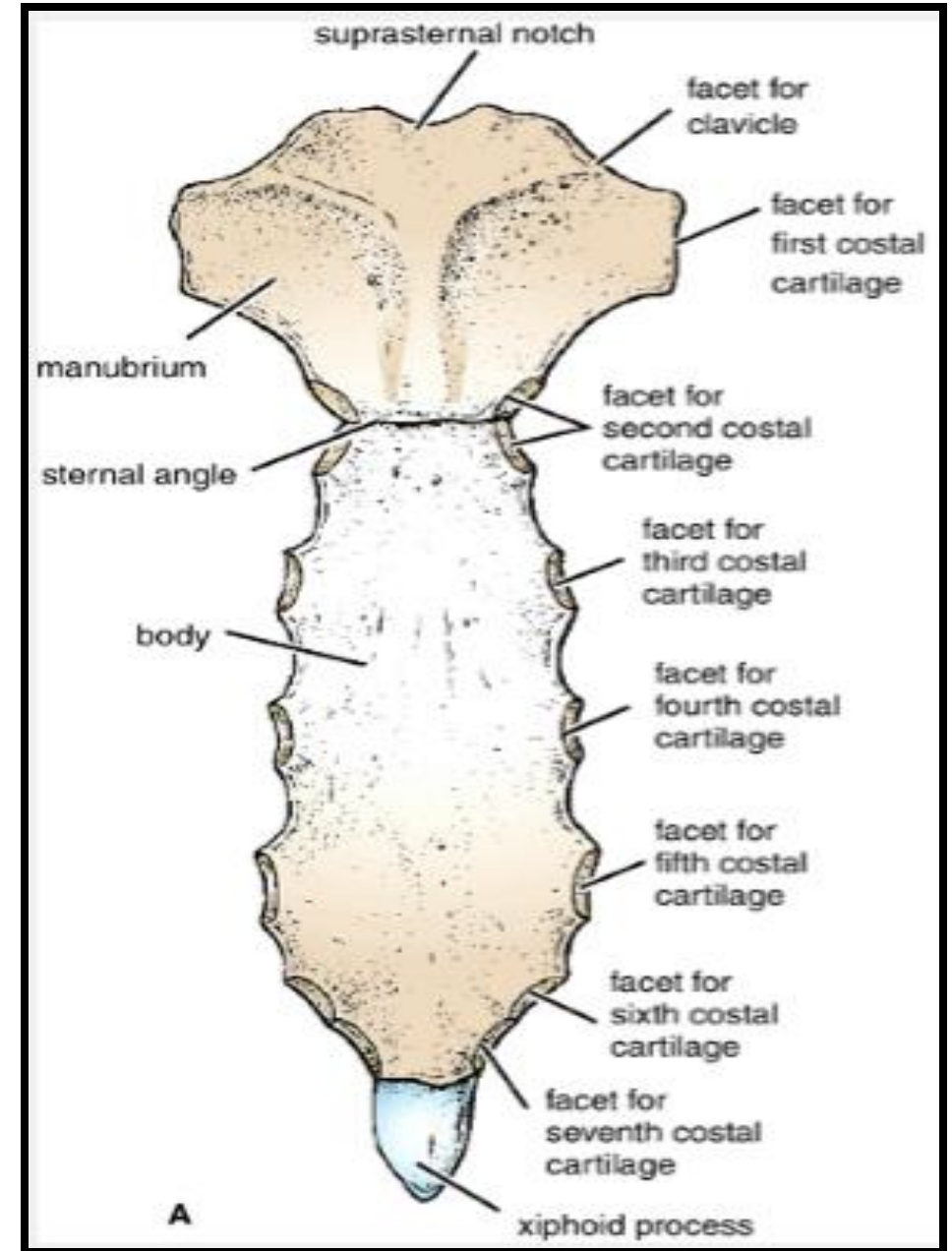


Thoracic Cage

Sternum

lies in the midline of the anterior chest wall.

It is a flat bone that can be divided into three parts: manubrium sterni, body of the sternum, and xiphoid process.

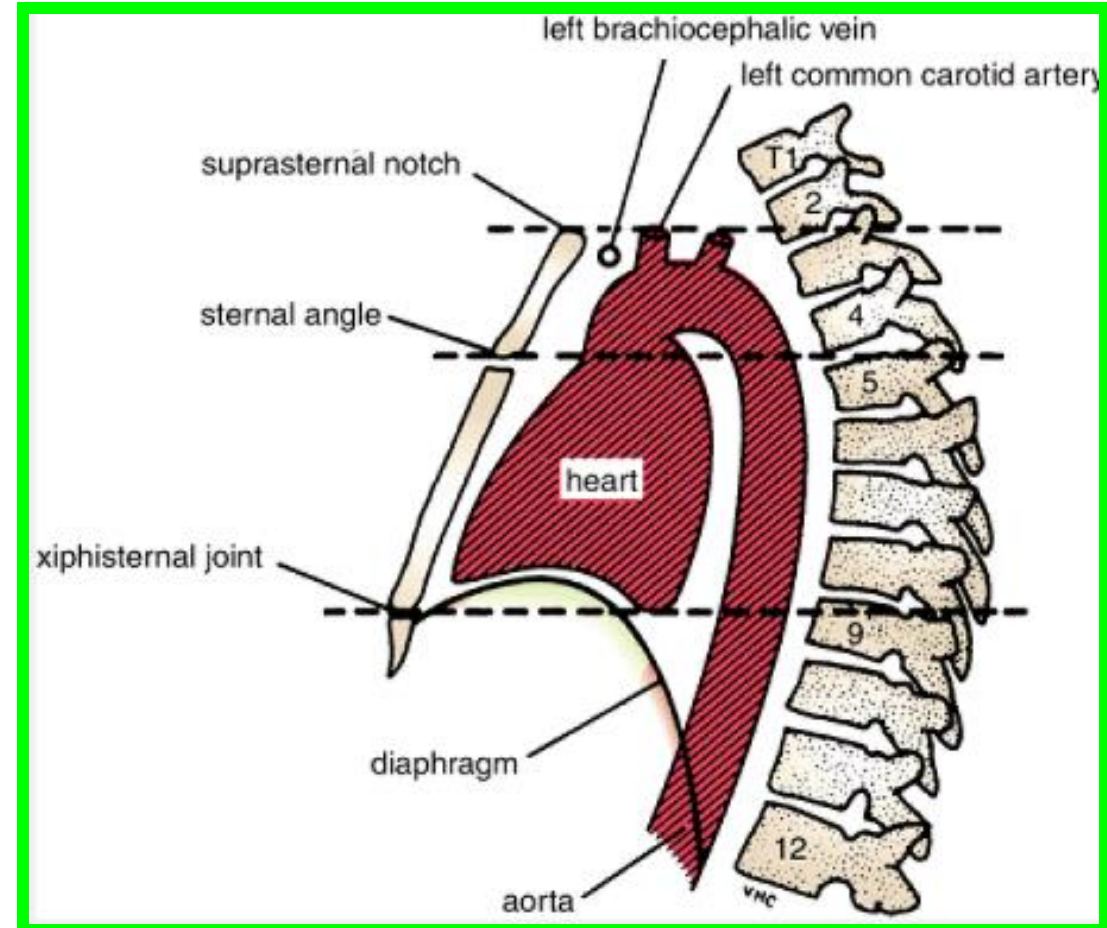


Sternum

The manubrium is the upper part of the sternum.

✓ It articulates with the body of the sternum at the **manubriosternal joint**,

✓ and articulates with the **clavicles** and with **the first costal cartilage** and the upper part of **the second costal cartilages** on each side



✓ It lies opposite the **third and fourth thoracic vertebrae**

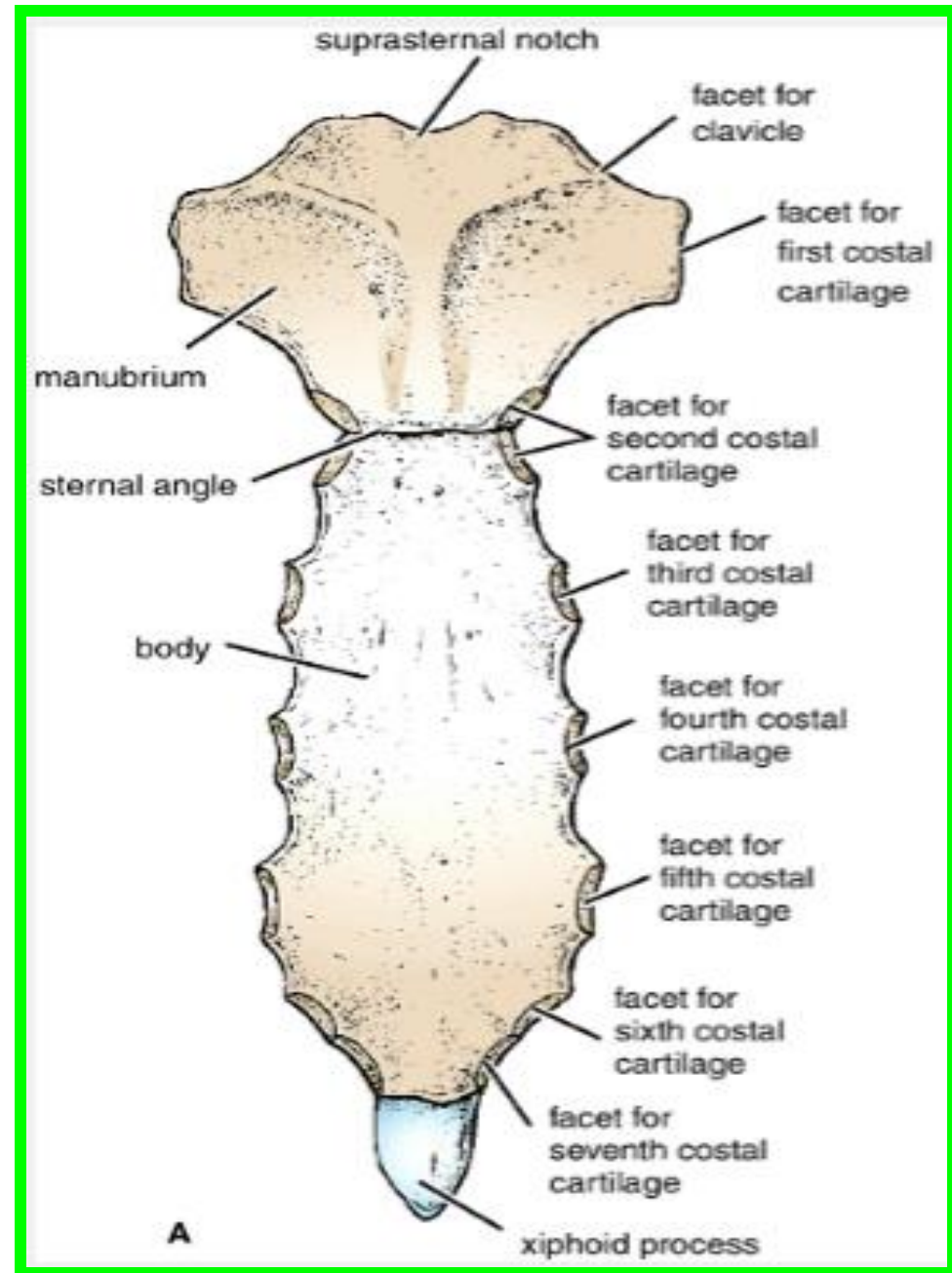
Sternum

The body of the sternum

Articulates above with the manubrium at the manubriosternal joint

And below with the xiphoid process at the xiphisternal joint.

On each side it articulates with the second to the seventh costal cartilages

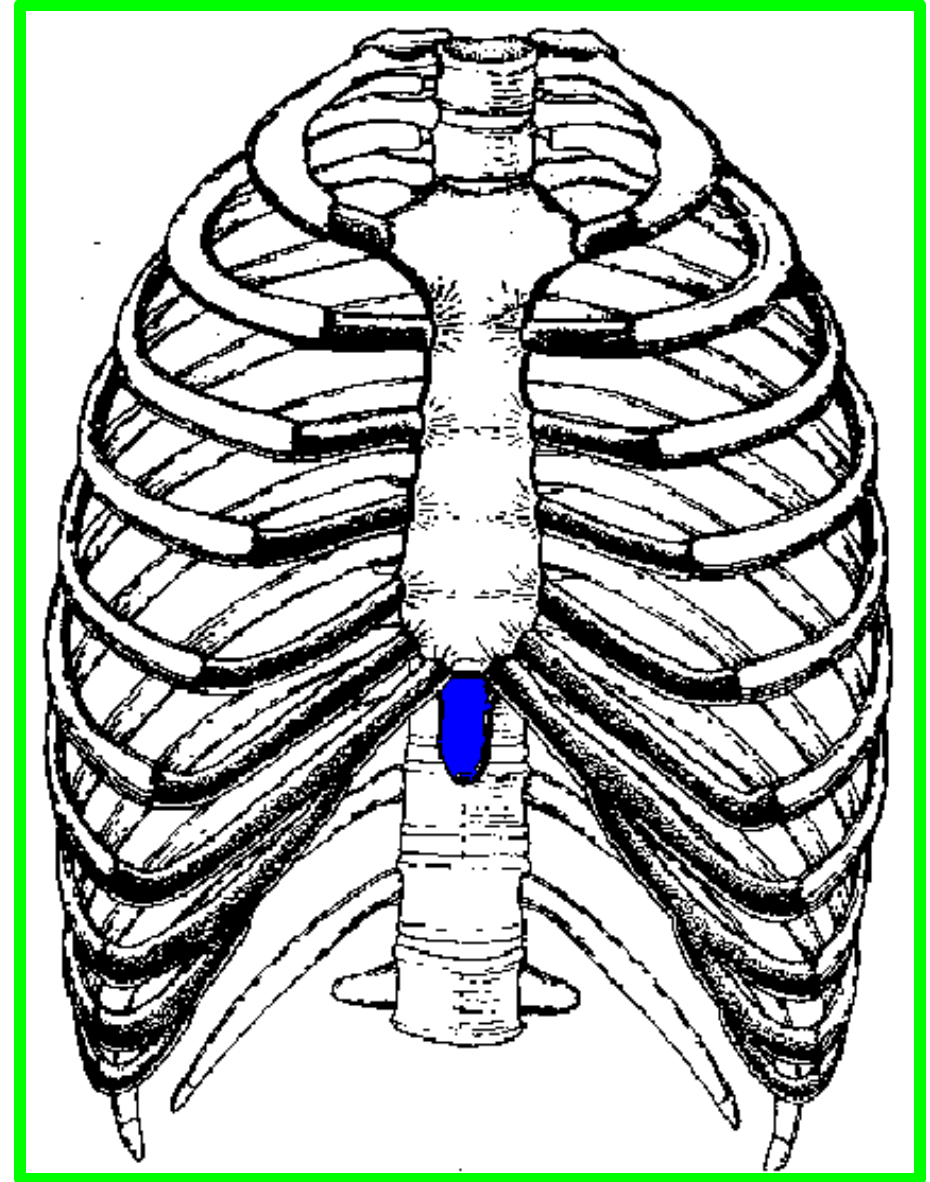


Sternum

The xiphoid process

Is a thin plate of cartilage that becomes ossified at its proximal end during adult life.

No ribs or costal cartilages are attached to it.

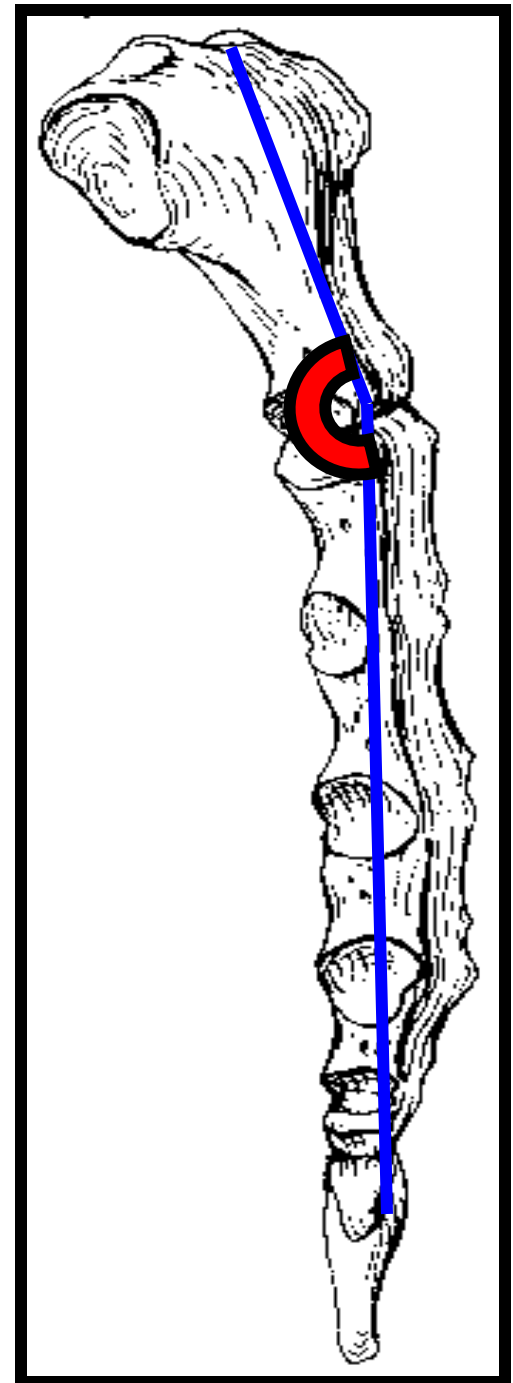


Sternum

The sternal angle (angle of Louis).
formed by the articulation of the manubrium with the body of the sternum,

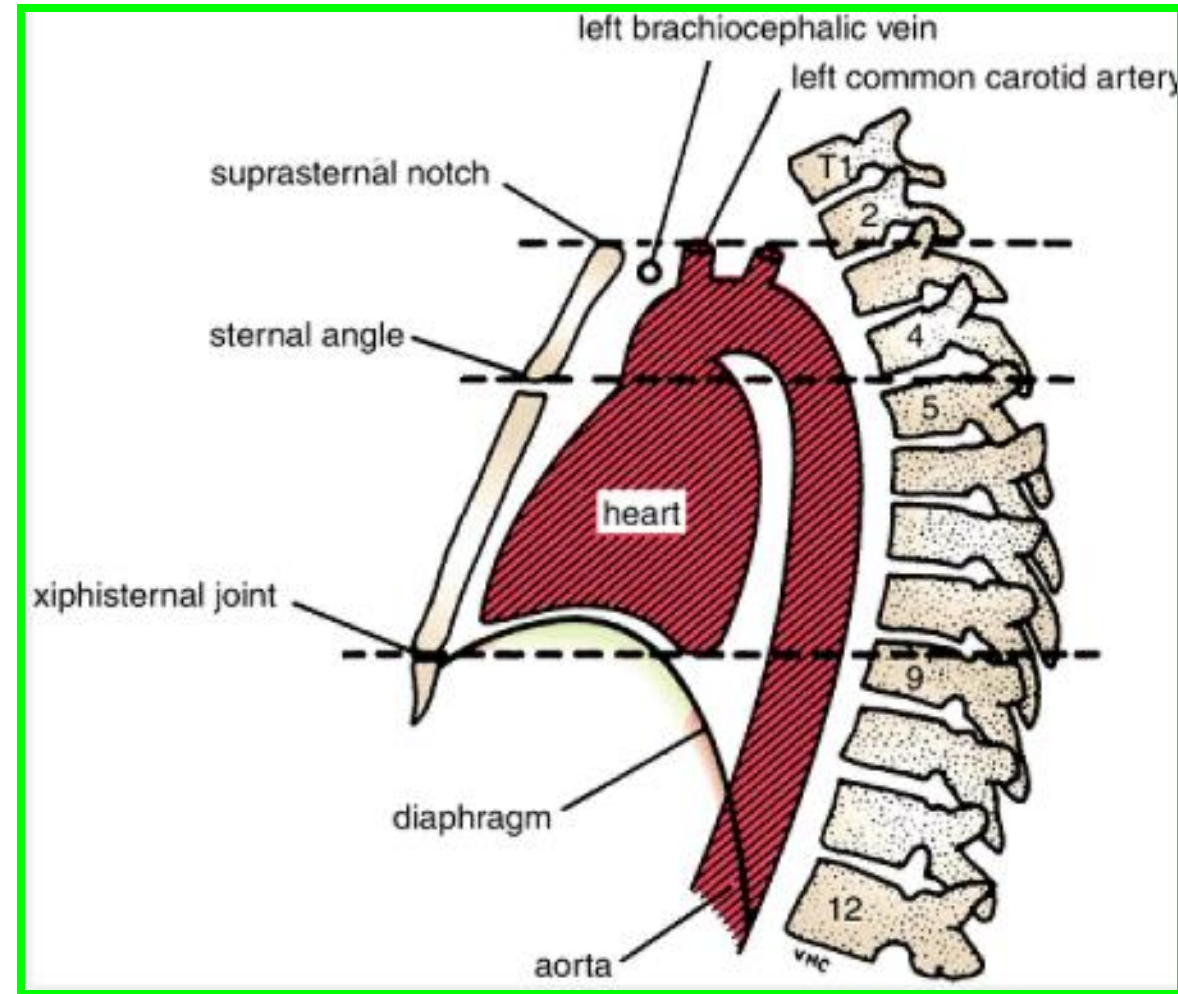
The transverse ridge lies at the level of the second costal cartilage.

❖ **The point from which all costal cartilages and ribs are counted.**



Sternum

The sternal angle lies opposite the intervertebral disc between the **fourth and fifth thoracic vertebrae**.



□ **The xiphisternal joint** lies opposite the body of the **ninth thoracic vertebra**

Sternum

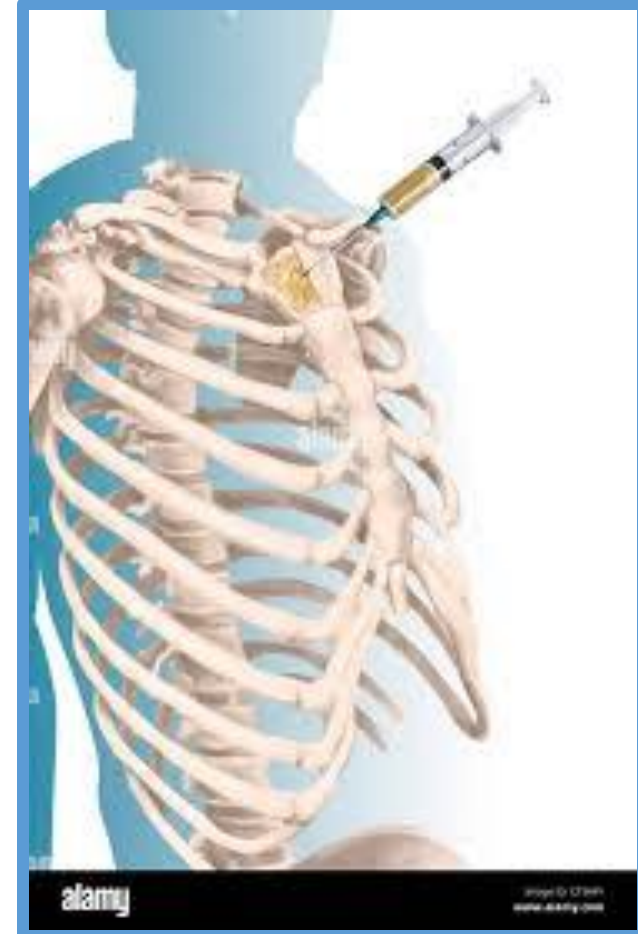Thoracic Cage

Sternal Biopsy

The sternal body is often used for bone marrow needle biopsy because of its **breadth and subcutaneous position** .

The needle pierces the thin cortical bone and enters the vascular spongy bone .

Sternal biopsy is commonly used to obtain specimens of marrow **for transplantation** and for **detection of metastatic cancer and blood dyscrasias (abnormalities)**

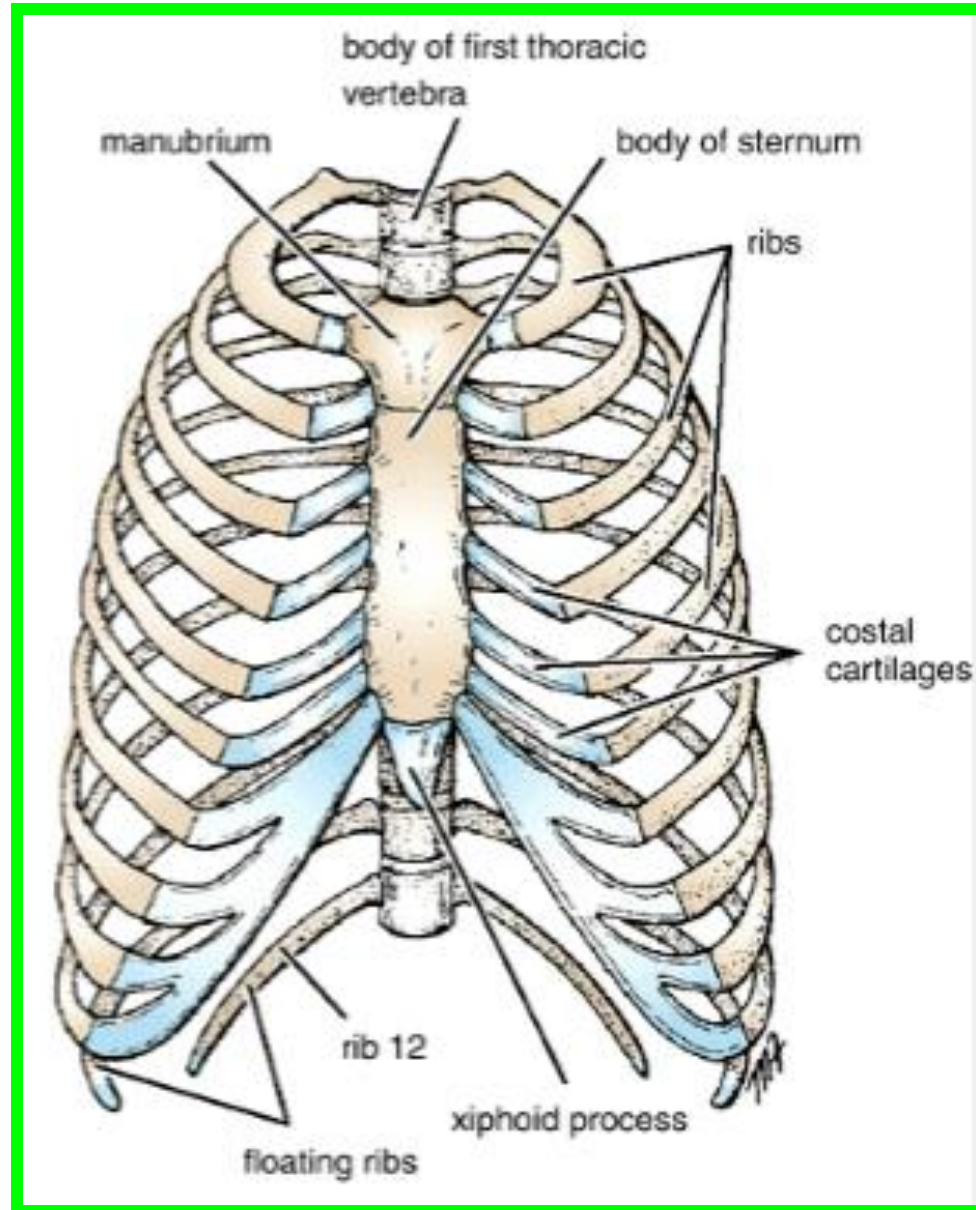


Thoracic Cage

Ribs

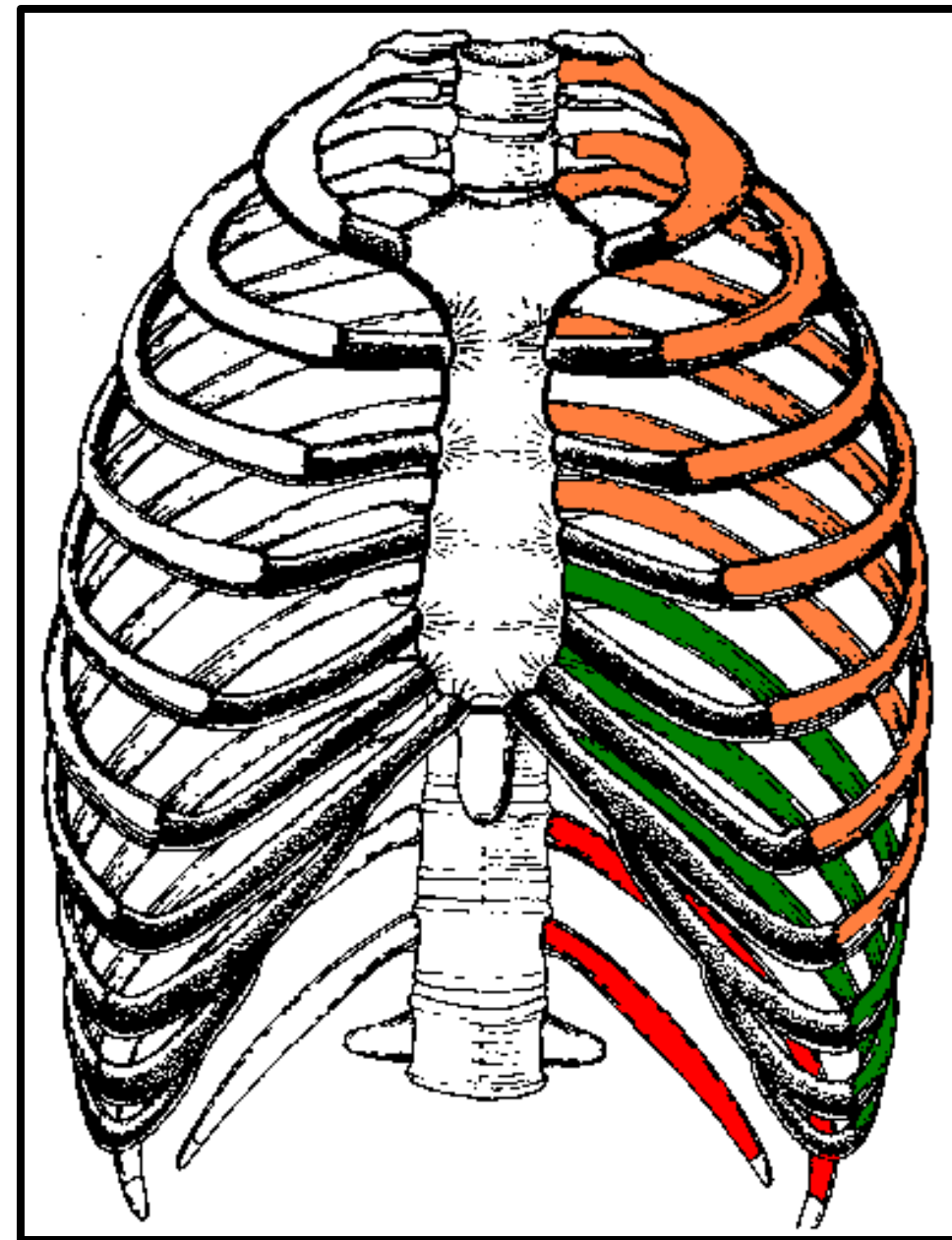
There are **12 pairs** of ribs, all of which are attached posteriorly to the thoracic vertebrae

The ribs are divided into three categories:



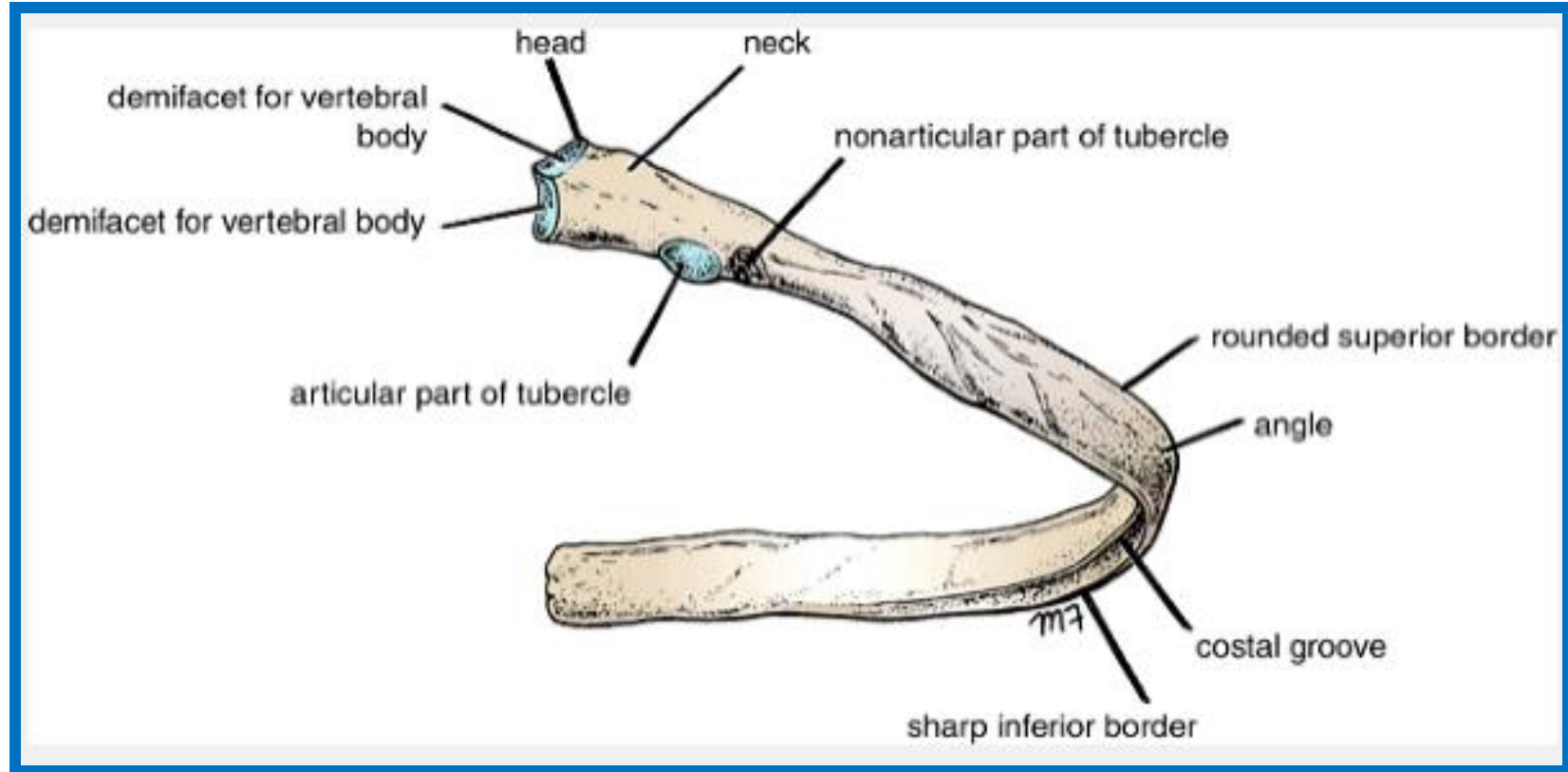
Thoracic Cage

- ❖ **True ribs:** The **upper seven** pairs are attached anteriorly to the sternum by their **costal cartilages**.
- ❖ **False ribs:** The **8th, 9th, and 10th** pairs of ribs are attached anteriorly to each other and to the **7th rib** by means of their costal cartilages and small synovial joints.
- ❖ **Floating ribs:** The **11th and 12th** pairs have no anterior attachment



□ Typical Rib

A typical rib is a long, twisted, flat bone having a rounded, smooth superior border and a sharp, thin inferior border. The inferior border overhangs and forms **the costal groove**, which accommodates **the intercostal vessels and nerve**. The anterior end of each rib is attached to **the corresponding costal cartilage**.



□ Typical Rib

The typical rib has a head, neck, tubercle, shaft, and angle.

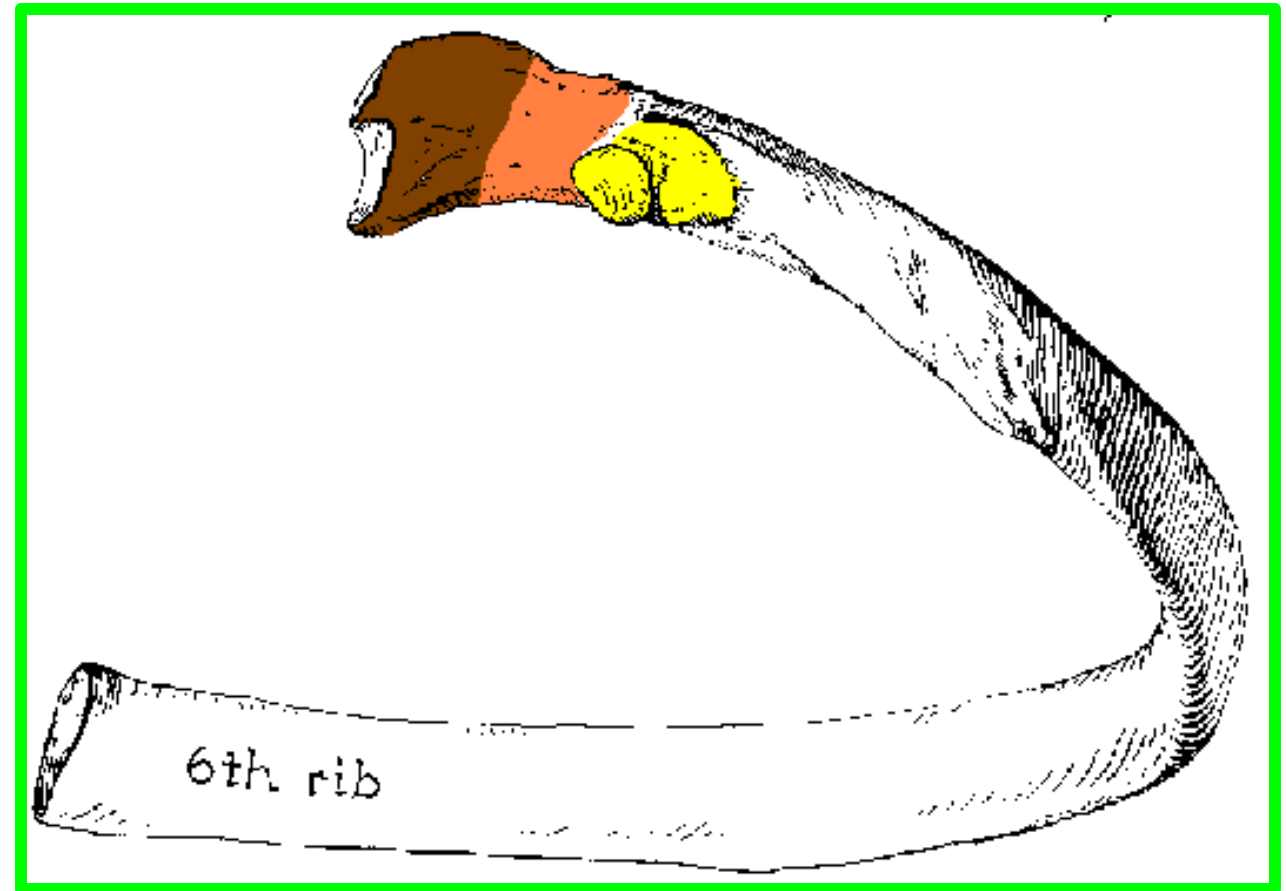
The neck is a constricted portion situated between the head and the tubercle.

❖ head

❖ neck

❖ tubercle

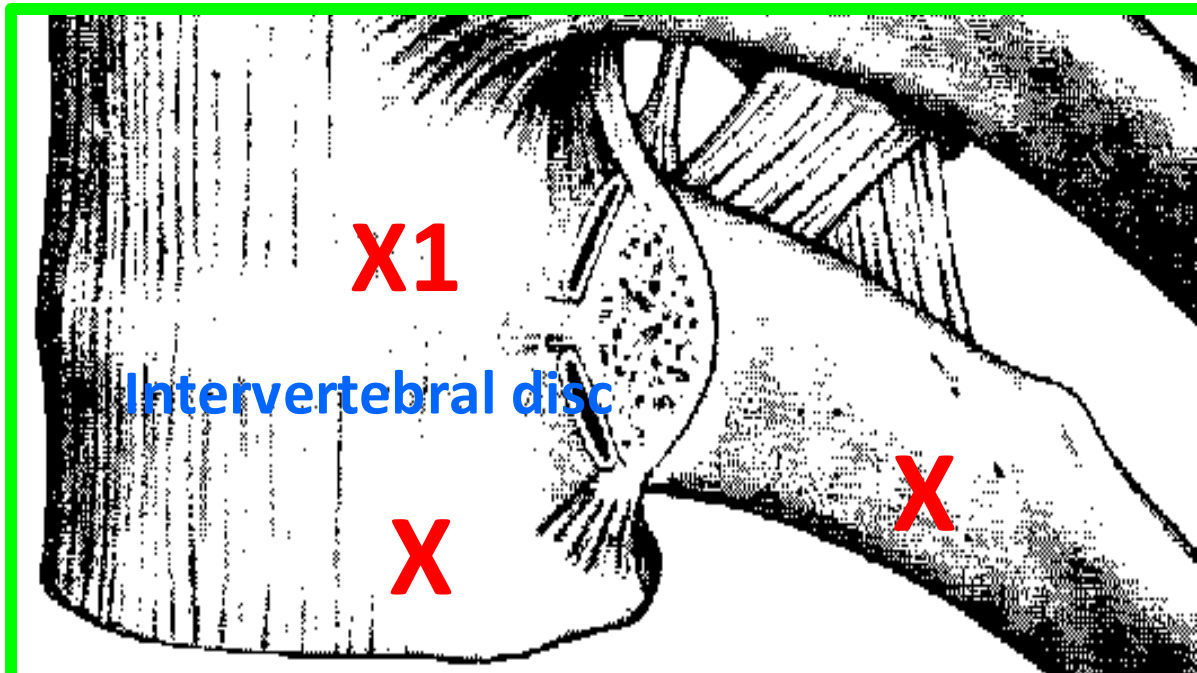
❖ and a shaft



❖ *The head of the typical rib*

- ❖ is the posterior end of the rib
- ❖ is wedge-shaped
- ❖ carries two articular facets

The head has **two facets** for articulation with the numerically corresponding vertebral body and that of the vertebra immediately above .

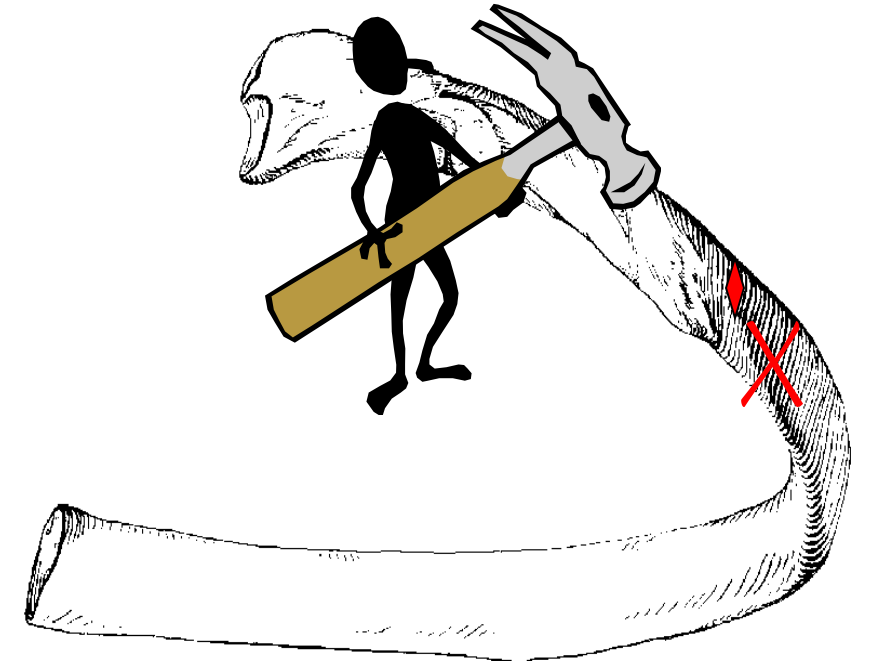
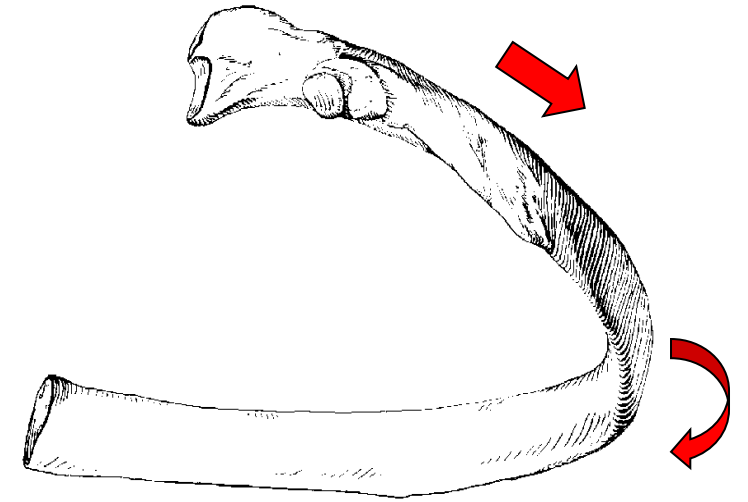


❖ The shaft

- ❖ Is lateral to the tubercle
- ❖ primarily it is directed posteriorly
- ❖ then it bends sharply anteriorly

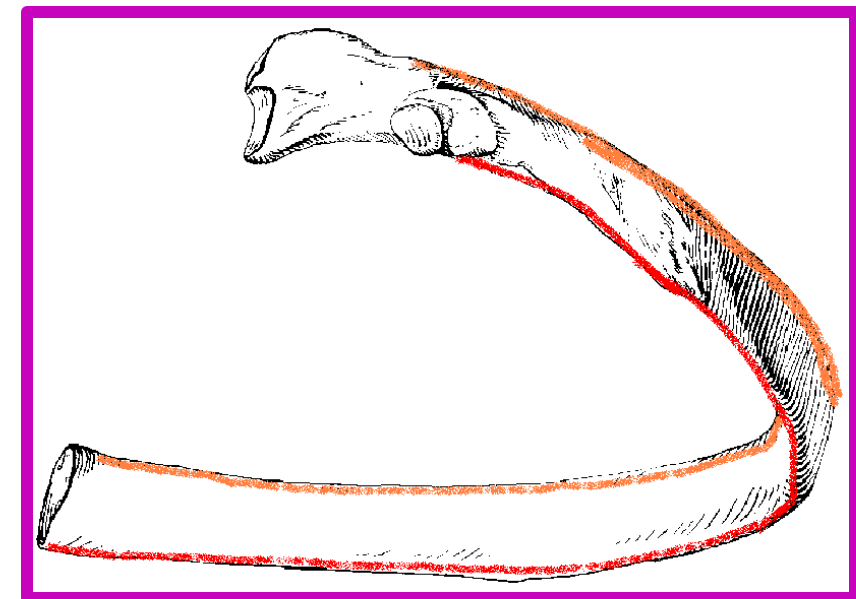
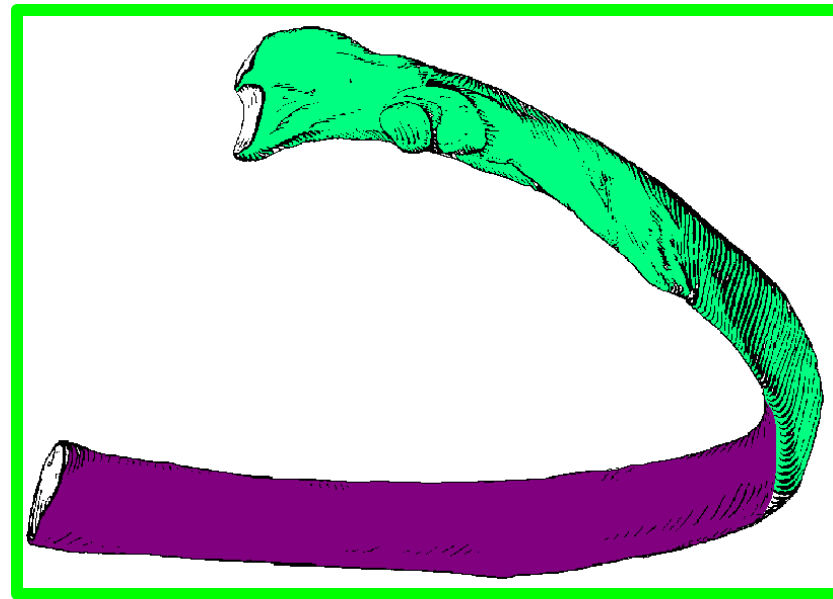
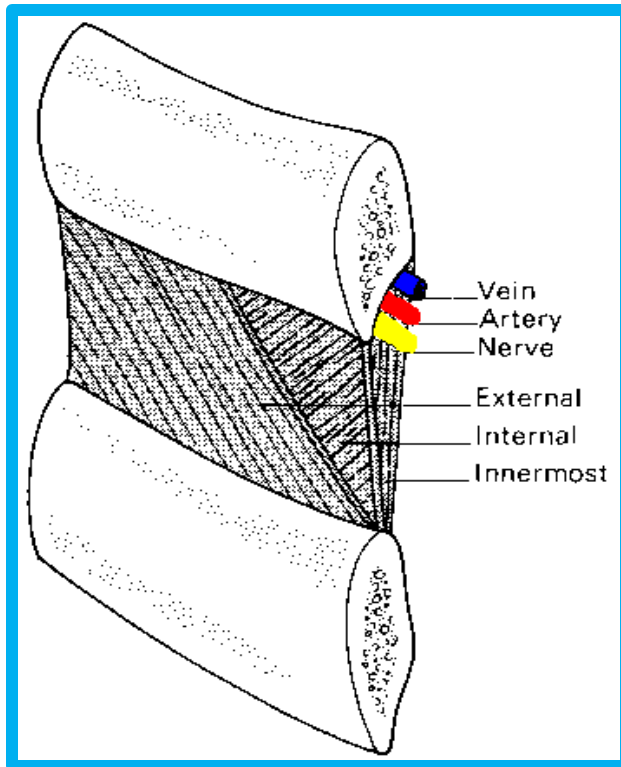
❖ The angle

- ❖ The point of greatest change in curvature is :
- ❖ The angle of a rib is its **weakest part** where it tends to fracture.



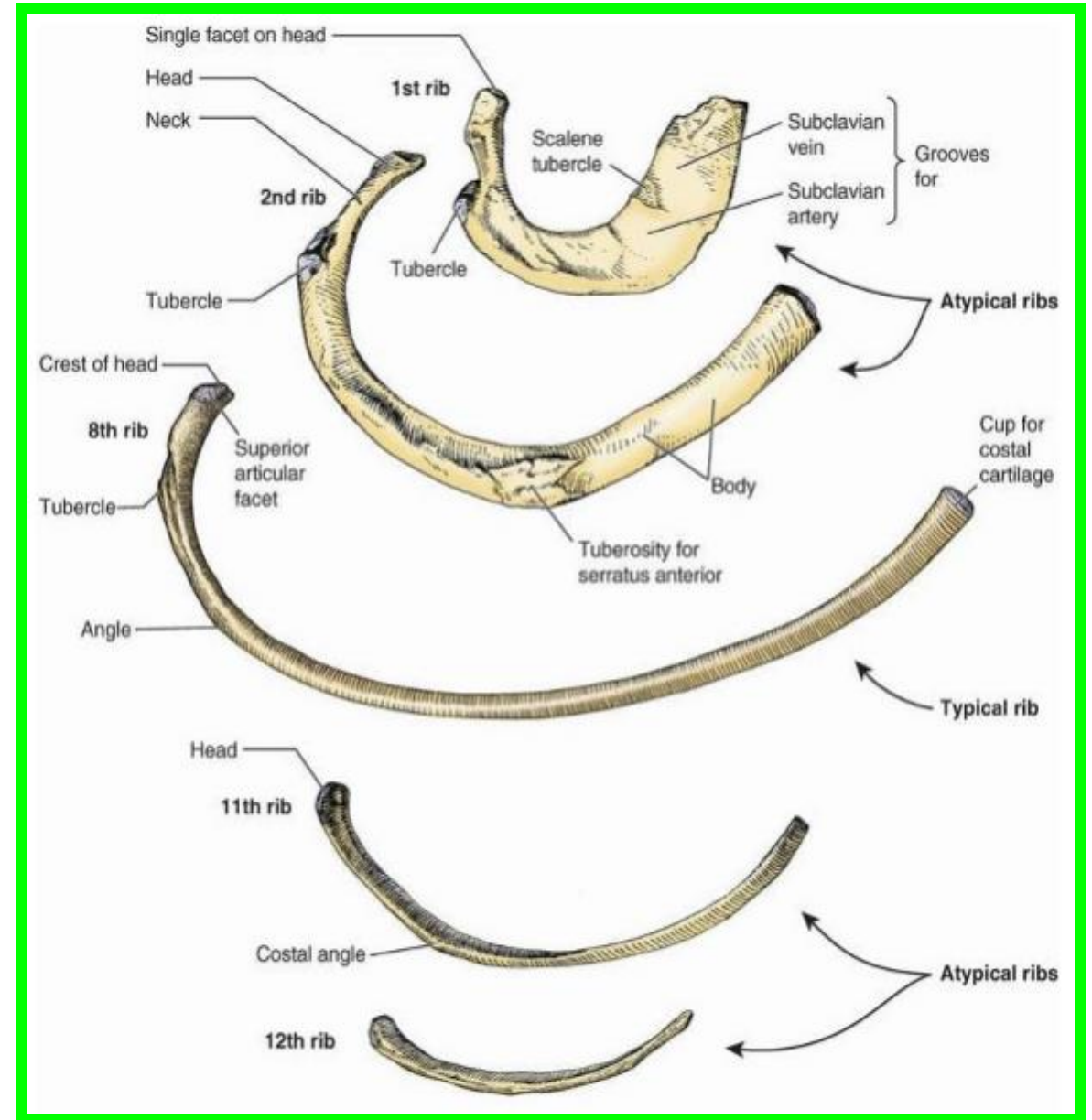
Typical ribs (3-10) Have

- **External** and **Internal** surfaces
- **Superior** and **Inferior** borders
- The inferior border is sharp and extends inferior to **the costal groove** on the internal surface of the shaft so that it protects the:
- **intercostal neurovascular bundle** located in **the costal groove**.




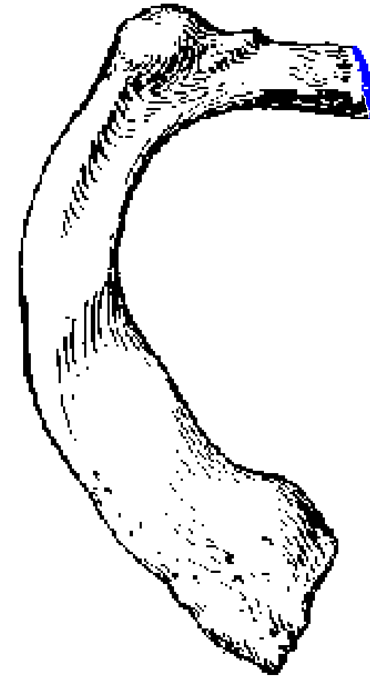
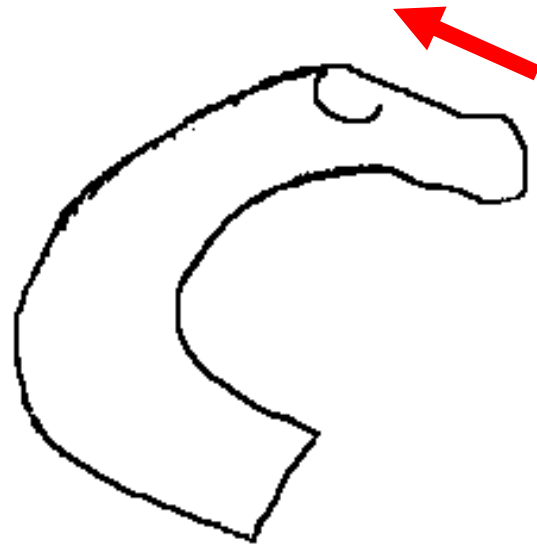
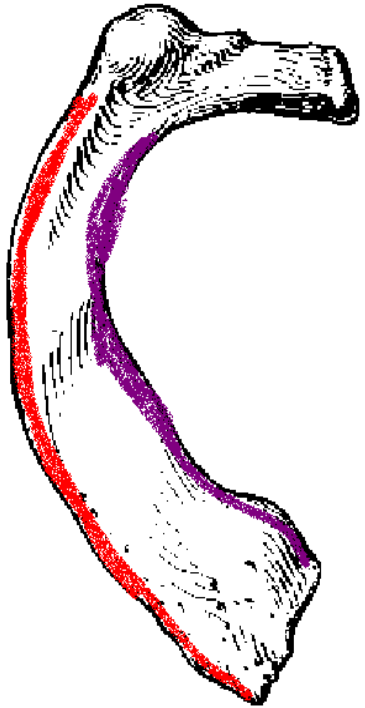
❑ Atypical ribs

(1st, 2nd, and 11th-12th)
are dissimilar :



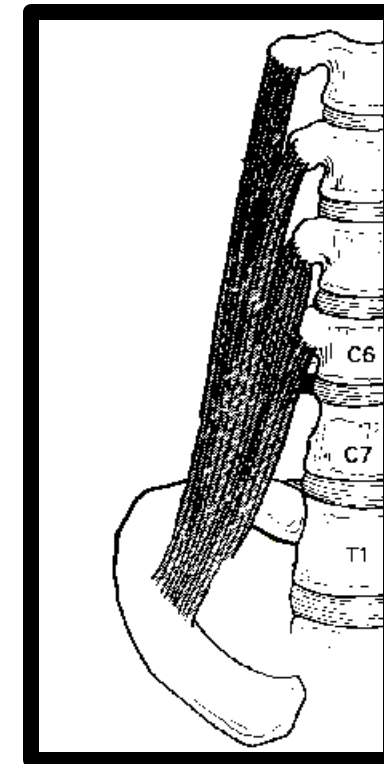
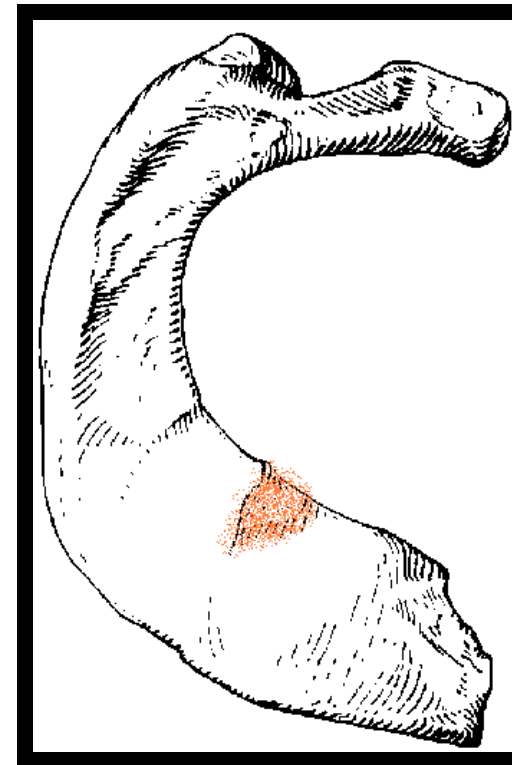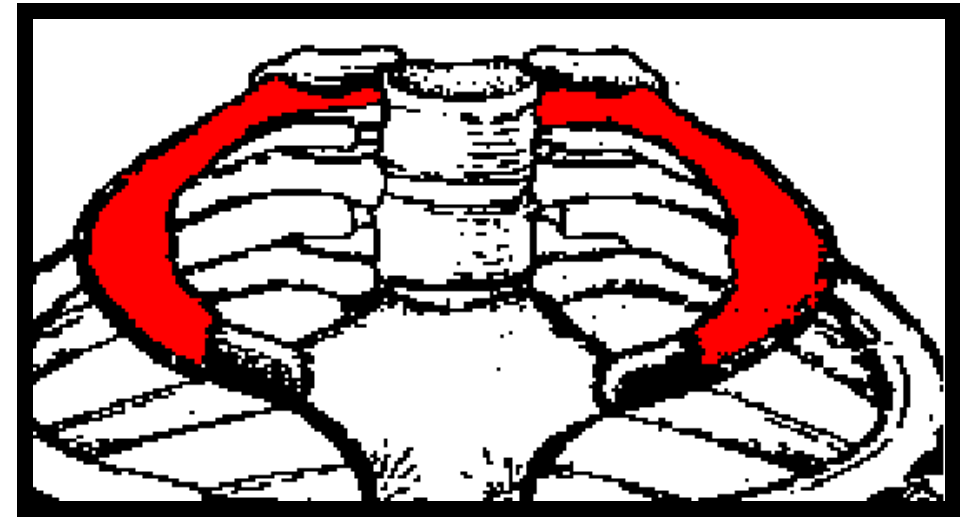
The first rib

- ❖ is the broadest and most curved rib
- ❖ Its head carries a single facet for articulation with the body of T1 vertebra
- ❖ The neck slopes up from the head towards the shaft
- ❖ The shaft has inner and outer borders



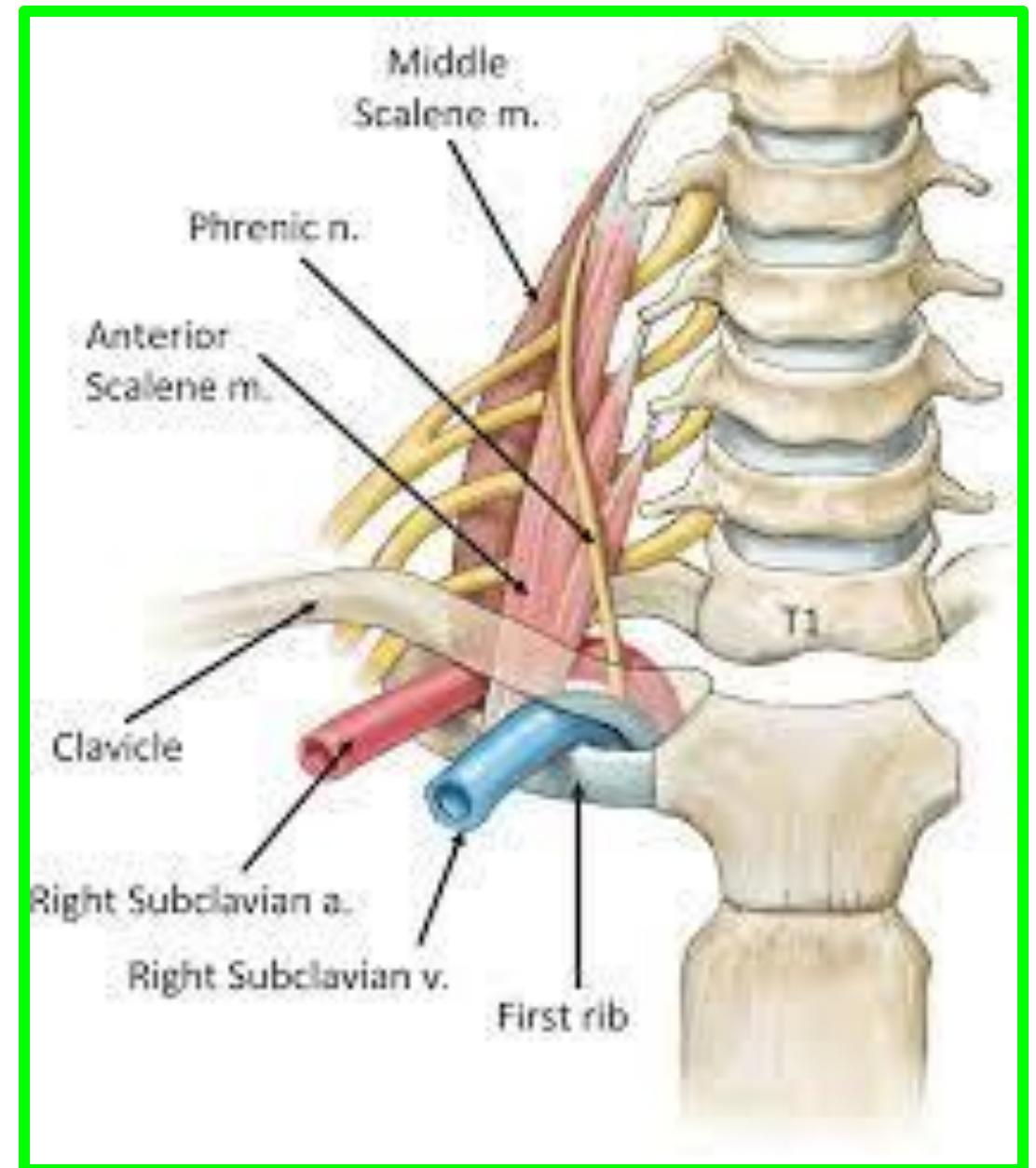
The first rib

- ❖ The shaft has **superior** and **inferior** surfaces
- ❖ The superior surface carries a prominent **scalene tubercle** on its inner border for the insertion of **scalenus anterior muscle**

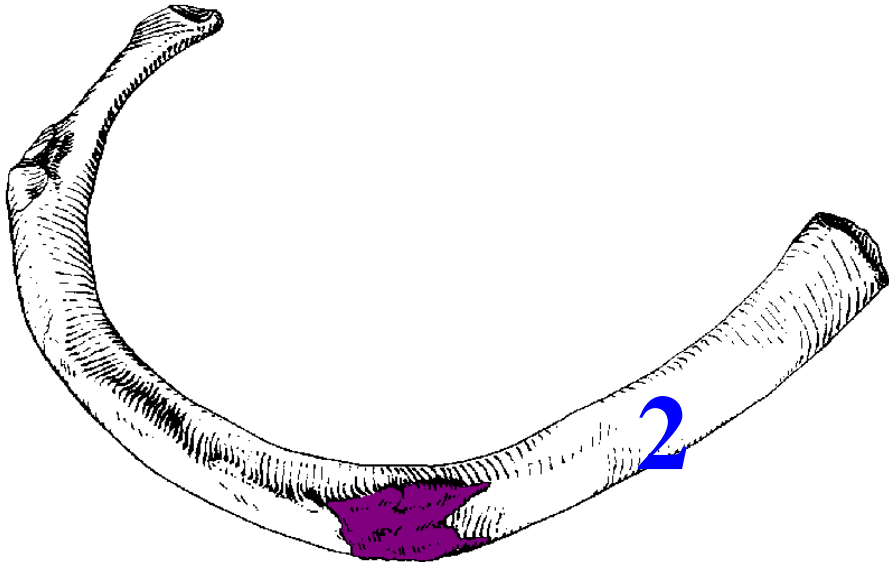
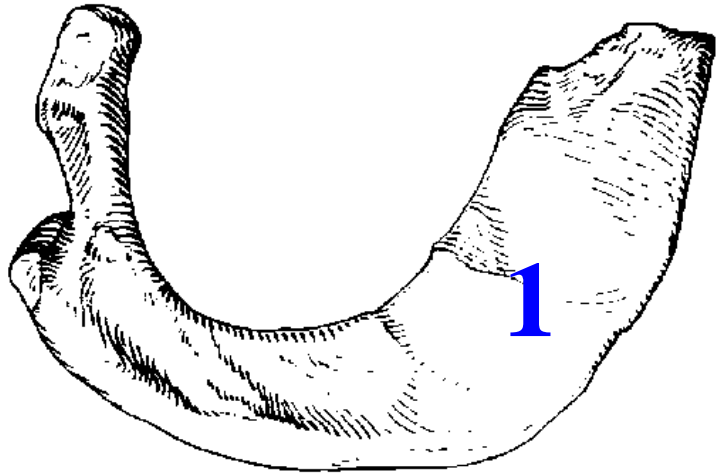


The first rib

- ❖ The **subclavian vein** crosses anterior to **scalene tubercle**,
- ❖ while the **subclavian artery** and the **inferior trunk of the brachial plexus** pass posterior to it



The second rib

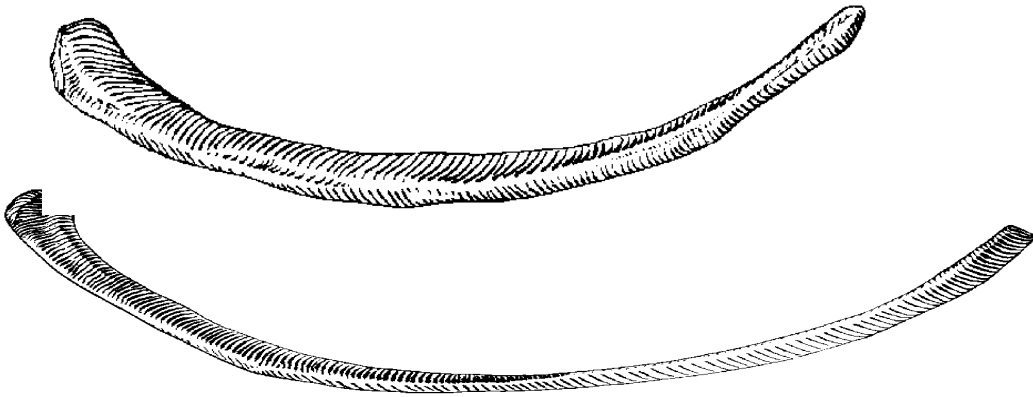


- ❖ Is longer than the first rib
- ❖ is characterized by the presence of a **tuberosity** for the attachment of serratus anterior muscle

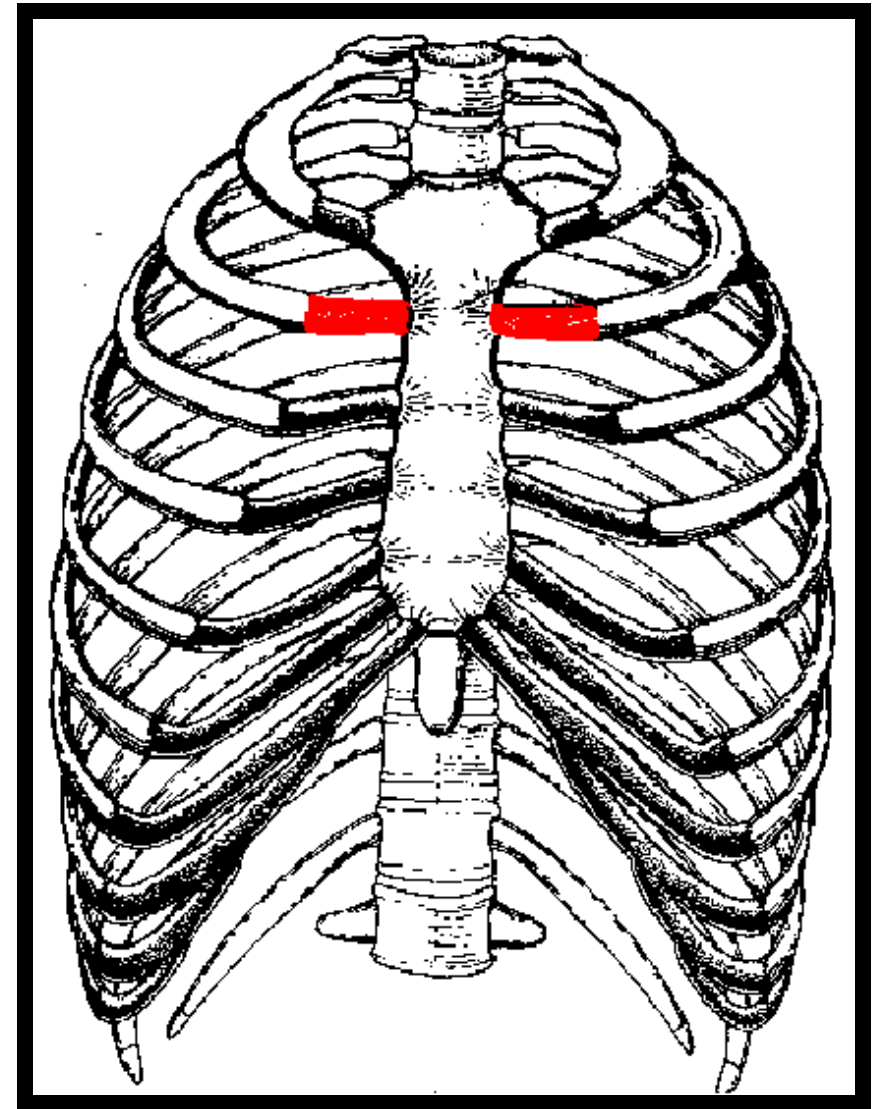
Sternal angle

- ❖ It is here that the **second costal cartilage** joins the sternum
- ❖ It is the starting place where the physician **counts the ribs** to use them as landmarks.

The 11th & 12th ribs



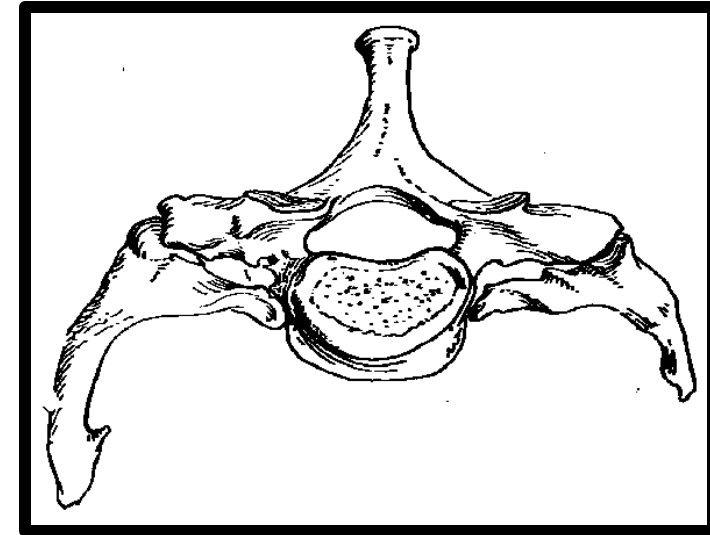
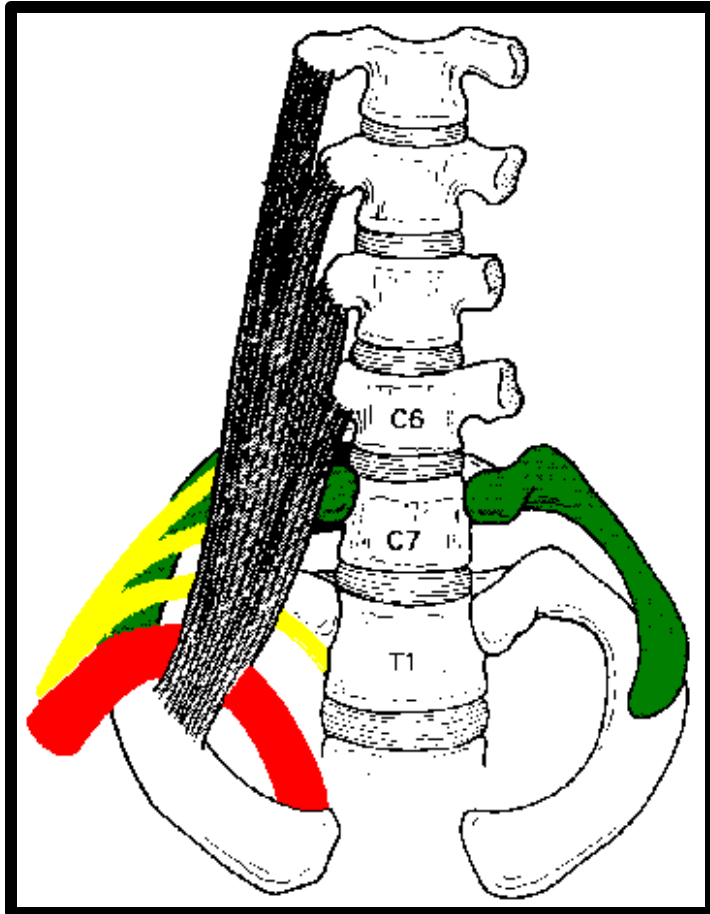
- ❖ are short and carry a single facet on the head
- ❖ **have neither neck nor tubercle**



Sunday 6 October 2024
Dr. Aiman Qais Afar

Cervical rib

- ❖ may articulate with the transverse process of **C7 vertebra** which is directed downward



- ❖ May be symptomless or may cause **neurovascular symptoms** in the upper limb due to **stretching or compression** related to structures on the superior surface of the first rib

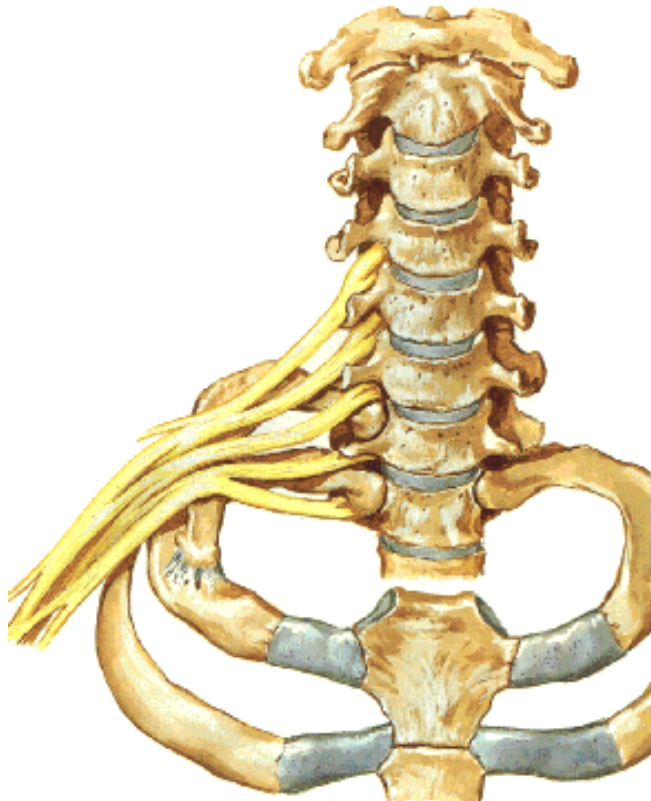
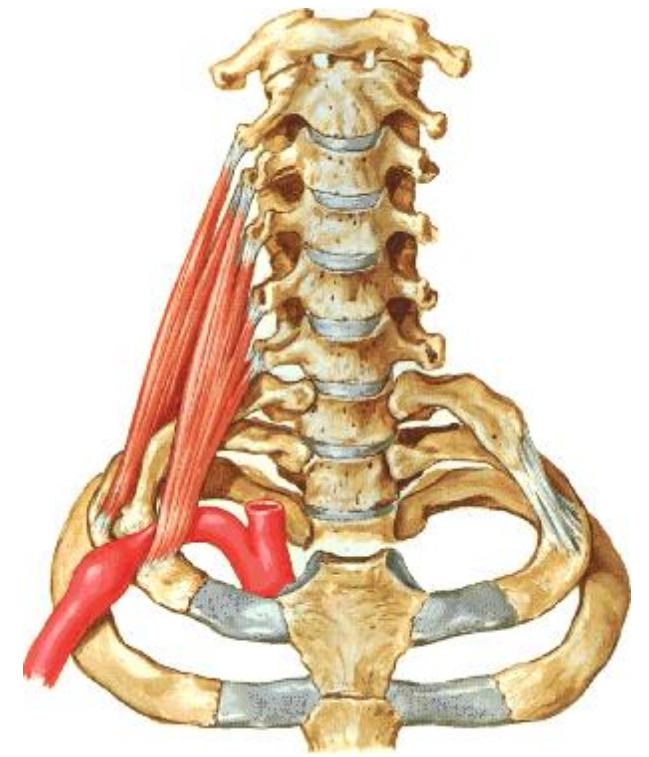
Cervical rib

❖ symptoms may be produced by compression

Vascular symptoms:

The cervical rib compresses the subclavian artery.

Note the poststenotic dilatation



❖ symptoms may be produced by stretching

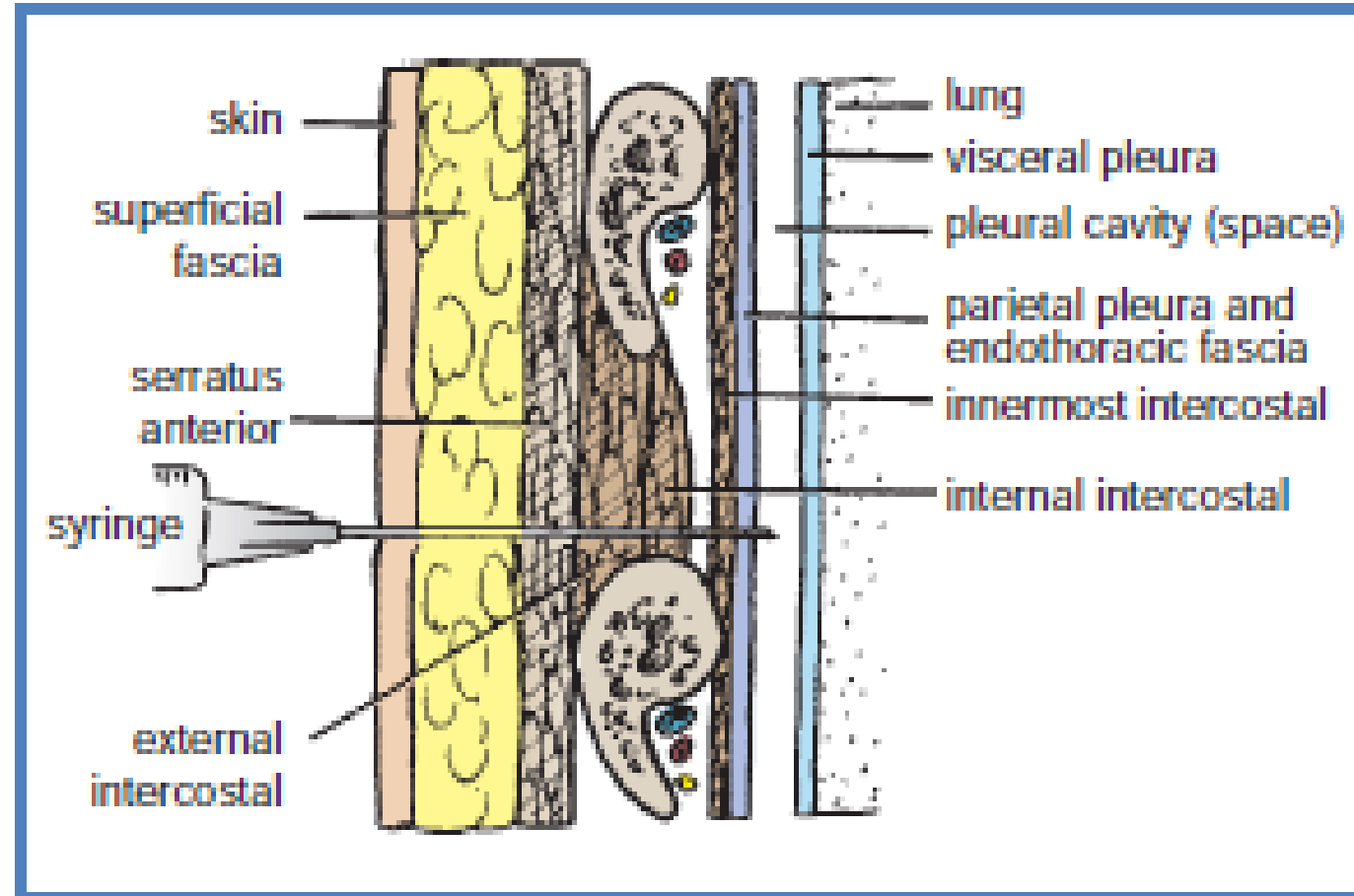
Neurological symptoms:

The cervical rib stretches the brachial plexus.

Intercostal Spaces

The spaces between the ribs contain three muscles of respiration: **the external intercostal**, the **internal intercostal**, and the **innermost intercostal muscle**.

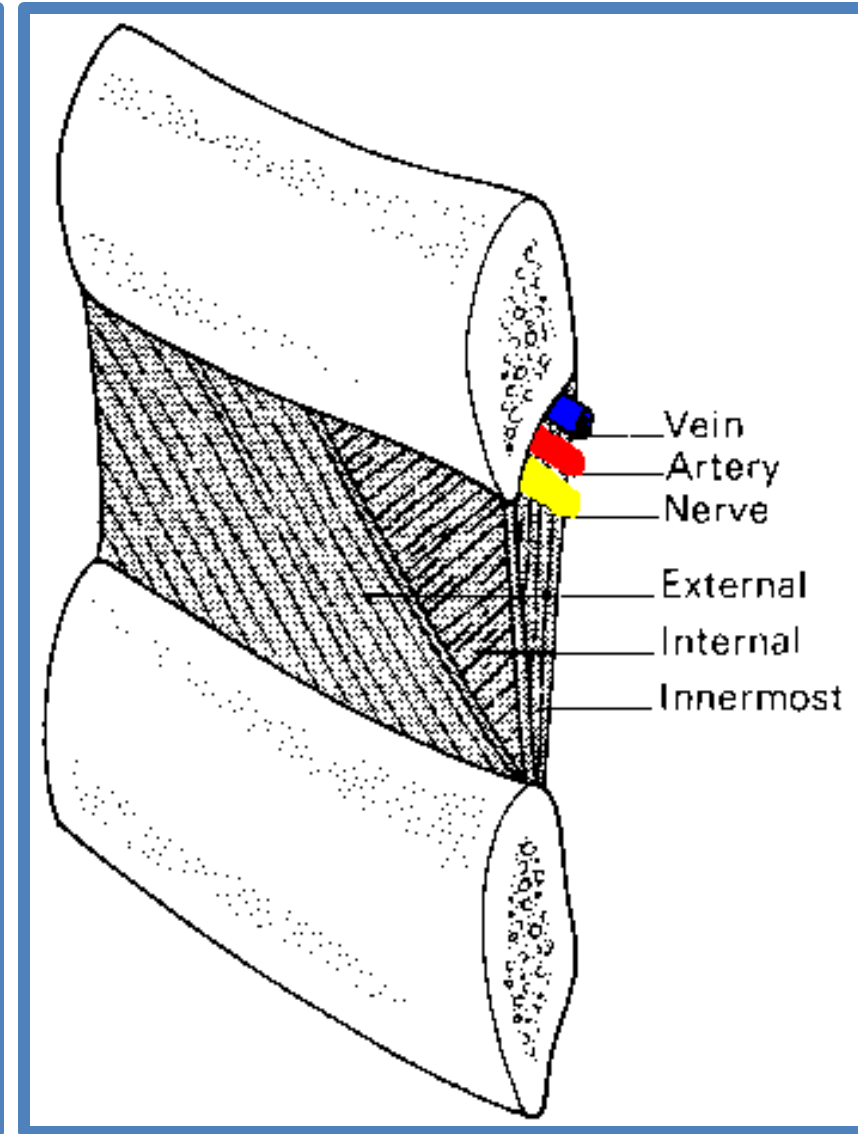

The innermost intercostal muscle is lined internally by the **endothoracic fascia**, which is lined internally by the **parietal pleura**.



Intercostal Spaces

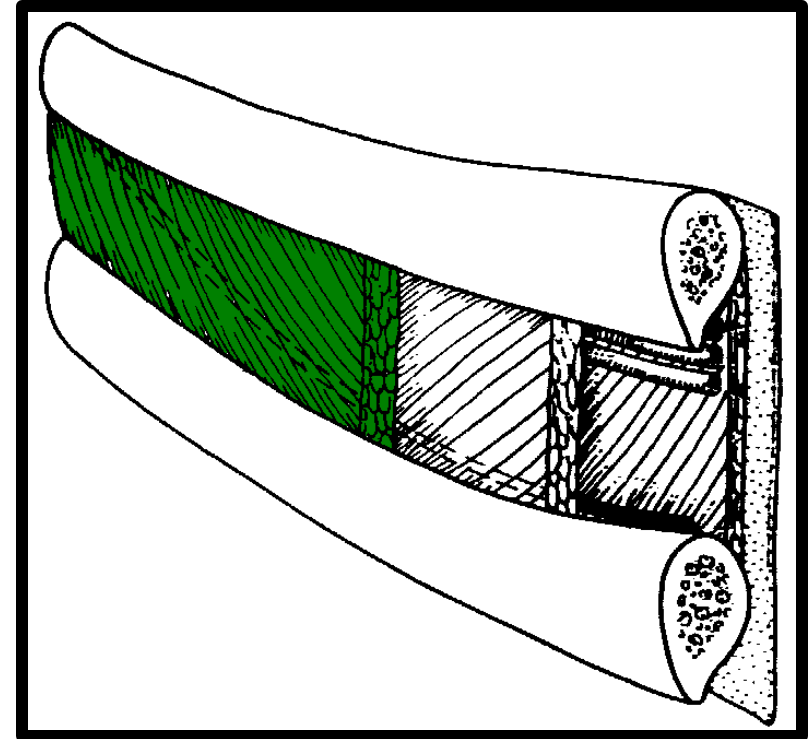
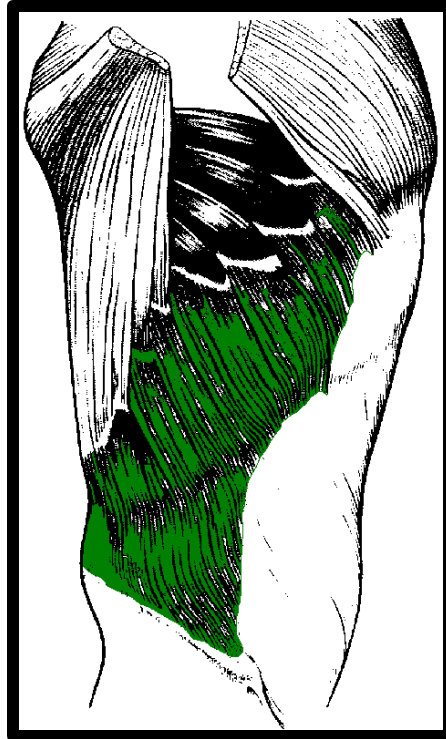
The intercostal nerves and blood vessels run between the **intermediate** and **deepest layers** of muscles

They are arranged in the following order from above downward:
intercostal vein, **intercostal artery**,
and **intercostal nerve** (i.e., **VAN**).



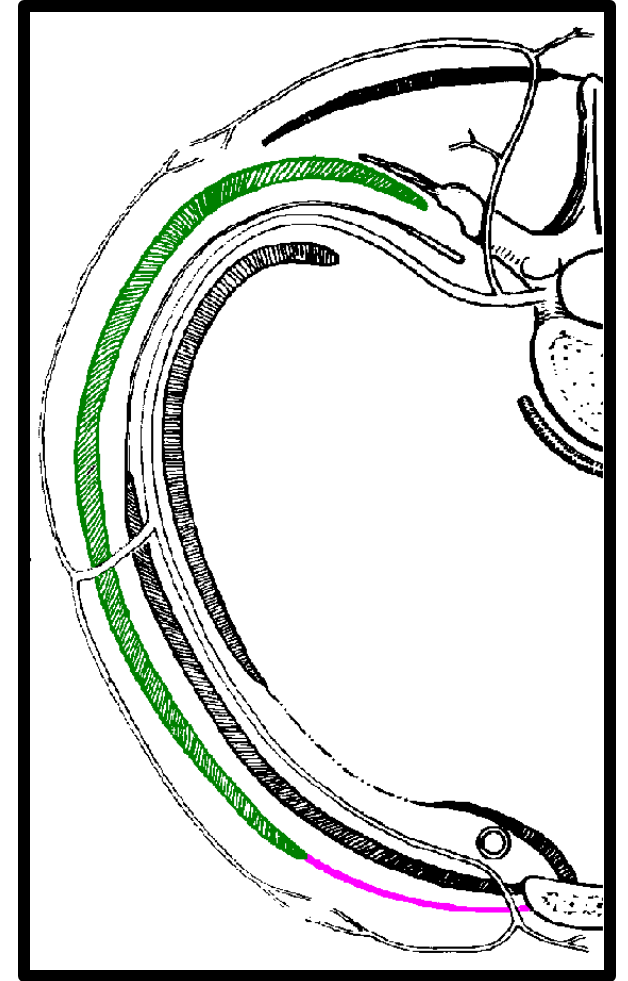
External intercostal

- ❖ forms the most superficial layer
- ❖ Its fibers are directed downwards and forward (same direction of external oblique muscle of the abdomen)
- ❖ from the inferior border of the rib above to the superior border of the rib below



❖ **The external intercostal muscle** extends from the **rib tubercle** behind to the **costochondral junction** in front

❖ Anteriorly the **external intercostal muscle** is replaced by an aponeurosis (thin flat tendon), the **anterior (external) intercostal membrane**

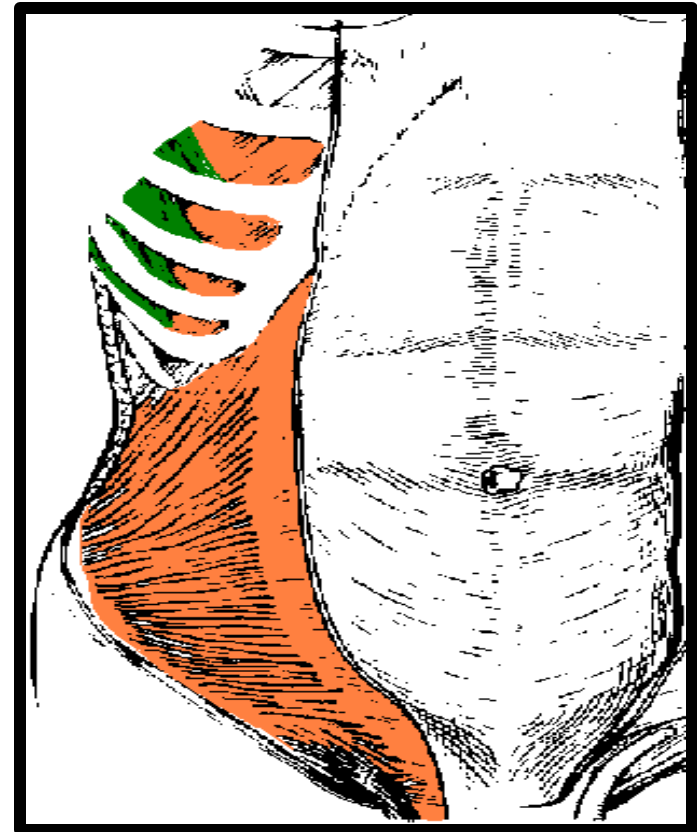
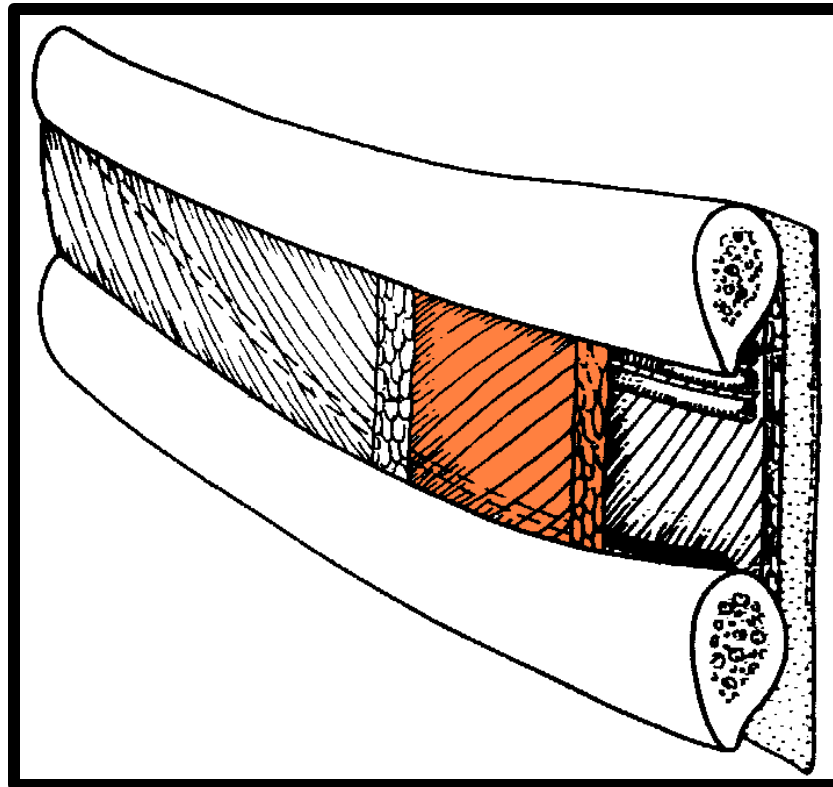


Internal intercostal

Dr. Aiman Qais Afar
Sunday 6 October 2024

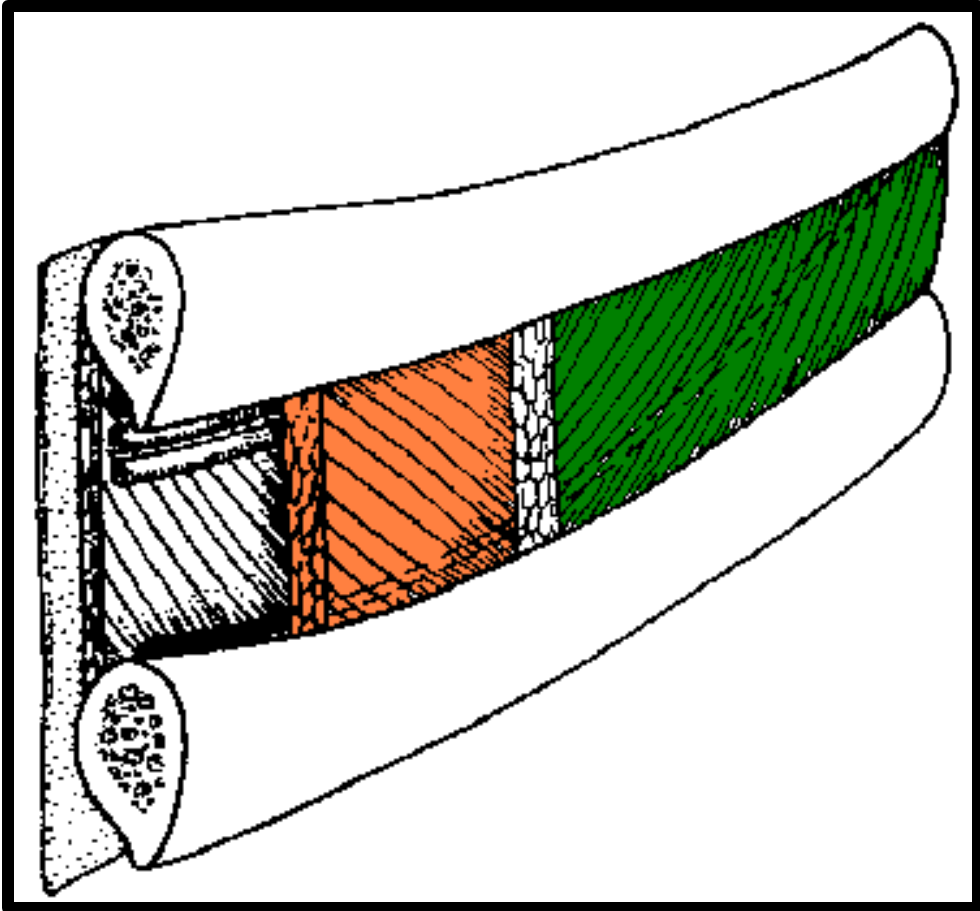
30

- ❖ forms the intermediate layer
- ❖ Its fibers are directed downwards and backwards (same direction of the internal oblique muscle of the)
- ❖ Extends from the costal groove of the rib above to the upper border of the rib below



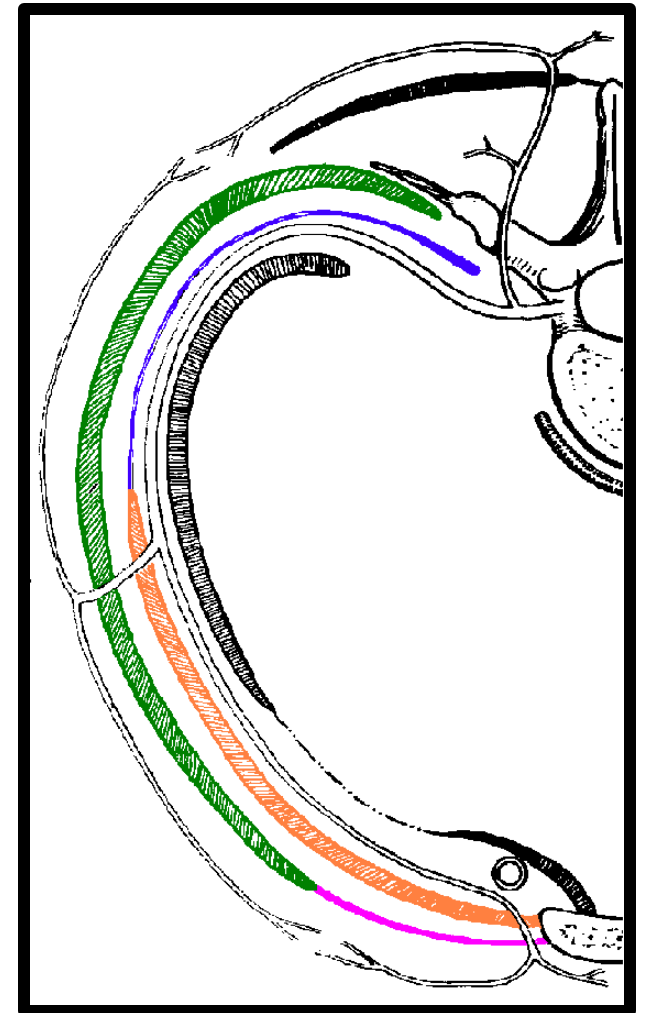
Internal intercostal

- ❖ the fibers of the **internal intercostal** are therefore at right angles to those of the **external intercostal**



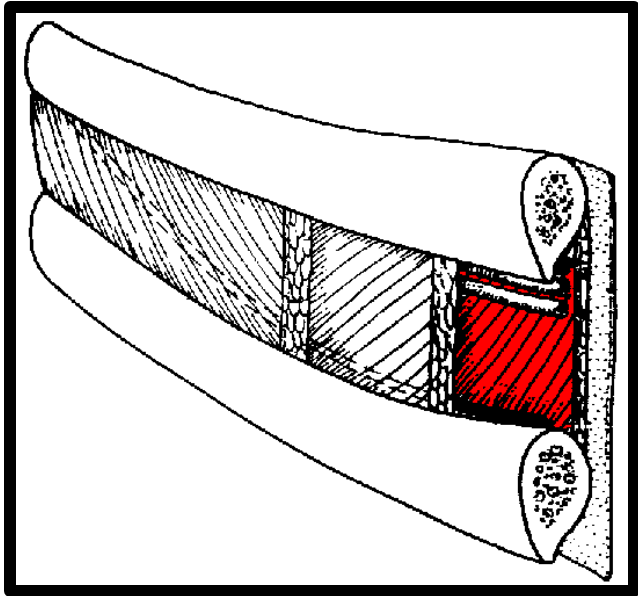
Internal intercostal

- ❖ The **internal intercostal** extends from the side of the sternum in front to the angles of the ribs behind
- ❖ The **internal intercostal** muscle is replaced by an aponeurosis, the **posterior (internal) intercostal membrane**




Innermost intercostal

- ❖ Extends between internal surfaces of adjacent ribs.



Innermost intercostal

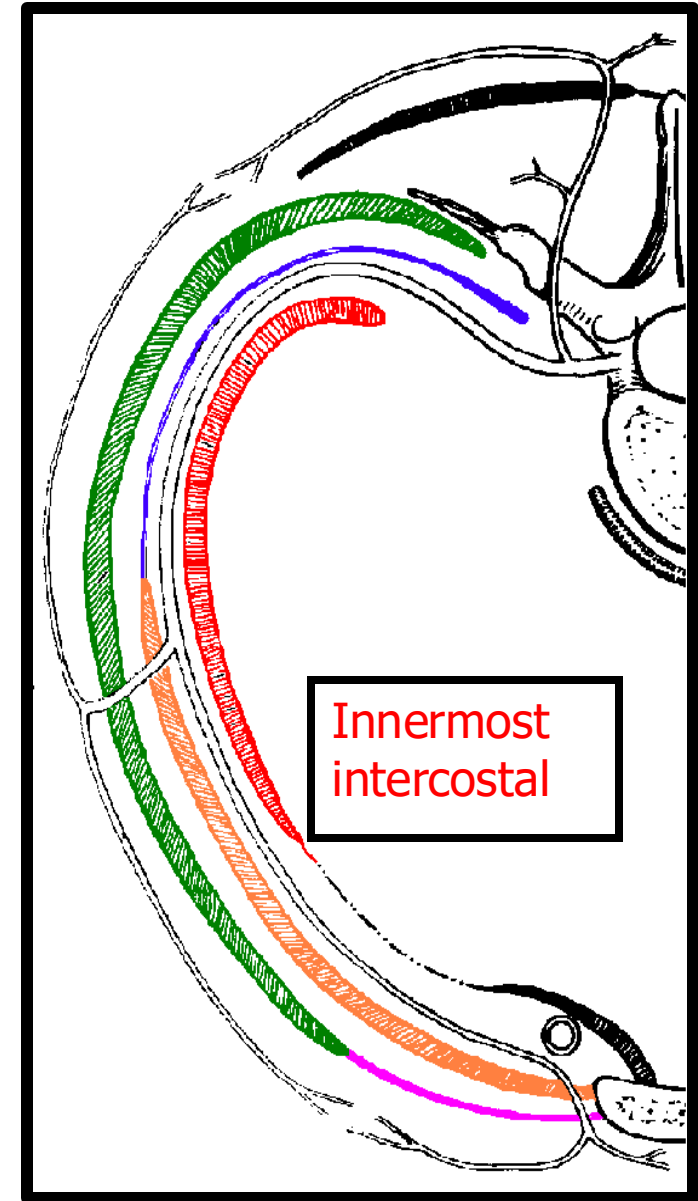


transversus abdominis

- ❖ It corresponds to the **transversus abdominis** muscle of the anterior abdominal wall

Innermost intercostal

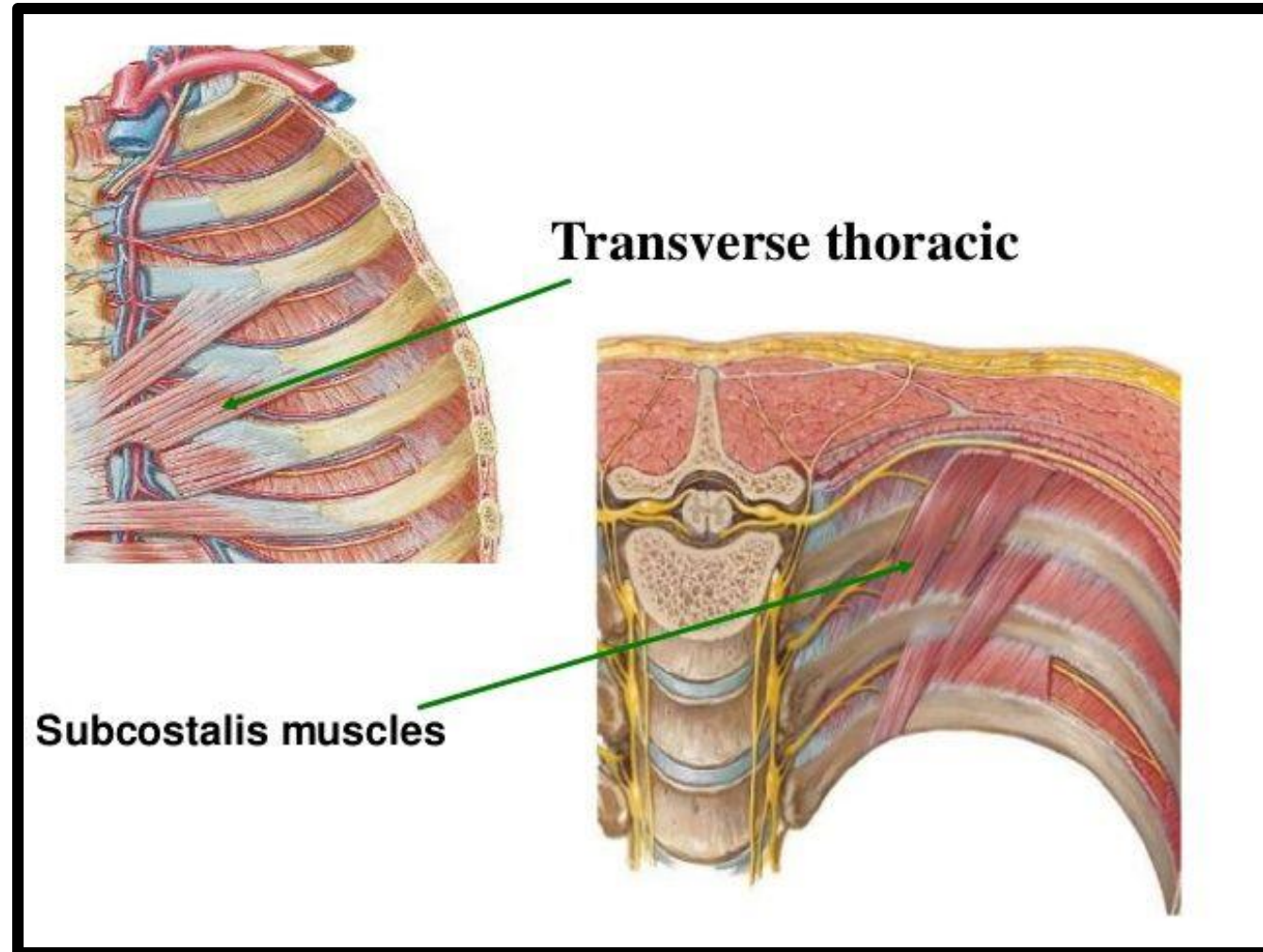
- ❖ The innermost intercostal fibers cover the middle $\frac{2}{4}^{\text{th}}$ of the intercostal spaces



Subcostalis & Transversus Thoracis

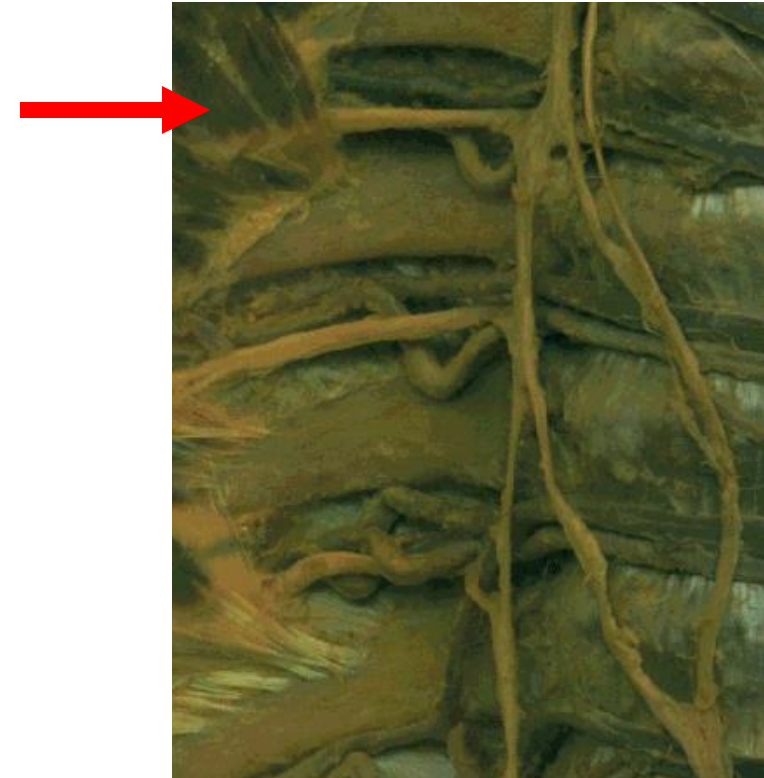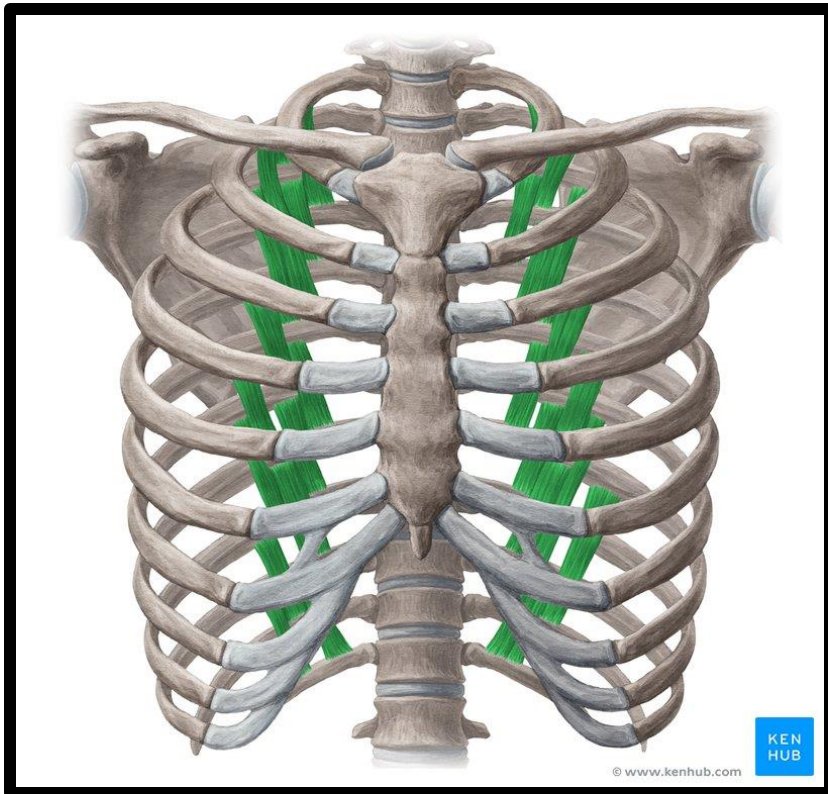
35

- ❖ Lie in a deeper plane than the innermost intercostal
- ❖ their fibers cross more than one intercostal space



Subcostalis

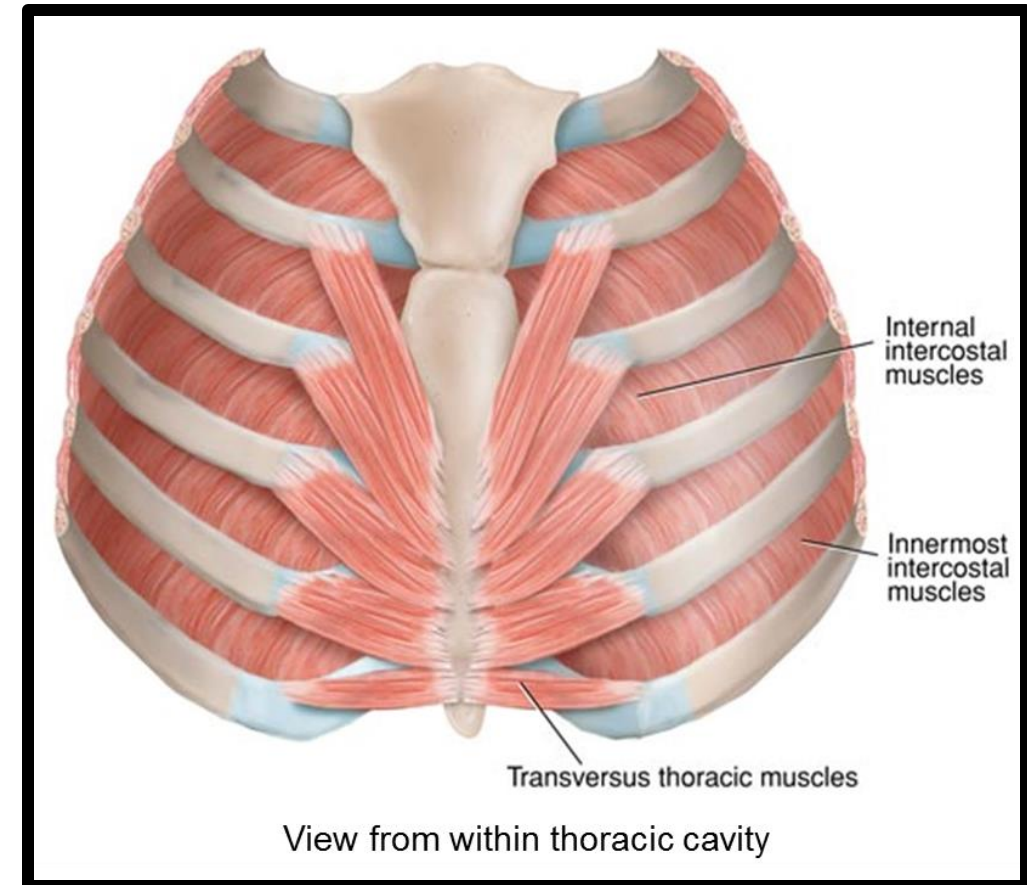
- ❖ The Subcostalis slips are located near the angles of the ribs mainly in the lower intercostal spaces
- ❖ Their fibers run parallel with those of the innermost intercostal



Transversus thoracis

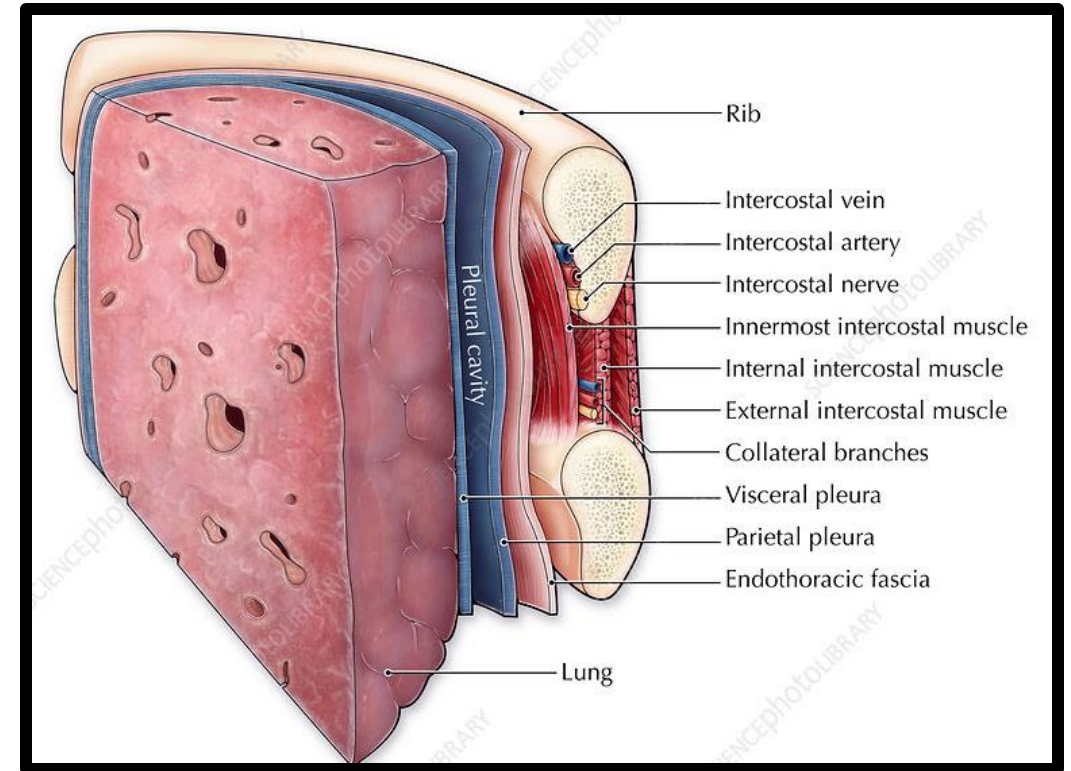
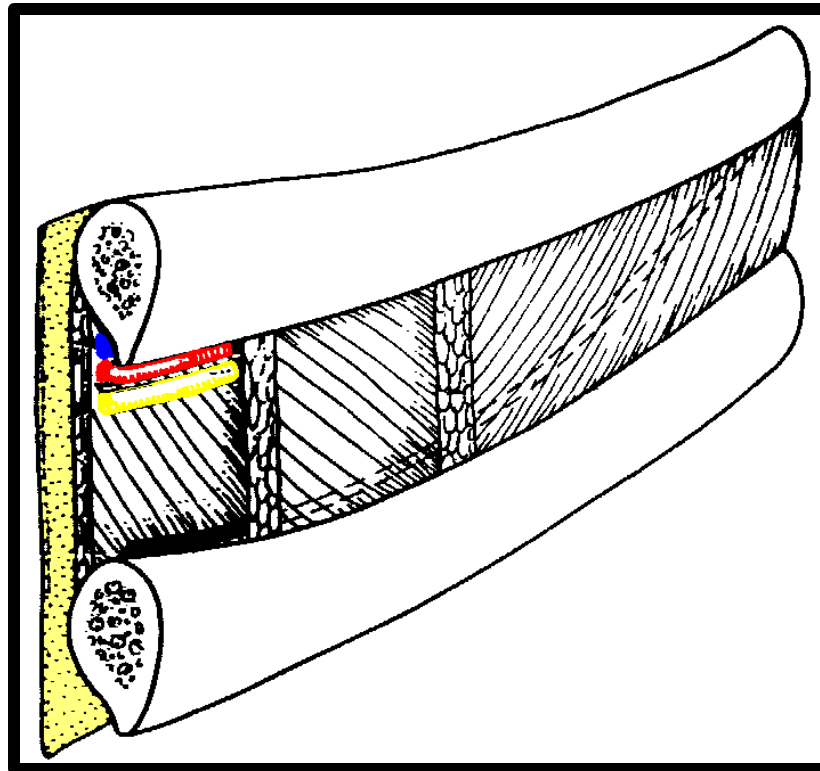
❖ Is also called **sternocostalis** since its fibers extend from the lower 1/3rd of the posterior surface of the sternum and the costal cartilages of the lower true ribs to the internal surfaces of the upper costal cartilages

- ❖ Its fibers have different obliquity
- ❖ the lower fibers are horizontal and become continuous with the transversus abdominis muscle, hence the name **transversus thoracis**



Endothoracic fascia

❖ The innermost intercostal, Subcostalis, and transversus thoracis separate the intercostal neurovascular bundle from the layer of fascia external to the pleura called the endothoracic fascia



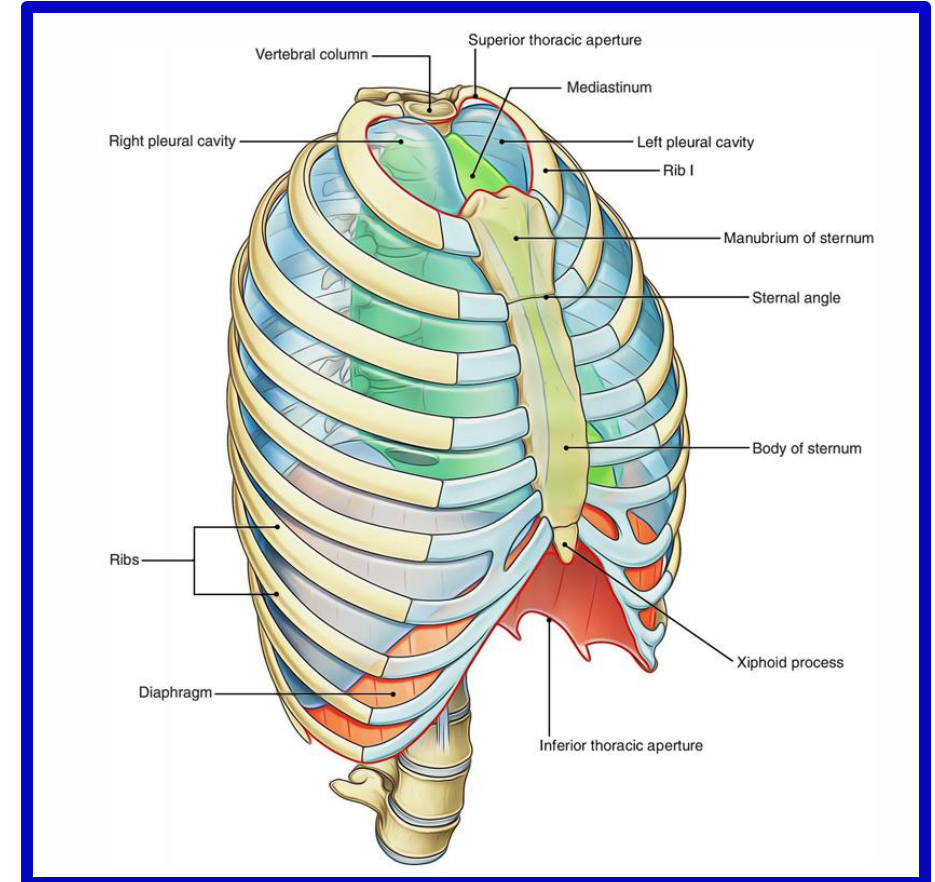
Openings of the Thorax

The chest cavity communicates with the root of the neck through an opening called the **thoracic outlet**.

The opening is bounded **posteriorly** by the **1st thoracic vertebra**,

laterally by the **medial borders of the 1st ribs** and **their costal cartilages**,

and **anteriorly** by the **superior border of the manubrium sterni**.

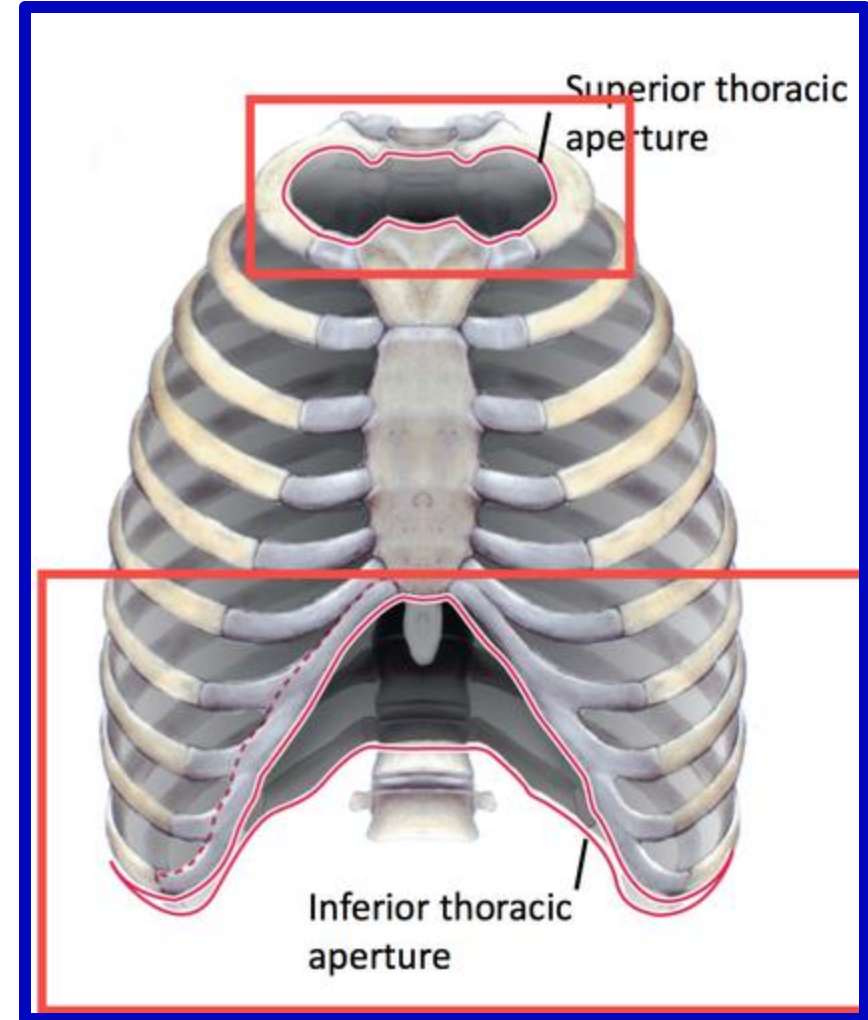
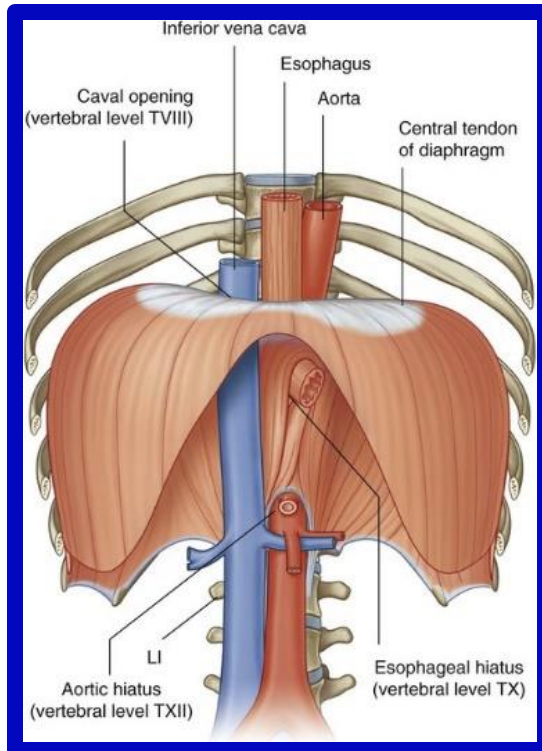


Openings of the Thorax

Dr. Aiman Qais Afar
Sunday 6 October 2024

The thoracic cavity communicates with the abdomen through a large opening.

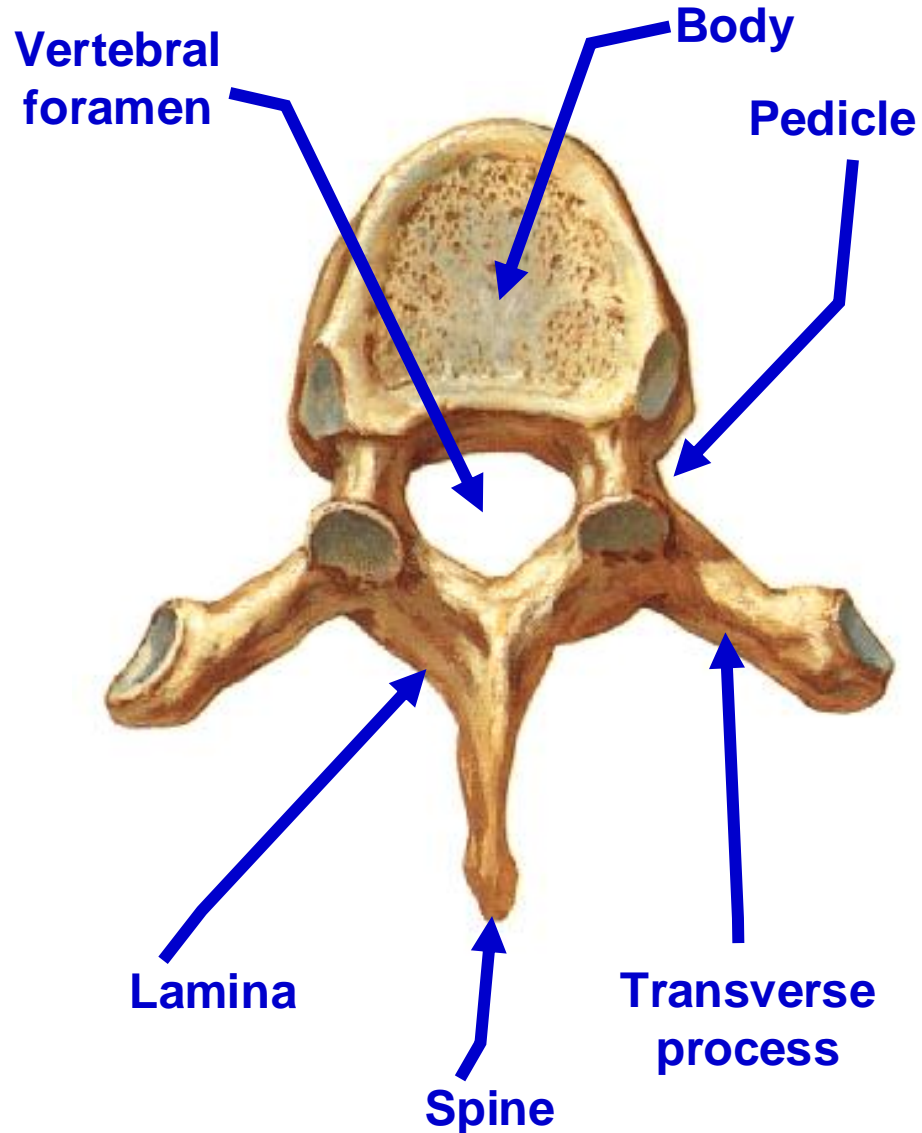
The opening is bounded **posteriorly** by the **12th thoracic vertebra**, **laterally** by the **curving costal margin**, and **anteriorly** by the **xiphisternal joint**.



- **Superior view of typical thoracic vertebrae**

- **From 2nd - 9th**

Dr. Aiman Qais Afar
Sunday 6 October 2024



- **Characters of typical thoracic vertebrae**

- 1- **Two demifacets (large superior & small inferior) on each side of body:**

- 2- **An articular facet on transverse process.**

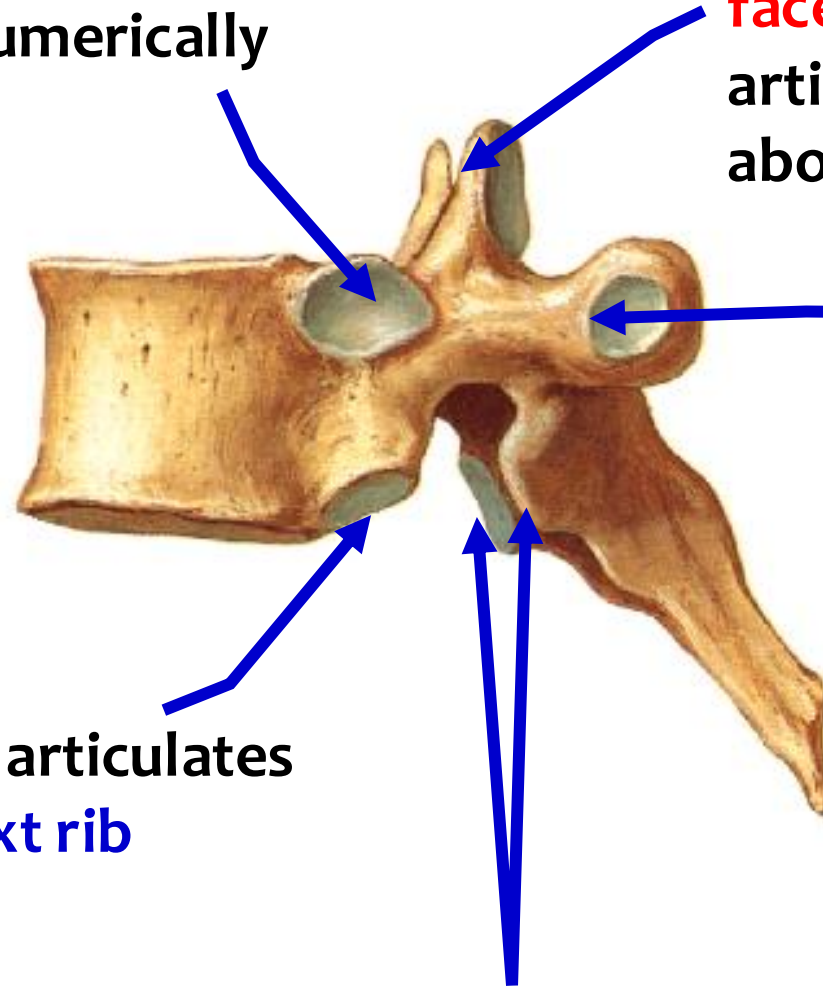
- 3- **Body is heart shaped.**

- 4- **Spine is long and directed backwards and downwards**

• Lateral view

Superior costal facet articulates with head of **same** numerically corresponding rib

Superior articular process and its facet articulates with inferior articular processes of the vertebra above



costal facet of transverse process articulates with tubercle of the **same** numerically corresponding rib

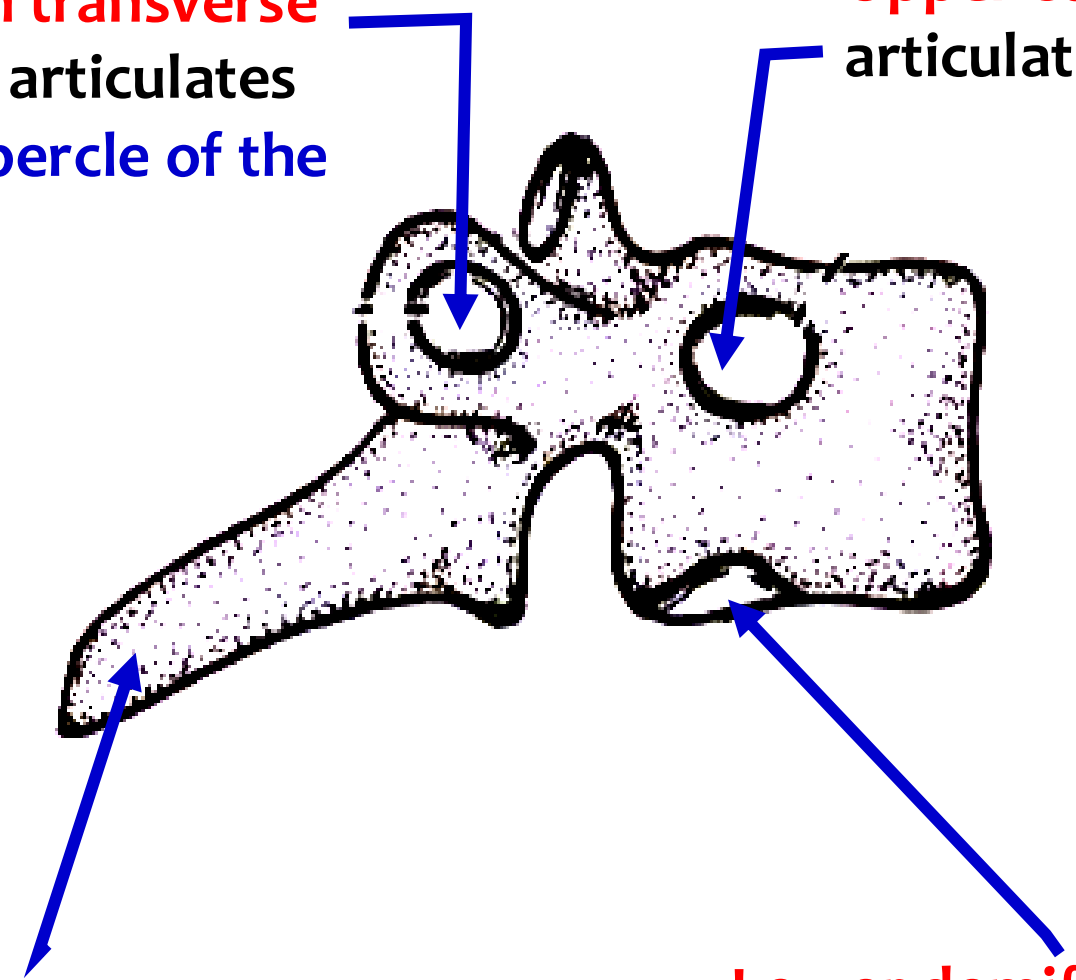
Inferior costal facet articulates with head of the **next rib**

Inferior articular process and facet

• The 1st Th. vertebrae

Facet on transverse process articulates with tubercle of the 1st rib

Upper complete facet on the side of body articulates with the head of the 1st rib



Spine is thick, long and nearly horizontal

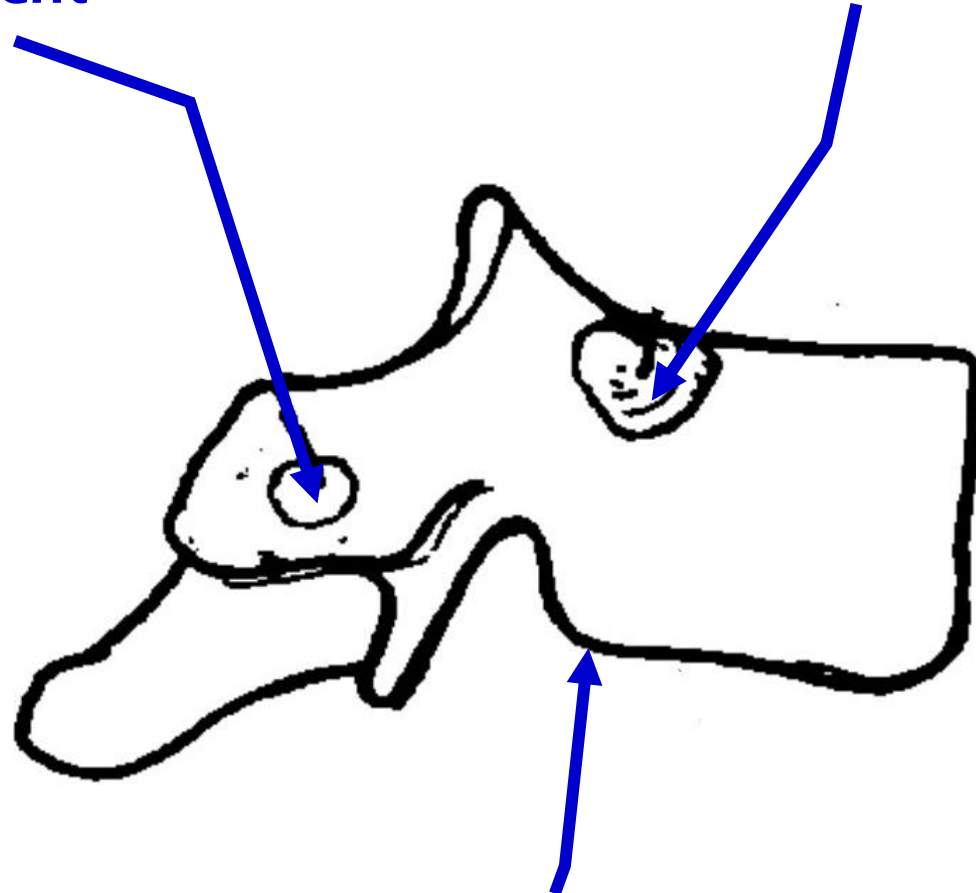
Lower demifacet on the side of body articulates with the head of the 2nd rib

Dr. Aiman Qais Afar
Sunday 6 October 2024

• The 10th Th. vertebrae

Facet on transverse process articulates with tubercle of the 10th rib, may be absent

Upper complete facet on the side of body articulates with the head of the 10th rib

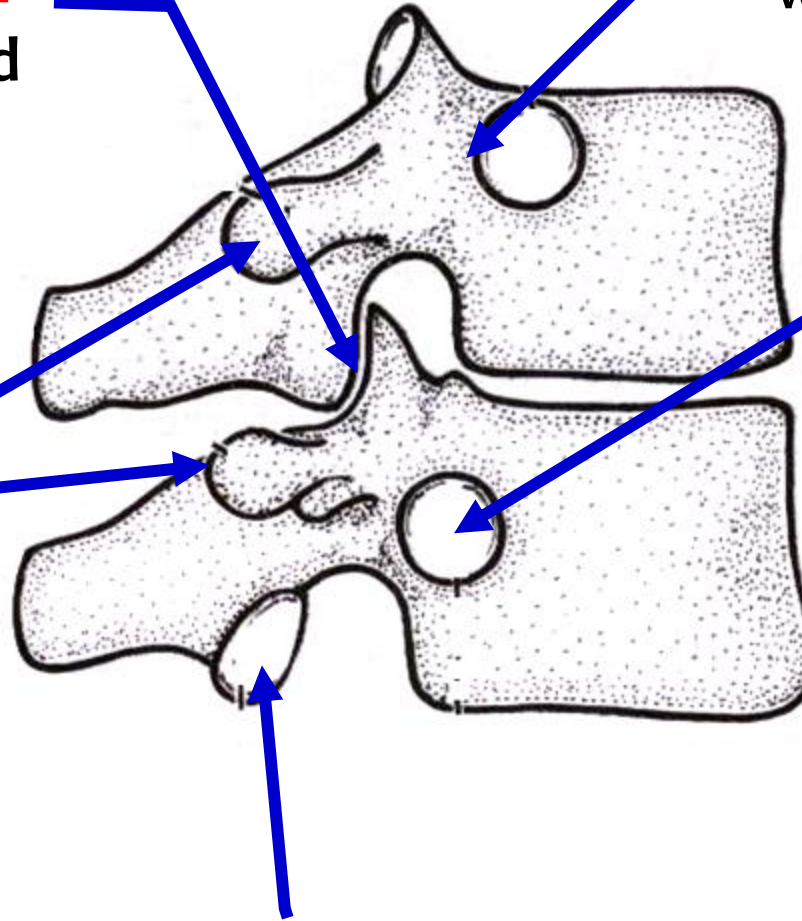


NO inferior demifacet

• The 11th & 12th Th. vertebrae

Articular facet of
Inferior articular
process directed
forward

Transverse process
has no articular
facet



Complete circular facet close to
upper border of the body, articulates
with head of 11th rib

Complete circular facet
away from upper border
of body and extending on
the pedicle, articulates
with head of 12th rib

Articular facet of Inferior articular
process directed laterally

Dr. Aiman Qais Al Maathidy

Sunday 6 October 2024

