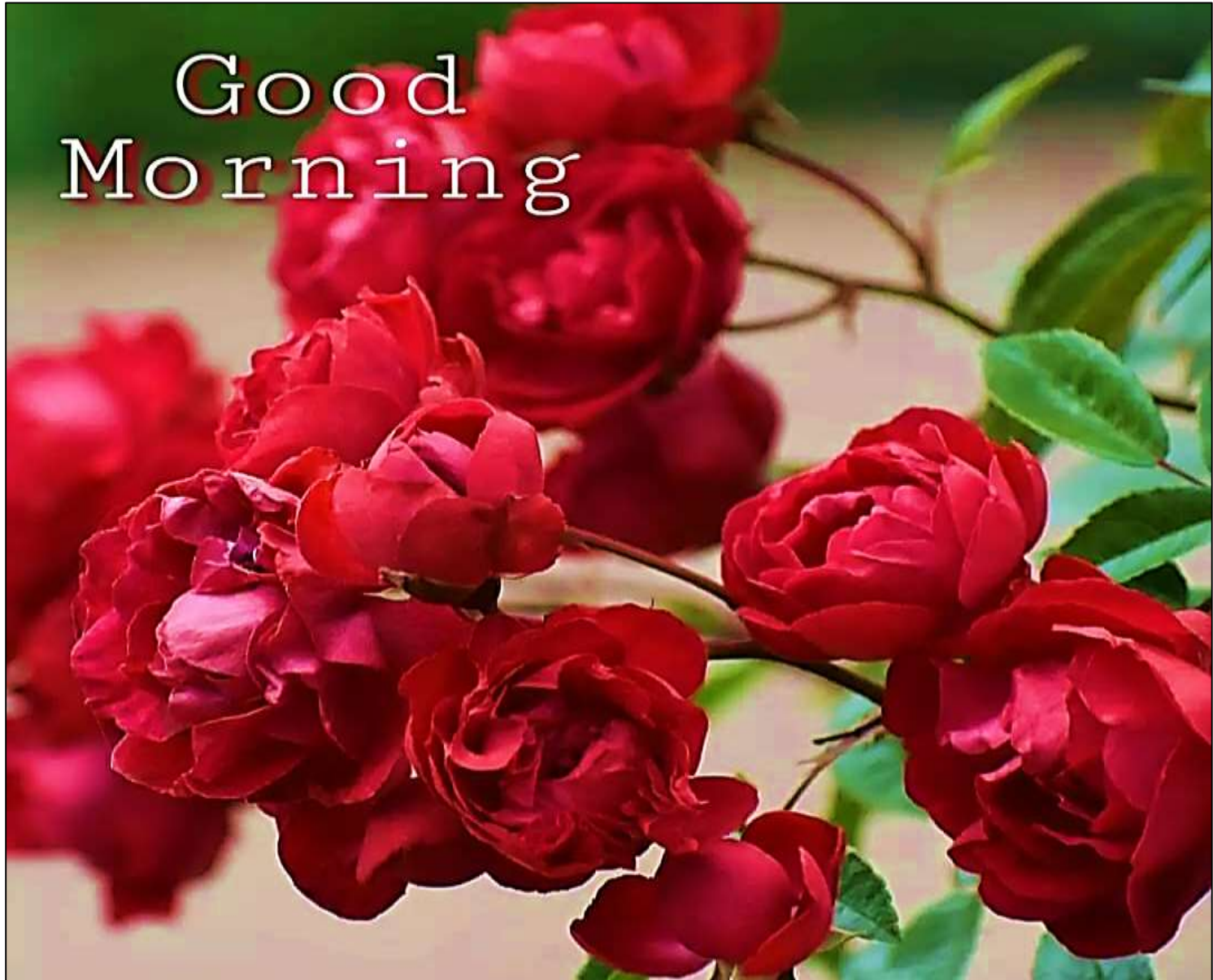


WELCOME THIRD YEAR CLASS





Congratulations Match 2024 Mutah University



Mina Al-Sammarraie-2022
(Internal Medicine)
University of South
Dakota /SD



Malek Amro-2021
(Internal Medicine)
wellington regional Med
Ctr /FL



Mays Khweileh-2016
(Neurology)
Duke University
Hospital/NC



Mustafa Subhi-2020
(Neurology)
Houston Methodist/TX



Husam Shakour-2022
(Internal Medicine)
U Kansas SOM-
Wichita/KS



Mai Al Khatalin-2021
(Internal Medicine)
Saint Peter's University
Hospital/NJ



Basel Masarweh-2019
(Internal Medicine)
Portsmouth Regional
Hospita/NH



Mohammad Salameh-2022
(Internal Medicine)
Meharry Med College/TN




Dana Ahmad-2019
(Internal Medicine)
White County Med
Ctr/AR



Anas Al Mardini-2020
(Internal Medicine)
Marys and St Clares/NJ





CONGRATULATIONS MATCH 2023 MU'TAH UNIVERSITY



OMAR DARWISH
2020
UNIVERSITY OF ARKANSAS
MEDICAL SCHOOL (UAMS)/ IM



ZAID ALWARAWRAH
2019
GRIFFIN HOSPITAL/ IM



NMAIR ALZIADIN
2019
HCA /TUFTS UNIVERSITY/
PORTSMOUTH/ IM



MOHAMMAD KLOUB
2017
SAINT MICHAEL/ IM



BAKER ABU SA'ALEK
2021
KANSAS UNIVERSITY/
NEUROLOGY



ALI ALZEGHOUL
2020
MAGNOLIA REGIONAL
HEALTH CENTER/ IM



DAOUD ELDAWUD
2020
SUNY DOWNSTATE
UNIVERSITY/ IM



YAZAN ALAMRO
2020
COREWELL HEALTH
HOSPITAL/ IM



SARA ALZAGLOOL
2021
HACKENSACK
MERIDIAN/JERSEY
SHORE UNIVERSITY
MED CTR/ IM



FAIQ ALDARAB'AH
2019
NYC HEALTH +
HOSPITALS/ LINCOLN
MEDICAL CENTER/ IM



KHALED EL-QAWAQZEH
2021
WESTCHESTER MEDICAL
CENTER/ GENERAL
SURGERY



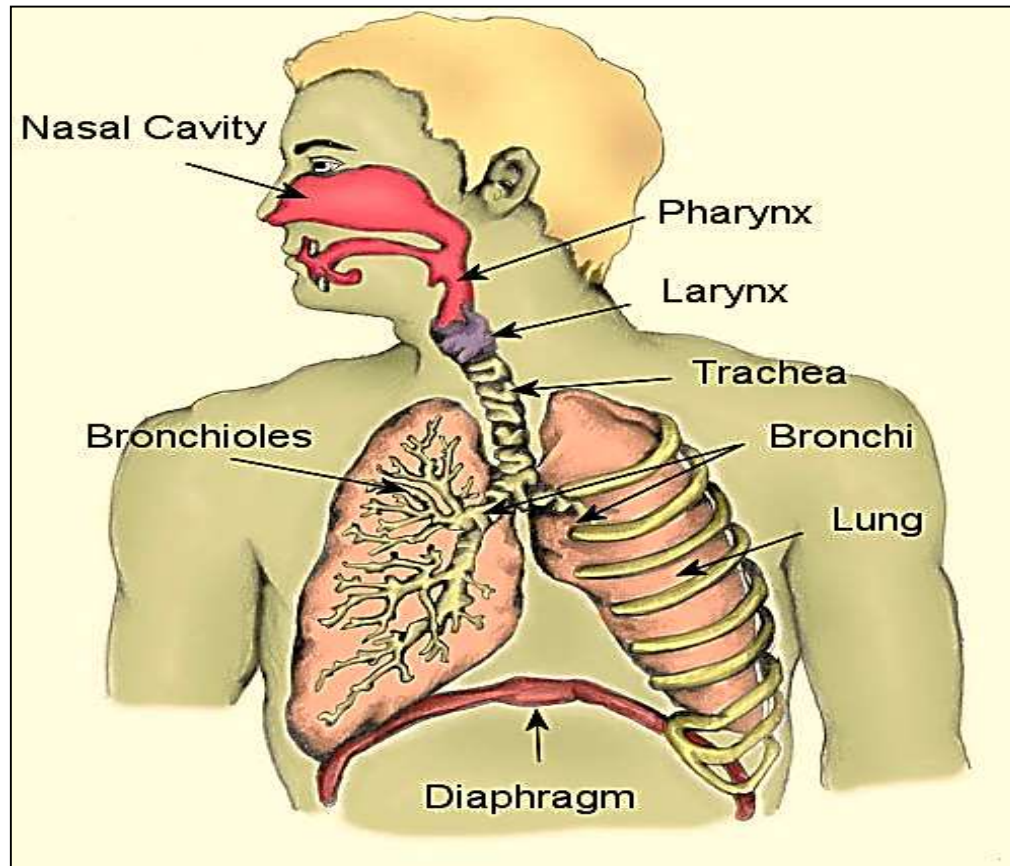
AMMAR ADAILEH
2020
HENNEPIN COUNTY
MEDICAL CENTER/ IM



TARIQ ALMANASEER
2019
HELEN DEVOS CHILDREN'S
HOSPITAL/ PEDIATRICS



The Respiratory system



Objectives of studying the respiratory system:

- Understand the structure and function of air ways , lungs, the role of their lining epithelium in clearing the inspired air and in gas exchange



- Understand the structure of chemoreceptors involved in the sense of smell



- Understand structures responsible for production of sounds (Phonation)



Learning objectives:

- 1- Recognize & describe the cellular components of respiratory epithelium
- 2- Understand the structure & function of conchae
- 3- Recognize & describe the cellular components of olfactory epithelium
- 4- Describe components of the vocal cords
- 5- Recognize & understand function of epiglottis
- 6- List the tubes that make up the conducting and respiratory portions
- 7- Distinguish between a bronchus, bronchioles & respiratory bronchiole
- 8- List all components that make up the interalveolar septum
- 9- Distinguish between type I & type II alveolar cells , macrophage and endothelium

Respiratory system

```
graph TD; A[Respiratory system] --> B[Conducting portion]; A --> C[Respiratory portion]; B --> D[Conduct, filters, warms & moistens air]; C --> E[Gas exchange & secretion of Surfactant]
```

Conducting portion

Conduct, filters, warms & moistens air

Respiratory portion

Gas exchange & secretion of Surfactant

- **Types of epithelium in the respiratory system:**

1- Non- K stratified squamous epith. → found at nostrils, lingual surface of epiglottis, & true vocal cords

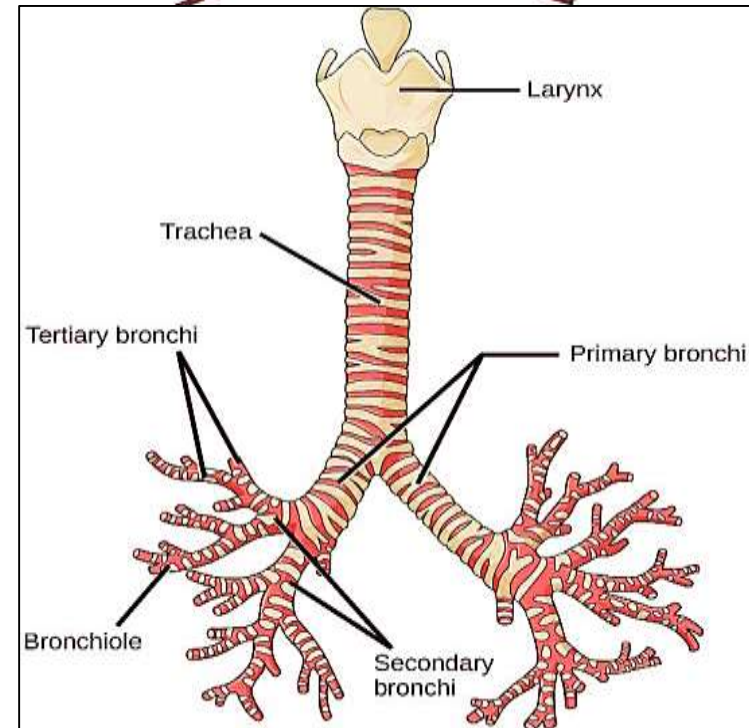
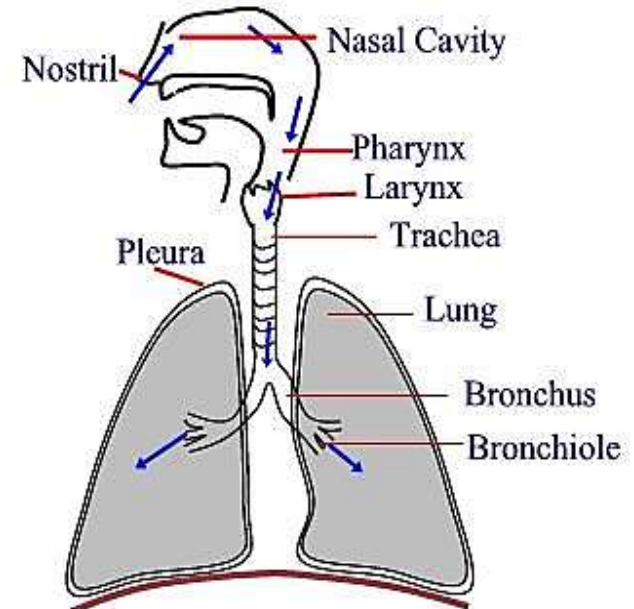
2- Respiratory epith. Cover most of the conducting portion of the respiratory tract

3- Olfactory epith. Contains chemoreceptors of smell sensation → superior conchae

4- Alveolar epith. Found in Respiratory portion / alveoli where gas exchange

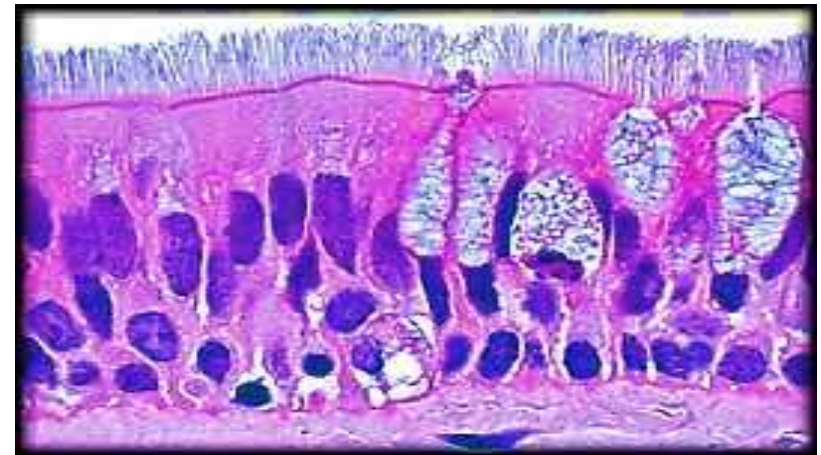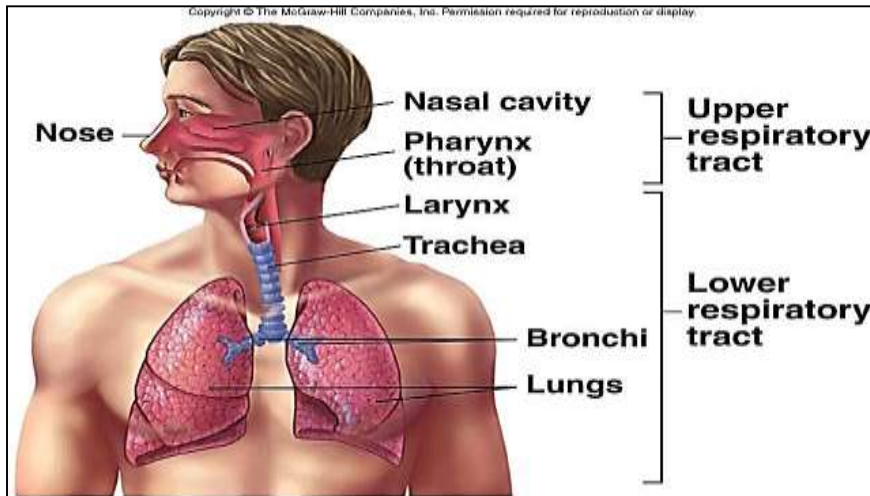
➤ A- Parts of The conducting portion :

- Nasal cavities & sinuses
- Nasopharynx
- Larynx
- Trachea
- Bronchi (Rt & Lf)
- 2ry , 3ry bronchi
- Bronchioles
- Terminal bronchioles



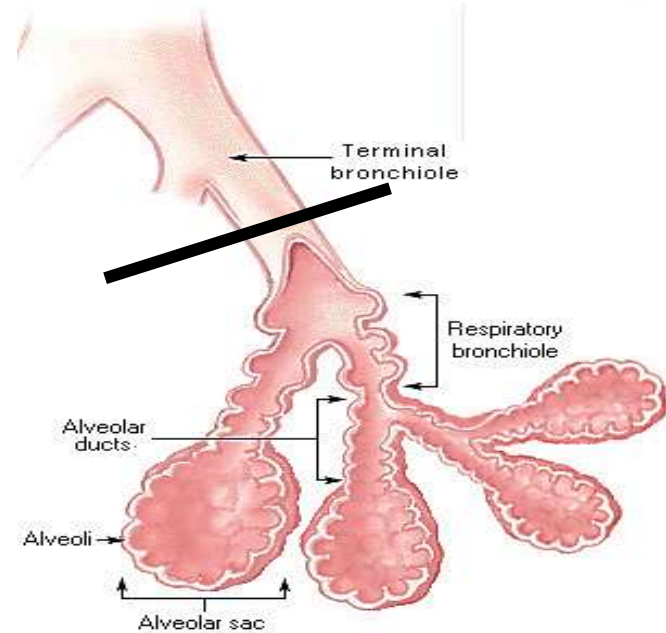
Structure / Function relation in Conducting portion

- **Cartilage** to prevent collapse → Maintain an open lumen
- **Elastic fibers & smooth ms. fibers** for flexibility → Ability to accommodate expansion & contraction
- **Respiratory epithelium** → Filtering, moisturizing & warming of inspired air



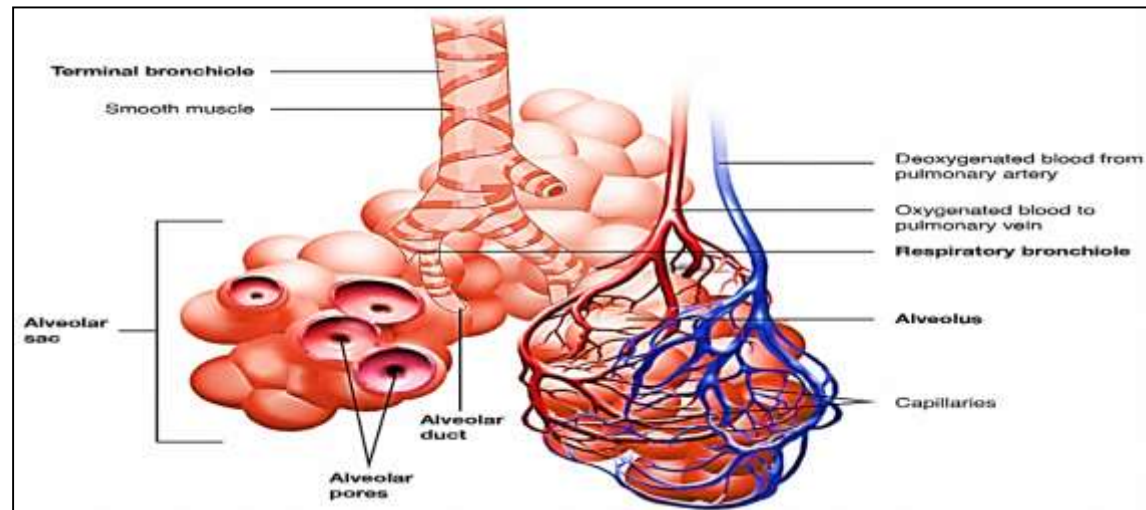
➤ B- Parts of The respiratory portion :

- Respiratory bronchioles
- Alveolar ducts
- Alveolar sacs
- Alveoli



Function of respiratory portion:

Gas (O_2/CO_2) exchange between blood & inspired air
Production of surfactant



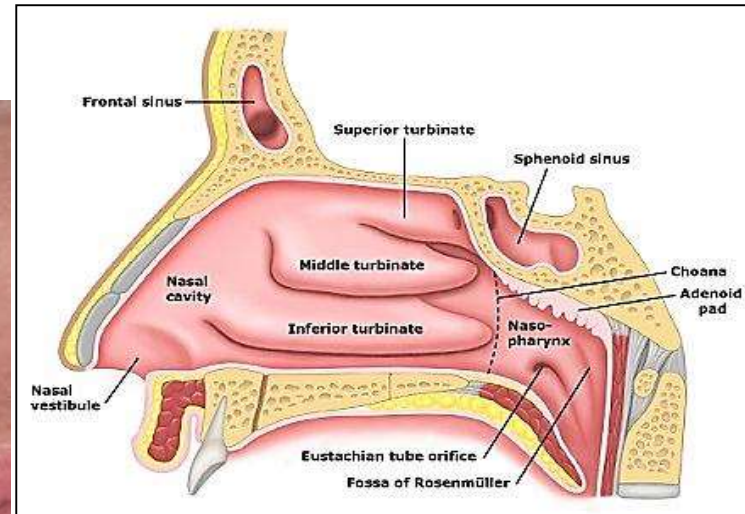
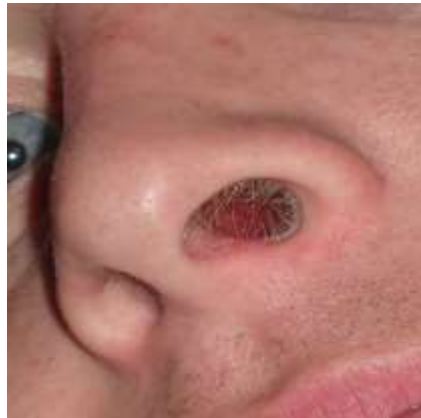A- Conducting portion

Nasal cavities:

separated by a septum (cartilaginous & bony) parts
each consists of: **vestibule & nasal fossa**

Vestibule:

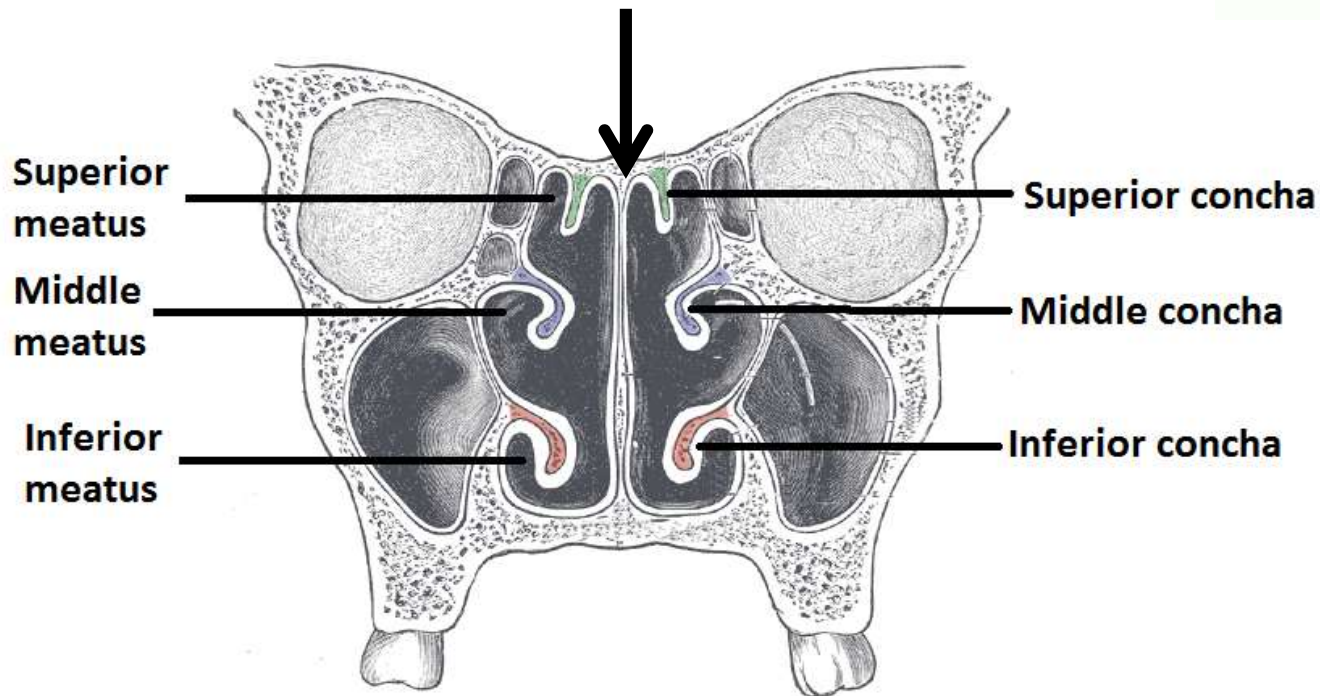
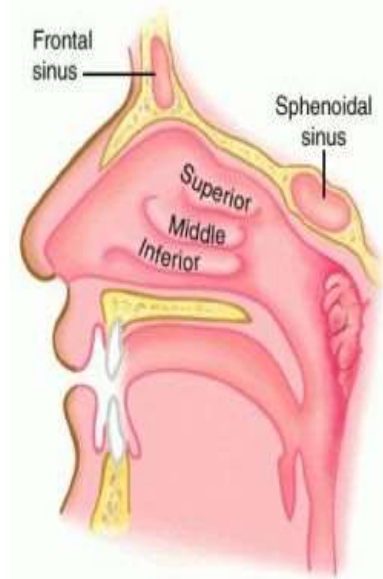
- Is the anterior part



- Lined e **thin skin** → as going deeper changes into → **non - K st. squ. epithelium** → then to **Respiratory epithelium**
- hair filters out large dust particles

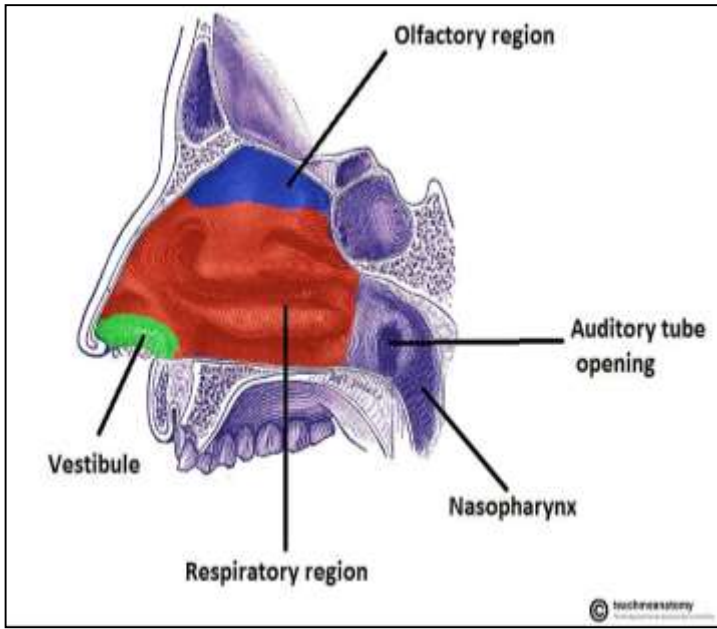
Nasal fossae:

- 2 cavities separated by nasal septum
- Their lateral walls contain 3 bony projections (conchae) superior, middle, inferior

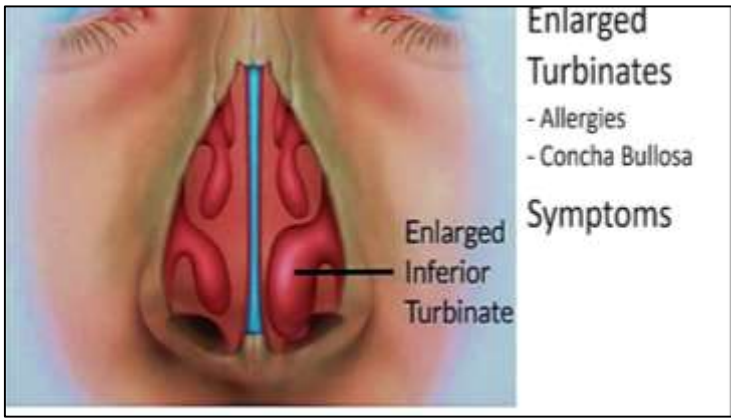


- Superior one covered e **Olfactory epithelium**
- Middle & inferior covered e **Respiratory epithelium**

- The conchae slow flow of air & increase the surface area of respiratory epithelium for conditioning of the inspired air



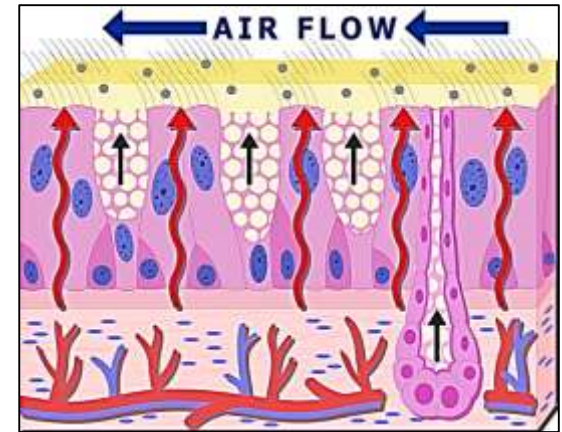
- lamina propria beneath RS epith. rich with superficial venous plexus (**swell bodies**)



Swell bodies:

Loops of venous plexus located in of lamina propria of the respiratory epithelium of the nasal cavities

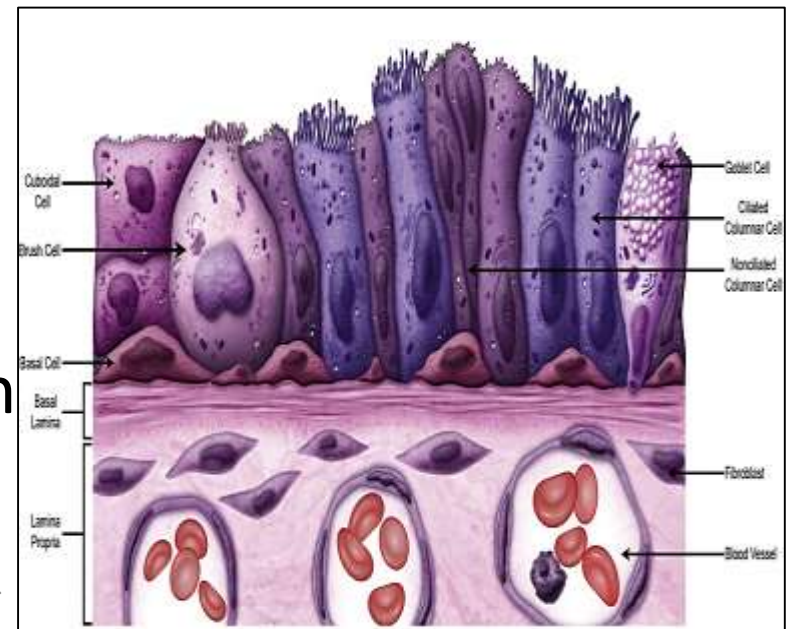
1- Important for conditioning & warming of inhaled air → “counter current flow”



2- Due to their thin wall & proximity to the surface **nosebleed** occurs so common

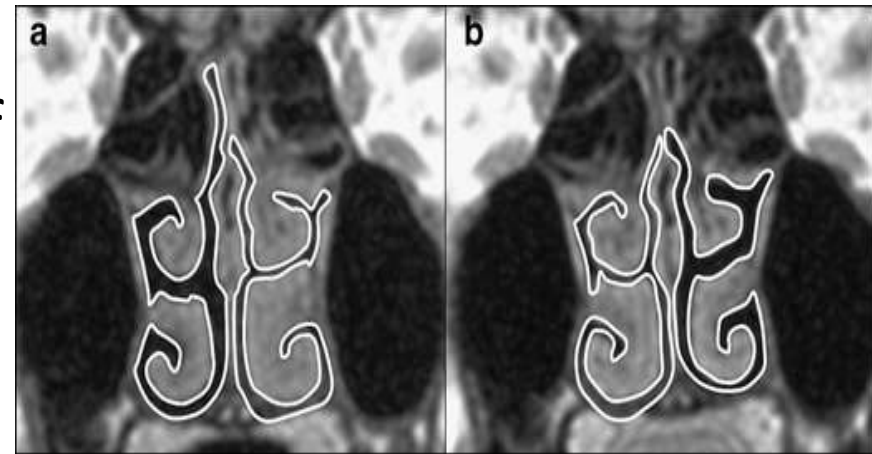
3- Responsible for **nasal cycle**

4- Allergic reactions & inflammation can cause sever engorgement of swell bodies in both fossa



Nasal cycle:

- Every 20-30 min. rhythmic cycles of physiological congestion & decongestion occurs in the mucosa of the nasal cavities. Normally we are not aware of it
- When Swell bodies in lamina propria of one nasal cavity become engorged with blood → distention of conchal mucosa → ↓ flow of air → allowing the engorged Res. Epith. To recover from dehydration
- The cycle under the control of autonomic nervous system



Nasal cycle using MRI imaging

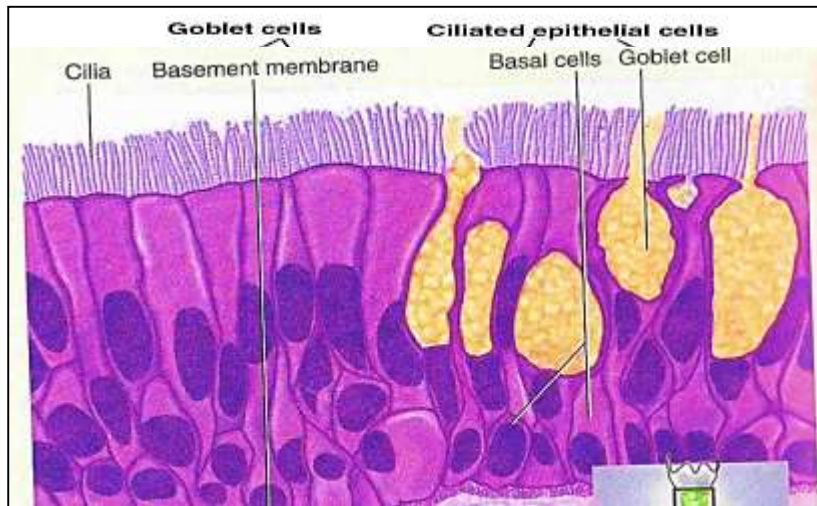
Why eating ice-cream causing pain & headache ?

- It is also called Brain freeze, or **cold neuralgia** or sphenopalatine ganglio-neuroalgia
- you experience this pain in the head or behind your eyes .
- Happen When the cold substance like ice or ice-cream touches the palate cause drop in the temperature which subsequently cause vasoconstriction of the blood vessels which ultimately re-open up again to restore the normal temperature

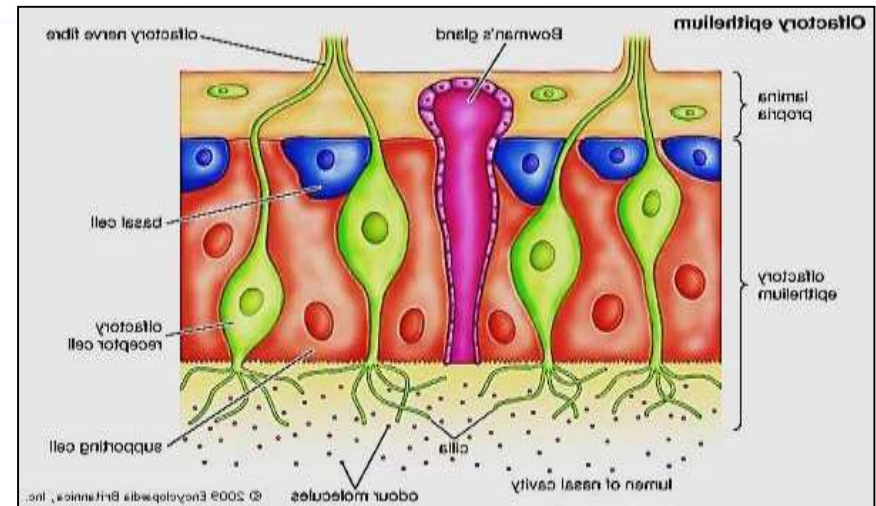


Q:What is the difference between the respiratory & olfactory epithelium?

RESPIRATORY



OLFACTORY



The respiratory epithelium:

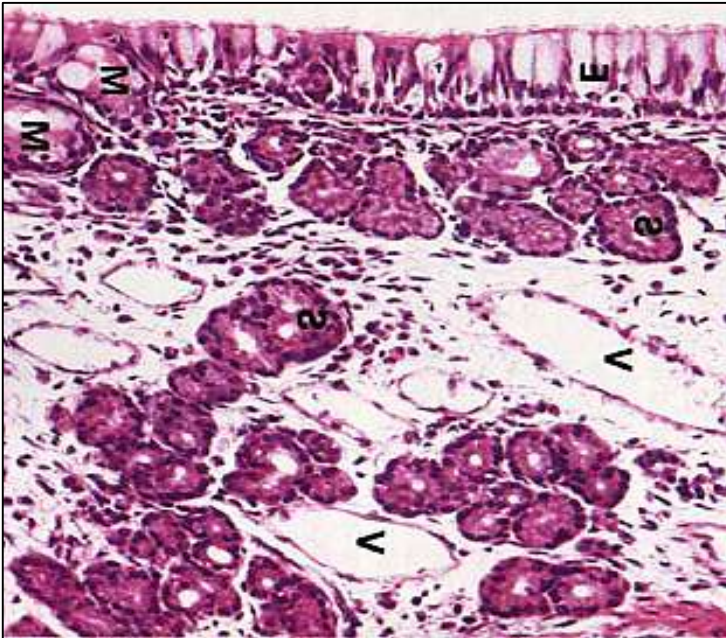
- Pseudostratified columnar ciliated e goblet cells

The olfactory epithelium:

- Pseudostratified columnar e chemoreceptors & NO goblet cells

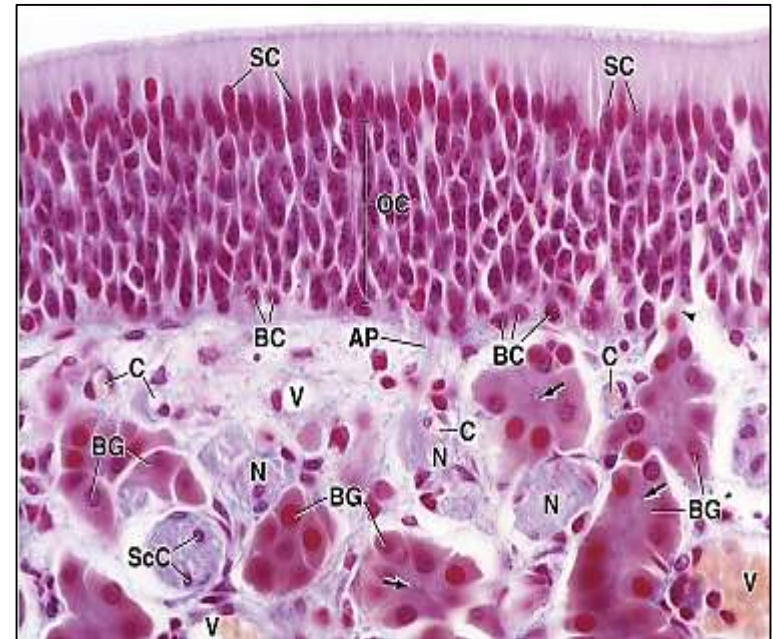
Respiratory mucosa

- Epithelium
- Lamina propria
- Nasal glands (M & S)
- Blood vessels



Olfactory mucosa

- Epithelium
- Lamina propria
- Olfactory glands (S only)
- Blood vessels



The respiratory epithelium

- Lines most of the conducting portion

- **5 types of cells** are present:

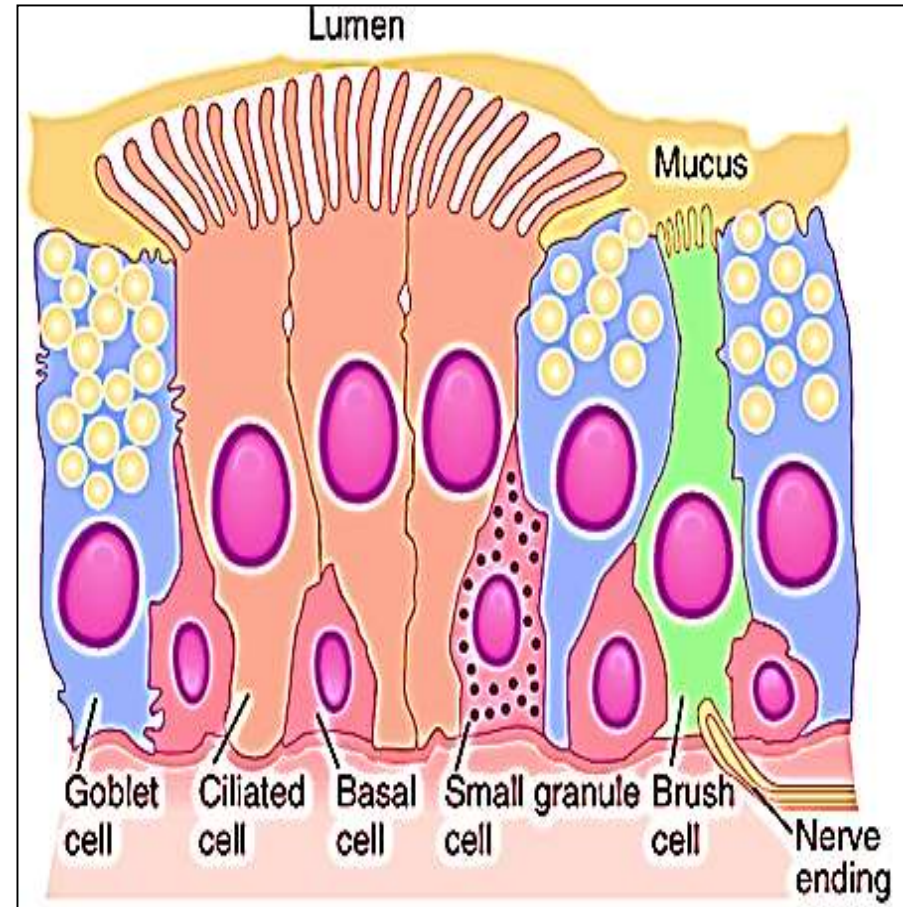
1- Columnar ciliated cells

2- Goblet cells

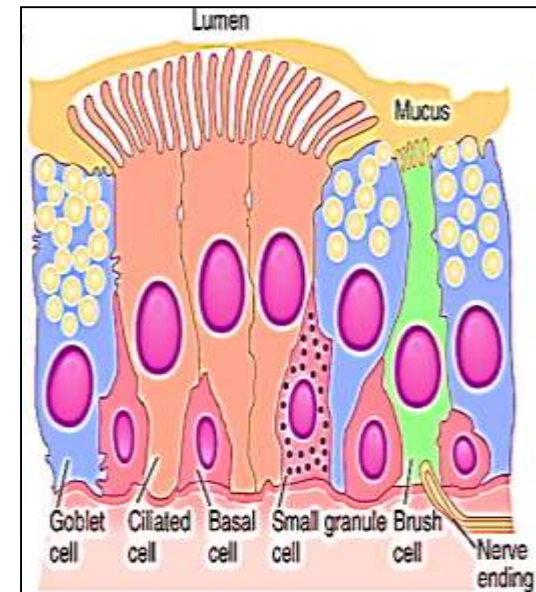
3- Brush cells

4- Basal (stem) cells

5- Granule cells (NE cells)



- 1- **Columnar ciliated cells** : most cells, have **motile cilia** (300) on apical surface (unidirectional beating)
- 2- **Goblet cells**: secrete mucus, cover surface to trap bacteria & dust
- 3- **Brush cells**: columnar cells e **apical microvilli**, have basal afferent nerve endings that communicate e trigeminal nerve 5th → give sensory information about the mucosa = (chemosensory receptors i.e. O₂ & Co₂ levels)
- 4- **Basal cells**: small cells, act as stem cells
- 5- **Granule cells**: (diffuse neuro-endocrine cells): have basal cytoplasmic granules, secrete hormones (serotonin & catecholamine) → regulate the caliber & secretions of airways



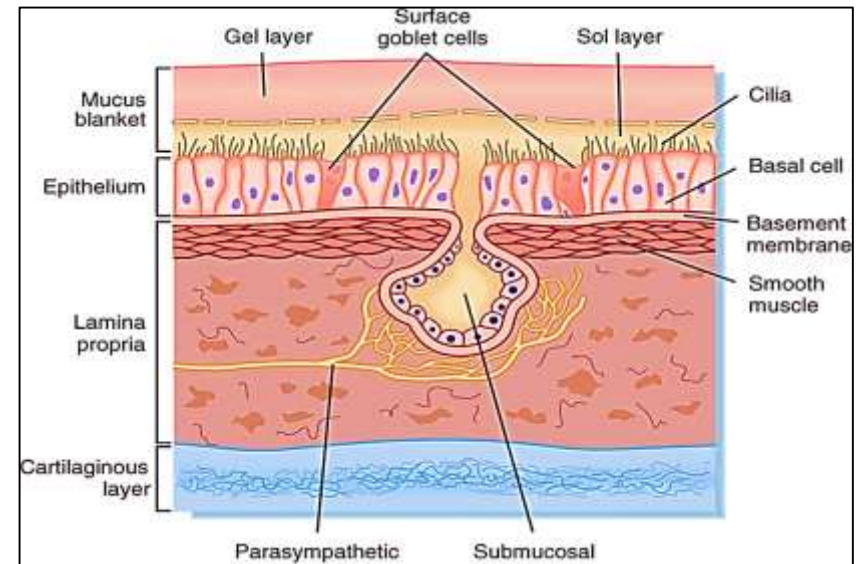
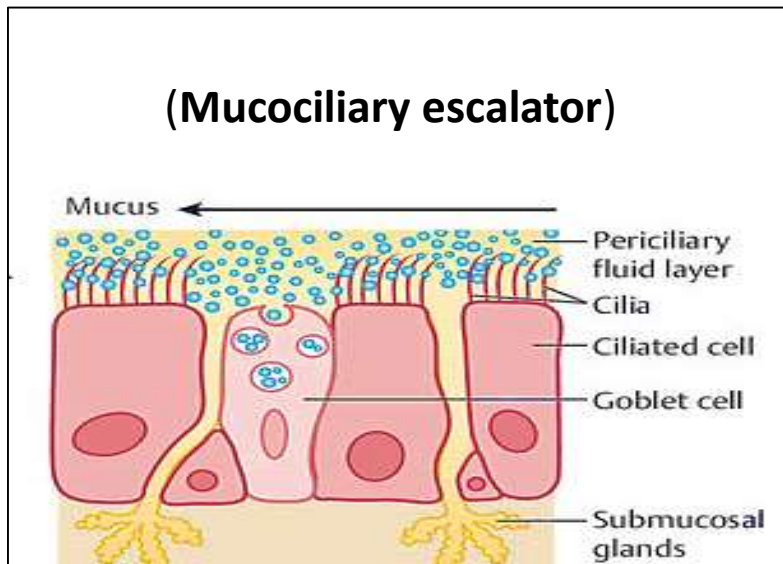
- Granular cells:
- During development :they exert a local mitogenic effect, they influence the lengthen of the individual airway branches.
- In adult: they provide local regulation of bronchial or vascular muscle tone in response to hypoxia or hypercapnia

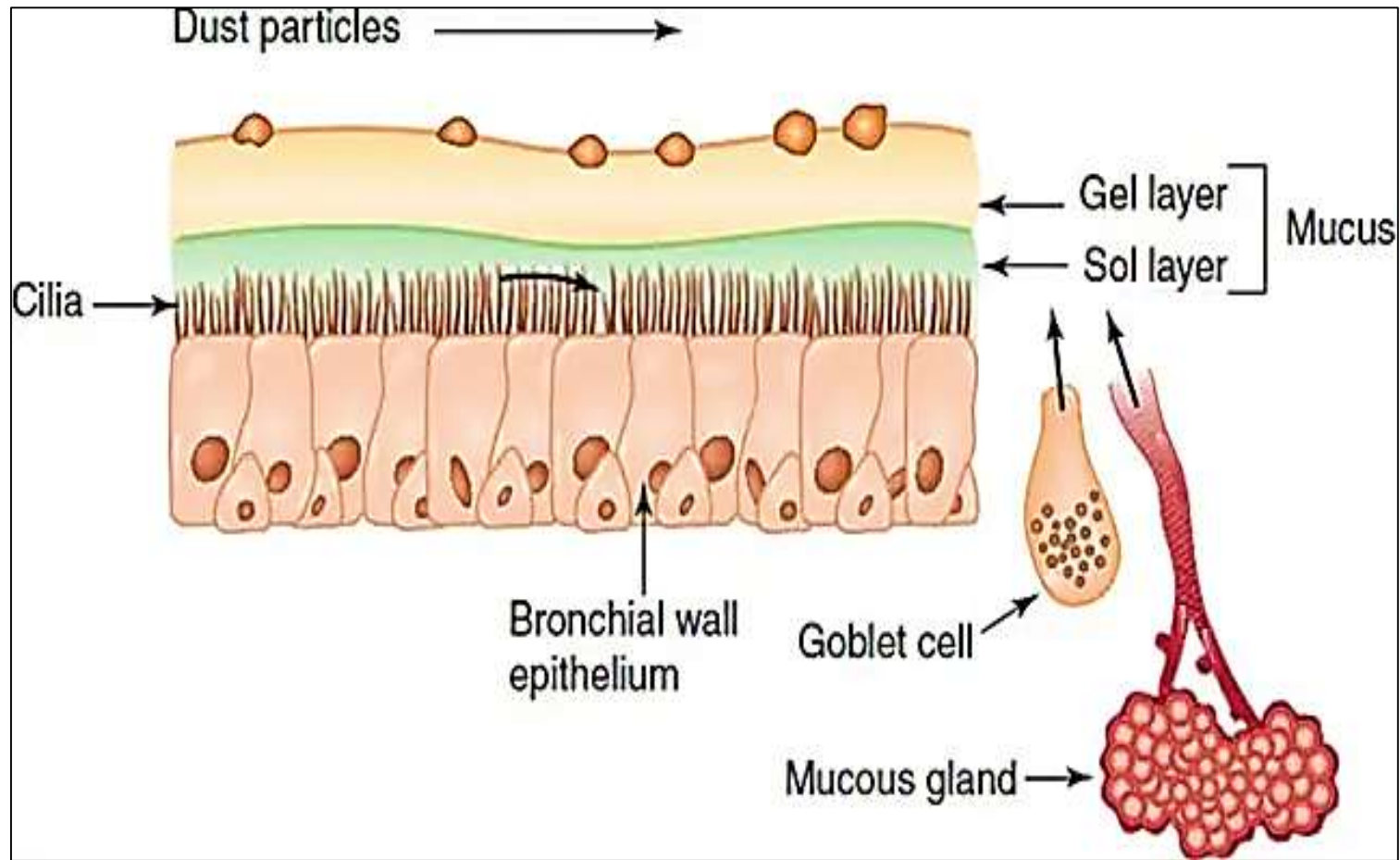
Role of serotonin

- **Serotonin**: is a cilio- stimulatory i.e. \uparrow ciliary beat frequency (CBF).
Serotonin: induces the release of Ach from columnar ciliated cells \rightarrow release of Ca & ATP \rightarrow \uparrow CBF .
- **Serotonin**: cause \uparrow in per-ciliary liquid & thus facilitate **mucoiliary clearance**
- **Serotonin**: induces vasoconstriction in pulmonary vasculature \rightarrow role in **Pulmonary hypertension(through its action on 5HT-1B receptors)**

The respiratory epithelium Rests on lamina propria contain many Nasal glands (*serous & mucus*) + BV + immune cells

- The serous glands sec. serve to facilitate movement of cilia
mucous glands sec. serve to catch inhaled dirt & bacteria particles inhaled & prevent dryness of RS mucosa
(both secretions form the mucous blanket)



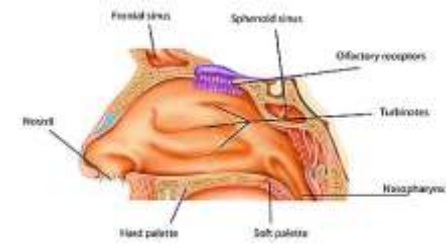


The mucous Blanket : The Gel layer is mucous, the Sol layer (peri-ciliary) is liquid

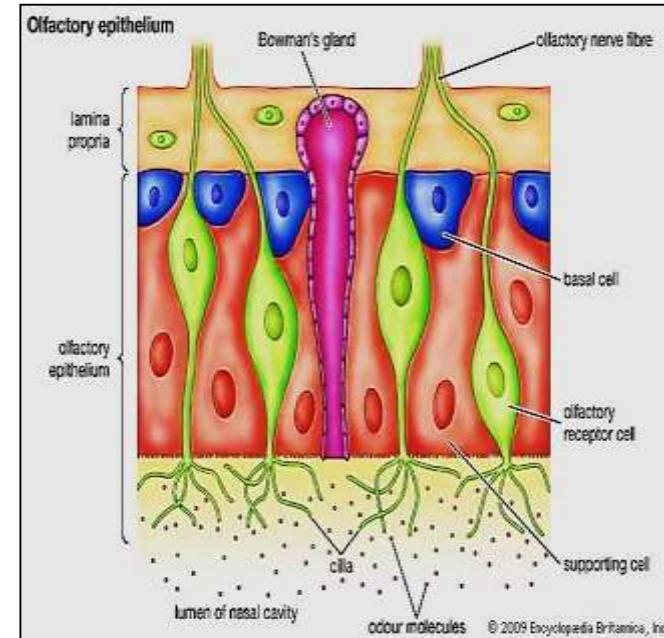
In cystic fibrosis disease this mucus become dehydrated, thick & sticky that the cilia become unable to propel the mucus out of the lung

- Lamina propria contains many immune cells e.g. mast cells , plasma cells & lymphoid nodules as part of mucosa associated lymphoid follicles (MALT)
to protect the RS from the microbes inhaled with air
(explains the allergic reactions in upper respirator tract)
- The blood vessels in Lamina propria serve to warm the inspired air (humidity of the lung can be maintained)
(mechanism is called counter-current exchange)
- In smokers the proportion of ciliated cells to goblet cells is altered (↑ goblet cells) to trap gaseous pollutants

The olfactory epithelium



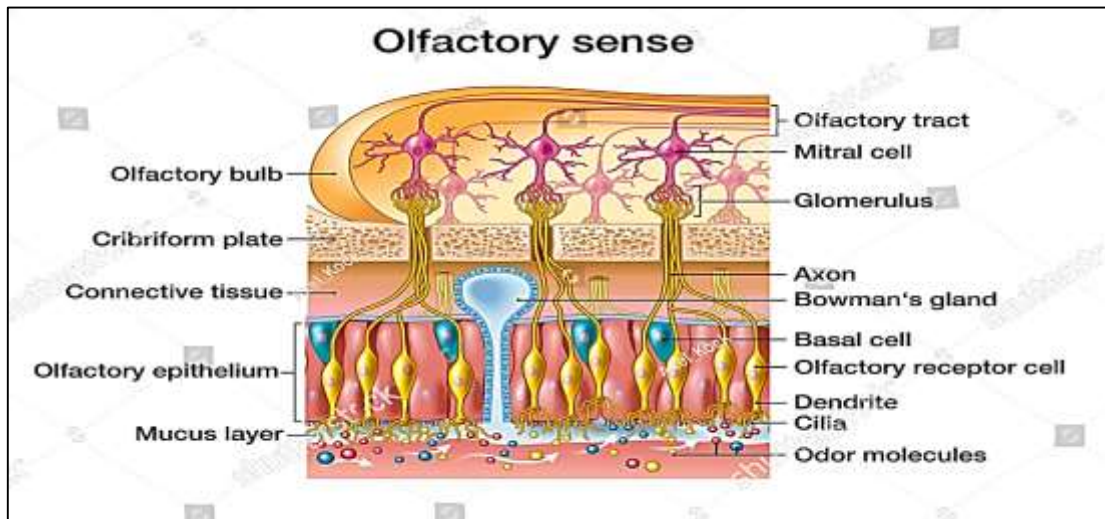
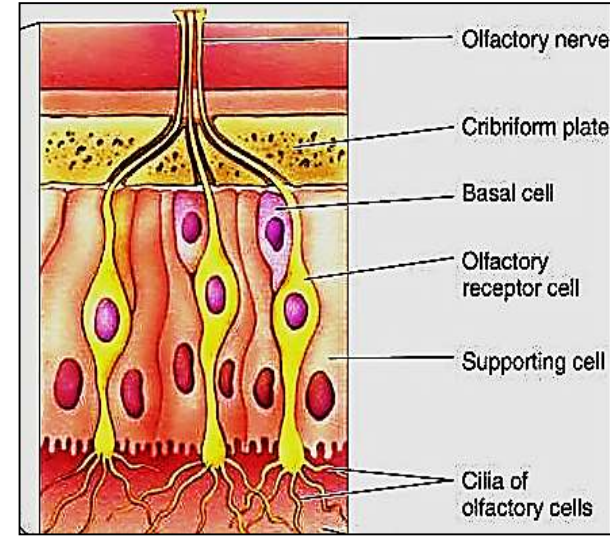
- Covers the roof of nasal cavities & superior conchae.
- Contains **chemoreceptors of smell**
- **3 types of cells** are present:
 1. **Olfactory neurons**
 2. **Supporting (sustentacular) cells**
 3. **Basal cells**

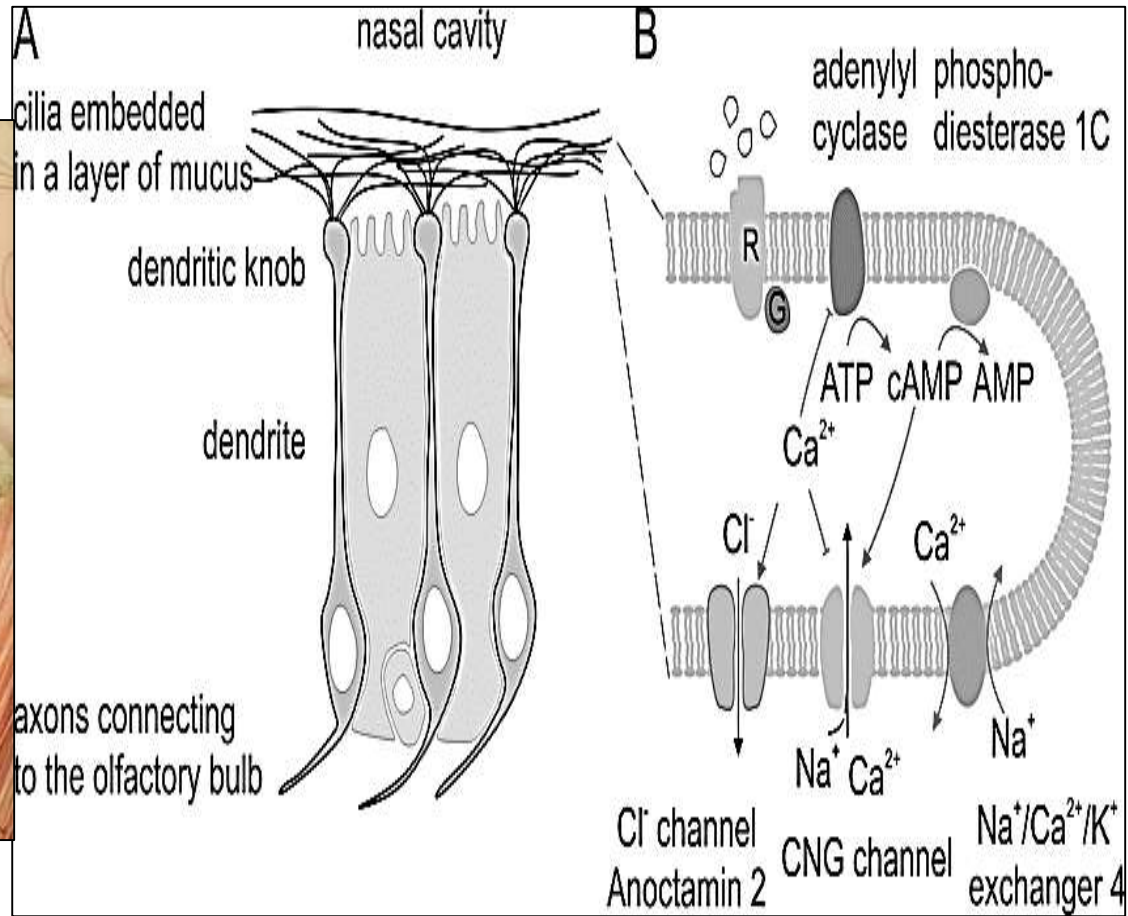
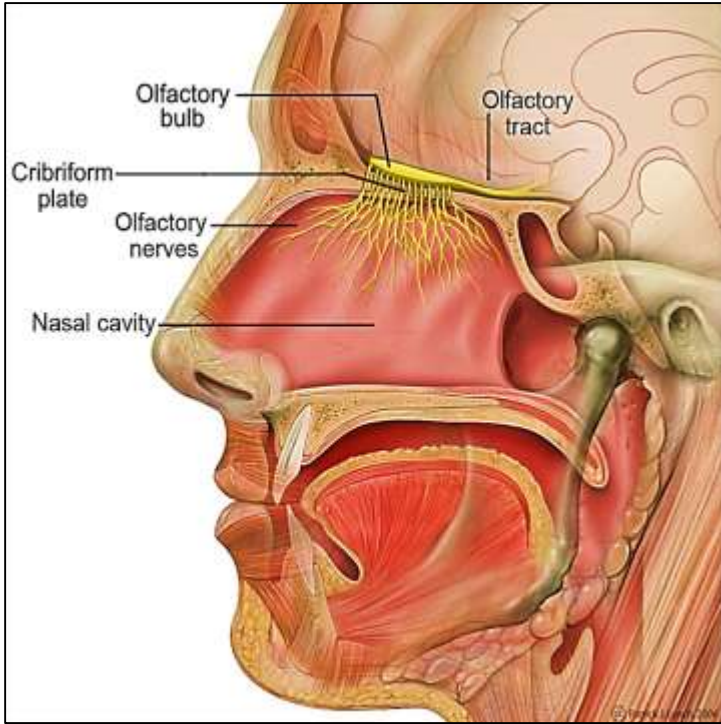


- The olfactory epithelium rests on lamina propria contains:
 - ✓ **BV & olfactory nerve fibers**
 - ✓ **Bowman's glands** secrete constant flow of **serous fluid** → surface → facilitate dissolve of odoriferous substance

1- Olfactory neurons:

- Bipolar nerve cells (renew 30- 60 days)
i.e(regenerative neuronal tissue !!)
- Their dendrites extend toward surface
→ end in swellings (olfactory vesicles)
from which cilia arise
- These cilia (10-20) are very long & non motile. It provides large surface for transmembrane chemoreceptors
- Their axons pass to lamina propria to form olfactory n. fibers

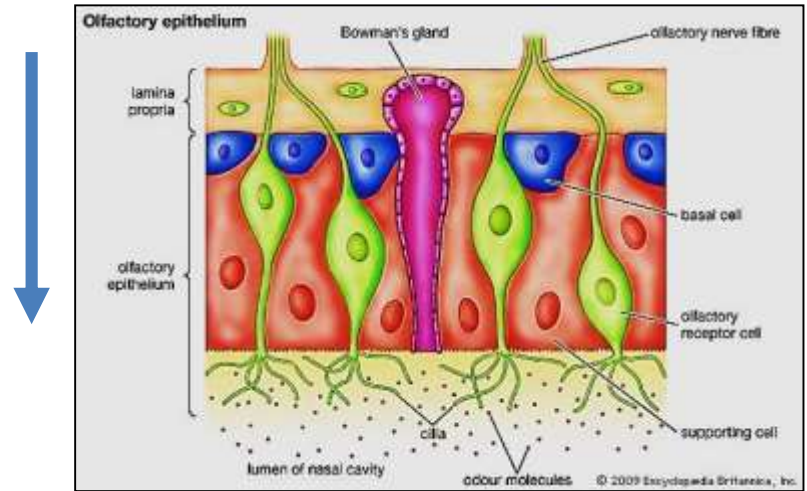




Schematic illustration of the of the olfactory epithelium with olfactory receptors

2- Supporting cells (neuroglia):

- Tall columnar cells e wide apex narrow base
- Their free surface has **microvilli**
- Tight junctions bind these cells e olfactory cells.
- They secrete **odorant binding proteins &** express **abundant ion channels** → role in signal conduction of smell sensation . These cells played main role in smell loss (anosmia) in COVID 19



3- Basal cells:

- Small pyramidal cells e basophilic cytoplasm
- Act as stem cells for both olfactory & supporting cells

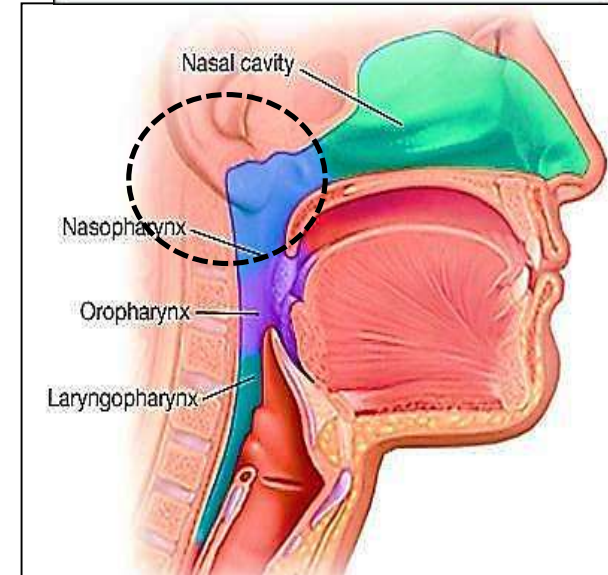
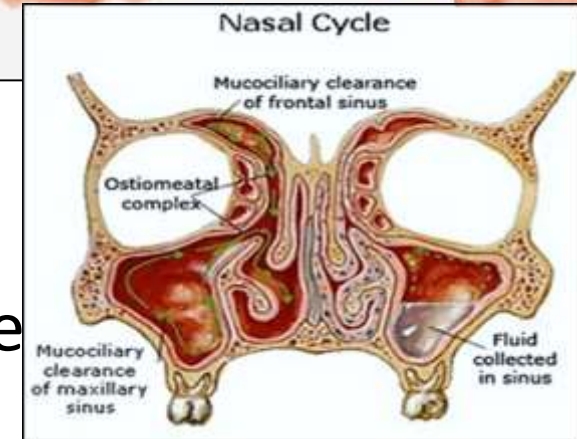
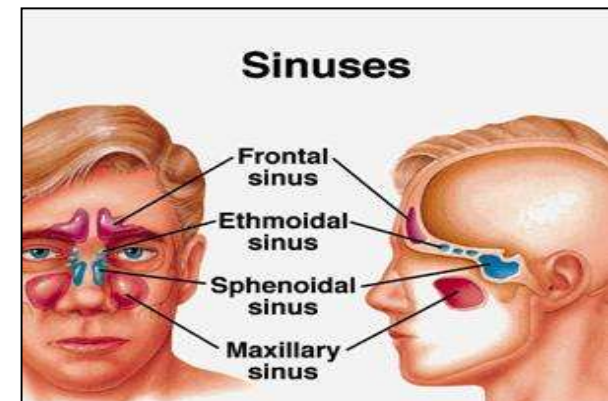
Paranasal sinuses (Bilateral)

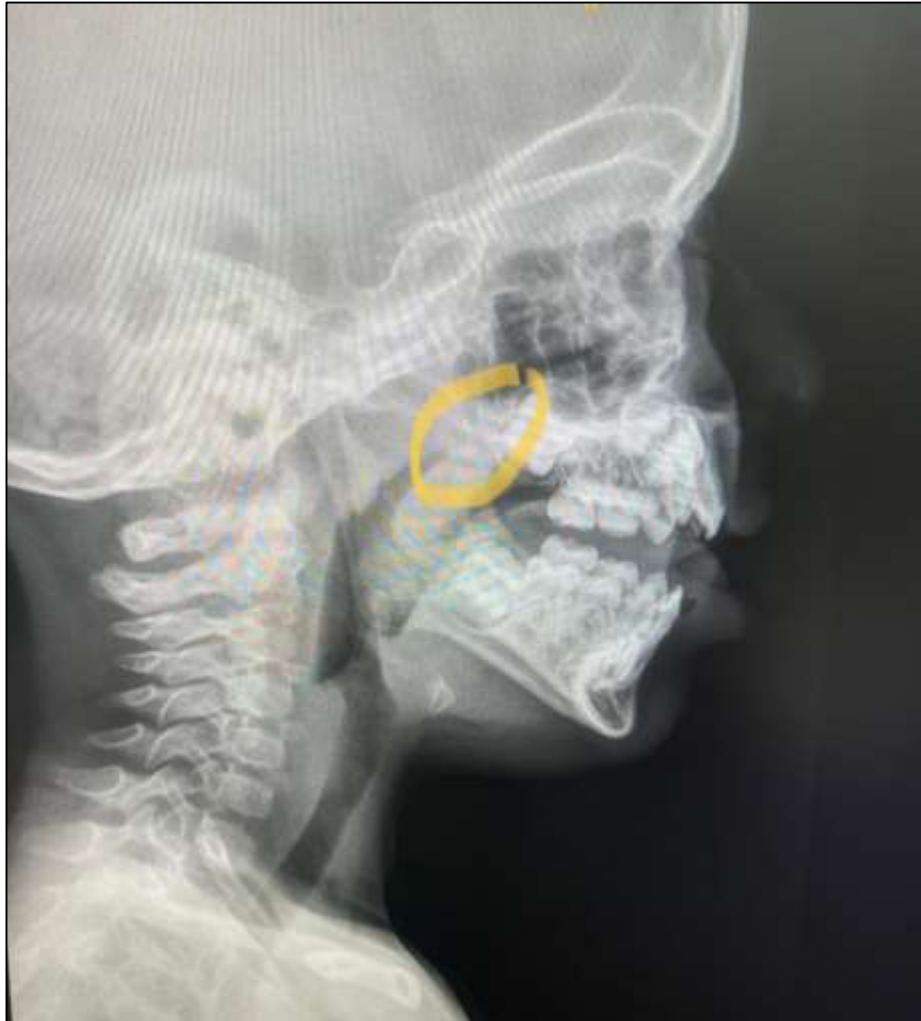- Frontal, Ethmoidal, Sphenoidal
Maxillary
- These cavities **open in nasal cavities**
- Lined e **thin** respiratory epith.
e few goblet cells

Chronic sinusitis = immotile cilia syndrome

Nasopharynx

- Lined e respiratory epithelium
- Its lamina propria contains
**pharyngeal tonsil & openings of
Eustachian tubes**

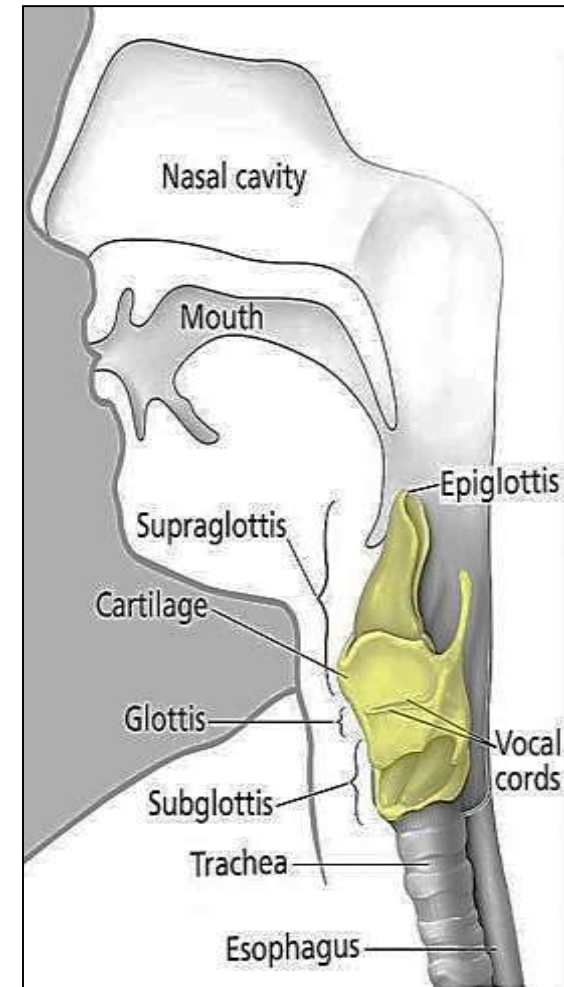




(Enlarged pharyngeal tonsil = adenoids)

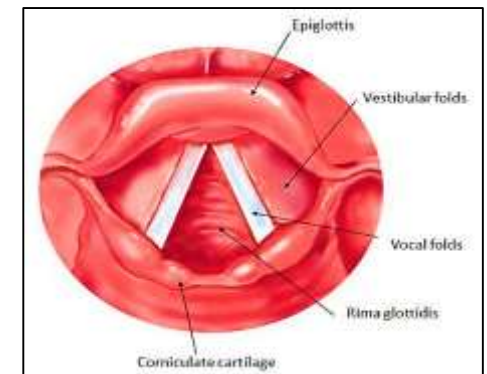
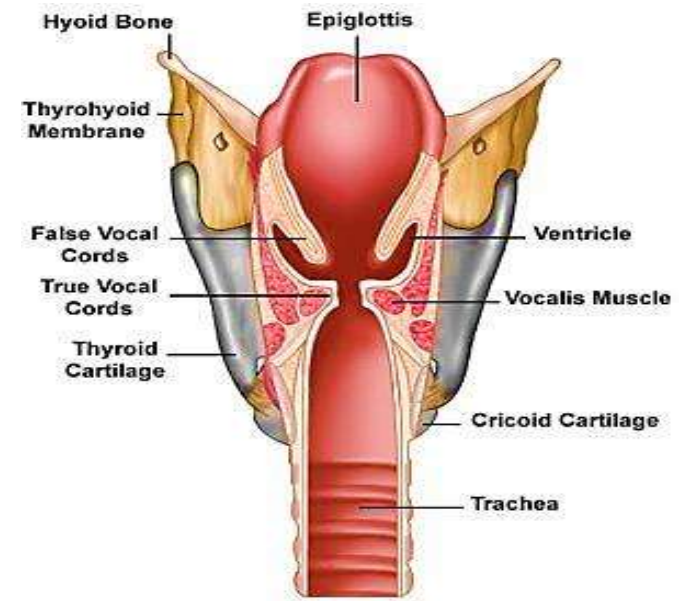
Larynx:

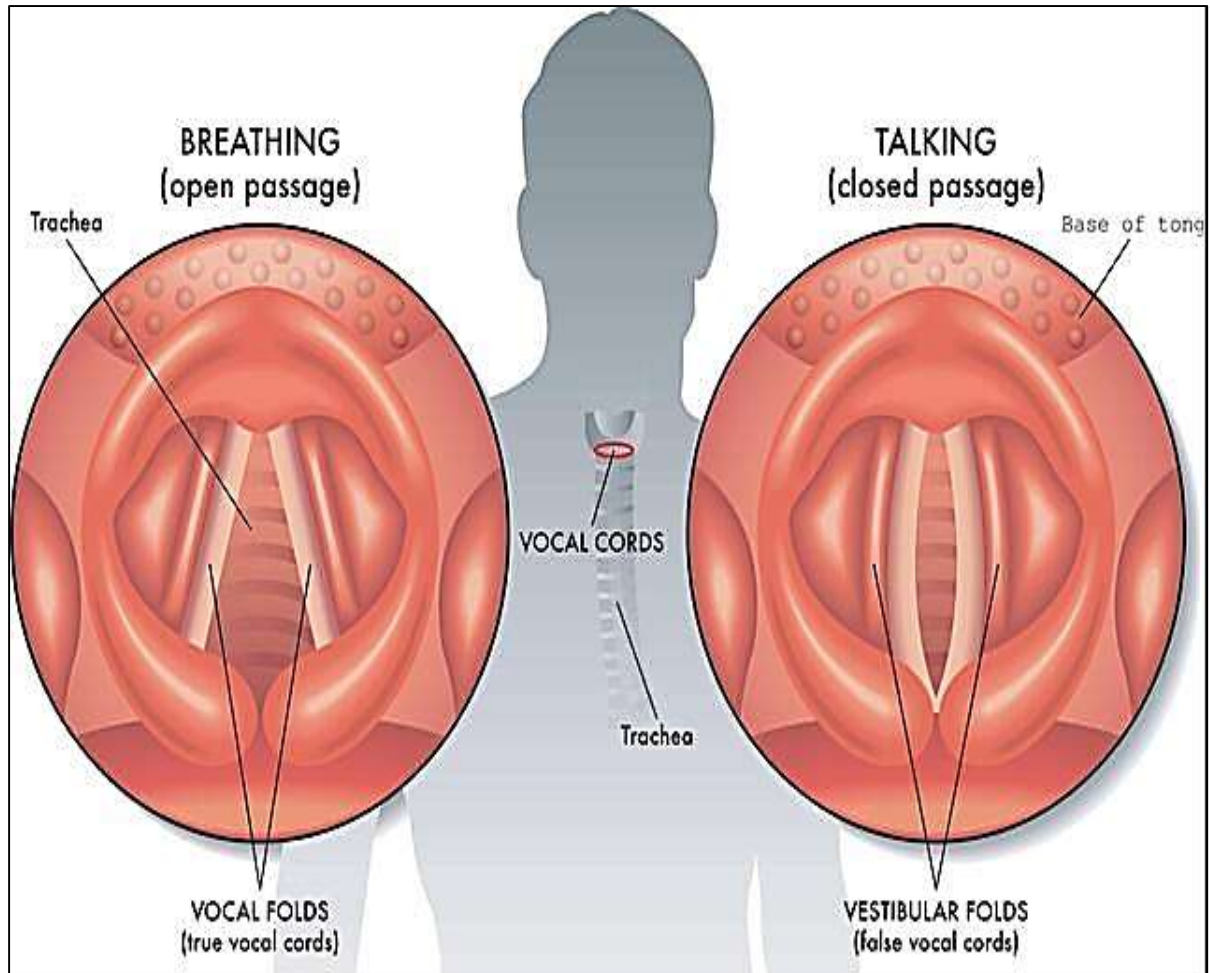
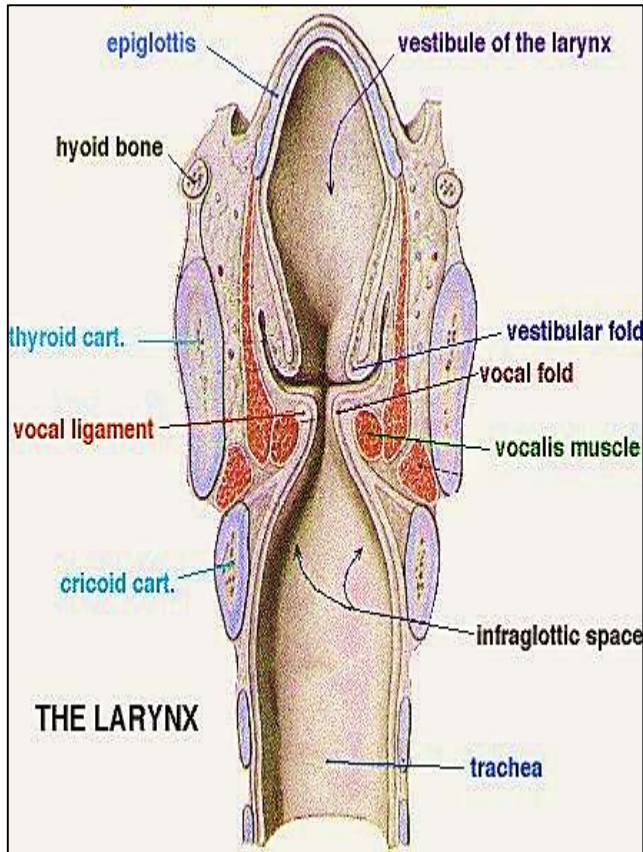
- At the beginning of trachea (4x4cm)
- Its beginning is guarded by epiglottis
- Has 2 functions:
 - ✓ production of voice (vocal cords)
 - ✓ Prevent food & fluid from entering the Trachea through the epiglottis (Epiglottis has **elastic** cartilage)
- It is lined with **respiratory epithelium**



Vocal cords:

- 2 pairs of mucosal folds extend in lumen of larynx
- False vocal cords (Upper pair)
 - called (**vestibular folds**)
 - covered e **respiratory epith.**
 - guard against entrance of food into larynx (made of vestibular ligament)
- True vocal cords (Lower pair)
 - covered e **non-keratinized stratified squamous epith.**
 - made of **ligaments (vocal lig.)** & **skeletal ms. (Vocalis ms.)**
 - tension of cords & distance between them produce sound

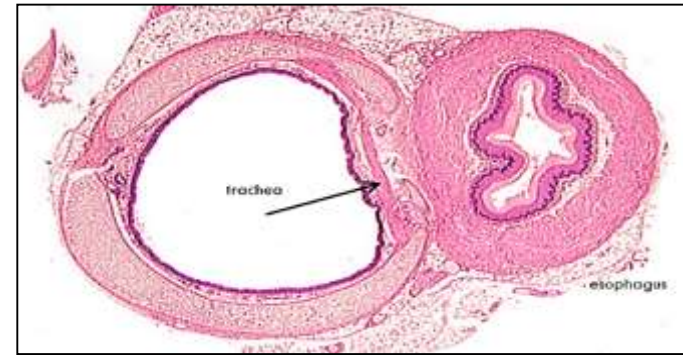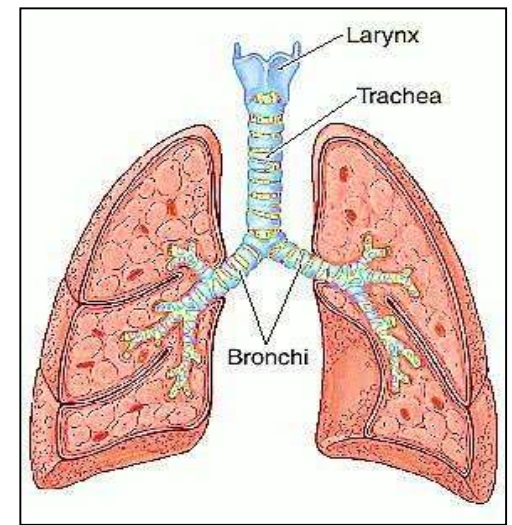




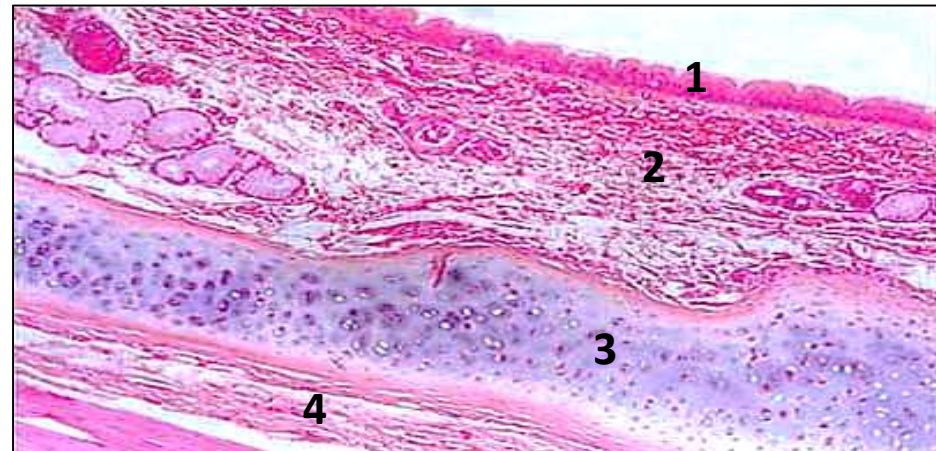
True and false vocal cords and the importance of the ventricle

Trachea

- Tube (12- 14 cm) extends from larynx to bifurcation of bronchi
- Kept open by about 20 C- shaped (horse shoe) cartilage rings (hyaline cartilage)



- Its wall is formed of 4 layers:
 1. Mucosa
 2. Submucosa
 3. Hyaline cartilage
 4. Adventitia

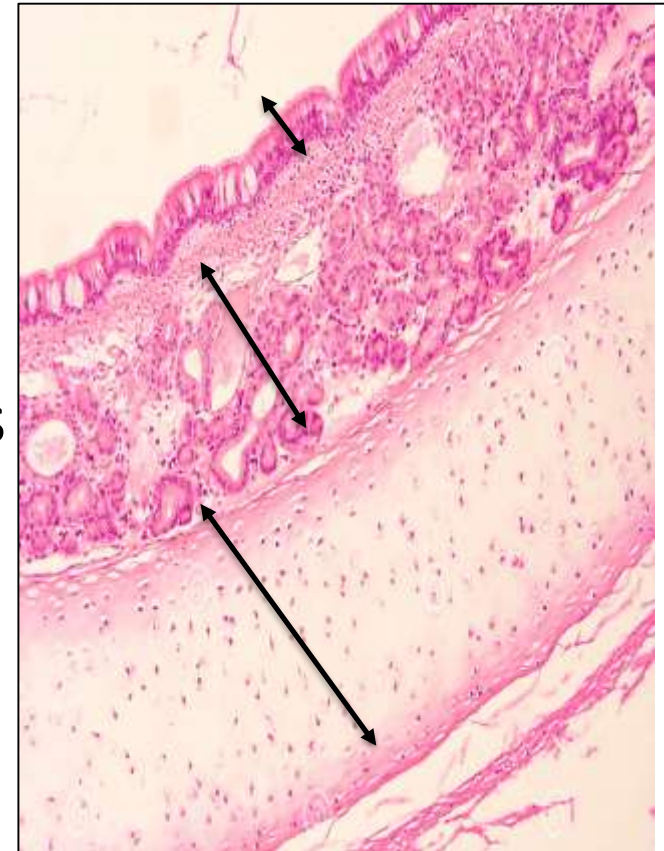


Wall of trachea:

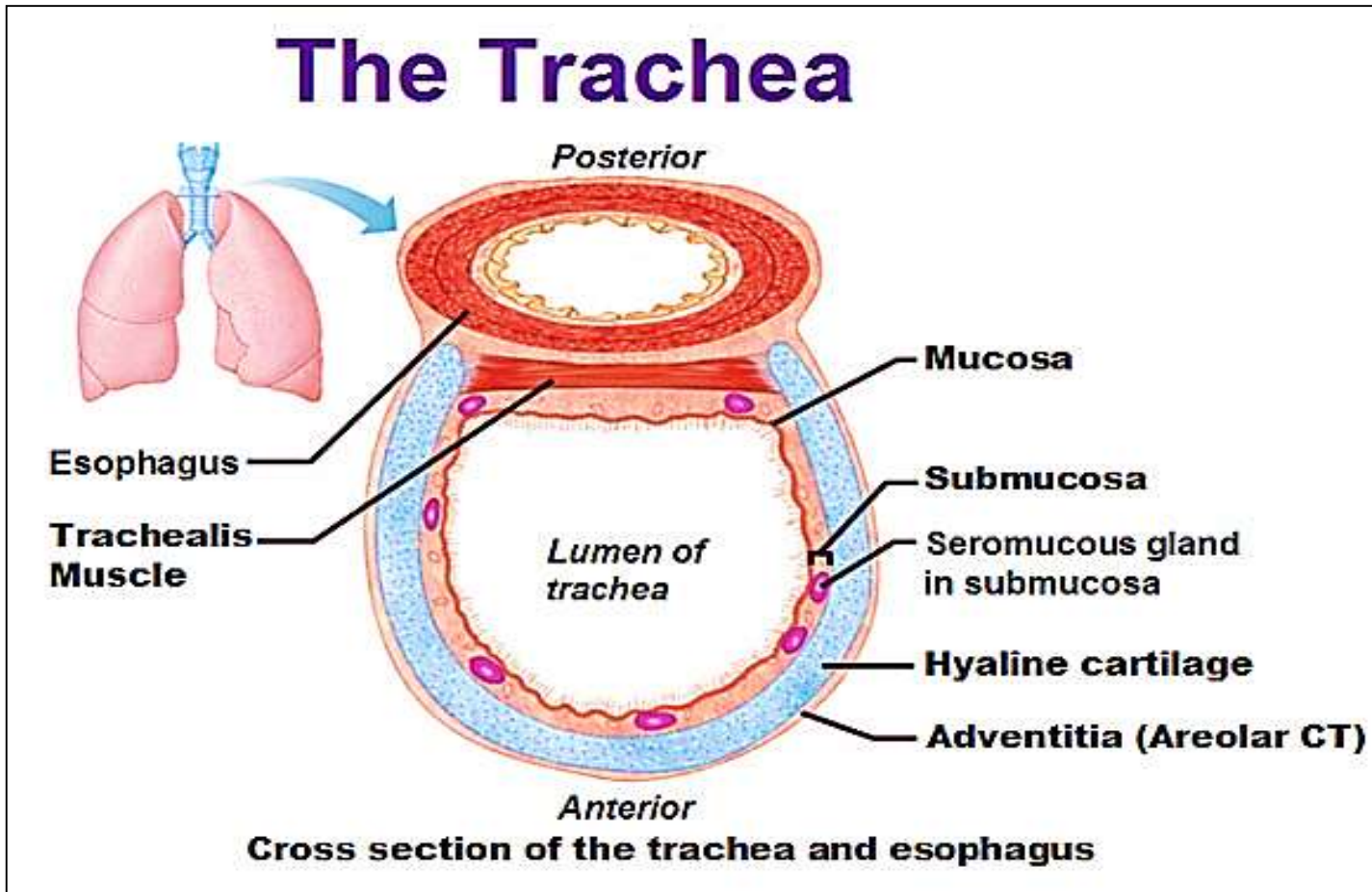
- Mucosa: epithelium – lamina propria – elastic fibers

Epithelium: respiratory epithelium

- Submucosa: BV, nerves, elastic fibers
Lymphoid nodules, Tracheal glands
- Cartilage layer: C- shaped cartilage rings, the gap between cartilage ends connected by elastic ligament & **Trachealis *ms*** (*smooth ms*)
- Adventitia: loose CT



The Trachea

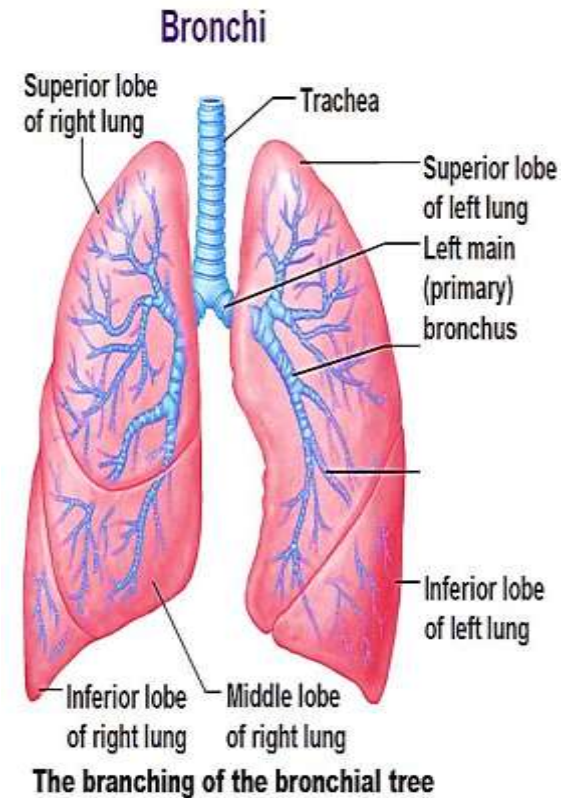


Contraction of the trachealis ms. is important for the Cough Reflex

Contraction → narrowing the tracheal lumen → ↑ the velocity of the expelled air → squeezed out → cough

Bronchial tree

- ✓ Primary (Extra pulmonary) bronchi
 - ✓ Secondary (Intra-pulmonary) bronchi
 - ✓ Bronchioles
 - ✓ Terminal bronchioles
- 1ry bronchi: RT & LF → similar to trachea
(but cartilage is a complete ring)



- 2ry bronchi: within the lung → divide to give 3ry bronchi
Its wall is formed of 4 layers (NO Submucosa):
 - Mucosa
 - Muscularis
 - Cartilage plates (isolated plates)
 - Adventitia

- **Mucosa**: ↑folded, respiratory epith., ↓goblet cells, lamina propria has elastic fibers & MALT (**mucosa associated lymphatic tissue**)

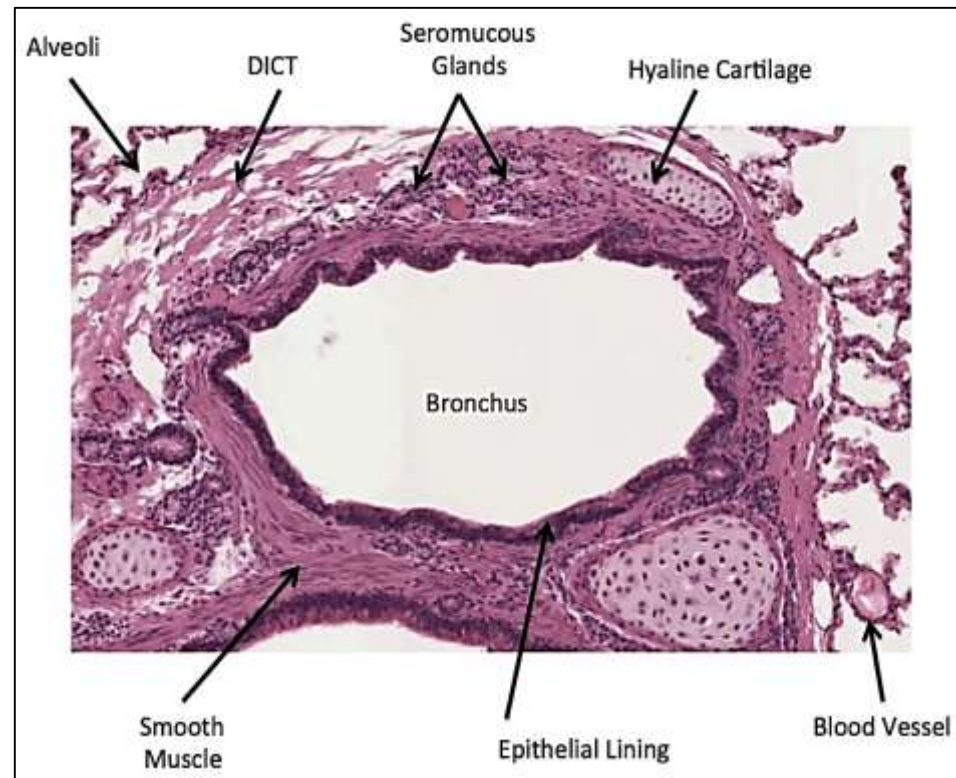
- **Musculosa**: spiral layers of smooth ms. encircling the mucosa

- **Cartilage plates**:

muco-serous glands &

lymph nodules found between cartilage plates

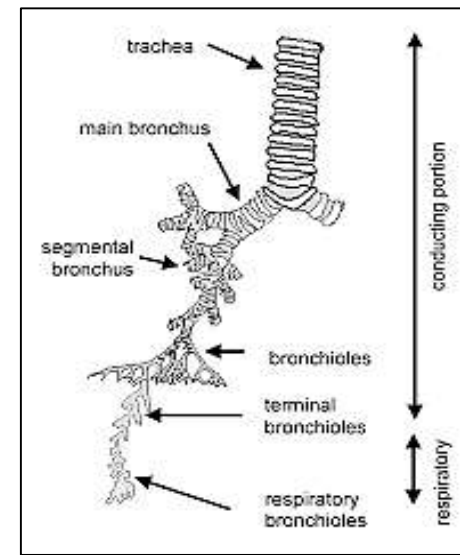
- **Adventitia**:



Structure of 2ry, 3ry bronchi

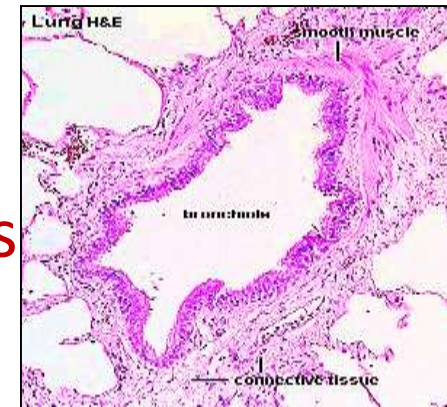
■ Bronchioles

- Small airways 5 - ↓ mm
- Its wall has (**No submucosa, No cartilage, No glands, No lymphatic nodules**)
- Its wall formed of 3 layers



Mucosa:

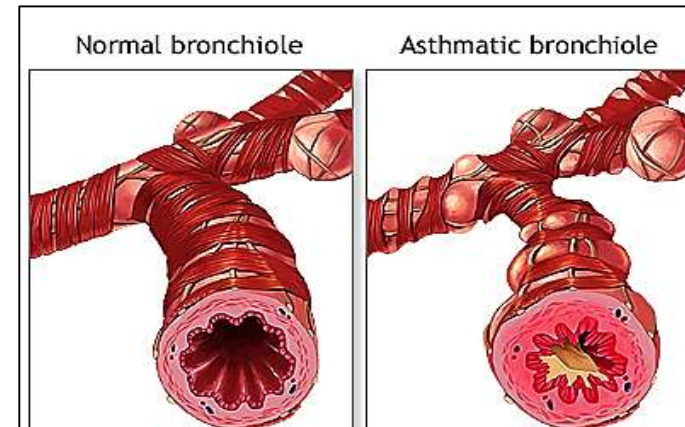
- **Simple columnar ciliated** epithelium e
Clara cells & NE cells & neuroepithelial bodies
(chemosensory receptors → O₂ level)



Musculosa:

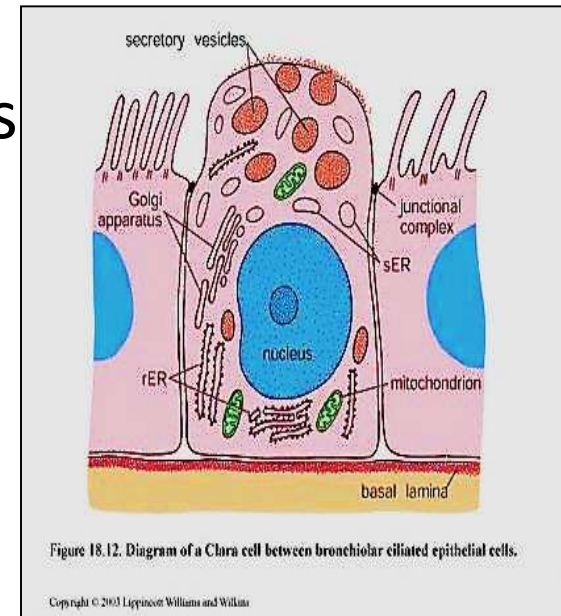
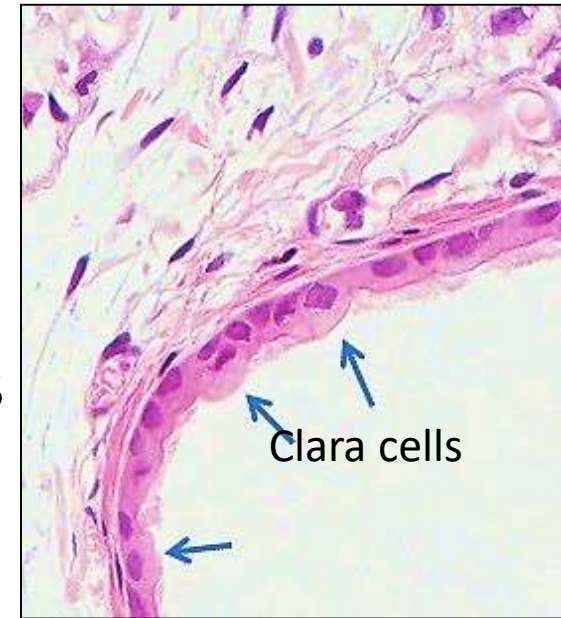
complete layer of circularly arranged smooth ms. (Asthma attacks)

Adventitia

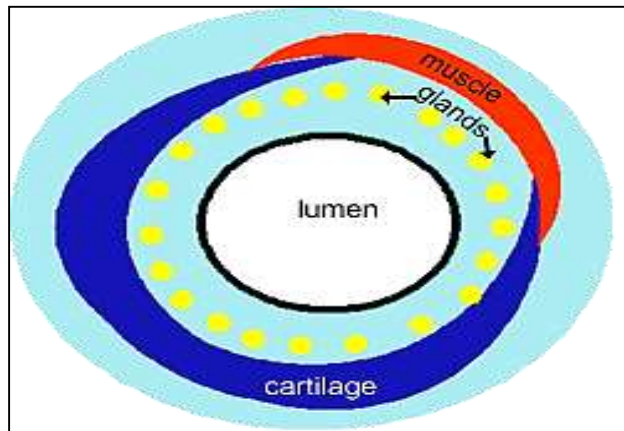


Clara Cells:

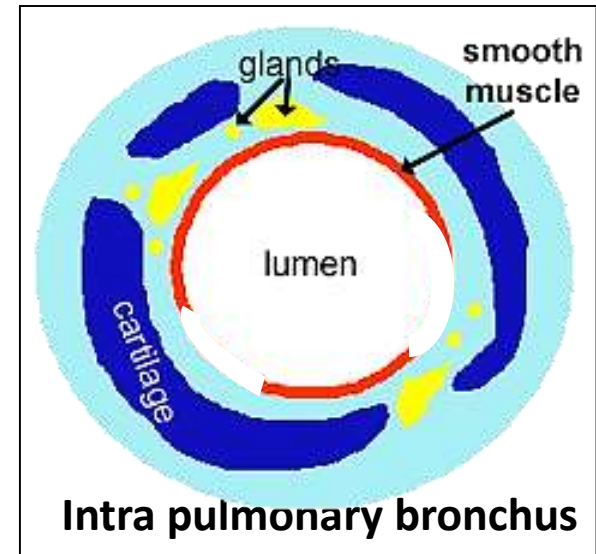
- Also called **club cells** or **bronchiolar exocrine cells**
- Dome-shaped, non-ciliated,
- Cytoplasm has lots of secretory granules (not mucus) basal rER, apical sER
- Function:
 1. Defensive role :glycoprotein granules (contain proteolyase & oxidase & cytokines)
 2. Degradation of inhaled toxins (sER)
 3. Secretion of surfactant-like substance to prevent collapse of bronchioles
 4. Act as stem cells
 5. Mutation → adenocarcinoma of lung



Difference between structure of wall of trachea vs. Wall of intra-pulmonary bronchi & bronchiole

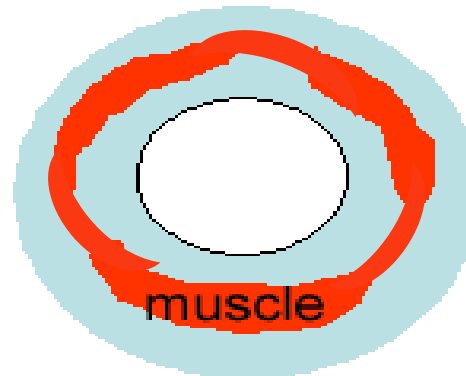


Trachea



Intra pulmonary bronchus

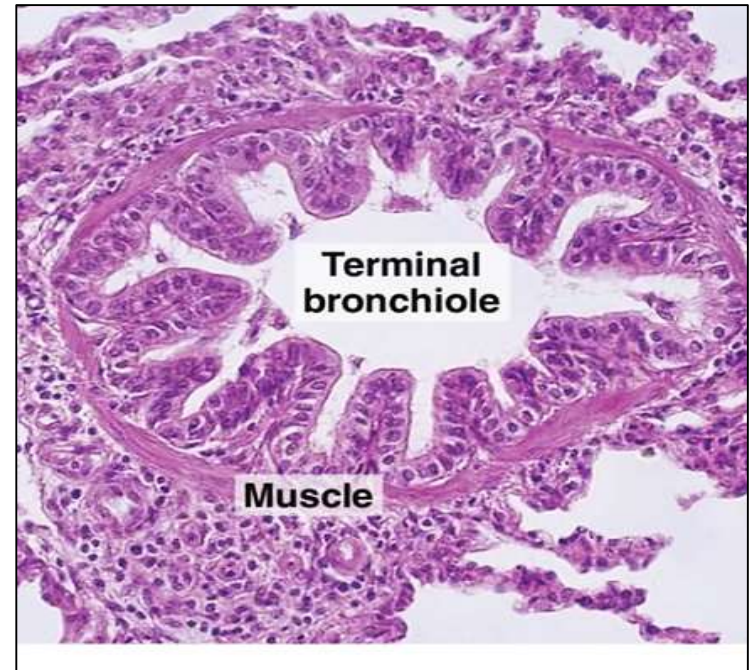
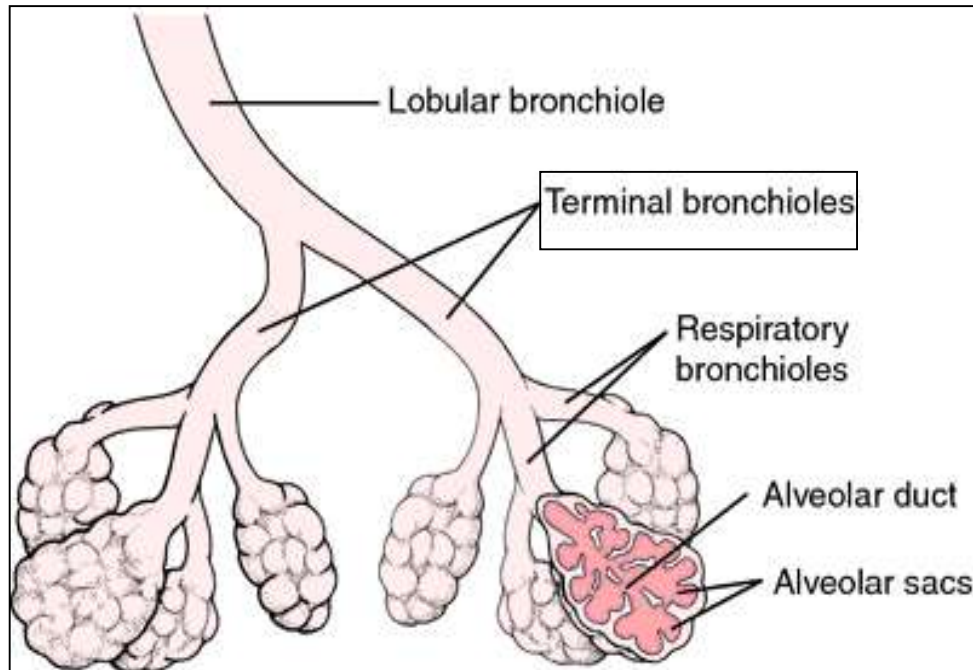
N.B: Smooth muscle component increases in proportion and continuity as the air passage decreases in size. Then decrease again till disappear in the respiratory portion



Bronchiole

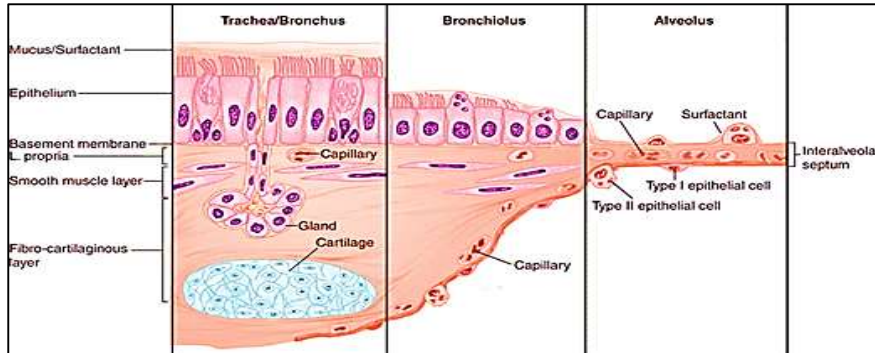
N. B: if cartilage is present, it is a "bronchus," but if cartilage is absent the airway is a "bronchiole."

■ Terminal bronchioles:



- The smallest & last part of conducting portion
- Lining epithelium: **Simple cubical ciliated e Clara cells**
- **Secondary pulmonary lobule:** is the lobule supplied by a terminal bronchiole that branches into respiratory bronchioles.

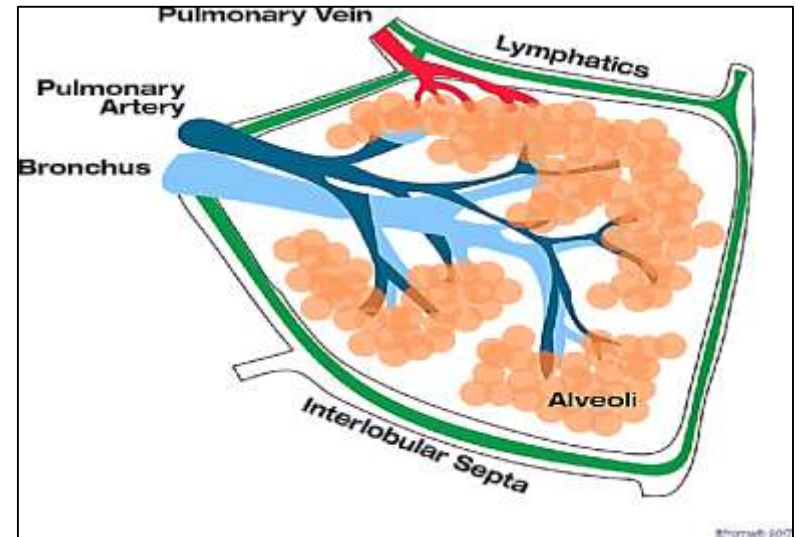
Changes occur in the epith. of conducting portion as it branches



Bronchial tree can be as small as 0.5 mm diameter and as they get smaller some changes occur. First, the glands disappear, then goblet cells. There is also an epithelial transition from the pseudostratified RE to simple columnar, then to a low cuboidal type. Along the way ciliation disappears.

Why secretion ends before ciliation does.?

Pulmonary lobule vs pulmonary acinus

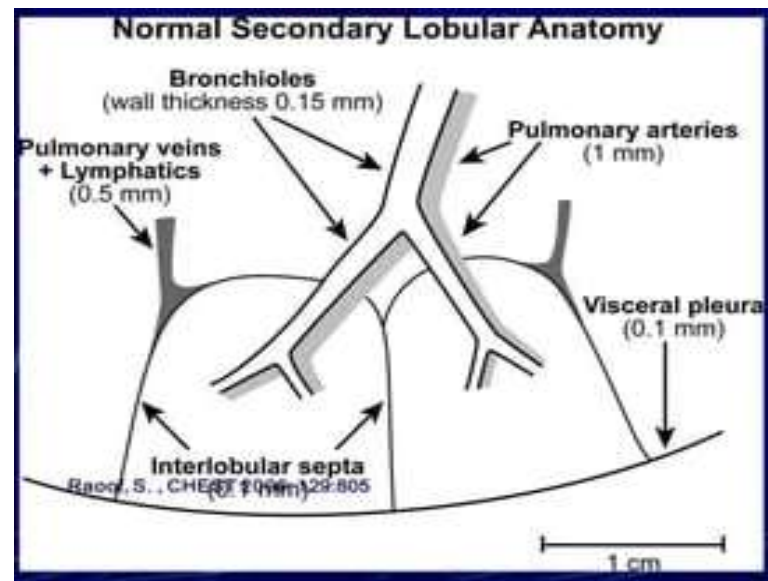
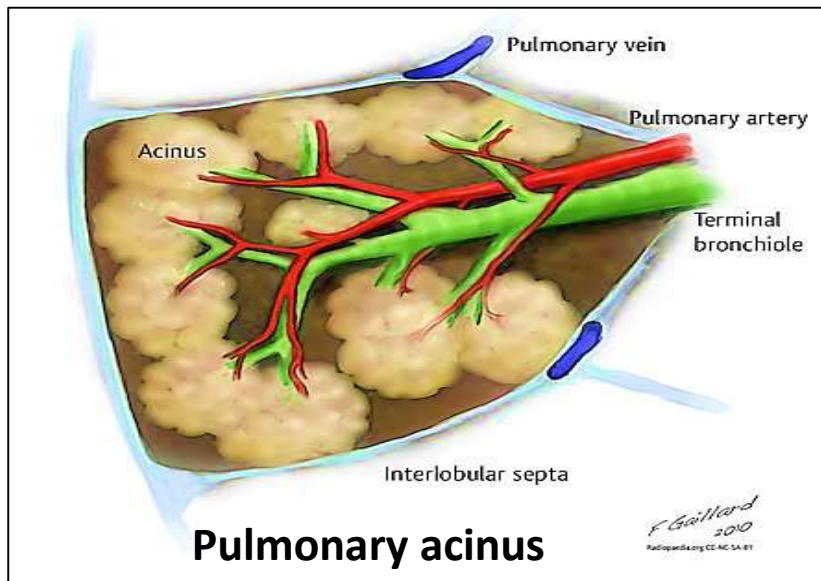


2ry Pulmonary lobule:

Bigger, lung unit supplied by 3-5 terminal bronchioles derived from **single bronchus** & surrounded by CT (3- 12 acini & 30- 50 1 ry L.)

Pulmonary acinus: lung unit distal to **single terminal bronchiole** includes resp .B, alveolar ducts, sacs, alveoli

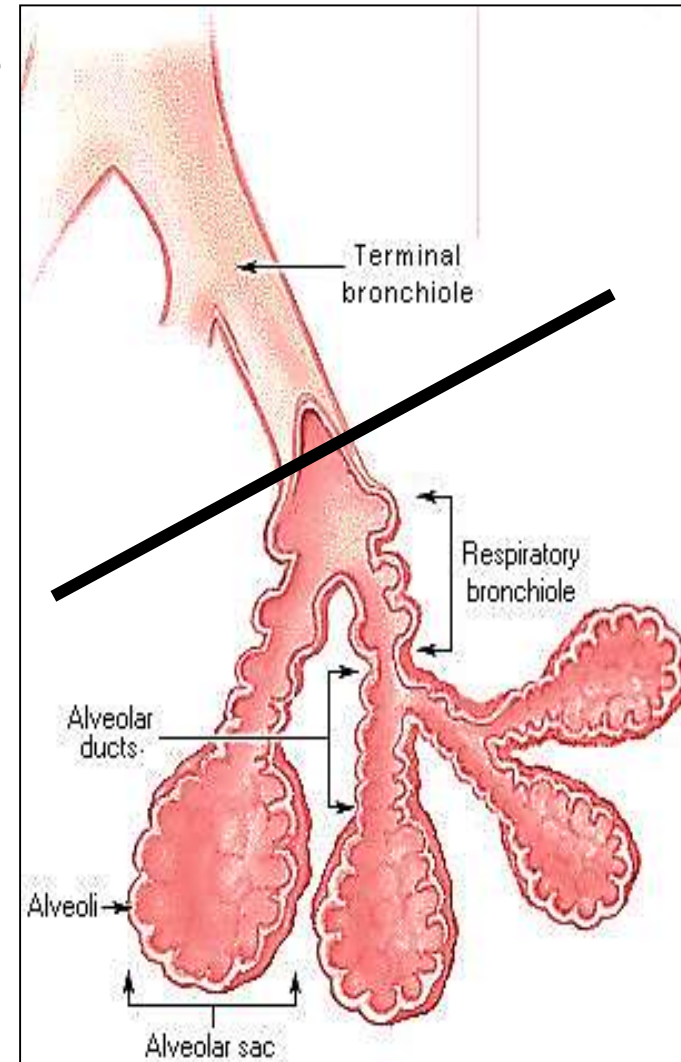
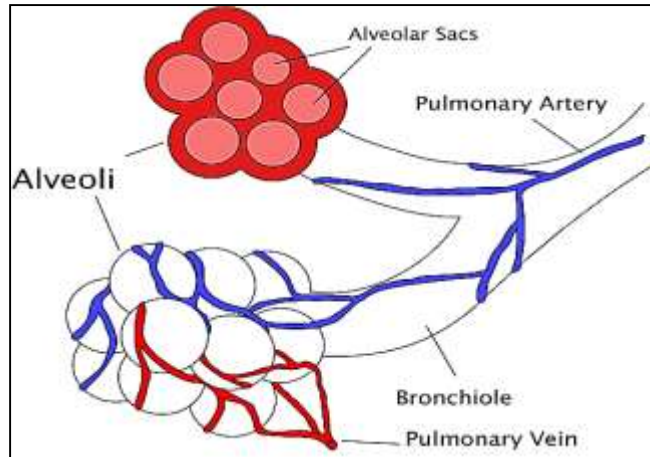
1ry pulmonary lobule : smaller than acinus includes lung unit distal to **respiratory B**, alveolar ducts, sacs, alveoli



The secondary pulmonary lobule is a fundamental unit of lung structure, and it represents the lung in miniature. Airways, pulmonary arteries, veins, lymphatics, and the lung interstitium are all represented at the level of the secondary lobule. Several of these components of the secondary lobule are normally visible on **thin-section computed tomographic (CT) scans of the lung**. The recognition of lung abnormalities relative to the structures of the secondary lobule is fundamental to the interpretation of thin-section CT scans. **Pathologic alterations in secondary lobular anatomy visible on thin-section CT scans include interlobular septal thickening and diseases with peripheral lobular distribution, centrilobular abnormalities, and panlobular abnormalities.** The differential diagnosis of lobular abnormalities is based on comparisons between lobular anatomy and lung pathology.

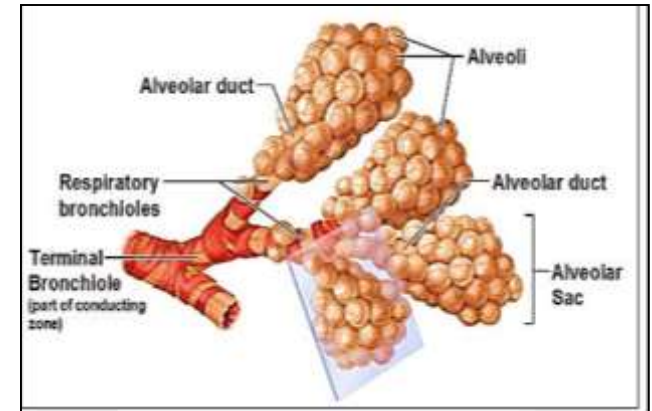
B- respiratory portion

- Is where gas exchange takes place
- Includes:
 1. Respiratory bronchioles
 2. Alveolar ducts
 3. Alveolar sacs
 4. Alveoli



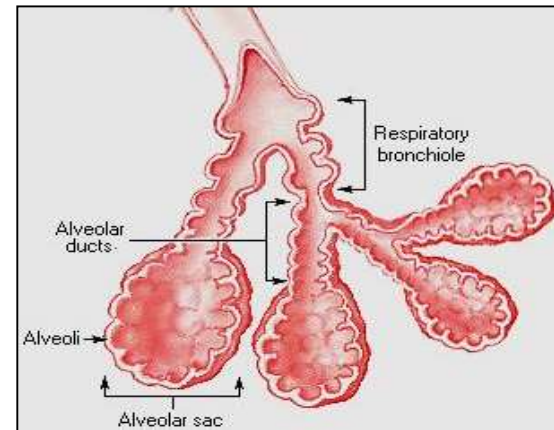
Respiratory bronchioles (RB):

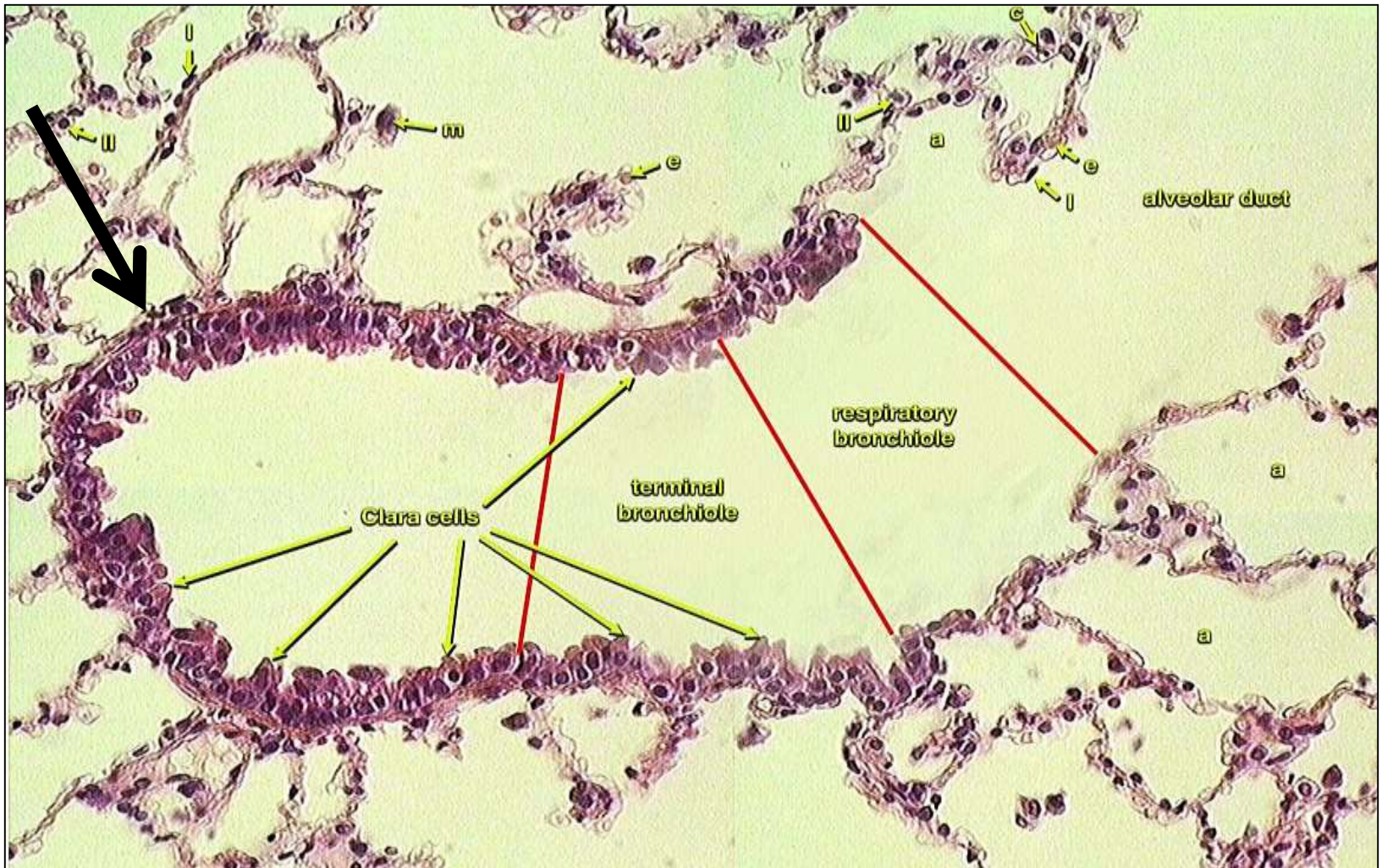
- **Transitional part** between conducting & respiratory portions, still bronchiole but shorter & thinner
- Lined with simple cubical ciliated e
Clara cells with Some alveoli open
in its wall



Alveolar ducts (AD):

- Alveoli open along its wall
- Lined e **squamous & alveolar cells**
- At the distal end of AD **smooth m. disappear**, elastic & collagen fibers provide the only support





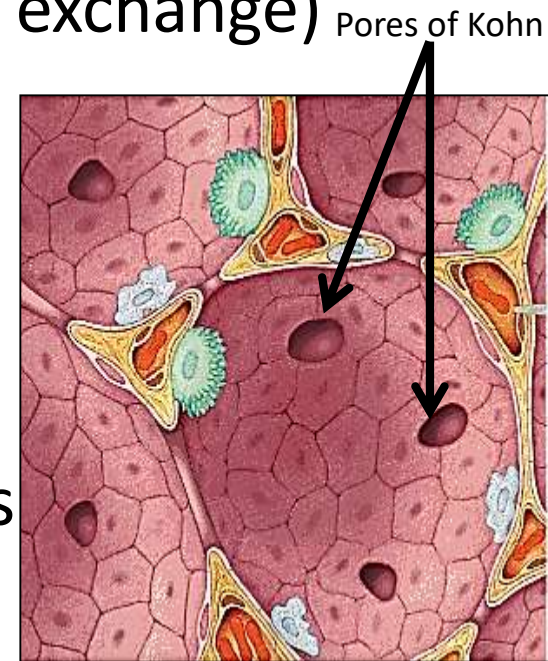
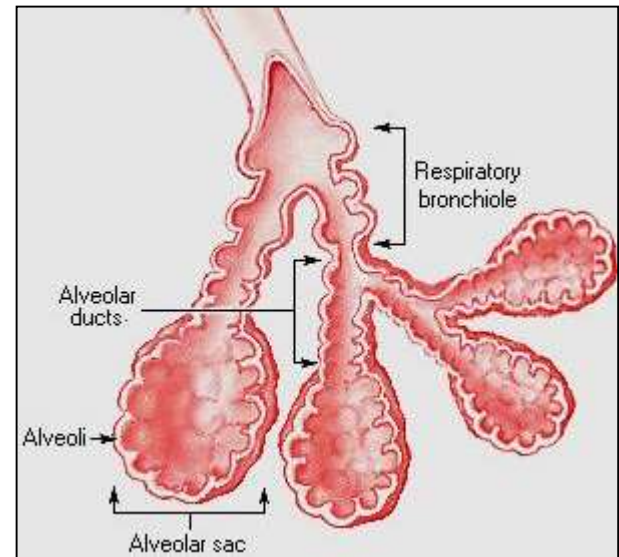
Section is showing **terminal bronchiole** and parts of the respiratory portion

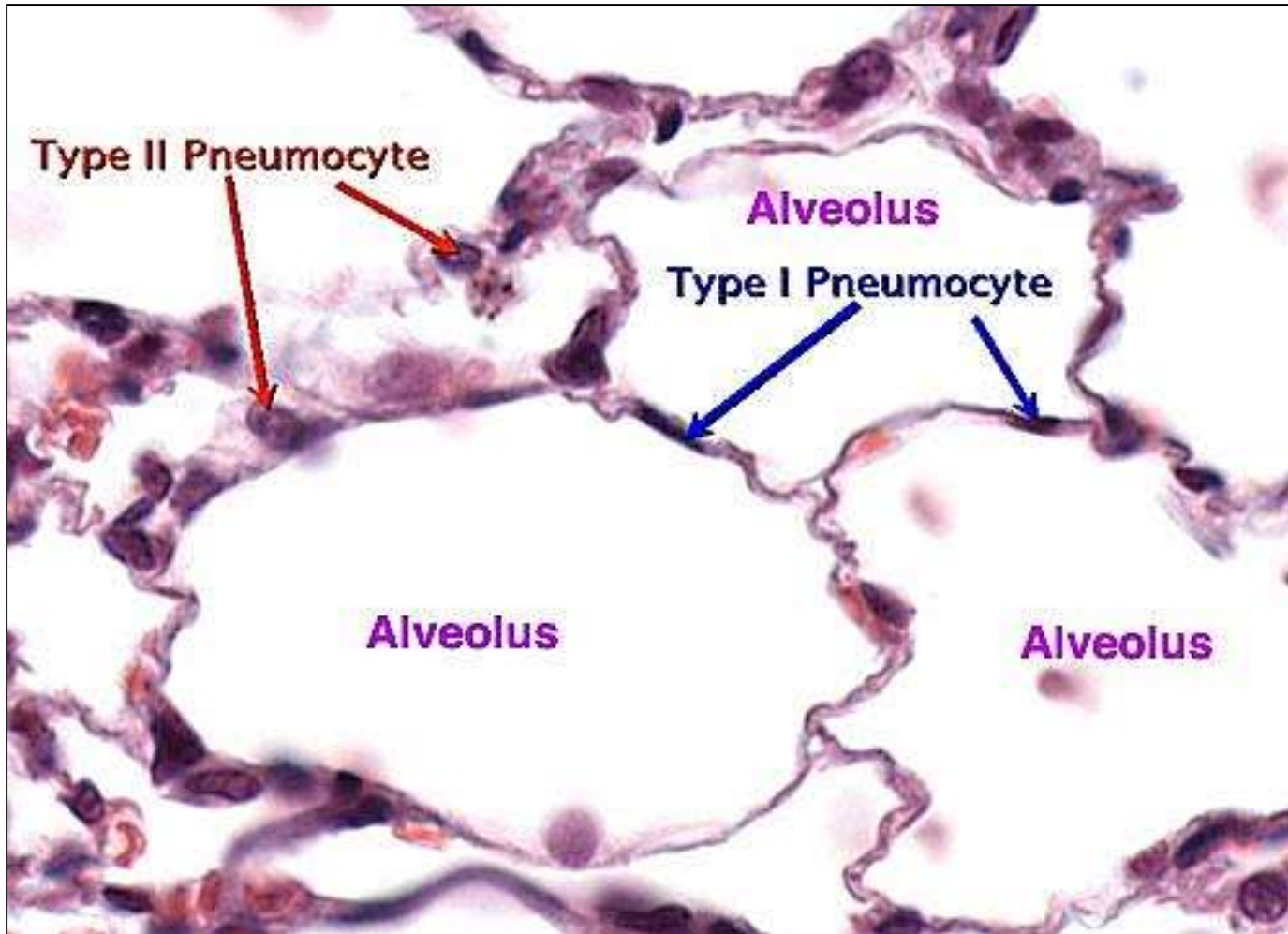
Alveolar sacs (AS):

- Group of alveoli opens into common Central space
- Lined e **alveolar cells**

Alveoli:

- Structural & functional units of lung (gas exchange)
- Alveoli found open into RB, AD, AS
- They separated by **inter-alveolar septa**
- **Alveolar pores of Kohn** present in walls between alveoli (collateral ventilation ??)
- Lined e **alveolar epith.** formed of **2** types of cells **type I & type II pneumocytes**

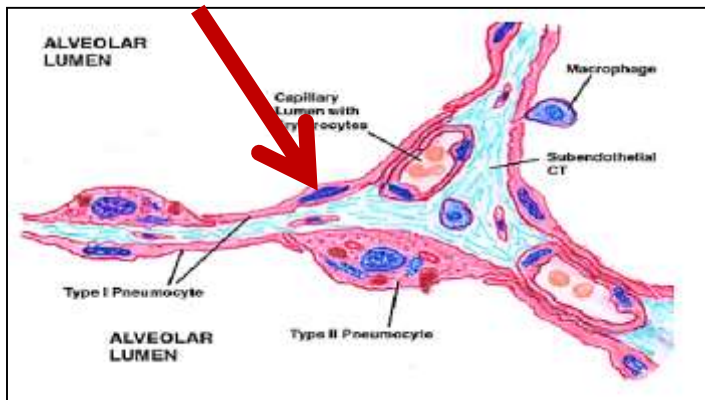




Type I and type II pneumocytes

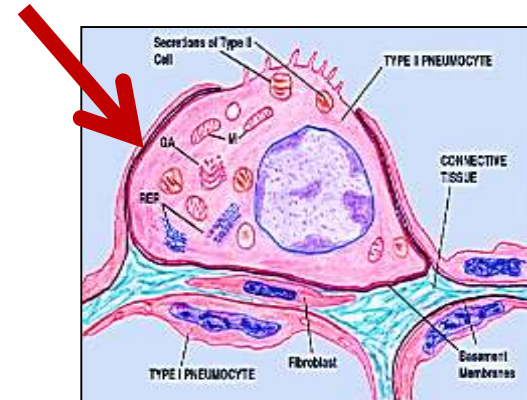
Lining epithelium of alveoli

Type I pneumocytes



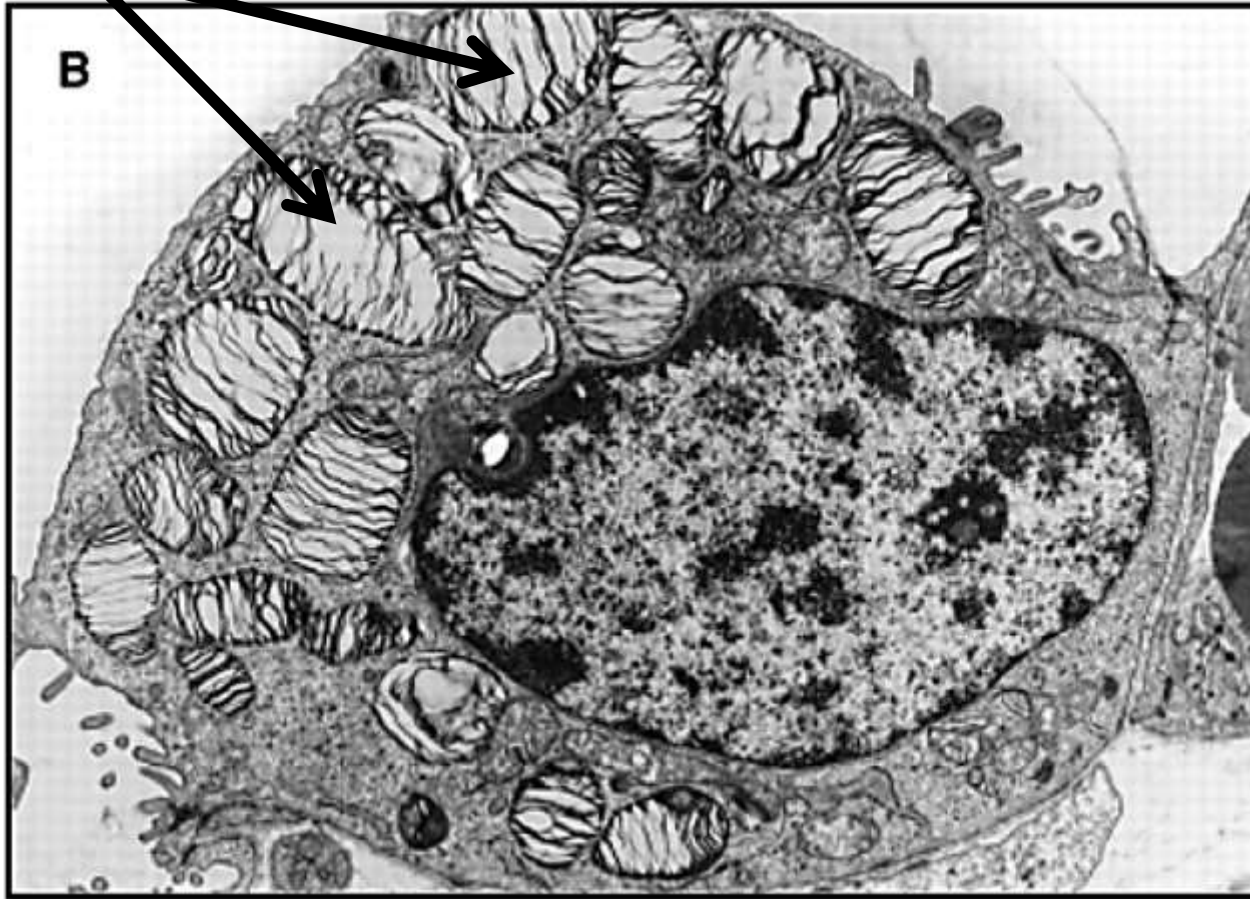
- Cover **97%** of alveolar surface
- **Flat simple squamous cells** e flat nuclei
- cytoplasm has **few organelles**
- Cells joined together by **tight junctions**
- **Gas exchange** occurs through them

Type II pneumocytes



- Cover **3%**
- **Cuboidal cells** e central nuclei & foamy cytoplasm
- Free surface has **short microvilli**
- Cytoplasm rich in **organelles, multilamellar bodies**
- **Secrete surfactant** (\downarrow **tension** & **bactericidal**)
- Act as stem cells
- Have ACE2 receptors where Covid-19 spikes attack

Multilamellar bodies

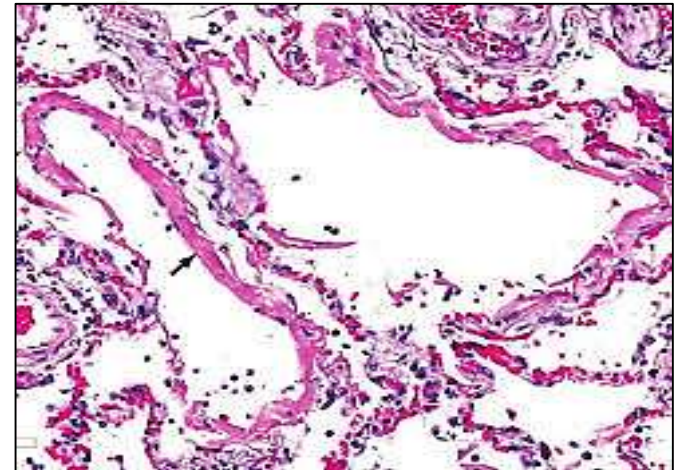
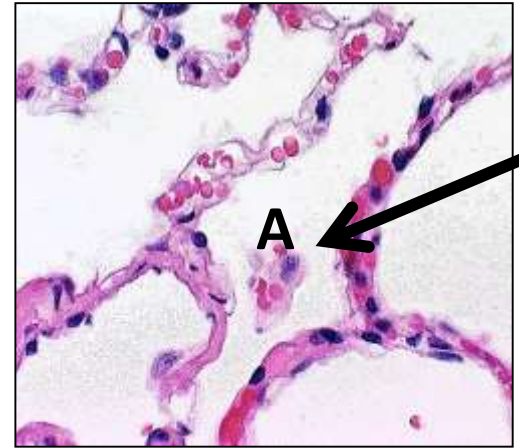


(E/M of type II pneumocyte)

Respiratory Distress Syndrome (RDS): occurs In premature babies because surfactant appears in last weeks of gestation

Inter-alveolar septa:

- Delicate walls separate adjacent alveoli
- Have **richest capillary network**
- **Where Gas exchange Take place**
- **Contains Blood –air barrier**
- **Rich in elastic & reticular fibers**
(support & prevent over expansion)
- No smooth ms. cells
- Contains extravasated leucocytes
(**monocytes**), which will migrate through the wall →
to the lumen and become alveolar macrophages (A)
- This septa are destructed in emphysema & Covid - 19



Blood- air barrier (respiratory membrane)

✓ Its where O₂& CO₂ cross for exchange

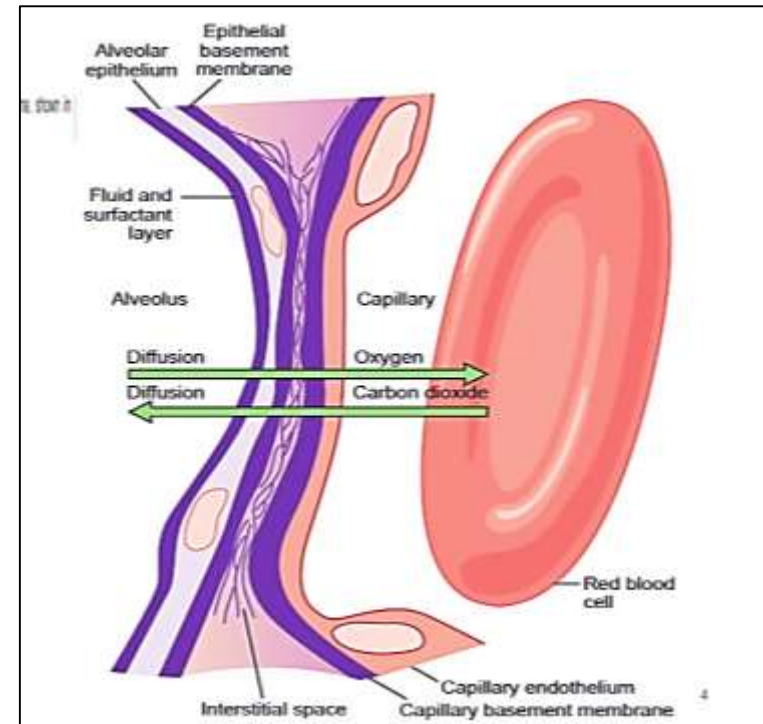
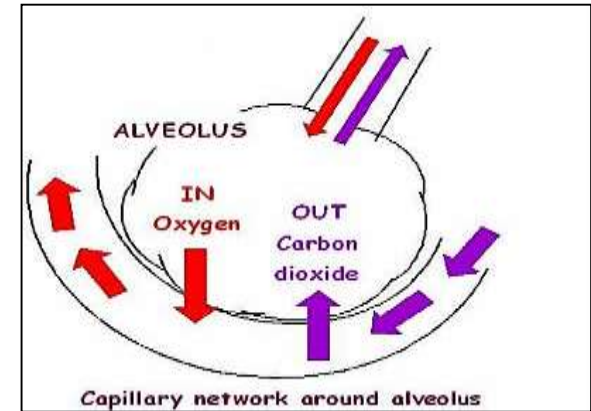
✓ Composed of 4 layers:

■ Thin film of **surfactant** on the surface

■ Cytoplasm of type I **pneumocyte**

■ **Fused basal lamina** of type I pneumocytes + capillary endothelia cells

■ Cytoplasm of **endothelial cells**



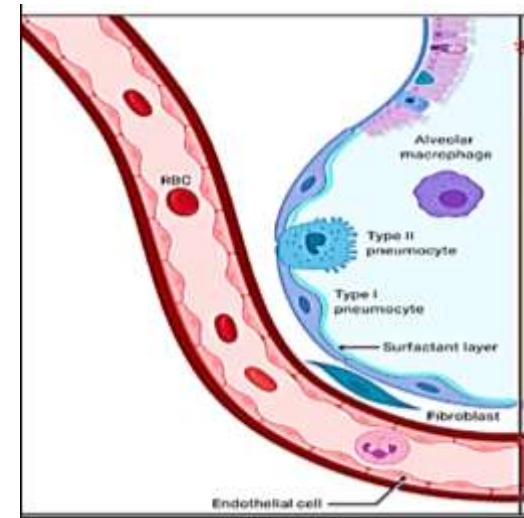
Alveolar phagocytes

- Blood monocytes → CT in alveolar septa → lumen of alveoli → **macrophages**

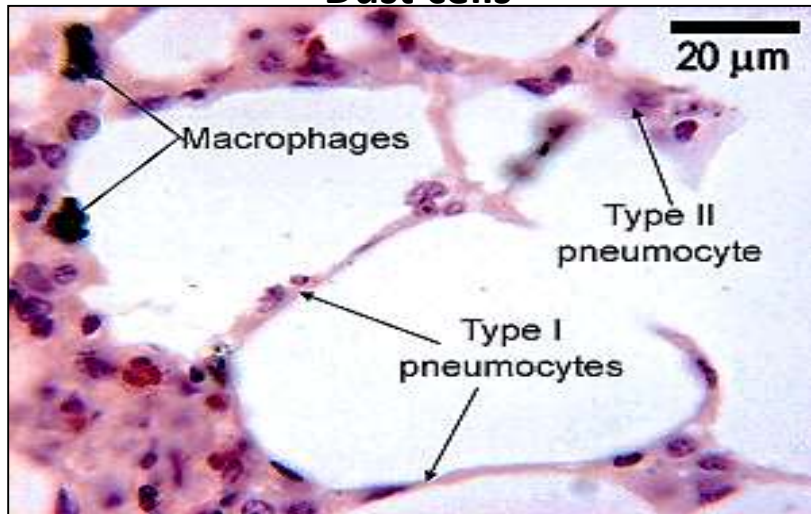
- **2 types** of alveolar macrophages:

Dust cells: macrophages engulfing dust particles

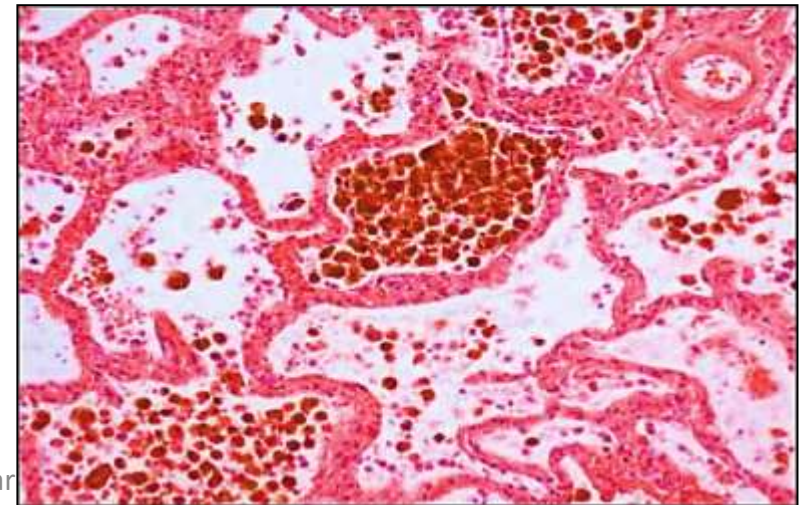
Heart failure cells: macrophages engulfing erythrocytes (hemosiderin granules) found in congestive heart failure



Dust cells



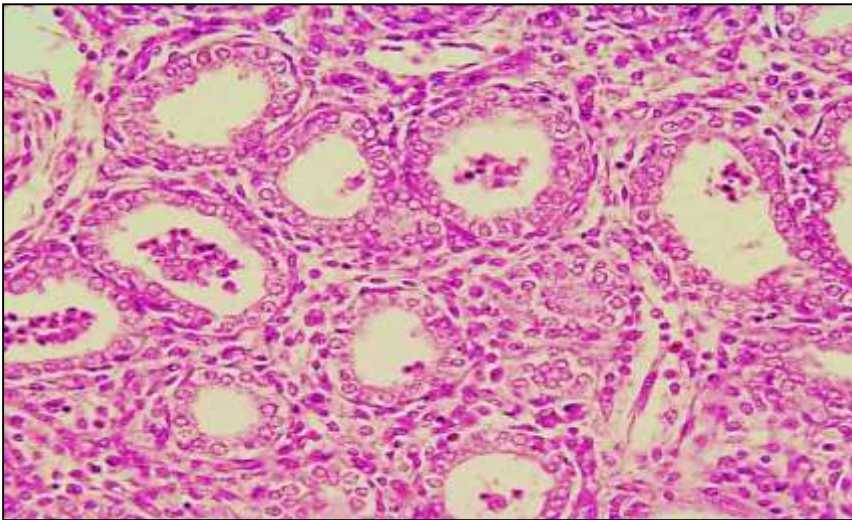
Heart failure cells



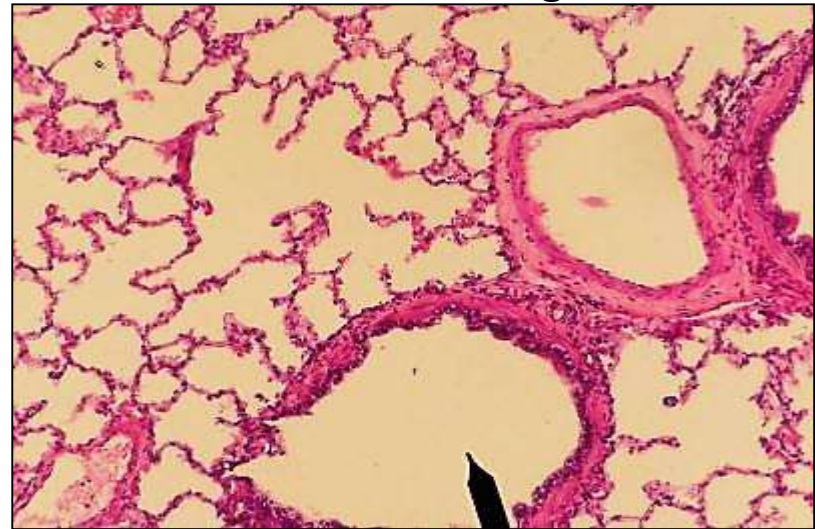
Fetal Lung

- **Lobulation** is clear due to thick CT septa
- Fetal lung **similar to gland** in histological section
- **Alveoli collapsed** lined e simple cubical epith.
- Pulmonary BV are congested
- Whole lung sinks in water

Fetal lung



Normal lung



Thank you

