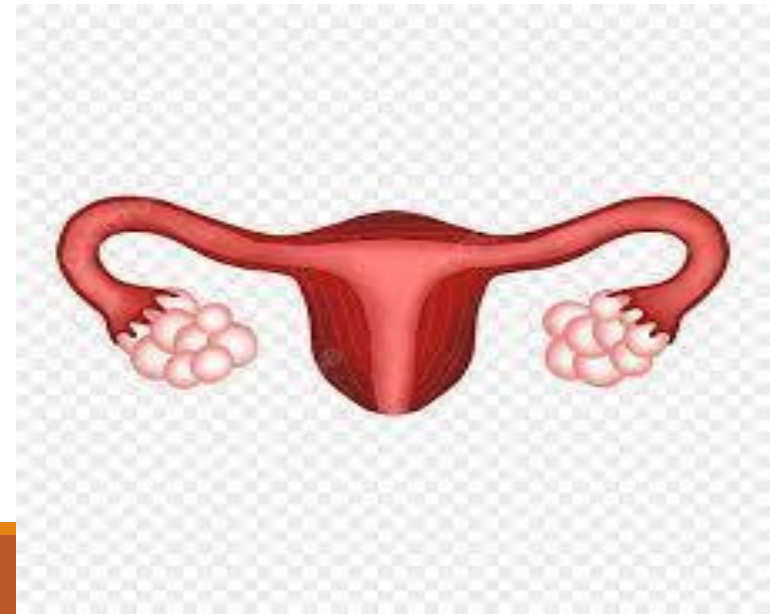

Approach to OVARIAN & endometrial CANCER

Supervised by: Dr.Omar ALDabas

- Nancy Alabed
- Mostafa Qasim
- Shahed Al-qatawneh
- Rahaf Dahamsheh
- Hamza Lafi

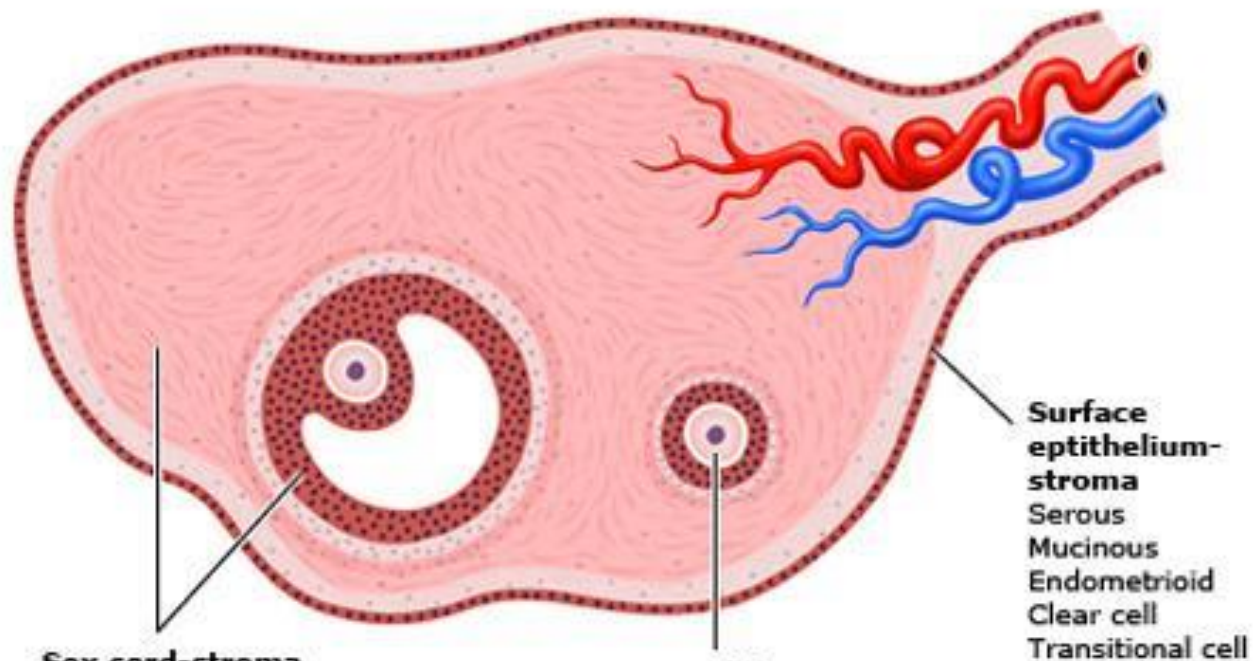


Ovarian Neoplasms

Nancy Alabed
-Mostafa Qasim

Ovarian Neoplasms

- Ovarian neoplasms arise from the surface epithelium, germ cells, and sex-cord-stromal tissue and may be benign, borderline or malignant. **These neoplasms persist unless excised.**
- Epithelial tumors account for **60-65%** of all ovarian tumors, germ cell tumors account for **30%** and sex-cord stromal tumors account for **8%**.



Sex cord-stroma
Granulosa cell
Thecoma
Fibroma
Sertoli cell
Sertoli-Leydig
Steroid

Germ cells
Dysgerminoma
Yolk sac
Embryonal carcinoma
Choriocarcinoma
Teratoma

Surface epithelium-stroma
Serous
Mucinous
Endometrioid
Clear cell
Transitional cell

Epithelial Ovarian Cancer

EPIDEMIOLOGY

- THE SECOND MOST COMMON GYNECOLOGIC MALIGNANCY IN DEVELOPED COUNTRIES.
- THE MOST COMMON CAUSE OF GYNECOLOGIC CANCER DEATH AND THE FIFTH LEADING CAUSE OF CANCER DEATH IN WOMEN (DIAGNOSED IN LATE STAGES).
- THE MAJORITY OF OVARIAN CANCERS ARE DIAGNOSED AT AN ADVANCED STAGE : CONFINED TO PRIMARY SITE (15 %); SPREAD TO REGIONAL LYMPH NODES (17 %); DISTANT METASTASES (61%); AND UNSTAGED (7 %).
- THE MAJORITY OF OVARIAN MALIGNANCIES (95 %) ARE DERIVED FROM EPITHELIAL CELLS; THE REMAINDER ARISE FROM OTHER OVARIAN CELL TYPES (GERM CELL TUMORS, SEX CORD-STROMAL TUMORS).
- SEROUS CARCINOMA, THE MOST COMMON HISTOLOGIC SUBTYPE OF EPITHELIAL OVARIAN CARCINOMA (75 PERCENT OF EPITHELIAL CARCINOMAS).

Risk factors

1) Age:

- The incidence increases with increasing age.
- The average age at diagnosis of ovarian cancer is 63 years old.
- The age at diagnosis of ovarian cancer is younger among women with a hereditary ovarian cancer syndrome.

2) Reproductive and hormonal factors:

- 1- Early menarche (< 12 years)
- 2- late menopause (> 52 years)
- 3- Nulliparity
- 4- Infertility(ovulation induction)
- 5- Endometriosis
- 6- Polycystic ovarian syndrome
- 7- Postmenopausal hormone therapy (not increase the risk of ovarian cancer)
- 8- Intrauterine device (not increase the risk of ovarian cancer)

Risk factors

3) Genetic factors:

- Several ovarian cancer susceptibility genes have been identified, primarily **BRCA1** and **2** and the mismatch repair genes (associated with **Lynch syndrome**).
- The estimated lifetime risk of ovarian cancer is **35-46 % for BRCA1** mutation carriers and **13-23 % for BRCA2** mutation carriers.
- The lifetime risk of ovarian cancer in women with Lynch syndrome is **3-14 %** compared with 1.5 % in the general population.

4) Family history of ovarian cancer:

- A personal or family history of breast cancer had been thought of as a risk factor for ovarian cancer; however, BRCA gene mutations appear to account for most of this increased risk

Risk factors

5) Environmental factors:

1- Cigarette smoking : Current smoking or past smoking appears to increase the risk of mucinous ovarian cancer, but not other types of EOC.

2- Talc and asbestos : e.g, genital use of talcum powder (talc).

3- Obesity : High body mass index (BMI) appears to increase ovarian cancer risk.

- No association between alcohol intake and the risk of EOC.
- There is no clear relationship between physical activity and ovarian cancer risk.

Protective factors

- Oral contraceptives
- Multiparity
- Bilateral Salpingo-oophorectomy,
- Tubal ligation
- Hysterectomy
- Breastfeeding/pregnancy
- Intrauterine device

1. High-grade serous carcinoma (70-80 %)
2. Endometrioid carcinoma (10 %)
3. Clear cell carcinomas (10 %)
4. Mucinous carcinoma (3 %)
5. Low-grade serous carcinoma (<5 %)

Clinical features and diagnosis

- Ovarian cancer is a type of tumor which rarely causes symptoms in its early stages. The clinical presentation of epithelial ovarian carcinoma (EOC), fallopian tubal carcinoma, and peritoneal carcinoma may be either acute or subacute.
 - Women who present in an **acute** fashion are typically those with advanced disease who present with a condition that requires urgent care and evaluation (eg, pleural effusion, bowel obstruction and VTE).
 - EOC may present in a **subacute** fashion (eg, adnexal mass, pelvic or abdominal pain, gastrointestinal symptoms like nausea, vomiting, constipation and acid reflux) in women with either early or advanced disease. These conditions are usually evaluated in an outpatient setting.
 - **Adnexal mass** : may be discovered due to symptoms of pelvic pain or pressure or it may be found on a routine pelvic examination or an imaging study performed for another indication.
 - **Pelvic or abdominal symptoms** : Bloating, pressure symptoms on bladder or rectum like urgency or frequency, constipation, Difficulty eating or feeling full quickly, Pelvic or abdominal pain.
- The symptoms associated with ovarian cancer are nonspecific.
- The type or severity of symptom does not reliably correspond to disease stage.

Other subacute presentations :

1- **Postmenopausal bleeding.**

2- **Rectal bleeding.**

3- For fallopian tubal carcinoma, a classic triad of symptoms has been described: clear or blood-tinged vaginal discharge, pelvic pain, and a pelvic mass.

4- **Atypical glandular cells on cervical cytology** : Women with a finding of atypical glandular cells should be evaluated for cervical and endometrial carcinoma.

5- **Paraneoplastic syndromes** : cerebellar degeneration, polyneuritis, dermatomyositis, hemolytic anemia, disseminated intravascular coagulation, acanthosis, or nephrotic syndrome.

6- **Palpable inguinal or cervical lymphadenopathy.**

7- **Incidental operative finding.**

On Physical Examination

1. General examination(cachexia,anemia, jaundice,virchow's LN)
2. Abdominal examination:- Abdominal distention by inspection is one of the more common findings. Palpation and percussion , presence of flank fullness and shifting dullness implies the presence of ascites or a large pelvic-abdominal mass, Recent eversion of the umbilicus
3. Lymph Node examination :- the supraclavicular and inguinal areas,Sister Mary Joseph's nodule refers to a metastatic implant in the umbilicus.

On Physical Examination

4. Pelvic examination:- A careful and thorough pelvic examination provides many helpful clues regarding the etiology of a pelvic mass.-(**Benign mass:- Mobile, smooth, cystic, unilateral**)-**malignant mass:- fixed, irregular, solid or firm, bilateral.**•

Other D.D for mass: Endometrioma, Fibroid, Functional cyst, Ectopic pregnancy , Dermoid tumor (**younger women**)

Tumor serum biomarkers

1. **Cancer antigen 125 (CA 125)**
2. **Cancer antigen 19-9 (CA 19-9)**
3. **Human epididymis protein 4 (HE4)**
4. **Carcinoembryonic antigen (CEA)**

Cancer antigen 125 (CA 125)

- The CA 125 antigen is a large transmembrane glycoprotein derived from both coelomic (pericardium, pleura, peritoneum) and müllerian (fallopian tubal, endometrial, endocervical) epithelia.
- Normal value : CA 125: **≤35 U/MI**.
- Serum CA 125 is the most commonly used laboratory test for the evaluation of adnexal masses for epithelial ovarian cancer (EOC).
- CA 125 testing alone has a low sensitivity, particularly for early stage ovarian cancer. **only raised in 50% of early stage disease.**
- CA-125 being raised in numerous conditions including fibroids, endometriosis, adenomyosis , pelvic inflammatory disease, liver cirrhosis with or without ascites , Cancers of the endometrium, breast, lung, and pancreas.

- In postmenopausal women, the sensitivity for ovarian cancer was 69-87 %, specificity was 81-93 %. For premenopausal women, the sensitivity was 50 –74%, specificity was 69-78 %.
- CA 125 is not consistently produced by some histologic types of epithelial ovarian cancer, including: mucinous, clear cell, and mixed müllerian ovarian tumors.
- Serum CA 125 >200 U/mL had been used as a criterion for referral to a gynecologic oncologist.

Imaging

- **Pelvic ultrasound** is the single most effective way of evaluating an ovarian mass. With transvaginal ultrasonography being preferable due to its increased sensitivity over transabdominal ultrasound.
- **CT or MRI** are used for the presence of distant extension of the disease.
- **Chest radiography** is performed in most patients to evaluate for pleural effusion, pulmonary metastases, and mediastinal lymphadenopathy.

Risk of Malignancy index (RMI)

- Is a multimodality approach that combines three *presurgical* features: serum CA 125, pelvic ultrasound, and menopausal status into an index score to predict the risk of ovarian cancer in women with an adnexal mass.
- **The ultrasound** result is scored 1 point for each of the following characteristics: **multilocular cysts**, **solid areas**, **metastases**, **ascites** and **bilateral lesions**. U = 0 (for an ultrasound score of 0), U = 1 (for an ultrasound score of 1), U = 3 (for an ultrasound score of 2–5).
- **The menopausal status** is scored as 1 = premenopausal and 3 = postmenopausal.
- **Serum CA-125** is measured in IU/ml and can vary between zero to hundreds or even thousands of units.

RMI I score of >200 = high risk (risk of cancer <80%)

RMI I score < 25 = low risk (risk of cancer < 3%)

$$\text{RMI} = \text{U} * \text{M} * \text{CA-125}$$

A 46-year-old nulliparous woman comes to the office for a routine examination. She has been feeling well. Her last menstrual period was a week ago. The patient has regular menses every 30 days that last 3 days, with crampy abdominal pain on the first day relieved by ibuprofen. She has a history of heartburn, which is relieved by over-the-counter antacids. The patient has never had any surgeries. She does not smoke cigarettes. Abdominal examination shows a symmetric, nontender, nondistended abdomen with normal bowel sounds. Speculum examination shows a cervix with a closed external os. Bimanual examination shows a 5-cm, irregular, right adnexal mass. Urine pregnancy test is negative. Which of the following is the best next step in management?

- A. CT scan of the abdomen and pelvis
- B. MRI of the abdomen and pelvis
- C. Pelvic ultrasonography
- D. Reassurance and routine follow-up
- E. Serum CA-125 level
- F X-ray of the abdomen and pelvis

A 46-year-old nulliparous woman comes to the office for a routine examination. She has been feeling well. Her last menstrual period was a week ago. The patient has regular menses every 30 days that last 3 days, with crampy abdominal pain on the first day relieved by ibuprofen. She has a history of heartburn, which is relieved by over-the-counter antacids. The patient has never had any surgeries. She does not smoke cigarettes. Abdominal examination shows a symmetric, nontender, nondistended abdomen with normal bowel sounds. Speculum examination shows a cervix with a closed external os. Bimanual examination shows a 5-cm, irregular, right adnexal mass. Urine pregnancy test is negative. Which of the following is the best next step in management?

- A. CT scan of the abdomen and pelvis
- B. MRI of the abdomen and pelvis
- C. Pelvic ultrasonography
- D. Reassurance and routine follow-up
- E. Serum CA-125 level
- F X-ray of the abdomen and pelvis

An adnexal mass may arise from the ovary or fallopian tube and requires further investigation once identified on physical examination. An asymptomatic, palpable, smooth adnexal mass without any additional signs of ovarian cancer (eg, ascites, cul-de-sac nodularity) is likely benign.

However, an adnexal mass may be the only sign of ovarian cancer, and reassurance (**Choice D**) is not appropriate until further investigation.

Pelvic ultrasonography is the **first-line test** for evaluation of a **palpable adnexal mass**. The entire pelvis can be visualized on ultrasound using a combination of transabdominal and transvaginal techniques, providing a full overview of any masses that extend past the pelvis. Pelvic ultrasound will show the uterus (including endometrium), ovaries, and cul-de-sac. The fallopian tubes are not visible on ultrasound unless pathology is present. Ultrasound has a high specificity for detection of malignant sonographic features (eg, thick septations, solid components). It is noninvasive, well tolerated, requires no radiation, is readily available, and is cost effective. However, performance can be limited by patient obesity.

(Choice E) In a premenopausal patient, pelvic ultrasound should first confirm that the adnexal mass is ovarian; CA-125 can then be considered based on sonographic features and patient medical history. CA-125 testing has particularly low specificity in premenopausal women as it can be elevated from many other benign conditions (eg, endometriosis, leiomyomata, lupus) and ovarian cancer is less common before menopause. CA-125 is useful mainly in postmenopausal women and is not recommended for the initial evaluation of an adnexal mass in premenopausal patients.

A 62-year-old nulligravid woman comes to the office for follow-up after right adnexal enlargement was found on routine pelvic examination 2 weeks ago. Pelvic ultrasound reveals a 5-cm right ovarian cyst. Menopause occurred at age 52, and the patient has had no postmenopausal spotting or bleeding. Her medical history is otherwise unremarkable. The patient has never had any surgeries. There is no family history of ovarian or breast cancer. Her most recent mammogram 2 months ago showed no abnormalities. Which of the following is the most appropriate initial course of action for this patient?

- A. Endometrial biopsy
- B. Laparoscopy
- C. Needle aspiration for cytology
- D. Papanicolaou test
- E. Serum CA-125 level

A 62-year-old nulligravid woman comes to the office for follow-up after right adnexal enlargement was found on routine pelvic examination 2 weeks ago. Pelvic ultrasound reveals a 5-cm right ovarian cyst. Menopause occurred at age 52, and the patient has had no postmenopausal spotting or bleeding. Her medical history is otherwise unremarkable. The patient has never had any surgeries. There is no family history of ovarian or breast cancer. Her most recent mammogram 2 months ago showed no abnormalities. Which of the following is the most appropriate initial course of action for this patient?

- A. Endometrial biopsy
- B. Laparoscopy
- C. Needle aspiration for cytology
- D. Papanicolaou test
- E. Serum CA-125 level

Ovarian cancer risk increases with age, particularly after menopause, and any ovarian mass in a postmenopausal patient requires investigation. Risk factors for this malignancy include age, use of fertility drugs, uninterrupted ovulation (eg, nulligravidity), and *BRCA* mutation. **Cancer antigen 125 (CA-125)** is a biomarker for **epithelial ovarian cancer**. Elevations are also caused by common gynecologic conditions (eg, leiomyomata, endometriosis) that are more likely present in premenopausal patients; therefore, the specificity of CA-125 levels is much greater in **postmenopausal** women. CA-125 levels are measured in conjunction with **pelvic ultrasonography** findings to categorize an ovarian mass as likely malignant or benign. This postmenopausal patient has no medical conditions that may cause a false elevation of CA-125, so measurement is the best next step to investigate the risk of malignancy for this ovarian cyst. CA-125 levels can also be used to monitor for recurrence of a proven malignancy after treatment.

In a postmenopausal patient, an elevated CA-125 level in the context of any adnexal mass is highly suspicious for malignancy. If the adnexal mass has no malignant features on ultrasound (eg, small size, simple cyst) and the CA-125 level is normal, the patient can be observed with periodic ultrasound, but observation without further workup is inappropriate in a postmenopausal patient. If there are suspicious features on ultrasound (eg, large mass, solid components, septations) and/or if the CA-125 level is elevated, the patient should undergo further imaging (eg, MRI, CT scan) to assess the extent of disease. Knowledge of the presence of metastatic implants from imaging is important to guide surgical exploration, which is recommended if malignancy is suspected based on clinical, CA-125, and imaging findings.

- Once an adnexal mass has been identified, the evaluation to exclude malignancy includes a medical history, physical examination, imaging studies, and laboratory evaluation for tumor markers.
- Definitive diagnosis of ovarian cancer requires surgery and histopathology.

Staging System

Cancer of the ovary is **surgically staged** according to the 2014 International Federation of Gynecology and Obstetrics (FIGO) :

STAGE I (Tumor confined to ovaries)

IA : Tumor limited to 1 ovary, capsule intact, no tumor on surface, negative washings

IB : Tumor involves both ovaries , otherwise like IA

IC : Tumor limited to 1 or both ovaries

IC1 : Surgical spill

IC2 : Capsule rupture before surgery or tumor on ovarian surface

IC3 : Malignant cells in the ascites or peritoneal washings

STAGE II (Tumor involves 1 or both ovaries with pelvic extension (below the pelvic brim) or primary peritoneal cancer)

IIA : Extension and/or implant on uterus and/or Fallopian tubes

IIB : Extension to other pelvic intraperitoneal tissues

STAGE III (Tumor involves 1 or both ovaries with cytologically or histologically confirmed spread to the peritoneum outside the pelvis and/or metastasis to the retroperitoneal lymph nodes)

IIIA : Positive retroperitoneal lymph nodes and/or microscopic metastasis beyond the pelvis

IIIA1 : Positive retroperitoneal lymph nodes only

IIIA1(i) : Metastasis \leq 10 mm

IIIA1(ii) : Metastasis $>$ 10 mm

IIIA2 : Microscopic, extrapelvic (above the brim) peritoneal involvement \pm positive retroperitoneal lymph nodes

IIIB : Macroscopic, extrapelvic, peritoneal metastasis \leq 2 cm \pm positive retroperitoneal lymph nodes. Includes extension to capsule of liver/spleen

IIIC : Macroscopic, extrapelvic, peritoneal metastasis $>$ 2 cm \pm positive retroperitoneal lymph nodes. Includes extension to capsule of liver/spleen

STAGE IV (Distant metastasis excluding peritoneal metastasis)

IVA : Pleural effusion with positive cytology

IVB : Hepatic and/or splenic parenchymal metastasis, metastasis to extra-abdominal organs (including inguinal lymph nodes and lymph nodes outside of the abdominal cavity)

Cyto-reductive surgery (De-bulking surgery)(Staging laprotomy):

1. Total abdominal hysterectomy
2. Bilateral salpingo-oophorectomy
3. Peritoneal cytology
4. Infra-colic omentectomy
5. Pelvic and para-aortic lymph node dissection

There are several potential benefits of aggressive primary surgical management in women with epithelial ovarian carcinoma (EOC), particularly for those with advanced disease :

- 1) Optimal response to postoperative systemic chemotherapy is achieved in the setting of minimal disease burden.
- 2) Disease-related symptoms (eg, abdominal pain, increased abdominal girth, dyspnea, early satiety) are related to tumor burden. Removal of bulky disease rapidly improves symptoms and quality of life.
- 3) Ovarian neoplasms produce multiple cytokines, at least some of which are immunosuppressive (eg, interleukin-10, vascular endothelial growth factor). Removal of tumor bulk may improve or restore host immune competence.
- 4) Cytoreduction is associated with increased survival. The volume of residual disease remaining after cytoreductive surgery correlates inversely with survival.

The terminology regarding extent of cytoreduction is:

- 1) **Complete cytoreduction** – Cytoreduction to no grossly visible disease.
- 2) **Optimal cytoreduction** – The Gynecologic Oncology Group (GOG) defines optimal cytoreduction as residual disease that is ≤ 1 cm in maximum tumor diameter.
- 3) **Suboptimal cytoreduction** – Cytoreduction with tumor nodules >1 cm remaining.

Adjuvant therapy

Women with EOC should undergo adjuvant treatment with the exception of those with stage IA EOC.

Neoadjuvant therapy

refers to the administration of systemic chemotherapy before definitive surgery.

The goal of NACT is to reduce perioperative morbidity and mortality and increase the likelihood of a complete resection of disease at the time of cytoreductive surgery.

In most cases of women treated with NACT, further chemotherapy is administered following surgery (ie, adjuvant chemotherapy).

A 60-year-old woman, gravida 3 para 3, comes to the office due to shortness of breath. Over the past 6 months, the patient has been finding it progressively more difficult to take deep breaths. She has also noticed that she cannot fit into any of her pants lately despite a decreased appetite and nausea. The patient has a history of type 2 diabetes and has never had any surgeries. All her children were born vaginally. Routine mammography 4 years ago was normal. The patient has a sister with breast cancer, *BRCA* mutation positive. Physical examination shows an ill appearing woman with a distended abdomen and decreased bowel sounds. The lungs are clear on auscultation. Pelvic examination shows a firm, nodular, non-mobile mass in the left adnexa. A pelvic ultrasound is performed and confirms the physical examination findings. Which of the following is the most appropriate next step in management of this patient?

- A. Exploratory laparotomy
- B. Hysteroscopy
- C. Image-guided biopsy of pelvic mass
- D. Loop electrosurgical excision procedure
- E. Myomectomy

A 60-year-old woman, gravida 3 para 3, comes to the office due to shortness of breath. Over the past 6 months, the patient has been finding it progressively more difficult to take deep breaths. She has also noticed that she cannot fit into any of her pants lately despite a decreased appetite and nausea. The patient has a history of type 2 diabetes and has never had any surgeries. All her children were born vaginally. Routine mammography 4 years ago was normal. The patient has a sister with breast cancer, *BRCA* mutation positive. Physical examination shows an ill appearing woman with a distended abdomen and decreased bowel sounds. The lungs are clear on auscultation. Pelvic examination shows a firm, nodular, non-mobile mass in the left adnexa. A pelvic ultrasound is performed and confirms the physical examination findings. Which of the following is the most appropriate next step in management of this patient?

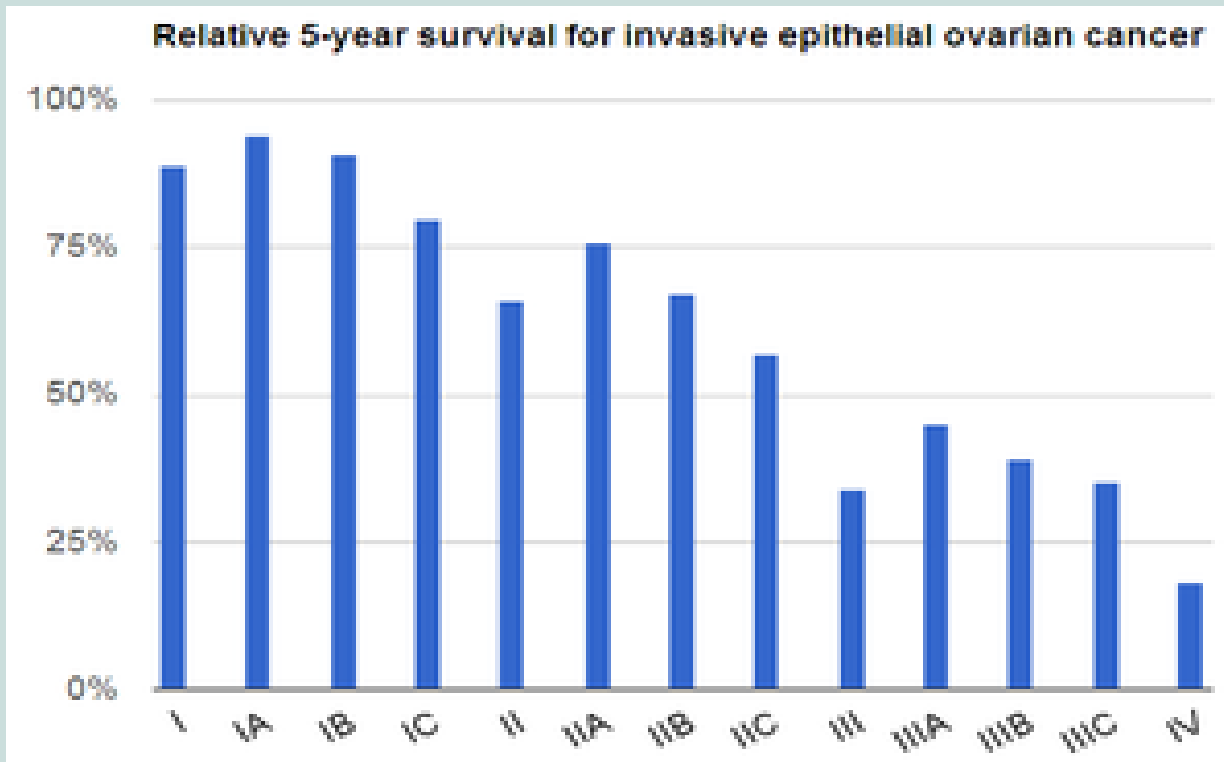
- A. Exploratory laparotomy
- B. Hysteroscopy
- C. Image-guided biopsy of pelvic mass
- D. Loop electrosurgical excision procedure
- E. Myomectomy

Epithelial ovarian cancer (EOG) occurs primarily in **postmenopausal** women, and those with a family history of ovarian or **breast cancer** (eg, *BRCA* mutation carrier) are particularly susceptible. EOG commonly presents with advanced disease as early symptoms (eg, bloating, abdominal pain) tend to be vague and nonspecific. A firm, non-mobile **pelvic mass with nodularity** in a postmenopausal patient is concerning for EOG that has extended beyond the adnexa. In addition, this patient has symptoms of **ascites** (eg, shortness of breath, decreased appetite, abdominal distension, decreased bowel sounds), which is likely due to peritoneal spread of cancer causing increased capillary permeability and decreased intravascular oncotic pressure.

Imaging (eg, pelvic ultrasound) is done to confirm the presumed clinical diagnosis of ovarian cancer and ascites; it may also evaluate for metastatic disease. CA-125 should be drawn to correlate with clinical findings and to monitor treatment in the future. **Exploratory laparotomy** with cancer resection and inspection of the entire abdominal cavity for metastases (ie, **surgical staging**) is **required** when there is a high clinical suspicion of EOG, particularly with an acute presentation, as in this patient. During surgery, the ovaries, uterus, omentum, and any visually apparent cancerous lesion will be removed and pelvic and paraaortic lymph nodes will be dissected. Chemotherapy with platinum-based agents is initiated after surgery.

Prognosis

Overall five-year survival in women with ovarian cancer is less than 45 %.



The major prognostic factors associated with improved outcome were :

- 1) **younger age** : Younger patients are more likely to have a favorable prognosis because they are more likely to have tumors of less aggressive histology and lower grade, and better baseline performance status.
- 2) **Low volume of residual disease.**
- 3) **Good performance status.**
- 4) **Serous histology.**

POSTTREATMENT SURVEILLANCE

- 1) Office visits (including physical and pelvic exams) every three to six months up to five years posttreatment, then annually.
- 2) CA-125 or other tumor markers (eg, HE4) every visit if initially elevated, if indicated
- 3) Other testing (ie, chemistry profile or complete blood count, CT scan, or transvaginal ultrasound in women who underwent fertility-sparing surgery) only as clinically indicated.

Screening for ovarian cancer

Screening for high risk women : There is a consensus that women at average risk for ovarian cancer should NOT undergo screening.

Screening tests : Measurement of CA 125 and transvaginal pelvic ultrasound.

A 58-year-old nulliparous woman comes to the office for a routine checkup. She is concerned about ovarian cancer because her cousin died of the disease last year and a close friend was recently diagnosed with it. Her medical history is significant for hypertension treated with an ACE inhibitor. Menopause was at age 55. The patient smokes a half pack of cigarettes a day. There is no other cancer history in her family. Physical examination is unremarkable. Which of the following is the most appropriate strategy for ovarian cancer screening in this patient?

- A. Genetic testing for BRCA mutation
- B. No further workup
- C. Pelvic ultrasonography
- D. Serum CA-125 level
- E. Serum carcinoembryonic antigen level

A 58-year-old nulliparous woman comes to the office for a routine checkup. She is concerned about ovarian cancer because her cousin died of the disease last year and a close friend was recently diagnosed with it. Her medical history is significant for hypertension treated with an ACE inhibitor. Menopause was at age 55. The patient smokes a half pack of cigarettes a day. There is no other cancer history in her family. Physical examination is unremarkable. Which of the following is the most appropriate strategy for ovarian cancer screening in this patient?

- A. Genetic testing for BRCA mutation
- B. No further workup**
- C. Pelvic ultrasonography
- D. Serum CA-125 level
- E. Serum carcinoembryonic antigen level

Ovarian cancer is one of the leading causes of **cancer mortality** in the World as the disease is typically diagnosed in **advanced stages** with widespread **metastasis**. For average-risk patients (eg, no hereditary cancer syndromes), **no screening** tests exist to detect ovarian cancer in its early, more treatable stages. This patient's family history of a single second-degree relative with ovarian cancer does not impart increased likelihood of a hereditary cancer syndrome.



Endometrial hyperplasia

Done by:

Shahed Awad Al-qatawneh

:Definition

An abnormal thickening of the uterine lining caused by the proliferation of endometrial glands due to estrogen stimulation and insufficient progestin stimulation

:Etiology

****Increased estrogen stimulation leading to excessive proliferation of the endometrium, e.g., due to:**

- **Follicle persistence** in anovulatory cycles (e.g., perimenopause, PCOS) Lack of follicle maturation and consequent anovulation result in persistent estrogen production.
- **Estrogen-producing ovarian tumors** (e.g., granulosa cell tumors, theca cell tumors)
- **Hormone replacement therapy without progestin administration** (Progestin normally prevents endometrial hyperplasia)
- **Obesity** (Adipocytes express cytochrome P-450 aromatase, which catalyzes the conversion of steroids to estrogens)
- **Tamoxifen therapy in postmenopausal women** -

(Tamoxifen acts as an estrogen receptor agonist in endometrial tissue. In the absence of progesterone, unopposed estrogen receptor stimulation increases the risk of endometrial hyperplasia)

****Lynch syndrome**

Classification:

Classification of endometrial hyperplasia based on histology (WHO 2014) ^[1]

Endometrial hyperplasia without atypia (benign endometrial hyperplasia)

Endometrial hyperplasia with atypia (endometrial intraepithelial neoplasm)

Histology


- Both stromal and glandular cells 
- Appearance varies
 - Simple endometrial proliferation with a few cysts
 - Enlarged, dilated mucous membrane glands (Swiss cheese pattern) located between abundant stromal tissue 

- Pronounced proliferation of glandular tissue
- Glands are positioned back-to-back with no separating stroma
- Clonal, atypical cells with extensive mitosis and loss of cell polarity

Risk of carcinoma

- Low (1–3%)

- Very high risk of **endometrial carcinoma**
- Incidence of coexisting invasive endometrial carcinoma is reported to be up to 40% ^[2]



Clinical features:

Vaginal bleeding (intermenstrual, postmenopausal, or constant bleeding)

Diagnosis: (history ,PE)

-**Ultrasonography:** to assess endometrial thickening (> 15 - mm in premenopausal women and > 5 mm in postmenopausal women)

Normal endometrial thickness can range from 3 mm (postmenstrual phase) to 15 mm (luteal phase -

- **Hysteroscopy-guided or blind endometrial biopsy** (rarely dilation and curettage): •
for histological analysis

For the evaluation of abnormal uterine bleeding, endometrial biopsy should be considered in:

Patients > 45 years old as first-line test

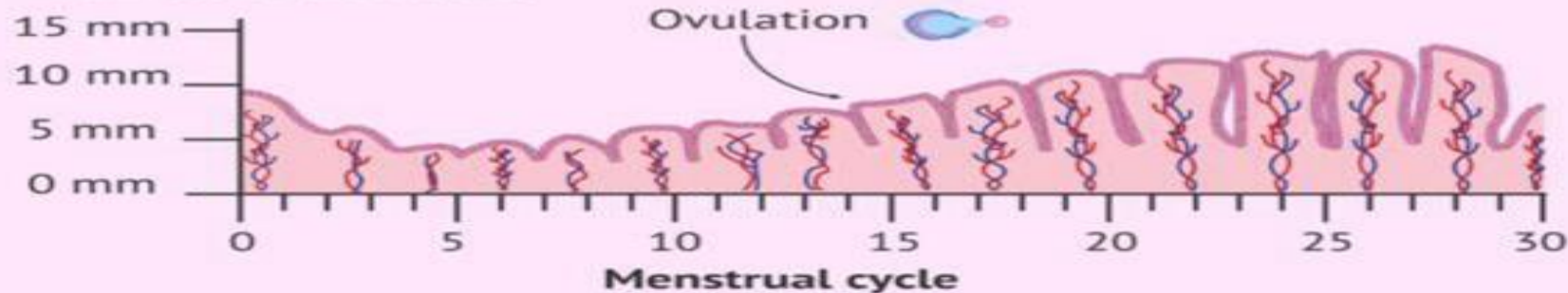
Patients with abnormal uterine bleeding that persists despite medical management, regardless of age

Patients < 45 years old with risk factors for endometrial cancer ([Strong Recommendation](#))

- **Laboratory measures:** FSH, estradiol, testosterone

(To exclude hormone-producing ovarian tumors)

Thickness of the Uterus



Normal



Menstruation
1- 4 mm



Follicular Phase
5 - 7 mm



Luteal Phase
7-14 mm

High Risk

**More than 16 mm
before Menopause**



**More than 5 mm
after Menopause**

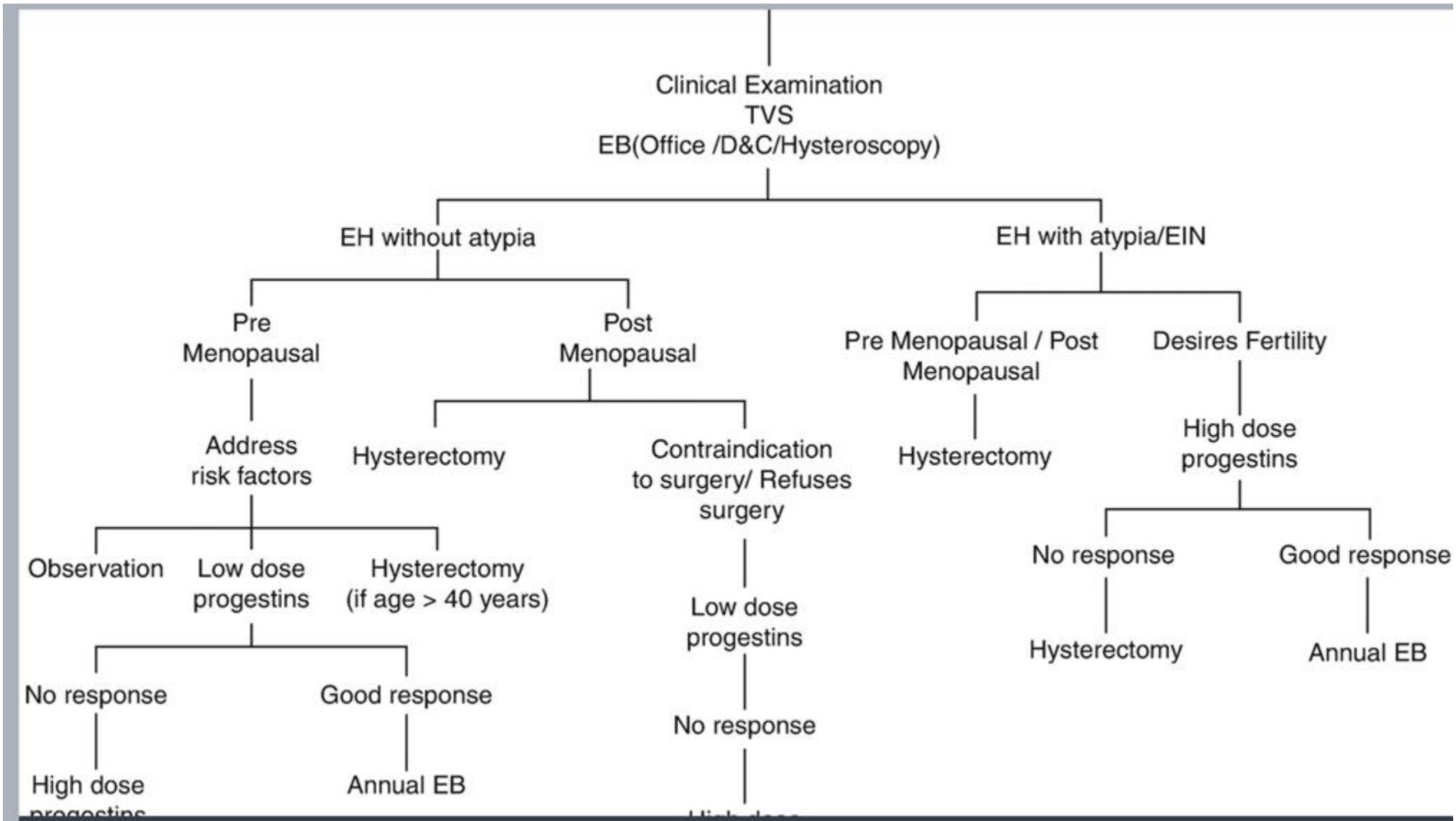
Management:

The main goals of management are as follows: • •

- To prevent the development/progression of endometrial malignancy. •
- To rule out the presence of a coexisting endometrial malignancy.
- To offer a treatment plan that best suits the needs of the patient.

• the following clinical factors are to pay attention to in management :


- 1.Type of EH (with or without atypia).
- 2.Menopausal status.
- 3.Desire for fertility in premenopausal patients



Treatment:



The choice of treatment primarily depends on the presence of atypia and if menopause has occurred yet. [5]

Treatment of endometrial hyperplasia based on histology		
	<u>Premenopausal women</u>	<u>Postmenopausal women</u>
<u>Endometrial hyperplasia without atypia</u>	<ul style="list-style-type: none">• <u>Progestin therapy</u>: cyclic <u>progestin</u> administration from the 12th to the 25th day of the <u>menstrual cycle</u>• In women with <u>PCOS</u>: administration of <u>hormonal contraceptive</u>	<ul style="list-style-type: none">• <u>Progestin therapy</u>
	<ul style="list-style-type: none">• All patients receiving <u>progestin therapy</u> should undergo:<ul style="list-style-type: none">◦ <u>Ultrasonographic follow-up</u> after 3–6 months◦ <u>Hysteroscopy with biopsy</u> in the case of suspicious findings on <u>ultrasound</u>• Just regular surveillance without <u>progestin therapy</u> is indicated if <u>progestin therapy</u> is:<ul style="list-style-type: none">◦ Contraindicated (e.g., <u>hormone-responsive cancer</u>, <u>progestin-receptor positive breast cancer</u>)◦ Not tolerated or declined by the patient	
<u>Endometrial hyperplasia with atypia</u>	<ul style="list-style-type: none">• In women with completed childbearing or no future wish to conceive: total abdominal <u>hysterectomy</u> with or without bilateral <u>salpingo-oophorectomy</u> • In women with a wish to conceive: <u>progestin therapy</u> and close surveillance with regular <u>endometrial sampling</u>	<ul style="list-style-type: none">• Total abdominal <u>hysterectomy</u> with bilateral <u>salpingo-oophorectomy</u>

- **Indications for hysterectomy:**

- Atypical hyperplasia develops during the treatment period
- No resolution of the disease after 12 months of treatment / Non-resolution of bleeding
- Relapse of endometrial hyperplasia
- A non-compliant patient who declines surveillance and follow-

FollowUp

American College of Obstetricians and Gynecologists (ACOG) recommendations for follow-up in patients with endometrial intraepithelial neoplasia or atypical endometrial hyperplasia:

Recommendations on endometrial sampling:

For patients treated with progestational agents:

Repeat endometrial sampling within 3-6 months.

-If the biopsy results indicate a complete resolution, discontinue treatment and perform endometrial sampling every 3-6 months for up to 2 years.

- If the biopsy results indicate no response to treatment or some regression, consider an additional 3-6 months of treatment.

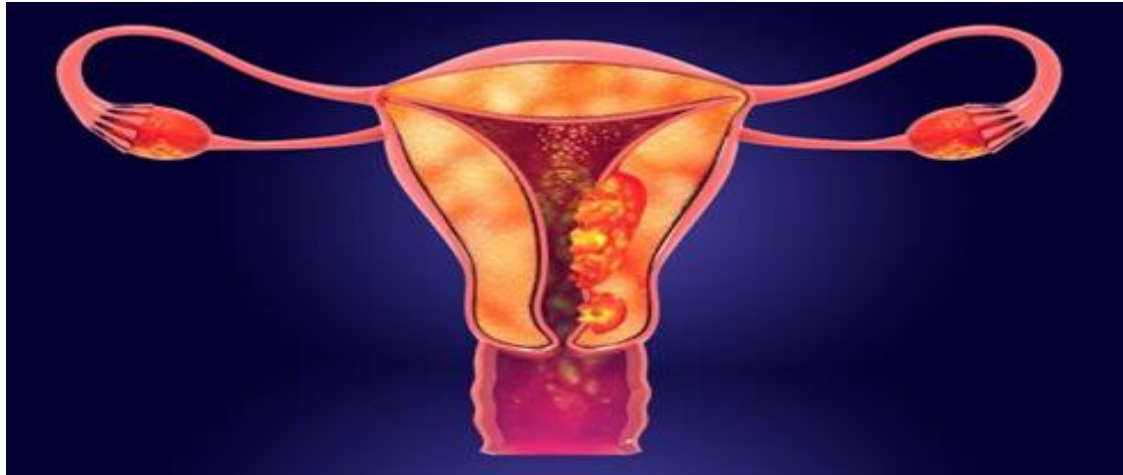- If the biopsy results indicate no response after 9-12 months of treatment, consider additional management strategies, such as definitive surgery.

A 55-year-old nulligravid woman comes to the physician because of a 3-day history of heavy vaginal bleeding, requiring more than 5 pads per day. Menarche was at the age of 10 years. Menopause occurred 1 year ago. She has a history of hypothyroidism and type 2 diabetes mellitus. She has smoked one pack of cigarettes daily for 20 years but quit 5 years ago. Current medications include levothyroxine and metformin. She is 165 cm (5 ft 5 in) tall and weighs 86 kg (190 lb); BMI is 32 kg/m². Physical examination shows mild vaginal atrophy and a normal cervix. The uterus and adnexa are nontender to palpation. Transvaginal ultrasonography shows an endometrial thickness of 6 mm. Endometrial biopsy shows noninvasive proliferation of endometrial glands with no nuclear or cytological atypia. Which of the following is the most appropriate next step in management?

☰ KEY INFO ? ATTENDING TIP 📄 LABS ✎ ADD NOTES 🚩 MARK ☆ GET ANKI CARDS ⋮

- A Total hysterectomy ×
- B Estrogen vaginal cream ×
- C Reassurance and follow-up ×
- D Progestin therapy ×
- E Surgical endometrial ablation ×
- F Anastrozole therapy ×

Endometrial cancer



Rahaf Dahamsheh
-Hamza Lafi

- Endometrial carcinoma is the **fifth** leading cancer in the women worldwide.
- In developed countries it's the most common gynecological cancer and second most common in developing countries after cervical CA.
- Mean age of presentation is **56 years** .
 - 75% after menopause.
 - 20% perimenopausal.
 - 5% before age of 40.

Etiology

- It is a case of **hyperestrogenemia**, so any case that include an increase in estrogen level will increase the risk of Endometrial carcinoma,
 - **indiscriminate use of oestrogen.**
 - **unopposed oestrogen.**
 - **Theca granulosa cell tumours.**

Risk factors:

- Diabetes or abnormal glucose tolerance test.
- Hypertension.
- Fibroids.
- Polycystic ovarian syndrome.
- overnight or obese patients .
- Infertility, Arthritis, and Thyroid disease.
- Early menarche and late menopause .
- Use of TAMOXIFEN.
- Previous pelvic irradiation.
- Positive family history of breast, ovarian, and colon cancer.
- ATYPICAL ADENOMATOUS HYPERPLASIA (complex atypical)
25% will progress into endometrial CA.

Protective factors:

- Smoking
- Use of oral contraceptive.
- Use of progesterone.

- Each is further graded according to **Broder's classification**

		% of undifferentiated cells
G1	Well differentiated	0-25%
G2	Moderately differentiated	25-50%
G3	Poorly differentiated	>50%

Grade 1 tumors are more often seen than anaplastic , therefore carries a better prognosis .

Spread :

- Invasion through the **myometrium** and by filling the **uterine cavity**.
- Invasion to the cervix with subsequent **lymphatic spread** involving the iliac and para-aortic nodes.
- From upper uterus may **spread to round ligament to the deep inguinal nodes**.
- In advanced cases, the **blood-stream spread** may carry to the lungs, liver, and to the bone.

Stage I Confined to uterus	IA : less than ½ of myometrium
	IB : more than ½ of myometrium
Stage II	Cervical stromal invasion, but not beyond uterus
Stage III Spread adjacent to the uterus	IIIA Tumor invades serosa or adnexa
	IIIB Vaginal and/or parametrial involvement
	IIIC1 Pelvic lymph nodes involvement
	IIIC2 Para-aortic lymph nodes involvement
Stage IV Distant metastasis	IVA Tumor invasion bladder and/or bowel mucosa
	IVB Distant metastases including abdominal metastases and/or inguinal lymph nodes

- **Staging** is made surgically by the following procedure:
- Laparotomy, peritoneal wash to detect the presence of mets.
- Total abdominal hysterectomy with bilateral salpingophrectomy.
- 3. Lymph nodes dissection.

History:

- postmenopausal bleeding or staining(this symptom should be assumed to be caused by carcinoma of the endometrium until proved otherwise), only 10% of PMB have endometrial carcinoma.
- Perimenopausal menstrual irregularities.
- Blood stained vaginal discharge.
- Heavy and irregular vaginal bleeding
- Dysuria
- Dysparenia
- Back pain
- pain or mass in the pelvis

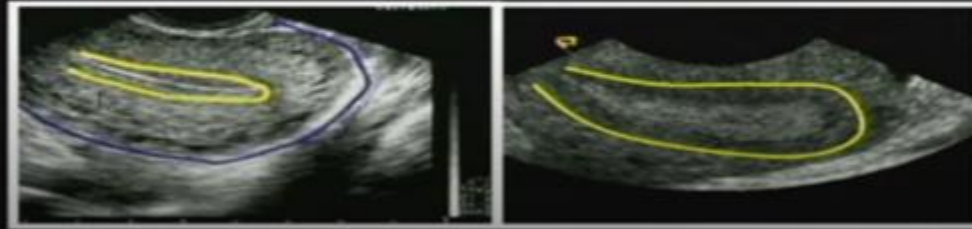
Examination:

- **physical examination** of the patient with endometrial carcinoma is frequently entirely **normal**, it should include palpation of supraclavicular and inguinal lymph nodes, abdominal palpation might be difficult due to obesity.
- **Gynaecological examination:**
- **inspection** of vulva, vaginal skin in suburethral area
- and cervix.
- **Bimanual vaginal examination** assesses uterine size, and mobility, state of parametria and adnexa.
- **Bimanual recto-vaginal examination.** (rectal and uterosacral ligament infiltration).

Investigations and imaging:


- **CBC.**
- **Liver function test.**
- **Renal function test.**
- **Chest X ray.**
- **Ultrasound:** reveals a **thick endometrium** in a postmenopausal woman. (>5mm)
(must be thin as estrogen should be very low).
- **Cytology brush** from lower cervical canal and posterior fornix to analyze the cells.

Endometrial Stripe (sono)



**Thin endometrium
endometrium**

Thick



Endometrial Cytology brush

Definite diagnosis is made by biopsy, which will be

obtained by:

- **1. Endometrial biopsy**, blind sample.

Fractional curettage, pipelle, jet irrigation and suction.

- **2. Examination under general anesthesia and D&C**

- **3. Hysteroscopy and biopsy**, the best, under vision, any abnormal lesions seen will be biopsied.

- **for staging:**

proctoscopy and / or sigmoidoscopy, cystoscopy

management

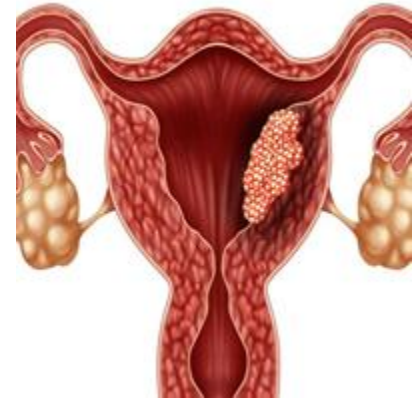- During surgery, if a frozen section facility is available we can do so, if the stage is IA, no need for lymph nodes dissection.
- **Stage IA grade I (well differentiated)** require surgery (TAH with BSO), no need for lymph nodes dissection, no need for postop chemotherapy or radiotherapy.
- **Stages IB-III** all require surgery, postop radio/chemotherapy, stage III require both to reduce the risk of recurrence.
- **stage IV** adenocarcinoma: Rare
- **Symptomatic management ,control of tumour growth, so: “Palliative”**
- **-hysterectomy to reduce the bleeding.**
- **-Radiotherapy to decrease the bleeding.**
- **-Cytotoxic drugs.**
- **-Hormonal therapy**
- May all be required. Rarely limited surgery to stop the bleeding as palliative procedure is carried out.

Indications for post operative radiotherapy:

- **Moderate or poor differentiation(G2,G3).**
- **Other histological type than adenocarcinoma as papillary or clear cell carcinoma.**
- **Invasion of myometrium of > 1/2. (IB)**
- **Positive peritoneal wash.**
- **Positive lymph nodes. (III)**

Complications

- peritonitis
- hematometra (collection of blood within uterus due to lower uterine or cervical obstruction) and if it gets infected may result in pyometra
- malignant fistula (bladder, rectum, ureters)



Prognosis

Generally endometrial CA has **good prognosis**, better than cervical CA due to:

- **Early presentation, as patient is symptomatic.**
- **Slow growth.**
- **Well differentiated .**
- **Late lymph nodes involvement.**

5 years survival:

- Stage I : 80-90%
- Stage II: 70-80%
- Stage III: 20-60%
- Stage IV: 15%

Thank you ALL