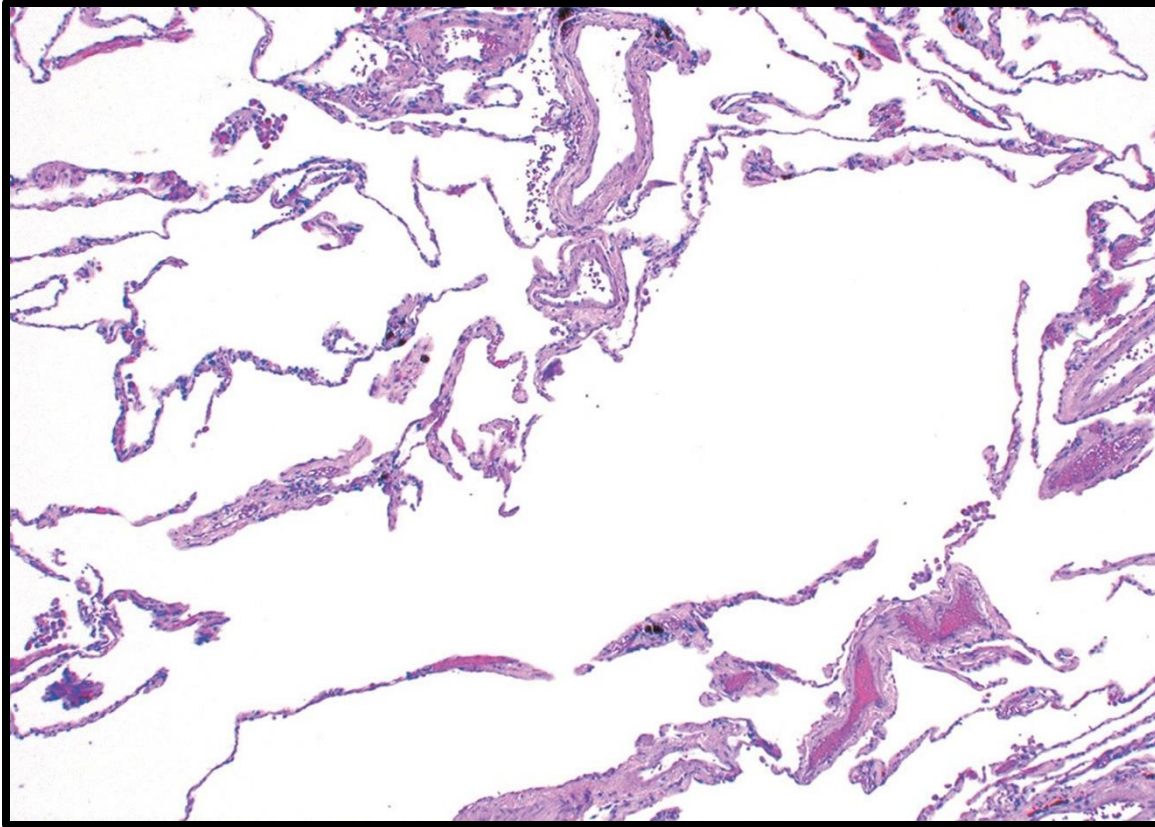


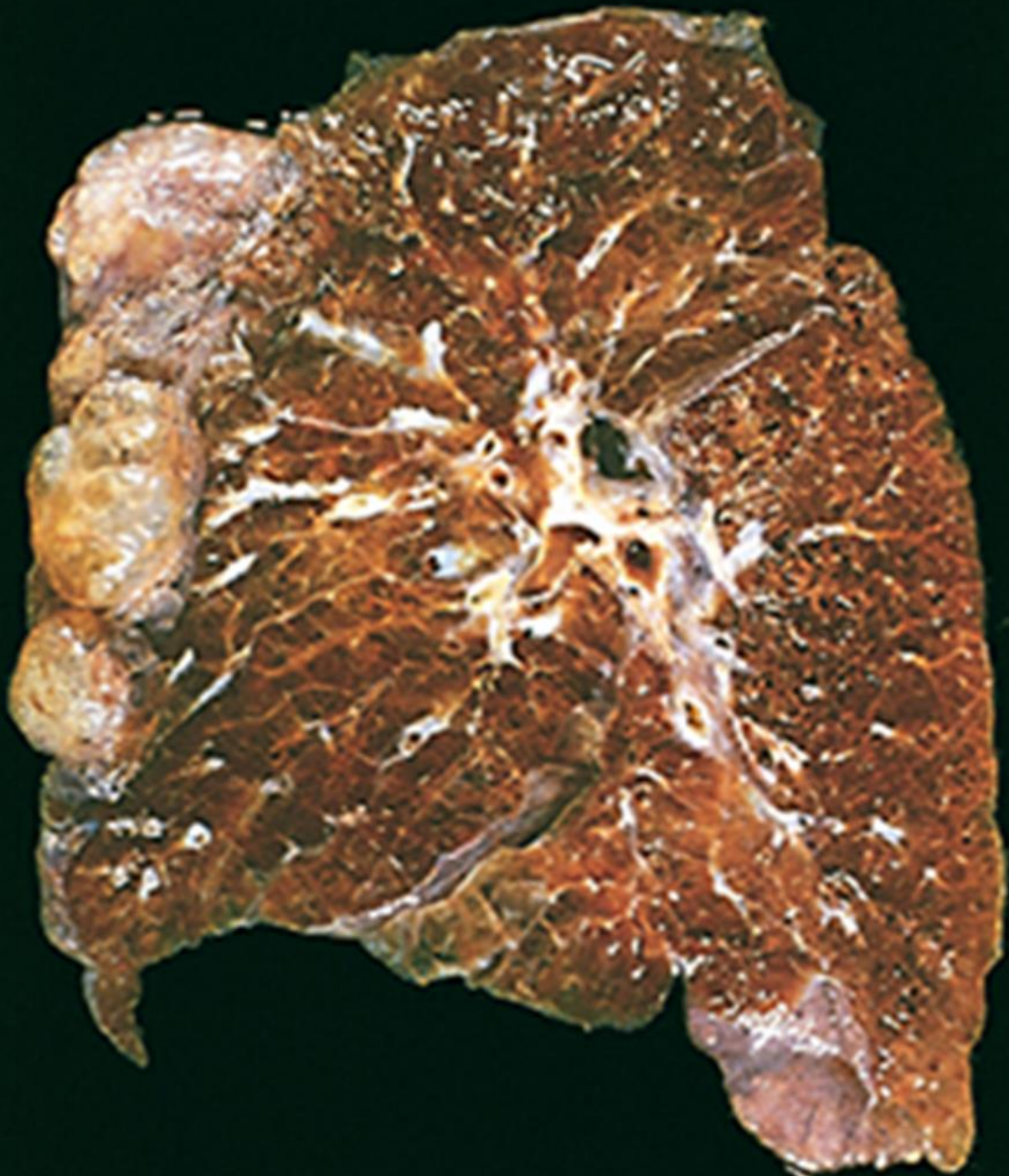Respiratory system LAB

Sura AL Rawabdeh,MD

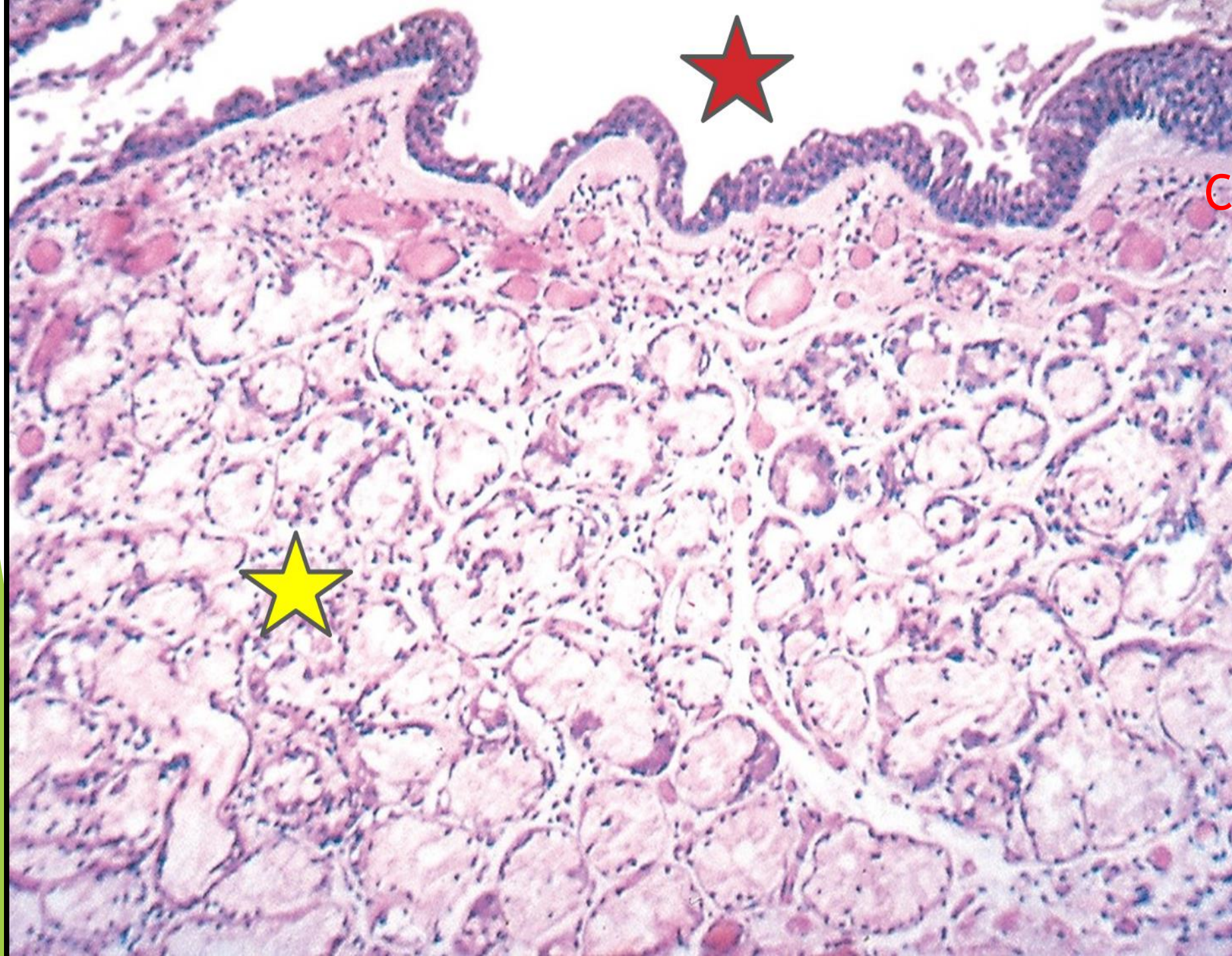
October 2024

Emphysema



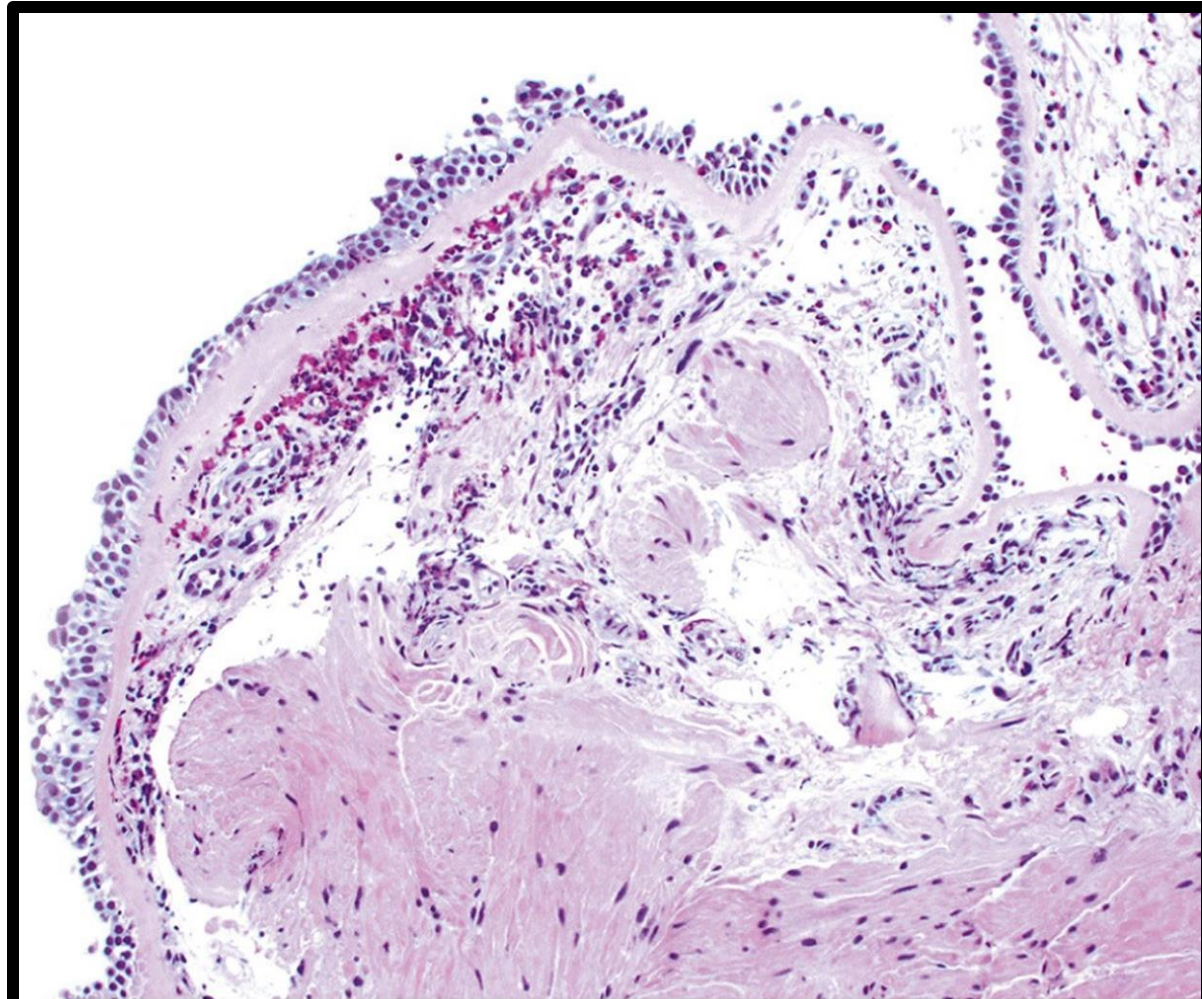


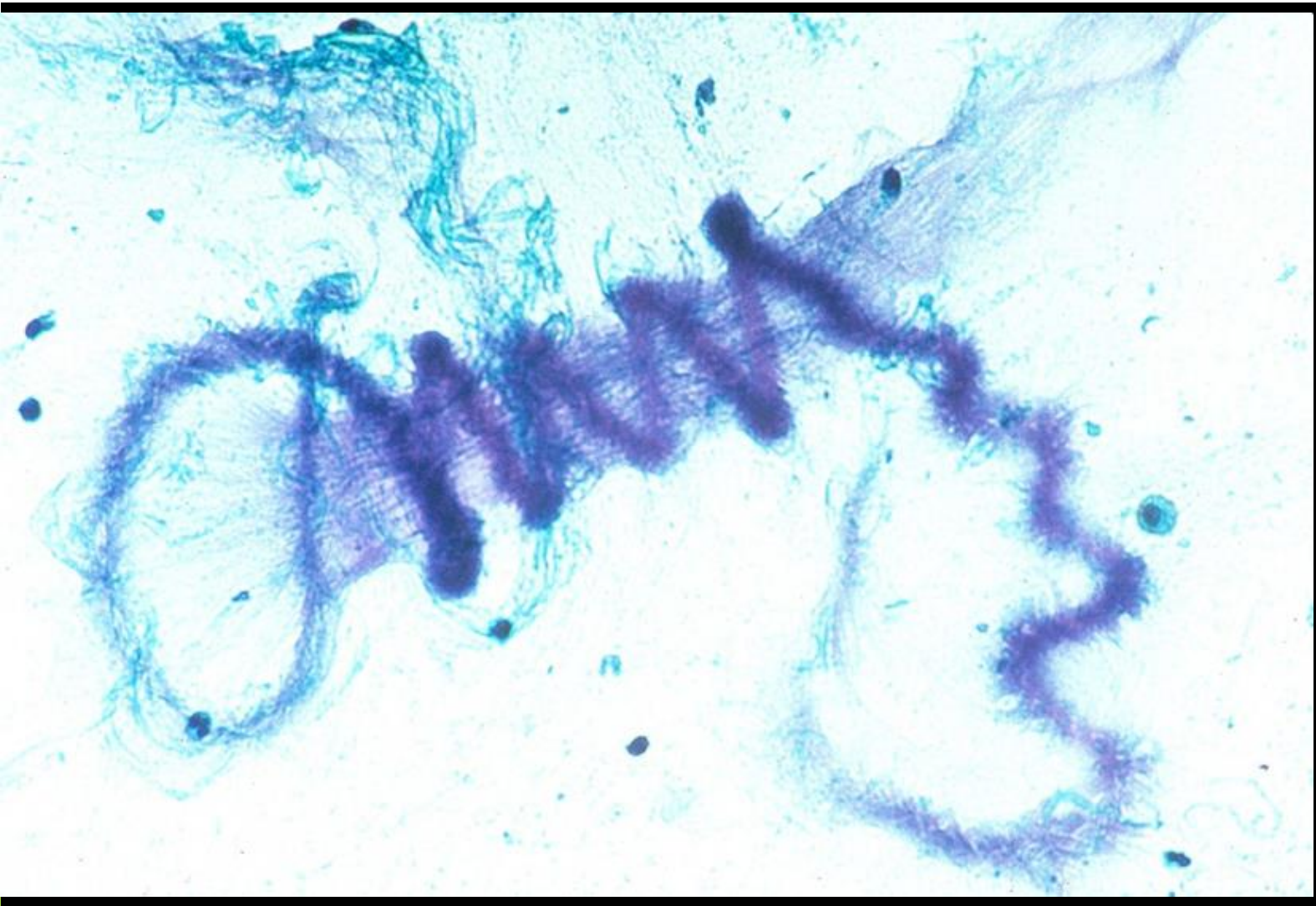
**Subpleural
bullae**



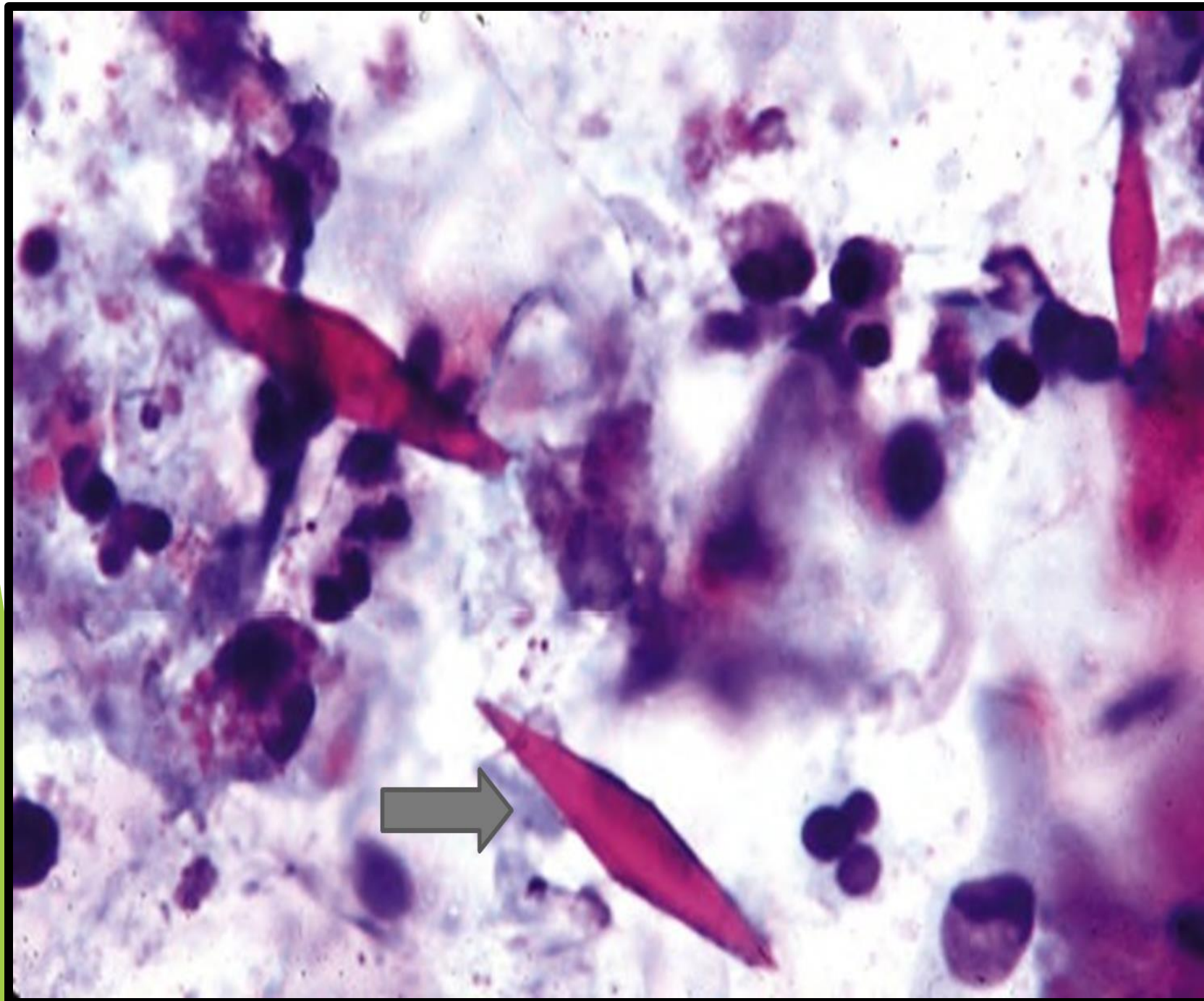
CHRONIC BRONCHITIS

Bronchial ASTHMA

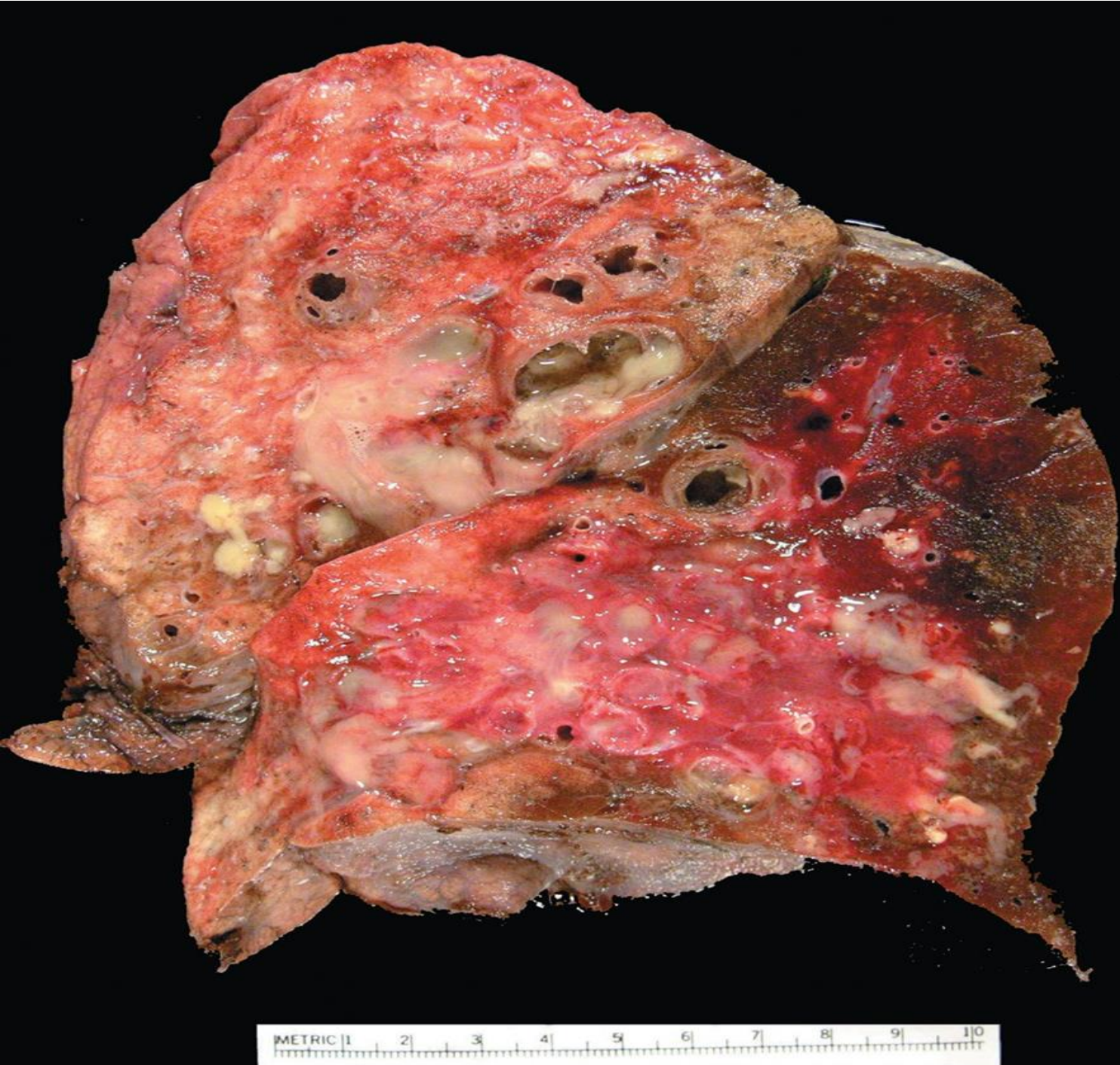



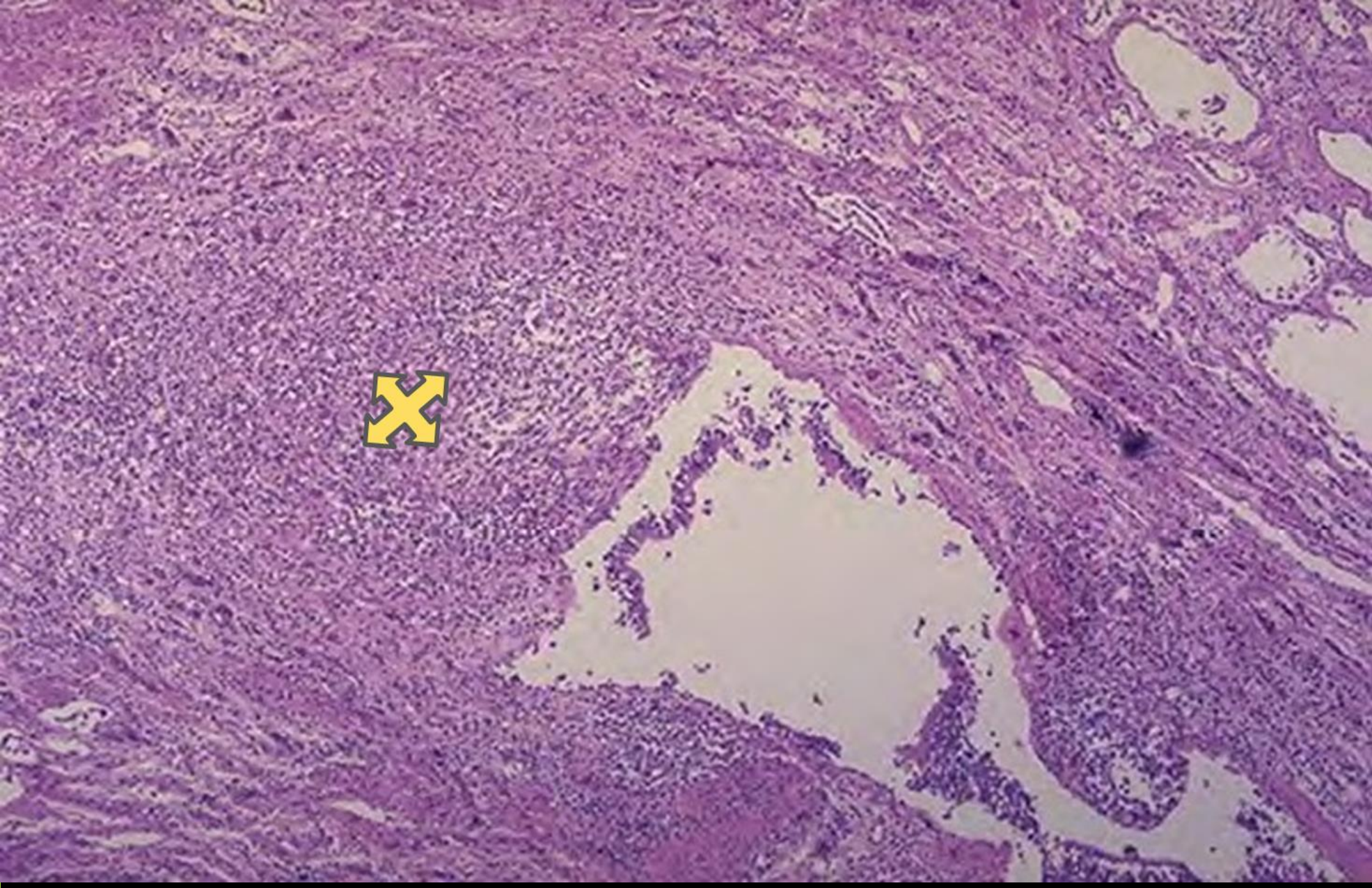
Curschman Spirals in sputum



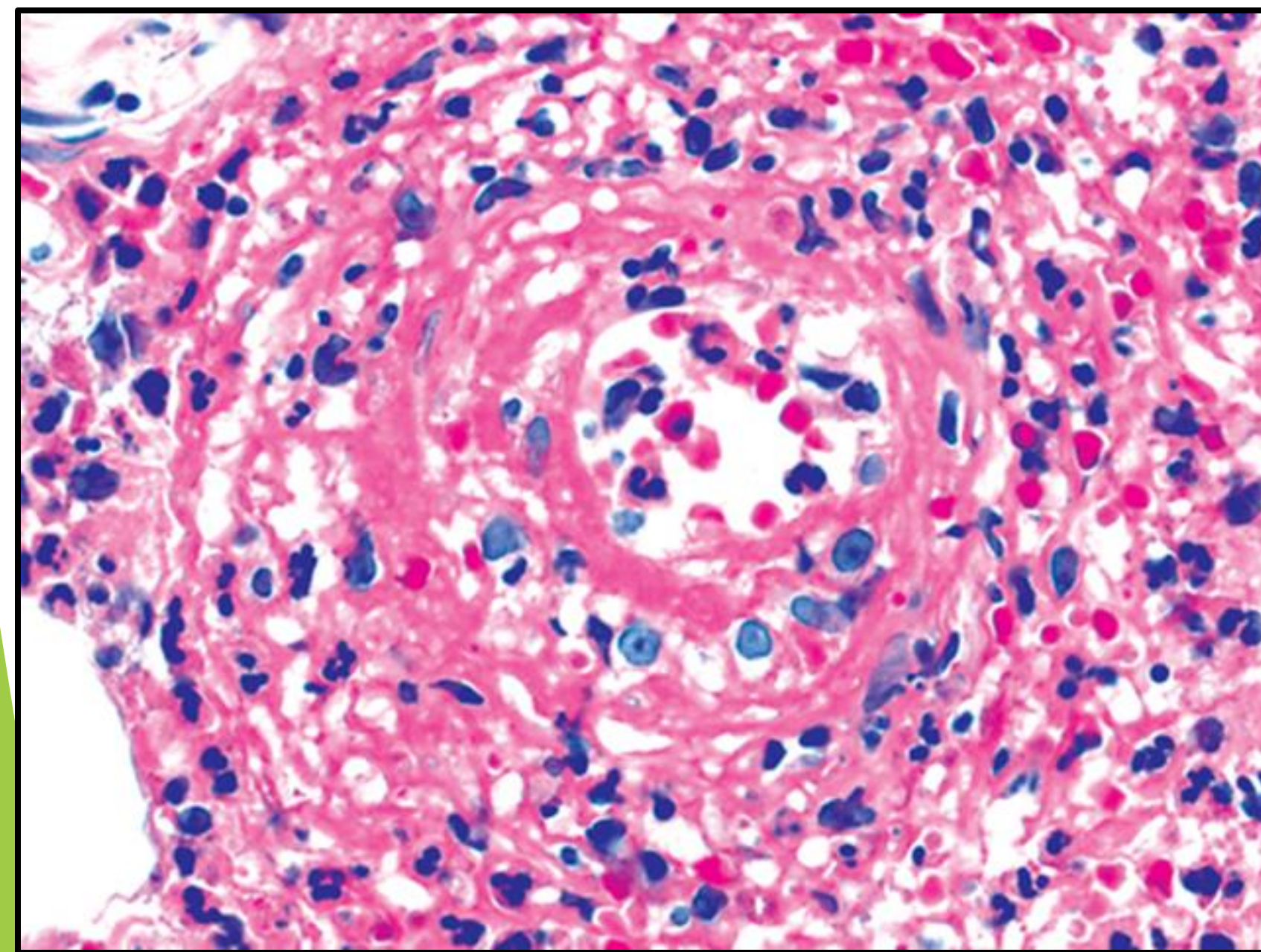
Charcot-Leyden crystals



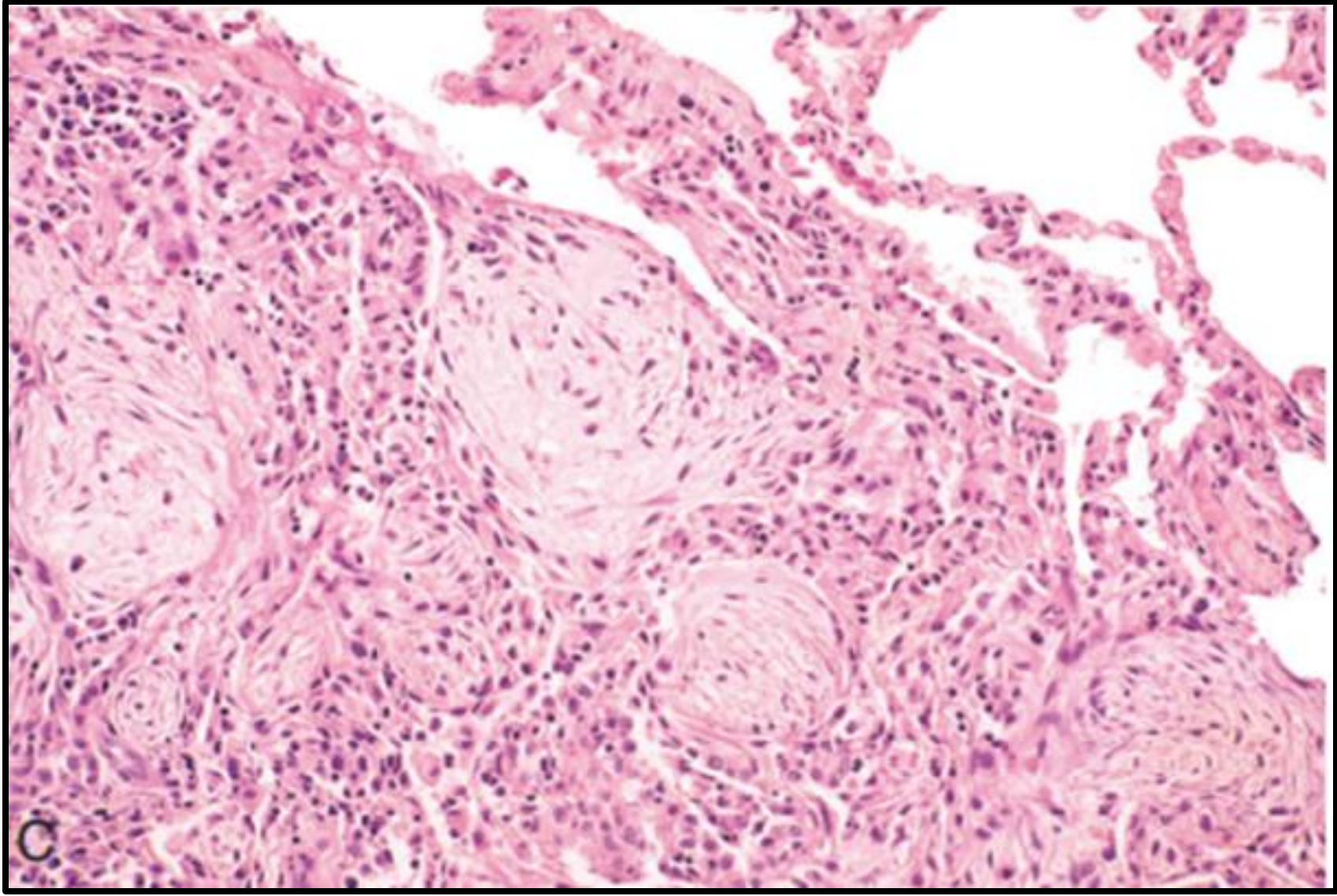
BRONCHIECTASIS



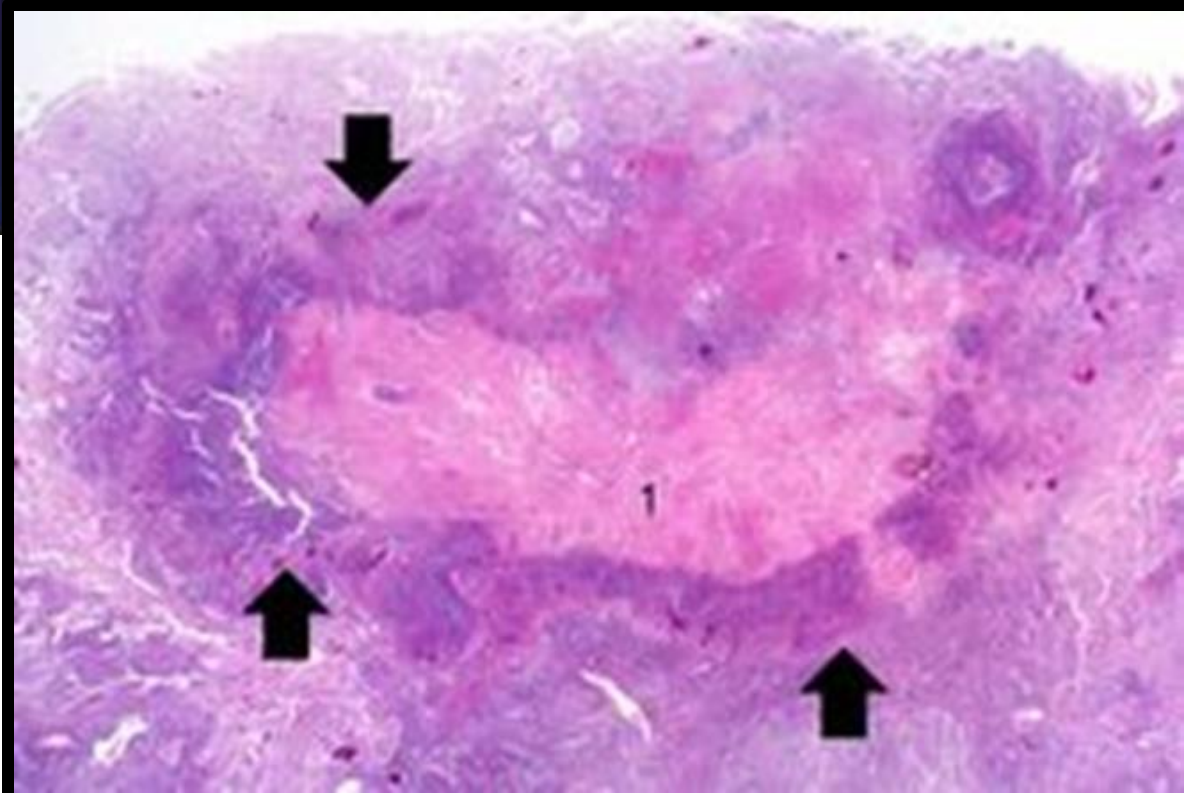
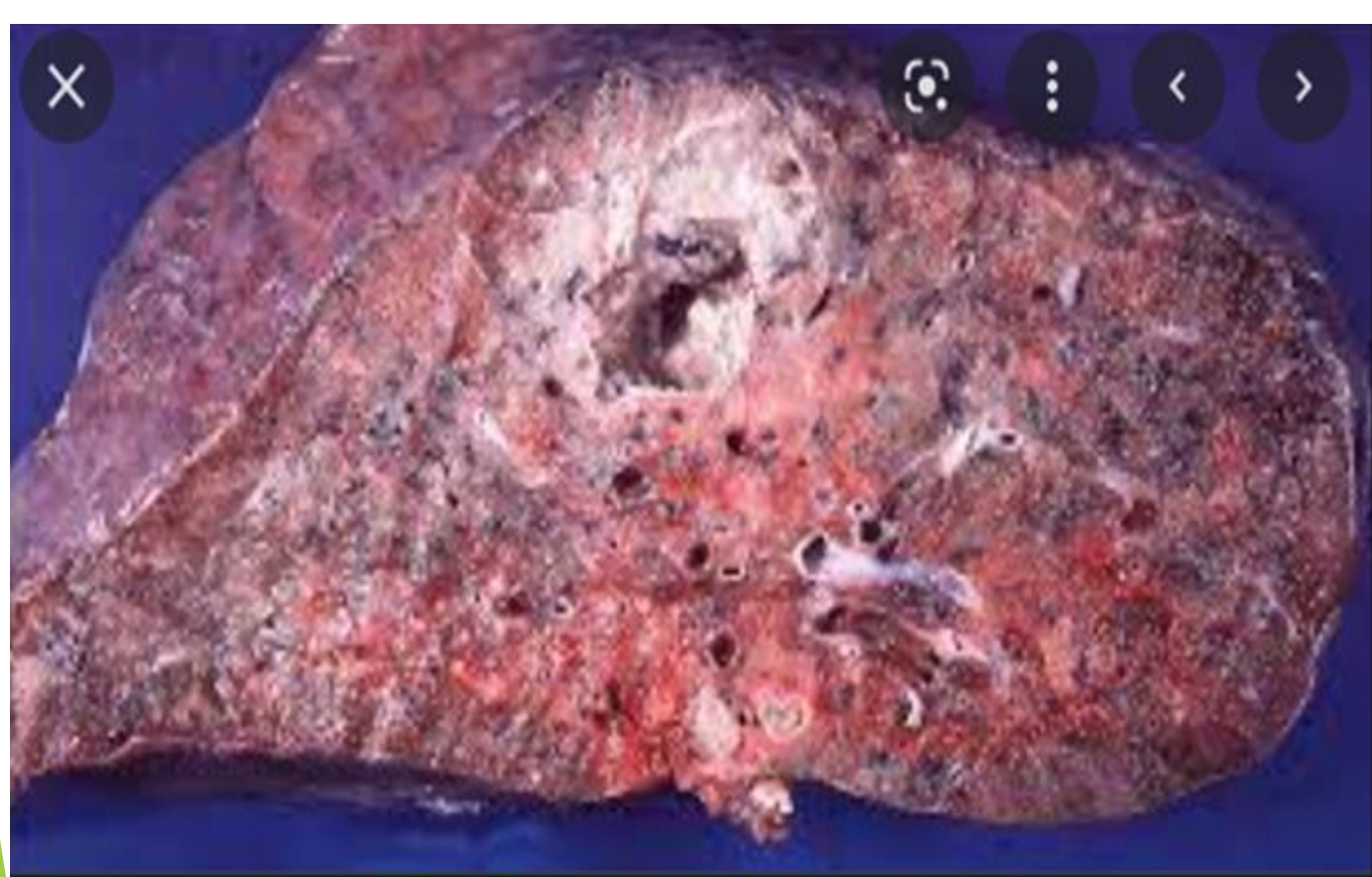BRONCHIECTASIS



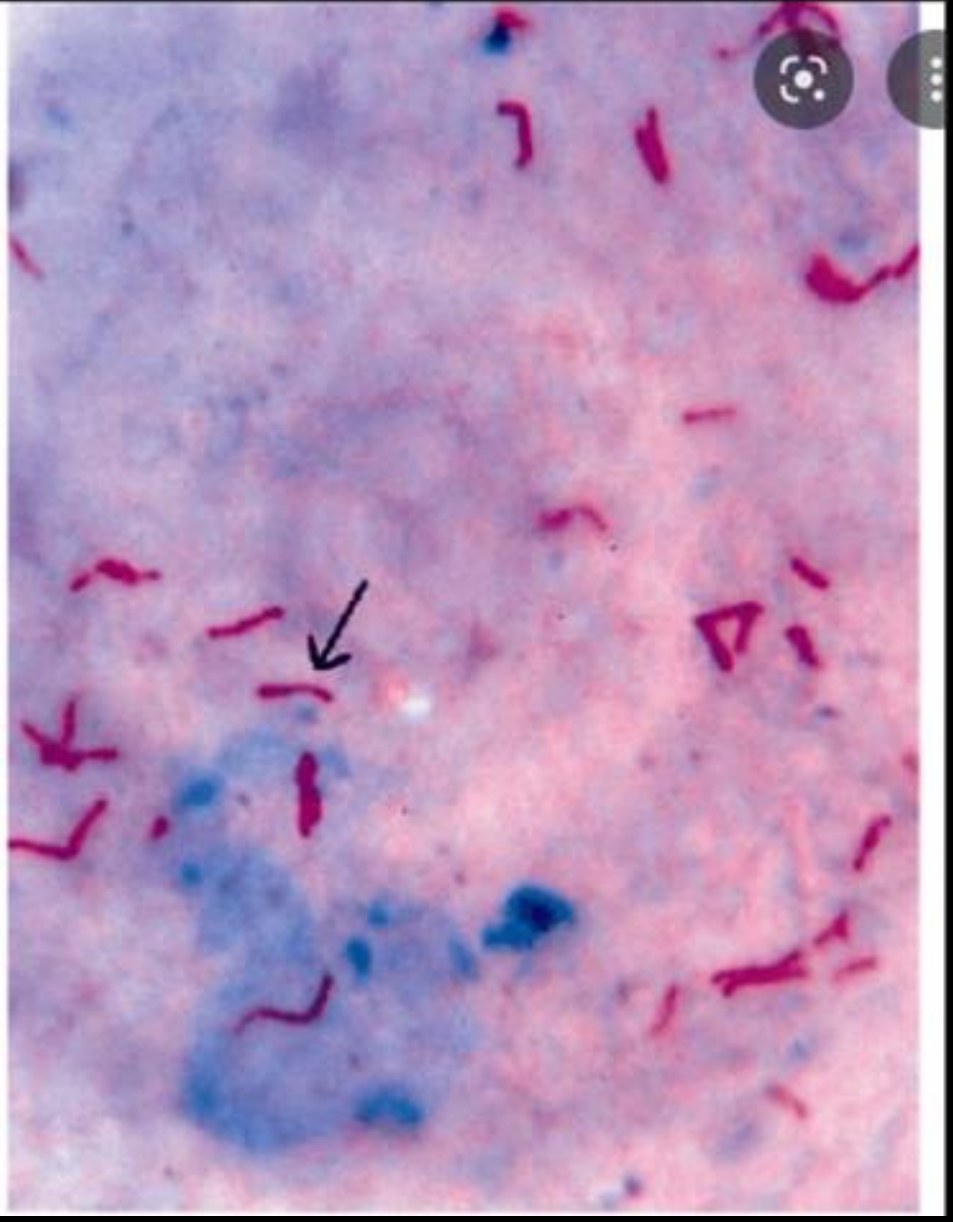
Pseudomonas aeruginosa



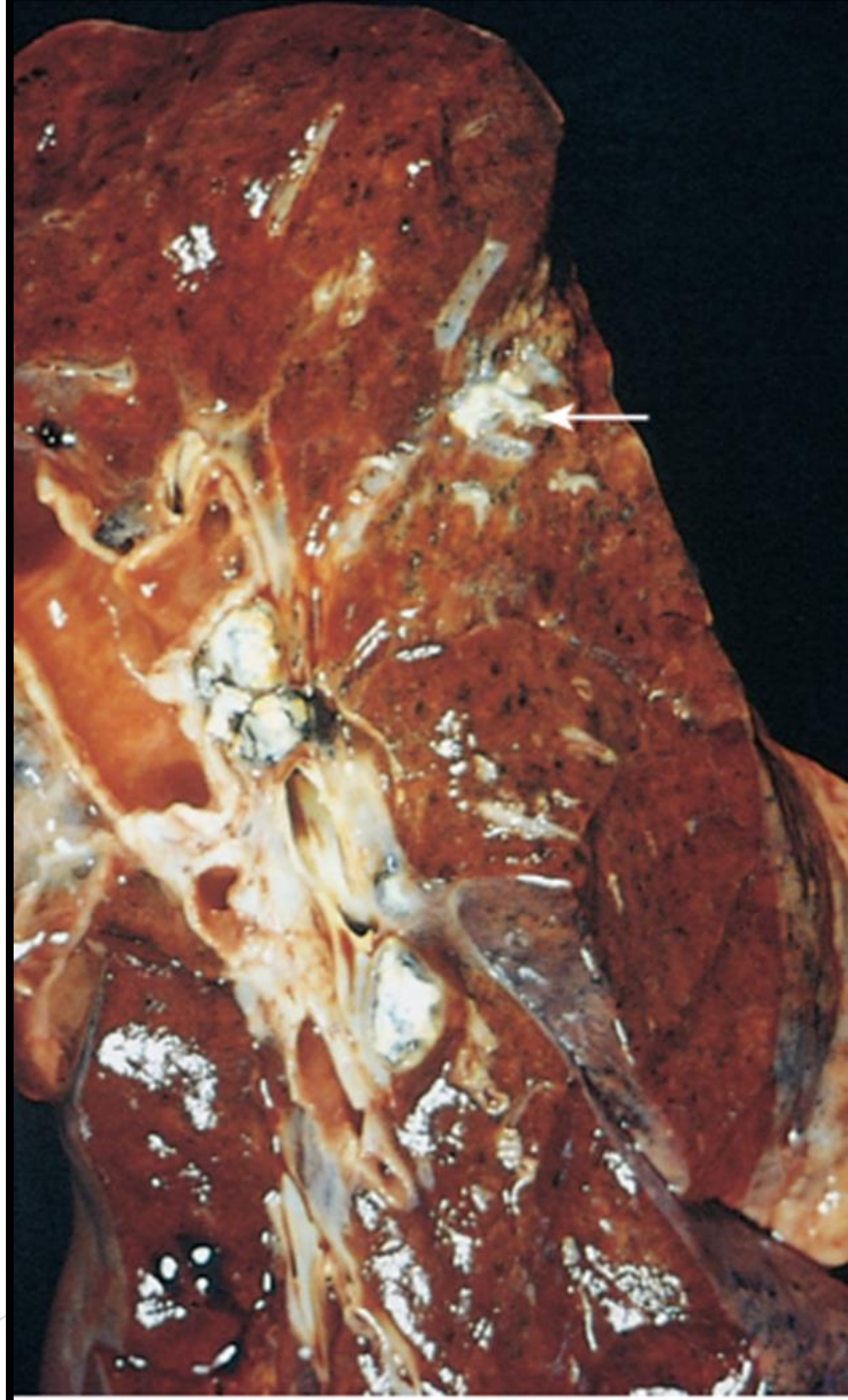
Resolution

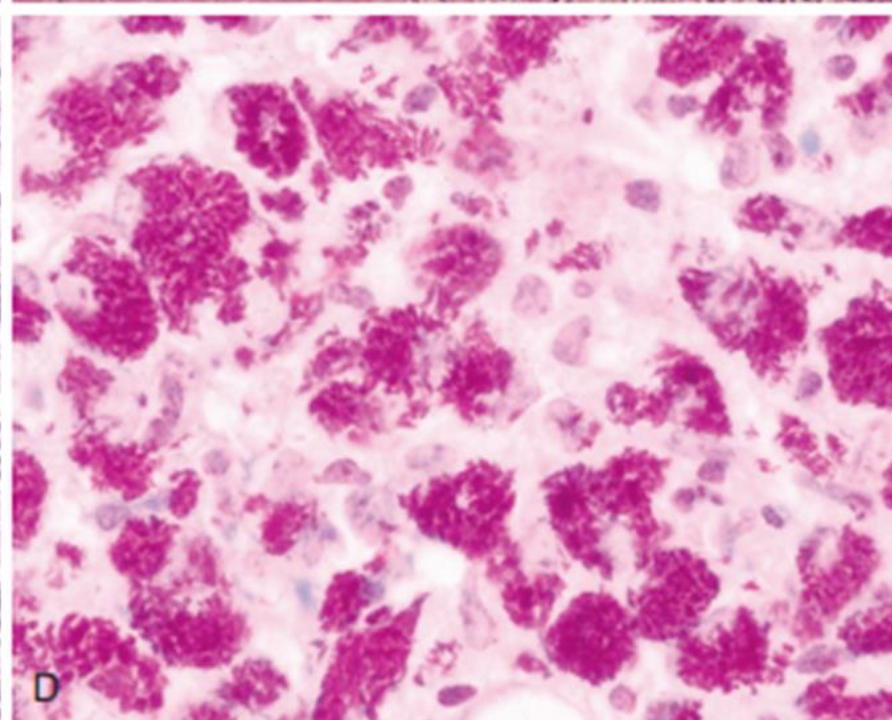
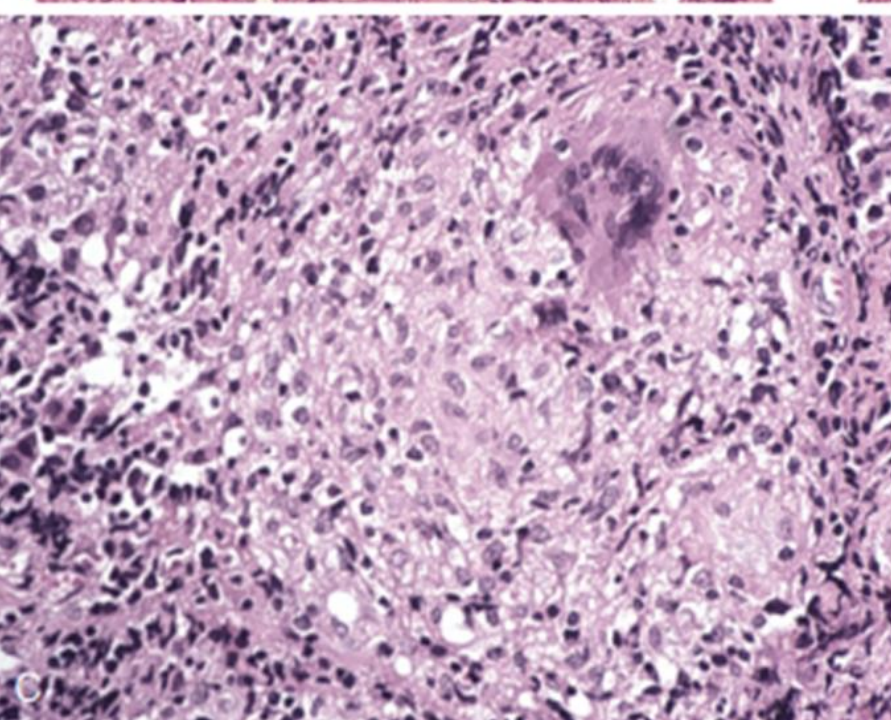
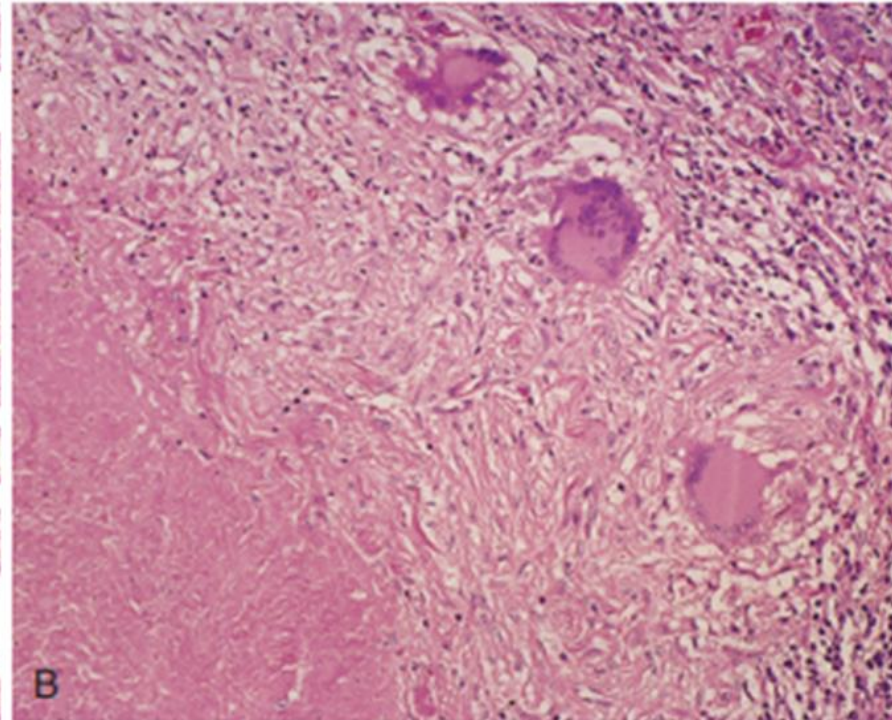
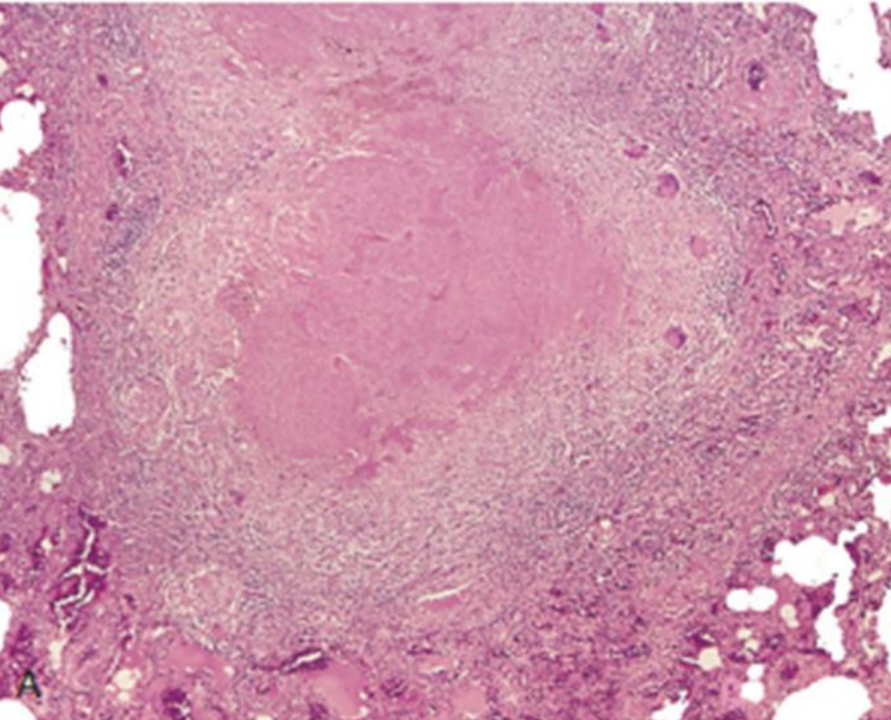


Lung Abscess

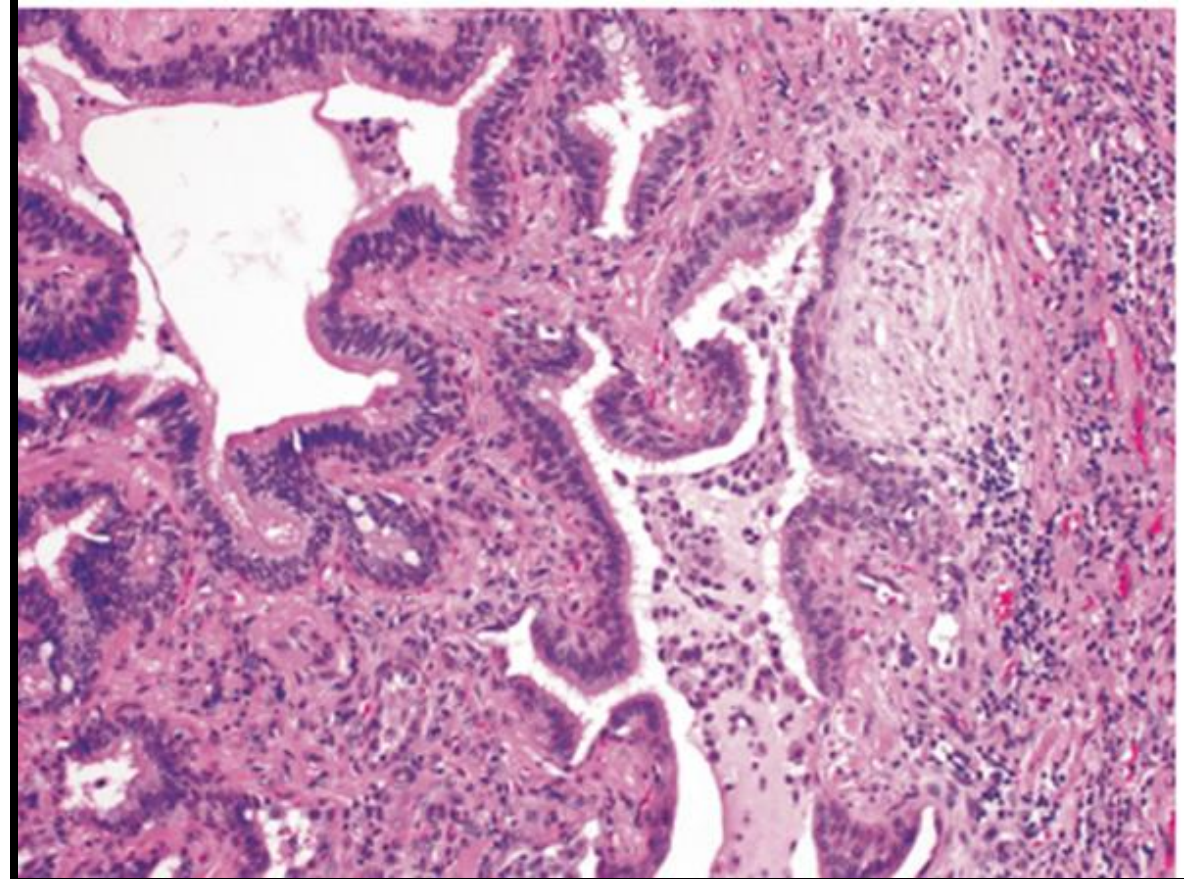
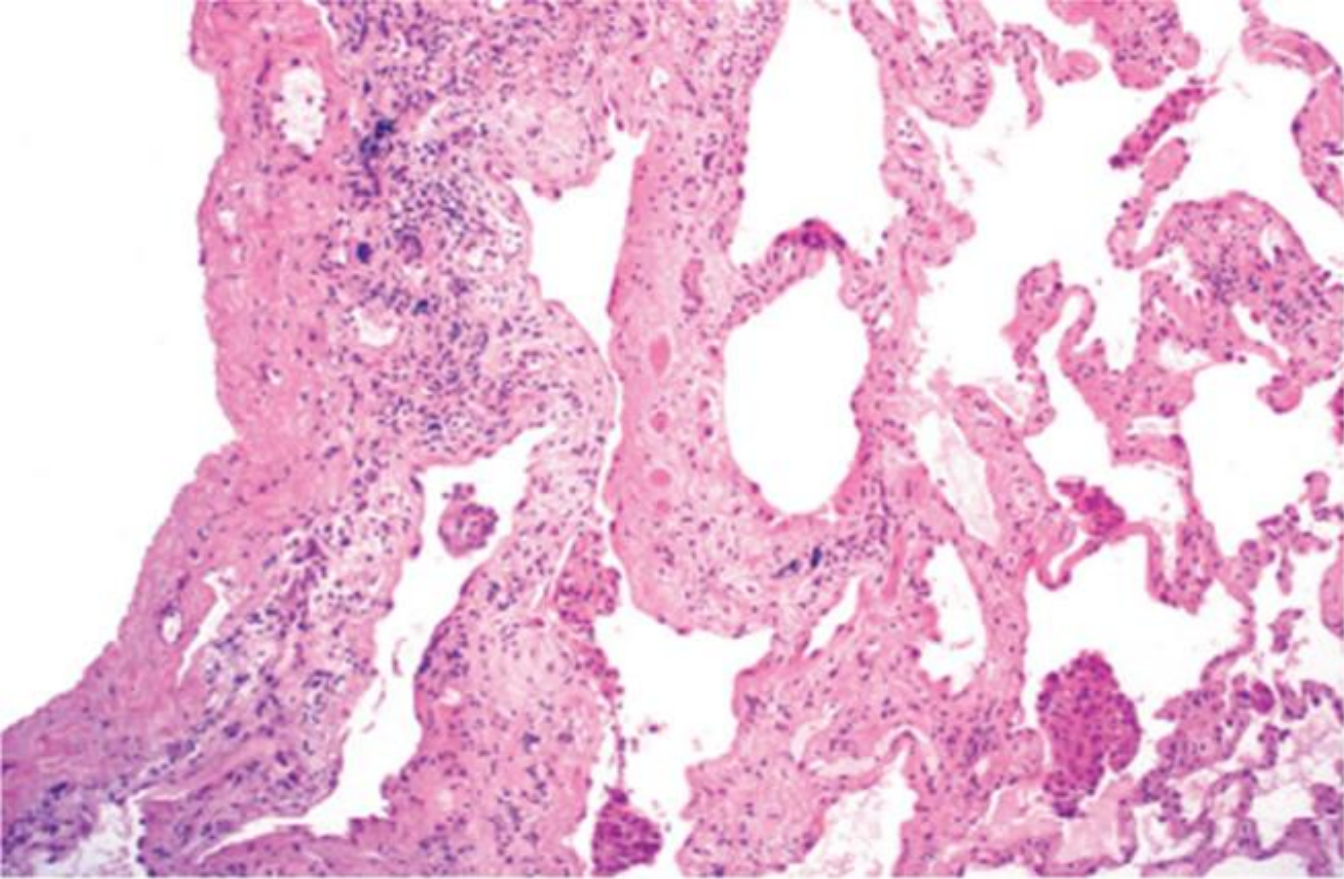


Ghon complex
Tuberculosis



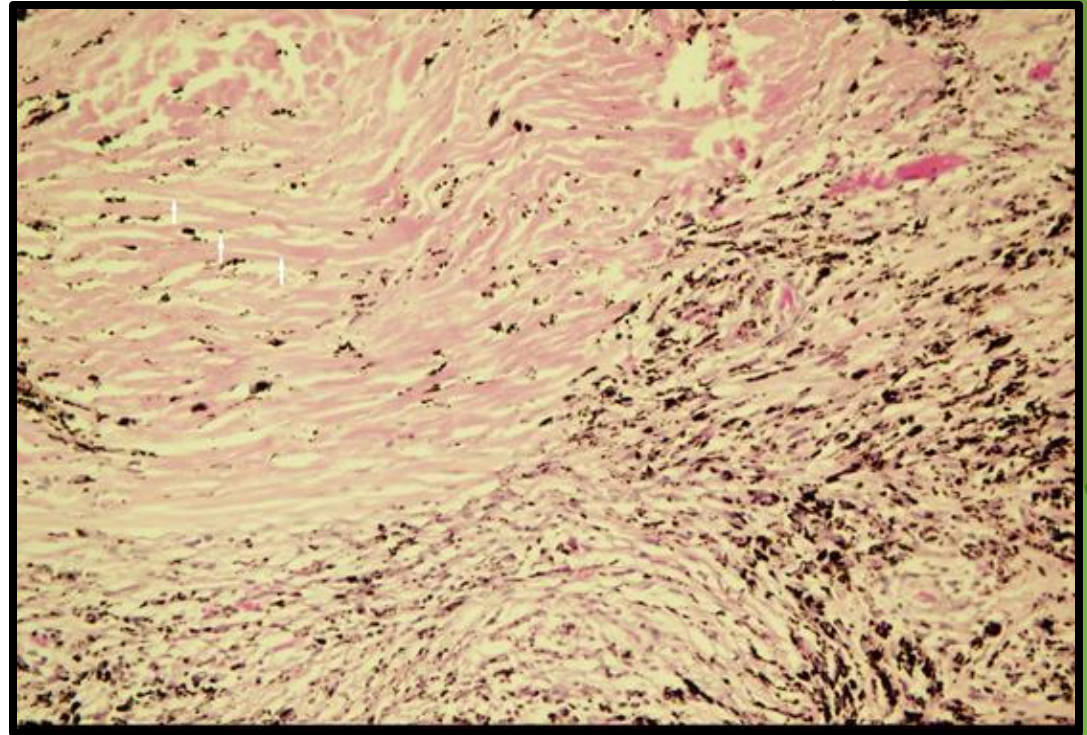
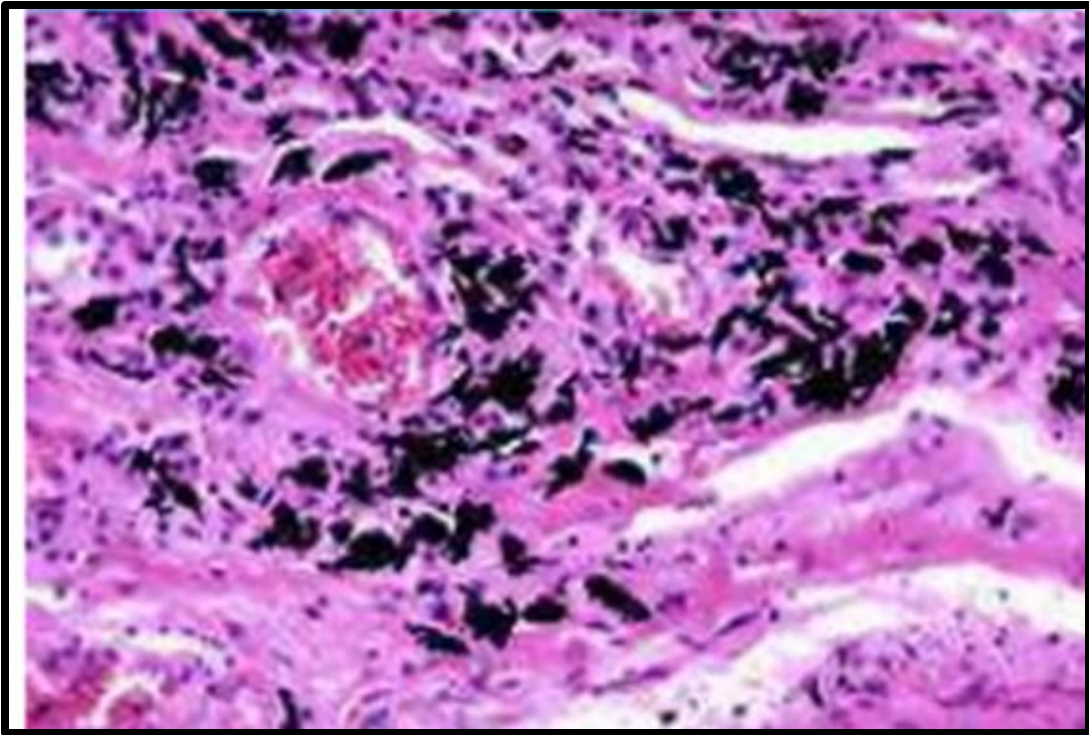


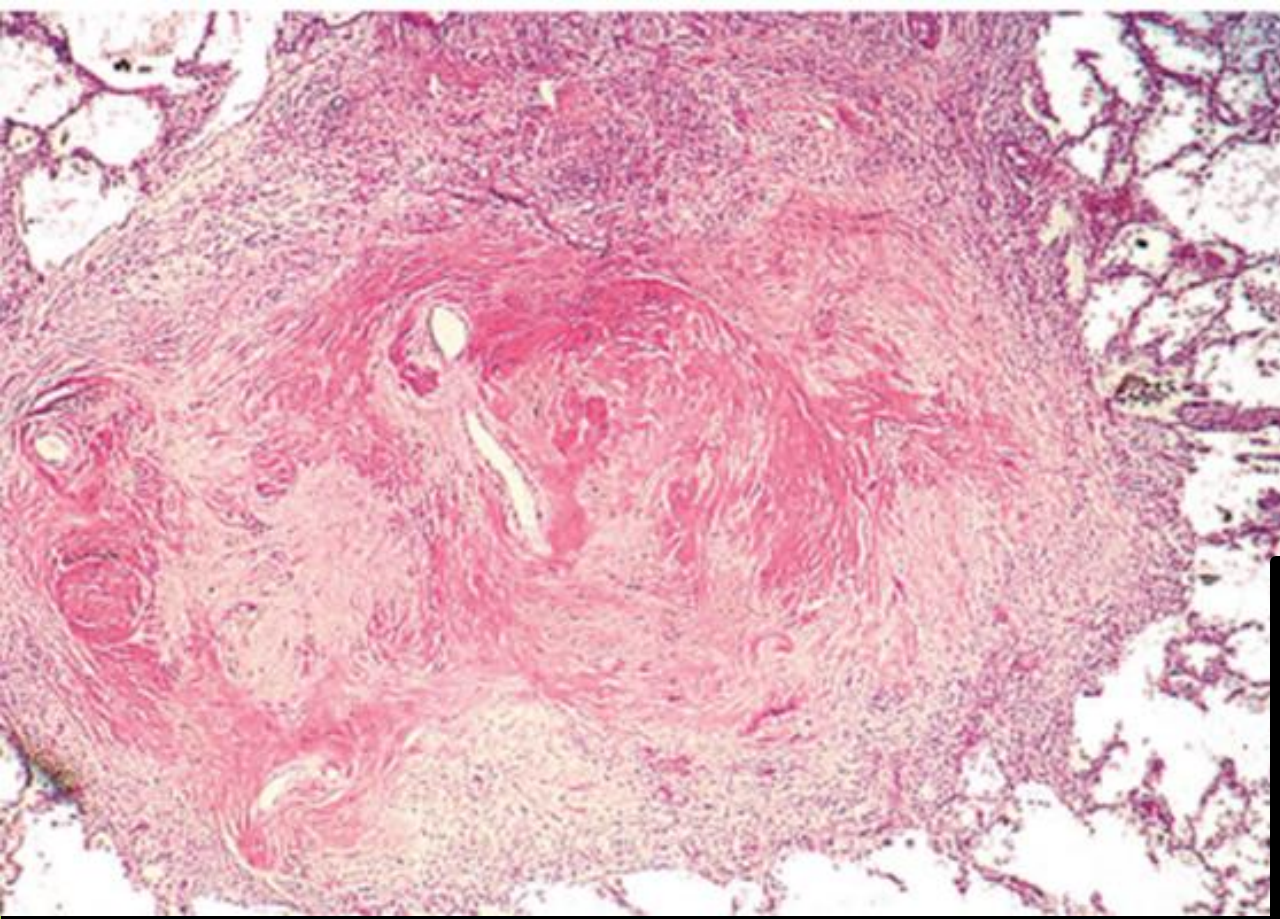
Tuberculosis



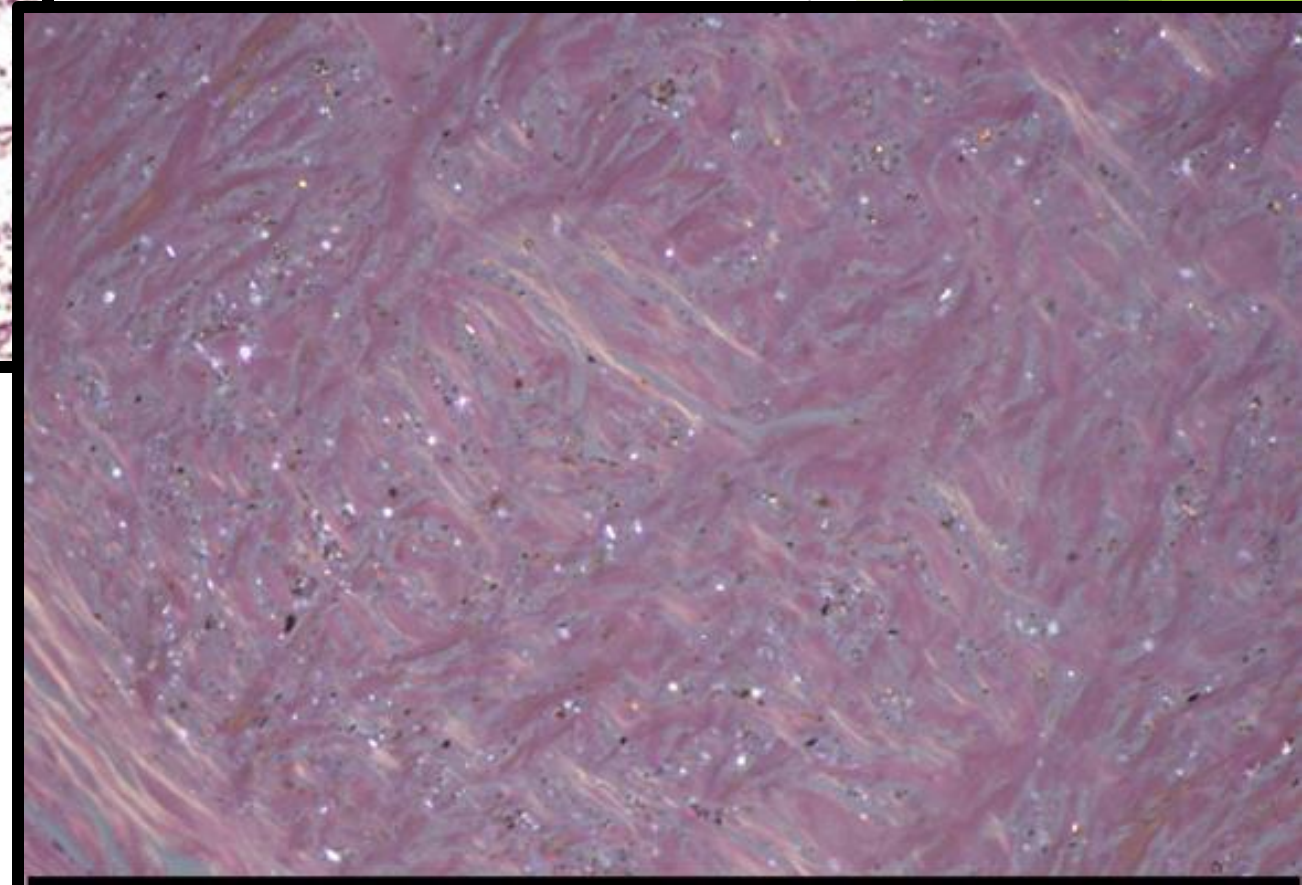
Idiopathic Pulmonary Fibrosis

Pulmonary anthracosis

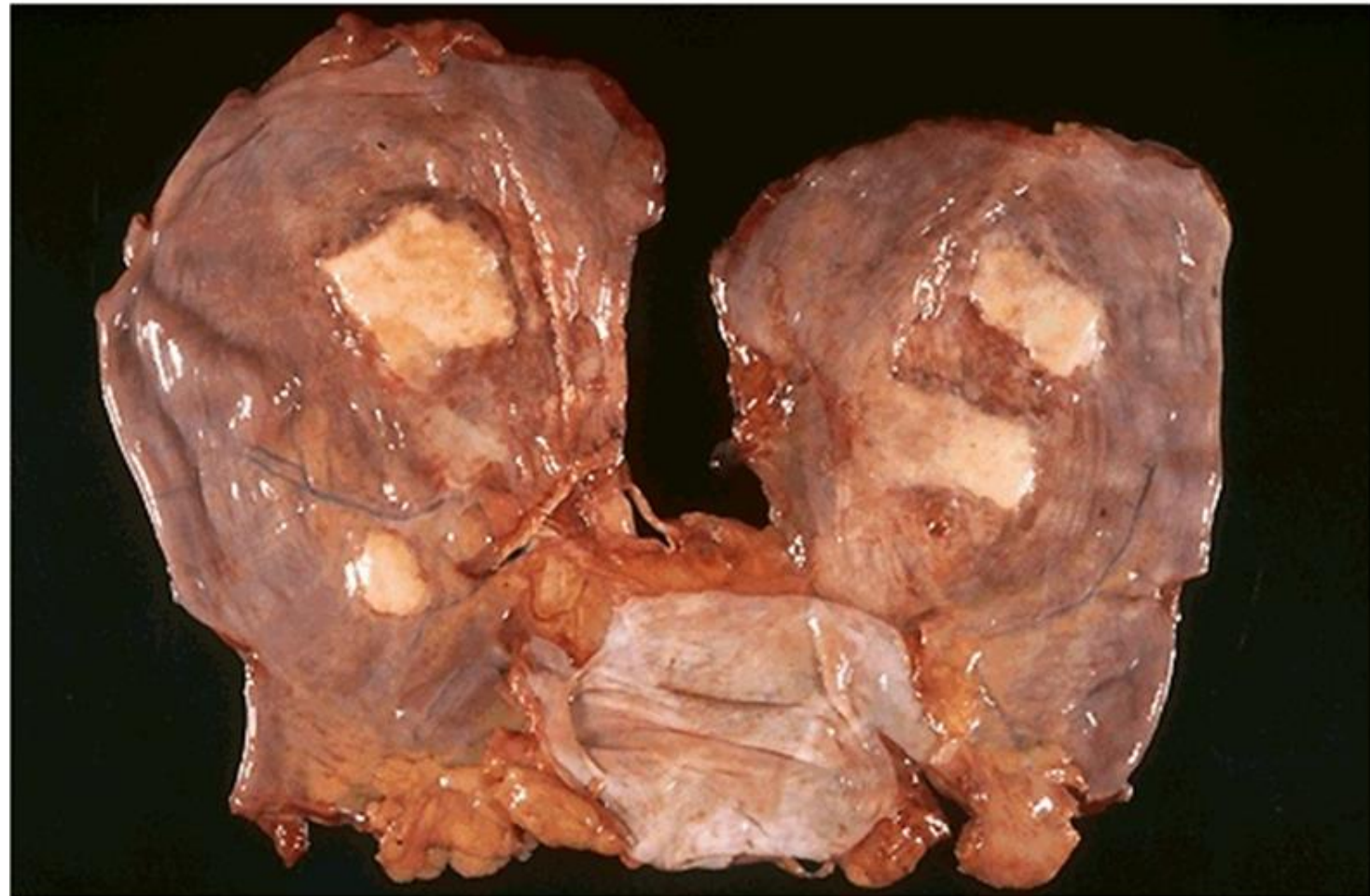
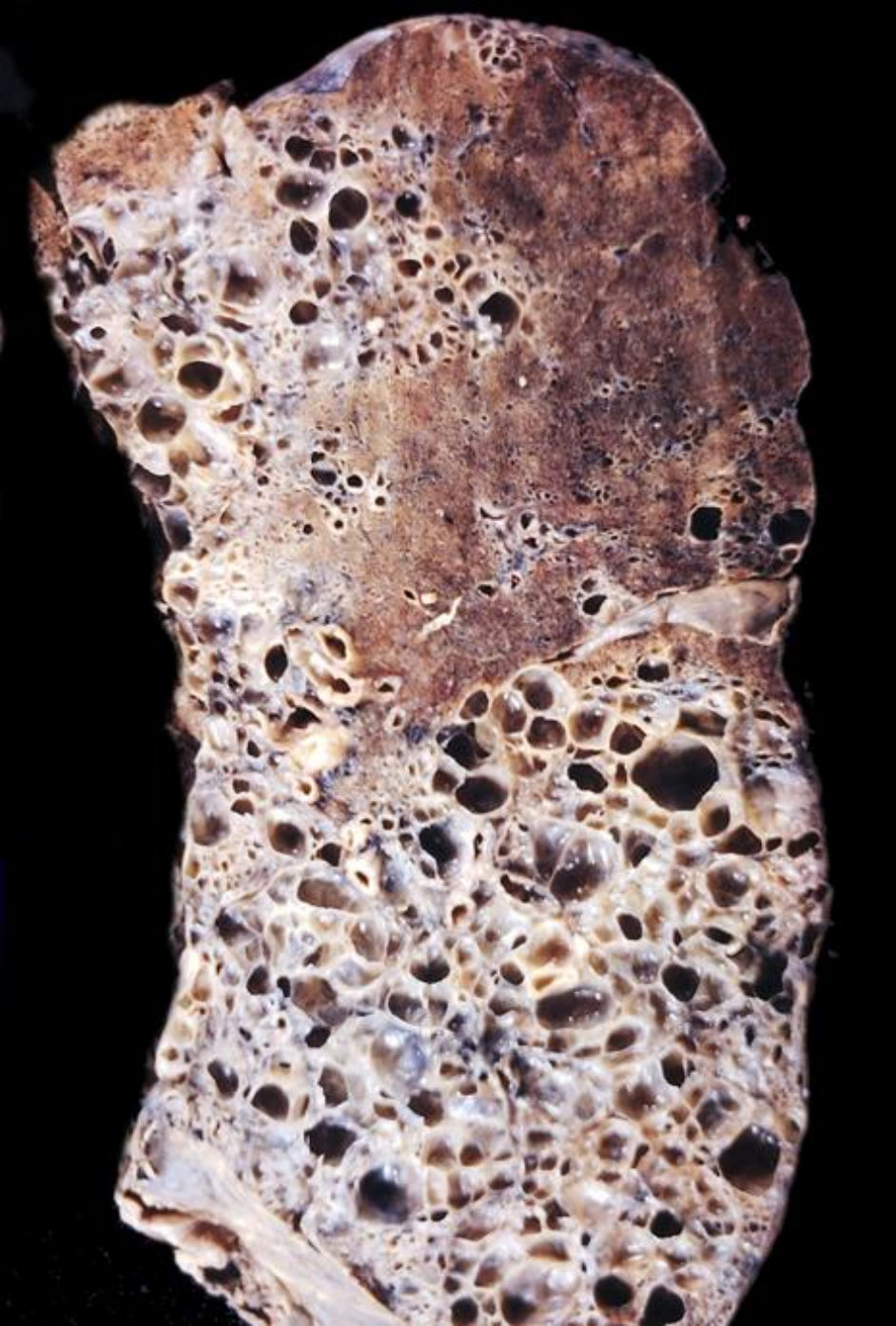



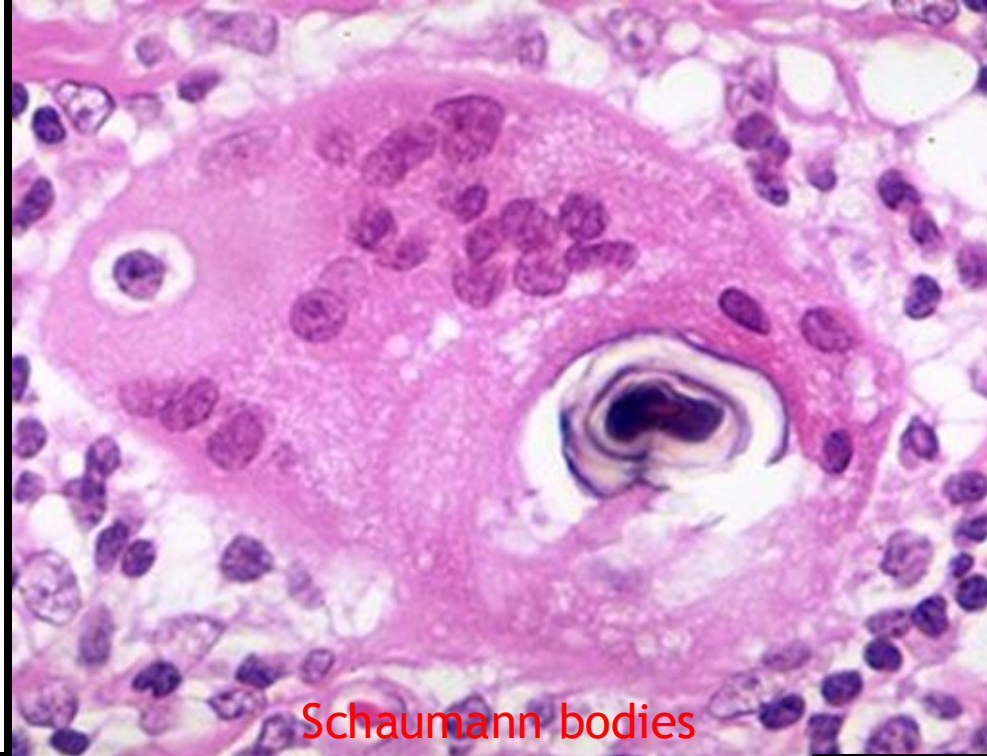
Silicotic nodules



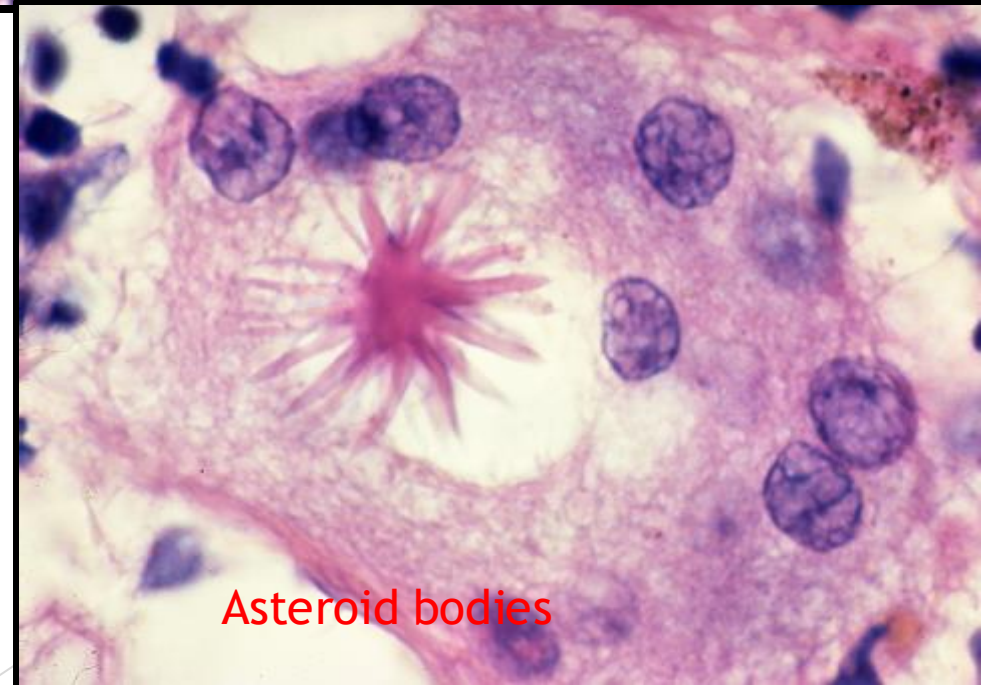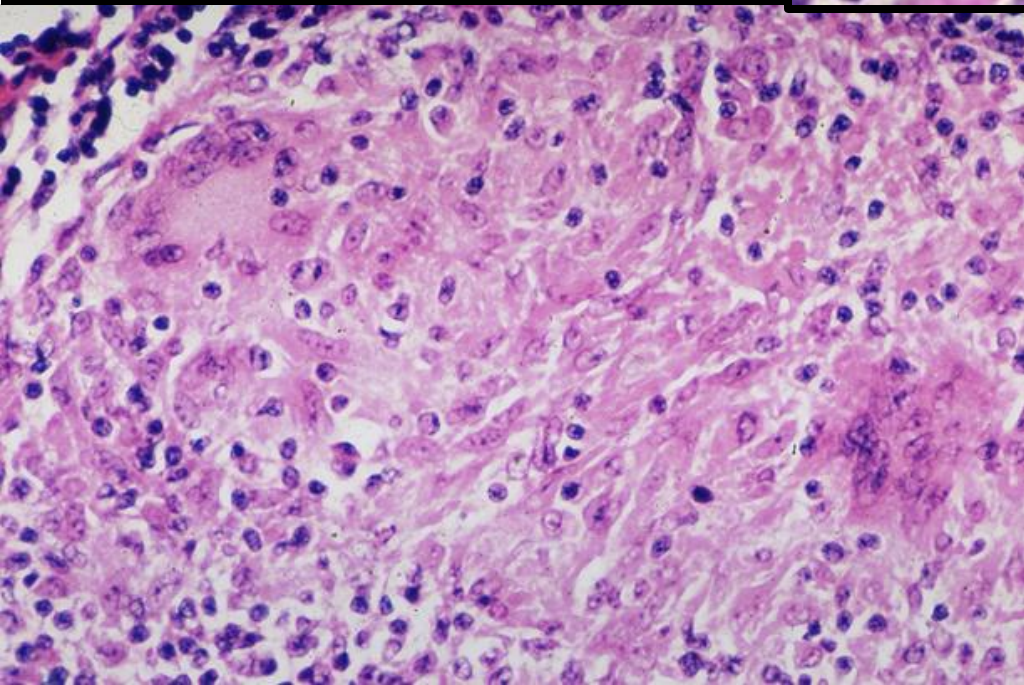
Asbestosis



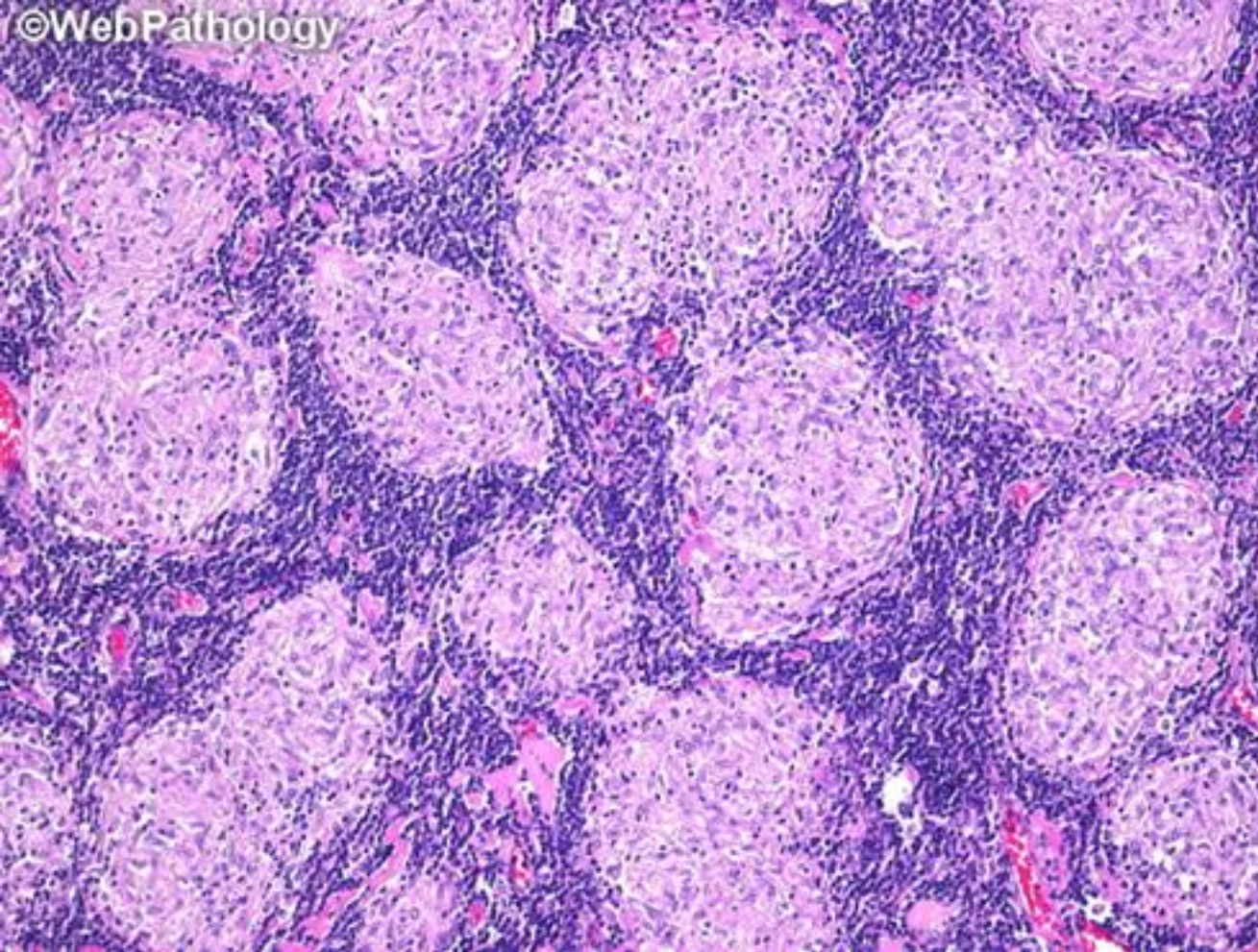
Sarcoidosis



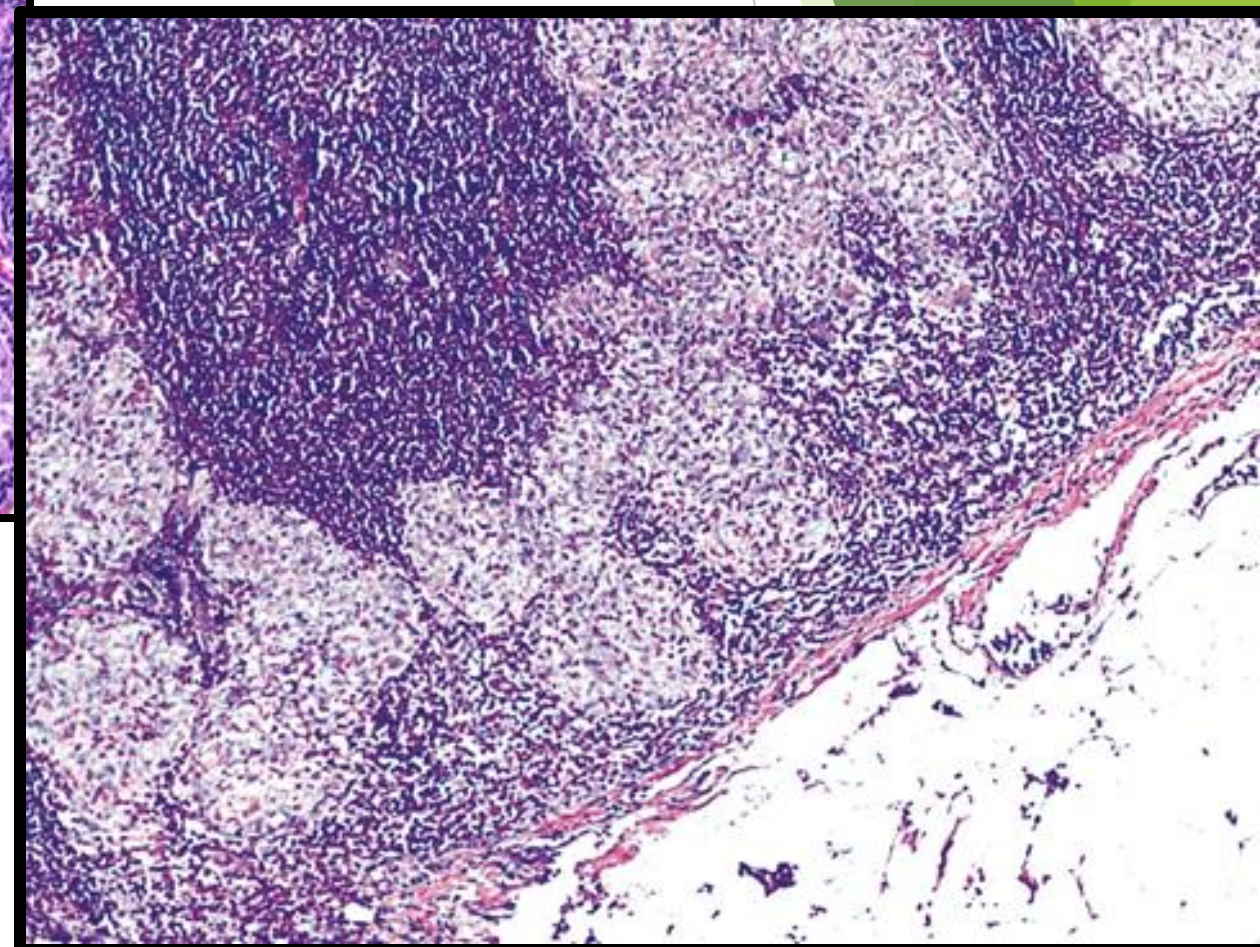
Schaumann bodies



Asteroid bodies



Sarcoidosis



The background features abstract, overlapping geometric shapes in various shades of green, ranging from light lime to dark forest green. These shapes are primarily located on the right side of the frame, creating a modern, layered effect. The rest of the background is plain white.

Thank you

Good luck