

Gynaecological exam

General exam

Vital signs

Thyroid examination

Abdominal examination

Before the vaginal examination :

Ask for permission and counselling

Chaperone

Privacy

Sterile instruments

ولم أجِدِ الْإِنْسَانَ إِلَّا ابْنَ سَعِيدٍ ... فَمَنْ كَانَ اسْتَعَىٰ كَانَ بِالْمَجْدِ أَجْدَرًا ،
وبالرهمة العلياءِ يرتقى إلى الغلا ... فَمَنْ كَانَ أَرْغَىٰ هَمَّتْ كَانَ أَظْهَرًا ، ولم يتأخر
مَنْ يريءُ تقدماً ... ولم يتقدم مَنْ يريءُ تأخراً .

- ابن هانئ الأندلسي ▼

Vaginal examination :

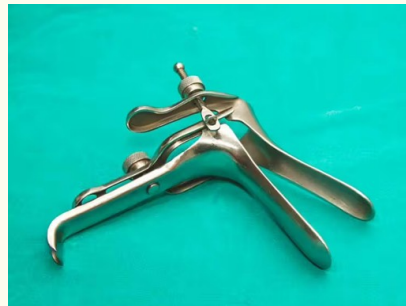- examination of the vulva if there is visible masses or discolouration
- examination of the cervix
- examination of the vagina

Univalve speculum
(simis)

- used mainly during surgery
- we can use in the clinic in case of prolapse

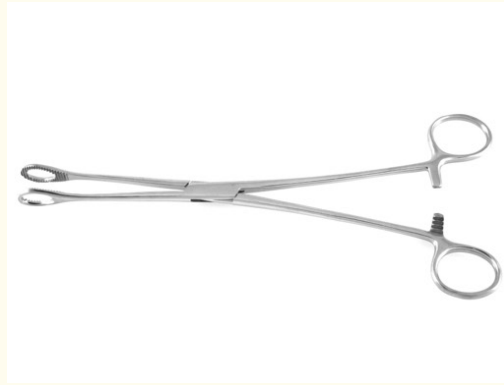


Bivalve speculum
(casco)
used mainly in
clinics

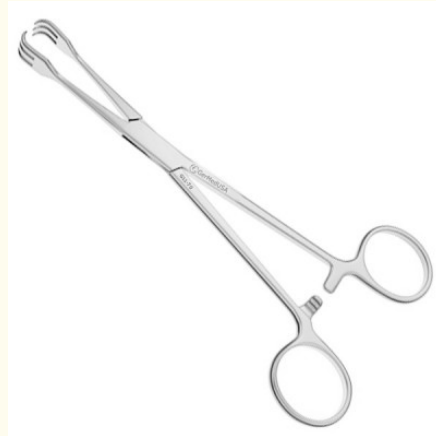

DNC : dilation and curettage

Atrumatic forceps (oval forceps)



Traumatic forceps
Tenaculum
More stable
May cause trauma

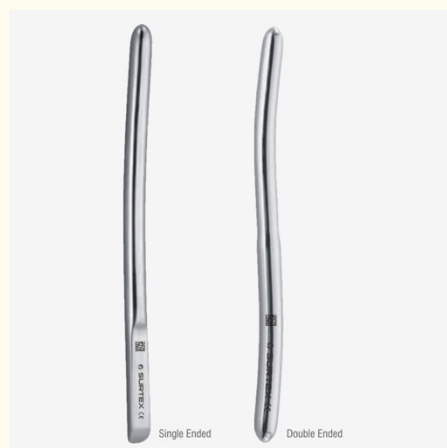

uterine sound
Measure the size and the direction of the
uterus

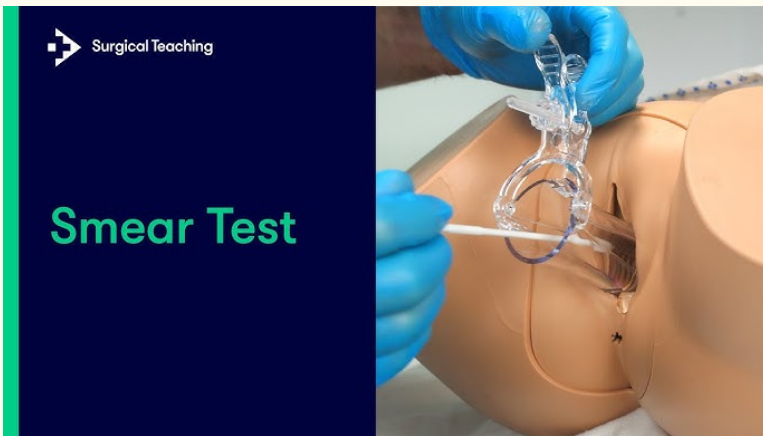



Perforation is the most common
complication on the uterus

Heger's dilater



Curet (traumatic and non blunt)



Pap smear



Kidney dish to evacuate the bladder before the procedure

Pre request before the use of instruments :
vacuum and forceps

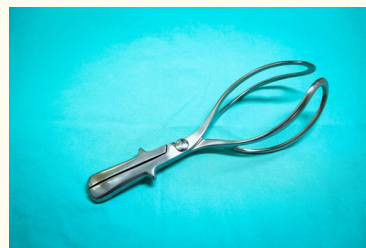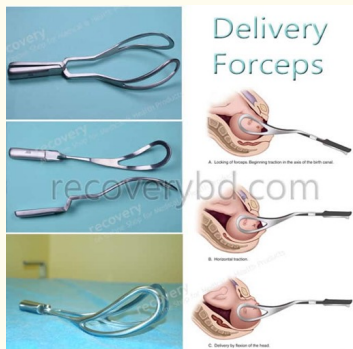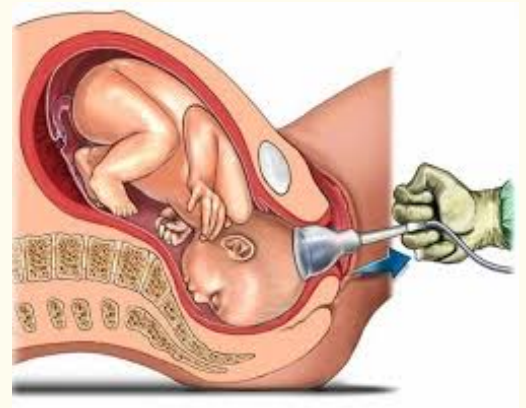
at fully dilated cervix , engagement of the head , ruptured membrane , experience how to use the instruments

When we use the vacuum we should know the position to keep flexion and to know where to put the vacuum (posterior Fontanell

used only After 34 weeks of gestation

Indication :

- failure to progress in the second stage of labour
- Maternal disease (cardiac disease or neurological disease) to shorten the second stage of labour
- Fetal distress



forceps


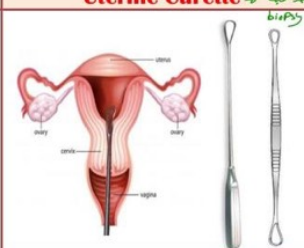

Notes :

Engagement assessed by rule of five which is abdominal examination

Forceps used for after coming head

Contraindicated in face presentation >> vacuum .

Instruments in OBGYN

ANESTHESIA NEEDED			
	Dilator	Uterine Curette → <i>نقطة بيضة biopsy</i>	Doyen Retractor <i>retraction (ليونة)</i>
	 <p><i>Tramatic</i> <i>لازم أن يكون اشارة</i> <i>retro-or ante-verted</i></p>		
Uses	<ul style="list-style-type: none"> - Dilatation preliminary to another operation <i>نوع Int. & ext. os</i> 	<ul style="list-style-type: none"> - for endometrial biopsy (Fractional curettage) or evacuation of products of conception 	<ul style="list-style-type: none"> - Used to retract the dissected urinary bladder down from the lower uterine segment during Cesarean section, to protect it and prevent bladder injury. <i>transverse or vertical opening</i>
Comp.	<ul style="list-style-type: none"> - Shock: if used without anesthesia. - Perforation of the uterus - Lacerations of the cervix - Introduction of Infection. - Anesthetic complications. 	<p>In addition to complications of dilatation, over curettage may lead to Asherman's syndrome.</p> <p><i>need anesthesia # GA</i></p>	<ul style="list-style-type: none"> <i>بنوع CS Vertical lower (طولة من تحت الورك)</i> <i>Transverse</i> <i>upper</i> <i>Doyen</i>





NB: In case of uterine perforation :

- Stop procedure
- Give antibiotics
- Observe vital signs
 - ↳ If normal : Discharge the patient
 - ↳ If deteriorates or intestinal contents appear through Cx : Exploratory laparotomy and proceed.

Notes of Dr. Nadine's lectures by Reem Abdelhakim

www.nadine-alaa-sherif.weebly.com

Instruments in OBGYN

NO ANESTHESIA NEEDED				
	Uterine Sound	Cusco speculum	Sim's speculum	Volsellum
	 <p><i>graduated</i></p>	 <p><i>bivalve</i></p>	 <p><i>Sim's position</i> <i>uni-valve</i></p>	 <p><i>Multiple</i> → <i>single</i> <i>multiple toothed</i> <i>single toothed</i></p>
Uses	<p>(size & direction of ut.)</p> <ul style="list-style-type: none"> - Measures the length of the uterine cavity preliminary to IUD insertion, or any procedure as dilatation <i>x u/s guidance #</i> 	<p><i>لبنية بيضة</i></p> <ul style="list-style-type: none"> - Used during gynecological examination to visualize the cervix and lateral vaginal walls. <i>No dilatation → No GA of cervix</i> 	<ul style="list-style-type: none"> - Used to retract posterior vaginal wall to expose the anterior one in case of vesicovaginal fistulae. Patient should lie in sim's position. 	<ul style="list-style-type: none"> - Used to hold and steady the firm (gynecology) cervix for any procedure of IUD insertion.
Comp.	<p>Uterine Perforation known to bladder, bowel</p> <p><i>Perforation</i></p>	<p><i>لا ينسحبه ولا ينسحبه</i> <i>Virgins</i> <i>cervical</i> <i>CA or Polyps</i></p> <p><i>Major</i> <i>Major</i></p>	<p><i>بمنطقة فقط بالميات</i> <i>Prolaps</i> <i>cytocele / rectocele</i></p> <p><i>دلا دائما بالويال فقط</i></p>	<p>May be traumatic to the cervix, causing lacerations especially in single tooth volsellum</p>

Notes of Dr. Nadine's lectures by Reem Abdelhakim

www.nadine-alaa-sherif.weebly.com