

# Archive Wateen group 3


---

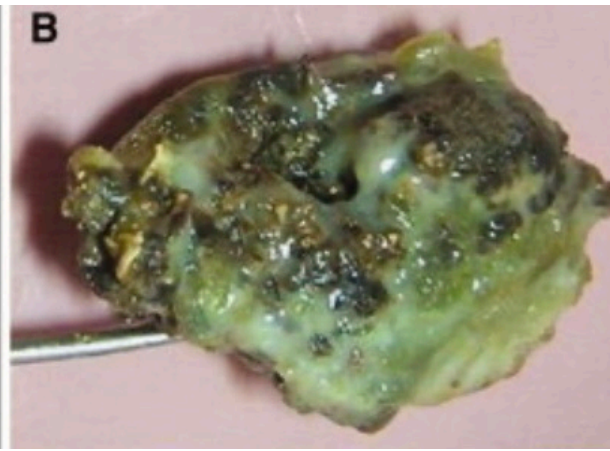
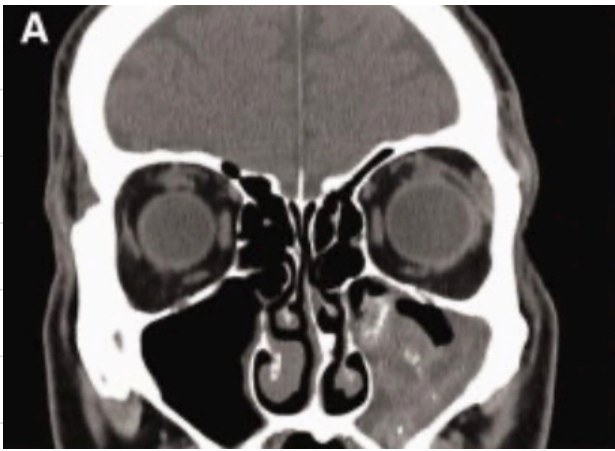
---

---

---

---



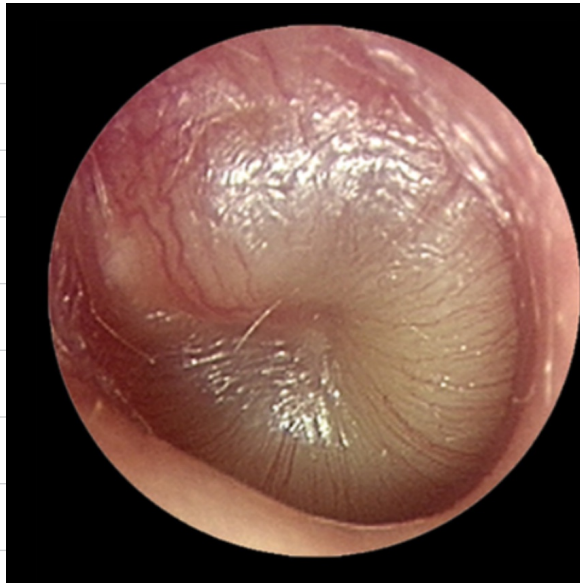


①

Q<sub>1</sub>: diagnosis → Sinus fungal ball

②

Q<sub>2</sub>: Treatment → FESS



Q 1

Q 1 : diagnosis  $\rightarrow$  Lt. ear bulging, otitis media

Q 2

Q 2 : Rinne/Weber  $\rightarrow$  Lt.  $\ominus$  / Rt.  $\oplus$  / to left

Q 3

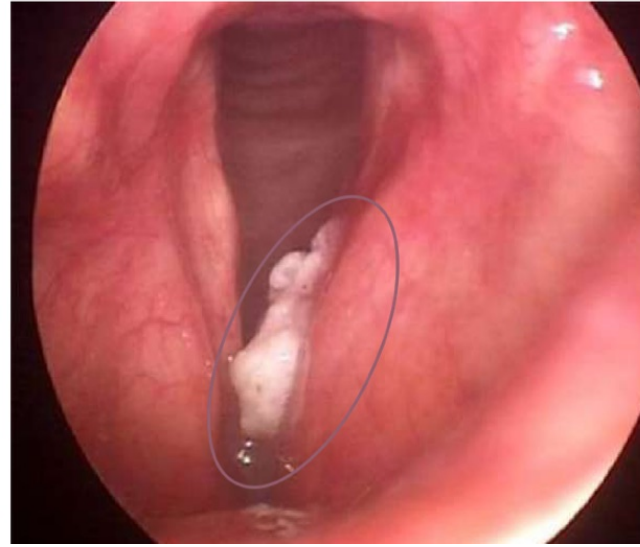
Q 3 : management  $\rightarrow$  Myringotomy + systemic antibiotic

Q 4

Q 4 : Tympanogram  $\rightarrow$  Rt.  $\rightarrow$  A

Lt.  $\rightarrow$  B with normal ECU

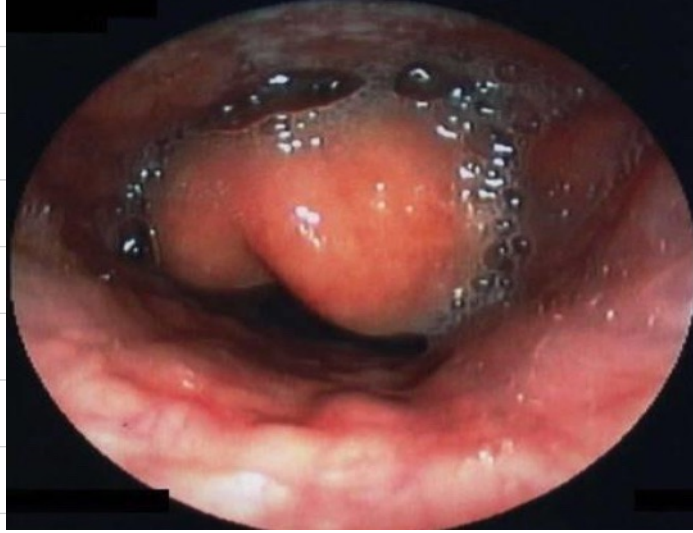
# Laryngeal carcinoma



Q 1: staging  $\rightarrow$  T1a

Q 2: all management except  $\rightarrow$  total laryngotomy

Hx → stridor 3 days

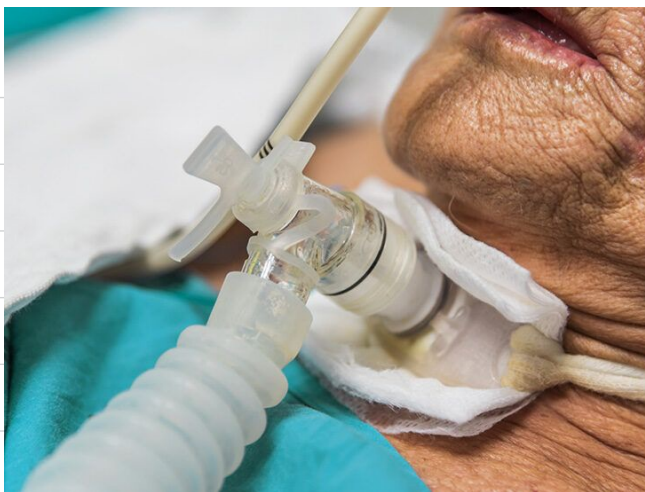

Ⓐ

Q 1 : all can be DD except : Laryngeomalacia

Ⓡ

Q 2 : next step management : secure airway



①

Q<sub>1</sub>: most common complication → Bleeding

②

Q<sub>2</sub>: All the following are true except →

① Position well popped up post op.

② Regular suction & deflate cuff.

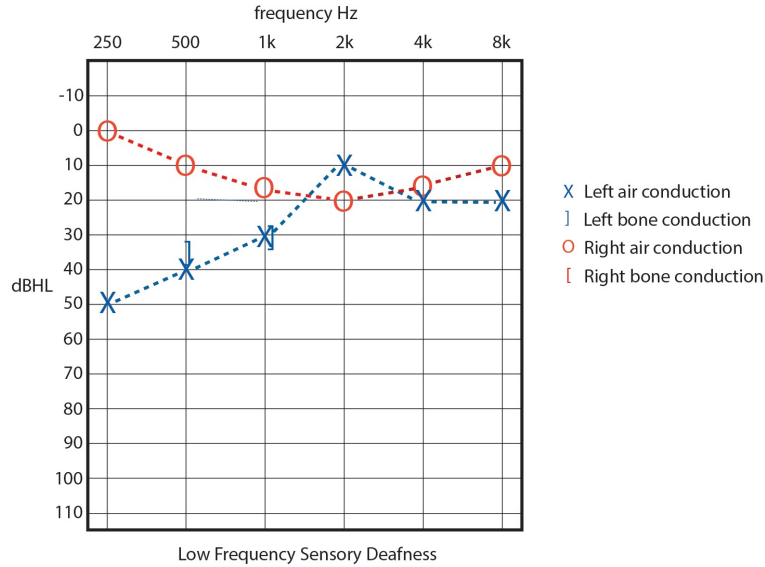
③ You can do it any tracheal ring (T<sub>1</sub>-T<sub>4</sub>)

④

⑤ In adult incision & excision allowed

# Hx of vertigo

female



Q 1: diagnosis  $\rightarrow$  Lt. SNHL

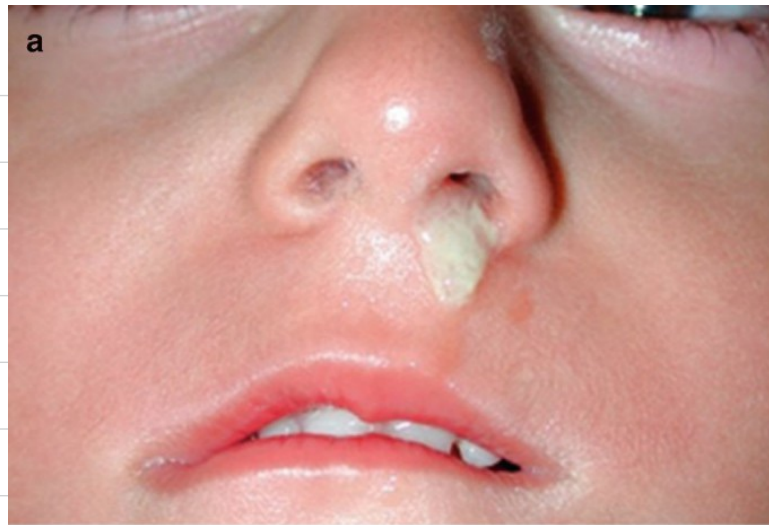Q 2: Renni & Weber  $\rightarrow$  Lt (+) Rt (+) weber to Rt

Q 3: describe vertigo  $\rightarrow$  fluctuating more than 20<sub>min</sub>

Hx

nasal discharge

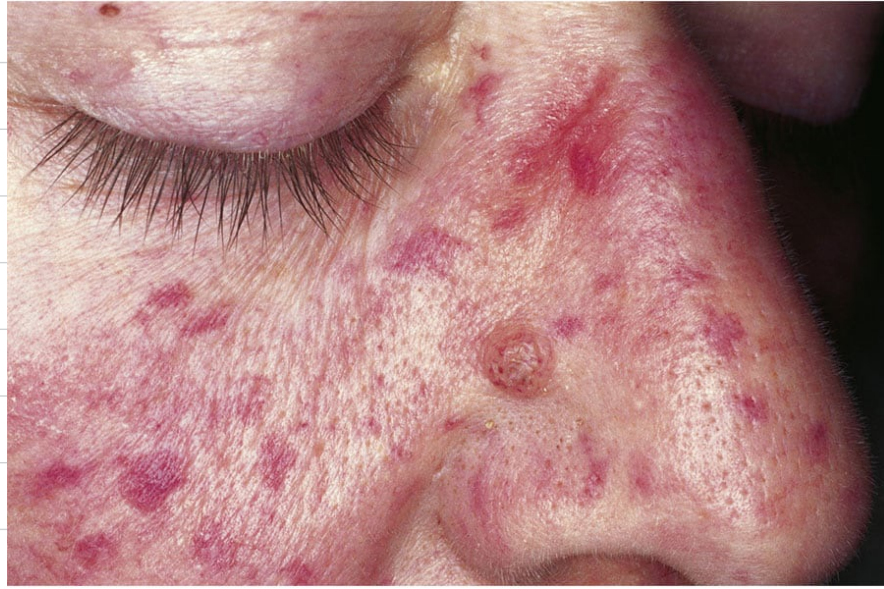+  
foul smell



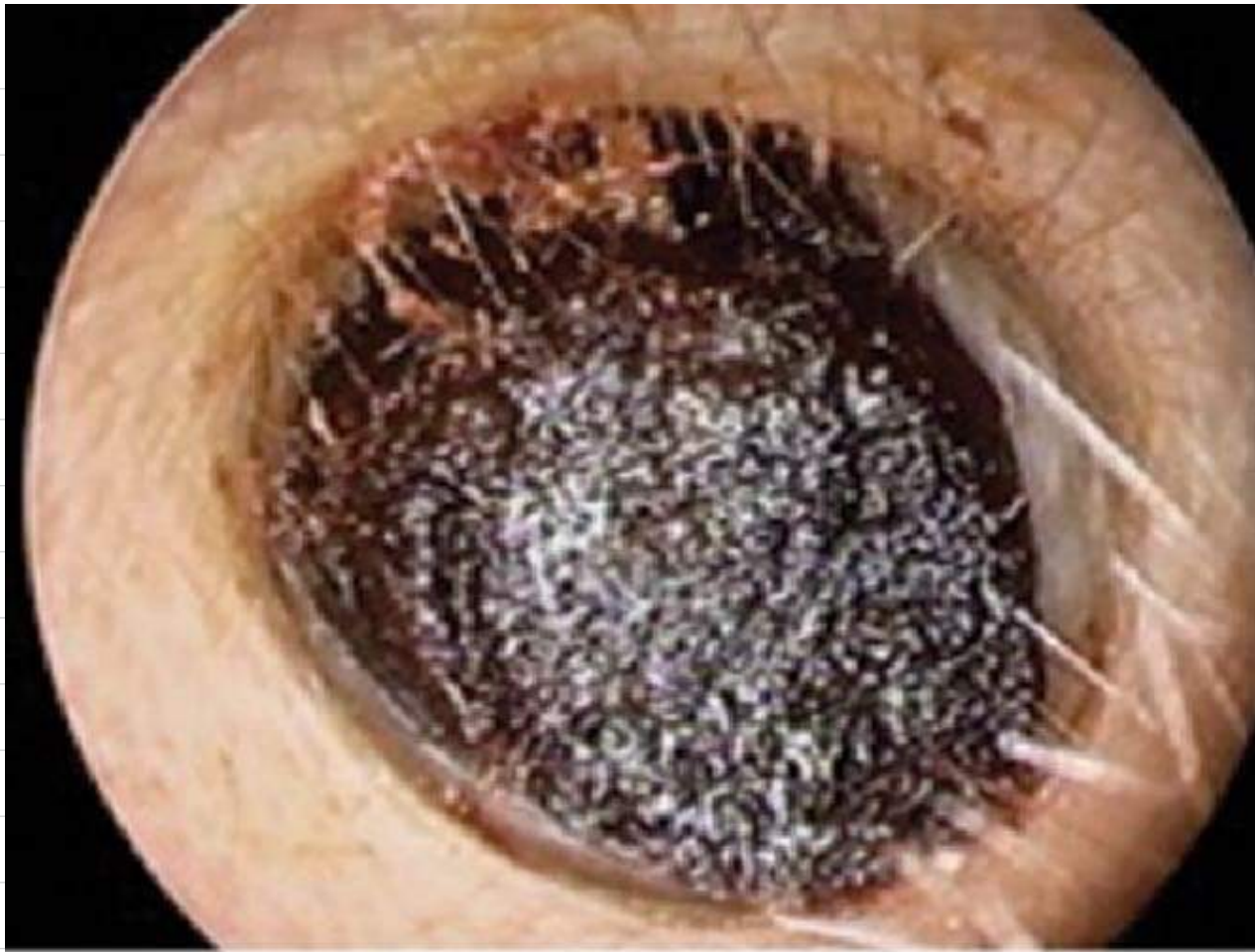① : all the following can be DD except :  
bilateral choanal atresia

② : if the cause was foreign body, all false  
except : (one true)





Q : management → septodermo plasty



Q1<sup>20</sup> Diagnosis of wax impaction

Q2<sup>21</sup> Treatment of Suction